M. H. Bertling M.D.

Digitized by the Internet Archive
in 2025

https://archive.org/details/bwb_C0-AMV-340

SURGICAL TREATMENT

A Practical Treatise
on the Therapy of Surgical Diseases for the Use of
Practitioners and Students of Surgery

BY
JAMES PETER WARBASSE, M.D.
Fellow of the American College of Surgeons
American Medical Association
American Academy of Medicine
New York Academy of Medicine
Surgeon to the Wyckoff Heights Hospital, Brooklyn, New York
Formerly Attending Surgeon
to the Methodist Episcopal Hospital, Brooklyn, New York

IN THREE VOLUMES
WITH 2400 ILLUSTRATIONS

VOLUME II

PHILADELPHIA AND LONDON
W. B. SAUNDERS COMPANY
1919

Copyright, 1919, By W. B. Saunders Company

Reprinted June, 1919

PRINTED IN AMERICA

CONTENTS

	Page
Treatment of Injuries and Diseases of the Head	17
The Scalp	17
The Skull	26
Operations upon the Skull	26
Diseases of the Cranial Bones	41
Intracranial Injuries and Diseases	42
Concussion of the Brain	52
Contusion of the Brain	52
Compression of the Brain	53
Intracranial Hemorrhage	54
Wounds of Intracranial Structures	61
Diseases of Meninges and Ependyma	65
Inflammations of the Brain	73
Tumors of Meninges and Brain	75
Operations on Hypophysis of Brain	82
Encephalocele	92
Hydrocephalus	94
Epilepsy	99
Traumatic Psychoses and Insanity	102
Intracranial Operations upon Fifth Nerve (Trigeminal)	105
Intracranial Operations on Auditory Nerve	110
Injuries and Diseases of Face	115
The Eye	115
Diseases of Eyelids	119
Wounds of Eyeball	121
Diseases of Conjunctiva	121
Diseases of Cornea	124
Diseases of Sclera	128
Diseases of Iris	129
Diseases of Ciliary Body	130
Diseases of Choroid	130
Diseases of Crystalline Lens	132
Diseases of Vitreous	134
Diseases of Retina	134
Diseases of Optic Nerve	135
Disorders of Orbital Muscles	135
Diseases of Lacrimal Apparatus	136
Diseases of Orbit	137
Operations on the Eye	138
Operations on the Eyelids	138
Operations on the Conjunctiva	149
Operations on the Cornea	152
Operations on the Iris	154
Operations on the Sclera	156
Operations on the Globe	157
Operations for Cataract	165
Operations upon the Eye Muscles	174
Operations on the Lacrimal Apparatus	177
The Nose	179
Injuries of the Nose	183
Infections of Nasal Cavities	186
Malformations of Nasal Septum	188
Empyema of the Antrum	195
Empyema of the Ethmoid Sinuses	197
Empyema of the Sphenoid Sinuses	198
Empyema of the Frontal Sinus	199

PAGE

Nasopharynx and Fauces . . . 205
Retropharyngeal Abscess . . . 205
Diphtheria . . . 207
Adenoids of Nasopharynx . . . 208
Tonsils . . . 212
Larynx and Trachea . . . 217
Malformations . . . 218
Injuries . . . 219
Inflammations . . . 220
Tuberculosis of Larynx . . . 222
Tumors . . . 223
Foreign Bodies in Larynx, Trachea and Bronchi . . . 224
Operations on Larynx, Trachea and Bronchi . . . 226
The Mouth . . . 244
Inflammation of Lips and Mouth . . . 246
Epithelioma of Lower Lip . . . 247
Diseases of Soft Palate and Uvula . . . 255
Cleft-palate . . . 257
Harelip . . . 266
The Teeth and Gums . . . 274
Caries of Teeth . . . 275
Alveolar Abscess, Pyorrhea Alveolaris, Gingivitis . . . 277
Extraction of Teeth . . . 278
Tooth Grafting . . . 279
Tumors of Gums and Teeth . . . 280
The Jaws . . . 280
Deformities of Jaws . . . 280
Periostitis and Osteomyelitis of Jaws . . . 283
Tumors of Jaws . . . 286
The Tongue . . . 286
Congenital Defects of Tongue . . . 286
Injuries of Tongue . . . 287
Inflammation of Tongue . . . 288
Ulcers of Tongue . . . 289
Tumors of Tongue . . . 292
Removal of Tongue for Carcinoma . . . 293
The Ear . . . 299
The External Ear . . . 303
The External Auditory Canal . . . 304
The Middle Ear . . . 306
Chronic Suppurative Otitis Media . . . 308
Radical Mastoid Operation . . . 312
Operation for Acute Mastoiditis . . . 317
Intracranial Complications of Infections of Temporal Bone . . . 318
Labyrinthine Disease . . . 319
THE SPINE . . . 322
Contusions and Concussion of Spinal Cord . . . 324
Stab Wounds and Bullet Wounds of Spine . . . 325
Osteomyelitis, Spondylitis . . . 326
Tuberculosis of Spine . . . 327
Tumors of Spine and Cord . . . 338
Operations on Posterior Nerve Roots . . . 344
Spina Bifida . . . 349
Lumbago . . . 350
Kyphosis . . . 351
Scoliosis . . . 352
Diseases of Sacro-iliac Joint . . . 355
Coccygodynia . . . 357
THE NECK . . . 360
Wounds and Injuries . . . 360
Infective Processes . . . 361
Diseases of Lymphatics of Neck . . . 363
Operations on Tonsil and Pharynx through Neck . . . 367
Tuberculous Lymph Glands of Neck . . . 368
Tumors of Neck . . . 372
Torticollis . . . 373

PAGE

Salivary Glands . . . 377
Parotid Salivary Fistula . . . 377
Thyroid Gland . . . 380
Inflammations . . . 380
Malignant Tumors . . . 381
Goiter (Struma) . . . 381
Hyperthyroidism . . . 389
Hypothyroidism . . . 394
Thymus Gland . . . 394
Carotid Gland . . . 395
THE THORAX . . . 396
Chest Wall . . . 397
Inflammation of Chest Wall . . . 398
The Pleura . . . 399
Wounds of Pleura . . . 399
Hemothorax . . . 400
Hydrothorax . . . 401
Pyothorax (Empyema) . . . 402
Tubercular Hydrothorax and Pyothorax . . . 413
The Lungs . . . 413
Wounds of Lungs . . . 413
Abscess of Lung . . . 414
Tuberculosis of Lungs . . . 416
Bronchiectasis . . . 419
Rigidity of Chest . . . 421
The Pericardium . . . 422
Serous Effusion in Pericardium . . . 422
Exposure of Pericardium and Heart . . . 424
The Heart . . . 424
Paracentesis of Heart . . . 425
Exposure by Plastic Flap . . . 426
Cardiorrhaphy . . . 427
Wounds of Heart . . . 428
Foreign Bodies in Heart . . . 429
Heart Massage for Cardiac Syncope . . . 430
The Esophagus . . . 430
Wounds . . . 431
Inflammations and Ulceration . . . 432
Congenital Stenosis . . . 433
Stricture . . . 433
Dilatations . . . 438
Fistula . . . 439
Foreign Bodies . . . 440
Esophagismus . . . 442
External Cervical Esophagotomy . . . 442
Partial Cervical Esophagectomy . . . 443
The Mediastina . . . 444
Tumors of Thorax . . . 444
Operations through Mediastinæ and Pleuræ . . . 446
Operations on the Lungs . . . 453
Exposure of Lungs . . . 453
Pneumotomy, Pneumectomy . . . 456
Operations on Mediastina . . . 458
Anterior Exposure of Mediastina . . . 458
Posterior Exposure of Mediastina . . . 459
Resection of Thoracic Esophagus . . . 463
Thoracic Exposure of Diaphragm . . . 467
THE BREAST . . . 471
Contusions and Wounds, Congenital Anomalies . . . 472
Hypertrophy . . . 472
Diseases of Nipples . . . 473
Mastitis . . . 473
Tuberculosis of Breast . . . 475
Benign Tumors . . . 475
Cysts . . . 476
Carcinoma . . . 477
The Male Breast . . . 497

PAGE

THE ABDOMEN . . . 498
General Principles . . . 498
Regions of Abdomen . . . 499
Structures of Abdominal Wall . . . 500
Landmarks of Abdomen . . . 503
Abdominal Section . . . 504
Incisions for Opening Abdomen . . . 504
Median Abdominal Section . . . 510
Ilio-inguinal Abdominal Section . . . 510
Oblique Postmuscular Abdominal Section . . . 511
Vertical Postmuscular Abdominal Section . . . 512
Low Median Abdominal Section . . . 513
Oblique Subcostal Abdominal Section . . . 513
Retraction, Sponging . . . 515
Protection of Peritoneum . . . 515
Leaving Instruments in Abdomen . . . 516
Closure of Abdominal Wound . . . 516
Dressing Abdominal Wound . . . 519
Methods of Dealing with Adhesions . . . 520
Methods of Dealing with Hemorrhage . . . 523
Methods of Securing Drainage . . . 524
Postoperative Treatment of Abdominal Cases . . . 529
The Abdominal Wall . . . 535
Wounds of Abdominal Wall . . . 535
Infections of Abdominal Wall . . . 536
Diseases of Umbilicus . . . 537
Tumors of Abdominal Wall . . . 538
Excessive Abdominal Fat . . . 538
Relaxed and Pendulous Abdomen . . . 540
The Peritoneum . . . 541
Injuries . . . 542
Foreign Bodies in Peritoneal Sac . . . 544
Peritonitis . . . 546
Paralytic Ileus . . . 552
Ascites . . . 557
Retroperitoneal Disease . . . 563
Preparation of Patients for Operations on Alimentary Canal . . . 564
The Intestines . . . 565
Contusions . . . 565
Rupture . . . 566
Perforating Wounds . . . 567
Wounds of Mesentery . . . 568
Infections of Intestinal Canal . . . 569
Ulcers and Perforations of Intestines . . . 576
Tumors of Intestines . . . 582
Intestinal Obstruction . . . 595
Diverticula . . . 603
Intussusception . . . 604
Chronic Intestinal Obstruction . . . 610
Chronic Intestinal Stasis . . . 610
Acute Intestinal Stasis . . . 614
Acute Dilatation of Stomach . . . 615
Enteroptosis . . . 616
Closure of Intestinal Fistula . . . 616
The Omentum . . . 620
Enemata . . . 620
Operations on Intestines . . . 621
Intestinal Suture . . . 628
Intestinal Resection . . . 636
Intestinal Anastomosis . . . 646
Intestinal Exclusion . . . 677
Operations for Closing Lumen . . . 681
Enterostomy . . . 683
Jejunostomy . . . 695
The Stomach . . . 698
Gastric Lavage . . . 700

PAGE

Inflammations 702
Carcinoma of Stomach 703
Hour-glass Stomach 706
Gastroptosis 710
Dilatation of Stomach 713
Cardiospasm 716
Pyloric Stenosis 717
Ulcer of Stomach 720
Hemorrhage of Stomach 727
Operations on Stomach 730
Gastrotomy 730
Gastrostomy 730
Pylorodiosis 737
Pyloroplasty 740
Gastroduodenostomy 747
Pylorectomy 747
Resection of Pyloric End of Stomach 751
Radical Operation for Cancer of Pyloric End of Stomach 756
Resection of Cardia for Carcinoma 756
Resection of Gastric Ulcer 759
Partial Gastrectomy 759
Total Gastrectomy 761
Gastro-enterostomy 762
Exclusion of Pylorus 771
Reconstruction of Wall of Gastro-intestinal Tract 773
Treatment of Shock in Gastric Operation 776
The Pancreas 778
Wounds 779
Approach 779
Drainage 780
Pancreatitis 780
Tumors 782
Pancreatic Calculi 783
The Spleen 784
Hemolytic Jaundice, Pernicious Anemia, Biliary Cirrhosis 785
Leukemia 786
Wandering Spleen 786
Operations on Spleen 787

INDEX OF NAMES 789
INDEX OF SUBJECTS 793

SURGICAL TREATMENT

REGIONAL SURGERY

TREATMENT OF INJURIES AND DISEASES OF THE HEAD

SCALP

In the treatment of injuries and diseases of the scalp, there are certain peculiarities of structure to be considered. The scalp is loosely connected to the bone by elastic connective tissue, which renders it freely movable and easily detached, excepting in infancy and old age. Its blood supply is so rich that healing is easily secured. The chief arteries are the supraorbital, temporal, and occipital; and in making large flaps these vessels should be considered. The capillaries, anastomosing venules, and arterioles are so numerous as to give the scalp almost an angiocavernous or spongy character. The veins communicate through the minute openings in the skull with the intracranial vessels so freely that infections in the scalp always threaten the venous sinuses of the brain. The structure of the scalp is so firm and so related to the vessels that when the latter are divided they do not collapse but their mouths tend to remain open and bleed.

The lymphatics empty into the lymph chains of the neck. The nerve supply is largely sensory, giving rise often to neuralgias if irritated by scar tissue. The motor nerves are to the occipitofrontalis, temporal, and small muscles of the ear. The nerve to the frontalis from the facial should be guarded from injury. The external periosteum of the skull has the power to generate bone even in adults. It is adherent with especial firmness at the suture lines. The deepness of the hair follicles and glands of the scalp renders perfect cleansing by mechanical means impossible. Iodin in alcohol or other penetrating antiseptic solution must be used for cleansing.

Contusions.—Contusions of the scalp require the treatment already given for contusions in general, unless associated with hematoma, open wound, or fracture of the skull. The vessels of the scalp are so easily torn and the scalp is so easily lifted up that more or less extravasation of blood accompanies contusions. To prevent or minimize this, cold and pressure are of service. Cold water, an ice-bag, or alcohol may be combined with a gently compressing bandage to the contused area immediately after the accident.

Hematoma of the Scalp.—The first essential in the treatment is to recognize the nature of the condition. When the scalp is lifted up by a bloody effusion, the softened center and the abruptly indurated circumference should not obtain for the patient an operation directed to the cure of a depressed fracture which does not exist. During its development a hematoma may be checked in its progress by the use of cold and pressure. The cold should not be of too low a degree. Having reached its maximum size and the back-pressure having stopped the bleeding, there is little to do but await the absorption of the blood. The active circulation of the scalp makes such absorption rapid, and usually the hematoma will have disappeared within a

week or ten days. The absorption may be hastened by warm applications. This treatment is not called for unless for cosmetic reasons.

If a hematoma has not been absorbed in two weeks, it is good treatment to incise it. This should be done with a narrow-bladed knife, making a puncture at its base at the lowest point. If the blood does not flow out freely, a canula may be inserted through the wound, and the contents of the swelling washed out with sterile water. Aspiration is not satisfactory because of the thick consistency of the blood. Such an operation should be done with the same aseptic care as any other operation upon the skull or brain, because the surgeon cannot know but that a fracture communicates with the hematoma. The pressure of a firm dressing for a few days will cause the scalp to adhere again to the skull. An infected hematoma demands free incision and drainage.

Accidental Wounds of the Scalp.—No open wound of the scalp should be regarded as unimportant. The aim of treatment should be to prevent cellulitis and suppuration and to minimize scar. Often wounds which look like incised wounds are contused wounds with ragged and devitalized tissue beneath. All scalp wounds should be freely exposed so that the nature and extent of the wound can be seen. Blood, dirt and hair should be removed until the wound is clean. The best cleansing for a scalp wound which contains foreign matter is accomplished with warm water and soap, or peroxid of hydrogen, followed by sterile water. The hair immediately around the wound should be shaved, and the remaining hair parted away from it. Ragged edges should be trimmed away. Clotted blood should be washed out. Every particle of foreign material which can be seen should be removed either by irrigation, with a scrubbing brush, or picked out with forceps. After cleansing and drying a dirty wound it should be swabbed throughout with 3 per cent. iodin in alcohol, or a chlorin antiseptic should be applied. Wounds which are not seriously soiled need not be treated with a chemical antiseptic. At the time of treating the wound the skull may be examined for fracture.

Every accidental scalp wound is an infected wound; whether it will suppurate or not is a fortuitous matter which the surgeon cannot predetermine. The best guarantee against suppuration is the antiseptic treatment. Drainage is advisable in all cases of large ragged wounds. This may be secured with a small rubber tube, a roll of rubber dam, or any other drainage material. Even in small wounds drainage for the first two days is wise. In small wounds, I like to use a small bundle of silkworm-gut sutures for drainage. Pockets often demand counter openings. The drainage should be adequate. A scalp wound properly cleansed, antisepticized, and drained, represents in a high degree the possibilities of good surgery; a scalp wound improperly cared for, covered with hair and matted blood, and its extent undetermined, represents one of the worst forms of surgical neglect.

The control of hemorrhage in small wounds is simple. In larger wounds, as a result of the cleansing and trimming of the edges, bleeding may be awakened. It may be controlled temporarily by pressure made by an assistant with a pad of gauze; or the bleeding edges may be covered with gauze and lightly clamped with T-shaped or ring-clamps. In extensive wounds the bleeding may be checked by the elastic bandage around the head. Time should not be wasted clamping and ligating bleeding points, for if this is once begun it means ligating the whole of the edges (see Operative Control of Hemorrhage of Scalp, page 20). If the facilities for stopping the hemorrhage by the above means are not at hand, temporary mass-ligatures may be applied with a needle. *The permanent control of bleeding in scalp wounds*

is accomplished by the sutures which close the wound and the pressure of the dressing. The only vessels entitled to separate ligatures are the main trunks of the frontal, temporal, posterior auricular, and occipital arteries; and even these can be controlled by the wound suture. The inexperienced surgeon will be seen wasting time, and blood, clamping and ligating bleeding points prior to suturing the wound, when the sutures which he will ultimately apply would accomplish all of the hemostasis that can be secured by the time-consuming process of multiple ligations.

For suturing wounds of the scalp, interrupted sutures of silkworm-gut or silk are preferable. They should be tied tightly enough to check bleeding. In the forehead a subcuticular suture of wire, or other stiff material

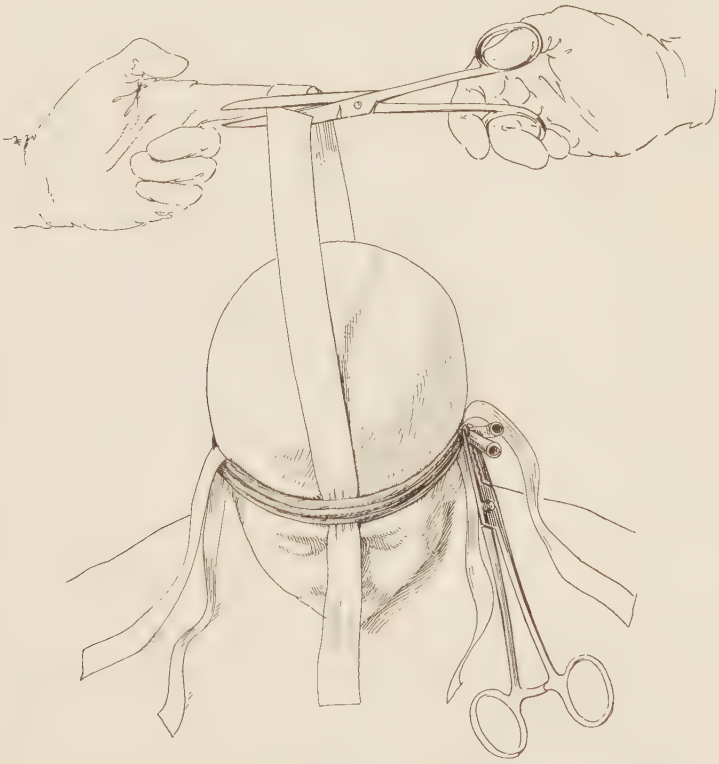

Fig. 700.—Tourniquet of Rubber Tubing for Control of Bleeding of Scalp. The tubing is applied over tapes and caught with a heavy clamp.

is most effective, as it avoids the multiple puncture wounds of the skin. The superficial subcuticular should be preceded by a deep buried suture of catgut which controls bleeding and closes the deep parts.

Bleeding appearing between sutures may be controlled by still another suture. Union takes place quickly. The wound should be dressed daily for the first four days in order to discover infection. Undrained infection and stitch-hole abscess call for the removal of sutures. Drainage is usually continued from two to four days, and the sutures removed in five or ten days, unless the presence of infection demands that the drainage be continued longer and the sutures removed earlier.

Operative Wounds of the Scalp.—In the wounds of the scalp, made by the surgeon as a step in an operation, the conditions are different from those of accidental wounds. A wide area of the scalp should be shaved of hair. In operations upon the skull or brain, either a half or, better, the whole of the scalp should be shaved. The shaving and cleansing with soap and warm water should be thorough. This should be done twenty-four hours before the operation. The scalp should then be washed with alcohol, and covered with a dry gauze cap. Just before the operation the dry scalp should be treated with tincture of iodin or other skin disinfectant. In the absence of such, scrubbing and treatment with an antiseptic solution may be used (see Preparation of the Skin for Operation, Vol. I, page 177).

To render the operation as free from blood as possible, a rubber elastic tourniquet should be applied. For this purpose the ordinary rubber bandage

Fig. 701.—Tourniquet of Rubber Tubing for Control of Bleeding of Scalp.

Tapes tied to prevent displacement of tubing. A sterile cloth may be placed under the tubing and tapes and folded downward when the operation is to proceed. Either of the tapes may be dispensed with, or the positions of the tapes may be altered to accommodate the site of operation.

or rubber tubing may be used. To apply this, all being ready for operation, a sterile cloth or square of gauze is laid smoothly over the scalp. Then a strip of sterile tape or muslin bandage, about 100 cm. (40 inches) long is placed over this, running anteroposteriorly in the middle line and having its middle at the forehead. A similar piece is placed transversely across the head (Fig. 700). The rubber bandage is then tightly applied in the form of a cord around the head over these, passing around 2 or 3 times just above the ears and the eyebrows, and its ends fixed by a clamp. The two ends of the tape or bandage are then gathered up and tied over the scalp in the most convenient place, the object of this being to prevent the hemostatic bandage from slipping downward. An opening is cut in the cloth at the site of operation, and the lower ends of the cloth so distributed as to cover the ears and adjacent parts (Fig. 701). Cushing used a tubular rubber, which was

fitted to the patient's head the day before the operation, provided with a tape to prevent slipping, and the ends fixed. This is ready sterilized, and can be snapped on just before the operation.

Instead of using a rubber tourniquet around the head, broad clamps may be applied to the bleeding edge of the scalp wound. W. P. Carr devised a useful appliance for this purpose. It is a clamp with a light spring, and with a crescent-shaped bite (Fig. 702). Such clamps may be applied about the whole outer edge of the wound, and removed just before the suture is applied.

L. Friedman (Surg. Gyn. and Obs., xx, 1915) devised a hemostat having the principle of a safety pin, which is very useful (Fig. 703).

The metal bobbins of Kredel are also useful for local hemostasis. They are made of soft pliable metal such as tin, lead or copper so that they may be given the shape of the surface to which they are applied. They consist

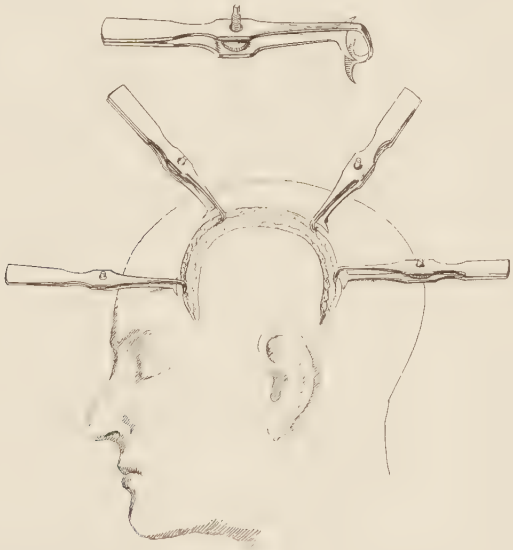

Fig. 702.—Clamp for Temporary Control of Bleeding from Wounds of Scalp.

simply of a notched rod (Fig. 704) made in lengths of 5 cm. (2 inches) and 7 cm. (2¾ inches). Before making the scalp incision, a heavy silk suture is passed through the scalp with a straight or slightly curved needle just beyond the contemplated line of incision. The needle slides along the bone and then emerges, embracing a distance about equal to the length of the rod to be used. If the longer rod is to be employed the needle should emerge at half the distance to be traversed and then reintroduced to make a loop. The thread is tied over the bobbin, and the scalp thus compressed. A number of these rods may be used. They are removed at the end of the operation.

A line of sutures of heavy catgut alone may be used. The sutures are passed down to the bone with a curved needle. Each stitch takes about 2 cm. (¾ inch) of scalp, and overlaps about half of the preceding suture. This is a running suture, placed about 1.3 cm. (½ inch) beyond the proposed line of suture. The suture should not only pass around parallel with the

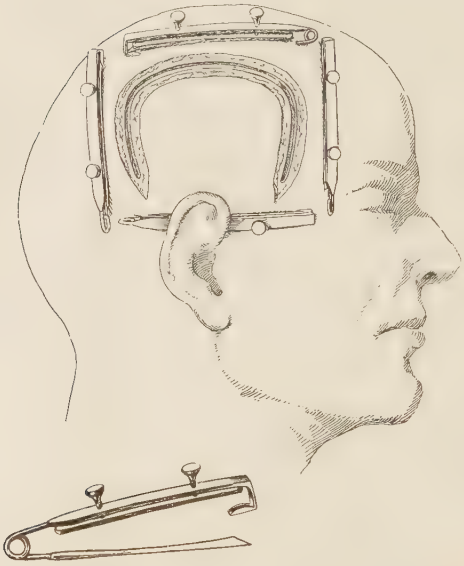

Fig. 703.—Hemostatic Safety-pin of Friedman for Controlling Bleeding in the Scalp.

If necessary a temporary suture of silk may be inserted at the angles left open between the pins.

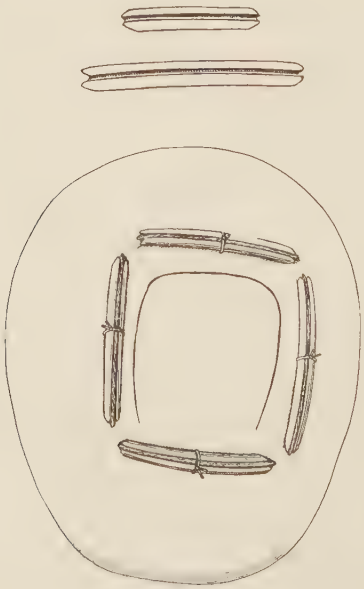

Fig. 704.—Metal Rods for Scalp Hemostasis.

A heavy silk suture is passed through the scalp, over the rod, and tied.

contemplated incision, but should cross the base of the flap also, thus completely surrounding it. At the end of the operation the suture is quickly removed by cutting the thread.

Avulsion of the Scalp.—This accident, occurring most commonly among women operatives in factories, should be treated by first controlling the hemorrhage from the main arteries if they are bleeding. Usually when the surgeon sees the patient, bleeding has stopped. If the avulsion is a partial one, the wound should be cleansed as described above for accidental scalp wounds, the hair shaved, and the flap sutured back in place. If the scalp or a part of the scalp has been completely detached, it should be cleansed in warm saline, shaved, kept warm all the time, and, as soon as the wound can be made ready, sutured back in place. If the scalp or a portion of the scalp has been irreplacably damaged, the wound should be cleansed and covered with strips of rubber dam or other porous material over which a copious wet gauze dressing is applied. A piece of scalp which is destined to become necrotic should not be left. The head should be kept warm and protected by the dressing. To prevent the remaining scalp sagging over the eyes, it may be necessary to fasten it with a few sutures to the frontal periosteum.

Usually the condition of the patient does not justify any more operation than the above at the first dressing in cases of complete avulsion. At the earliest time possible, steps to cover the denuded area with epithelium should be made. This may be accomplished by turning up flaps from the back of the neck or elsewhere; skin grafts may be used; or scalp flaps may be donated by members of the patient's family (see Plastic Operations, Vol. III).

The granulating surface should not be left too long uncovered by epithelium, as the more time that elapses the poorer becomes the nourishment of the surface on account of the deposit of scar tissue. With good care, healing in the worst of these cases may be expected. Treatment by skin-grafting or skin transplantation is imperative. Large areas cannot be expected to become covered by epithelium growing in from the periphery. If the surgeon cannot make grafts or transplants grow to the denuded area, he should not be satisfied with an alternative; he should put the case in the hands of some surgeon who can.

In these distressing cases there is no use of attempting to restore a completely avulsed and dirty scalp. A small piece may be cleansed and restored, but a large piece cannot. Just as soon as granulations have formed, plastic flaps should be applied. Flaps containing some fat are best. The Italian method of taking flaps from the arm is highly advantageous. Thin skin grafts should not be used over a large area, as the skull needs a thick covering, and, unless it has it, nervous disturbances will develop. The best results are secured, by turning up flaps from the periphery and adding to these flaps transferred from the arm.

In *complete avulsion of the scalp*, after checking hemorrhage, it is well to apply hot boric acid compresses. From three to five days later, skin grafting should be done. It is best to take the skin from the patient herself. One-third or one-half of the area may be grafted, preferably one or the other sides so that an ungrafted side is left to lie on. A week or ten days later the other side may be grafted.

If an area of denuded bone develops, granulations may be made to grow upon it by boring holes in the bone. Each hole becomes an island of granulations.

Infections of the Scalp.—*Cellulitis* easily takes place in the loose cellular tissue under the scalp. It is for this reason that every scalp wound should be watched carefully, and sutures removed upon the earliest appearance

of infection. There should be no hesitation in opening up widely a wound which shows infection. Unless this is done, the cellulitis is prone to extend, it may be, over the whole skull. Treatment must be aimed to check its progress. An area of cellulitis of an undrained part of the scalp should be freely incised, and copious wet dressings kept applied (see Cellulitis, Vol. I, page 264).

Abscess should be prevented by combating cellulitis and providing free drainage before an abscess occurs. Wherever an abscess develops it should be incised and drained. The hair should be kept shaved from the infected area. Indeed, as soon as a spreading infection appears the scalp should be shaved. These infective processes are amenable to treatment by suction hyperemia, but free incision and drainage should be the main reliance.

Other reasons for vigorous treatment of scalp infections are because of the danger of infection of the intracranial sinuses and meninges through the communicating veins and because of the strong tendency to caries and necrosis of the underlying skull. For these reasons cellulitis of the scalp should be thought of as a serious disease, and should receive the best surgical attention.

Erysipelas is prevented by the measures above described. Copious wet dressings combined with the induction of artificial hyperemia by suction or bandage are the most effective treatment. The disease runs a course of about nine days, during which time the general as well as the local condition of the patient should receive attention (see Erysipelas, Vol. I, page 262).

Tumors of the Scalp.—These tumors are similar to those encountered elsewhere in the integument (see Tumors of Skin, Vol. I, page 840).

Sebaceous cysts (wen) should be removed for cosmetic reasons or when they become objects of annoyance (see Cystoma, Vol. I, page 325; Steatoma, Vol. I, page 845). *Dermoid tumors* develop at the sites of closure of congenital clefts, and require removal because their pressure often produces rarefication and absorption of bone. In removing these growths the lining epithelium, or enveloping epithelium, of the cystic tumor should be removed or destroyed. Such growths in the orbit or temporal fossa may require resection of bone to accomplish their removal. These tumors should be removed early in life to obviate the damages which their pressure would inflict upon the growing parts.

Lipomata and *fibromata* may be important because of their confusion with other conditions. They are easily excised. For treatment of *keloids* (see Vol. I, page 843; and Vol. III). *Fibroneuroma* (plexiform neuroma, elephantiasis nervorum, multiple neurofibromatosis) is observed most frequently in the temporofrontal region, but wherever it occurs it should be excised as soon as possible. When the tumor has become larger, its extirpation becomes more difficult because of its size, vascularity and spongy character. If the tumor is allowed to grow it may become too extensive for safe removal, or several operations may be required.

Pericranial pneumatocele, the air tumor caused by a defect in the wall of the mastoid or frontal sinuses, permitting air to lift up the pericranium and scalp into an air-filled sac, should not be confused with transient emphysema of the scalp due to fracture of the sinuses or with infection with gas-forming bacteria. The method of treating this condition, which would suggest itself to the surgeon, is incision of the sac, breaking down any ridges of new bone, destroying epithelium which may be present in the sac, turning in an osteoplastic flap over the bone defect, curetting or irritating the lining of the sac, and holding the parts together by firm pressure uutil healing has taken place.

Sinus pericranii is the condition in which there is a tumor under the scalp,

caused by the formation of a sac of blood, which communicates through a defect of the skull with an intracranial venous sinus and empties or fills from the sinus as the intracranial pressure diminishes or increases. The treatment which would naturally suggest itself to the surgeon would be the exposure and removal of the sac under the scalp, suture, ligation or crushing of the communicating outlet, and closing the bone-opening by an osteoplastic flap. No such operation should be done if there is present some disease which causes increase of intracranial tension which may be the etiologic factor in forcing out blood and dilating an emissary vein. Harvey Cushing cites cases in which the swelling subsided after decompression operation for brain tumor.

Spurious meningocele is a collection of cerebrospinal fluid under the scalp, communicating with the subdural space through a skull defect due to fracture or disease. In the acute cases, occurring in children, any bony displacement which is present should be corrected, and the fluid may be expected to be absorbed. The chronic cases are analogous to true meningocele and should be treated as such (see Encephalocele, page 92).

Aneurism is usually traumatic and involves one of the large afferent vessels of the scalp. The treatment is simple ligation (see Aneurism, Vol. I, page 380). *Arteriovenous aneurism* is best treated by ligating all of the vessels which have any communication with the arteriovenous anastomosis, and the extirpation of the diseased veins. In a recent case, simply the ligation suffices. When the disease is of long standing and a tumor exists, it is best to turn back a flap, uncovering the disease, ligate all vessels tributary to the tumor, extirpate the diseased vessels and close the wound (see Arteriovenous Aneurism, Vol. I, page 393). The old treatments by galvanopuncture and pressure are not to be recommended. *Cirsoid aneurism* should be treated by ligation, if possible, of all of the vessels passing into the diseased area, and destruction by the actual cautery of the diseased arterioles and capillaries. For the treatment to be successful the ligations should be made in sound parts of the vessels and the vessels of the diseased area should be extirpated (see Cirsoid Aneurism, Vol. I, page 400). In a number of cases of this sort, I have been compelled to operate a second and even a third time because of failure to destroy all of the diseased vessels passing into the cavernous mass. These cases bleed most profusely. In a case involving the supra-orbital vessels, success was attained only by turning down a forehead flap, double-ligating all of the vessels, excising the cirsoid mass as a tumor, and destroying the supraorbital foramen.

Nevus is amenable to treatment by excision of the diseased area, and covering the resultant wound by plastic flaps or skin grafts (see Nevus, Vol. I, page 325).

Angioma of the scalp is best treated by excision of the cavernous mass of vessels by turning back a skin flap and ligating all tributaries in sound tissue (see Angioma, Vol. I, page 325). Old cavernous angiomata, which have developed large communications through the skull with the intracranial sinuses, are serious conditions. If not removed there is a strong tendency to pressure destruction of the bone and ultimate wide anastomosis with the sinuses. Extirpation of these tumors, even with the utmost care means a great loss of blood. Notwithstanding the danger of serious hemorrhage, the best surgery demands their removal. Depending upon the shape and size, either a U-shaped flap should be turned back from the tumor, or an elliptical incision made about it. The ligation of all vessels in the scalp around the spongy tumor is not so difficult, but when the separation of the tumor from the bone is attempted, the hemorrhage can be checked only by pressure. This last stage of the operation must be done expeditiously, and

hemostatic pressure maintained for as many days as necessary. The pressure does not need to be great, but it does need to be constant and well secured. A good plan is to have the circumference of the tumor ligated and freed; it is then grasped with heavy pedicle clamps, and, with a broad knife or large curved scissors, cut free from the skull, while immediately a piece of rubber dam follows the incision and is pressed flatly against the skull with a gauze pad. This gauze pad should be in readiness, of size slightly larger than the base of the tumor, and for convenience it may have the rubber dam sewed to its under surface. The advantage of introducing an impervious material is to prevent pulling out the clots when the dressing is changed. The dressing should be held down by a bandage which makes dependable pressure. If a U-flap has been employed the pressure should be wholly beneath it, not upon it. After a few days, when hemostasis has been assured, the wound may be sutured. Large openings through the bone should be closed by crushing them with a chisel in such a way as to drive the edges of the bone into the opening.

THE SKULL

The successful treatment of injuries and diseases of the skull requires an understanding of its anatomical peculiarities. The extreme thinness of the infant's skull and the absence of diplöe are important. The surgeon should bear in mind that the thickness of the adult skull varies much in different regions of the head and also in different individuals. Also the density of the tables varies: some are hard like ivory, others are soft and cancellous. The character of the diplöe varies not only in thickness but also in the size of the blood spaces; in some the spaces are so small as to render the diplöe scarcely distinguishable from the two tables; in others the spaces are so large that bleeding from them may be difficult to control. The periosteum (pericranium) is more important than that of other bones, because its power to regenerate bone persists even in adult life, and because the continuity of the covering of the brain should be maintained as complete as possible. The interior lining of the cranium is important because its surface is a serous membrane with which the brain articulates. The skull is chiefly important because it constitutes the protective covering of the brain, and is involved not only in its own diseases and injuries but requires to be operated upon whenever the surgeon would expose or operate upon its contents.

Operations upon the Skull

Here will be described the common operations which are performed upon the skull for the purpose of gaining access to the cranial chamber. The treatment of the diseases which these operations are aimed to attack will be given in their several places. The technic of operations upon the scalp, which must precede attacks upon the skull, have been described (see Operative Wounds of the Scalp, page 20).

Instruments.—Besides the common instruments of surgery used in all cutting operations upon bones, certain special instruments are employed in operations upon the skull.

The tourniquet and other apparatus for controlling hemorrhage from the scalp have been described (page 19). The ordinary periosteal elevators, rongeur bone-cutting forceps, bayonet bone-lifting forceps, and wire saw, are employed (see Operations on Bones, Vol. I, page 688).

Of the instruments for incising the skull, the *trephine* is the most important. This instrument should be of the beveled pattern (Fig. 705) and not

the straight cylindrical trephine. The former is less apt to do damage to the meninges. A central button, carrying a pin is used to "center" the cut. The pin should project just far enough to hold the instrument until the circular cut is well started. The pin is then removed. This should surely be done before the pin has penetrated the skull. The cutting is done with a boring wrist motion. After the outer table has been cut through, the

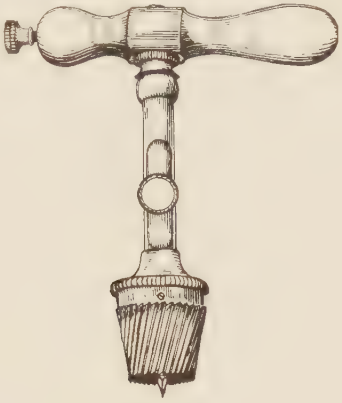

FIG. 705.—BEVELED TREPHINE.
The conical shape of this instrument prevents its too sudden penetration. The pin is elevated as soon as the outer table has been cut.

operation should proceed with caution. The pressure of the instrument should be well under control. As the penetration of the inner table is approached, the pressure should be made very light, and the rotating hand supported by the other hand beneath it. By removing the trephine, and tapping gently upon the circumference of the button with the handle, the percussion will show if the skull has been penetrated at any place. The trephine should be perpendicular to the inner table. Unless care is taken thus the cutting edge

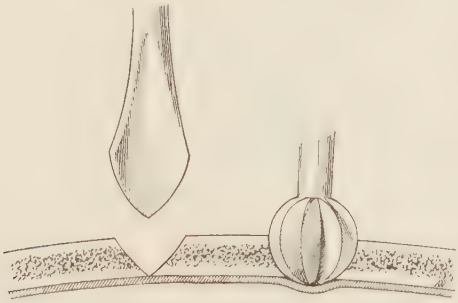

FIG. 706.—BURR OF DOYEN CUTTING THROUGH SKULL.
This burr may be driven by a hand-brace or by electric power (*Marion*).

may be operating upon bone in one place and meninges in another. When the bone is cut through, the button is removed and placed in warm salt solution if it is to be replaced later. Excessive hemorrhage from the diplöe should be checked by pressing in some bone-wax. If necessary this may be done while the trephine is being used. For general use the trephine should be about 2 cm. (¾ inch) in diameter.

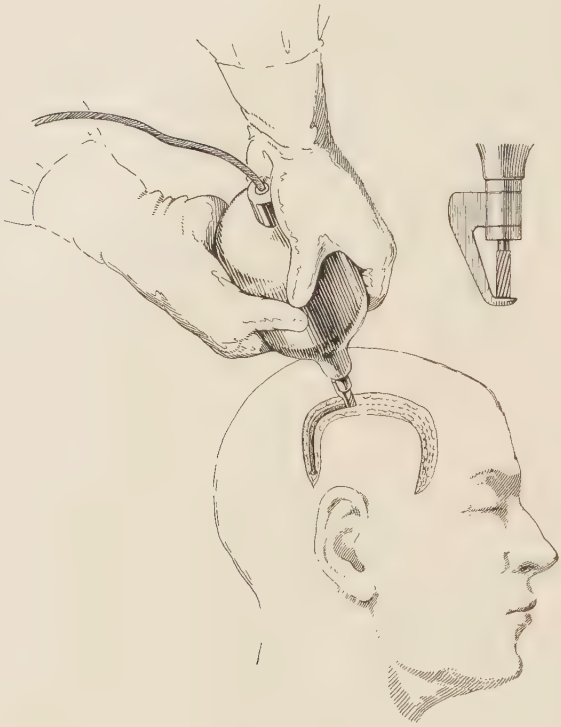

FIG. 707.—SPIRAL OSTEOTOME.
This instrument is driven by electric power. The button at the end prevents injury of the meninges.



FIG. 708.—BURRS OF HUDSON.
These burrs may be used with the hand power brace or with electric power.

Other instruments for penetrating the skull are the burr and the circular craniotome.

The burr of Doyen is most useful as it does not cut the dura (Fig. 706). For making linear cuts between primary openings several instruments and methods are used (see Operations on Bones, Vol. I, page 688).

The appliances driven by electric engines are being more and more employed. The spiral osteotome devised by M. H. Cryer is a most useful

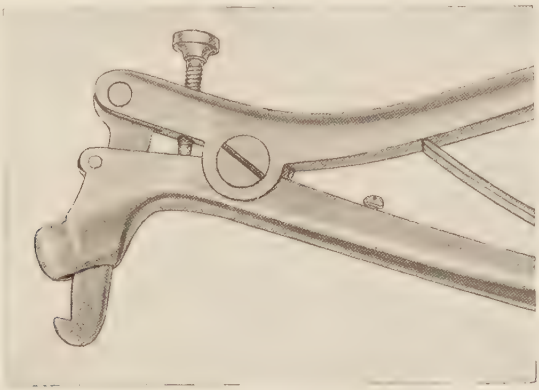

Fig. 709.—Linear Bone-cutting Forceps.

device (Fig. 707). It may be attached to any dental or surgical engine. For cutting the skull, a button runs along under the skull and protects the meninges.

The burrs invented by W. H. Hudson (Fig. 708) are valuable for cranial surgery because they minimize the danger of injuring the meninges. Hudson invented a most effective forceps for linear craniotomy (Fig. 709).

The bone drill bores a hole 8 mm. ($^5/_{16}$ inch) in diameter and has a guard by which the depth of the hole is regulated. A number of these holes may

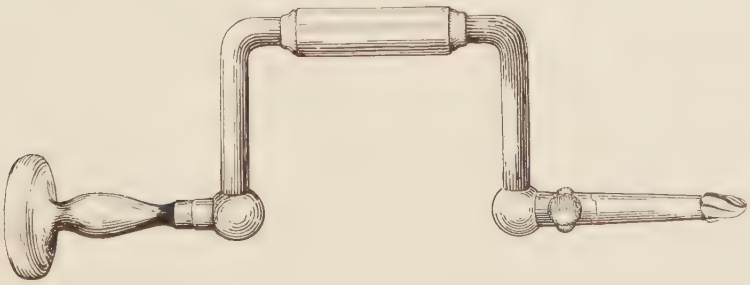

Fig. 710.—Simple Brace, with Bone-cutting Burr, Driven by Hand Power.

be made rapidly in the line of the bone division, and connected by cutting with the linear bone-cutting forceps or wire saw. The hand brace (Fig. 710) is a most effective instrument for operating the drills and burrs.

The bone-cutting forceps of Montenovesi and Dahlgren are effective. The wire saw of Gigli is used by passing it through two trephine openings and cutting the intervening bone. Inasmuch as the saw operates when taut in a straight line there is danger of wounding the dura if used where the skull

is much curved or through too long a distance. When it is used the dura should first be separated from the bone by passing a spatula or dural elevator into the openings. The saw is then passed and the dura protected by a spatula in each opening while the saw is operated. The wire saw has the advantage that it allows an oblique cut in making an osteoplastic flap so that when the flap is replaced bone rests upon bone (Fig. 711).



Fig. 711.—Oblique Division of Part of Osteoplastic Skull Flap. This obliquity prevents depression when the flap is replaced.

The simple, bladed saw is also employed for making linear cuts. For this purpose are used the hand saw of Doyen (Fig. 712) or the circular saw driven by an engine. For driving the burr or circular saw an electric motor is most effective. V-shaped and U-shaped chisels are still used by some surgeons, but they possess the disadvantage of causing concussion. With the exception of the trephine, instruments should be preferred which cut the inner table from within outward.

Fig. 712.—Hand Saw of Doyen for Making Linear Bone Incisions. The guard regulates the depth of the cut.

Osteoplastic Craniotomy.—The temporoparietal region most commonly requires operation. The technic of the typical osteoplastic operation for exposure of the brain in this region will be described.

Preparation of the patient should be according to the methods already described. The shaving and cleansing of the scalp should have been done on the preceding day, although many operators have this done just before the operation (see Operative Wounds of the Scalp, page 20). The patient should come to the operating room with the scalp covered with a protective dressing. A final preparation of the scalp should be done after the patient is placed on the table. In the absence of iodin, chlorin, or other skin-penetrating antiseptic, alcohol and bichlorid solution are used.

Landmarks should be identified. The location of the lesion and the line where the incision is to be made may be marked on tincture of iodin with a white starch pencil, or with methylene blue solution, or carbol-fuchsin. The protective cloths and the hemostatic tourniquet should be applied when everything is in readiness for the operation to begin. All of the environs of the field of operation should be covered with protective sheets. The anesthetist should be excluded from the field of operation by a screen or by his own carefulness.

The *administration of the anesthetic* in cerebral operations requires a high degree of skill because of the effects of manipulation of the cranial contents upon the cardiac and respiratory functions. In serious cases the blood-pressure should be taken before the operation and recorded during the operation. The choice of anesthetic must rest upon the rules already laid down (see Anesthetics, Vol. I, page 165). The sensitiveness of the scalp is not acute. In many conditions, such as intracranial hemorrhage, in which the sensibilities are obtunded, no anesthetic at all is required, in other cases it suffices to give a preliminary injection of morphin and to use an anesthetic during the division of the scalp and skull, but not while the meninges and brain are being operated upon. Local anesthesia is applicable in some cases. In operations done in two stages, the secondary turning down of the flap and operation on the cranial contents require no anesthetic.

The anesthetist is so close to the field of operation that he must use his surgical sense to prevent transmitting infection. A screen to separate the scalp and the face is used; if not the anesthetic mask should be covered with a couple of layers of sterilized gauze, and should be as small as possible. If ether is given, the small drop-method mask should be used. Some surgeons prefer ether given by the pharyngeal tube.

The *position on the table* should be well under control. The head should lie on flat sand-bags, with the face rotated toward the well side. The neck should be straight. The table should be so constructed that the patient's head can quickly be extended or flexed upon the neck.

For *operations in the occipital region* the head may lie latterly, or, the patient may lie prone with the head projecting over the end of the table and supported by a special head rest.

The *incisions* for turning down a flap of skull and scalp in the parieto-temporal region should be in the form of a horseshoe with the opening downward to receive the temporal and middle meningeal arteries. The size and position of the flap varies, of course, with the region to be exposed and the object of the exposure. The lateral aspect of the brain, *i.e.*, the motor area and the convolutions anterior and posterior to it, is exposed by a horseshoe-shaped incision, the anterior end of which begins at the middle of the zygoma and the posterior end lies above the external auditory meatus. The whole incision lies within the temporal fossa. This incision is carried down through the scalp to the bone. Any bleeding vessels are caught. At its mesial arc the soft parts are pressed aside anteriorly and posteriorly. The periosteum should be pressed back external to the flap for about 1 cm. along the whole line.

If the trephine is used an opening is made at the internal anterior part of the incision, and another about 5 cm. (2 inches) posterior to it at the internal posterior part of the incision. The buttons should be removed. The dura should not be wounded. With a dural spatula, made in the shape of a thin, smooth teaspoon handle, the dura should be separated from the skull between these two openings. A wire saw should be passed into one opening and out of the other, and the dura pressed away from the saw by means of a spatula inserted in either opening. The saw should cut through the intervening bone in an oblique direction toward the median line, so that the upper margin of the bone flap shall have a lip which shall prevent the bone pressing upon the brain when the flap is replaced.

The two arms of the flap, from either trephine opening downward are best cut by means of the bone-cutting forceps, care being taken to separate the dura from the skull without wounding it. The posterior incision should be cut first, leaving the possibility of wounding the middle meningeal artery

for the last. In making these two bone cuts, the scalp outside of the flap should be retracted away from the cut, in order not to separate the scalp and bone of the flap. When the flap has thus been cut, an elevator is inserted at the top, and as the flap is pried up the dura is gently detached with a spatula. At last the bone breaks across the base of the flap. If the middle meningeal artery is torn and bleeds, it should be ligated by making a small opening in the dura just below and passing a ligature around it in a curved needle. If the mesial cut with the trephine or saw is made so high that the longitudinal sinus is opened, or if the expansions of the lateral sinuses are wounded, bleeding may be controlled easily by gently packing in a bit of gauze. To expose the brain, the dura mater is then incised and cut parallel to the bone incision.

The dura flap is made the same shape as the bone flap, but it should be about 6 mm. (¼ inch) smaller, so that there shall be a margin outside for suturing.

The most satisfactory instrument for *cutting the bone flap* is the *circular saw*, driven by an electric motor. The chisel and mallet are not desirable because of the concussion and possible injury of the dura. The wire saw of Gigli if passed through trephine openings is usually satisfactory, but in a thick skull the saws break, time is lost in introducing them, and adherent dura is torn. Cutting a line with the biting forceps is slow if the bone is thick. The depth of the cut can be regulated by an adjustable shoe in the circular saw. This saw may be supplied with washers to regulate the depth to which the saw will cut (see Operations on Bones).

Fig. 713.—Measure for Determining Thickness of Skull.

The thickness of the skull is best measured, through the holes bored on the line of incision, by the instrument devised by Doyen for that purpose (Fig. 713).

In operating upon the brain the cerebral topography should be marked with carbol-fuchsin or other stain. The lines of Chipault (Fig. 714) are most satisfactory (see Cerebral Localization, page 43).

With the motor engine, a cutter bores holes at the corners of the flap and along the sides. Between the adjoining holes the thickness of the skull should be uniform. The saw should be adjusted to cut a certain thickness, and all of the bone between the holes having that thickness should be cut. Then the saw should be adjusted to the next thickness and the bone having that thickness cut. By slanting the saw so that it does not cut at a right angle, thinner bone may be cut without changing the saw. Bleeding from bone is controlled by bone-wax. The uncut parts of the inner table are divided with an osteotome and mallet. The flap is then pried up and fractured at the base (Fig. 716).

For cutting small flaps, a large number of holes may be bored with the motor burr, and the intervening bone cut with rongeur or other bone-cutting forceps.

If it is desired to perform an operation in *two stages*, the flap may be replaced before the dura is opened, and a dressing applied. This is often advisable in serious operations, or in operations when at this juncture there is a

FIG. 714.—HEAD PREPARED FOR CRANIAL OPERATION.
Lines of Chipault marked for localization.

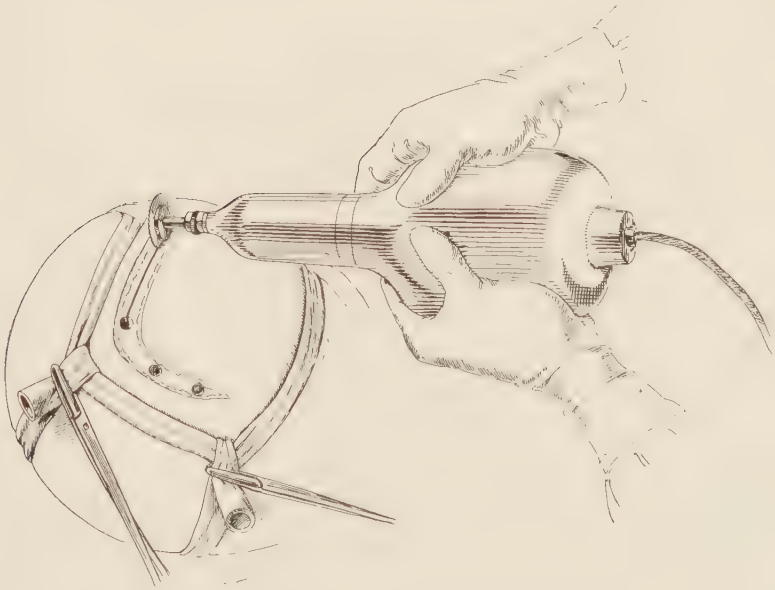

FIG. 715.—CUTTING OSTEOPLASTIC SKULL FLAP.

Hemostasis has been secured by rubber tubing compression. The scalp has been incised. Holes through the skull have been made with the burr in order to determine the thickness of the bone. The skull is being cut by the electric-motor-driven circular saw provided with a washer to regulate the depth of the cut.

decided fall of blood-pressure. In doing this the tourniquet should be removed, and bleeding from the scalp controlled either by suturing the wound or by a compressing dressing. After a few days the second stage of the operation may be undertaken.

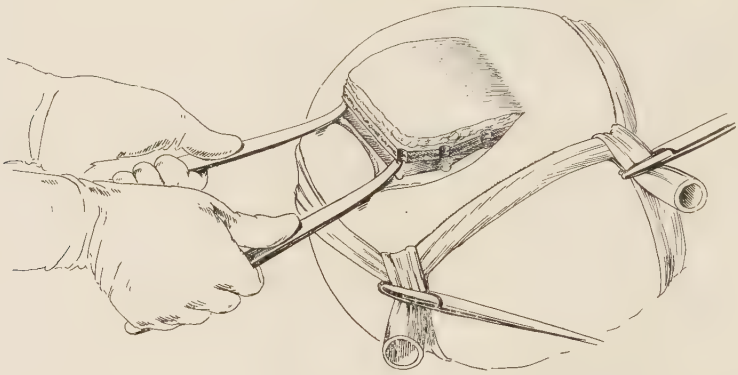

Fig. 716.—Osteoplastic Craniotomy.

The flap of the skull, having been cut through on three sides, is pried up and fractured across the base. A pad of gauze should be placed under the levers to protect the scalp.

In order to incise the dura safely so that pial and arachnoid vessels shall not be cut, a grooved director should be passed beneath it or it should be cut with scissors having a probe on one blade. Vessels in the dura which bleed or are to be divided are best closed by passing a fine ligature in a needle. Vessels crossing the line of incision should be tied thus in two places and cut between.

Fig. 717.—Temporal Osteoplastic Craniotomy.

The flap of bone and scalp has been turned down. The dura has been incised as a flap and turned down. Note free margin of dura. This margin permits suturing the flap of dura back in place at the close of the operation. Vessels in the dura have been caught with needle and thread and tied before they were cut.

If it is desired to expose the brain further in any direction, the rongeur forceps may be used, and then the dura cut in a radiating direction from the flap. Bleeding from the cortex of the brain is best controlled by gently laying a piece of gauze on the vessel. Adrenalin may be added. Clamps

should not be used. Larger vessels may be surrounded by a fine ligature in a needle. The dura should be cut as a flap and turned back (Fig. 717).

Having dealt with the intracranial condition, the wound is closed, unless a tumor which cannot be removed is discovered. In the latter event, a decompression operation may be indicated, and a part or all of the bone in

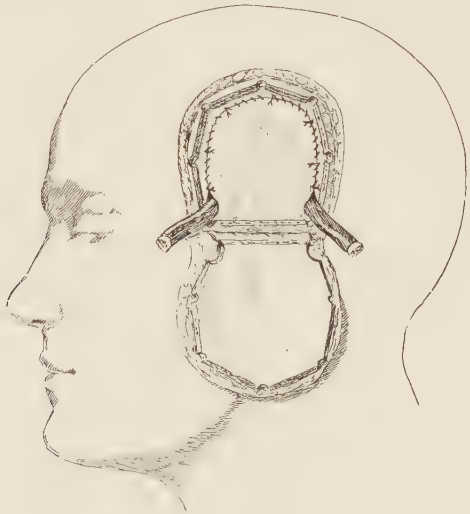

Fig. 718.—Method of Applying Drainage in Connection with Osteoplastic Craniotomy.

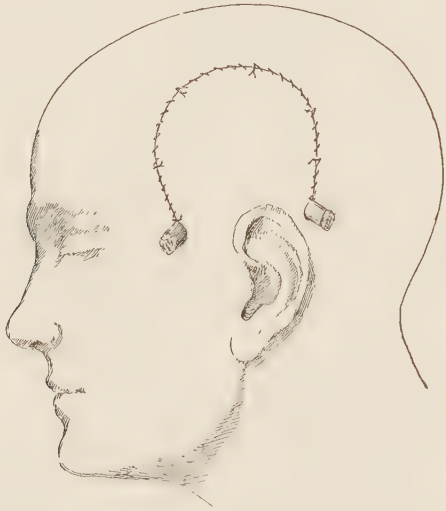

Fig. 719.—Osteoplastic Craniotomy Completed.
Wound closed with drainage.

the flap should be removed. Ordinarily the bone flap should be replaced. To do this, the dura is sutured with fine chromicized catgut. The bone-scalp flap is then pressed back into place, and the scalp sutured (see page 18). The first part of the dressing should be applied and the tourniquet removed. The suture and the pressure of the dressing are depended upon to prevent

bleeding. Over the trephine openings or wherever there is much separation, the periosteum also should receive a few buried sutures.

If drainage is necessary, as it is in some cases, especially in which a little packing must be left to check bleeding from a sinus, the gauze or wicking may be lead out directly through the wound (Fig. 718), but it is often better to carry it out obliquely through a special wound made outside of the flap. This drainage should be enveloped in rubber protective to prevent adhesions. It may be removed at the end of forty-eight hours (Fig. 719).

Temporal operations are performed for exploration for hemorrhage, for purposes of decompression, for the removal of tumors, for abscess of the temporal lobes, and for other conditions in the middle fossa or temporal

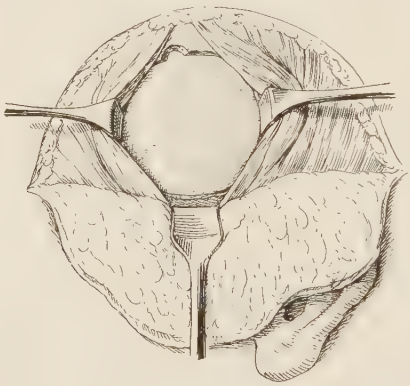

FIG. 720.—INTERMUSCULAR TEMPORAL CRANIOTOMY.
This is the operation done for decompression. A smaller flap of scalp should be turned down than is here shown. The dura is shown exposed but not yet incised.

regions of the brain. The temporal muscle and the strong temporal fascia furnish sufficient protection for the brain so that the preservation of the bone is not necessary. For exposing the temporal region, a curved incision is made, making an arc somewhat parallel to the superior border of the temporal fossa but lying below it, and terminating at the front of the upper border of the zygoma and on the same level behind the ear. This flap of scalp is turned down exposing the temporal fascia. The fascia is divided in a direction parallel with the fibers of the muscle and the incision deepened to the bone by blunt separation of the fibers. The periosteum is incised. The muscle is retracted laterally along with the periosteum. The trephine is applied carefully because of the thinness of the bone. From the trephine opening, with the bone-cutting forceps, the exposure is enlarged in any directon to the desired degree (Fig. 720). The opening in the dura should be made in such a way that the dura can be sutured back in place if necessary.

After dealing with the brain condition, the dura should be sutured (unless decompression is desired), the muscle with the underlying periosteum sutured over the opening, the temporal fascia closed by a running stitch, and the scalp-flap sewed back in place. Osteoplastic temporal operations are described above.

Suboccipital operations are done for the exposure of the cerebellum, the fourth ventricle, auditory nerve and basilar regions of the brain. The heavy muscular covering of this region makes it unnecessary to preserve the bone.

The tourniquet for the control of hemorrhage cannot well be used, and bleeding vessels must be cared for as they are exposed.

The position of the patient is important. The head must be held well forward; this is the first essential. All things being considered the lateral position is to be chosen. C. H. Frazier devised an attachment for holding the patient to the table by the shoulders. In order to give the best exposure and minimize venous bleeding, it is desirable that the lower part of the body be lowered (Fig. 721). H. Cushing operates with the patient's face downward, by supporting the forehead and malar prominences upon an extension beyond the end of the table, and the shoulders and upper chest upon a special rest.

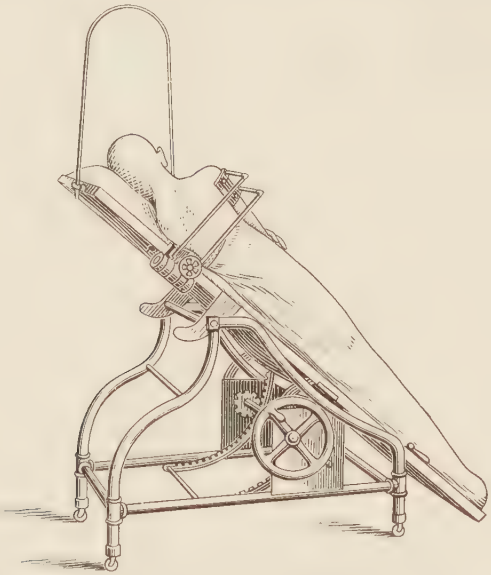

Fig. 721.—Device for Holding Patient on Table for Exposure of Occipital Region, Permitting Elevation of Head.

Note frame for screen between anesthetist and field of operation.

For most operations for conditions other than tumor, a *unilateral operation* suffices. The incision should begin at the tip of the mastoid process and pass outward parallel to the superior curved line, and 2 cm. above it, to the external occipital protuberance, and thence downward in the median line for about 8 cm. (3 inches), more or less, depending upon the thickness of the tissues (Fig. 722). This incision should include only skin, scalp and superficial fascia. They should be dissected free for 3 cm., and then the deep fascia and muscles divided down to the bone just below the superior curved line, leaving enough tissue for suture. This triangular musculocutaneous flap should be dissected away from the bone and strongly retracted. The trephine is applied midway between the mastoid process and the middle line. This opening may then be enlarged with the rongeur forceps in all directions, as far as the mastoid process, the median line, the lateral sinus and the foramen magnum. Such an opening will usually allow access sufficiently to displace the hemisphere for exposure of the auditory nerve.

The bleeding in this operation will be considerable unless hemostasis keeps pace with the incisions. The large openings in this part of the skull

transmit emissary veins which may require to be dealt with by plugging the openings with bone-wax. Crushing the bone will stop bleeding from these bony sinuses. At the conclusion of the operation the dura is sutured, and the musculocutaneous flap sewed back in place.

For operations upon tumors and whenever necessary to give a degree of displacement which cannot be secured by a unilateral operation, the *bilateral operation* is done. Inasmuch as this takes more tissue and involves more loss of blood than the one-sided operation it possesses disadvantages; but it does give better access in many of the conditions requiring operation by this route. The operation really amounts to two unilateral operations. A unilateral operation may be continued into a bilateral one whenever indicated. Or the latter may be planned from the beginning. In the last case an incision is carried from one mastoid process to the other just above the superior curved lines. This is intersected by a median incision down to the spinous processes of the upper vertebræ (Fig. 723). The two flaps are turned down and the

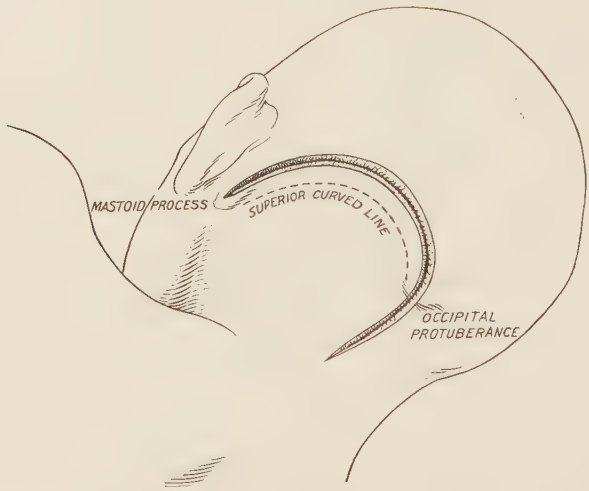

Fig. 722.—Incision for Unilateral Suboccipital Craniotomy.

skull opened on either side, upward to the lateral sinuses, across the middle line avoiding the torcular Herophilii, and downward into the posterior part of the foramen magnum. The dura may then be opened, and the medioccipital sinus ligated. This is the method of H. Cushing.

For exposing the *occipital lobes* and the *cerebellum*, it is customary to remove the bone; but the **osteoplastic flap operation** may be done. The bone in this region is often very thick. To expose both occipital lobes of the cerebrum and both lobes of the cerebellum, the upper border of the flap should be about 4 cm. (1½ inches) above the lateral sinus, the sides should extend downward and inward just behind the posterior border of the mastoid thickening, and the base should be broken across just above the foramen magnum. If the bone is thick it is not safe to attempt to fracture the base of the flap until the bone has been cut to weaken it where the fracture is desired. If this is not done there is danger of breaking the base into the foramen magnum. J. H. Kenyon (Annals of Surg., Jan., 1915) described a practical method. A longitudinal incision is made in the median line from the external occipital protuberance downward 5 or 8 cm. (2 or 3 inches).

This goes down to the bone. An elevator is passed into the wound and the soft parts separated from the bone on either side along the line of the desired fracture. A motor drill then bores holes along the line to weaken the base

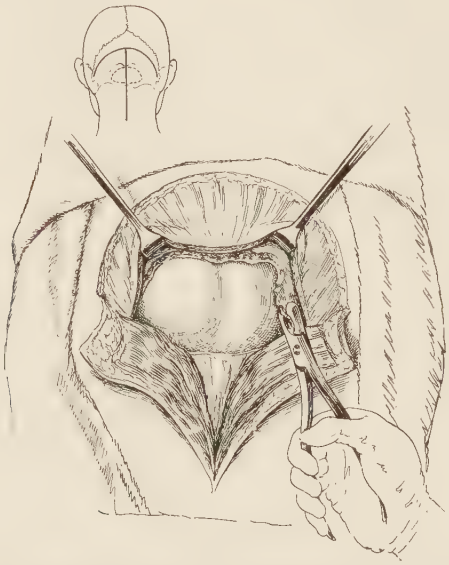

Fig. 723. -Bilateral Suboccipital Craniotomy.

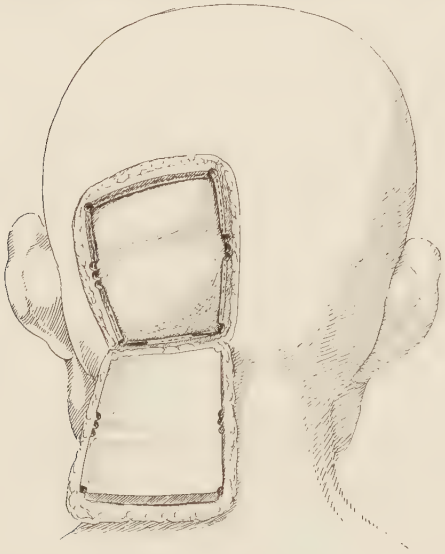

Fig. 724.—Unilateral Occipital Craniotomy.

Osteoplastic occipital flap turned down to expose cerebellopontine angle. The bone on three sides has been cut and fractured at the base of the flap. The dura is exposed.

of the flap. The same is done at the lower end of each lateral incision. The bone is then easily broken (Fig. 724). The cutting of the dural flap is not difficult. The occipital sinus and the falx cerebri are doubly ligated and cut between.

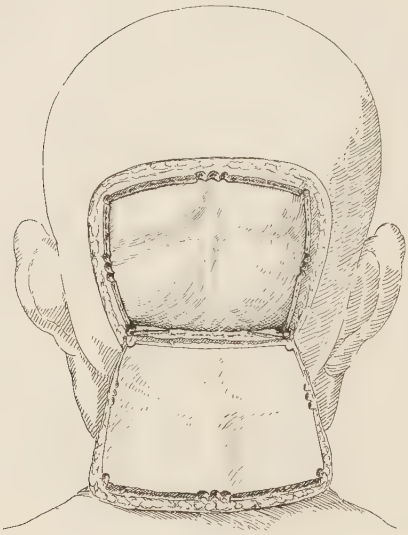

Fig. 725.—Bilateral Osteoplastic Occipital Craniotomy. First Stage.

Osteoplastic occipital flap turned down. Holes have been bored with a drill and the circular motor saw used to cut the bone between them. The base line of fracture has been weakened by boring holes at the lower ends of the lateral incision and through a median incision. The dura is exposed.

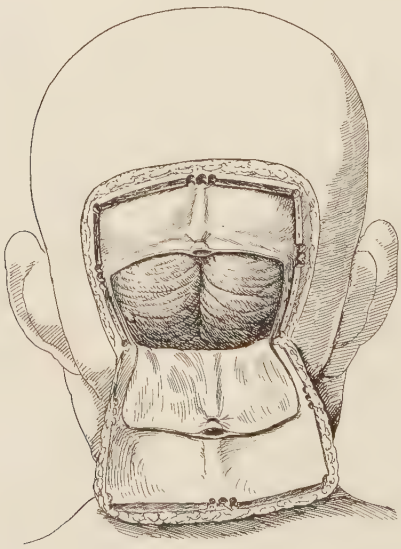

Fig. 726.—Bilateral Osteoplastic Occipital Craniotomy. Second Stage.

The bone flap has been turned down. The sinus or large vessels in the dura are tied by passing a ligature with a needle, and a flap of dura cut and turned down. Note free margin of dura.

For exposing the **cerebellopontine angle** by an osteoplastic flap the same method is used. An incision is carried upward from the posterior border of the mastoid to a point about 2.5 cm. (1 inch) above the lateral sinus. Another incision about 1 cm. (3/8 inch) to the same side of the median line is carried upward from below the occipital ridge to the same height. The two are connected by a transverse incision at their upper ends. The base of this flap should be 12 mm. (1/2 inch) above the foramen magnum and should be bored before it is broken (Fig. 725) (see Suboccipital Craniotomy, page 36). The treatment of the dura and the exposure of the brain are the same as for temporal craniotomy (Fig. 726).

Diseases of the Cranial Bones

There are certain diseases of the skull for which there is little treatment but which should be borne in mind because of their relations to the treatment of other conditions.

Atrophy of the bone may result from local or general nutritive disturbances. Such is the senile atrophy which may result in cranial defects.

Pressure, either from intracranial or extracranial tumors, may cause thinning of the bone and finally perforation. Natural decompression may be caused in this manner. The atrophy of *rickets*, giving rise to *craniotabes*, should be treated by the measures already given (Vol. I, page 32). Children suffering with this disease should have the position of the head upon the pillow frequently changed to prevent distortion of the skull.

The **hypertrophies, acromegaly, gigantism, osteomalacia,** and **osteitis deformans,** have been discussed. **Leontiasis ossea** has in some cases called for removal of masses of bone where pressure demanded such operation.

Infective Diseases of the Cranial Bones.—*Acute periostitis and osteitis* of the bones of the skull should, if possible, be prevented, by the free drainage of infections of the scalp. Abscess under the scalp, whether the result of infected wound, hematoma or contusion, should be freely opened. Unless this is done there is danger of infection of the bone. Infection of the bone, arising from extension of pericranial infection or developing as a primary osteomyelitis (*Pott's puffy swelling*), may secondarily involve the pericranial structures or give rise to meningitis, brain abscess or infection of the cerebral sinuses. Because of the danger of intracranial infection, osteomyelitis should be drained by trephining down to the dura. If free drainage external to the dura can be maintained there is little danger of subdural infection.

Necrosis calls for the removal of enough bone to provide free drainage; then, when the extent of the disease has declared itself, all dead bone should be removed. Care should be taken to uncover and remove the dead bone in cases in which the inner table is more widely diseased than the outer. The wound after operation for infected bone should be left open and packed with gauze. When granulations have developed and the infection has subsided measures may be taken to close the wound (see Operations on Bones, Vol. I, page 688). Even though a considerable bony defect exists, it need not necessarily be operated upon, as the tough scar tissue which grows in it furnishes adequate protection for the brain.

Tuberculosis of the skull, most commonly observed in children and especially in connection with the temporal bone, should be treated by general hygiene. Abscesses should be aspirated. Sinuses should be laid open and dead bone uncovered and removed (see Tuberculosis, Vol. I, page 276).

Syphilis of the cranium should be treated by active constitutional

measures. Constitutional treatment usually should be pushed to toleration. Where necrosis exists, free drainage should be secured and dead bone removed. If the patient's general resistance is poor, care should be taken in making new wounds lest they become infected and an acute cellulitis set up. When the patient is brought well under the constitutional treatment, these bony lesions heal often with striking rapidity (see Syphilis, Vol. I, page 283).

Tumors of the Cranial Bones.—These tumors are not notably different in their treatment from tumors in other bones. The malignant tumors should be removed; the benign tumors require no treatment unless pressure or cosmetics demand it.

Osteoma of the small external variety requires no treatment, unless for cosmetic reasons the patient desires its removal. When these tumors encroach upon the brain cavity, their removal is called for. They sometimes develop in the accessory sinuses, such as the frontal sinus. In these cases the tumor should be uncovered and removed. In their extirpation, the whole tumor wall should be removed. Chisel, burr, and rongeur are the instruments required.

Sarcoma presents serious difficulties. The diagnosis not being easy, the only treatment that can be curative is often deferred until hope is passed. Syphilitic osteitis and periosteitis, osteoma, and echinococcus cyst must be quickly excluded. By making a wide excision in the early stage of the growth, it should be possible to remove it. Rarely does the surgeon have such an opportunity: when he does he should grasp it quickly. The myleogenous sarcomata occur in the skull, and should offer a fairly hopeful prognosis if dealt with radically. In dealing with sarcoma, the surgeon should examine carefully to discover whether it may be a metastatic growth or the local manifestation of a general disease as is the case in myeloma.

Carcinoma invades the skull either by direct extension from an adjacent growth or by metastasis, and is, therefore, hopeless in most cases. When the invasion is from an epithelioma of the skin, there is often a possibility of its removal, and the disease should be eradicated by one of the methods already given (see Tumors, Vol. I, page 323).

Deformities of the Skull.—The deformities due to fractures, rickets, hypertrophies and atrophies of the bone are discussed above. Deformities associated with tumor require the treatment of that disease. In the case of any deformity, which gives rise to increase of intracranial pressure and which is not amenable to treatment, the symptoms may be relieved by decompression.

In *oxycephaly* ("tower head," "steeple skull") if the intracranial pressure is above normal and gives rise to distress, subtemporal decompression gives relief. The operation may be done first on the right side and then, if necessary, on the left side. Patients with this condition, suffering with disturbed vision, vertigo, neuralgia and other signs of pressure are decidedly relieved by operation. Operation is only indicated for the relief of pressure.

Intracranial Injuries And Diseases

General Principles of Treatment.—In the treatment of intracranial injuries and diseases, their close relation to the delicate vital organs gives them extraordinary importance. The surgeon should be familiar with craniocerebral topography. As he looks at the outside of the skull, he should be able to picture in his mind, the structures which lie within and their relations to the skull (Fig. 727).

The **dura mater** is a strong membrane, lining the skull and adherent to it. Its inner surface is covered with smooth endothelium, which articulates with the pia-arachnoid covering of the brain. The dura carries between its layers the great venous sinuses.

The **pia mater** is a delicate transparent membrane which closely covers the brain, dipping down into all its sulci and following every convolution. The *arachnoid* lies external to the pia, does not dip down into the sulci but bridges across them; it is a diaphanous membrane, supporting the external cerebral vessels.

The **brain** lies and hangs, supported and surrounded by subarachnoid fluid, blood-vessels and sinuses. It encloses the fluid-containing ventricles. All these are contained in an

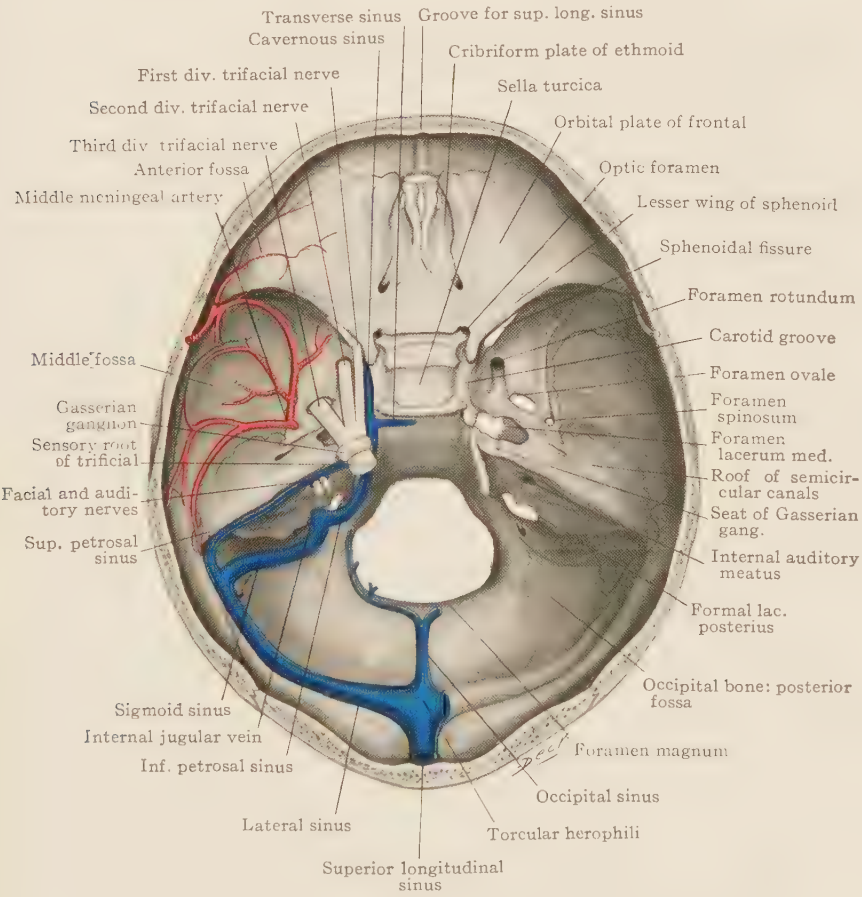

FIG. 727.—BASE OF SKULL.

Showing vessels and nerves on left side and bony openings on right side.

unyielding case. Both the cerebral fluid and the blood can escape from the inelastic cranium into extracranial channels with which they communicate, thus maintaining an equable intracranial pressure. Such a fluctuation takes place physiologically as the mass of blood and the blood-pressure in the cranium are influenced by respiration and cardiac pulsation. The exposed brain is observed to pulsate with these two movements.

The brain receives its nourishment chiefly through the two carotid arteries. Not withstanding the free anastomosis with the other vessels, through the circle of Willis, occlusion of an internal carotid, or especially of a common carotid, is apt to cause unilateral softening of the brain. The occlusion of both carotids, if rapid, is apt to cause fatal cerebral anemia. Slow and gradual occlusion of the vessels need not destroy life (Fig. 728).

The **motor area** of the cortex of the brain, from which originate the impulses to the muscular system of the body, occupies a narrow strip of the outer surface of the gyrus centralis anterior, and extends to the depth of the central fissure (fissure of Rolando). The area extends upward to the median fissure of the cerebrum and slightly over onto the mesial surface of the paracentral lobe. The lower limit of the motor area ends somewhat short of the fissure of Sylvius. The fibers from the motor cortex pass downward through the pyramidal tract. They degenerate throughout their whole extent after destruction of their cortical cells, and muscular paralysis results.

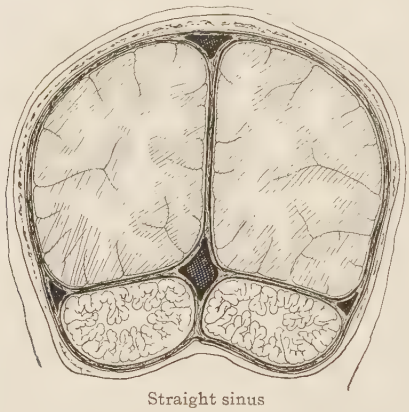

FIG. 728.—SINUSES OF BRAIN, SHOWN BY TRANSVERSE VERTICAL SECTION. The straight sinus is seen at the junction of the four lobes.

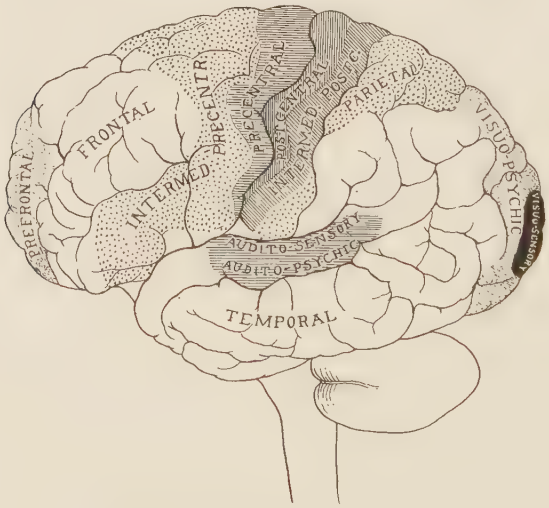

FIG. 729.—BRAIN SURFACE TOPOGRAPHY.

The cortical areas, concerned in *speech*, lie about the lower end of this motor area. The posterior part of the gyrus frontalis inferior is regarded as the motor center for speech. In right-handed people, the center for the recognition of spoken *words* lies in the gyrus temporalis superior of the left temporal lobe, below and behind the center for general audition. The center for the recognition of written words, or the visual *reading center*, is located in the outskirts of the visuopsychic field in the gyrus angularis. The *writing center* is in the posterior part of the gyrus frontalis medius, anterior to the motor area which controls the hands and fingers (Fig. 729).

The **sensory area** of the cortex is situated posterior to the motor area. The motor area extends to the depths of the central fissure anteriorly; the sensory area extends to the depths of the central fissure posteriorly. The sensory field, besides occupying the anterior portion of the gyrus centralis posterior, which is hidden in the central fissure, also occupies about the anterior half of the exposed external part of the gyrus. This is the area of common sensation, cutaneous sense, tactile sense, and muscular sense. The centripetal fibers to this area pass by way of the posterior part of the internal capsule and the thalamus.

The fields of **special sensation** lie posteriorly to and below this, where the sensations become more complex and involved with association. The sensation of pain and of temperature probably are located in the intermediate postcentral zone. The center for the recognition of objects and the stereognostic sense are situated in the parietal lobe. The *visual* sensory center is located in the occipital lobe especially on its mesial surface in the calcarine region. The *auditory* sensations are received in the gyrus temporalis superior. *Olfactory* sensations are believed to be received in the pyriform lobe or the adjacent areas (Fig. 730).

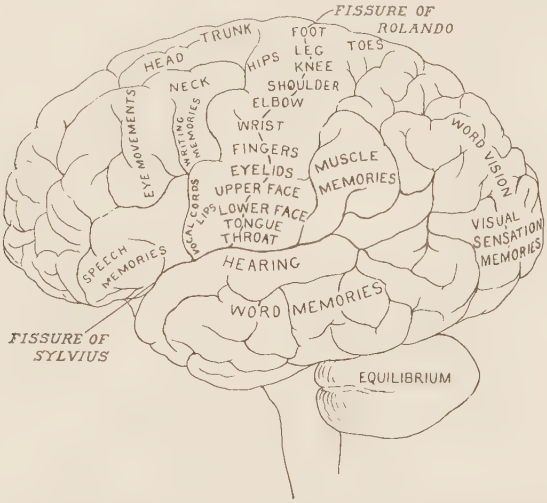

FIG. 730.—CORTICAL FUNCTION TOPOGRAPHY OF BRAIN.

Craniocerebral topography determines the position of the parts of the brain with reference to the exterior of the head.

Cranial Landmarks

Glabella.—Nasal eminence of the frontal bone in the median line midway between superciliary arches.

Nasion.—Median point of junction of nasal and frontal bones.

Inion.—External occipital protuberance.

Bregma.—Anterior fontanelle at junction of coronal, frontal, and sagittal sutures.

Condyloid Point.—Outer end of condyle of inferior maxilla.

Midzygomatic Point.—Middle of horizontal upper border of zygoma.

Midsagittal Point.—Middle of median line between nasion and inion, usually lying perpendicularly above external auditory meatus.

Lambda.—Posterior fontanel at junction of lambdoid and sagittal sutures, situated 8 to 10 cm. (3¼ to 4 inches) behind the superior Rolandic point and 6 or 7 cm. (2¼ to 2¾ inches above the inion.

Stephanion.—Point of intersection of coronal suture and superior temporal ridge.

Auricular Point.—Centre of external auditory meatus.

Supra-auricular Point.—Point at root of zygoma vertically above auricular point.

Nasolambdoidal Line.—An imaginary line beginning at the nasofrontal groove, passing backward 6 mm. (¼ inch) above the external auditory meatus, and ending 1 cm. (⅜ inch) above the lambda or 7 cm. (2¾ inches) above the inion. This line lies on a level with the lower part of the inferior frontal convolution of Broca, 4 to 6 cm. (1 9/16 to 2⅜ inches) of the posterior limb of the fissure of Sylvius, and the base of the angular gyrus.

Coronal Suture.—Suture between frontal and parietal bone, on a line from bregma to midzygomatic point, lying 2.5 to 3.8 cm. (1 to 1½ inches) anterior to fissure of Rolando.

Sagittal Suture.—Median suture between parietal bones.

Squamous Suture.—Suture between parietal bone and squamosa.

Lambdoid Suture.—Suture between parietal and occipital bones.

The *supra-orbital arch* is the upper margin of the orbit. The *superciliary ridge* is the first eminence above the supra-orbital arch. The *frontal eminence* is the second prominence above the supra-orbital arch. The *internal angular process* is the inner end of the supra-orbital arch; the *external angular process* is the external end. The *retro-orbital tubercle* is an apophysis on the posterior border of the upper part of the frontal process of the malar bone, lying just below the fronto-malar suture.

Superior Rolandic Point.—A point 55 per cent. of distance from nasion to inion in median line. This is the upper end of the Rolandic fissure.

Sylvian Point.—Point at which Sylvian fissure reaches the convexity of the hemisphere 2.9 to 3.2 cm. (1⅛ to 1¼ inches) directly behind the external angular process (Fig. 731).

On the *naso-inial line*, 5.6 per cent. equals 1.3 to 2 cm. (½ to ¾ inch). The superior Rolandic point is 1 to 2 cm. posterior to the centre of the naso-inial line. It is 2 or 3 cm. posterior to the bregma. The presence of the parasinoidal sinuses renders this region very difficult of access. In large heads it is about 18 cm. and in small heads about 17 cm. posterior to the nasion in the median line.

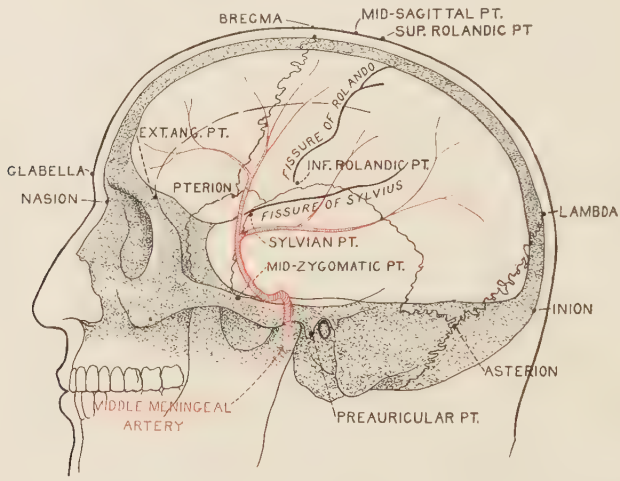

FIG. 731.—RELATIONS OF BRAIN AND SKULL.
Showing cranial landmark points, brain fissures, and middle meningeal artery.

The *lower end of the fissure of Rolando* is 9.5 cm (3¾ inches) below the upper end on a line passing downward and forward at an angle of from 65 to 75 degrees, with the median line. It is 7 cm. (2¾ inches) above the condyloid point on a line perpendicular to the upper border of the zygoma, or 5.5 cm. (2⅛ inches) above the zygoma. It lies generally about 1 cm. above the Sylvian line.

The *fissure of Rolando* may be located by connecting the two points above described. If the line is continued downward it should cross the midzygomatic point. The fissure lies entirely under the parientalbone. The superior Rolandic point is 4 to 5 cm. (1 9/16 to 2 inches) and the inferior Kolandic point about 3 cm. (1 3/16 inches) posterior to the temporoparietal suture.

The *fissure of Sylvius* lies in the direction of a line connecting the external angular process of the frontal bone and a point 77 per cent. of the distance from the nason to the inion. This line crosses a point at the junction of the middle and lower thirds of a line connecting the condyloid point and the midsagittal point.

The *Sylvian point*, or bifurcation of the fissure, is opposite the antero-inferior angle of the parietal bone. This point is found by carrying a straight line from the frontomalar junction horizontally backward for 3.1 to 3.5 cm. (1¼ to 1⅜ inches), and from this point vertically upward for 6 to 12 mm. (¼ to ½ inch).

The *Sylvian line* is found by carrying a straight line from the Sylvian point backward and upward to a point 1.2 to 1.8 cm. (½ to ¾ inch) below the most prominent point of the parietal eminence. This marks the horizontal or posterior limb of the fissure of Sylvius; it is 7.5 to 10 cm. (3 to 4 inches) long. From the Sylvian point, the fissure runs backward

and slightly upward; at first it follows the squamous suture; and thence it passes backward and upward to a point below the parietal eminence. The ascending limb passes upward and forward from the point of bifurcation. The anterior limb runs from the same point forward in the direction of the squamous suture.

The floor of the middle fossa of the skull lies on a level with the upper border of the zygoma. The motor area lies entirely under the parietal bone, on the top of the brain rather than on the side. A meridian line from the midsagittal point, passing downward and forward at an angle of 60 degrees, to the midzygomatic point lies in the direction and shows the position of the middle of the precentral convolution. The temporal lobe is covered by the squamous portion of the temporal bone. The Sylvian point is opposite the island of Reil. The *middle meningeal artery* curves forward and upward from the foramen spinosum across the front of the temporal lobe, lying against the anterior part of the squamous portion of the temporal bone, grooving the antero-inferior angle of the parietal bone, and crossing close to the Sylvian point (Fig. 732).

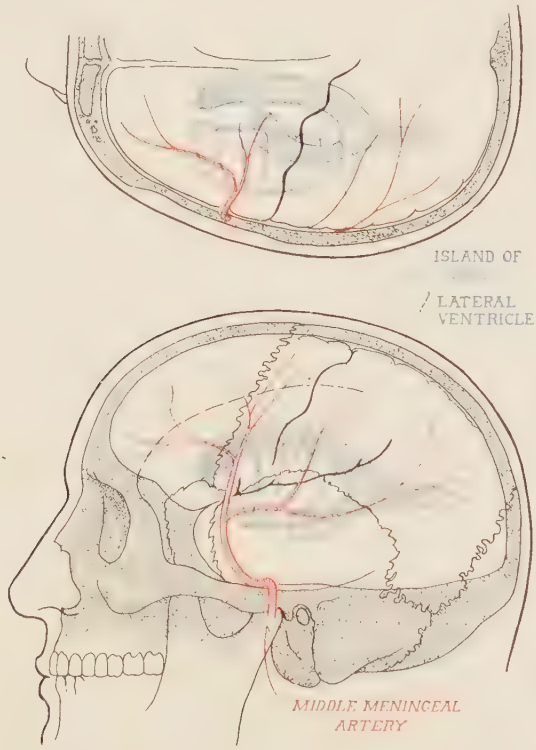

FIG. 732.—SHOWING RELATIONS OF LATERAL VENTRICLE, ISLAND OF REIL, SINUSES AND MIDDLE MENINGEAL ARTERY.

The *superior longitudinal sinus* may be outlined by drawing two straight lines, each starting at the middle of the nasofrontal suture, where is located the foramen cecum, and diverging as they pass backward on either side of the sagittal suture, the left one ending 5 mm. (3/16 inch) to the left of the inion, the right ending 10 mm. (3/8 inch) to the right of the inion.

The *lateral sinuses*, in their transverse portion, form a slight curve, convexity upward, from the external occipital protuberance to a point back of the external auditory meatus. The highest point reached by the sinus is at the mastoparietal suture, 1.5 to 2.5 cm. (5/8 to 1 inch) above a line drawn from the inion to the center of the external auditory meatus, and slightly external to the center of this line. The sigmoid portion of the sinus begins back of the ear on a level with the upper border of the external auditory meatus, and passes in a curve, with its convexity forward, over the mastoid process to its apex, lying 10 to 12 mm. (7/16 to 1/2 inch) behind the external auditory meatus and extending 5 mm. (3/16 inch)

below it. The sigmoid portion of the sinus lies at a depth of about 7 mm. (3/8 inch) from the external surface of the mastoid process. This distance is very variable.

The *lateral ventricle* may be located by taking a point 3.1 cm. (1 1/4 inches) above and the same distance behind the external auditory meatus. The ventricle lies a distance of from 5 to 6.3 cm. (2 to 2 1/2 inches) from the surface. It is located by Chipault as lying opposite the junction of the third and fourth tenths of the lambdoidal line. F. Hartley found that the ventricle is reached at a distance from the surface of the brain equal to one-third of the transverse diameter of the whole brain at this point. The diameter of the whole head is taken with calipers; from this is subtracted the thickness of the scalp and skull, multiplied by two; one-third of the remainder gives the desired distance. A needle passed horizontally enters the ventricle at this distance, the descending horn of the ventricle may be reached by passing a needle through the middle temporosphenoidal convolution directly above the external auditory meatus. The posterior horn is reached by passing the needle through the middle temporosphenoidal convolution in a line with the posterior border of the mastoid process. (Fig. 732).

Craniocerebral Localization.—Chipault's method is most commonly employed. It is based on relations of the parts of the brain to the skull as determined by averaging the measurements of a large number of skulls. The objection to the method is that it requires working out for each case the percentage distances between the nasion and inion and dividing the primary and secondary lines into tenths. It is applicable to skulls of all sizes, shapes, and ages (Fig. 733).

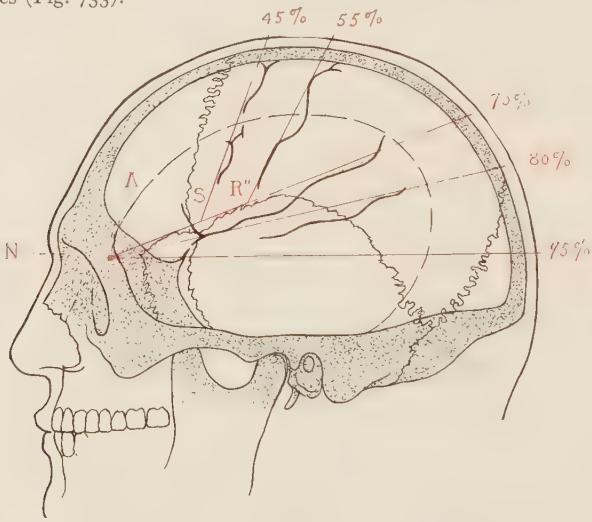

FIG. 733.—CRANIOCEREBRAL TOPOGRAPHY BY CHIPAULT'S LINES.
N, Nasion; *S*, Sylvian point; *R''*, inferior Rolandic point; *A*, external angular process.

A median line is drawn from nasion to inion (median naso-inial line). This line is divided by certain percentage points. The *precentral point* is marked at 45 per cent. of the distance from nasion to inion. The *Rolandic point* is marked at 55 per cent. of the distance. The *Sylvian point* is marked at 70 per cent. of the distance. The *lambdoidal point*, or *superior temporosphenoidal point*, is marked at 80 per cent. of the distance. The *lateral sinus point* is marked at 95 per cent. of the distance.

Thus if the median distance over the scalp between nasion and inion is 30 cm., then the precentral point would be $^{45}/_{100}$ of that distance, or 13.5 cm. from the nasion; the Rolandic point $^{55}/_{100}$ of 30, or 16.5 cm. from the nasion; the Sylvian point $^{70}/_{100}$ of 30, or 21 cm. from the nasion; the lambdoidal point $^{80}/_{100}$ of 30, or 24 cm. from the nasion; and the lateral sinus point, $^{95}/_{100}$ of 30, or 28.5 cm. from the nasion. If the med an nasoinial line were 12 inches long, the precentral point would be $^{45}/_{100}$ of 12, or 5.4 inches from the nasion.

The three *primary lines of Chipault* are the *Sylvian line* from the retro-orbital tubercle (*A*) to the Sylvian point, the *lambdoidal line* from the retro-orbital to the lambdoid point, and the *lateral sinus line* from the retro-orbital tubercle to the lateral sinus point. Chipault divides these three primary lines into tenths of their length. Thus, if the Sylvian line is 22 cm. long, it is divided into 10 parts, each 2.2 cm. long.

The *two secondary lines of Chipault* are the *precentral line*, which passes from the point between the second and third tenths of the Sylvian line to the precentral point on the naso-inial line, and the *Rolandic line*, which passes from the point between the third and fourth tenths of the Sylvian line to the *Rolandic point* on the naso-inial line. The *precentral line* commences at the bifurcation of the Sylvian fissure, follows the ascending limb of the fissure and in its two upper thirds lies over the precentral fissure. The *Rolandic line* begins below at the lower extremity of the Rolandic fissure and follows it throughout.

The two secondary lines are marked off in tenths. The tenths on the primary lines are numbered from the front backward; on the secondary lines, from below upward.

The *inferior frontal fissure* begins at the junction of third and fourth tenths of the precentral line. The anterior branch of the *middle meningeal artery* crosses the second tenth of the three primary lines. The *lateral ventricle* is opposite the junction of the third and fourth tenths of the lambdoidal line.

The *technic* of applying this method of measurements in operations on the brain is not difficult. The scalp should be shaved and the necessary lines and landmarks marked on the scalp with silver nitrate or with a marking pencil. To mark a point on the skull for identification, a sharp-pointed instrument is passed through the scalp, and with a few taps of a mallet a puncture is made in the outer tables of the skull, which can be seen when the scalp is turned back and the skull exposed. Only the area to be sought need be marked on the skull. The only lines that require to be marked are those which have to do with the localization of that area.

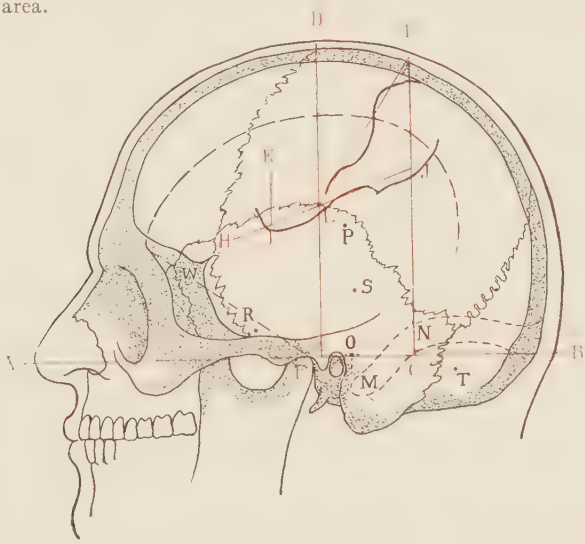

FIG. 734.—CRANIOCEREBRAL TOPOGRAPHY BY REID'S LINES.

Reid's method of craniocerebral localization has three primary lines. The *base line* (*AB*) is drawn horizontally from the lowest part of the infra-orbital border through the center of the external auditory meatus, and thence backward (Fig. 734). The *anterior perpendicular line* (*DE*) is drawn from the pre-auricular point (a depression on the base line between the condyle and the tragus), at right angles to the base line, and ends at the median line above. The *posterior perpendicular line* (*FG*) begins at the base line at a point vertically above the posterior limit of the mastoid process and passes upward vertically to the median line. The *Sylvian fissure* (*HJ*) extends from a point 3.1 cm. (1¼ inches behind the external angular process to a point 1.8 cm. (¾ inch) below the most prominent point on the parietal eminence. The *ascending limb of the Sylvian fissure* (*IK*) may be marked out by drawing a vertical line, beginning at the Sylvian line 1.8 cm. (¾ inch posterior to its anterior end, and passing upward for 2.5 cm. (1 inch). The *Rolandic fissure* (*LF*) is represented by a line beginning at the upper end of the posterior perpendicular line and passing diagonally downward and forward to the point where the Sylvian line crosses the anterior perpendicular line. The *sigmoid portion of the lateral sinus* (*M*) lies at a point on the base line 1.8 cm. (¾ inch) posterior to the center of the external auditory meatus. The *transverse portion of the lateral sinus* (*N*) lies at a point 2.5 cm. (1 inch) posterior to the center of the external auditory meatus and 6 mm. (¼ inch) above the base line. The *mastoid antrum* (*O*) lies at a point opposite the intersection of a vertical line passing along the posterior wall of the external

auditory meatus and a horizontal line along the upper border of the meatus. The *latera ventricle* (*P*) is opposite a point 3.8 cm. (1½ inches) above the external auditory meatus. The *anterior branch of the middle meningeal artery* (*R*) lies under the bone at a point 3.8 cm. (1½ inches) posterior to the external angular process, and 3.8 cm. (1½ inches) above the zygomatic arch. The *posterior branch of the middle meningeal artery* is found at a point 4.4 cm. (1¾ inches) posterior to the external angular process, and 6 mm. (¼ inch) above the zygomatic arch.

The *usual site of cerebral abscess* (*S*) is the temporosphenoidal lobe at a point 1.8 cm. (¾ inch) above the base line, on a line drawn vertically along the posterior border of the external auditory meatus. The *usual site of cerebellar abscess* (*T*) is opposite a point 3.8 cm. (1½ inches) behind the center of the external auditory meatus, and 6 mm. (¼ inch) below the base line. These figures are all calculated upon the basis of an average adult skull.

Krönlein's method of craniocerebral localization employs three parallel vertical, two parallel horizontal lines and two oblique lines (Fig. 735). The *inferior horizontal line* (*GB*) passes through the inferior border of the orbit and the superior border of the external auditory meatus. The *superior horizontal line* (*UH*) is parallel with the inferior line and passes through the upper border of the orbit. The *anterior vertical line* (*ZS*) passes through the midzygomatic point. The *middle vertical line* (*CR*) passes through the condyloid point.

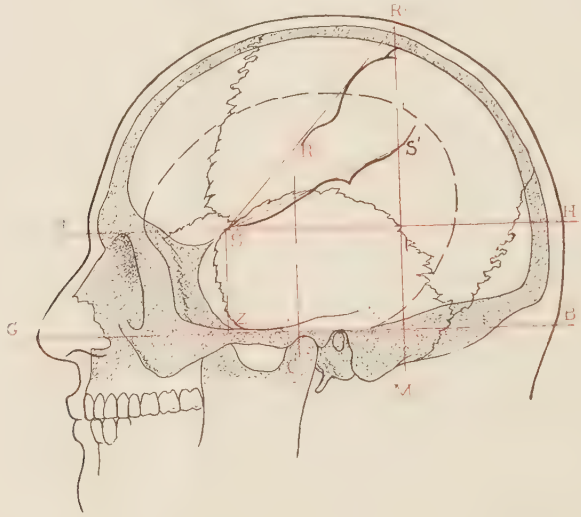

Fig. 735.—Craniocerebral Topography by Körnlein's Lines.

The *posterior vertical line* (*MR'*) passes through the most posterior part of the posterior border of the mastoid process. The *Rolandic line* (*SR'*) begins at the point of intersection of the superior horizontal and anterior vertical lines and ends at the point of intersection of the posterior vertical and median lines. The inferior extremity of the Rolandic fissure (*R*) lies opposite the point where this line crosses the middle vertical line. The *Sylvian line* (*SS'*) is found by bisecting the angle formed by the Rolandic line and the superior horizontal line, the Sylvian fissure extending from the apex of the bisected triangle to the point on the posterior vertical line where the bisecting line crosses it. The main trunk of the *middle meningeal artery* crosses the anterior vertical line just above the inferior horizontal line; the anterior branch lies at the intersection of the superior horizontal and anterior vertical lines; the posterior branch runs along just below the superior horizontal line between the anterior and posterior vertical lines. *Otic abscess* is explored for in the area bounded by the middle and posterior vertical lines and the upper and lower horizontal lines.

For determining these various lines and points, instruments made of flexible metallic bands have been devised. The differences in human brains and skulls give a small margin of error. The surgeon should be familiar with the appearance of the surface of the brain so that he shall recognize the important fissures and convolutions. The fissure of Sylvius is easily identified. If necessity demands it the motor centers of the paracentral convolution may

be determined by testing their electric reaction. A fine platinum wire electrode with a blunt end is used for this purpose. It is covered with a glass handle, between which and the tip it is twisted into a spiral to obviate the danger of pressure which might wound the pia-arachnoid (Fig. 736). A faradic current should be used which is just strong enough to cause muscle fibers to contract. (It may be tested on some exposed muscle such as the temporal.) If there is cerebrospinal fluid under the arachnoid, it should be evacuated by a puncture at a sulcus so that the membrane shall lie close to the brain. The patient should not be deeply narcotized. A negative pole is applied to the peripheral region innervated by the cerebral area to be tested. The platinum electrode is lightly applied to the cortex. This test will positively give contraction of the muscle receiving its nerve supply from the faradized cortical cells unless there is degeneration of the nerves passing through the pyramidal tract.

Fig. 736.—Electrode for Testing Electric Reaction of Motor Area and Motor Nerves while Operating.

The pia-arachnoid being exposed, when it becomes necessary to incise the cortex for exploration, for the removal of a tumor, or for the extirpation of a cortical area, the cortical meningeal vessels should be ligated on either side of the incision. It is best that the incision should not cross a sulcus. For ligatures, very fine catgut is preferable. The dissection should be done mostly with blunt instruments, but not with the fingers.

Bulging of the brain may be prevented by elevation of the head, by seeing that there is no impediment to respiration, or by making punctures of the arachnoid at sulci to permit the escape of cerebrospinal fluid. Lumbar puncture to remove fluid may be called for during an operation. It is a simple procedure, and the fact of the skull being open does not seem to add to its hazard. It should not be practised in cases of brain tumor situated below the tentorium, because of the danger of fatal disturbance in the basilar centres. In the case of tumors above the tentorium, the gradual withdrawal of fluid may be of help during the course of an operation for decompression or removal of the tumor. The puncture should not be made until the dura is exposed and ready to be opened. In suboccipital explorations, if high intracranial pressure is found, the dura should be incised low down near the foramen magnum, and the posterior cisterna opened to permit the escape of fluid. This procedure makes lumbar puncture unnecessary.

The loss of a considerable amount of brain substance need not create serious disturbance, particularly if areas which have no specially localizing function are removed. Frazer has removed as much as one-third or one-half of one cerebellar hemisphere without causing any apparent disturbance of brain function. The function of the missing part is apparently assumed by the remaining hemisphere. Such operations are necessary in some instances to expose the cerebellopontine space; and often hernia cerebri or uncontrollable extrusion of brain tissue can be treated only by removal of brain substance.

The advantage of *outward dislocation* of the brain is always to be borne in mind in intracranial operations. It is possible, by making an osteoplastic flap on one side of the skull, to perform an operation through a smaller opening on the opposite side by virtue of dislocating the brain partially

through the larger opening. Such a procedure allows freer access to tumors and permits wider exploration by giving more room within the cranium because some of the cranial contents are extruded through the opening.

To lessen the danger of meningitis, in cases in which the subarachnoid space is exposed to infection, *hexamethylenamin* may be administered internally as it finds its way to the cerebrospinal fluid. It may be given for this purpose as a preliminary to operations involving the meninges.

Concussion of the Brain

Concussion of the brain is the disturbance which results from sudden traumatism which has not produced discoverable anatomic changes. Satisfactory treatment of this condition revolves around diagnosis. When, after a traumatism to the head, fracture, intracranial hemorrhage, and laceration has been ruled out, and only concussion remains, the treatment is simple. The patient should be kept quiet and recumbent in bed. This is the main thing. The bowels should be moved by a laxative or enema. The diet should be fluid. Tradition calls for an ice-cap or other temperature lowering application to the head. I do not know that this does any good.

Serious heart weakness and lowering of blood-pressure call for their appropriate treatment. They are due, perhaps, to an inhibitory effect of the traumatism upon the basilar centers, and are to be treated the same as shock. Having excluded hemorrhage, the head should be lowered. In the absence of such an appliance as Crile's pneumatic suit, the surface tension may be increased and the depleted internal vessels filled by bandaging the limbs from their extremities up to the trunk. Abdominal pressure has also proved of service in emptying the dilated veins of the splanchnic area.

In true concussion, the stupor tends to subside. If it does not do so after a few hours or days, the surgeon may know that he has to deal with some other condition. Irritability, restlessness, or convulsive movements mean the addition of pressure or laceration, which should be met by their appropriate treatment. The patient should be watched for localizing symptoms.

After consciousness has returned and the grave symptoms have subsided, the patient should be kept quiet, a light diet prescribed, and freedom from responsibility enjoined until the symptoms of headache, vertigo, and muscular weakness have gone.

The muscular unbalance, headache, and circulatory and nervous disturbance which sometimes persist, are probably due to vasomotor depression, and may be relieved by alternate hot and cold douching. The douches may be given for half a minute each at a temperature of 45°C. (113°F.) and 14°C. (59°F.), ending always with the cold.

Contusion of the Brain

Contusion of the brain is that condition, following sudden traumatism to the head, in which there are added to the concussion anatomic changes which are discoverable in the nature of minute hemorrhages, damage to blood-vessels, producing extravasation of blood elements, and slight lacerations or cellular separations caused either by the primary traumatism or by the extravasated materials, all of which are not gross enough to be described as cerebral hemorrhage or laceration. The treatment is that of concussion. Usually this suffices, and after a period of several weeks the patient goes on to recovery. Continuous improvement even though slow calls for no additional treatment. These patients often desire to be up and about and to re-

turn to work prematurely. So long as there is headache, vertigo, muscular weakness, or evidence of abnormal cerebral pressure as shown by slow pulse and venous stasis of the retina, rest and quiet should be insisted upon.

In cases which do not improve, localizing symptoms should be sought. If the signs of cerebral pressure persist, the lumbar puncture which is employed to determine the presence or absence of blood in the cerebrospinal fluid, may draw off enough fluid to have a curative effect.

If the evidences of pressure are positive and unabated, in the absence of localizing symptoms, the skull may be trephined in the temporal fossa between the separated fibers of the temporal muscle. Upon incising the dura, clear or bloody cerebrospinal or edematous fluid may be found. The liberation of this will often suffice to effect a cure. If after trephining upon one side, a bulging of the dura, indicating pressure, is found, and if after incising the dura no excess of fluid is discovered, the opening should be enlarged with the rongeur in search of clot. None being found, the wound should be closed, and the effects of the decompression awaited. No improvement appearing, a similar operation should be done upon the opposite side. Often when no lesion is discovered, the operation will sufficiently reduce the pressure to turn the balance in the favor of recovery.

Compression of the Brain

Whether compression of the brain is due to foreign body, depressed fracture, tumor, blood-clot, excess of cerebrospinal fluid, extensive venous occlusion, or edema, the treatment consists in either (1) removal of the compressing factor, (2) reducing the amount of normal fluids in the skull, or (3) making more room for the cerebral contents by removing some of the skull. All of these are aimed to prevent the ultimate fatal anemia of the cardiac and respiratory centers in the medulla. The skull-box itself is unyielding; the brain is incompressible as water; any cerebral content, over and above that which is normal, must either destroy brain substance and replace it, or it must cause the extrusion from the skull-box, through some of its numerous openings, of cerebrospinal fluid, blood or brain substance. When the pressure reaches a certain point, greater than that of the blood-pressure, blood is squeezed out of the intracranial vessels. When this pressure begins to produce anemia of the vital medullary centers, and the vasoregulator mechanism has done all it can to keep up the blood-pressure in the vessels, if the pressure outside of the vessels increases, death takes place. The rise of systemic blood-pressure in case of increased intracranial pressure is an essential and salutary vasoregulator function. Brain compression is a mechanical condition which must be met by mechanical treatment, but not by lowering the systemic blood-pressure.

Accessible clot, abscess, tumor, or other compressing agent should be removed. Edematous fluid, which is producing serious pressure, should be evacuated. In the presence of edema, noninfective meningitis and certain other inaccessible or irremovable compression factors, the amount of normal fluid in the skull may be reduced and more room secured by lumbar puncture. Decompression operations accomplish the same result. There is no merit in reducing the amount of circulating fluid by means of bleeding or inhibiting the fluid intake. The operative expedients may always be resorted to as temporary measures of relief in an impending emergency.

The withdrawal of cerebrospinal fluid by lumbar puncture under these circumstances is by no means free from danger. A number of fatalities have attended this simple operation. After the withdrawal of spinal fluid,

the intracranial pressure may become much greater than the intraspinal pressure, the brain may be forced down against the foramen magnum so strongly that immediately fatal anemia of the medulla, or compression of the fourth ventricle and fatal edema of the medulla, may occur. This danger seems to be obviated if a decompression operation upon the skull has been done before the puncture is made.

Blood-letting was once much resorted to, especially in compression due to intracranial hemorrhage. It is rarely of value. The natural physiologic mechanism for regulating blood-pressure had usually better be depended upon. Death in cerebral compression is ultimately due to a failure of the pressure-maintaining mechanism, and when this last stage is approached the patient needs his blood. The exceptional conditions under which phlebotomy may be practised belong in the province of the internist.

Decompression of the brain is an operation which has proved of much value and is finding a constantly increasing field of application, especially in tumors of the brain. For cerebral compression the operation is best done in the temporal region (see Temporal Craniotomy, page 36). The temporal muscle should be preserved, by separating its fibers, in order to prevent hernia cerebri, and to afford protection to the brain. In right-handed persons the operation should be done on the right side. Here the squamous wing of the temporal bone covers a fairly silent cortical area. The trephine opening should be made posterior to the middle meningeal artery and below its posterior branch. It should be remembered that the lower end of the fissure of Rolando lies just above the squamous (temporoparietal) suture from 4 to 7 (average 5.5 cm.) above the zygoma. The opening may be enlarged in all directions, but it should not go above this inferior Rolandic point. The posterior branch of the middle meningeal artery will be found in the dura, and need not give trouble. The size of the opening made must vary with the degree of bulging encountered. Usually an opening about 5 cm. (2 inches) in diameter is made. The dura should be incised so that it shall not restrain the brain, and not be sutured. Some surgeons remove it. The muscle and temporal fascia should be sewed in layers. No drainage should be required or used lest it be responsible for hernia cerebri. A unilateral operation usually suffices. Later, if necessary decompression may be done upon the other side.

In subtentorial lesions, especially in tumors of the cerebellum, the suboccipital operation is done (see Suboccipital Craniotomy, page 36). This gives the protection of the suboccipital muscles. The general principles of the operation are the same as those of the temporal operations. Here, for decompression purposes, the bilateral procedure is, perhaps, more efficacious than the unilateral operation. In compressing disease, situated below the tentorium, it may be hoped that suboccipital decompression will relieve the pressure which causes occlusion of the exit from the fourth ventricle, if such occlusive pressure be present.

Intracranial Hemorrhage

The treatment of intracranial hemorrhage may be either expectant or operative. Small hemorrhages which are not causing serious compression, which do not involve important areas, which will not leave irritating adhesions, or which are inaccessible, may be left to be absorbed. Hemorrhages which are producing serious pressure, which are paralyzing important organs, which are apt to leave epilepsy-engendering patches of adhesions, should be exposed and the clot removed if it is accessible. It should be remembered that clot itself does not destroy at once the brain structure. It produces

anemia by pressure; and intracerebral clot causes a separation of structures. If clot is at once removed, restoration of brain function may be expected.

Extradural Hemorrhage.—The treatment of extradural hemorrhage should be operative exposure of the clot, removal of the same, and stanching of the bleeding as soon as the diagnosis is made. Most of these hemorrhages are from the trunk of the middle meningeal artery or one of its main branches, and operation in the temporal region is called for. The best approach is by trephining between the separated fibers of the temporal muscle (see Temporal Craniotomy, page 36). If the first opening does not discover the clot, a subsequent opening in the next most probable site should be made. This is better than turning down an osteoplastic flap, unless the site of the trouble is positively known. The middle meningeal, it should be remembered, after entering the skull through the foramen spinosum, passes outward and curves upward, grooving the bone under the temporal fossa. It reaches the squamous wing of the temporal bone just in front of the condyloid point, passes upward and forward, and bifurcates about two fingers' breadth above the zygoma and a thumb's breadth behind the frontal process of the malar bone. Its branches spread out over the whole temporal region, and hemorrhage may be looked for anywhere within this zone. In trephining for meningeal hemorrhage the first point may be the temporal fossa about 2.5 or 4 cm. (1 or 1½ inches) above the midzygomatic point. A second place is 5 cm. (2 inches) above the midzygomatic point. A third place of choice is the posterior temporal region in a vertical line from the posterior border of the mastoid process on the same horizontal as the first opening. It should be borne in mind that the middle meningeal may be ruptured at the foramen spinosum by fracture of the base, and that hemorrhage may involve the base as well as the lateral region. Commonly it will be found that a fracture has caused the rupture of the vessel and the site of rupture can be located by the fracture. The pressure in this vessel is so great that unless operation is done a fatal amount of clot will be produced in most cases.

Rupture of veins or sinuses may also be responsible for extradural hemorrhage. The surgeon should have in mind the possibility of the hemorrhage being located on the side opposite that which received the blow, and, indeed, the possibility of bilateral hemorrhage. Because of the hemorrhage usually being below the motor area, no localizing symptoms are present to serve as a guide; but in many cases, if the patient is carefully watched, twitching of the face or upper extremity may be observed as the upper edge of the clot advances. These focal indications may sometimes be confused, and facial symptoms may be due to motor area disturbance or to basilar fracture affecting the facial nerve.

Hemorrhage occurring beneath an osteoplastic flap after the closure of a craniotomy wound is not uncommon, and calls for reopening of the wound.

It should be borne in mind that concussion commonly accompanies this hemorrhage, the latter coming on after the symptoms of the former have abated. The development of pressure symptoms under these circumstances is quite characteristic. Impediment to the return flow of blood from the eye appears early, and can be discovered in a tortuosity of the veins and edema of the eye-ground, usually first on the affected side.

When the hemorrhage is found, the trephine opening should be enlarged sufficiently to allow the removal of the clot and the checking of the hemorrhage. Often it will be found that upon the removal of the pressure the bleeding becomes aggravated. The torn vessel may be closed temporarily with gauze packing while a new trephine opening is made or the rongeur applied to expose the place to be ligated.

Ligation of the middle meningeal artery is the first thing to be done in a steadily progressing hemorrhage of known meningeal origin. The skull should be exposed as in temporal craniotomy (page 30). The trephine should be applied about 2.5 cm. (1 inch) above the midzygomatic point. The vessel curves forward below and upward in front of the middle of this opening. The removal of the button will usually reveal the artery. If it is not here, by pressing away the dura, and enlarging the opening downward, it will be found. The branch which passes posteriorly comes off just below and behind this, and the ligation of this branch may be required. In trephining over the artery care must be taken as the vessel often lies deeply imbedded in the bone. If, as the trephine approaches the dura, there is a sudden gush of arterial blood, the division of the bone should be quickly completed, the button lifted out, and the wounded vessel seized in the dura with mouse-tooth forceps. Then the dura may be pressed back from the bone, and the opening enlarged with the rongeur sufficiently to permit carrying a ligature around the vessel by means of a small curved needle.

Subdural Hemorrhage.—Hemorrhage occurring within the cranium as a result of traumatism is usually subdural, between the dura and pia-arachnoid. Such hemorrhage comes from the bone when the dura also is torn, as is apt to be the case in fractures of the base where the dura is closely adherent. The bleeding may also come from arachnoid or cortical vessels with or without fracture. Unlike the extradural hemorrhage, the blood passes freely through the subdural space. Often the delicate arachnoid at the base gives way or is torn and permits the blood to mingle with the cerebrospinal fluid about the cord. The bleeding is usually from small veins and tends to be self-limiting. The proportion of cases in which the hemorrhage is slight and unrecognized, and in which recovery takes place without operation is greater than we have any statistics to show. It is the graver cases which require operation.

After traumatism and symptoms of concussion, if recovery is not as prompt as from concussion alone, and if symptoms of pressure supervene, subdural hemorrhage, in the absence of something else more positive, may be assumed to exist. Commonly the hemorrhage is basilar. If there are no localizing symptoms to guide the surgeon, operation should be aimed to drain the subdural space near the base. Operation is done when the positive evidences of pressure are present. If no focal symptoms are present, perhaps, one or the other sides may show lateral symptoms. Venous stasis in the eye-ground will often point to the side which is suffering compression. If there is no guide but the general symptoms of compression from subdural hemorrhage, the place of choice for craniotomy is low in the right temporal fossa (see Temporal Craniotomy, page 30). The trephine opening should be made as low as the retraction of the fibers of the temporal muscle will permit, 1.3 to 2.5 cm. (½ to 1 inch) above the zygoma, in a vertical line above the condyle of the inferior maxilla. The opening may be enlarged as required. Upon incision the dura and discovering hemorrhage, clots should be irrigated away. If the source of the bleeding seems to have been the near vicinity, and the hemorrhage is represented by a coagulum which is removed, the wounds may be closed without drainage. If, as is usually the case, the blood has diffused itself in the subdural space, drainage by means of wick or gauze rolled in an impervious sheath (cigarette drain) should be inserted. The rest of the wound is closed. On account of the usual necessity for drainage, the low, intramuscular, temporal operation has the advantage of giving good drainage and offering the least danger of hernia cerebri.

The temporal craniotomy affords very satisfactory drainage if the hemorrhage comes from the middle fossa of the base. The temporal lobes can be lifted up and the base drained. A bilateral operation is called for if the drainage secured from one side is inadequate, or if the evidences of subdural hemorrhage are strong and the hemorrhage is not discovered by the first operation. Suboccipital craniotomy gives the best drainage in fractures of the posterior fossa of the skull and in subtentorial hemorrhages (see Suboccipital Craniotomy, page 36). When the pressure symptoms are localized the operation should be applied to expose the hemorrhage wherever it is.

Checking of subdural hemorrhage is not a matter of moment. The seat of bleeding can rarely be discovered. It is almost invariably venous and from small vessels with but little pressure. It may be left to take care of itself. The main thing is to relieve the intracranial compression. If drainage is provided to carry off the blood as fast as it accumulates, the bleeding need not give concern. It will stop.

The cases which always require operation are those with distinct focal symptoms. Here, if the clot is accessible, it should be removed; if it is at the base, drainage as near to it as possible should be provided. Operation should also be done though the symptoms are not localized, if the compression is steadily progressing toward the danger point, the stupor becoming deeper, and the pulse slower. My own practice has tended to watch these cases as the pulse rate went down from 80 or 90 per minute, incidental to the concussion, to 65, 60, and 55, indicative of pressure. I have usually operated before the pulse reached 50.

In mild nonlocalizing cases, or in cases before operation, the patient should be kept quiet in bed with the head slightly elevated. If the general condition remains fairly good, if the stupor does not deepen but seems to abate, if the pulse rate does not grow progressively slower, operation may be deferred. If, after three days, improvement does not show itself, but the symptoms of pressure continue unabated, operation is advisable. Operation will be of most service, if it is to be done at all, when it is done not too late. After paralytic symptoms have developed, and clot has become organized and provoked adhesions, permanent damage has been done which operation can not relieve.

Pachymeningitis Hemorrhagica.—This condition is associated with the deposit of a membrane in the subdural space, presumably made of blood clot. The indications for operation are variable. There may be progressive dementia, convulsive attacks, headache, and signs of intracranial pressure. The diseased area should be uncovered by craniotomy, and the deposit removed.

Subarachnoid Hemorrhage.—Subarachnoid bleeding is usually the result of contusion of the brain. It is commonly associated with laceration of the brain, or with fracture and subdural hemorrhage. When near the medulla it is usually fatal. Over the hemispheres, where it exists alone, it may reveal itself by pressure symptoms. These are apt to be preceded by symptoms of irritation. Such hemorrhage should be uncovered by trephining. The overlying meshwork of arachnoid should be incised, and the clot, if thick, washed out by means of a gentle stream of warm saline solution. If the clot is not thick, the decompression alone should suffice.

Hemorrhage into the Brain Substance.—Bleeding into the substance of the brain may be the result of traumatism or disease. It may occur in the cortex of the cerebrum, deep in the brain substance, in the basilar ganglia, or in the cerebellum. The points of hemorrhage may be single or multiple. From the standpoint of treatment, it is chiefly the single hemorrhages with which the surgeon is concerned—those which require attention because of compres-

sion. Here, as in the other intracranial hemorrhages, operation is called for chiefly to relieve pressure. If death does not result from pressure, in most cases the clot will either be absorbed or degenerate into a cyst. Small hemorrhages are serious only when they involve important regions; otherwise they are absorbed and leave little trace of their existence.

Hemorrhages connected with a wound, such as made by a bullet, a stab wound, or associated with depressed fracture, if sufficient to give even slight symptoms of compression, should be evacuated. Usually this is best done by following the track of the wound. If further damage to important areas would be entailed, some other course of approach through a silent area may be selected. Hemorrhage in a vascular tumor, such as gliosarcoma, should receive treatment by decompression, and if possible by drainage or removal of the tumor.

The same rules which are applied to the treatment of subdural hemorrhages apply to brain hemorrhages. If the location of the clot is known and it is approachable, it should be exposed and drained, provided that it is producing serious pressure. If such a clot cannot be reached, the condition should be treated as a brain tumor, and a decompression operation done.

Spontaneous cerebral apoplexy, the hemorrhage due to disease of the blood-vessels occurring especially in the aged and giving rise to the so-called "stroke of apoplexy," usually comes from a rupture of one of the small branches of the middle cerebral artery. The indications for surgical treatment are those of pressure. In most cases some localizing symptoms are present which show the side of the brain involved. The differences of the eyes, the differences in muscular tone between the limbs of the two sides, and the lines of the face showing muscular flaccidity on one side or the other usually suffice for lateral localization. Medical treatment offers much for the prophylaxis of this disease but little for its treatment. Surgery can do much for this condition which in every respect is a surgical lesion.

The blood coagulates quickly, and the hemorrhage usually is ended in a short time. The progressive symptoms which continue are most probably the gradual changes, such as the development of a zone of edema, due to the pressure. It is doubtful if the routine measures to lower blood-pressure in these cases are of value; it is certain that they often do harm. The use of drugs which act as vasodilators, bleeding, the constriction of limbs to confine the blood in the extremities, none of these things have proved to be of definite service. The high blood-pressure is a result of the apoplexy; it is essential to overcome the compression anemia of the basilar centers; a fatal anemia of these centers occurs unless the systemic blood-pressure is maintained sufficiently high to overcome the increased intracerebral pressure which is caused by the presence of the clot. The rational treatment of this condition must be worked out not by combating the natural life-saving mechanism for regulating the systemic blood-pressure, but by relieving the increased intracranial pressure due to the presence of a foreign body.

Given a case of spontaneous apoplexy with stupor or coma, flaccidity of the muscles of one side of the body, a high blood-pressure in response to an abnormal intracranial pressure, and the other characteristic signs of a hemorrhage in the internal capsule on the side of the brain opposite to that of the paralyzed muscles, the surgeon may expose the brain and relieve the pressure by draining the clot focus. Usually no anesthetic is required. The head should be shaved. A temporal craniotomy should be done between the retracted fibers of the temporal muscle (page 36). This is done through a vertical incision above and anterior to the external ear. The temporal fascia is exposed and incised in the same direction. The fibers of the temporal muscle

are separated, but not cut, and the squamous portion of the temporal bone and the adjacent parietal bone are exposed. The skull should be opened by trephine or burr just below or above the squamous suture, and the opening enlarged to about 3 or 4 cm. (1¼ inches) in diameter. The dura is opened by a crucial incision. This is all done rapidly and should consume but a few minutes. An opening should be made sufficiently large to expose the region of the lower end of the fissure of Rolando, the lower ends of the two central convolutions, and the fissure of Sylvius. The brain will often show edema or other local evidence of injection and hemorrhage. If not, it should be entered at the prominent rounded eminence of the lower end of the posterior central convolution just behind the lower end of the Rolandic fissure and above the Sylvian fissure. This point is horizontally above the external auditory meatus, about 5.5 cm. (varying from 4 to 7 cm.) above the zygoma. The opening in the dura should be as small as possible. A trocar and canula of small size should be entered in a downward and inward direction. It should pass sufficiently above the fissure of Sylvius to avoid the island of Reil (Fig. 737). By inserting the instrument in the middle of a convolution,

FIG. 737.—SPONTANEOUS CEREBRAL APOPLEXY.

Showing transverse vertical section of brain. Trocar and cannula passed inward and downward to tap clot. This is the point of election for tapping the usual capsular clot through the postcentral gyrus. The instrument is entered high enough to pass above the island of Reil.

no vessels are injured. The apoplectic clot should be encountered within 5 cm. (2 inches) of the surface. A soft roll of rubber tissue, to serve as a drainage tube should be inserted through the canula. The dura, fascia, and muscle should be sutured snugly about the tube with chromicized catgut. Every precaution should be taken to prevent hernia cerebri. The clot may be expected to extrude itself through the tube.

If the lower end of the postcentral convolution cannot be located, the puncture may be made somewhere posterior to a line erected horizontally above the external auditory meatus, from the zygomatic line, and above the Sylvian fissure. That means from 4 to 7 cm. above the zygoma, depending upon the size of the brain. The puncture should be made at the convexity of a convolution.

Some surgeons draw apart the borders of the operculum at the junction of the Sylvian fissure and a continuation of a line from the Rolandic fissure. The island of Reil is in the depths of this fissure. A trocar is inserted into

the island, penetrating the white matter of the island, the claustrum and the globus pallidus. Blood is encountered at a depth of from 1 to 3 cm. (⅓ to 1¼ inches).

Because of the intracranial pressure, there may be troublesome bulging of the brain after the dura is opened. This may be overcome by elevating the head of the table. Lumbar puncture may be required. As soon as the dura is opened, the decompression should show itself in improvement in the patient's general condition. The results of these operations have not been collected sufficiently to place the operation upon a definite surgical basis. Most of them have been done too late when, as a result of laryngeal paralysis, inhalation pneumonia has been engrafted. Others have been attempted when the compression had exhausted the vasoregulator centers. But it can be safely predicted that as a result of the experimental work which is now being done the operation will become an accepted surgical procedure.

In exceptional cases, in which there was abnormally high blood-pressure before the apoplexy, in a plethoric individual, if the patient is seen immediately while the hemorrhage is going on, there is, perhaps, some value in phlebotomy, or in throwing a bandage about the bases of the arms and legs to shut off the venous return and confine as much blood in the limbs as possible for a short period. An injection of nitroglycerin during the bleeding may be of service. Elevation of the head is surely called for. But these expedients must be applied quickly as the hemorrhage is soon over. Whatever is done to reduce the blood-pressure, it is absolutely essential that the blood-pressure shall rise again sufficiently to overcome the extravascular pressure in the skull.

The pre-apoplectic stage belongs to the province of medical therapy. Treatment of that stage is vastly more important than the treatment of apoplexy, for it deals with a yet undamaged brain.

Intracranial Hemorrhage in the Newborn.—This condition follows injuries sustained *in utero* or at birth. Usually they are the result of prolonged or instrumental labor. They commonly occur in the first born of women who are advanced in years. Traumatism and congestion are, perhaps, both causative factors. The hemorrhage may be unilateral or bilateral, and is usually subdural. It is important that the clot shall be removed by operation. Unless it is removed, if the child survive, the clot produces pressure which destroys cortical cells, and adhesions remain as a permanent cause of irritation. Spastic paralysis, "birth palsy," hemianopsia, epilepsy and mental defectiveness are some of the permanent results of failure to give these cases the benefit of operative treatment.

The indications for operation are that the child at first suffers with respiratory difficulty or irregularity often amounting to asphyxia; it displays the symptoms of intracranial pressure; there may be slowing of the pulse, prominence of the fontanels, dilatation of the veins of the skull and eye; the child does not suckle well, and has to be fed with a spoon or dropper; there may be twitching or convulsive movements, which may be unilateral. There are no localizing muscular paralyses because the motor impulses have not yet become cortical.

The operation should be conducted on the same principles as with an adult. These cases are by no means hopeless. The elasticity of the infant's skull permits it to accommodate a large clot. The operation need not cause any more traumatism than it suffers in labor. Localization may be impossible, but it may often be decided by some lateral differences in venous congestion. It is important in operation that the body heat shall be conserved by hot-water bottles, and that blood shall be saved as much as possible. The

operation should be done as soon as the diagnosis is made. If the clot is not found on one side it may be looked for on the other.

The child's head should be shaved, and its limbs and trunk enveloped in warm blankets containing hot-water bags. Unless there is stupor, light general anesthesia is used. Hemostasis is secured by a light elastic band about the head (see Scalp, Hemostasis, page 19). An incision, the shape of a horseshoe is made, base downward, just within the limits of the parietal bone. The bone is freed for a short distance at its upper border by cutting the interosseous membrane. With a director or an elevator under the bone, it is divided in a line corresponding to the scalp incision. The bone may be cut with scissors, a knife or cutting forceps. The scalp-bone flap should be turned down. Clot will show through the dura by its dark color. The dura should be divided some distance from the bone margin, the flap turned down, and the clot washed away with warm saline solution. In older cases an adherent fibrinous mass may be found, which should be peeled off and removed. The dura should be nicely approximated with fine chromicized catgut, and the skull and scalp sutured back in place. (See Injuries of the Newborn, Vol. III).

Wounds of Intracranial Structures

Wounds of the meninges usually require treatment in connection with depressed fractures and operative procedures. All hemorrhage should be checked before the wounds are closed. This is important because even slight bleeding is prone to continue until a considerable clot has formed. Wounds of the pia-arachnoid, if large enough to gap and expose brain substance, should be sutured with extremely fine catgut.

Still more important is the suturing of wounds of the dura mater. Such wounds in the presence of skull defects, if not closed effectively, are prone to be followed by extrusion of the brain or hernia cerebri. If they are not smoothly closed so as to present an even endothelial surface to the pia-arachnoid, adhesions which obliterate the subdural space are apt to form. Such adhesions are a prolific source of irritation to the cells of the underlying cortex and prone to be causative factors in the development of epileptic attacks. It sometimes happens that the dura is torn and ragged. Under such circumstances it should not be trimmed off in the wasteful manner that other tissues are treated. All that is viable must be preserved. The dura is but slightly elastic. Sometimes the bulging brain prevents good apposition, and it is advisable to perform a lumbar puncture to relieve the pressure.

By applying a slight plastic operation *dural defects* may often be closed. Adjacent fascia or periosteum may be turned in. Hydrocele or hernial sac or transplanted fascia with its fatty layer may be employed. To strengthen a dural defect under a bony defect, an osteoplastic operation should be done, applying solid bone over the weak place. This can often be accomplished by turning down a patch constituted of the outer table of the skull and periosteum, applied with the periosteum toward the brain. Or bone may be transplanted from the tibia, scapula or rib.

In emergency work when haste was necessary, I have with much satisfaction closed defects in the dura by weaving the opening across in two directions with chromicized catgut over a piece of fascia.

Wounds of the brain require treatment applied chiefly to the skull and meninges. Hemorrhage has been discussed. Such wounds fall together by their own consistency. The brain cannot be sutured. Brain substance which is lacerated and torn loose should be removed. Brain tissue which is torn and extruded through a skull wound should be removed. It often

becomes necessary to remove brain tissue in order to close a rent in the dura. No hesitation need be had to make such sacrifice; the motor area is the only part of the cortex which need receive conservative consideration.

Stab wounds of the brain are important on account of the danger of (1) hemorrhage; (2) infection; (3) foreign matter carried into the cranium; and (4) subsequent irritating adhesions. A certain amount of hemorrhage will invariably be present. If it gives any symptoms whatever, it should be exposed and dealt with; this for the reason not only of the hemorrhage, but also because of the three other dangers associated with the wound. These wounds may heal without infection, provided the scalp wound is properly cared for; but upon the first appearance of symptoms of infection, the wound should be opened. If the symptoms point to intracranial infection, a button of bone should be taken out. This should include the bone wound. The opening should be enlarged if necessary to uncover and drain meningeal infection. The development of abscess should receive the treatment elsewhere described (page 73). If the wound has been inflicted with a blunt-pointed instrument which has obviously carried in foreign matter, it should be trephined and as much of the offensive substance as is accessible removed.

Any one or all of these complications are prone to give rise to adhesions. A clot with a mild localized infection creates the conditions most prone to produce subsequent trouble. If to this are added spicules of bone and bits of hair, a mass of scar tissue may result, capable of predetermining an epileptic destiny. For all of these reasons it is clear that but a very slight excuse should call for the excision of enough bone to remove clot, check hemorrhage, eliminate foreign matter, and provide drainage, thereby minimizing the dangers of pressure, infection, and subsequent cortical irritation.

Whatever is done, at least the scalp for several centimeters around the wound should be shaved and cleansed, a drain should be carried down to the bone, and through it, if possible, a copious wet antiseptic dressing applied, and the patient kept quietly in bed.

Bullet wounds of the brain should be treated according to the rules already given for the treatment of bullet wounds (Vol. I, page 222) and of wounds of the brain in general. Practically the same rules apply as are given for stab wounds. The peculiar feature of many of these injuries is that the bullet lodges within the cranium. The treatment here becomes one of a tentative nature. By no means should an attempt be made to locate the bullet by means of a probe. If it is suspected that the ball lies just beneath the skull, there is far less hazard in doing a systematic trephining than in the most careful introduction of a probe. Quite invariably a probe fails to locate a bullet, and only serves to carry in more infection. But a trephine opening may be of some use. One of the pernicious activities of obsolete surgery was the probing of the brain for bullets.

In most injuries of this sort, the scalp should be shaved about the wound, cleansed, and dressed with a copious wet antiseptic dressing after the introduction of a small drainage tube just to the bone opening. If there is a wound of exit, it also should receive the same treatment. If the bullet is lodged within the cranium, in most cases it may be left undisturbed. It usually sinks to the base of the skull laterally, becomes surrounded by a fibrous envelope, and does no appreciable harm. Next to leaving the bullet alone, the most important thing is to determine its location by means of *x*-ray pictures taken at right angles to one another.

If the ball happens to lie near the surface of the brain where it can be reached without harm, particularly if it occupies some position from which focal disturbances would arise, it should be removed either through a tre-

phine opening or by turning down an osteoplastic flap. If the bullet is hidden in brain tissue, the operation should not be attempted until the most accurate measurements and guides have been made whereby the surgeon shall be able to find it with the least amount of traumatism. The cortex should be entered through the middle of a convolution because of the greater abundance of vessels at the sulci. A fine needle should locate the bullet. A telephone attachment will add to its delicacy. It should be extracted with the least possible traumatism. The motor area of the cortex should be avoided, if possible, in such operations.

Hemorrhage, infection, and abscess are discussed elsewhere. An abscess developing in connection with the bullet gives an opportunity in the treatment of the former to remove the latter.

Foreign bodies in the brain require the same general treatment as bullets. Jagged and irregular bodies do more damage, carry in more surface dirt, and are more prone to be associated with infection; consequently such wounds must be especially asepticised down to the meninges, and the early localization of the body and its removal are more urgently demanded. Removal of pieces of bone and other foreign matter and drainage down to the meninges are imperative.

Injuries of intracranial nerves give rise to scar formations which require treatment for the relief of neuralgia, paralyses, and other disabilities. Fractures of the base of the skull are the chief causes of injury to these nerves.

The sixth nerve (the abducens) is sometimes injured by fractures of the base as it lies in its groove on the basilar surface of the sphenoid bone. Its paralysis causes internal strabismus in the eye of the affected side. There is no treatment directly applicable to the nerve. Time and correcting exercises of the eye often suffice to effect a cure (see Strabismus, page 135).

The fifth nerve (the trigeminus) is often injured by fractures and diseases at the base of the skull. Such injury may involve the Gasserian ganglion or its roots, but most commonly the superior maxillary nerve at the foramen rotundum, the vidian in the Vidian canal, or the inferior maxillary at the foramen ovale. Such injury may compress the nerve or involve it in scar tissue, for the relief of which some of the methods of treatment elsewhere described are called for (see Neuralgia of Trifacial Nerve, Vol. I, page 865; Operations on the Gasserian Ganglion, Vol. II, page 106).

The seventh nerve (facial and auditory) is often injured by fractures of the petrous portion of the temporal bone, by clot, tumor or inflammatory disease in that region. Such injury occurs to the facial nerve at the internal auditory meatus, in the canal of Fallopius, or at the stylomastoid foramen. The *portio intermedia* of Wrisberg, connecting facial and auditory, may also be involved. The auditory nerve may be injured with the facial or it may be the seat of separate disease. The determination of the location of injury of these nerves, and its extent, is one of the delights of exact anatomic knowledge. Whether the indications for treatment are muscular paralysis, neuralgia, convulsive tic, or tinnitus aurium, much can often be done to bring relief (see Paralysis of the Facial Nerve, Vol. I, page 881; Neuralgia of the Facial Nerve, Vol. I, page 877; Spasm of the Facial Nerve, Vol. I, page 888; Injuries of the Auditory Nerve, Vol. I, page 890; Intracranial Operations on the Seventh Nerve, Vol. II, page 110).

Injuries of the brain have been discussed under the heads of "Concussion," "Contusion," "Compression," "Intracranial Hemorrhage," "Wounds," and "Fractures of the Skull." There is no distinction between the treatment of injuries of the cerebrum and cerebellum excepting that in the former the integrity of the motor area is to be conserved by all means.

Injuries of the *pons* and *medulla* are usually immediately fatal. Slight injuries by wounds, foreign bodies, or blood clots, which are not at once fatal, demand that the head shall be kept quiet and the blood-pressure equable.

Injuries of the meningeal sinuses occur in fractures of the skull, in connection with wounds of the brain and meninges, and in operations upon the head. The blood-pressure in these venous sinuses is very low. Hemorrhage from small wounds is easily controlled by pressure. If a bit of gauze is placed at the sinus wound the pressure sufficient to stop the bleeding need not be great enough to do any injury to the adjacent brain. In some cases, if there is a sufficiently free exposure, the wound in the sinus may be sutured. In operating in the presence of a wounded sinus, the surgeon, having in mind the ease with which the bleeding can be stopped by pressure when he is ready to apply it, may proceed with the operation. These sinuses, being held open by their non-collapsible surroundings, do not tend to spontaneous hemostasis as other vessels do; and the first business of the surgeon is to check the bleeding. A minute pad of gauze may be held against the rent by a retractor. It should not be forgotten and left in the wound. If the sinus has not been closed by suture or by the pressure of other structures, a narrow strip of gauze may be packed against it and the end brought out through a convenient place in the scalp. At the end of forty-eight hours this may be removed, and hemostasis expected.

The parasinoidal sinuses especially may be injured in the operation of craniotomy. When a large rent is made in the roof of a sinus, gauze may be packed directly into it. A clot forms and obliterates its lumen. The only sinus thrombosis which need be feared is that which is associated with infection.

Hernia Cerebri.—Hernia cerebri is a protrusion of the brain through an opening in the dura and cranium, and is due to increased intracranial pressure. In operating upon the brain or skull and in treating injuries of these parts, it should be borne in mind that any increase of intracranial pressure will tend to produce protrusion. Congestion within the cranium, whether from traumatism, infection, low position of the head, respiratory obstruction due to narcosis, or any other cause, in the absence of dura and skull covering, will always cause cerebral hernia. When these coverings are removed and a brain is exposed in the presence of congestion, tumor, clot or excess of cerebrospinal fluid, protrusion may be expected to take place.

Two things are important to keep in mind in the treatment of these conditions: (1) If the brain is uncovered in the presence of normal intracranial tension, the normal atmospheric pressure will balance it and prevent hernia; (2) when the brain protrudes, it is conclusive that there is abnormal intracranial tension, the treatment of which should not be aimed toward suppression of the protrusion but toward reduction of the pressure. To attempt the reduction of extruded brain in the presence of pressure increases the pressure, and is bad surgery. In acute conditions, the protrusion may be due to some of the causes, above enumerated, which produce congestion. Thus, in operating for compound depressed fracture, it will often be found that the traumatism produces local congestion and edema sufficient to cause cerebral hernia if the dura has been opened. In order to overcome this temporary condition so that the dura may be sewed, the patient's respiration should be made easy and equable, numerous punctures may be made in the arachnoid to permit the escape of some fluid, the head may be elevated, and if these expedients do not suffice some fluid may be drawn off by lumbar puncture.

It is seen that the treatment of hernia cerebri is a treatment of the causa-

tive force from behind rather than of the hernia itself, that it is a salutary condition, and that so long as the brain is protected by a good covering of scalp the disease is not a serious one. If the causative factor cannot be removed it is better surgery to leave a well-covered hernia than to expose it and attempt replacement or excision of the herniated tissue. If the causative factor disappears, the herniated portion may be expected to recede within the skull. An exception will be found in the cases in which the hernia has existed for a considerable time; here when the pressure becomes normal the extrusion is apt to persist.

Fungus cerebri is a hernia in which there is an absence of all brain covering—meninges, skull and scalp are deficient. This is due to unhealed wounds of all the coverings, or to ulceration of the coverings of a hernia cerebri. Infection of the exposed brain is usually present. The increase of pressure which provokes the extrusion is often kept up by the infection and traumatic congestion. This localized pressure continues so long as the causes are present. If portions of the brain are excised or slough away, further infection and congestion keep up the extrusion. Unless the condition is controlled, fatal meningitis is sure to develop.

An attempt should be made to secure a scalp covering in order to stop the infection. This is accomplished by shaving and cleansing the scalp, drying it with alcohol, and applying tincture of iodin or phenol followed by tincture of iodin or other antiseptic.

At the operation the vessels of the scalp should be controlled by a tourniquet. The scalp for a wide distance about the field of operation should be painted with tincture of iodin or other skin disinfectant. Crevices which cannot be reached by the iodin should be sterilized by the sharp point of the actual cautery. The extruded brain tissue should then be cut away, the scalp dissected free, and the area covered by a plastic operation of the scalp (see Plastic Operations, Vol. III). If sterilization has been secured, the operation should succeed.

Diseases of Meninges and Ependyma

Extradural Infections.—Pachymeningitis externa usually springs from disease of the bone and requires the treatment necessary for the bone disease. Collections of pus between the dura and skull should promptly be evacuated lest they produce subdural infection. Often these lesions are syphilitic and require both operation and medication. When the infection is secondary to middle-ear disease prompt operation may prevent the infection passing through the dura. The sensitiveness of the dura gives much pain when pus presses it away from the bone, and this symptom is often the call for operation. Even when pus is not present, an infection which has reached the dura should have free drainage outward. Pachymeningitis has no especial surgical significance except as a part of an extradural or subdural infection.

Syphilitic pachymeningitis may be from extension from the bone or a distinct gummatous deposit. The constitutional treatment should be applied and the thickening excised if necessary.

Extradural infection of otic origin often gives rise to a collection of pus between the bone and dura. The causative ear disease should be operated upon (see Suppurative Otitis Media, page 306; Mastoid Operations, page 310). The suppurative process should be followed to the place where it penetrated the skull. Here the inner table should be cut away widely enough to expose freely the extradural focus. Drainage should be provided.

Leptomeningitis (Subdural Meningitis).—There are many varieties of

subdural meningeal infection, all involving the pia-arachnoid. The surgeon is most concerned with the treatment of those which tend to be localized or which have a known focus of origin. Such a meningitis following, for example, an infected compound fracture of the skull presents some difficult problems. As soon as the signs of meningeal infection are elicited, local drainage should be secured by reopening the wound. When the dura is reached, if it had been previously opened, no hesitation should be had to reopen it, care first being taken to sterilize its outer surface with phenol or iodin and to use newly sterilized instruments in opening it. A seropurulent discharge found in the subdural space discloses the meningitis. If upon approaching the dura from the outside the dura is found not to have been wounded, its opening is still called for if the evidences of meningitis are positive. Still further assurance is afforded by the appearance of thickening and inflammation of the dura. If there is bulging of the dura the evidence of meningitis is still stronger. The same aseptic precautions against infecting uninfected meninges should be taken, and the dura opened. Drainage should be secured by rubber tubing or wick.

Whether to proceed further with the operation is a difficult question. It often appears that the meningeal involvement extends downward to some more dependent region which should be opened if the best possible drainage is to be secured. Thus a secondary opening may be required in the temporal or occipital regions. Death in these cases is due to pressure and sepsis. The pressure is usually the most serious factor; and it is best overcome by drainage.

The infecting agents in meningitis are so variable that the treatment must be modified much according to the nature of the infection. The pyogenic organisms, such as the various *Staphylococci*, and *Streptocooci*, and the *Bacillus pyogenes fetidus* call for drainage at once. Organisms such as the *Pneumococcus*, *Bacillus typhosus*, *Bacillus Pfeifferi*, *Bacillus anthracis*, and *Bacillus tuberculosis* must be met by other general indications. But in any infection, drainage is called for if the symptoms of compression progress toward the danger point. The natural tendency of meningitis is to gravitate toward the base, and here drainage will be found most effective. The anterior and middle fossæ of the skull may be drained by lateral operations. The posterior fossa requires suboccipital craniotomy. Here, after making a good-sized trephine opening, the cerebellum should be lifted up and a wick drain passed forward and inward toward the basilar cistern. Operation on both sides is often called for. These operations are indicated in the meningitis caused by infection through fractures of the base of the skull.

The posterior temporal and parietal regions and the occipital region above the *tentorium cerebelli* may be drained low down by a trephine opening just above the superior curved line, sufficiently high to escape the lateral sinus—2 cm. (¾ inch) above the posterior inferior angle of the parietal bone; or midway between the parieto-occipital suture and the superior curved line on the occipital bone, midway between its lateral and superior angles.

Meningitis of otic origin usually follows suppurative otitis media. It may be serous or purulent. Infection reaches the meninges by way of the roof of the middle ear, the roof of the mastoid, through the posterior wall of the petrous portion, through the internal auditory meatus, or by way of the aquæductus vestibuli. The tendency of this infection is toward the base of the brain. Prophylactic treatment is of first consequence. The presence of an infective process in the middle ear always threatens intracranial infection, and it should be healed as soon as possible (see Otitis Media, page 306). Even when meningitis has developed, the suppurative focus in the ear should

be freely exposed. Similar puncture done for diagnostic purposes, by relieving pressure is often of therapeutic value.

The important treatment of these cases is the operative exposure of the infected meninges. Usually this is best done by continuing the ear operation through the skull, if possible, following the track of the infection (see Suppurative Otitis Media, page 306; Mastoid Operations, page 310). Upon following the infection to the dura, the dura should be opened and drainage established by means of wick or soft-rubber tubing. This operation may lead to opening the skull in the angle between the lateral and superior petrosal sinuses on the posterior surface of the petrous portion, or in front of the superior petrosal sinus on the anterior surface of the petrous portion, or at the petrososquamous junction. In the first event the posterior fossa of the base is entered, in the second event the middle fossa is entered. It is, therefore, important to follow the route by which the infection passed from the ear to the meninges in order that the infected fossa shall be drained. If the lateral operation does not give adequate drainage, a suboccipital craniotomy may be required.

Epidemic cerebrospinal meningitis, due to the *Diplococcus intracellularis meningitidis*, must be differentiated from meningococcic, streptococcic, pneumococcic, influenzal, and tuberculous meningitis, before treatment can properly be inaugurated. Persons who have been in contact with the disease should be suspected as "carriers," and their nasal secretions examined. Children who have been exposed to known cases should be immunized with a vaccine of the specific organism. Antimeningococcic serum is also of value.

The treatment of the disease was placed on an effective scientific basis by Abraham Flexner. Fluid is drawn from the spinal canal; if it is cloudy, the serum of Flexner is injected at once. The injection is best not made with a syringe, but by the gravity method. The dose for an adult is 20 to 40 c.c., and for babies and children 3 to 20 c.c. The dose should be 5 or 10 c.c. less than the amount of cerebrospinal fluid withdrawn. In severe cases the antimeningococcic serum should be injected every twelve hours, preceded always by the withdrawal of a greater amount of spinal fluid. In milder cases the injection may be made once daily for four days. If the cases show a tendency to become chronic, an autogenous vaccine should be made and given in doses of 250,000,000 to 1,000,000,000 bacteria every five days.

There are certain purely surgical aspects to this disease. In the absence of the Flexner serum and in advanced cases with pressure due to the accumulation of inflammatory products, surgical drainage is called for. Lumbar puncture will usually remove enough fluid to give temporary improvement, but ultimately the accumulation of fluid in the lateral ventricles is apt to demand attention. Obstruction to the escape of fluid from the ventricles is often caused by intracranial pressure alone. When the excess of fluid in the arachnoid and subdural spaces is evacuated, the ventricles drained, and the spinal fluid tapped, an equalization of pressure may be secured. This equalization of pressure cannot be attained in advanced cases unless all three of these reservoirs are tapped; because, while normally they all communicate, under the conditions entailed by pressure, meningeal adhesions, and exudate, their intercommunications are shut off. Therefore, it is often necessary to combine these operations. The disease is self limiting; and death is due to pressure, causing anemia of the vital basilar centers.

Whether the skull operation shall be a suboccipital craniotomy or a lateral craniotomy must be determined by the conditions present. Tapping the ventricles in the posterior temporal region gives an opportunity to secure

some subdural drainage; but, as Ballance has shown, the best subdural drainage is to be secured by bilateral suboccipital craniotomy and the careful lifting of the brain and placing wick drains forward and inward to the basilar cisterns.

As a general plan of procedure for the relief of pressure in these cases it is best to do first a lumbar puncture. If pronounced relief is secured, the operation may be repeated so long as it is effective. The next step should be tapping the ventricles (see Operations for Drainage of the Ventricles, page 95). The ventricular tapping may be repeated as is required. The combination of lumbar and ventricular drainage may be sufficient to secure relief of pressure while the infection is subsiding. As a last resort, suboccipital drainage combined with decompression is called for.

These are desperate cases. Anesthesia is rarely required because the patients are usually in a comatose state. These lines of treatment described for epidemic cerebrospinal meningitis are equally applicable to all forms of meningitis in which the relief of pressure is called for (see Operative Treatment of Meningitis, below).

Noninfective Meningeal Effusion.—This condition is comparable to the nonmicrobic effusions found in other serous membranes. The causes to be combatted are various; in some cases an unrecognized or healed infection may be the cause. The presence of irritating toxic materials, which are often the products of infections in other parts, may be a cause. Surgical treatment is called for to combat compression. When the compression is overcome, and hygienic treatment has eliminated the causative factor, the patient is cured.

Lumbar puncture has been shown by Quincke to be the most valuable operation. If there is free communication between the ventricles and the spinal canal the operation may be expected to be curative. Unfortunately, in some of the cases the exit from the ventricles is closed, and a condition of hydrocephalus exists. After repeated lumbar puncture communication may be established; but if the pressure symptoms persist unabated or assume a serious character, drainage of the ventricles should be done (see Operations for Drainage of the Ventricles, page 95). In some cases the obstruction is due to the intracranial pressure and its release by any expedient may be curative. A temporal operation for decompression may be done if necessary.

Tuberculous Meningitis.—The surgical treatment called for in this disease is relief of the pressure. This should be done by lumbar puncture as in the other meningitides. The operation relieves pressure and eliminates toxins. Tapping of the ventricles is also indicated in cases in which pressure symptoms are referable to the distention of ventricles. The general treatment of the disease belongs to the province of medicine and hygiene (see Tuberculosis, Vol. I, page 276).

Lumbar puncture prevents convulsions. From 20 to 30 c.c. of fluid may be drawn off every second day. Tubercle bacillus will be found in the fluid in a minor proportion of the cases. The fluid is rarely turbid.

Syphilitic Meningitis.—The vigorous treatment of syphilis in its early stage should be looked to for the prevention of meningeal lues. Upon the appearance of meningeal syphilis, which is usually within three or four years of the original infection, antisyphilitic treatment should be pressed (see Syphilis, Vol. I, page 283). A large proportion of these cases will be relieved by this means. In other cases, particularly if treatment is not promptly instituted, so much inflammatory tissue will have been deposited at the site of the lesion that, despite active treatment, the symptoms of pressure will persist. These call for operation.

How long medical treatment should be used before operating, is a question which the surgeon must answer for each case. If antisyphilitic treatment is used for diagnostic purposes, it should not be continued longer than two months without results. Some authorities advise continuing for three months or even longer. It should be borne in mind that some forms of neoplasm are temporarily improved by mercury and iodid. If the case is one of syphilis, improvement should be expected in two weeks. If there are decided symptoms of pressure, if the pressure threatens permanent damage to important nerves or organs, operation should be done if there is no abatement of symptoms in two weeks—or even earlier if the pressure symptoms are extreme. When early operations are done to relieve distressing symptoms, the medical treatment may be continued after the operation.

The operation called for is that which treats the syphilitic deposit as a tumor. If it can be localized it should be exposed and removed. Gummata are sometimes found which are hard and unabsorbable. If it cannot be localized, the dangers of compression should be relieved by a decompression operation. Temporal decompression is preferred. By operating early the blindness, which a choked disk presages, may be averted. Decompression may usually be expected to relieve the severe headaches with which these patients suffer. A pachymeningitis externa may be discovered. Operation is called for also in localized conditions, such as give rise to Jacksonian epilepsy, whether general compression symptoms are present or not.

Hydrocephalus should receive its special treatment. Distended ventricles should be relieved by tapping rather than by decompression operations upon the skull. If the latter are required they may be done later. Paralysis of nerves later may require nerve grafting.

The Operative Treatment of Meningitis.—In meningitis operation is capable of giving better results than any other treatment. It should not be employed as a routine measure; but in the majority of cases, in which there is a dangerous increase of intracranial pressure, due to an increased amount of infected cerebrospinal fluid, operation is the important indication. It should be borne in mind that the brain is unyielding and the skull is undilatable, and that when infection and inflammation increase the bulk of the fluid secreted by the pia-arachnoid, the excess of fluid can only be accommodated within the skull by compression of the blood-vessels, which causes anemia of the brain and consequent disturbance of the vasomotor and respiratory centers in the medulla. As a physiologic reaction the systemic blood-pressure rises to overcome the intracranial pressure and to force blood through the vessels of the brain. In this life-and-death struggle, the balance may be turned in the patient's favor by operative relief of the intracranial pressure.

The normal amount of cerebrospinal fluid is about 60 to 80 c.c. (2 to $2\frac{2}{3}$ ounces). The increase of cerebrospinal fluid, caused by bacterial infection, gives rise also to the phenomena of infection. As the bacteria destroy the dextrose in the cerebrospinal fluid at a rapid rate this phenomenon may be utilized in determining the necessity for operation. Dextrose exists in amounts of from 0.04 to 0.08 per cent. The absence of sugar may often be detected by the chemical tests for dextrose before bacteria can be found. This is of much importance in differentiating infective meningitis from other conditions giving similar symptoms. The absence of the copper-reducing substance can be discovered often twenty-four hours before bacteria can be found in the spinal fluid. With the other means of diagnosis, such as the clinical symptoms, the increase in cellular elements in the fluid, the excess of globulin, and the presence of potassium salts, operation may be done early enough to save life in a majority of cases which without operation would perish.

The identification of the specific microbe is not so important as to relieve pressure and provide drainage. The excess of fluid must be removed from the cranium to make room for the life-giving blood, and make it possible for nature to overcome the infection. As an exception, it may be stated that, if the first examination of the cerebrospinal fluid shows the presence of the diplococcus of meningitis or any other organism against which a serum or bacterin is promptly effective, then the serum or bacterin should be used; and if improvement does not quickly supervene, operation should be done. A delay of not more than twenty-four or thirty-six hours should be allowed for such treatment.

Irving S. Haynes (Archiv. of Pediatrics, Vol. xxx, No. 2, Feb., 1913) called attention to the fact that opening of the skull in these cases ordinarily fails because the brain is pressed into the opening and drainage defeated, and that there is one location where it may be done without this occurrence. This is the space between the two poles of the cerebellum and the medulla. The cerebellomedullary angle in the cisterna magna lies close to the occipital bone, and is easily accessible. This space is in free communication with all the rest of the subarachnoid space about the brain and cord and with the ventricles of the brain. It is a natural cavity into which the fluid flows as it comes from its source in the ventricles.

The operation, as worked out by Haynes, is as follows: With the scalp completely shaved, the patient is placed on the table, face downward. An incision is carried in the middle line from the occipital protuberance to the spinous process of the axis. This passes down to the bone. The periosteum with the attached muscles is pressed outward on either side, exposing a space 4 or 5 cm. (1½ or 2 inches) long by 2.5 cm. (1 inch) wide at the foramen magnum. A trephine, 1 cm. (⅜ inch) in diameter, is used to make an opening in the skull in the median line about 2.5 cm. (1 inch) above the margin of the foramen magnum. The dura mater is carefully freed from the bone toward the foramen magnum, and with a bone cutter, a line is cut on either side from the outer part of the trephine opening to the outer part of the foramen magnum. These two lines should remove a truncated wedge of bone about 7 mm. (¼ inch) wide above and 1.3 cm. (½ inch) wide at the foramen magnum. The dura should be protected carefully and separated from the bone as the operation proceeds. The occipital sinus, lying in the median line in the falx cerebelli, may be tied at its upper part and at the foramen magnum. If there are two occipital sinuses, instead of one, the incision may be made between them without ligating, or a longitudinal incision may be made on either side of the usual occipital sinus. The incision through the dura exposes the arachnoid which should be incised. This opening taps the cisterna magna, and the fluid will spurt forth. The posterior poles of the cerebellum are exposed, and in the notch between, the posterior surface of the medulla is seen. A gauze drain enveloped in rubber tissue is placed in the space, the deep parts closed with catgut, and the superficial wound with silkworm-gut sutures.

Treatment by *lumbar laminectomy*, so far as results go, has, perhaps, more to recommend it than occipital craniotomy. Laminectomy at the third and fourth lumbar vertebræ is an operation which has been tried by many surgeons with excellent results. The dura, having been exposed, should be incised, and a cigarette drain placed at the dural opening. It should be conducted out at the lower part of the wound, and the soft parts closed about it (see Operations for Drainage of Ventricles, page 95).

Thrombosis of the Venous Sinuses of the Dura Mater.—Thrombosis of a venous sinuses may be infective, traumatic, or spontaneous. It may be

complete or only partially occlude the lumen of the sinus. When it once begins, its tendency is to become complete. Having become complete, there arises a venous obstruction which is usually recognizable if one bring to bear a knowledge of the anatomy of the veins which drain into the sinus and which become obstructed by its occlusion.

Infective thrombosis is the most serious. It can often be anticipated and preventive measures adopted. Usually it is an infection by extension from a neighboring disease of cranial bone. Fortunately coagulation and thrombosis go ahead of the infection and form a protecting zone, otherwise pyemia would result. Prophylaxis demands that all infective processes involving the cranial bones or their sinuses should be regarded seriously. This applies particularly to the regions lying close to the dural sinuses. The most important of these are the middle ear and the mastoid cells. A running ear is a constant menace to life, and should be cured as speedily as possible. The same may be said of chronic infections of the sphenoidal and frontal sinuses. Indifference with regard to such chronic suppurations cannot be too strongly condemned. This applies also to caries and necrosis of the skull and to cellulitis and other infections of the scalp.

An infected thrombus should be exposed, and its center removed and drained. In thrombosis, connected with ear infections, this can always be done. In all cases of mastoid disease in which thrombosis is even suspected, the mastoid cells should be exposed and freely laid open (see Mastoid Operations, page 310). The bone should be removed in the direction of the infection and the dura exposed. If extradural abscess is found, it should be uncovered by widely removing the overlying bone. The indurated wall of the sinus will be exposed. The presence of clot shows itself by a thickening of the sinus wall, by a sense of resistance, and by an absence of the normal fluctuations of the sinus. The dura should be incised in the middle of the induration, and the center of the clot removed. The outlying parts of the thrombus should not be broken through but should be left to protect the bloodstream from infection. Drainage by means of gauze or wick should be provided. The passability of subdural infection or abscess should be had in mind and any sign leading to such a condition should be followed. When there is doubt as to what lies beneath the exposed meninges, a small area may be sterilized with iodin or phenol and a small incision or a puncture with an aspirating needle made.

Opening and drainage of an infected thrombus should result in a subsidence of symptoms. If marked cerebral symptoms persist unabated, meningitis or brain abscess should be suspected, and further operative treatment should be undertaken.

Thrombosis involves most commonly the posterior part of the inferior petrosal sinus, where the mastoid vein enters it, or the lateral sinus. The blood-current is forward in the direction of the internal jugular vein, which receives the blood of the sinus a few centimeters anterior to the entrance of the mastoid vein. When the thrombus has extended into the jugular vein it can no longer be reached through the temporal bone; tenderness and pain will be present along the vein; and often pressure symptoms will be observed in the glossopharyngeal, vagus, and spinal accessory nerves. There is a strong probability of infected clot being detached and swept downward into the general circulation. So great is this danger in jugular thrombosis that the operation of choice is ligation of the jugular in the lower part of the neck, opening the vein above the ligature, and washing it through from the sinus with saline solution. This is the operation recommended by Zanfel. It has given a percentage of recoveries far exceeding any other method of treatment.

Opening of the jugular alone does not suffice; the sinus should be opened in all cases. As much of the clot as possible, lying centrad to the mastoid opening, should be removed with forceps. The vein should then be irrigated through-and-through. It should be remembered that from the lateral sinus or from the base of the petrous portion, the inferior petrosal sinus, through which irrigation is done, passes inward, downward, and forward to the jugular opening. Usually a clot will be found to have occluded the inferior petrosal sinus anterior to the jugular opening, so that after the blood is washed out of the vein between the thrombus and the ligature there is no more bleeding. Both wounds should be drained.

Ear disease leading to the superior petrosal sinus should be followed up and the sinus drained.

Thrombosis of the cavernous sinus is a still more serious condition because of its greater inaccessibility and its intimate relation to important structures. The signs of the disease calling for operative relief are characteristic. The sight in the eye of the affected side, it may be assumed, is destroyed, so great is the pressure-congestion in the obstructed veins. The adjacent sinuses are prone to become involved. These are desperate cases. Death from pyemia or meningitis is the usual result; any neighboring focus of infection should be open freely and followed, if possible, to the infected dura. This should be opened and drained as in thrombosis of the lateral or petrosal sinuses. If the infection originated in the sphenoidal sinus of the sphenoid bone this should be opened and drained (see Sphenoidal Sinus, page 198). Two routes have been advocated for reaching and draining the cavernous sinus; the orbit and the subtemporal route.

The surgeon is fully justified in sacrificing the already damaged eye. By doing an enucleation and clearing out the orbit, the terminus of the cavernous sinus is exposed. This is the ophthalmic vein. The artery enters the orbit with the optic nerve through the optic foramen. The vein is large; it passes through the inner extremity of the sphenoidal fissure and lies below the artery. The vein may be opened, the anterior part of the thrombus removed and drainage applied.

The sinus may be reached by the same route as is used for approach to the Gasserian ganglion. Instead of carefully turning down an osteoplastic flap, the quickest possible opening in the skull should be made. A generous amount of bone should be removed. The sinus is reached by elevating the dura along the anterior part of the floor of the middle fossa.

Infected thrombus of the superior longitudinal, lateral or occipital sinuses occurs commonly from adjacent bone disease and should be treated by removal of the overlying bone, removal of the center of the clot, and drainage.

Whatever is done in the operative way for infective thrombosis should not detract from the importance of constitutional measures. The resistance of the patient should be maintained, and if there is any doubt as to the adequacy of the other treatment the resistance against bacteria should be increased by the use of an appropriate vaccine (see Veins, Thrombosis, Vol. I, page 454).

Thrombosis due to *parasites* other than bacteria requires the treatment already laid down for infective thrombosis.

Noninfective thrombosis of the sinuses of the dura mater may be traumatic or spontaneous. *Traumatic thrombosis* is usually the result of fracture or operation. The treatment consists in keeping the patient quiet, the blood-pressure equable, and preventing infection. Equalization of the circulation must be looked for by the natural establishment of collateral compensation. *Spontaneous thrombosis* of the non-infective type occurs in extremely debili-

tated persons. The treatment should be a continuation of the treatment of the causative disease.

Cerebrospinal sinuses develop at the base of the skull as a result of fracture or disease and cause a continuous or intermittent discharge of cerebrospinal fluid from the nose (cerebrospinal rhinorrhea) or ear. The treatment consists in keeping the discharging cavity clean and free from inflammation.

Arteriovenous aneurism occurs in connection with the cavernous sinus, as a result of fracture of the base, wounding the internal carotid artery. It produces *pulsating exophthalmos*. The treatment consists in ligation of the internal carotid in the neck. This treatment can be expected to give improvement but not a cure because of the collateral circulation in the circle of Willis. Efforts to secure thrombosis in the sinus by ligation of the ophthalmic vein have not met with success. Ligation of the common carotid instead of the internal carotid has added much to the danger of softening of the brain and little to the expectation of cure. Ligation of both internal carotids has been attended with high mortality. The ultimate treatment consists in approaching the base of the brain through the temporal fossa and dealing directly with the disease.

Inflammations of the Brain

Acute Encephalitis.—This inflammation, by the local swelling and edema which accompanies it, may call for decompression, or it may give localizing symptoms sufficient to demand local exploration. It is sometimes discovered in operations for acute compression, or in mastoid operations with cerebral symptoms. Incision and drainage of the inflamed area may be expected to be followed by relief. It is probable that such operations may in some cases be responsible for preventing abscess formation, for an inflammation which has produced so much swelling as to call for operation is associated with a degree of inflammatory infiltration not far from the abscess stage.

Abscess of the Brain.—The treatment of cerebral or cerebellar abscess is by incision and drainage as soon as the diagnosis can be made. While it is true that some of these abscesses become walled off and chronic, and exist for many years, as the autopsy findings among the insane have shown, still the natural tendency of the disease is toward the destruction of life or toward the production of serious mental derangements. Diagnosis is often difficult, and the surgeon is referred to works dealing with diagnosis because of the harm that may be done by misdirected operative attacks in brain diseases. Diagnosis cannot always be positive, and operation must often be done upon strong but inconclusive evidence.

Some of the chief indications for operation may be given. They are observed usually in a patient with a chronic suppurative process in or adjacent to the skull. Chronic otitis media is the most common source of infection. Commonly in otitis the discharge abates; headache is apt to be severe; vomiting may be expected; changes of position often produce dizziness; a chill may be followed by a rise of temperature; the infection may be of a milder grade and give only pressure symptoms with subnormal temperature and slow pulse; drowsiness and stupor may be present, or irritability and delirium, depending upon the location and degree of pressure; tenderness upon percussion usually exists over the diseased area; focal symptoms point to the location; pressure gives its peculiar symptoms; involvement of the frontal lobes produces mental disturbances; dizziness, ataxia, and defective

coördination point to the cerebellum. The juxtaposition of the causative suppurative process is the most important guide to the location of the abscess.

Differentiation must be made between abscess of the brain, encephalitis, meningitis, infective sinus thrombosis, extradural abscess, ependymitis, and tumor of the brain in the chronic cases.

Operation directed toward abscess, fortunately, is also applicable to most of these. The prognosis in abscess without operation is very bad; with operation it is also bad. The operation gives the best hope of recovery. In the most experienced hands the mortality following operation is not below 50 per cent. Without operation all cases perish within a short time or after a prolonged period of brain derangement. The dangers of the operation are the infection of the meninges, fungus cerebri, and cerebritis.

Prevention is of the same importance here as in sinus thrombosis. The care of suppurative processes in the accessory parts of the skull is a surgical obligation. The best hope for relief is early operation. Most of these cases are sacrificed to the desire for positive diagnosis. It can rarely be made. When that late stage is reached when the diagnosis is fairly clear, it is too late.

Technic.—If there are localizing symptoms it is best to open the skull over the area indicated. If the disease starts from a suppurative otitis, and seems near the posterior temporal region, it is best to open the mastoid cells freely and expose the dura as for sinus thrombosis of similar origin. In such a case it is often possible to trace the course of an infection through the bone and dura to the brain. Cases are sometimes found in which the main abscess cavity communicates with the surface by a stem or fistula, the drainage of which is sufficient without doing any further injury to the brain tissue. Operation by way of the ear and mastoid cells gives the best opportunity to discover extradural abscess or sinus disease. It also affords the best approach to the cerebellum.

If the location of the abscess is indicated in the temporal region, a temporal craniotomy may be done as for decompression (see page 30). By this route the brain may be inspected and punctured through an uninfected region. If desired, the brain may be lifted up and the anterior surface of the petrous portion inspected.

In either method of approach, it may seem wise as a result of having discovered some other possible cause, to defer further operation. If necessary, at a later time, the wound may be reopened and the brain punctured. Upon exposing the meninges, if abscess is present there will usually be observed the bulging indicative of pressure.

For exploring the brain for abscess, the best instrument is a small-sized trocar and canula or a hollow aspirating needle with a stilette. The needle should be entered in such a way as to avoid sulci and important regions as described in the operation for spontaneous apoplexy (see page 58). The pus is sometimes thick and flows with difficulty. Having discovered an abscess, a larger trocar and canula should be inserted, and through the canula a rubber drainage tube may be passed and left *in situ.* As little traumatism as possible should be inflicted. For this reason it is usually best not to use irrigation. It is well to paint the meninges about the tube with tincture of benzoin in order to cause occlusive adhesions. A copious moist dressing should be applied and the patient should lie with the opening downward. The drainage tube, therefore, should be just long enough to reach the abscess. As the cavity drains and the pressure symptoms subside the tube may be shortened and then removed.

These patients are easily depressed, and the utmost care must be taken during the operation to minimize shock. The minimum amount of anesthetic should be used, and everything should be in readiness to meet the emergencies of cardiac and respiratory failure.

Tuberculosis of the brain and *syphilis of the brain* are treated under tumors.

Tumors of the Meninges and Brain

Benign tumors of the meninges are peculiar in that they are superficial, cause cortical compression, often give distinct localizing signs, and usually are easily detached from the brain. The malignant meningeal growths are apt to involve both brain and skull, and their removal is often difficult or impossible.

Tumors of the brain proper are represented by most every known variety of growth. The tumors of inflammatory origin are the most common. **Tuberculosis** of the brain is prone to manifest itself in circumscribed inflammatory deposits especially in the cerebellum of children. These so-called granulomata sometimes are amenable to surgical treatment. **Syphilis** develops gummatous deposits which are even more resistant to antiluetic medication than is meningeal syphilis. The dense, circumscribed, inflammatory deposit so far as symptoms and treatment are concerned is a tumor. It so often refuses to respond to constitutional treatment that it must be regarded in the same category with fibroma.

The most common form of neoplasm requiring treatment is **endothelioma.** These tumors usually originate in the endothelium of the meninges, are encapsulated, and call for operation because of pressure. When removed, brain function is often restored. **Glioma** and **gliosarcoma** are infiltrating tumors, removal of which is difficult because of their infiltrating character. They sometimes require operation for the spontaneous apoplexies which take place in them or for cystic degeneration. **Carcinoma** is usually metastatic and inoperable. **Cystoma** may be relieved by drainage if due to degenerated clot or abscess. Echinococcus and hydatid cysts require destruction of the lining of the sac. Cysts developing in broken-down neoplasms require removal of the growth to effect a cure.

Other tumors of brain requiring treatment are those which are outgrowths from the skull and meninges and metastatic deposits; also **fibroma, lipoma, myxoma, teratoma, psammoma** and **angioma.**

The chief **indications for operation** are found in the general increase of intracranial pressure and in localized disturbances of brain function. Headache, nausea and vomiting, and venous congestion of the retina (choked disk) are the most important *pressure indications.* Dizziness and vertigo are often present. The development of these is very slow, often with remissions, and the signs of pressure which call for relief in acute lesions, such as in hemorrhage, are not apt to be present.

Localizing indications are often present, and make it possible to discover and remove the tumor. A tumor too small to give pressure may urgently manifest its position and call for removal, whereas a much larger tumor may give only the signals of general pressure. To determine where to operate for the removal of a tumor the surgeon must bring to bear a good knowledge of brain function and localization (see Brain Localization, page 43). Some of the important indications may be given. Tumors first produce irritation, then paralysis from pressure. The zone of irritation precedes the paralysis, and later represents its periphery.

Tumors of the motor area of the cortex manifest themselves by causing irritation leading to focal epileptiform convulsive seizures referable to the muscle groups taking their innervation from the affected cells. As the pressure becomes greater, irritation gives place to paralysis in the same groups. Tumors of the sensory field in the postcentral gyrus and in the posterior sensory areas often cause convulsive seizures preceded by sensory aura, and ultimately followed by sensory paralysis.

Aphasia, word blindness, and speech defects indicate inhibition in the region of the left angular gyrus. Gradually the motor area may be encroached upon. Tumors of the frontal lobes are indicated by mental disturbances such as go on to insanity; the general pressure symptoms are least marked. Involvement of an occipital lobe or its optic fibers leads to blindness. The temporal lobe is a fairly silent area, but as a tumor grows it encroaches upon the motor area, and on the left side upon the speech area. Involvement of the apex of the temporal lobe causes disturbances of taste and smell.

Tumors of the base of the brain may cause pressure upon the motor and sensory paths and paralysis. Involvement of the corpora quadrigemina cause failures of coördination. Tumors of the crura cerebri, pons and other parts of the mid-brain are apt to cause

obstruction to the ventricular outlet and result in hydrocephalus; they are difficult of treatment.

Tumors of the cerebellum are not difficult of recognition. They soon cause enough pressure to close the canal against the escape of fluid from the ventricles, and the pressure symptoms of obstructive hydrocephalus appear. There is often suboccipital tenderness. Tumors compressing the substance of the cerebellum give vertigo and disturbances of coördination in the muscles of the same side. Tumors of the surface of the cerebellum are apt to lie in the cerebellopontine recess and involve the acoustic nerve. Tumors of the pituitary body cause suppression of the functions of the glandular part of that structure; acromegaly and loss of procreative power may be present; and pressure on the optic chiasm may cause hemianopsia.

Tumors of the frontal, temporal, and right parietal lobes may give no sign of their situation, and if they have been of slow growth may fail to be recognized. The distinction between tumor of the brain and certain other conditions may be difficult. Chronic nephritis, producing edema of the brain, compression, venous engorgement of the retina, and convulsions, is often confused with tumor. The symptoms are of similar origin; perhaps, similar decompressive treatment may be effective. Abscess of the brain, ependymitis, and chronic meningitis may be operated upon for brain tumor, but operation in all of these conditions is of value when called for by pressure.

Without operation the prognosis in tumor of the brain is very variable. The nature of the growth and its situation are important factors. It is impossible to determine what course the disease will pursue. Most cases are fatal. A gliosarcoma may steadily progress toward a fatal termination, and then suddenly break down in its center, and the symptoms abate. Brain tumors have spontaneously disappeared. Another may give no signs, and then suddenly develop acute and fatal pressure symptoms from hemorrhage in its substance. An endothelioma may give no signs for many years until that degree of pressure is reached when it closes a natural channel or shuts off the venous return from some part and produces edema which itself becomes a sudden and fatal cause of compression. Spontaneous decompression sometimes takes place (see Sinus Pericranii, page 24; and Spurious Meningocele, page 25). Separation of fissures in infancy sometimes results from tumor, and gives the decompression necessary to preserve life. A tumor should be removed; but this is rarely possible. Most cases can be benefited and life prolonged by palliative operations.

Active treatment is called for at once if tumor of the brain is recognized or suspected. The distressing symptoms such as pain and convulsions are to be met by means of analgesics and sedatives. Opium and coal-tar products have value. Antisyphilitic treatment should be employed in all cases unless there is a positive diagnosis of nonsyphilitic disease or unless syphilis is positively excluded. This treatment should be pushed to its utmost. The most important guide to the necessity for operation is the condition of the eye-ground. Here intracranial pressure shows itself most palpably. Venous congestion, due to increased pressure against the return of blood from the optic nerve, quickly manifests itself in choke disk, swelling of the retinal veins, and limitations of the field of vision. This is the most important guide, and examinations should be made frequently, preferably by the surgeon himself in order that he may be in closest touch with the progress of the case. Tests of vision and especially of the size and shape of the field of vision should be repeated and recorded.

If at the early examinations of the eye-ground, a condition of venous congestion is found which is so great as to threaten the eyesight, time should not be lost in testing antisyphilitic treatment but a decompression operation should be done at once with the primary object of saving the eyesight. When this has been accomplished the antiluetic measures may be applied. If there is no great urgency indicated, antisyphilitic treatment should be continued until in the judgment of the surgeon it has had a fair trial. If no results are secured from it, it may be stopped after from six weeks to three months. Judgment is required, for each individual case is different. It should be remembered that in some nonsyphilitic tumors benefit is observed from antisyphilitic measures; and on the other hand the symptoms of some old gummata of the brain, with an abundant deposit of fibrous tissue, are

unaffected by such treatment. Furthermore the treatment may do harm by disturbing digestion and increasing the nausea and vomiting already present, and thus aggravate the symptoms. Having relieved any urgent distress and given constitutional measures a fair trial the curative or palliative treatment of the tumor is called for.

Frazier warns against *lumbar puncture*, either as a diagnostic or curative measure in brain tumor. A large number of fatalities have followed this procedure, due to disturbances provoked in the basilar centers.

Curative treatment should be attempted whenever the location of the tumor is known. To partly remove a malignant tumor is worse than useless. Attempts to extirpate a diffuse growth have proved disastrous. Normal brain tissue should rarely be removed; it may be incised and separated. The tumors which are successfully removed are those which are encapsulated and those which are small. Early operation is necessary for the best success. The early cases which should not be neglected are those which give definite focal symptoms, often associated with Jacksonian epilepsy. These should not be temporized with, but should be operated upon at the place indicated before general pressure symptoms have appeared. Better results are now being secured as operative treatment is applied early as a curative measure rather than as a last desperate resort. It is surprising and gratifying to observe how cortical cells resume their function after the removal of a compressing tumor which had caused paralysis. Shock need not be feared in these operations if *blood is not lost* and if *the brain is spared rough handling*. To plunge a finger into the brain to pluck out a tumor is brutal; it is not surgical. By the use of the scalp tourniquet, by quickly controlling oozing from the diplöe, and by care in the treatment of the extradural vessels and the sinuses, there need be no considerable loss of blood. Bloody operations for the extirpation of brain tumor are serious.

Incision of the brain for the removal of a tumor should preferably be made not through the motor area. A subcortical tumor, lying in this region should be exposed by incision preferably posterior to the motor area.

The tumor being localized, the choice of making a trephine opening and enlarging it with the rongeur or of turning down an osteoplastic flap must rest upon the requirements of the individual case. The first can be most quickly executed. In either an inverted U-shaped flap is best (see Operations on the Skull, page 26). Whichever operation is done, a good big exposure should be made. The position of the patient has been discussed. Ether, up to the present time, remains the anesthetic of choice. Horsley keeps a stream of irrigation at 46°C. (115°F.) playing gently upon the exposed brain to prevent cooling. Incisions through the cortex should be made at the summit of a convolution in preference to near a sulcus. Pia-arachnoid vessels should be ligated before cutting them. The field of operation should be kept free from blood by attention to hemostasis. If a sinus has been opened and pressure applied to control bleeding, or if much blood has been lost before opening the dura, or if there are evidences of beginning shock, it is well to close the wound, and then after a few days reopen it and proceed with the operation. Many surgeons advocate operating thus in two stages in all cases.

In operating upon tumors connected with the cerebellum, Cushing lays stress upon the advantage of outward dislocation of the brain to give more room for access to the growth. By doing a bilateral suboccipital craniotomy, room is made to permit the cerebellum to protude from the skull. If more room is desired it may be secured by drawing off fluid from the lumbar subarachnoid space (see Suboccipital Craniotomy, page 36).

Krause applied **suction apparatus** as an aid in removing brain tumors, to obviate the disadvantage of prying out the tumor, by pressure from behind it. Glass cups of various sizes, ranging from 10 to 5.5 mm. (¼ to 2 inches) in diameter, are used. The cup is connected with a suction apparatus by a soft rubber tube. The tumor having been exposed, the cup is applied to it; and by making gentle traction upon the tumor and pressing back the brain with pledgets of gauze, its removal is accomplished with the least possible bleeding and traumatism (Fig. 738).

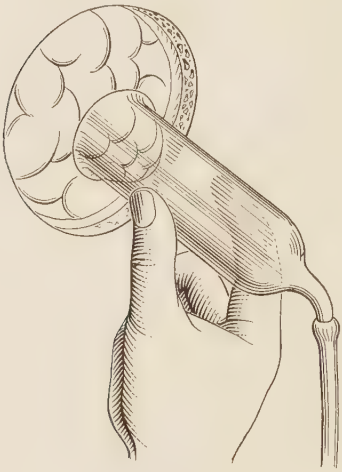

Fig. 738.—Suction Retractor for Drawing out Delicate and Friable Tumors in Tissues where Metal Retractors are Contraindicated and the Fingers cannot be Used.

Operations in two stages are often indicated. The first operation consists in turning down a large bone-scalp flap; and when, because of loss of blood or other depressing influence, the condition of the patient is not good, the dura is not opened, but the flap is replaced and held with a few temporary sutures, and the wound dressed. The closest watch should be kept for extradural hemorrhage after this first stage of the operation. After four or five days, when the condition of the patient has improved, the second stage of the operation is undertaken. The sutures are removed, and the flap is again turned down. This second operation may be done without the use of a general anesthetic. The dura may be incised and a tumor may be removed from the substance of the brain while the patient remains conscious and converses with the surgeon. Traction upon the dura causes pain, but simple incision is not painful.

Palliative operations are done in cases in which the growth cannot be removed but in which symptoms demand relief—such as headache and ocular congestion. Relief may be secured in these cases by giving the cranial contents more room. The operation which accomplishes this is called decompression.

Decompression consists in the removal of a part of the skull and dura mater, and permitting the compressed cranial contents to expand beneath the scalp. When an amount of cranial contents equal in bulk to that of the tumor has extruded itself, intracranial pressure becomes normal, and thus the symptoms of compression are relieved. If the tumor is of slow growth the relief may last for a long time. If the tumor continues to grow slowly, the plastic cranial contents will be extruded with pace equal to that of the growth of the tumor. Such conditions sometimes go on for many years. It has happened in a gratifyingly large proportion of cases that, after decompression the growth has ceased to enlarge; this has been either because it has attained its maximum growth or because it had undergone degeneration. In some cases, the increase in size of the growth after the operation has been so slow that the progress of the protrusion has been scarcely perceptible. In other cases the growth has gone on rather rapidly, causing a large extrusion of brain beneath the scalp. In other cases the growth of the tumor has seemed to be accentuated by the operation, and the progress to a lethal end has been rapid. It is doubtful if the operation is worth while in

cases with well-developed paralyses such as render life unhappy; or in cases in which the tumor has caused an obstructive hydrocephalus.

Whatever happens, the operation is strongly justified in the majority of cases. It gives relief to a brain, suffering from the effects of compression, which if continued will produce pain, blindness and death. It can give relief at least for a period. It should be done early. Patients thus relieved often return to their work and enjoy many years of comfort. The operation is practically without hazard in skillful hands. It is the expedient called for in the great majority of cases of tumor of the brain. In some cases, after decompression, focal symptoms appear and a second operation may be done for the removal of the tumor.

The area from which bone and dura mater are removed should be on the side upon which the tumor is located. The part of the brain which becomes

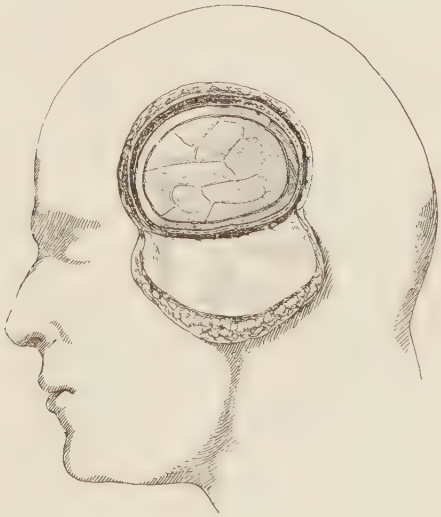

Fig. 739.—Subtemporal Decompression.

Showing relation of skull opening to the brain in subtemporal decompression operation. The scalp-muscle flap is to be sewed back in place. Note free edge of dura which is destined to cover the rough edge of bone as the brain bulges forth. This operation gives larger access than when the fibers of the temporal muscle are separated but not cut; it also leaves a weaker covering to the cerebral protrusion.

extruded suffers some derangement of function because of edema and tension, and should be some silent area. If decompression upon one side does not suffice, it may be done later upon the other side. The place of choice for the operation is the lower temporal region, especially, of the right side. This has the advantage that it exposes the silent temporal convolutions below the motor area and adds the temporal muscle to the scalp for the protection of the brain (see Temporal Craniotomy, page 30). The operation may be done in one or two stages under local anesthesia with 0.5 per cent. novocain-adrenalin solution. If the operation is done with the patient in the sitting position, no special method for hemostasis is necessary. Partial general anesthesia is necessary only in very sensitive patients.

A scalp flap should be turned down. The temporal muscle should be split and preserved. The size of the round or ovoid bony defect to be made in the skull must vary with the amount of compression which appears to

require relief. The opening should not extend above the lower end of the central fissure. It should be extended downward as far as possible; that will be nearly to the base of the skull. Usually it should be carried as far forward and backward as the retraction of the split temporal muscle will permit; that will be nearly to the anterior limit of the temporal fossa, and posteriorly to the longitude of the mastoid process. No sharp bony points should be left. The dura mater should be cut away just inside of the bony opening, leaving a free edge of dura equal at least to the thickness of the bone (Fig. 739). The meningeal artery should be ligated. When this has been done and enough bone has been removed, the temporal muscle is allowed to fall back in place. This occurs as soon as retraction is discontinued. The



Fig. 740.—Showing Result of Subtemporal Decompression.
Patient one year after operation. Note fulness of right temporal region.

temporal fascia and scalp should be sutured over the closed muscle. No drainage should be used as it is apt to cause hernia or fungus cerebri (Fig. 740).

Tumors of the cerebellum or tumors situated below the tentorium should be decompressed by suboccipital craniotomy (page 36), either unilateral or bilateral, depending upon the location of the growth and the degree of compression. In this operation also, after removing the desired amount of bone and dura mater, the muscle should be sutured back in place. In general, it is best to make a wide opening here, extending from the superior curved line to the middle of the foramen magnum, and from mastoid to mastoid (Figs. 741).

Cerebellopontine tumors, approached by the bilateral suboccipital route, may best be removed in a one-stage operation. High tension should be lowered by occipital puncture of the lateral cerebral ventricle. The greatest gentleness should be practised. After extirpation of the tumor, time should be taken to check all bleeding, the wound should be closed with

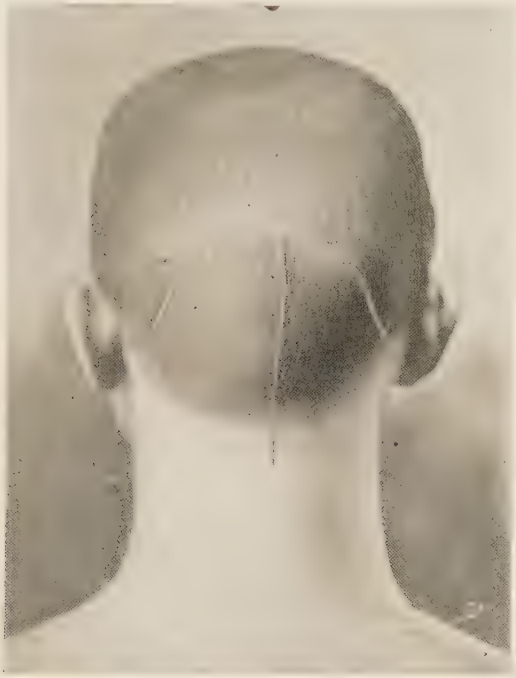

FIG. 741.—RESULT OF SUBOCCIPITAL DECOMPRESSION FOR TUMOR.
The hernia here is well protected by muscle. Note bulging in occipital region.

FIG. 742.—RESULT EIGHTEEN MONTHS AFTER DECOMPRESSION OPERATION FOR TUMOR OF LEFT OCCIPITAL LOBE.
Showing large size of hernia of brain which may be attained in locations where the skull opening is not covered by muscle.

care, and the patient should be left quietly on the table for some time in the position in which he was operated upon while the parts become adjusted to new conditions, and hemostasis becomes established.

The operation of decompression may be done as a preliminary to a later curative operation. It was once the practice to decompress directly over the tumor (Fig. 742); but the extensive cerebral protrusions which developed beneath the scalp unsupported by muscle lead to the selection of the two muscle-covered sites. As a result of the relief given by the operation, more deliberate study of the localizing symptoms may be made, or in the course of time more definite localizing signs may appear. The curative treatment should always be kept in mind, and at the opportune time a curative operation done. Subsequent to decompression, if the tumor is located with sufficient assurance to warrant an attempt at removal, if the place of approach selected is not covered by muscle, then an osteoplastic flap should be turned down so that there shall be no bony defect after the operation (see Puncture of the Lateral Ventricle as a Decompressive Measure, pages 95 and 96).

The **results** of operations for tumors of the brain are very variable. In this field surgery is recording some of its most brilliant triumphs. These operations should be undertaken only by an experienced surgeon. Sudden cessation of breathing from compression of the medullary centers is not uncommon, and must be guarded against. H. Cushing has succeeded in restoring breathing by evacuating a cerebellar cyst in a patient who had had paralysis of respiration for forty-five minutes. The *mortality* of operations is quite as variable as the results. In skilled hands, there should be no mortality in subtemporal decompression; osteoplastic craniotomy with partial or total removal of tumor shows a mortality of 8 per cent.; transsphenoidal operations for hypophyseal tumor show a mortality of about 6 per cent.; and suboccipital partial or total removal of tumor show a mortality of about 12 per cent. Operations on cerebellopontine tumors, occurring in the acoustic or lateral recess, have a high mortality. Cushing lowered the mortality of operation by a bilateral exposure. He thought the operation best done in one stage.

Operations on the Hypophysis of the Brain.—The hypophysis of the brain, or *pituitary body*, plays so important a rôle in the glandular functions of the body, and its diseases produce such serious consequences, that surgery has attempted and has succeeded in dealing with some of the most serious of its lesions. Tumors and hypertrophies of the hypophysis, which are causing serious symptoms, are amenable to surgical treatment, and operation may give good results. Thus far operations have been aimed at the removal of the tumor. The hypophysis lies in the sella turcica of the sphenoid bone. It is surrounded by such structures as the cavernous sinus, the optic tracts and the termination of the internal carotid arteries.

There are several routes by which the hypophysis may be approached. It may be reached by the frontal operation through the anterior fossa of the skull, or by the basilar transsphenoidal operation through the body of the sphenoid bone. The basilar operation is done through the nose or through the mouth and nose. Exposure laterally through the middle fossa of the skull, by lifting up the temporosphenoidal lobe of the brain, has been used. The former two methods of approach are the best. The objections to the trans-sphenoidal operations which are performed through the nose or mouth, are that infection may occur and the operation must be carried out through a long and deep channel.

The differences in size and shape of the sella turcica and of the sphenoid

cells are very variable. There is not only a wide normal range of difference but great pathologic variations also are encountered. The surgeon should always have in mind these possibilities, and should have checked up the situation with *x*-ray pictures (Fig. 743). The sphenoidal cells may be continuous with the ethmoidal cells and intimately connected with them.

The posterior wall of the sphenoidal sinuses in a third of the cases is very thin. Injury to the pons must be guarded against, as in these cases there may be but the merest shell of bone. In a few cases there will be found a transverse sphenoidal septum, which must not be mistaken for the floor or roof of the sinus. In the cases of shallow sella, the surgeon must be on his guard lest he make a path beneath the sella and enter the cranium behind it. In some cases, the tumor will have caused erosion of the sella, and entered the sinuses of the sphenoid; and when the anterior wall of the sphenoid body has been removed, the tumor comes into view.

The choice of operation must depend upon the conditions present. In cases in which the *x*-ray shows that a growth of the hypophysis deepens the sella turcica and encroaches upon the sphenoidal cells and the orifice of the cells is narrowed, the growth is best reached by one of the basilar operations, carried out through the nose or mouth. In cases in which the *x*-ray, the nasal examination, and the clinical signs indicate that the sphenoidal cells are not encroached upon but that the growth is pressing upon the brain and developing upward and laterally, the best approach is by the frontal route.

Operations on the hypophysis should preferably be done only by surgeons experienced in brain surgery. No surgeon should attempt these operations without having, in addition to an understanding of the anatomy, a knowledge of the functions of the hypophysis. The surgeon in his attacks upon this organ should bear in mind that it is a composite gland. It has a small posterior lobe, the posterior part of which is of neural origin and the anterior part of which originates from the pharyngeal epithelium. The posterior part is called the *pars nervosa;* the anterior part of the posterior lobe is called the *pars intermedia.* The larger anterior lobe, which originates entirely from the same structures as the pharyngeal epithelium, is the *pars anterior* and originates from the same structures as the *pars intermedia.* The total removal of the hypophysis leads to death with the peculiar symptoms known as apituitarism, or cachexia hypophyseopriva. Even partial removal of the gland interferes with the balance of internal secretions and indirectly affects the thyroid, testicles and other glands. The most profound disturbances arise from removal of the anterior lobe, and it is probable that overactivity of this lobe causes giantism and acromegaly. The tumors for which operation is done, which spring from the hypophysis or neighboring structures, may be removed without removing so much of the gland structure as to cause appreciable disturbance. A tumor of the hypophysis it should be remembered, is not a hypertrophy of secreting tissue. By its pressure it may cause diminution of secretion; and its removal restores the action of the gland.

The tumor cannot be dissected out with the nicety of the ordinary dissection on account of its depth and inaccessibility. Usually a soft growth is found which can partially be scooped out, or a cyst which can be evacuated. Hard tumors are to be removed piecemeal. Complete extirpation is not to be expected in the majority of cases.

Profound anesthesia is not necessary in most cases. The nasal operations may be done with local anesthesia. Twenty per cent. cocain solution with adrenalin, or the pure flakes of cocain are preferred by the rhinologists for anesthetizing the mucous membrane in the line of incision. Scopolamin and morphin, combined with local anesthesia, suffice for the nasal operations.

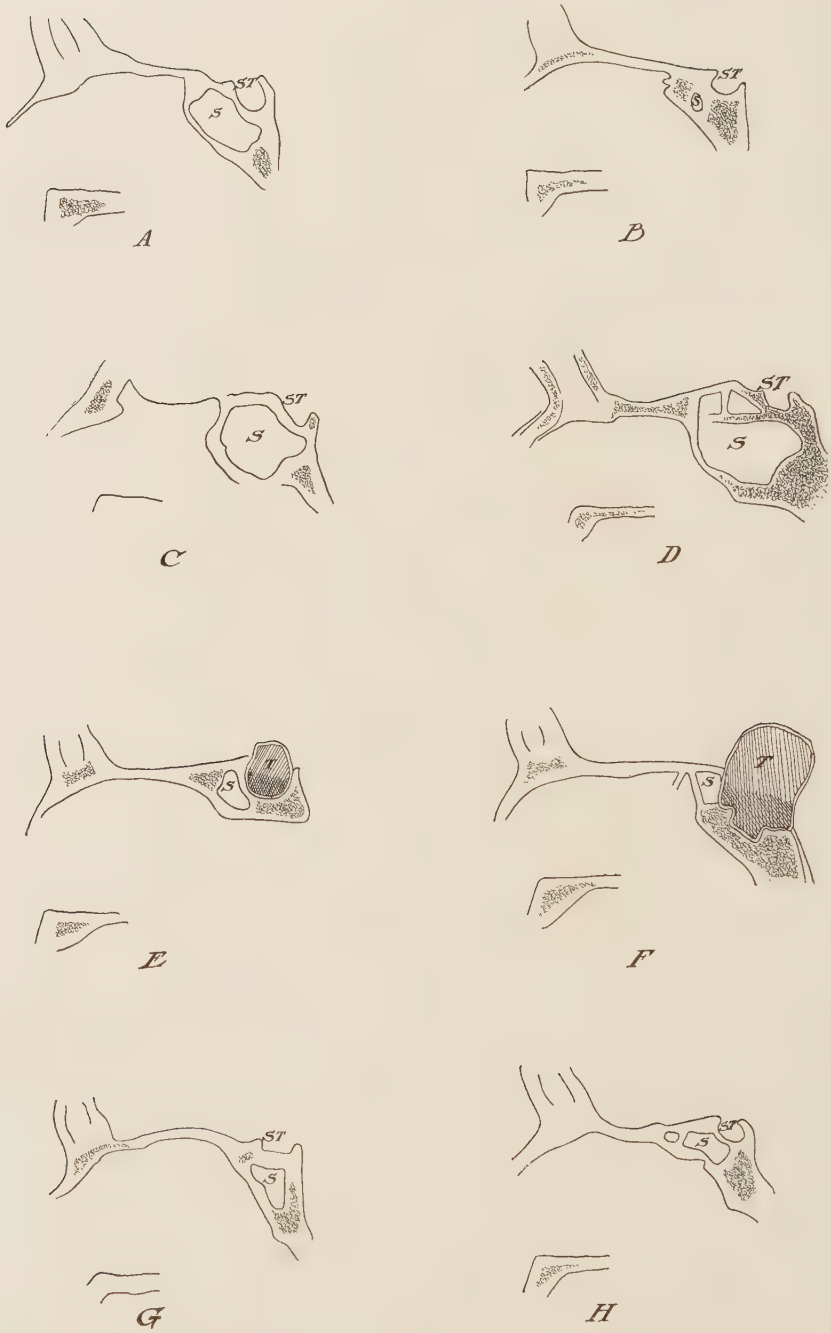

Fig. 743.—Showing Various Relations and Sizes of Pituitary Body (*P*), Sella Turcica (*ST*), and Sphenoidal Sinus (*S*).

T, Tumor of hypophysis; *A*, large sized sinus; *B*, small thick-walled sinus; *C*, large sinus, small sella turcica; *D*, large multiple sinuses; *E*, small sinus, small pituitary tumor; *F*, small sinus, large pituitary tumor; *G*, low sinus; *H*, high sinus. The possibility of meeting any one of these conditions must be had in mind in operating on the pituitary body. The *x*-ray can be of valuable service in predetermination.

The patient should be placed on a table which will permit tilting in any direction, as it may become necessary to elevate the head to stop bloody oozing, or depress the head to cause the brain to move upward to make more room.

Approach to the hypophysis by the frontal route is accomplished by turning back an osteoplastic flap on the forehead. The two horizontal incisions may be hidden by placing them on the hairy scalp, the lower limb involving the eyebrow. The vertical incision may fall in the median line (Fig. 744). The plate of frontal bone turned back with this flap should be about 5 cm. (2 inches) in diameter, or more, and should include the supra-orbital ridge

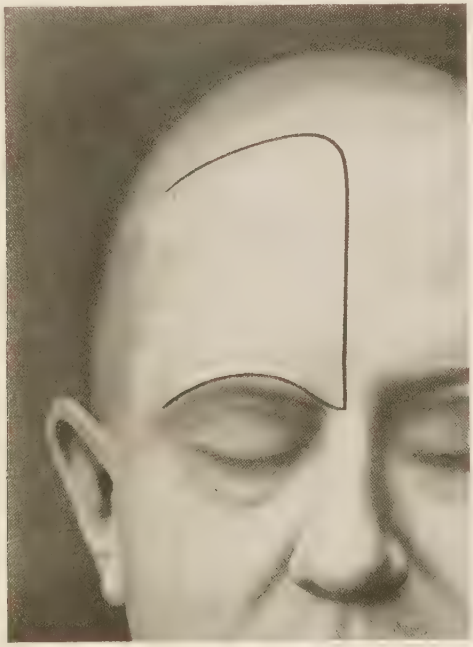

FIG. 744.—APPROACH TO HYPOPHYSIS BY THE FRONTAL ROUTE, SHOWING LINE OF INCISION.

The patient's head has been shaved. The incision is in hair-bearing areas except in the median line.

(Fig. 745). The object of this opening is not only to give access but also to provide for some extruding displacement of the frontal lobe (see Osteoplastic Resections of Skull, page 30).

The orbital plate of the frontal bone should be removed with rongeur forceps. The removal of the roof of the orbit should be carried back through the lesser wing of the sphenoid to the optic foramen. The head of the table should be elevated about 30 degrees. The patient's head is then extended dorsally and allowed to hang over the end of the table so that the brain shall be displaced upward. By retracting the frontal lobe of the brain upward and depressing the contents of the orbit, the contents of the sella turcica are freely exposed. The optic nerve is gently retracted outward, and the dura, covering the hypophysis, is incised from one anterior clinoid process to the other. This brings the hypophysis into full view (Fig. 746). The incision in the dura should be about 0.5 cm. ($\frac{3}{16}$ inch) above the base

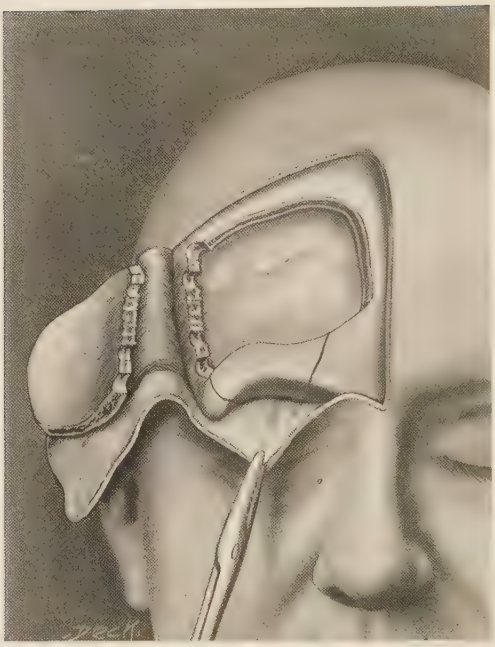

FIG. 745.—FRONTAL APPROACH TO HYPOPHYSIS.
Osteoplastic flap has been turned back. Supra-orbital bone is to be removed with roof of orbit.

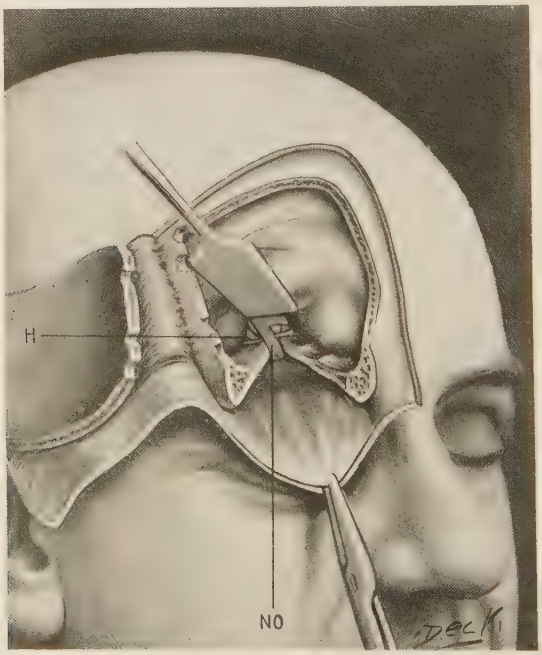

FIG. 746.—FRCNTAL APPROACH TO HYPOPHYSIS.
The roof of the orbit has been removed. The frontal lobe is elevated with a thin flat retractor. The optic nerve (*NO*) is exposed. To the left of the optic nerve is seen the hypophysis (*H*).

of the skull. By passing a retractor into this slit the hypophysis is seen as a reddish-gray body. The optic chiasm is above the opening.

C. A. Elsberg made the scalp incision almost wholly upon the hair-bearing scalp. (Annals of Surgery, 1914, vol. 59, page 455.) This is done by placing the base of the flap at the median line (Fig. 747). The only advantage of this is the cosmetic elimination of the incision in the middle of the forehead. The flap with the base outward has better nourishment.

C. H. Frazier (Annals of Surgery, 1913, vol. 57, page 145) preferred the flap with the base outward. He did not include the superciliary ridge in the osteoplastic flap, but removed it with part of the orbital plate, and replaced it afterward. The operation is done preferably on the right side.

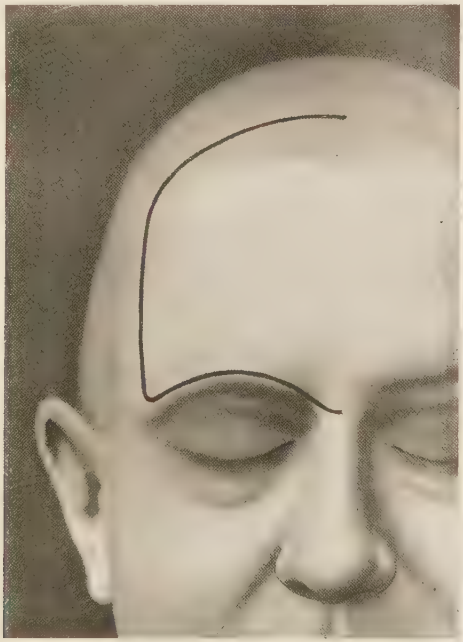

Fig. 747.—Frontal Approach to Hypophysis.
Incision for turning back osteoplastic flap with base inward.

If the condition of the patient requires it, the scalp-bone flap may be cut but not turned back until the patient has fully recuperated after one or more weeks, thus doing the operation in two stages. It is possible, by cutting an H-shaped opening in the dura, greater displacement of the brain takes place and more room is secured. This should rarely be resorted to. If adequate room is provided without cutting the dura, it is much better to preserve the dura, carefully separating it from the bone, and leaving it unopened until the hypophysis is reached. Under no circumstances should the basilar dura be injured before reaching the chiasm. A broad flat retractor should lift up the dura with the brain, while another retractor should press downward the orbital contents. This retraction must be intrusted only to a skilled assistant; it is one of the most important functions in the operation.

In making the transverse incision in the dura, 0.5 cm. above the level of the floor of the anterior fossa, great care must be used. Krause has de-

vised a hook-shaped knife for this purpose. If the incision in the dura is made too low the venous sinus, which lies in the groove between the two optic foramina, will be opened. The hooked knife prevents cutting the vessels immediately under the dura. The incision is placed between the sinus and the optic chiasm. The chiasm does not occupy the optic groove but lies above the sinus which does. This frontal operation, if carefully carried out, does not endanger or involve any important structures until the incision is made in the dura.

After exposing the hypophysis, and dealing with the tumor, a thin cigarette drain is carried back to the dural opening, brought out through the eyebrow region, and the wound closed.

The osteoplastic flap method may give place to resection of a bony segment, and its replacement at the close of the operation. This frontal operation, although planned by Krause, was first applied by N. F. Bogojawlensky (Zentralb. f. Chir., Feb. 17, 1912, vol. xxxix, no. 7), and in America by L. L. McArthur (Jour. Am. Med. Assoc., June 29, 1912, vol. lviii, no. 26).

H. Cushing (Jour. Am. Med. Assoc., Oct. 31, 1914) worked out an operation whereby approach is made through the mouth. The operation is a low nasal approach. An incision is made along the line of mucous membrane reflection between the alveolar margin and the upper lip. The soft parts are dissected up and the nose entered.

Approach to the hypophysis by the nasal route has been made safer by the newer methods of rendering the operative field aseptic. The use of iodin plays an important rôle in this. The nasal route is to be chosen in cases in which the growth is downward and encroaching on the sphenoidal sinus.

The simple transnasal operation may be done under cocain anesthesia in several stages. Cocain and adrenalin solution are used. The operation may be done most easily on the left side. At the first sitting the middle turbinated bone is removed. After several days the ethmoid cells are removed. After another interval of several days the anterior wall of the sphenoidal sinus is removed. This is done with trephine, rongeur, chisel, or burr (see Operations on the Nose, page 179). These operations are performed by the methods commonly used in rhinologic work. The hypophyseal prominence is now seen projecting into the sinus. At a later sitting a transverse opening is made through the bony wall of the sella turcica by means of a burr or chisel. The wall of bone may be removed with a steel hook, or, if very thick, it may be cut away with a trephine or burr. This brings the hypophysis into view. The dura, covering it, may then be incised, and the operation completed, or the incision of the dura may be done at a later sitting. A small antiseptic gauze packing completes the operation. Some surgeons leave the cavity without any dressing, but simply plug the naris with a gauze tampon. A head mirror or a nasal lamp is necessary for this operation. It can be done only in large nasal cavities. Sacrifice of the turbinates and ethmoid sinuses is often followed by chronic ozena.

Nasal operation with removal of the septum gives a wider path of approach (Fig. 748). The turbinates are removed from both nasal cavities at a preliminary operation. Usually it will be found best to remove the middle and part of the inferior turbinates. At a later sitting the anterior wall of the sphenoidal sinus is removed on either side of the septum. At the same operation or later a quadrilateral piece is removed from the nasal septum. This is done by making an incision, about 2.5 cm. (1 inch) long, parallel with and anterior to the anterior border of the perpendicular septal plate of the ethmoid. From each end of this incision the septum is divided with a chisel in an upward and backward direction in two parallel lines as far as the sphe-

noid (Fig. 349). This quadrilateral piece of septum is removed as for submucous resection. The remains of the septum attached to the sphenoid are removed together with the median portion of the anterior wall of the sphenoidal sinus. At the same or at a later operation the sella is opened.

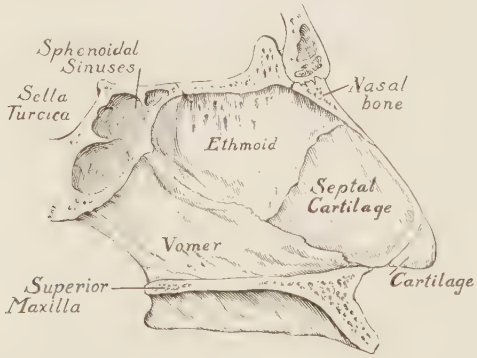

FIG. 748.—SHOWING ANATOMY OF NASAL SEPTUM.

This opening has the disadvantage that it gives an oblique path of access to the sella and it is more difficult to orient such a path. Direct median straight access may be secured by carrying a skin incision around the base of each ala of the nose, and prolonging the upper end of the anterior septal incision upward to the tip of the nasal bones and completing the division of the septum at its lower anterior part (Fig. 749, *FA* and *EB*). This permits lifting up the anterior part of the nose and turning it back as a flap.

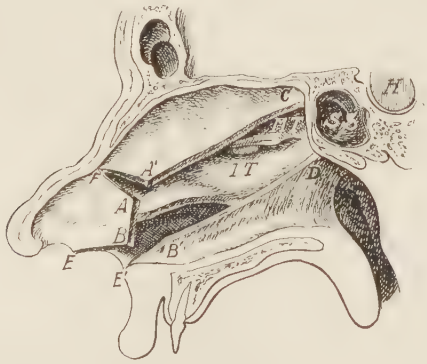

FIG. 749.—NASAL APPROACH TO HYPOPHYSIS.

Showing quadrilateral piece (*ABDC*) removed from septum to give access to sphenoid sinus (*SS*) and hypophysis (*H*). The anterior wall of sinus and the floor of sella turcica remain yet to be removed. The middle turbinate (*MT*) and the inferior turbinate (*IT*) have been partly removed. By making incisions *FA* and *EB* through the septal cartilage, the tip of the nose may be reflected upward and wider access secured.

A more satisfactory method is to turn up the anterior part of the nose as a flap as the first step in the operation. The operation is done with the patient in a semisitting position. A tampon is inserted to close the posterior nares. The nose is packed with adrenalin gauze. An incision on the face follows the curve of the alæ and passes just below the nostrils. The cartilage

of the septum is cut from its attachment to the vomer below and from the perpendicular plate of the ethmoid above. This leaves the end of the nose and septum free as a flap. The cartilaginous septum is retracted to one side, the middle turbinates are removed, and the bony septum is cut away with rongeur forceps back to the sphenoid. The sphenoidal foramina are identified and the cells opened with chisel and forceps. This is the operation worked out by A. B. Kanavel. Instead of removing the turbinates, they may be pressed aside and flattened by long straight retractors.

The *high nasal operation* is the most destructive, but provides the shortest path to the hypophysis. An incision is begun at the inner end of the eyebrow, passing down the side of the nose, curving about the ala, and ending at



Fig. 750.—High Nasal Approach to Hypophysis. Skin incision.

the opposite side of the septum (Fig. 750). The nose is reflected to one side, the vomer being cut as far back as possible and reflected with the flap. Preservation of much of the vomer is necessary to prevent subsequent saddle-nose. The operation then proceeds directly backward, removing the turbinates and the rest of the vomer, and reaching the sphenoidal sinus (Fig. 751).

O. Chiari (Wiener Klin. Woch., Jan. 4, 1912, vol. 25) obtained access to the hypophysis by an incision along the outer edge of the nasal bone. The soft parts are retracted, the eyeball carefully pressed outward, and the inner wall of the orbit, the ethmoidal and sphenoidal cells, resected and the rear part of the nasal septum removed.

It is possible to substitute for this operation a submucous resection of the septum. The resection is carried as far as the rostrum of the sphenoid. The middle turbinate is removed, and a long nasal speculum used to hold aside the flap of mucous membrane, cartilage and periosteum. The mucous membrane, with the periosteum, is elevated from the point of the sphenoid. By retracting the parts the denuded sphenoid is well exposed and the anterior wall is broken into and removed. The septum of the sphenoid may be removed with forceps.

The *combined frontal and nasal operation* may be performed in cases in which the frontal operation has been attempted and the tumor found to have

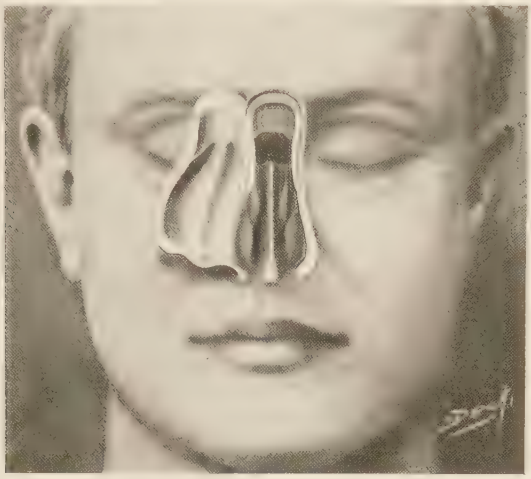

FIG. 751.—HIGH NASAL APPROACH TO HYPOPHYSIS, NOSE REFLECTED ASIDE.
The upper nasal cavity is exposed and entrance through the frontal sinus provided.

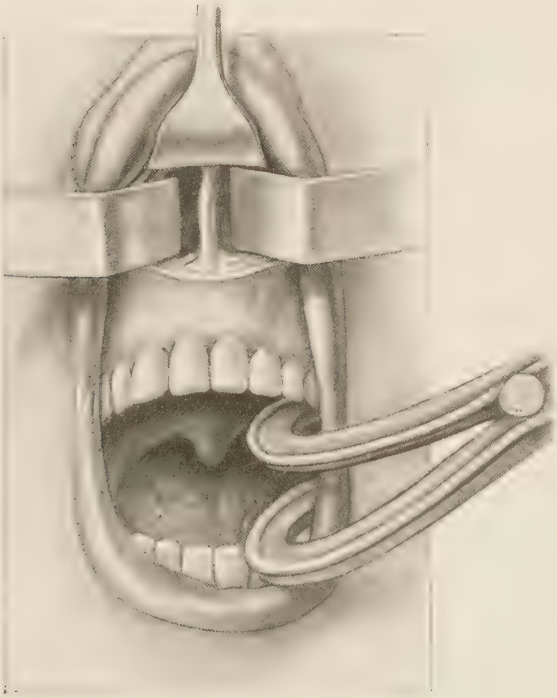

FIG. 752.—NASOBUCCAL APPROACH TO HYPOPHYSIS.
Mouth held open by gag. Incision made at labio-alveolar junction. Mucous membrane stripped up from cartilaginous septum. Retractors in opening showing septum of nose. Note mouth-gag provided with ether vapor tubes.

grown downward into the sphenoid so far as to be inaccessible from above. Under such circumstances the surgeon may proceed to make an incision along the inner margin of the orbit, remove the inner wall of the orbit, gain access to the posterior nares, and complete the operation by the intranasal route.

The *bucconasal route* is practically the same as the low nasal approach. It gives more room than the unilateral operations, and does not require the rhinologist's skill. Intratracheal etherization is most effective in these operations. A transverse incision is made in the mucous membrane at the angle where the posterior lining of the upper lip is reflected upon the alveolar process

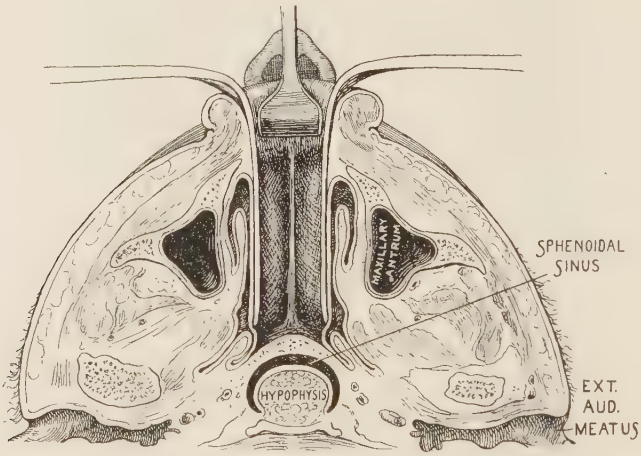

Fig. 753.—Nasobuccal Approach to Hypophysis.

Transverse horizontal section, looking down upon the parts in a reversed position. The mucous membrane has been stripped from the septum nasi. The bony part of the septum has been removed. The turbinates and mucous membrane are pressed against the lateral walls by long retractors. The anterior wall of the sphenoidal sinus is exposed for removal.

of the upper jaw. The mucous membrane is separated upward, and the septum of the nose exposed without opening through the mucous membrane of the nasal cavities (Fig. 752). The mucous membrane is separated from the septum and retracted laterally. The cartilaginous septum is cut through obliquely at the level of the anterior limit of the upper jaw. The upper lip, and the anterior part of the nose and septum are retracted upward. Lateral retractors are inserted, and the posterior part of the cartilaginous septum and the bony septum are removed directly back to the sphenoid. (Figs. 748 and 749). The turbinates are flattened against the lateral nasal walls by lateral retractors. By saving the turbinates, the patient is spared the disagreeable ozena which commonly follows their removal (Fig. 753). After the removal of the septum back to the sphenoid, a special bivalve speculum is inserted. This shows a straight path to the sphenoid. The sphenoid antrum is opened with cutting forceps and the hypophyseal bulge exposed (Fig. 754). This is the operation worked out by H. Cushing.

Encephalocele.—This is a developmental defect, occurring usually in the median line of the skull. It is observed in the occiput, below or above the tentorium cerebelli, and in the region of the frontonasal angle, having passed through a defect in the ethmoid bone. *Meningocele, hydrencephalocele,*

encephalocystocele, and *cenencephalocele* are all variations of this form of encephalomeningeal hernia. The important fact in the treatment is that they are congenital defects which are apt to be associated with other defects such as spina bifida, hydrocephalus, and other brain abnormalities, which often render a complete cure difficult, if not impossible. The treatment by compression, tapping, reduction and retention, or by the injection of irritating substances has in rare cases been successful. It is not to be recommended.

The skin over these tumors should be kept healthy and clean, lest ulceration and sloughing lead to infection. The rational surgical treatment consists in exposure of the hernia, reduction or removal, and closure of the opening. As much of the scalp should be removed as is necessary to avoid

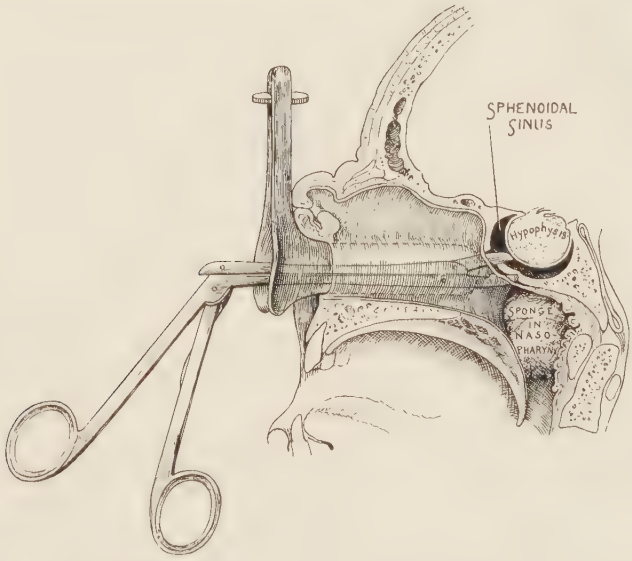

FIG. 754.—NASOBUCCAL APPROACH TO HYPOPHYSIS; SPECULUM IN PLACE.
Nasal cutting forceps are removing wall of sphenoidal sinus. The gauze sponge in the naso-pharynx is controlled by a thread passing forward through the nostril.

redundancy. The incision should be carried down to the meninges. In a comparatively large tumor the meninges will be found much thinned. There may be an absence of dura, and the pia-arachnoid will be found lying against the connective tissue of the scalp. The treatment of the herniated tissue must depend upon its structure. If the thinned-out meninges and nerve tissue enclose a chamber of cerebrospinal fluid which communicates with a ventricle, as is usually the case, the fluid may be drawn off and the hernia reduced; or the herniated structures may require to be excised and the meningeal wound sutured with fine catgut. If enough dura is present it should be sutured across the opening. The closure of the cranial defect is most important. A good covering of dura mater may suffice, but usually this is not to be had. The most effective closure is secured by means of an osteoplastic flap, which may be added to the dural covering or used in its stead. Absence of dura may in some cases be compensated for by transplanting a piece of fascia lata.

In the absence of dura a flap of bone or periosteum is necessary for success. The pericranium in children has the power of generating bone, and it may be used as a flap without taking the underlying skull. Such a flap may be turned in from the adjacent parts of the skull (see Operations on Bones, Vol. I, page 688). The skull in infants is thin and pliable and may be cut and turned in as desired. The edges of the cranial opening may be freshened and a piece of skull of similar size and shape may be cut out from the adjacent bone and transplanted into the opening (see Bone Grafting). Or partly detached flaps may be used (Fig. 755).

The success of such an operation can be assured only by asepsis. If the operation is not well done it had better not be done at all. Before undertaking it, the surgeon can know the size and site of the bony opening, and

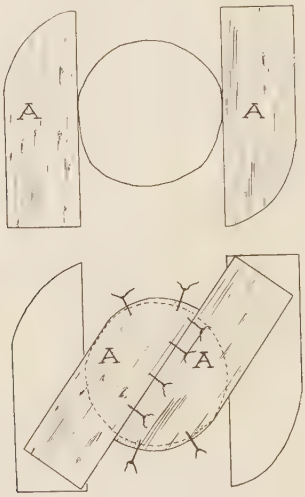

Fig. 755.—Sliding Flaps of Bone (AA) for Closing Defect in Infant's Skull.

These flaps may be left attached to the scalp; rotated across the opening, and sewed.

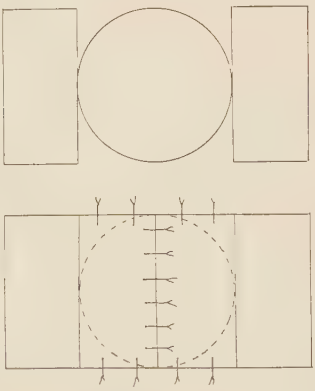

Fig. 755*a*.—Flaps of Bone Used to Close Defect in Skull.

Diagram showing flaps slid over defect and sewed.

he should have worked out tentatively the osteoplastic operation which he purposes to do. After closing the wound a firm dressing should be applied so that the crying of the child shall make the last possible strain upon the sutures. There is often obstruction in the ventricular communications in these cases, often associated with hydrocephalus, and recurrence is prone to take place. The withdrawal of cerebrospinal fluid from the lumbar region is often called for to relieve tension. Or drainage of the ventricles may be indicated (see Hydrocephalus).

Hydrocephalus.—Hydrocephalus is a symptom of local disease which results in an excessive collection of cerebrospinal fluid in some of the intracranial chambers. There may be an excessive secretion of fluid or a deficient absorption of fluid. The latter is most commonly due to some obstruction in the channels, as a result of which the fluid is prevented from escaping from the ventricle where it is secreted to the parts where it is absorbed. This is the common cause of hydrocephalus, and treatment to be curative must remove the barrier. (1) *External hydrocephalus*, in which the excess of fluid

is between the brain and the skull, is rare. (2) *Acquired internal hydrocephalus* results from postnatal obstructions, caused by meningitis, ependymitis, venous obstruction in the velum interpositum, or tumors. (3) *Congenital ventricular hydrocephalus* is the common form, and is apparently due to some disease which produces both obstruction and increase of the ventricular fluid.

External hydrocephalus must be treated by the withdrawal of the fluid, the location of which may be determined by the *x*-ray. A small trocar and canula or aspirating needle may be passed through the skull at any convenient point away from the venous sinuses and meningeal arteries.

Acquired internal hydrocephalus is caused by certain known conditions, and the treatment is first that of the causative factor. Because of the fact that consolidation of the skull is well advanced when this disease occurs, death usually takes place with symptoms of compression; although a spontaneous bulging apart of the cranial sutures may produce natural decompression. Compression of the brain is the cause of death in most cases of basilar meningitis.. Sometimes the exudate may act as an intermittent obstruction to the ventricular passages, and there may be remissions and exacerbations. Obstruction in a single ventricle at the foramen of Monro causes unilateral internal hydrocephalus.

The removal of the obstruction is sometimes possible if it is a tumor. If the tumor cannot be removed, a decompression operation will sometimes so relieve the pressure that the cerebrospinal fluid again circulates and the symptoms are mitigated. Before obstruction to the ventricular outlet has become complete, relief may be secured by lumbar puncture. Warning is necessary against the danger of this operation if the intracranial pressure is considerable, and especially if the ventricular outlets are not free, because the withdrawal of spinal fluid may cause the medulla to be jammed down into the foramen magnum with fatal force. Lumbar puncture may be done safely after a decompression operation or after withdrawal of the ventricular fluid by puncture.

Puncture of the cerebral ventricles is done when curative treatment cannot be carried out. Direct drainage of the fluid from the distended ventricles should be done in connection with all operations for decompression, unless it is known that there is no obstruction to the ventricular passages. This operation is also done for diagnostic purposes. Ventricular puncture proves to be curative in cases in which the obstruction is due to inflammation or congestive swelling which may be helped to subside by the removal of the compressing or infected fluid. Natural drainage of the ventricles may be reëstablished when the pressure is removed.

The *technic of ventricular puncture* is simple. The puncture should be made with an aspirating needle with openings on the side and a closed point, a trocar and canula may be used, but if there is doubt as to the diagnosis, a blunt-pointed needle, having lateral openings should be used in order that any other fluid, such as abscess, short of the ventricle may be discovered. The operation requires that the needle shall not wound sinuses, meningeal arteries, sulci, or the island of Reil, in order to avoid hemorrhage. Important cortical regions should be avoided. The operation is proceeded with as any brain operation (see Operations on the Skull, page 26). The skull is exposed by a linear incision or by turning down a small U-shaped flap. A trephine opening is made, and the dura incised in order to discover the summit of a convolution. The needle is passed to the ventricle, the fluid drawn, the button of bone replaced (if no infection is present), and the wound closed. A bilateral operation may be required; or subsequent punctures

may have to be made. If meningitis is present, care must be taken to sterilize the site of puncture.

The site of puncture, commonly selected is the posterior part of the middle frontal lobe, 2.5 cm. from the median line and 3 cm. anterior to the fissure of Rolando. On the skull this is perpendicularly above the midzygomatic point, somewhat in front of the bregma (page 49). The needle should pass downward and slightly backward. The ventricle is 4 or 5 cm. from the surface, and extends at least 2 cm. from the median plane.

Keen advocated puncturing at a point about 3 cm. behind and 3 cm. above the external auditory meatus, in the posterior part of the first temporal convolution. The needle should be directed toward the top of the opposite pinna. The ventricle will be reached at about 5 cm. from the surface. This temporal puncture has the advantage that it may be used in those cases in which the mastoid cells have been opened and the temporal lobe exposed in search of abscess. When no abscess is found to account for pressure, it may be determined by puncture of the ventricle that the symptoms are due to ventricular obstruction due to basilar meningitis.

Puncture of the lateral ventricle as a decompressive measure was advocated by F. von Bramann (Deut. Med. Woch., Sept. 23, 1909, vol. 35, no. 38) and now widely applied in brain tumors and *hydrocephalus*. It has given very satisfactory results. A short longitudinal incision is made in the scalp 1 or 2 cm. to the right of the median line and a small button of bone removed from the skull with a trephine 1 or 2 cm. posterior to the coronary suture. The dura is incised and a small curved trocar and canula is passed downward and inward. It should reach the tough falx cerebri, which serves as a guide, and glide downward along the side of the falx to the corpus callosum. The trocar should not be too sharp, lest it puncture the falx. It should then be pressed gently through the corpus, and when it has penetrated that body, its tip lies in the cavity of the ventricle, and fluid should flow. The opening through the corpus callosum should be enlarged to 1 cm. by moving the canula forward and backward. The canula should then be removed, and the incisions in the dura and skin closed. The pressure of the ventricular fluid causes it to continue to escape through the wound tract, which is thus kept patent, and find its way to the subdural space.

In some cases of internal hydrocephalus the opening seems to become permanent.

In children the trephine need not be used; the canula may be introduced through the coronary suture.

In cases of intracranial tumor, whether the increased tension is due to the tumor alone or to edema, there is interference with the flow of fluid from the lateral ventricles to the fourth ventricle and the cord. This causes increased intraventricular pressure, which this operation relieves. In tumors causing blindness and coma, this simple operation has produced most brilliant improvement.

Not only are symptoms relieved, but, the pressure complications being removed, focal signs are more easily discovered, and the location of a tumor determined. Many surgeons believe that this method should be used in preference to decompression operations. In skilled hands it is practically without mortality or harm.

In cases of *congenital hydrocephalus*, *subtemporal drainage* has some advantages. A curved incision, 6 cm. (2½ inches) long, is made above the right ear with its convexity directed backward. A scalp-flap is turned forward. The fibers of the temporal muscle are separated in the front part of the wound. The skull is opened at the point for ventricular puncture

(see page 36). The opening is made with a burr or small trephine. The dura is incised and the lips of the wound held apart. A ventricular puncturing tube or a large hollow needle with a dull point is passed into the ventricle. The cerebrospinal fluid flows forth. A silver drainage tube is then inserted into the ventricle. Its end should just emerge through the bony opening. A flange should prevent its inward displacement. The wound is closed, and the patient kept quiet. The fluid from the ventricle passes into the connective-tissue spaces of the temporal region.

Congenital ventricular hydrocephalus is peculiar because it develops while the skull is still capable of distention, and produces a characteristic enlargement of the head. Prophylaxis demands the elimination of syphilis in the parents. The etiologic factors in rachitis must also be eliminated. Healthy parentage is the essential preventative. In the treatment, it does not seem to be sufficient to draw off the fluid because there seems to be an abnormal and excessive secretion of cerebrospinal fluid. Even when the foramen of Magendie is patent, which it usually is, and the ventricles can be tapped by puncture of the lumbar subarachnoid space, the disease persists.

Encephalocele and spina bifida are so often associated with this disease that it would seem that some congenital defect in the circulatory system of the cerebrospinal fluid must lie at the base of the trouble. Attempts to find and remedy the defect have had poor success. Some cases of congenital hydrocephalus undergo spontaneous cure. This has been observed usually in the mild cases. The pronounced cases and the rapidly progressing cases have perhaps never been cured by surgery.

Inasmuch as no means has yet been found to check the abnormal production of cerebrospinal fluid, three alternatives remain: to remove it as it accumulates, to restore communication between the occluded cavities, or to conduct it to some tissue which can accomplish its absorption.

The ventricles in these cases may be tapped without much consideration of the rules for tapping in acquired hydrocephalus. The brain is flattened out against the dura in some cases to the thinness of paper, and puncture may be made most anywhere except through the venous sinuses. The fontanel, at one or the other side of the longitudinal sinus, is commonly used. All that is required is that the scalp shall be cleansed and the puncture made with a hollow needle. All of the excess of fluid may be drawn off at one time if no bad symptoms develop. It may be expected to reaccumulate rapidly —sometimes within a few hours. The operation may be repeated indefinitely. It has no curative value. Its only uses are for diagnosis; as a temporizing expedient to keep the child alive in the hope that the natural circulation and absorption of the cerebrospinal fluid may become established; and as a preliminary or part of an operative attempt to cure the disease.

Attempts to reëstablish communication between the ventricles and the subarachnoid space around an occluded foramen of Magendie have failed to cure the disease. Even if the occluded foramen becomes patent, as it is in most cases, the disease persists.

Many operations have been devised to establish permanent drainage between the subarachnoid space and the connective-tissue spaces of some external tissue. The operations which have given the best results originated in attempts to establish communication with the peritoneal cavity. This communication has failed to remain patent, perhaps, in all cases because of a sealing over of the peritoneal opening, but communication with the subperitoneal connective-tissue spaces has persisted and continued to drain off the cerebrospinal fluid.

Before attempting the operation for *subperitoneal drainage* it is important

to know if there is any obstruction in the passage from the ventricles to the subarachnoid space of the cord. This may be determined by lumbar puncture. If a sufficient amount of fluid flows to show evidences of emptying of the head accumulation, as manifested by the amount of fluid and by the depression of the fontanel, it may be known that there is a patent communication. The fluid flows slowly. The amount that escapes depends upon the internal pressure. Some temporary occlusion may be deceptive. Some surgeons make the test more accurately by simultaneous lumbar and ventricular puncture, connect a small glass tube with each needle and observe the fluid rise to the same height in each if the communications are patent; and if one tube is lowered to permit the fluid to flow away the pressure in the other tube is at once observed to be reduced if the two fluids connect.

Several days after the above test has shown that the ventricles empty into the subarachnoid space, the operation may be done. The bifurcation of the aorta is exposed by a median laparotomy. The peritoneum is divided just below the bifurcation, and the anterior surface of the body of the fifth lumbar vertebra is exposed. The bone is penetrated by a small trephine, and the spinal canal opened. The dura is cut away, and the arachnoid membrane perforated by blunt dissection. This is followed by a steady flow of cerebrospinal fluid. A bit of peritoneum may be removed from either side of the wound so as to leave it open, and the abdomen is closed. There is a tendency after this operation for the peritoneal wound to become sealed over; but still the drainage goes on into the retroperitoneal space. After a time the bone wound tends to close and shut off entirely the escape of the fluid.

To keep the wounds open a silver tube may be inserted into the trephine opening, giving the bony canal a silver lining. Cushing then turned the patient over, did a laminectomy, and opened the subarachnoid space. The strands of the cauda equina are separated, and another tube is inserted which fits and locks into the anterior tube. The wounds are then closed. The fluid drains at first into the peritoneal cavity, but the peritoneal opening soon becomes closed and drainage goes on into the retroperitoneal connective tissue, whence the fluid is taken up into the receptaculum chyli, and thrown back into the blood. The reports of enough of these operations have not been published to justify a conclusion as to their merits. It is doubtful if the introduction of a silver tube adds much to the permanent value of the operation; the presence of a foreign body certainly has decided disadvantages.

If, in the preliminary tests, it is found that the subarachnoid space of the cord cannot be made to drain the ventricles, then a communication must be made. This is accomplished by exposing the brain in the temporal or parietal region, incising the ventricle, and removing a bit of brain tissue so that the ventricular fluid shall flow into the arachnoid. It is best that the brain wound should not lie in contact with the wound of the dura, skull and scalp, lest adhesions defeat the object of the operation. Hernia cerebri is also to be feared. These objections may be obviated by turning down a skull flap.

Drainage of the cisterna magna into the cranial sinuses was worked out and first practised by I. S. Haynes (Annals of Surg., vol. 57, 1913). The operation aims to expose the occipital bone from the foramen magnum to the occipital protuberance by a median incision. The periosteum and muscle are reflected laterally. The bone is trephined midway between the foramen and the protuberance, and the bone removed upward to expose the posterior end of the longitudinal sinus. The feature of the operation is to connect the cisterna magna with the longitudinal sinus by a tube which shall permit

the flow of fluid. Haynes used rubber and silver tubes having an internal diameter of 1.5 mm. The tube is let into the cistern and the sinus by minute openings into which it fits tightly, and sewed with silk. The length of the tube should be from 2 to 2.5 cm. (¾ to 1 inch). The lower puncture is made through the dura and arachnoid into the cisterna, the upper puncture is made through all of the structures directly into the longitudinal sinus. As the pressure in the basilar subarachnoid space (the cisterna magna) is greater than in the venous sinus, the flow of fluid should be toward the sinus.

The operation with tubes of rubber or metal is naturally bound to fail. Payr used a piece of the child's long saphenous vein. If that is not big enough, an enlarged scalp vein, external jugular, internal jugular or femoral vein may be used.

So far as is known none of these operations have succeeded in restoring hydrocephalic children to health. Payr attempted diverting the fluid through a vein into the superior longitudinal sinus. A rubber tube is not to be considered for such a purpose.

W. Sharpe (Am. Jour. Med. Sci., 1917), employed strands of linen thread, inserted into the ventricles in the internal type of hydrocephalus and into the subarachnoid and subdural spaces in the external type. Six strands are used and their ends brought out through the temporal muscle and temporal fascia beneath the scalp in a stellate manner. This method has given better results than any of the operations yet devised.

Epilepsy.—Many cases of epilepsy are of surgical significance from an etiologic, pathologic, or therapeutic standpoint. The *prophylaxis* of epilepsy is one of the important functions of eugenics. It is of greater social than surgical consequence. Most epilepsy is preventable through the regulation of human propagation. The alcoholic, the syphilitic, the neurotic, and the degenerate are the progenitors of the epileptic; and the prevention of epilepsy demands the prevention and treatment of these conditions, and the regulation and inhibition of their breeding.

From the more strictly surgical standpoint, the prevention of epilepsy is to be furthered by proper surgical treatment of causative lesions. Fractures of the skull should not be left with fragments of bone pressing against the cortex of the brain. No depressed fracture should be left unelevated; it may give no immediate disturbance, but ultimately it is prone to be a factor in epilepsy. Subdural hemorrhage may not give sufficient pressure to cause alarm; the clot may be absorbed in due time; but the small residuum of fibrous tissue which marks the site from which the clot was absorbed often becomes the etiologic factor. The same of foreign bodies, relics of meningitis, abscess, etc. Therefore, in the treatment of these conditions, especially involving the cortex of the cerebrum, something more than saving the life of the patient should be had in mind; the future possibilities of epilepsy should be thought of, and such treatment applied as shall leave the least irritation. This is a reason for the removal of clots and foreign bodies. Many of the cases of epilepsy of supposed congenital origin are due to injuries sustained by the brain during difficult labor. The child recovers from the hemorrhage, later to become an epileptic. The blood in these cases should be liberated even though the compression is not sufficient to threaten life (see Intracranial Hemorrhage of the Newborn, Vol. II). It is important that these etiologic factors should be removed early because if their removal is deferred until the "epileptic habit" has become established, the seizures will continue even after the original local cause is apparently removed.

Many pathological conditions, which may be remedied by surgery, are capable of producing the irritation necessary to precipitate epileptic attacks;

and when these conditions are cured the attacks cease. Such conditions are found in every part of the body. Elongated prepuce, deep urethral disease, intestinal adhesions and obstructions, appendicitis, orificial fissures and ulcers, eye-strain, nasal disease, and other conditions producing nerve irritation are among the lesions amenable to surgery.

In all cases, the general *hygienic treatment* is important. Causes of irritation to the nervous system should be eliminated. This means not only immediate and gross causes but distant and indirect causes. Sources of peripheral irritation should be sought for especially in the sexual organs and abdomen. Errors of refraction in the eyes should be corrected. The gastrointestinal tract in many patients is a source of absorption of nerve-irritating toxins (see Nourishment, Vol. I). Regulation of the diet, which usually means simply diminution of food intake, is imperative. The discontinuance of vicious habits, such as the use of alcohol, tobacco and other narcotics, is to be demanded. In general, a hygienic mode of life should be adopted.

Diseases of the nose and its accessory sinuses should be corrected. Nasal obstructions which prevent a proper cooling of the basilar sinuses should be removed.

In a certain number of cases a definite local cause may be known to exist or its presence may be pointed to by focal symptoms. It is rarely too late for the *removal of an old traumatic cause*, even though this should have been done before the attacks began. An old depressed fracture should be treated by removal of the depressed bone. Exceptionally, it is so extensive that it should be elevated instead of removed. At the same time any scar tissue which is present should be cut away. It is often worth while in these cases to turn back the dura, and with a fine probe or knife separate any adhesions between it and the arachnoid. None of the dura should be removed. Such operations while not often curative, in old cases may be expected to ameliorate the disease. Foreign bodies and scar tissue due to old clots may be exposed either by turning down an osteoplastic flap or by removal of bone. In these cases also it is well to divide adhesions existing between dura and arachnoid. Some of the measures for preventing adhesions may be used with advantage. A piece of hernia sac or fat, introduced under the dura, to prevent the dura adhering to the pia and brain, is often effective.

Epilepsy, occurring in cases in which there is a bone defect in the skull, calls for a search for cortical irritation. The trouble in these cases will often be found in the form of subdural adhesions, due to the original lesion which made necessary the opening. These should be separated. If any gross scar tissue is present, it should be removed. The old practice of closing such openings with a silver plate, thinking that the opening was the cause of the epilepsy, never gave results. It would, indeed, be better surgery to enlarge the whole defect by removing bone from its circumference, for it is often the case that irritation has developed in connection with the edge of the bone.

It is doubtful if operation has much value in patients over forty-five years of age. If there is history or evidence of a traumatic cause, operation is to be considered. If no absolute localizing guide is present, a craniotomy may be done on the right side, anterior to the motor area.

It should be laid down as a rule that upon the first appearance of epilepsy of traumatic origin the region of the traumatism or focus of the symptoms should be exposed; and that, although the correction of the local conditions may not effect a cure, it may be expected to ameliorate the symptoms in the reduction of the frequency and severity of the attacks.

There are local *causes of spontaneous origin* which can often be removed. Tumor as a cause of epilepsy is well known (see Tumors of the Brain and Meninges, page 75). The adhesions following meningitis or spontaneous hemorrhage should be treated by separating them. Sometimes these adhesions are very delicate, requiring only that the dura shall be turned back as a flap and the fine adhesions to its under surface broken with a probe. Such operations often give surprisingly good results.

The cases which are most amenable to surgical treatment are those of distinctly *focal epilepsy*. Here the peripheral symptoms call attention to the cortical focus of disturbance, which may be exposed with anatomic exactness. Whatever lesion is found should be dealt with accordingly; depression, scar mass, foreign body or tumor removed, and subdural adhesions divided. A scar involving the cortical substance should be regarded as a tumor and removed. The appearance of focal symptoms should call for immediate exploration of the focus indicated. In spontaneous cases a tumor may be found. These are the cases in which tumor of the brain is most successfully treated.

In a certain proportion of these focal cases, when the cortical area indicated is exposed, no visible lesion can be found. If such a patient has had the benefit of general hygienic treatment without avail, if there are no evidences of deeper disease, and if the epileptic seizures are distinctly referable to the functions controlled by the exposed area, the surgeon may excise that portion of the cortex indicated by the aura of the disease. This operation requires exact anatomic knowledge, which should be corroborated, if possible, by electric tests (see Cerebral Localization, page 43).

Some cases of epilepsy, due to a local cortical lesion, do not give focal symptoms; some cases with focal aura have no discoverable focal lesion; and many cases present neither focal aura or lesion. Much can often be done by way of *general surgical treatment of non-focal cases.*

Epilepsy associated with persistent or enlarged *thymus* calls for excision of the gland (see Thymus Gland).

Jonnesco conceived the idea of inducing a cerebral hyperemia by a bilateral removal of the *sympathetic ganglia* in the neck. The operation causes a dilatation of the cerebral vessels and was presumed to produce a better nourishment, oxidation, and elimination in the brain. The two upper ganglia require to be removed to accomplish this. Theoretically, it was believed that reflex impulses to the brain from the viscera would be cut off. The operation has received a fair trial. In less than half of the cases, no improvement has been secured. In the others the results have not been sufficiently encouraging to warrant an acceptance of the operation as a therapeutic measure (see Cervical Sympathectomy, Vol. I, page 898).

Kocher has advocated *decompression* for the treatment of epilepsy of unknown origin and pathology. By giving the brain more room, or by its relief of pressure when abnormal hyperemia occurs, or for some other reason, this operation has seemed to benefit a small percentage of patients. The operation may be bilateral or unilateral. It should preferably be a temporal decompression, preserving the muscle (see Temporal Craniotomy, page 36).

The *curative effects of operations per se*, through psychic effect or other agencies, are undoubtedly factors in the results secured in operations for epilepsy. Thus the decompression itself or the operation *per se*, may be a factor in the cure in the cases in which good results are secured where no lesion is found. Operations remote from the nervous centers are often followed by cure or marked improvement if the psychic influence is sufficient. Operations on the genital organs, or any other operation which is done un-

der general anesthesia and with the impressions of gravity, may cure epilepsy as effectively as a trephining which discovers nothing, or, indeed, as effectively sometimes as trephining which actually discovers a lesion. The turning down of a large osteoplastic skull flap has often cured epilepsy when no definite lesion was found. It may also be said that amputations of the arm and operations on the leg have been followed by equally good results in some cases.

The *internal treatment* of epilepsy has for many years rested upon the use of bromids. The bromids of sodium, potassium, ammonium, and strontium are given to the point of toleration. They have decided value in lessening the susceptibility of the nervous mechanism to reflex excitability; and their administration tends to diminish the frequency of attacks. When, by disturbing the digestion or other functions, they interfere with the general health, then their use becomes detrimental. The benefit of operations sometimes rests upon the fact that medication is stopped and a better general hygiene is secured. It is well recognized that constipation, excessive proteid diet, and intestinal infections must be remedied before a cure can be hoped for.

Traumatic Psychoses and Insanity.—*Early disturbances* of the mental state, due to concussion, contusion, laceration, or compression of the brain, should be treated by the measures recommended for these several conditions. *Primary traumatic insanity*, due to one or more of these conditions, may continue for several weeks and subside, without developing any indications for operation. Restraint by force may at times be necessary. Operation for compression sometimes reveals only edema or serum to account for it.

Residual disturbances are the later manifestations which develop out of the early disturbances or appear *de novo* as *posttraumatic neuroses*. Prophylaxis is the main thing in these cases. Their prevention is based upon the same grounds as that of epilepsy, just as their causation is similar (see Epilepsy, page 99). It cannot be too strongly impressed upon the surgeon that the immediate recovery in brain injuries is not all. With rest and time, nature may put the patient on his feet and send him back to work, but later disturbances may develop from some condition which might have been corrected primarily, but which defies later treatment. It is imperative that the brain and meninges should be left in as nearly a normal condition as possible. If traumatism has caused any change of anatomic relations which nature will not correct, it should be corrected by art. A patient may recover apparently from the effects of compression from fracture, clot, or serum, but he stands less chance of developing later traumatic psychoses if the compression is relieved at once, as soon after the injury as its symptoms can be discovered. Wounds of the dura should be nicely closed so as to give the least amount of subdural scar. The whole treatment of intracranial injuries should be conducted with the view of minimizing connective tissue and scar formation.

There is less liability to later disease if cases with pressure symptoms are trephined than there is if they are allowed to recover without operation. This is not only true when the compression is due to hemorrhage or bone depression which can be localized, but it also applies to fracture and contusion cases in which there are but vague general symptoms of compression.

Many fractures of the base develop compression symptoms. They will usually subside, but in the interest of the patient's later welfare, it is best to make a trephine opening to drain the bloody serum from the base. Such an opening should be placed to drain the fossa through which the fracture passes. This means a low operation in the temporal fossa for the middle fossa of the

skull; a subtentorial operation through the occipital bone for the posterior fossa; or, more rarely, an opening through the frontal bone in the temporal fossa just above the level of the roof of the orbit for drainage of the anterior fossa of the skull. The operation may be unilateral or bilateral, depending upon the needs of the case.

If the location of the fracture is not known and there are no localizing signs, a low temporal opening on the right side should be made. No cause of compression being found, a subtentorial operation on the left side may follow. In these operations, a button of bone should be removed, the dura picked up, and a small opening made, through which the serous fluid may drain. If free subdural fluid is not found, the opening in the dura may be enlarged, sufficiently to give a view of the arachnoid, which should be punctured in several places if edema is present. And, whether there is fracture or not, compression symptoms due to edema or amicrobic serous meningitis are best treated by trephining and drainage. A low temporal opening can do no harm, and it may do much good.

Patients who have fully developed neuroses or insanity as a result of these unrelieved traumatic conditions, are objects for pity more than for surgery. If there is any discoverable clue to a lesion, exploration should be made, and any operable lesion that is found dealt with the same as in epilepsy (page 99). The hope of relief in these later cases is even poorer than it is in epilepsy.

It should be borne in mind that insanity often follows some slight traumatism to the brain, not because of any gross injury but because the patient had inherited an unstable mental organism already predisposed to insanity. Such cases are not surgical.

What cases of insanity shall be operated upon? J. C. Da Costa said that operation should be undertaken in cases in which insanity has soon followed an injury to the head, if the location of the injury is indicated by a scar, local tenderness, localized headache, depression of bone, or other localizing symptoms. Operation should be done in cases in which the insanity has come on later, but in which the period between the injury and the insanity has been characterized by the development of a change in the patient's disposition, by headache, irritability, insomnia, outbreaks of passion, moodishness, loss of memory, immoral excesses, alcoholism, carelessness of person, neglect of business or family obligations, or epilepsy. "One should not operate upon a case simply because there is a dubious record of an antecedent fall or blow, which merely suggests the possibility of a traumatic origin for the insanity. In any case in which there are positive signs of increased pressure, it may be considered proper to trephine as a palliative measure."

Congenital Imbecility, Idiocy, and Insanity.—These conditions, due to developmental defects, are not amenable to surgical treatment. It was once thought that microcephalic idiocy was due to premature ossification of the skull, and that linear craniotomy, to permit the brain to expand, would be of service. The operation is of no value. The rational treatment of these conditions rests upon the application of the principles of eugenics. The unborn should be given the benefits of prophylaxis, and the born idiots the benefit of educational training.

Traumatic Neurasthenia and Traumatic Hysteria.—The treatment of these conditions should begin with prophylaxis. Persons who have sustained injuries which are associated with psychic or physical shock should be assured of recovery, and reassured. They should be given a hopeful outlook. After the psychosis has developed, treatment is a matter of hygiene. Any

functional derangements which can be discovered should be corrected. A good state of mind and body should be secured. The patient should be made to live under the most hygienic conditions possible. Work, to occupy the mind and body, is most important.

Surgery of the Insane.—These are certain peculiarities in the treatment of surgical diseases of the insane. Treatment is often difficult because of the failure of coöperation on the part of the patient. The character of the diseases to be treated is often unusual. Peculiar injuries made in an unusual manner, extraordinary cases of foreign body in unusual places, self-mutilations, accidental wounds, and suicidal attempts are often such as the surgeon is not accustomed to treat among the sane.

Because of the restlessness of most lunatics, the fastening of dressings upon wounds and fractures must be made with extraordinary security. Physical restraint is often necessary to keep the patient quiet or to prevent him from removing the dressings. The temperature in insanity is often subnormal, and a normal temperature or a slight rise of temperature may signify infection. Infection should be suspected and wounds examined for it upon the evidence of a much lower temperature than would indicate infection in the sane.

The insane are especially liable to fractures, particularly of the ribs, because the bones are unusually fragile and accidents more common. The prevention of these injuries is important. Patients who are apt to injure themselves should be watched and protected. Beds with sides, to prevent their falling out, or a mattress on the floor, should be provided.

Ulcers and abscesses are common, and should be prevented by cleanliness. Hematoma of the ear is best treated by cold applications, if seen early, to check the bleeding; then, by painting the skin with collodion, protection and slight pressure are secured. If the hematoma becomes infected it should be incised. If the clot becomes fluid, it may be aspirated. Whatever treatment is applied, the ear should be separated from the scalp by layers of gauze, and well enveloped in cotton to prevent further traumatism.

Gall-stones, cholecystitis, appendicitis, and hernia should receive the same treatment which they do among the sane, excepting that operation is more urgently called for because of the lesser certainty in the recognition of grave symptoms. Hernia is always a menace, and should be operated upon whenever practicable. In many cases extraordinary precautions are necessary to prevent infection. For this purpose, a plaster-of-Paris spica may be put on over the dressing, and, if necessary sealed against soiling by the use of rubber tissue and collodion.

Operations for delusions have been done to remove the locus of an imaginary ill; but these operations are not curative because the mind is diseased and the operation only results in shifting the delusion to some other part. When hallucinations originate in some part of the cortex, the function of which is known, and the seat of origin can be identified, it is possible that surgery may be of service in excising this particular area. The matter has not yet passed beyond the realm of theory.

Pelvic disease, especially affecting the ovaries, is common among insane women. These diseases are often contributory causes of the insanity. Operation should positively be done for those conditions which are amenable to operation. The cure of pelvic diseases or the removal of the diseased organ is followed by an amelioration or cure of the insanity in a gratifying proportion of cases.

Catatonic dementia precox seems to have some connection with the internal glandular secretions. A curative or ameliorative effect is sometimes

secured by partial thyroidectomy if the operation is done in the early stages of the disease. In the later stages, operation is of no benefit.

Surgery of the Neurotic and Neurasthenic.—The principles of surgery which are applicable to the insane apply also to the neurotic. In gynecological cases especially, prolonged and repeated treatments are most objectionable. Minor treatments, applied for a prolonged period, may be expected to aggravate and fix the neurotic condition. Radical operations which are destined to be followed by depression are to be deprecated, and should be done only when the indications are well defined. When the question of operative treatment of a neurasthenic person is under consideration, surgery should be avoided if possible. Operation should not be attempted, as in epilepsy, with the hope that the operation *per se* may have a helpful effect, for want of something better to do. No operation should be done on a neurasthenic unless the indications for operation are so clearly defined that, operation would be indicated were the patient perfectly free of neurasthenia. If operation is undertaken, the hope that it will cure the neurasthenia should not be entertained.

Intracranial Operations upon the Fifth Nerve (Trigeminal)

The roots of the trigeminal nerve and the Gasserian ganglion require operation for neuralgia and tumor. Intracranial operation for trigeminal neuralgia is called for in the major form of trifacial tic involving more than one of the divisions (see Trifacial Neuralgia, Vol. I, page 865). These patients come to operation after having suffered much pain and treatment. They have usually had divisions of the peripheral branches, alcohol injections, internal medication, and local treatments. Often their general health is much impaired by pain, loss of rest, and morphine addiction. It is clear in these cases that the disease is a central one, and partial division of the sensory root is the least that will be of service. The Gasserian ganglion is the anatomic key to the situation (see Neuralgia of Trifacial Nerve).

Anatomy.—A perfect familiarity with the anatomy of the parts is essential. The fifth nerve is made up of a sensory and motor root which come forward from the basilar ganglia, and pierce the dura mater. The larger root (sensory) arises chiefly from the medulla, and has upon it the Gasserian ganglion. This ganglion lies in a hollow on the apex of the petrous portion of the temporal bone. On its inner side is the cavernous sinus embracing in its wall the oculomotor, trochlearis, and abducens nerves. The latter lies close to the ganglion. The ganglion is a reddish-gray enlargement situated at the trifurcation of the sensory root, and is enclosed in a sheath of dura mater, which must be incised to expose the ganglion. It measures about 2 cm. by 1 cm. and is crescentic in shape. Two vessels supply it; a branch of the middle meningeal and a branch of the internal carotid, both entering the under surface. These vessels are encountered in the effort to dislodge the ganglion from its bed. The middle meningeal artery enters the skull through the foramen spinosum which is external to the ganglion. Usually the spinosum is behind and external to the ovale, although it may lie anterior to it. The important point is that, to approach the ganglion, the artery must be ligated and divided. The motor root passes beneath the ganglion without having any connection with it. From the front of the ganglion the three divisions proceed; the ophthalmic, through the sphenoidal fissure; the superior maxillary, through the foramen rotundum; and the inferior maxillary, through the foramen ovale. The first two have only sensory fibers, the third division receives also the fibers from the motor root.

The disease usually involves the second and third divisions. When the first division is not involved, there is no advantage in dividing the filaments which constitute it; and there is a decided disadvantage, because paralysis of sensation of the conjunctiva usually means keratitis and possibly loss of vision.

No surgeon should attempt intracranial operations upon this nerve without having practised the operation on the cadaver. Even then the difficulties arising from hemorrhage cannot be appreciated. A study of the base of the skull and of the relations of the basilar foramina to the external landmarks is essential.

Craniotomy for Exposure of the Gasserian Ganglion.—Many methods of approach to the Gasserian ganglion have been devised. No single one has been adopted to the exclusion of others. The approach should give adequate room, should not expose the brain to undue traumatism, should not injure important structures, and should be capable of restoration of the parts to a nearly natural condition. It is a decided disadvantage to divide the temporal branch of the temporofacial division of the facial nerve, which supplies the orbicularis palpebrarum muscle. In all operations the brain is exposed by a temporal craniotomy (see page 26).

High temporal craniotomy is carried out through a horseshoe-shaped incision through the scalp and pericranium. It begins just behind the external angular process of the frontal bone and ends above the tragus of the ear. The base of this flap corresponds to the upper border of the zygoma; and the upper margin reaches the height of the temporal ridge which marks the upper border of the temporal fossa. The bone is divided along the line of the scalp incision and the bone-scalp flap turned down. As the bone breaks across the base of the flap, the middle meningeal artery may be torn, and require ligation at once. The zygoma need not be divided. This is the approach of the now little used Hartley-Krause operation.

Low temporal craniotomy is done as follows: The incision is the shape of a horseshoe. It begins just behind the frontal process of the malar bone and terminates at the zygoma a finger's breadth in front of the ear. The summit should be about 1 cm. below the temporal ridge. The scalp, muscle, and periosteum are divided in the line of the incision, and the zygoma is divided at the two termini. The flap of soft parts is dissected free from the great wing of the sphenoid as far down as the pterygoid ridge and from the temporal bone. The periosteum should be included in this flap. The flap is retracted downward and the zygoma depressed. Cushing removed the zygoma. A trephine opening is then made in the skull midway between the external auditory meatus and the external angular process of the temporal bone. This is then enlarged in all directions. The upper margin of the opening need not pass the grove of the middle meningeal artery at the anterior-inferior angle of the parietal bone. Below, the opening should be carried nearly to the foramen ovale. The middle meningeal artery may be ligated or not, as seems best. By cutting away the base of the skull toward the foramina ovale and rotundum, the opening through the temporal fossa need not be more than 4 cm. high (see Craniotomy).

Auriculotemporal craniotomy approaches the ganglion posteriorly. It is adapted for access to the sensory root. A horseshoe-shaped incision is made, beginning at the middle of the zygoma, passing up to within 1 cm. of the temporal ridge, and ending posteriorly behind and a little below the summit of the auricle. The flap of scalp, muscle and periosteum is turned down over the ear. The skull is opened with a trephine, and the opening enlarged to within 0.5 or 1 cm. of the scalp wound. The enlargement of the opening is extended downward as far as the infratemporal crest. This is the route of Frazier.

Subtemporal craniotomy may be done through a right-angle incision with the apex downward. It avoids the temporofacial branch of the facial nerve. It is begun about 1 cm. behind the frontal process of the malar bone, passes downward and backward to the condyle of the inferior maxilla, and thence at a right angle upward and backward a short distance in front of the ear. This is the incision used by T. Kocher. The terminal branches of the temporal artery should be ligated. The temporal fascia is cut at its attachment to the upper border of the zygoma, and the zygoma is divided

at either end and retracted downward. The skin flap is dissected up, and the temporal fossa exposed by splitting the muscle and strongly separating its fibers. The skull is trephined low down, and the opening enlarged almost to the foramina ovale and rotundum. The opening is carried upward for 3 or 4 cm. In performing this operation the preliminary flap of soft tissues may be made rounded instead of angular.

The **intracranial operation** varies with the craniotomy of approach and the methods of the surgeon. The operation has passed through many stages. Many procedures have been followed: (1) Division of the affected branches distal to the ganglion; (2) division of the branches and avulsion of the ganglion; (3) division of the branches and root and removal of the ganglion; (4) division of the sensory root and avulsion of the ganglion and branches; (5) avulsion of the ganglion, root and branches; (6) division of the sensory root; and (7) splitting the ganglion and removing only the portion connected with the second and third branches—these are some of the operations which have been done. The operations now in use are: (*a*) division of the sensory root; (*b*) total extraction of the ganglion if the ophthalmic is involved; (*c*) extraction of the part of the ganglion connected with the second and third divisions if the ophthalmic is not involved; and (*d*) simple division of the second and third divisions, if the ophthalmic is not involved, and the interposition of some foreign substance to prevent their union. An important discovery is that, when the sensory root is divided, it does not reunite.

Fig. 756.—Blunt Hook Used in Operations on Nerve Roots.

This hook serves to pass ligature around the middle meningeal artery and to catch the nerve and draw it out.

The skull opening having been made and the dura mater exposed, the latter should be separated from the base of the skull by the handle of a scalpel and lifted up on a thin flat retractor. This should gently lift up the dura and brain as far inward as the foramen spinosum, and bring into view the middle meningeal artery as it enters the skull. A ligature upon a small carrier should be passed around the vessel, tied close to the foramen, and the artery divided. Most surgeons do this. The dura is then incised just internal to this, directly above the foramen ovale. The inferior maxillary division is the guide to the ganglion.

To divide the sensory root, the dura is carefully dissected from the superior surface of the ganglion backward and inward. The sensory root may now be caught on a blunt hook (Fig. 756), and divided, or avulsed as suggested by Spiller and first practised by Frazier. If any of its fibres are not cut, pain may continue. This simple division of the sensory root is a less bloody operation than removal of the ganglion; there is the least danger of injury to important structures; and rarely the motor root may be preserved, and the subsequent disturbances of the muscles of mastication prevented. Sensory paralysis of all three divisions follows complete division of the sensory root. If it can be identified, the motor root should be avoided. Exposure of the sensory root is best accomplished by auriculotemporal craniotomy (Fig. 757). This is the *Spiller-Frazier* method.

To remove the ganglion, after raising the dura and brain, the third and second divisions as they enter their foramina are exposed and followed backward to the ganglion; the dura is split to expose the ganglion; the latter is

isolated, grasped with forceps, the divisions cut with scissors, and the ganglion rotated and avulsed, bringing with it the sensory and motor roots. This is the *Hartley-Krause* method, which approaches by the high temporal route.

To remove part of the ganglion, the third and second divisions should be well exposed, and the dura detached until the ganglion is freed from its bed; the two exposed divisions are then cut across just above the foramina; the ganglion is grasped with forceps, and the part connected with the two cut divisions is removed, while the part connected with the ophthalmic division is left.

Special modifications of these procedures have been made by many surgeons. It is conceded that the best approach is secured by ligation of the middle meningeal artery. In the low temporal and subtemporal operations, temporary resection of the zygoma is called for, and gives decidedly more room. Both Cushing and Lexer advised total extirpation of the ganglion. Horsley approached by the low temporal method, exposed the ganglion, divided the third and second divisions, detached the first division, and

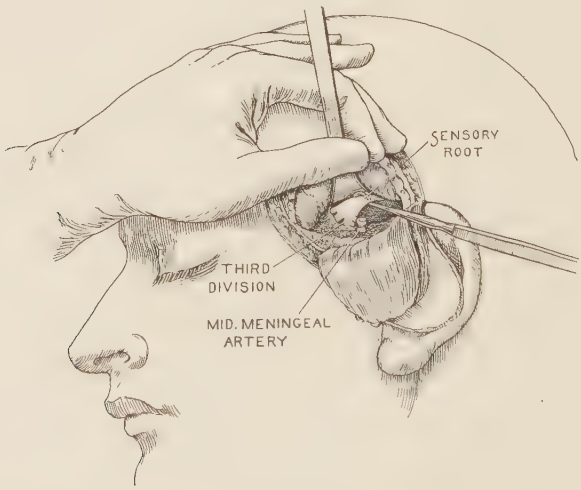

Fig. 757.—Operation on Sensory Root of Trifacial Nerve.
The third division and the posterior aspect of the ganglion have been exposed. The hook has been passed around the sensory root.

avulsed the ganglion with its roots. Abbè cut the affected divisions, prevented their regeneration by interposing rubber tissue, and left the ganglion intact. He has been able to secure sufficient exposure for this operation through a vertical incision. Kocher slowly avulsed the sensory root and left the ganglion.

Operation in two stages sometimes becomes necessary when bleeding is persistent and controlled with difficulty, or when the patient becomes intolerant to further operation. Under such circumstances the immediate conditions are met and the wound temporarily closed. Tampons should not press so firmly as to give compression symptoms. After a few days, when hemorrhage is controlled and the patient's condition permits, the wound may be reopened and the operation concluded.

The *position of the patient* is worthy of consideration. A table should be used which will permit longitudinal tilting so that the head may be elevated at any time. Von Bergmann advocated operation in a nearly vertical

position, and many surgeons now operate with the patient in that position. A special operating chair with a head rest has been made for the purpose. The advantage of the elevated head position is that hemorrhage is less. At the same time, any posture which minimizes venous engorgement renders anemia of the cardiac and respiratory centers more liable. The surgeon is between two dangers. Greater skill on the part of the anesthetist is required in the upright position. Upon the appearance of the signs of anemia of the vital centers the head must be lowered.

The *control of hemorrhage* is first facilitated by ligation of the middle meningeal artery. Bleeding from the scalp and skull have been discussed elsewhere. The annoying hemorrhage which interferes with a view of the nerve is from the small veins passing between the dura and the skull. Bleeding from these is best controlled by pressure applied at the bleeding point with a small piece of gauze. This may often be held in place with a spatula-retractor. Adrenalin gauze has been used for that purpose. Pressure for a few minutes will usually suffice. It is much better to give attention to each bleeding place and attempt to control it by pressure than to attempt gross sponging out of the blood while the operation proceeds between times. By making pressure with minute sponges in one place, the operation may proceed in another. Wounds of the venous sinuses are still more troublesome; but a properly applied piece of gauze, held in place by a flat retractor, will be found best. In closing the wound these pieces of gauze should not be neglected. The patient's blood-pressure should be recorded before the operation, and accurately kept track of during the operation.

The *operation of choice* must vary with the conditions to be met and the surgeon's individual preferences. At present surgeons are not performing typical or routine operations. The procedure must be modified to suit the peculiar conditions present. In general, there are certain things of advantage: (1) The surgeon's first operation should not be upon a living patient; or, if it is, he should have assisted in the operation many times. (2) Hemostasis by means of the scalp tourniquet will save blood. (3) A skillful anesthetist is necessary. (4) The low temporal, subtemporal and temporoauricular routes of approach are the best. (5) In the first two, it is of advantage to continue the bone opening nearly to the foramen ovale. (6) Division or avulsion of the sensory root is the operation of choice—it is a less bloody operation, and in all respects more easy and less hazardous than removal of the Gasserian ganglion. Removal of the ganglion is a difficult and dangerous procedure. Kocher, following Spiller's suggestion, avulses the sensory root, and has not had a case of recurrence of neuralgia in his experience. (7) The dangers of the operation inhere in hemorrhage and traumatism to the brain. With care both of these may be confined within the limits of safety. This is an operation in which haste can not be made. The brain need not be elevated more than 1 or 1.5 cm. from the base of the skull. Artificial illumination may be used, if necessary, to throw light into the wound. (8) Some oozing will usually make it advisable to close the wound with drainage, leaving sufficient tampon for hemostasis. After division of the sensory root the field of operation is anesthetic, and no further anesthesia is required (see Operations on the Scalp, page 19). Operations on the Skull, page 26; Brain Topography, page 43; Injuries of the Venous Sinuses, page 54; and Intracranial Operations, page 30).

Mortality from the operation varies with the skill of the surgeon. The mortality from the old operation for removal of the Gasserian ganglion was high. Perfection of the technic has removed much of the hazard. The modern operation upon the sensory root gives a low mortality. Frazier

collected the statistics from his own clinic, and from those of Lexer, Horsley, Döllinger, and Cushing, and found the mortality to be 3.7 per cent. Among his own cases there was a mortality of 3 per cent. Loss of blood, traumatism to the brain, and depression from the anesthetic are the chief causes of immediate death; and infection is the chief cause of later death. All of these dangers are preventable, and scarcely play a rôle in the work of the well-equipped surgeon.

Results in these operations are improving as the technic improves. Following attempts at extirpation of the ganglion there has been not a small percentage of recurrences; but division or avulsion of the sensory root gives an assurance of permanent sensory paralysis and cure of the neuralgia. Following the older operations for removal of the ganglion, complications such as restlessness, headache, dizziness, and motor paralyses occurred; but these now rarely follow operations on the sensory root.

Keratitis is very apt to occur if to the sensory paralysis of the cornea there is added an inability to close the eye on account of division of the temporal branch of the facial nerve. Trophic disturbances also, perhaps, play a rôle. To prevent disease of the cornea, the eye should be protected from the entrance of dust by being covered with a shield having a glass window. In extirpation of the whole ganglion, besides paralysis of the ophthalmic branch, there is always danger of injury to the third, fourth, and sixth nerves in the wall of the cavernous sinus adjacent to the ganglion. This is another strong reason in favor of splitting the ganglion and leaving the part attached to the first division when it is not neuralgic.

Intracranial Operations on the Auditory Nerve

Operations upon this nerve are done for tinnitus, otalgia, acoustic vertigo and tumor. It is distributed exclusively to the inner ear. It passes from the

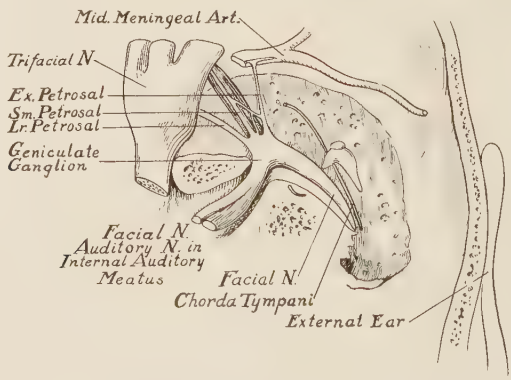

Fig. 758.—Showing Relations of Seventh Nerve in Temporal Bone.
The nerves have been uncovered by removing the roof of the petrous portion within the skull.

lower border of the pons forward in company with the facial nerve, with which it enters the internal auditory meatus. It is soft in texture, destitute of neurolemma and distinguished from the facial which is firm. It lies external to the facial. It is larger than the facial, somewhat flattened and grooved to envelop it (Fig. 758). Within the meatus it receives one or two filaments from the facial. The nerve is recognized in the wound by its glistening white appearance. Directly posterior and below the internal

auditory meatus is the posterior lacerated foramen, transmitting the inferior petrosal sinus, the lateral sinus, and the glossopharyngeal, pneumogastric and spinal accessory nerves. These come into view in the operation. The root of the trifacial passes just internal to the auditory. The positions of the lateral sinus and the jugular foramen should be fixed in the mind (see Craniocerebral Topography).

The skull is opened by the suboccipital route (see Suboccipital Craniotomy, page 36). The unilateral operation suffices in most cases. The bilateral operation is called for in operating for tumor. Frazier performed the operation under intratracheal insufflation anesthesia with the patient in the prone position, the forehead resting on a special support.

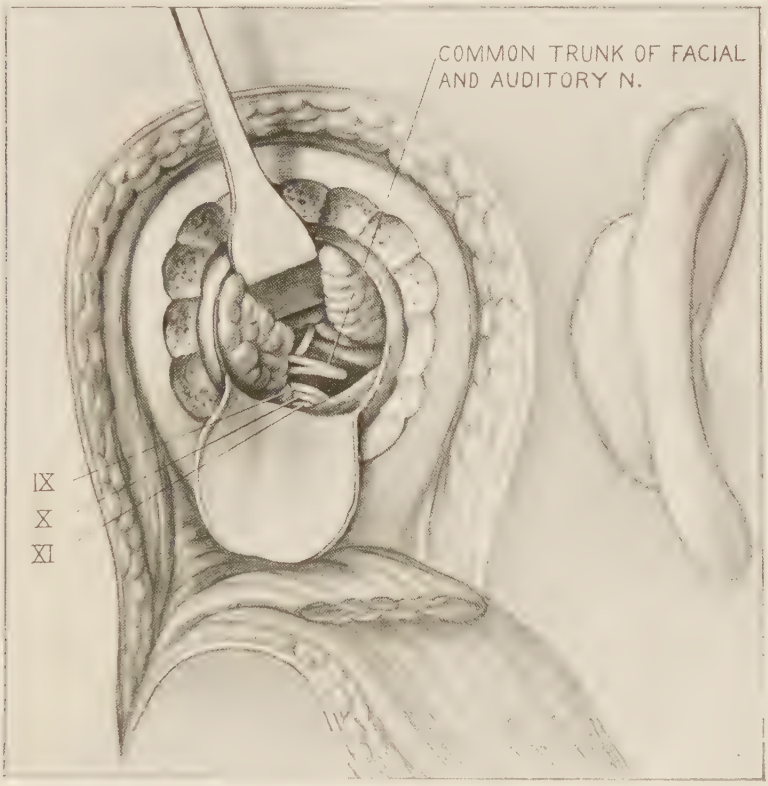

Fig. 759.—Exposure of Seventh Nerve by Suboccipital Craniotomy.

The cerebellum is retracted. The facial and auditory nerves are exposed at the internal auditory meatus. The facial is the upper of the two in this picture. *IX*, Glossopharyngeal; *X*, pneumogastric; *XI*, spinal accessory. These three latter nerves are about to enter the jugular foramen.

After cutting away the bone sufficiently, the dura is incised a short distance from the bone edge and turned down as a flap. The cerebellum is then lifted with a flat retractor and the auditory nerve brought into view. Much care must be exercised in this operation lest serious pressure be made upon the medulla or the cerebellum lacerated. The cerebellum should be displaced backward, making use of the skull opening to give room for its displacement. By no means should attempts be made to press the brain in-

ward. Some venous bleeding will occur as the brain is separated from the region of the petrous portion. This is controlled by gauze pressure. The surgeon should think of approaching the nerve laterally rather than from behind. Good artificial illumination is necessary. Retraction, giving an opening 1 cm. in height, should suffice to expose the nerve (Figs. 759 and 760).

In operating for **tinnitus** or **acoustic vertigo,** the nerve must be divided. The facial should be protected and preserved. Retracting the cerebellum should expose the two nerves as they are put on the stretch. The facial

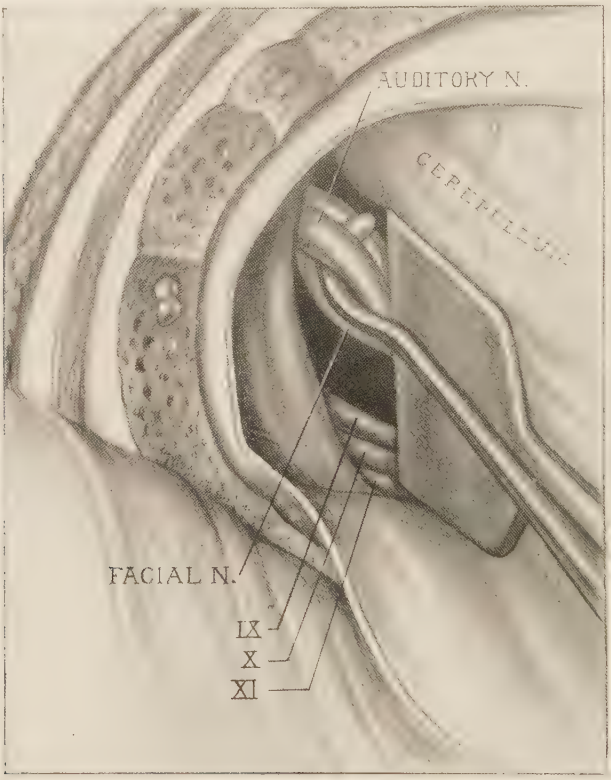

Fig. 760.—Exposure of Seventh Nerve by Suboccipital Craniotomy. The auditory nerve (8th) has been caught on the blunt hook and is separated from the facial nerve (7th).

and auditory nerves may be separated by blunt dissection. The blunt hook is useful for this purpose. This should be done patiently and deliberately. No strands of the auditory should be left clinging to the facial. The nerve having been isolated, it is grasped with forceps and avulsed. Any remaining fibers may cause a continuation of the symptoms for which the operation was done. The facial nerve should be identified by applying an electrode to it. The operation is done upon patients who already have serious impairment or loss of hearing. Labyrinthine disease calls for the operation; in tinnitus or vertigo of central origin, the operation would be of no avail. Lesions of the cochlear ganglion or vestibular ganglion create the indications. Vertigo is relieved by removal of the semicircular canals, but this operation does

not affect the tinnitus. In cases in which the vertigo is not associated with tinnitus, removal of the semicircular canals is the operation of choice. This is a much less formidable operation.

This nerve has been approached by the temporal route and by the masto-occipital route. None of the operations have succeeded wholly in relieving the symptoms. Patients should be warned of the possibility of facial paralysis. The mortality has been high. Complete deafness results. Only the extreme cases should be operated upon by this method.

A certain number of cases of aural vertigo, even with tinnitus, are cured by destroying the vestibule and semicircular canals. Therefore, upon the basis of present information, the operation on the ear should be tried first.

The removal of *tumors of the auditory nerve* is accomplished through the same route. The bilateral operation is necessary to give the requisite displacement of the cerebellum. If the tumor has reached a size to cause internal hydrocephalus, the increased intracranial pressure may be largely due to the hydrocephalus, which may require to be relieved by tapping before the occipital operation is done. Neurofibroma of the nerve should be recognized early and removed. In the case of large tumors an operation in two stages may be done.

Usually after these operations there will be considerable bloody oozing. Gauze or wick drainage should be provided for one or two days. The drainage should be dispensed with as soon as the bleeding has ceased. The sooner it can be removed the less is the danger of a continuous discharge of cerebrospinal fluid.

Operation by the mastoid route in two stages is as follows: The incision begins just below the tip of the mastoid process on the affected side. It passes upward and slightly backward to the level of the upper border of the external auditory meatus, thence curves backward above the external occipital protuberance and downward, just to the sound side of the median line to end at the spine of the second cervical vertebra. The bleeding is checked and the skin-flap thus outlined is dissected free and turned downward. The incision is then deepened and the flap of fascia, muscle, and periosteum is turned down. All bleeding should be checked. Bleeding from foramina in the bone should be checked by plugging them with wax or a wooden pin.

The occipital bone is opened where it is thin just below the superior curved line. A burr or gouge quickly makes an opening here and exposes the dura. About this opening the dura is separated and the bone is removed with bone-cutting forceps. As the separation of the dura proceeds, the bone is cut away until much of the exposed area of the occipital and temporal bones is removed. The bone is removed to a point just beyond the occipital sinus in the median line, above until the lateral sinus is exposed, anteriorly along the sigmoid sinus, and downward nearly to the margin of the foramen magnum. It is not necessary to open into the foramen. The lateral and sigmoid sinuses are so intimately connected to the bone that some force and much care are necessary in separating them from their beds. The dura having been freely exposed and all bleeding checked, the soft parts are replaced, sutured back into position, and the wound dressed.

At the end of a week, the sutures are removed, and the flap of soft tissue is again turned down. A large flap of dura is turned down, the margins of which lie just within the area bounded by the occipital, lateral and sigmoid sinuses. The base of the flap is downward. This step should be carried out with care to prevent hemorrhage, and unnecessary wounding of vessels. When all vessels have been tied, adrenalin may be applied to check oozing.

A thin flat retractor is carefully passed beneath the cerebellum, and the

brain lifted upward and inward away from the base of the skull. An electric head lamp should furnish illumination. The retraction should proceed slowly and carefully. As the cerebellum is lifted up cerebrospinal fluid rushes forth from the basilar cistern. The fluid should be sponged away, and the retraction slowly continued until the auditory nerve is seen passing forward with the facial nerve to enter the meatus auditorius internus in the petrous portion of the temporal bone. By means of faradic stimulation applied to

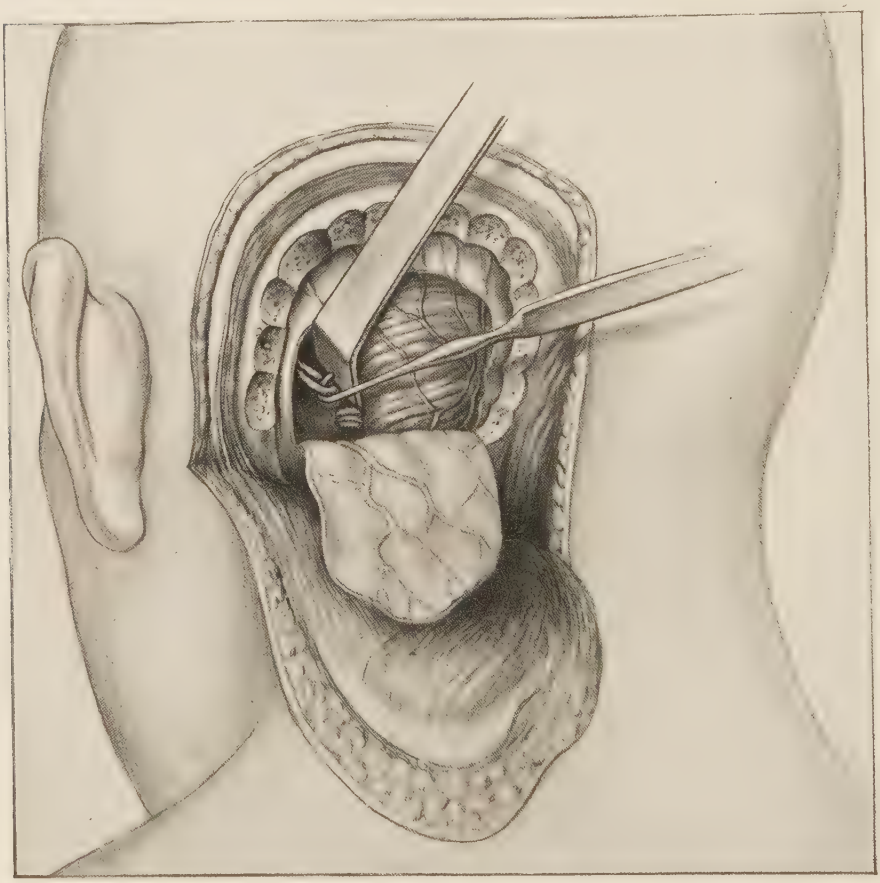

Fig. 761.—Showing Operative Field in Exposure of Seventh Nerve.

The skull has been opened by removing the bone with rongeur. The flap of dura has been turned down. The cerebellum is gently retracted. The auditory nerve is caught by the hook, separating it from the facial nerve.

the facial nerve with a long electrode that nerve may be identified and its division avoided. The auditory nerve lies external and below the facial. The auditory artery usually lies between the two. For tinnitus, the auditory alone is drawn away with a blunt hook, grasped with forceps and pulled away from its central attachment. For otalgia, both the facial and auditory are divided (Fig. 761).

The flap of dura mater should be sewed back in place. The muscle should be sewed with catgut, and the scalp with silk or silkworm-gut.

Intracranial Operations on the Facial Nerve for Facial Nerve Neuralgia

As the facial is a mixed nerve with a sensory ganglion (the geniculate ganglion), receiving sensory fibres from the root of the auditory nerve through the pars intermedia, neuralgia of the circumscribed area of its sensory distribution sometimes requires operation. The area of sensory distribution is the anterior wall of the external auditory canal and the skin just in front of the ear. The natural treatment for this neuralgia, when operation is necessary, is division of the pars intermedia.

Injuries and Diseases of the Face

Contusions of the face, for cosmetic reasons require to have their traces quickly removed. Cold followed by heat and massage gives the best results (see Contusions, Vol. I, page 218).

Wounds of the face heal most quickly because of the vigorous blood supply. Nice apposition is essential for the minimization of scar (see The Closure of Wounds, Vol. I, page 187).

Fractures of the jaws, malar bone, and zygoma have been discussed (see Fractures).

Inflammations usually heal more promptly than in other parts. When necessary to apply irritating solutions to the face, the eyes may be protected by compresses wet with boracic acid solution and covered with impervious protective. **Erysipelas, lupus,** and **tuberculosis** has been discussed under Inflammations.

Tumors come early to the surgeon because of their cosmetic importance. *Sebaceous cysts, nevi, moles,* and *epitheliomata* may be removed by the knife in their early stages, the wounds nicely closed, and good results expected (see Tumors, Vol. I, page 323).

Facial Neuralgia.—(See Trifacial Neuralgia, Vol. I, page 865; Facial Neuralgia, Vol. I, page 877.)

Facial Paralysis.—(See Facial Nerve, Vol. I, page 881; Facial Spasm, Vol. I, page 888.)

THE EYE

Anatomy.—The eyeball or globe of the eye (bulbus oculi) is situated in the anterior part of the orbital cavity (Fig. 762). It is embedded in the fatty connective tissue of the orbit, being surrounded immediately by the capsule of Ténon, a thin membrane, which allows of free movement. It has about it also the muscles of the orbit which give it motion (Fig. 763). The conjunctiva lines the back of the eyelids and is reflected upon the front of the eye. When the lids are closed the conjunctiva forms a sac (Fig. 764). The lacrimal apparatus consists of the lacrimal gland, situated at the upper and outer part of the orbit, its ducts, and the tear ducts at the inner aspect of the eyelids which carry the tears into the nose (Fig. 765).

The anterior part of the eyeball is most commonly the field of surgical operations. The most sensitive and important regions are the cornea, the iris, the ciliary body, and the crystalline lens (Fig. 766).

Treatment of Diseases of the Eye.—In the treatment of surgical diseases of the eye every care should be given to the protection of the cornea from irritation. When a dressing is required for the eyelids, compresses wet with boric acid or other non-irritating solution should be used. If discharges behind the lids are present, the lids should be separated at least once or twice a day, and the discharges, which have not escaped, should be washed away with non-irritating solution. It is a great mistake to cover with a dressing eyes from which there is much discharge, unless the dressing can be removed frequently and the eye cleansed. If there is profuse discharge, no dressing should be used unless the eye can be uncovered and cleansed hourly.

In order to expose the eyeball or conjunctiva for treatment, the upper lid must often be everted. To accomplish *eversion of the lid*, the patient should be directed to look continuously downward; the surgeon then takes between the index-finger and thumb of the left hand the central lashes of the upper lid, draws the lid downward and forward, places the tip of the thumb of the right hand on top of the lid, steadies the other fingers against the head,

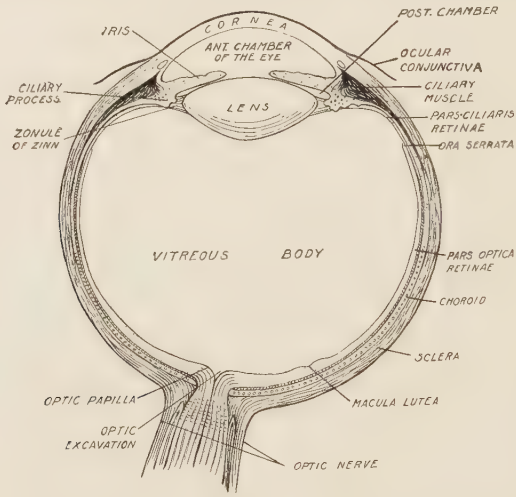

Fig. 762.—The Eyeball or Globe of the Eye (Bulbus Oculi). Horizontal section of right eyeball.

and turns the lid back over the tip of the thumb. If there are no lashes on the upper lid, the lower lid may be pushed beneath it and used to turn it back. A match or toothpick may be used instead of the thumb.

In order to *inspect the cornea* to observe the progress of treatment or to discover foreign bodies, oblique illumination is used. The patient is placed 2 feet from a light which is located to the side and somewhat anteriorly;

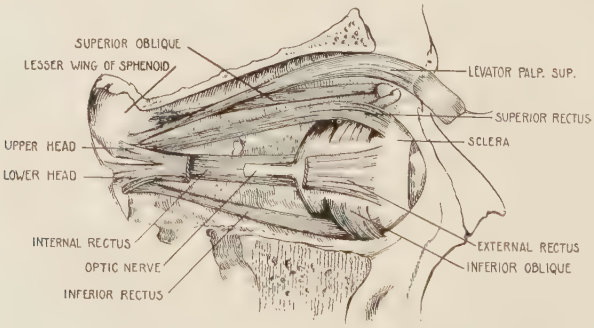

Fig. 763.—Muscles of the Eye, Right Orbit.

the surgeon sits facing the patient; with a simple 5- or 10-cm. lens, a beam of light is thrown upon the eyeball, while with the other hand a similar lens is used for magnifying the field to be inspected. Oblique illumination enables not only an inspection of the cornea but also of the anterior chamber and the crystalline lens. Strong magnifying lenses are also used for this purpose. For observing the interior of the eye, the ophthalmoscope is used.

The use of *mydriatics* (drugs which dilate the pupil) is often called for. *Atropin* has the widest range of application. It is usually employed in a strength of 0.25 Gm. (4 grains) of atropin sulphate to 30 c.c. (1 ounce) of

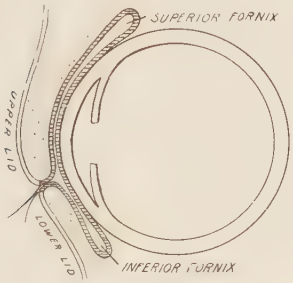

FIG. 764.—CONJUNCTIVA.
Vertical section of eye showing upper and lower fornices of conjunctival sac.

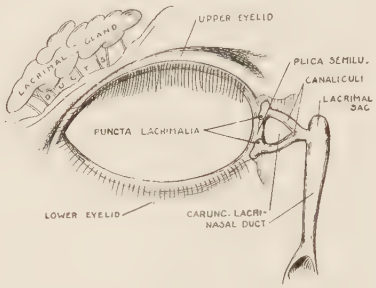

FIG. 765.—LACRIMAL APPARATUS OF RIGHT EYE. (*After Gray.*)

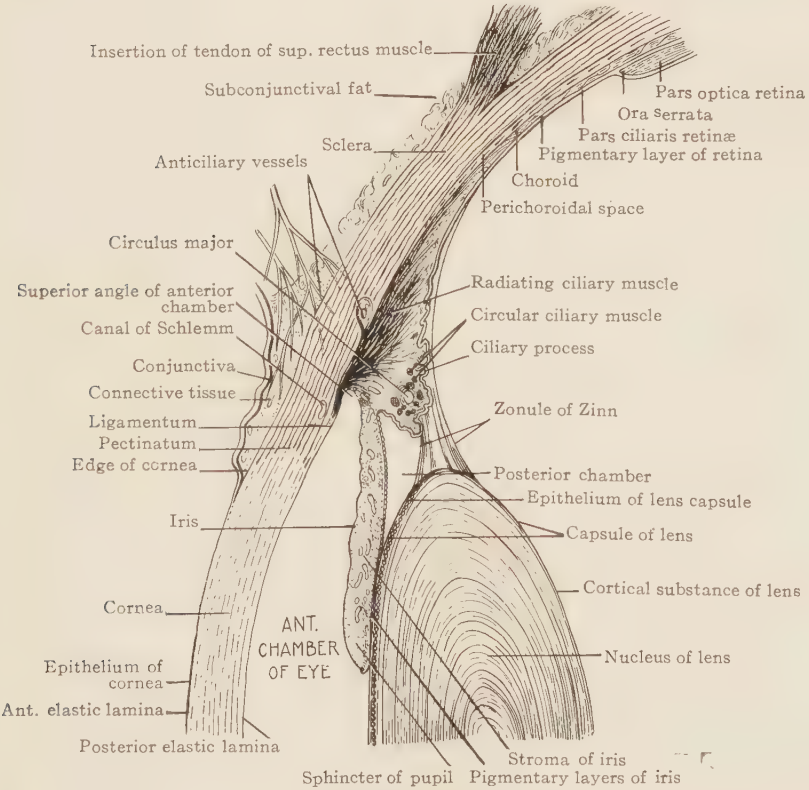

FIG. 766.—FRONT OF EYEBALL, UPPER HALF OF VERTICAL ANTEROPOSTERIOR SECTION.

sterile water. A drop of this solution on the conjunctiva dilates the pupil in about fifteen minutes; and by causing paralysis of the ciliary muscle paralyzes accommodation, which lasts for a week. The retraction outward

of the iris renders it less liable to become adherent when inflammation reaches the anterior chamber. The mydriatic places the eye in a state of physiologic rest, and diminishes the possibility of iritis. To keep the pupil dilated, it may be necessary to use the drug daily for several days. From 1 to 5 drops are used at a time. *Homatropin* produces an effect lasting about two days. A solution of 0.5 to 1 Gm. (8 to 16 grains) to 30 c.c. (1 ounce) is used—1 drop every fifteen minutes is instilled for an hour and a half, beginning two hours before the full effect is required. *Cocain hydrochlorid* (2 to 4 per cent. solution), besides its anesthetic effect upon the conjunctiva and cornea, is an excellent mydriatic. If a mydriatic produces signs of *glaucoma*, it should be neutralized at once by a myotic and discontinued.

Should atropin not be tolerated, solution of *hyoscin* (1 : 400), *scopolamin hydrobromid* (1 : 500), or *duboisin sulphate* (1 : 500 or 1 : 200) may be used.

Drugs which contract the pupil are called *miotics*. The *salicylate of physostigmin* (eserin) is used for this purpose and as an antidote to counteract the effect of atropin. It is used as eye drops in solution—0.03 to 0.25 Gm. (½ to 4 grains) to 30 c.c. (1 ounce)—several drops 3 times daily. The *hydrochlorid of pilocarpin* has a similar miotic action, and is used in a strength of 0.13 to 0.6 Gm. (2 to 10 grains) to 30 c.c. (1 ounce) of water. In chronic glaucoma the strength of the miotic solution should at first not exceed 0.03 Gm. (½ grain) to the 30 c.c. (1 ounce).

For using *cocain as an anesthetic* in eye operations, such as iridectomy and cataract extraction, a sterile 4 per cent. solution is employed. Three instillations are made at intervals of four or five minutes. After each instillation, the eye should be closed, and covered with a pad. *Holocain* in a 2 per cent. solution is used by some surgeons.

Solutions of *dionin* (peronin, ethyl-morphin hydrochloride) in strength of from 5 per cent. to saturation are used. The pure powder is also used. Applied to the conjunctiva, it possibly has some effect in dispersing lenticular opacities. It is most effective when used by subconjunctival injection. It is a valuable analgesic in the treatment of corneal ulcers, acute glaucoma, iritis, scleritis, and other inflammations of the uveal tract. It is applied to the conjunctiva in these diseases. It seems to be harmless.

The *antiseptics* are useful. Boric acid solution is most commonly employed in connection with eye work. Mercuric and silver solutions are used in more pronounced infections. After wounds of the eyeball in which some discharge is to be expected, a mercurial ointment may be placed in the conjunctival sac with advantage. It prevents adhesion of the lids and crust formation.

	Grams	
Hydrarg. iod. rub.	0.06	gr. i
Pot. iodid.	0.30	gr. v
Aquæ, *q. s.*		
Adipis lanæ	30.00	℥i
Petrolati albi, *q. s. ad.*	300.00	℥x

This ointment, Dichloramin-T (0.5 to 1 per cent.), may be dropped in the eye every hour. The smarting is temporary. A 25 per cent. solution of argyrol is useful.

The *preparation of the patient* is important. Except in emergency operations, for several days before operation the eyes should be protected from anything that might cause irritation. The patient should rest his eyes. The face and lids should be washed frequently with warm water and soap. If there is any abnormal discharge, it should be treated with a 25 per cent.

solution of argyrol or other mild antiseptic. Operation should not be done in the presence of an infective discharge. This should be determined by bacteriologic examination. Disorders of the nasopharynx should be corrected; and for a few days before the operation the nose should be cleansed with a nonirritating nasal wash. The preparation of the skin of the face has been described. Before operating, the margins of the lids should again be washed with soap and water, the conjunctival sac freely irrigated with normal salt solution, and the lacrimal sac pressed to remove any infective material. The canthi are then wiped with wet cotton. After the anesthetization and the introduction of the speculum, before inserting the knife, the cornea should again be irrigated.

The *position of the patient* should be such that a good light is had and an easy attitude for the operator secured. The patient should lie in a comfortable position with the head resting upon a fairly hard cushion or sand bag.

For most operations involving the interior of the eye, besides the instruments, the following *materials* should be at hand; cocain (4 per cent.), atropin, 0.25 Gm. (4 grains) to water, 30 c.c. (1 ounce); eserin, 0.03 Gm. (½ grain) to water, 30 c.c. (1 ounce); saturated boric acid solution; normal salt solution; bichloride of mercury (1 : 5000); sterilized gauze; gauze bandages; and absorbent cotton.

The *position of the surgeon*, if he is right-handed, for operations on the right eye, should be above the patient; for operations on the left eye, he should stand at the side of the patient.

Diseases of the Eyelids

Congenital anomalies, such as **absence of the lids, cleft eyelid,** and **cryptophthalmos** are to be treated by plastic operation (see Plastic Surgery, Vol. III). **Ankyloblepharon** (union between the margins of the lids), **symblepharon** (cohesion between the eyelid and ball), **blepharophimosis** (cohesion at the outer angle), **ptosis, ectropion,** and **entropion** are all treated the same as the acquired lesions (which see). **Epicanthus** (a fold of skin passing in front of the inner canthus from the inner end of the brow to the side of the nose), when aggravated and bilateral, is remedied by excision of an area of skin at the middle of the root of the nose and closing the wound, thus smoothing out the two folds.

Cellulitis of the lid should be treated by hot, antiseptic compresses until an **abscess** forms. This should be opened by an incision through the skin, parallel to the lid margin.

Sty (hordeolum), in its early stages, should be treated by hot fomentations. Ointment of yellow oxid of mercury, 1 part; petrolatum, 30 parts; and lanolin, 30 parts, are of service. As soon as pus collects, a free incision should be made into the bottom of the swelling parallel to the edge of the lid.

Herpes zoster of the lids, associated with derangement of the cutaneous nerve supply, tends to run an acute course and to subside in two or three weeks. It may be treated locally by weak phenol solution. The treatment of the diseased nerve is of greatest importance.

Blepharitis (inflammation of the margin of the eyelids) should call attention to the refraction of the eye, and any anomaly should be corrected by glasses. The general health should be improved. If the disease persists, a daily washing of the eyes with warm water, containing 1 per cent. of alcohol is useful. For *seborrhea* of the lid-border or squamous blepharitis, the

scales should be removed with bicarbonate of soda solution (2 per cent.) or chloral hydrate solution (5 per cent.); and an ointment of yellow oxid of mercury (1 part), petrolatum (30 parts), and adeps lanæ hydrosus (30 parts) applied once or twice daily. In chronic cases with ulceration, the loose hairs should be extracted, the ulcers touched with nitrate of silver, and the above ointment used. Boric acid ointment (10 per cent.) is also employed. Another useful ointment is salicylic acid, 1; ointment of red oxid of mercury, 3; and ointment of rosewater, 30.

Blastomycosis of the lids is commonly associated with the same lesion in the adjacent skin of the face (see Vol. I, page 838). The local application of antiseptics, such as 4 per cent. silver nitrate, to destroy the fungus is most effective. Curetting is useful in obstinate cases. Large doses of potassium or sodium iodid internally are effective. Copper sulphate internally in doses of from 0.05 Gm. (¾ grain) to 0.1 Gm. (1½ grains) daily, and externally a 1 per cent. copper sulphate wash are useful.

Tumors of the eyelid should receive the same treatment as tumors elsewhere. Benign tumors should be removed if they cause irritation. Cysts may first be punctured, and, if they return, dissected out (see Cystomata, Vol. I, page 325).

Xanthelasma, yellowish patches of connective-tissue growth with fatty tissue, are most successfully treated by excision as a tumor. They often return. The high-frequency electric current is also of value. Removal by escharotics is effective.

Chalazion (meibomian cyst) is best treated by operation (see page 138).

Blepharospasm, spasm of the orbicularis muscle, is due to irritation in the facial nerve either direct or reflex, and, in general, demands the same treatment as facial spasm (Vol. I, page 881). The correction of defects of refraction should receive attention. In children it is often a form of chorea. When the spasm is tonic, it will usually be found that some local lesion requires attention—fissure, foreign body, or conjunctivitis. Reflex irritation in the trifacial nerve may require relief.

Ptosis of the upper eyelid, if due to hypertrophy, requires excision of tissue, if due to paralysis of the oculomotor nerve or injury to the levator muscle, it requires treatment of the causative lesion. Aggravated and intractable cases are cured by operation on the lid. In congenital ptosis only operative treatment is of service; in acquired ptosis operation should be resorted to only after all other measures have failed (see Operations for Ptosis, page 138).

Lagophthalmos (an inability to close the eyelids) should be treated by remedying the cause; if this cannot be done operation is called for (see Tarsorrhaphy, page 144).

Symblepharon, ankyloblepharon, and **blepharophimosis,** may be prevented by treatment of the causative inflammations. For operative treatment see page 142.

Entropion (turning of the lid border toward the ball), when temporary or spasmodic may be corrected by everting the lid and painting the skin with collodion to hold it. Adhesive plaster is used for the same purpose. When organic, it requires operation (see page 143).

Ectropion (turning forward of the lid margin away from the ball) when temporary or spasmodic requires treatment of the cause. Organic ectropion requires plastic operation (see page 144).

Injuries of the lids are to be treated as injuries in other parts. Nice approximation of wounds with fine sutures leaves little scar. Wounds if possible should be made parallel to the lid margin. Edema easily develops

and subsides. The treatment of *ecchymosis* should be first by cold to check bleeding, and then by hot applications and massage to hasten absorption. For temporary cosmetic purposes, the discolored skin may be painted flesh color.

Wounds of the Eyeball

Foreign bodies should be removed as promptly as possible under aseptic precautions. Mild antiseptic washing is advisable in all wounds of the eyeball. Boracic acid solution, iodid of mercury (1 : 5000), cyanid of mercury (1 : 2000), or bichlorid of mercury (1 : 5000) may be used. Particles of iron should be removed with the magnet. No eye should be condemned to enucleation until it has been cleansed and a careful investigation of the extent of the injury made. The surgeon should know precisely with what injuries he has to deal. Atropin and dionin should be used when indicated.

Wounds and operations upon the several parts of the eye are dealt with under each separate head (see Operations on the Eye, page 138). Wounds of the lids and conjunctiva should be sutured. Wounds of the cornea which penetrate should be closed with the finest silk sutures. Extrusion of the iris should be treated by replacing it and suturing the wound. If it cannot be replaced it should be cut off. Penetrating wounds of the globe should be treated by cleansing, removing foreign matter, and suturing. The utmost patience and persistence should be practised in removing foreign bodies. Many sittings may be required. Too much should not be attempted at one time. The eye should always be given time to recover from traumatic reaction after each operation. The patient should be kept quietly in bed. Hot dressings are to be preferred. Enucleation is called for if a foreign body, which would destroy sight, cannot be removed.

Enucleation of the eyeball should be done when the eye is irreparably destroyed. An eyeball which has lost its vitreous may be saved by filling it with salt solution and closing the wound. Even in bad wounds, if there is a possibility of saving the eye, the surgeon may defer enucleation till the third or fourth day. In the meantime it should be kept cleansed, and gotten into the best possible condition. Enucleation should be done at once upon the slightest symptom of sympathetic irritation in the other eye. Even though the vision of the injured eye is capable of light perception, sympathetic ophthalmia calls for its enucleation. If the injured eye remains painful and subject to recurring attacks of acute inflammation, without restoration of vision, it should be removed. It is, perhaps, unwise to enucleate when sympathetic inflammation is in progress, if *sight* has not been destroyed in the injured eye.

Diseases of the Conjunctiva

Hyperemia of the conjunctiva requires correction of any refractive errors and removal of local exciting causes. Boric acid, 0.6 Gm. (10 grains), in camphor water, 30 c.c. (1 ounce) is useful. More astringent solutions may be called for—such as alum, tannic acid, or zinc sulphate. Constitutional disorders should be corrected.

Purulent nonspecific inflammation, requires the same treatment as hyperemia. If a cure is not effected, the disease should be treated as ophthalmia.

Conjunctivitis (ophthalmia) varies much in character, depending on the cause. Causative and irritative factors should be removed. *Simple conjunctivitis*, due to organisms of low virulence, should be treated by frequently washing out the discharges with boric acid in normal salt solution and keeping

the margins of the lids clean. Other preparations which are of value are: alum, 0.25 to 0.5 Gm. (4 to 8 grains) in 30 c.c. (1 ounce) of water; or sulphate of zinc 0.06 to 0.12 Gm. (1 to 2 grains) in 30 c.c. (1 ounce) of water. Either of these may be combined in the boric acid solution, and used as eye drops. If the infection does not subside, the everted lids should be touched with a solution of silver nitrate (0.4 to 1 per cent. in strength), or protargol (5 to 20 per cent.), or argyrol (10 to 25 per cent.). Once or twice daily the lids should be separated and one of these solutions dropped into the conjunctival sac.

If the disease does not yield to silver, irrigation with bichlorid of mercury (1 : 10,000) should be used.

The eyes should not be bandaged or covered with compresses of any kind. No pressure should be made upon the lids, but the discharges should be allowed free exit. Colored glasses may be worn for the photophobia. Small squares of gauze, cooled by ice, laid on the lids give relief from pain during the acute state. A useful eye-wash for simple cases is boric acid, 2; chlorid of sodium, 0.3; and camphor water, 100.

In *acute contagious conjunctivitis* and *catarrhal epidemic conjunctivitis*, silver solution should be used at once, and followed by mercury if necessary. The other eye should be protected from infection. Strict cleanliness for the protection of others should be observed.

Diplobacillus conjunctivitis (nongonorrheal) is best treated with zinc solution; silver seems to be of little value.

Conjunctivitis neonatorum (ophthalmia neonatorum) should be prevented. Women should not have gonorrhea. A child's head which has passed through an infected birth canal, as soon as born, should be treated as follows: the lids should be cleansed and separated and 2 drops of a 1 per cent. solution of silver nitrate dropped into each conjunctival sac at the outer canthus. In the present stage of civilization all birth canals should be regarded as infected unless they can be proved to be not infected.

When the disease has developed vigorous treatment must be pursued. There is perhaps some value in hot applications made by means of small squares of gauze wrung out in weak phenol solution at a temperature of 49°C. (120°F.). The discharges from the eye must have free escape. The eye should be cleansed often enough to keep it free from pus. This may be every half hour, or it may be every three hours; but it must be kept clean. The cornea should be spared from traumatism; and the utmost gentleness should be used. Every hour, day and night, if necessary, the lids should be gently separated and the discharges washed out with boric acid and salt solution. Thick or hardened discharges should be wiped from the lids. The edges of the lids should be anointed with vaselin, olive oil, liquid petrolatum, or boracic ointment, to prevent their sticking together. Once a day the conjunctiva of the lids should be exposed, cleansed and touched with a strong solution of silver nitrate 0.6 or 1.2 Gm. (10 or 20 grains) to the 30 c.c. (1 ounce). This should be followed by irrigation with normal salt solution until the excess of silver is washed away. In making the applications, it is well to wrap the child in a sheet to confine its arms and legs. It should be held by the nurse, sitting in a chair opposite the surgeon. The latter may hold the child's head between his knees, covered with a rubber cloth. The lids should be lifted away from the eyeball. The cornea should not be touched. A smooth wire retractor may be used.

In milder cases argyrol (25 per cent.) or protargol (10 per cent.) may be used. These substances should be instilled at intervals of from every hour to every four hours. Some surgeons use argyrol solution (10 per cent.) every half hour until suppuration ceases, and then silver nitrate (1 per cent.)

once daily. Whatever method is used, once daily the palpebral conjunctiva should be exposed, cleansed, dried, and touched directly with the stronger solution.

In the presence of corneal ulcers the utmost gentleness should be used in handling the eye. No pressure should be made on the ball. The appearance of a corneal haze should call for 1 drop of a 0.5 per cent. silver nitrate solution dropped into the eye 2 or 3 times daily.

The uninfected eye should be protected from infection by antiseptic gauze held on with a bandage or shield.

Gonorrheal conjunctivitis, whether in young or adults, should be treated essentially the same as conjunctivitis neonatorum. If the swelling of the lids becomes so great that discharges do not freely escape, the outer canthus should be divided as far outward as the bony wall of the orbit. The incision should not involve the conjunctiva. In desperate cases it may become necessary to split the lid vertically, and repair it later. Permanganate of potash (1 : 5000 to 1 : 2000), used 3 or 4 times daily as a continuous stream of irrigation has found much favor. Silver should be used as in conjunctivitis neonatorum. Atropin should be employed upon the first appearance of corneal ulceration (see Keratitis and Corneal Ulcer, page 125). To protect the uninfected eye it should be kept covered. For this purpose a watch-glass may be fastened in front of the eye and its edges sealed with adhesive plaster reinforced with collodion.

Pseudomembranous conjunctivitis, is best treated by cleansing irrigations and instillation of silver solution. *Diphtheric conjunctivitis* should receive frequent local treatment with mild cleansing solutions; and diphtheria antitoxin should be used as soon as the diagnosis is made.

Phlyctenular conjunctivitis (eczema of the conjunctiva) requires mild antiseptic collyria such as are used for simple conjunctivitis. After the acute symptoms, yellow oxid of mercury ointment (2 per cent.) may be introduced into the conjunctival sac. The constitutional treatment is that of eczema.

Vernal conjunctivitis should be treated by change of climate, correcting nasal disease, and locally applying the measures used in simple conjunctivitis. Colored glasses protect from light, and the instillation of adrenalin chlorid solution (1 : 10,000) relieves congestion. Yellow oxid of mercury ointment (1 : 60) is of service after the acute stage.

Follicular conjunctivitis, if not amenable to the treatment described for the simple form should be treated by incision and expression of each follicle.

Granular conjunctivitis (trachoma, granular lids) is an infectious contagious disease which unless cured results in trichiasis, entropion, contractures of the conjunctiva, cloudiness and ulceration of the cornea, and pannus. The treatment consists in cleansing the conjunctiva and destroying the infective material. Care must be taken that neither the disease nor the treatment shall produce much cicatricial tissue.

If there is much discharge, the antiseptic astringent solutions used in simple conjunctivitis should be employed. Permanganate of potash solution 1 : 3000 and 1 : 5000 also are used. When softening and swelling of the granulations are present, nitrate of silver (2 per cent. solution) should be used as in conjunctivitis neonatorum.

In the stage of eruption of new granulations and cicatrization of the old, a smooth crystal of sulphate of copper may be applied to all of the affected area, especially the retrotarsal folds. The treatment is painful unless preceded by cocain. It should be followed by irrigation to wash away the copper. This treatment should be confined to the mild cases of passive papillary trachoma with little or no secretion.

In some cases, carbon dioxid snow is efficacious. Five to twenty applications are required. A 5 per cent. ointment of copper citrate, followed by gentle and thorough massage, is useful in papillary cases.

When the disease has been brought under control, the absorption of the remaining granulations may be hastened by the application with a cotton swab of boroglycerid (50 per cent.) or tannic acid in glycerin (10 per cent.). Most of the known antiseptics and astringents have been used in this disease, including phenol, ointment of yellow oxid of mercury, and ichthyol. Dionin is useful if pannus or corneal disease is present—one or two drops of a 5 or 10 per cent. solution twice daily. If exacerbations appear, irritating treatment must be discontinued, and simple cleansing washes used.

True trachoma tends to become chronic. The two remedies for the early stage are silver nitrate, when there is much secretion or corneal ulcers, and copper sulphate, when there is much hypertrophy. Silver nitrate must not be used continuously as it stains the fornices and conjunctiva. Argyrol (25 per cent. solution) stains less.

The *operative treatment* has more to offer than any other measure. Of the operations used, expression of the follicles, is the most effective (see operations for Trachoma, page 150).

The treatment of **pannus** associated with trachoma depends upon its degree. If limited, it will disappear with the trachoma; but if it is extensive or complicated by ulceration, it should receive the treatment described for vascular keratitis. Jequirity and jequiritol serum are recommended by many ophthalmologists for trachoma.

Pinguecula and **pterygium** are treated by operation (see page 149).

Tumors of the conjunctiva should be excised. Malignant tumors, carcinoma and sarcoma, can rarely be removed without removal of the eyeball.

Tuberculosis of the conjunctiva should be treated the same as tuberculosis elsewhere. Hygiene, tuberculin injections, excision, and curettage are most effective.

Skin diseases may involve the conjunctiva, and require the same treatment as when in other parts of the body.

Foreign bodies in the conjunctiva are usually easily removed with a bit of cotton wound about the end of a splinter. If lodged far back under the upper lid, they may not come into view when the lid is everted unless the fold is pushed forward and the eyeball rolled downward. Cocain or other anesthetic is of help.

Wounds of the conjunctiva should be sutured the same as wounds in other parts. A buried suture with fine chromicized catgut is good.

Burns of the conjunctiva with lime, hot fluids, acids, etc., should be treated by first washing out the foreign material. This may be done by injecting water or oil with a syringe into the conjunctival sac. To prevent adhesions the sac should be injected full of vaselin or oil.

Diseases of the Cornea

The treatment of diseases of the cornea must often be looked to to save the eye from blindness or serious defect due to infiltration of the cornea, causing loss of transparency, the development of vessels in the cornea, and ulceration. Antiseptics and mild astringents are usually called for. Protection from light by means of goggles or bandage is essential. Atropin is necessary in many cases. *Dionin*, an antispasmodic analgesic drug, seems to have the power also of promoting the local lymph flow. It is used in a 1 to 5 per cent. solution, of which 1 or 2 drops are instilled into the eye from 1 to 4

times daily. At first it produces smarting and edema. These subside and an immunity develops, after which it may be increased in strength up to 10 per cent.

Phlyctenular keratitis (eczema of the cornea), occurring usually in children, should be treated with irrigations with saturated boric acid solution, followed by 1 or 2 drops of 1 per cent. solution of silver nitrate. Ointment of the yellow oxid of mercury (1 : 60) is of value. In order to make these applications, the child's head should be held firmly and the eyelids separated. Local anesthesia may be used for the first few applications, or a little chloroform given. For the photophobia, the eyes should be protected with goggles; and the dread of light may still further be overcome by douching the eyes with cold water. For the blepharospasm, the ulcerated external commissure may be touched with pure sulphate of copper. Extreme cases may require incision of the external commissure. The constitutional treatment of this disease is the same as that of eczema. Ulcers resulting from the disease require their own special treatment.

Lymphatic nodular keratoconjunctivitis is a local expression of constitutional disease, as it is most commonly found in persons suffering with tuberculosis. The nodules (phlyctenules) present a microscopic appearance very like tuberculosis. Accordingly the treatment should be addressed to the hygiene of the patient. The local treatment should be similar to that of conjunctivitis. If corneal ulceration is present 1 per cent. atropin and colored glasses should be used. Prolonged treatment with *tuberculin* is useful. Thirty to fifty treatments are necessary. The average dose should be about 0.0001 mg.

Ulcers of the cornea must be prevented and cured because of the dangers of opacity or perforation.

Simple ulcers may be treated by the methods given for phlyctenular keratitis: boric acid solution and dark glasses for the photophobia; cocain will give temporary relief from photophobia, but its continuous use does harm. Holocain is not harmful. An application to the ulcer of nitrate of silver solution (1 per cent.) will often be sufficient to effect a cure. This is less apt to cause a permanent stain than are the proprietary silver preparations. Dionin (2 to 5 per cent. solution) is recommended as of value. The conjunctiva should be kept cleanly irrigated. If the ulcer does not heal promptly stimulation is secured by the use of yellow oxid of mercury ointment (1 : 60).

In deep ulcers threatening involvement of the anterior chamber atropin should be used. When perforation seems imminent the eye should be kept clean and after each treatment covered with a dry sterile compress. Upon the appearance of bulging of the floor of the ulcer intra-ocular tension should be reduced by paracentesis of the cornea (see page 152). This operation will often relieve pain, prevent perforation, and hasten the healing of the ulcer.

In ulcers which spread in spite of treatment, more active measures must be adopted. The ulcer may be touched with phenol followed by alcohol. These applications should be made quickly and neatly. A fine probe with a small amount of cotton wound about the end is used. The eyelids should be separated so that they cannot close during the operation. The ulcer should be touched in every part with the phenol, which should not run over on the rest of the cornea. Following the phenol, alcohol should be applied in the same manner; and then the eye irrigated with normal salt or boric solution.

Other substances, such as tincture of iodin, nitrate of silver, and trichloracetic acid, also are used. When sloughing tissue is present it should be

curetted away and a dry antiseptic powder, such as iodoform, applied. Some indolent ulcers are best sterilized and stimulated by the actual cautery applied lightly just to the edges of the ulcer and to the sloughing tissue. This is the most effective treatment for serpiginous ulcer, annular ulcer, fascicular keratitis, furrow keratitis, and rodent ulcer. The method was first used and described by Martinache of San Francisco, Cal. (Pacific Med. and Surg. Jour., Nov. 18, 1873; and Ann. d'ocul., 1878, 80, 21).

In order to bring out an ulcer so that it may be seen clearly, there may be dropped into the eye a solution containing 2 per cent. of fluorescein and 3 per cent. of bicarbonate of soda. This stains a bright green the area which is denuded of epithelium; healthy epithelium is not affected, but it should be remembered that epithelium damaged by inflammation takes the stain. For the same purpose may be used toluidin blue (1 : 1000 solution).

The general health of the patient should be improved. Disorders of the nose and mouth should be corrected. The patency and health of the lacrimal canal should be insured.

Corneal opacity, resulting from ulceration or inflammation, is treated by massage of the cornea. This is made with the finger tips against the closed lids. Absorption is hastened by introducing a bit of ointment of yellow oxide of mercury (1 : 60) into the conjunctival sac. A small amount of cocain will allay the pain. Fine vibratory massage also is used. Galvanism and phototherapy have been used. The transplantation of cornea from another person or animal has met with some encouragement. Iridotomy, to form a new lateral pupil, may be done in cases of central opacity.

Corneal opacity, due to the action of lime or other caustics, may be removed by dissolving the opaque tissue. The eye should be anesthetized, and treated with a 4 per cent. solution of ammonium chloride, to which 0.02 to 0.1 per cent. of tartaric acid has been added. Applications of the chlorid may be increased in strength up to 10 per cent., but the amount of tartaric acid should not be increased.

Special forms of keratitis require special treatment. *Neuroparalytic keratitis*, from trigeminal paralysis, such as follows operations on the Gasserian ganglion or its root, requires that the cornea shall be protected from the dust of the air and that it shall be kept moist. The lids should be kept closed and covered with a dry gauze dressing, or a protecting shield should be worn as in gonorrheal conjunctivitis. Such eyes are more comfortable in a moist atmosphere. Some surgeons practise stitching the lids together.

Hypopyon keratitis (keratitis with pus in the anterior chamber of the eye) is treated by incision. A Beer's knife is held so that its back is toward the cornea, and the point is caused to enter obliquely at the margin of the ulcer. The knife is then passed across the middle of the ulcer to the opposite margin. The incision should be as deep as possible without opening the anterior chamber. The slanting position of the knife, as it is pushed along, prevents wounding Descemet's membrane. The point of the knife is then entered at the center of the incision and an incision made at right angles to the first. A similar incision is made on the other side. These incisions are carried to the margin of the ulcer thus a crucial incision is produced. If the ulcer is large several incisions may be made to radiate from the center. The border of the ulcer is then scraped with the edge of the knife, and the ulcer dried with small swabs.

The ulcer should then be touched with an antiseptic solution. For this purpose iodin, 25; potassium iodid, 50; and water, 100, are applied for five minutes. This solution should touch, only to the ulcer, as it is capable of seriously injuring the epithelium of the cornea. Salt solution should be

ready to wash off the eyeball at once should any of the solution flow beyond the ulcer.

If the ulcer is very small the incisions may be omitted. If the hypopyon is large a small puncture should be made through the center of the ulcer, and the infected aqueous fluid evacuated. The puncture should not be large enough to evacuate the hypopyon which serves to hold the iris and lens away from the opening.

The patient should be kept quietly in bed. Bland mercuric ointment should be applied as a lubricant, and atropin should be instilled to keep the pupil open. This is the method of treatment employed by F. H. Verhoeff (Jour. Am. Med. Assoc., June 30, 1917).

Xerotic keratitis, in which the lids do not cover the eyeball, requires a dressing to hold the lids, or stitching together of the lids. *Herpetic keratitis*, is treated the same as herpes zoster. Dionin, 1 or 2 drops of a 5 or 10 per cent. solution, is much in favor. A pressure bandage is of service. Tincture of iodin is also used. In *keratitis bullosa*, the blebs should be punctured and the constitutional disorder corrected. *Vascular keratitis* may require iridectomy to form a new pupil. One of the measures which have proved helpful is *periotomy*, which consists in removing a strip of conjunctiva around the circumference of the ball just posterior to the cornea. *Interstitial keratitis*, involving the whole thickness of the cornea and usually syphilitic, requires atropin and dionin, and, if indicated, antisyphilitic treatment.

Foreign bodies in the cornea and conjunctiva are usually particles of cinder, ash, metal, or sand. In most cases the body will be found on the cornea or the tarsal portion of the conjunctiva of the upper lid. The upper lid should be lifted up or everted. Good light must be thrown upon the eye. Often a magnifying lens will help to discover a small body. First the cornea should be examined, then the upper lid, and lastly the lower lid. When the body is discovered, its removal will be facilitated by local anesthesia.

The cornea is anesthetized by a drop of a 4 per cent. solution of cocain, a 4 per cent. solution of alypin, a 2 per cent. solution of holocain, or a 4 per cent. solution of novocain. But 1 drop of cocain solution is required. The other solutions require a drop every two minutes, repeated 2 or 3 times. The two lids are held apart with the thumb and forefinger of the left hand, in the case of a body on the center of the cornea. A splinter, hairpin or a needle is tightly wound about one end with a small bit of cotton, taken in the right hand, and used to lift out the foreign body. A naked needle may in some cases be required.

The patient should be requested to keep *both* eyes open. The foreign body should be dealt with very gently. The first effort to remove it should be with the cotton swab which should be used to brush it off.

If the foreign body, such as a splinter of steel, has penetrated the cornea, it should be removed with a magnet (page 160). Complete penetration of foreign bodies may sometimes be prevented by passing a needle into the chamber of the eye behind the body and thus preventing further backward progress while its removal is attempted.

A foreign body, lodged behind the retrotarsal fold of the upper lid, is exposed by turning up the lid as the patient looks downward; then the edge of the everted lid is pressed against the supraorbital margin with the left thumb; and the lower lid is pressed upward over the cornea with the fingers of the right hand.

If there is strong reason to believe that a foreign body is present, and nothing can be found after systematic search with a good light and a magni-

fying glass, a drop of fluorescein solution may be placed in the eye. This is a solution of 2 per cent. fluorescein and 3 per cent. bicarbonate of soda in water. The lids are closed and the solution allowed to remain for two minutes. The excess of solution is then washed away with boric acid solution. This pigment stains abrasions of the cornea. If there is an abrasion caused by a foreign body, a small green ring will appear around it, and make its discovery easy.

The foreign material should all be removed. Care must be taken not to push it into the anterior chamber. If it has perforated the cornea and lies just behind it, the foreign body should be removed by enlarging the wound. In partial penetration it may be necessary to pass a needle behind the body to lift it out.

No matter how small the foreign body, the eye should be washed out every hour with a few drops of boric solution until soreness has subsided. Following an operation with much wounding, atropin should be instilled, and the eye protected by a bandage for a few days. If much wounding of the cornea has occurred or the danger of infection seems considerable, the conjunctival sac should be irrigated with bichlorid of mercury solution (1 : 10,000).

Wounds of the cornea are nonpenetrating or penetrating. The former should be treated as a simple ulcer. In penetrating wounds, the eye should be cleansed with boric acid solution, and the iris, if prolapsed, replaced by means of a small probe. If there is much protrusion of the iris, it is usually impossible to replace it, and it should be excised as in iridectomy. Gaping wounds should be sutured with fine silk. Atropin should be used if the wound is central. If the wound is toward the periphery beyond which atropin cannot draw the iris, physostigmin or pilocarpin should be employed. Plastic operations are done in some cases. One operation consists in suturing a flap of conjunctiva across the cornea, and then replacing it after healing has been secured. In severe wounds, involving the iris, ciliary body and lens, the advisability of enucleation must be considered.

Burns of the cornea are treated the same as burns of the conjunctiva (page 124), keratitis and ulcer.

Tumors of the cornea are treated by excision.

Hypopyon (abscess of the anterior chamber) should be treated by paracentesis or incision (see page 152).

Staphyloma should be prevented, if possible, by preventing perforation of the cornea. After perforation has occurred, a compressing bandage and the use of eserin, is of service. If the bulging continues, paracentesis of the anterior chamber or an iridectomy opposite the clearest part of the cornea may be done. A staphyloma which is unsightly and incurable, or which threatens the other eye with sympathetic ophthalmia calls for enucleation.

Diseases of the Sclera

Episcleritis is often complicated by inflammation of the cornea and uveal tract. Hot compresses promote healing. Atropin allays pain. Dionin is of service. If no iritis is present, in chronic cases, myotics are indicated. A localized inflamed area may have its hyperemia artificially increased by scarification or cauterization. Massage with ointment of the yellow oxid of mercury (1 : 60) is of service in chronic cases.

Scleritis and **sclerokerato-iritis** is treated like episcleritis. The eye should be protected by colored glass. When the acute symptoms have subsided subconjunctival injections of saline solution are helpful. Constitutional disorders should be corrected.

Staphyloma of the sclera, if due to wound, should be treated as a hernia, the scar excised and the wound sutured, if it is accessible. If intra-ocular tension is greater than normal, it should be reduced by iridectomy.

Wounds of the sclera are perforating or non-perforating. The former are dangerous because of the loss of vitreous and the possibilities of infection of the interior of the globe. The first thing is to learn if a foreign body is left in the globe (see below). The wound should be cleansed and sutured with fine silk or catgut. The sutures should not touch the choroid. Some surgeons suture only the conjunctiva. The most careful asepsis is necessary to save the eye. The eye should be covered with a gauze dressing and the patient kept quietly in bed. If the wound is extensive, and the sight undoubtedly destroyed, enucleation should at once be done to minimize the dangers of infection and disease of the other eye.

Foreign bodies which have passed through the sclera into the eye should be removed, although if the body is small it may remain for a long time and cause but little trouble. Ultimately it may be expected to damage the vision. The determination of the location of the body is most important. The *x*-ray is used for this purpose in the case of substances opaque to it. If possible the body should be grasped by delicate forceps passed through the wound, or through a new wound made near its predetermined position. Foreign bodies lying free in the vitreous gravitate to the bottom of the chamber. Bodies of iron are best removed by the magnet (see page 160).

Infection of the interior of the eye demands drainage of the infected chamber. If necessary irraigtion should be added to this. If efforts to save the eye fail and infection threatens destruction of sight, enucleation or evisceration of the ball is called for.

Tumors of the sclera should be removed and the wound closed with sutures.

Diseases of the Iris

Iritis requires treatment varying with the stage and character of the disease. The cause of the disease should be ascertained and remedied. Syphilis especially should be had in mind. For the acute inflammation hot fomentations to the eye should be used. To prevent adhesions and secure rest for the iris atropin should be used. Further than this, operative treatment may be called for to meet certain special indications.

Atropin solution should be dropped in the eye every three or four hours. Dilatation of the pupil should be continued until ciliary irritation has abated. If atropin is not well tolerated another mydriatic may be used. Dionin is used in 5 to 10 per cent. solution, and is believed to be of value.

The specific iritides, such as **syphilitic, gonorrheal, rheumatic, gouty,** and **diabetic,** require in addition their specific constitutional treatment.

In some forms of iridocyclitis with continued high tension, paracentesis of the cornea is advisable. Mydriatics cannot be continued indefinitely, and chronic iritis which recurs or refuses to heal may be helped by iridotomy. Iridectomy is indicated especially in posterior circular synechiæ to establish communication between the anterior and posterior chambers. Glaucoma may thus be prevented.

Tumors of the iris are removed through an incision in the cornea, which is closed by suture after the removal of the tumor.

Wounds of the iris require the treatment described for the structure through which the wound is received.

Iridodialysis, a rupture of the ciliary attachment of the iris, whereby a second pupil is established external to the torn-off iris, may be cured by the

vigorous use of atropin which may cause the iris to readhere. If the opening is small it does little harm.

Diseases of the Ciliary Body

Cyclitis, inflammation of the ciliary body, requires the same treatment as iritis.

Uveitis, causing a deposit of whitish clots on the back of the cornea, is treated in a manner similar to iritis.

Wounds of the ciliary body are best treated by suture the same as wounds of the sclera and cornea. The asepticity of such wounds is of extreme importance. The ciliary body is the source of infection from which *sympathetic ophthalmia* in the other eye originates. It is a dangerous zone. Asepsis is more important than a good mechanical result, and if it cannot be secured enucleation should be done at once to save the other eye.

The following are *rules for enucleation* which have been compiled by de-Schweinitz for application in these cases in order to prevent *sympathetic ophthalmia* extending to the other eye and destroying its sight.

1. An eye with a wound so situated as to involve the ciliary region, and so extensive as to destroy sight immediately, or to make its destruction by inflammation of the iris or ciliary body reasonably certain.
2. An eye with a wound in this region already complicated by severe inflammation of the iris or ciliary body, even if sight is not destroyed; or an eye containing a foreign body which judicious efforts have failed to extract, and in which severe iritis is present, even if sight is not destroyed.
3. An eye, the vision of which has been destroyed by plastic iridocyclitis, or one which has atrophied or shrunken, provided there are tenderness on pressure in the ciliary region and attacks of recurring irritation; or without waiting for signs of irritation.
4. An eye, the sight of which has been destroyed, even though sympathetic inflammation has begun in the other eye, in the hope of removing the source of irritation.
5. An eye in which a wound has involved the cornea, iris, or ciliary region, either with or without injury to the lens, and in which persistent sympathetic irritation in the other eye has occurred, or in which there have been repeated relapses of sympathetic irritation.
6. An eye, either primarily lost by injury or in a state of atrophy, associated with signs of sympathetic irritation in the other eye.

The enucleation of an injured eye, the vision of which cannot be restored, is one of the surest ways of preventing sympathetic ophthalmia; but if sympathetic ophthalmia is well established, enucleation of the exciting eye must not be done if there is any vision remaining in the latter, because it may ultimately be the more useful of the two.

Diseases of the Choroid

Choroiditis requires treatment of any specific constitutional disorder which may be present, rest of the eye, relief of tension by atropin, and the correction of refractive errors by proper glasses. Suppurative choroiditis with infiltration external to the choroid should be treated by the above means and by hot wet compresses; free incision of the sclera should be made where pus seems confined. Panophthalmitis in these cases calls for enucleation of the eyeball. Some surgeons believe that there is less danger of meningitis if evisceration instead of enucleation is done.

Tumors of the choroid are usually sarcomata. They are usually primary, and call for enucleation as soon as the diagnosis is made. Other rarer tumors require treatment, varying with their malignancy and their location.

Tuberculosis of the choroid should be treated by general measures. If the eyesight is destroyed enucleation should be done.

Injuries of the choroid require treatment similar to injuries of the sclera. **Wounds** and **foreign bodies** should be treated the same as of the sclera.

For **rupture** of the choroid, atropin should be used, and a pressure bandage applied.

Glaucoma.—This disease, if not checked, goes on to blindness in acute cases. Early operation offers the most hope. Iridectomy may be looked to to check the disease. But before an operation can be done myotics should be quickly instilled to give relief. As soon as the severity of the attack is over the operation should be performed. In both acute and chronic cases, the most valuable myotics are physostigmin (eserin) salicylate, and pilocarpin nitrate. Pilocarpin is best used every four hours during the day, and physostigmin in twice the strength at night. In beginning cases 0.015 Gm. (¼ grain) to 30 c.c. (1 ounce) of water is used, and the strength gradually increased during the first two years. Physostigmin, 0.06 to 0.25 Gm. (1 to 4 grains) to 30 c.c. (1 ounce) of water, or pilocarpin, 0.12 to 0.3 Gm. (2 to 5 grains) to 30 c.c. (1 ounce) of water, usually relieve the acute symptoms. One or 2 drops should be instilled in the eye every hour in acute cases, until relief is secured. If relief is not secured within a few hours, iridectomy should be done. Dionin is also of service. Full doses of salicylate of strontium and a purge will help give relief.

In chronic or subacute glaucoma the myotics may be depended upon in smaller doses (page 118) to hold the disease in check. The minimum amount to keep the pupil contracted should be used. Pilocarpin is least irritative, and it may be used at first in a strength of 0.015 Gm. (¼ grain) to 30 c.c. (1 ounce) of water; and gradually increased until at the end of three years it is used in a strength of 0.6 Gm. (10 grains) to the 30 c.c. (1 ounce) if necessary. The solutions should be sterile and the conjunctiva should be irrigated frequently with boric acid solution.

Gentle massage of the eye may be practised several times daily with advantage. But little near use of the eyes should be allowed. The general health should be improved.

The above measures are tentative. Iridectomy is the best treatment for acute glaucoma. It should be done early, before the periphery of the iris has become adherent to the cornea. If done promptly the eye will be saved in most cases. The indications for iridectomy in acute glaucoma are, greatly increased intraocular tension; semidilated, immobile pupil; pronounced deficiency of vision; much pain; shallow anterior chamber; and edematous, anesthetic cornea. General anesthesia is best. The operation is performed with a narrow cataract knife if the anterior chamber is shallow. The knife should be withdrawn slowly to prevent a too rapid escape of aqueous fluid. The excision of the iris should be carried to the periphery, and represent about one-fifth of the circumference. It should be done cleanly, and no bit of iris left in the angles of the wound. In chronic non-congestive glaucoma the coloboma need not be so broad. If iridectomy fails, it may be repeated, or a sclerotomy done. Sclerotomy is called for as preliminary to iridectomy in great tension. The other eye should be kept under the influence of a myotic during the treatment. If it shows prodromal signs of glaucoma, it should have the benefit of iridectomy.

The *osmosis treatment* of glaucoma gives temporary relief. It is based on the principle of the transmission of fluids of different densities, or the power of solutions of neutral salts to imbibe water from colloid fluids. From 0.3 to 1 c.c. (5 to 15 minims) of 4 to 5.4 per cent. solution of pure sodium citrate is injected into the subconjunctival sac, adjacent to the eyeball. The injection is preceded by cocain and adrenalin solution to prevent pain. Following the injection, tension is reduced and the patient is much more

comfortable. The relief lasts for a few days or several weeks (see Subconjunctival Injections, page 179).

The results obtained from sclerocorneal trephining are best in the non-inflammatory type of the disease.

In chronic glaucoma, iridectomy should be done as early as possible; but the strikingly good results are not to be expected as in the acute form. If both eyes are affected with chronic glaucoma, the worst one should first be operated upon even though it is blind. Malignant glaucoma calls for myotics, posterior sclerotomy, and the administration of large doses of salicylates. Excision of the superior cervical sympathetic ganglia has proved of little use in this disease. (For other operations, see Operations for Glaucoma, page 161.)

Reducion of intraocular tension by intravenous injections of glucose has given remarkably good results. The normal tolerance limit of glucose intake by the resting individual is between 0.8 and 0.9 Gm. per kilogram of body weight per hour. When glucose considerably over this amount is injected into a vein increased urine secretion takes place. If the amount of water injected with the glucose is less than that excreted in the urine the tendency is toward systemic dehydration. By using solutions of glucose which have a strength of 35 to 55 per cent., and injecting at a rate corresponding to 3.6 to 5.4 Gm. of glucose per kilogram of body weight per hour, rapid dehydration takes place with the glycosuria. This is a refinement of the old methods of treating glaucoma by catharsis, diuresis and sweating. The "soft eyeball" which is found in diabetics indicates that this treatment may be reversed and ocular hypotension increased by increasing the body fluids.

R. T. Woodyatt and W. D. Sansum (Jour. Biolog. Chem., 1917, 30, 155) prepared a solution of glucose with freshly distilled water, in strengths of 36 to 54 per cent. The solution is filtered and sterilized in the autoclave. The exact titer is determined by the polariscope. The solution is injected into a vein. The rate of injection must depend upon the concentration of the fluid, the nature of the case, and the amount of water which it is desired to abstract from the body. By extending the injection over a period of two hours, the dangers of more rapid injection are obviated. R. W. Wilder and W. D. Sansum (Arch. Int. Med., Feb., 1917) found that a 54 per cent. solution given at a rate corresponding to 3.6 Gm. of glucose per kilogram of body weight per hour (6.66 c.c. of a 54 per cent. solution per kilogram per hour) has greater power of dehydration than the same amount of glucose injected in the same time in the form of a 36 per cent. solution (10 c.c. of a 36 per cent. solution per kilogram per hour). During the administration the ocular tension should be taken by a tonometer.

Diseases of the Crystalline Lens

Cataract cannot be cured by any known drug. Operation is the only effective treatment. Upon the first appearance of the disease refractive errors should be corrected by glasses, the general health should be improved, and the use of the eyes should be limited. In the early stages vision may be improved by a weak solution of atropin, 0.015 Gm. (¼ grain) to 30 c.c. (1 ounce) of water, instilled in the eye every three or four days. This admits more light past the cataract by widening the pupil, but has no curative effect. It is the stock in trade of the charlatan. All cataracts occurring in persons over thirty years of age should be removed; all cataracts in persons under fifteen should be treated by discission and allowed to dissolve. The rule has been that cataract should be operated upon when ripe. This is

not accepted by surgeons now since the early operation in experienced hands has proved so successful. Many oculists now declare that the most favorable form of cataract for operation is the immature.

The results of operation are good, in old persons as well as young. About 4 per cent. of operations in the hands of skillful operators fail to give relief. About 2 per cent. of the eyes operated upon are lost by infection. Congenital cataract should be operated upon about the tenth month; if deferred longer permanent amblyopia may result. In all cases of binocular disease it is best to operate upon but one eye at a time.

In *partial cataract*, a mydriatic will show how much improvement may be expected from iridectomy; if worth while, it should be done opposite the clear part of the lens. In posterior polar cataract iridectomy offers little help; either no operation should be done, or if both eyes are involved, ripening should be hastened with a view of subsequent extraction. Zonular cataract, if vision is greatly impaired, should be treated by iridectomy, or by discission when mydriasis gives no improvement.

Inasmuch as extraction cannot be carried out as satisfactorily until the degenerative process has separated the lens from its capsule, operation usually is deferred until "ripening" is complete. Sometimes it is slow and the patient is kept in a state of partial blindness. *Artificial ripening* is often advisable. This is effected by division of the anterior capsule of the lens, to allow the aqueous fluid to act upon it. Some surgeons combine the operation with iridectomy; others do a paracentesis of the cornea and massage the anterior capsule to cause some irritation. Many ophthalmologists prefer to extract an unripe cataract rather than do a ripening operation.

A *monocular cataract*, if extracted will not much improve the field of vision. Extraction may be done for cosmetic reasons or to avoid overmaturing. A subsequent operation for strabismus may be required (see Operations for Cataract, page 165).

A ripe cataract usually is gray-white; it may be white or amber; rarely it is black. A cataract is ripe when, after dilatation of the pupil, oblique illumination of the papillary area causes no shadow of the iris to appear as a dark semicircle on the opacity, and if illumination with the mirror of the ophthalmoscope shows no red reflex, and if no shining sectors are visible. Usually extraction should not be done until the cataract is ripe, but in patients over sixty a cataract may be extracted even though not wholly matured if the stage of swelling is not present. Operation should not be done if the eye is otherwise not reasonably sound. This may be determined as follows: The patient sits facing a lighted candle about 2 meters away. The eye should distinctly recognize the flame. As the vision is fixed upon this flame another lighted candle should be moved through the field of vision. The patient should recognize this flame as soon as the light falls upon the cornea. He should recognize the direction in which the light moves.

Traumatic cataract is caused by injuries which by lacerating the capsule permit the aqueous humor to reach the lens and cause complete or partial opacity. If the cataract has become complete and the lens is swollen, it may be removed at once. If not seen immediately after the injury, it may be treated with hot compresses, atropin and dionin. When the acute disturbance has subsided, extraction may be done. In some cases the aqueous acting upon the lens causes cataract, and then, continuing to act, causes its absorption and cure without operation.

Foreign bodies in the lens should be extracted if possible. Unless this is done the condition should be treated as a cataract.

Dislocation of the crystalline lens, if partial and producing little visual defect, may require no operation. A lens dislocated into the anterior chamber or under the conjunctiva should be removed. A lens dislocated into the vitreous chamber, if causing no serious disturbance, may be left; but if it requires removal, it may be caught with a needle or scoop, or it may be manipulated into the anterior chamber, imprisoned by a strong miotic, and extracted by incision of the cornea.

Diseases of the Vitreous

Pus in the vitreous is rarely sterilized by natural processes. Drainage and sterilization by disinfectant solution may succeed. Enucleation is usually necessary.

Opacities in the vitreous require correction of errors of refraction and improvement of the general health. **Muscæ volitantes** belong to this category.

Hemorrhage into the vitreous is treated by removal of causative factors, and rest of the eye.

Fluidity of the vitreous (synchysis) is not to be cured by any known treatment.

Foreign Bodies in the Vitreous.—(See Foreign Bodies in the Sclera, page 129.)

Diseases of the Retina

Retinitis requires treatment depending upon its nature and cause. Protection from overuse and correction of errors of refraction are essential. *Diabetic*, *leukocythemic*, *hemorrhagic*, *nephritic*, and *syphilitic retinitis* each require attention to the constitutional disorder.

Detachment of the retina is highly amenable to treatment, provided the surgeon applies patient and persistent methods. The most hopeful cases are those produced by traumatism and spontaneous post-retinal hemorrhage, of recent occurrence. Old cases rarely are cured. Spontaneous cure occurs in many cases. When a patient first comes for treatment, non-operative measures should be used for about a month.

Subconjunctival injections of salt solution should be given. Rest in bed and avoidance of blood-pressure-raising conditions should be prescribed. Coughing, sneezing, laughing, straining at stool, or anything which increases intracranial pressure, should be avoided. The causative disease should be treated vigorously. Tuberculin is valuable in tuberculous cases.

The simple surgical treatment consists in passing a broad needle or narrow cataract knife, by the aid of a mirror, through the wall of the eyeball far enough posteriorly to tap the post-retinal sac. The retina should not be injured. The flat instrument is rotated slightly, as it is withdrawn, to allow some of the fluid to escape. The eye is quieted with atropin, bandaged, and the patient kept at rest. The operation may be repeated as often as necessary. This may be once or twice a week. The principle of osmosis should be taken advantage of after such puncture. If 1 or 2 c.c. (15 to 30 minims) of salt solution are injected under the conjunctival sac, the intraocular tension is lowered during its absorption. The strength of the salt solution may be increased as high as 5 per cent.

Most satisfactory results have been secured by puncture of the sclera beneath the detached retina to allow escape of the subretinal fluid. An incision is made parallel with the fibers of the sclera as far back as possible, by extreme rotation of the eyeball.

If the detachment is in the lower part of the globe, the operation of bisection of the detached retina is the operation of choice. The eye is cocainized and the field cleansed. A two-edged knife is passed through the wall of the globe well back of the ciliary region. It passes downward and backward through the vitreous chamber as directly as possible and punctures the detached retina at a point opposite its entrance through the sclera. As the knife is withdrawn it is rotated slightly to allow some of the fluid to escape. The operation may be repeated as often as necessary, allowing sufficient interval for recovering from the traumatic reaction. Atropin should be used, and both eyes covered for the first twenty-four hours. After this atropin should be continued and the diseased eye kept covered. The patient should be kept in bed for at least a week and the condition examined, while the patient is recumbent, with the ophthalmoscope. This is the method of R. Deutschmann (Beitrage z. Augenheilk., No. 59, 1904). It may be repeated in a month if necessary. The operation has not found general favor.

Retinal hemorrhages require treatment of the cause of the disease.

Glioma of the retina requires enucleation with division of the optic nerve as far back as possible.

Diseases of the Optic Nerve

Intra-ocular edema of the optic nerve (choked disk, engorgement edema of the papilla) is a sign of increased intracranial pressure or of obstruction to the return of venous blood from the optic nerve. Relief of these conditions is called for before the third stage of Gunn (decided increase of edema, increase of elevation of the nerve head, vascular striation of the swollen tissue, striæ in the retina between the disk and the macula, and retinal hemorrhages). If the obstruction or pressure is not relieved before these conditions have appeared, atrophy of the nerve and blindness may be expected. Usually within a week or ten days of the removal of the cause, the choked disk begins to subside. The causes to be reckoned with are syphilis, secondary infection from accessory sinus disease, sinus thrombosis, and intracranial tumors and other pressure-producing conditions. Decompression is often the operation called for (see Compression of the Brain, page 53).

Atrophy of the optic nerve, if not controlled by prophylactic measures, may be treated by large doses of strychnia given hypodermatically.

Orbital optic neuritis, of irritative, toxic origin, should be treated by removal of the cause. Any focus of infection in the body should be discovered and removed. When the disease is due to tobacco, alcohol, lead, or other poisons they must be withdrawn. Strychnin in large doses is of service.

Tumors of the optic nerve are removed by enucleation of the eyeball, or by a resection of the temporal wall of the orbit (see Operations on the Eye, page 164).

Wounds of the optic nerve may be approached by resection of the outer wall of the orbit (see Operations on the Eye, page 164).

Disorders of the Orbital Muscles

Paralysis of the ocular muscles, giving rise to strabismus, is to be treated the same as paralysis of other muscles. The correction of visual defects due to such paralysis is accomplished in a large measure by proper glasses. Exercises of the muscles are also practised. When all means to restore vision have failed, tenotomy, or advancement of the paralyzed muscle, is practised. In one-half to two-thirds of the cases of convergent squint,

glasses, occlusion pads, cycloplegics, and stereoscopic exercises fail to correct the squint, and operation is necessary (see Operations on the Eye, page 174).

Diseases of the Lacrimal Apparatus

Inflammation of the lacrimal gland should be treated as other glandular inflammations—hot applications to increase hyperemia, and incision through the skin or conjunctiva when abscess is present. Iodin is of value for chronic inflammation. **Fistula of the lacrimal gland** opening through the skin, should be converted into a fistula, opening through the conjunctiva.

Hypertrophy of the lacrimal gland which is chronic and uncontrolled, and which is so great as to threaten the eyesight, should be removed by dividing the external canthus and retracting the lid upward. The same is the treatment of *tumors of the lacrimal gland.*

Prolapse of the lacrimal gland is best treated by suturing it back in place.

Atresia of the puncta lacrimalia and canaliculi, which causes overflow of the tears (epiphoria), may be congenital or acquired. Stricture, closing the puncta or canaliculi, should be dilated with a silver wire made into a probe or with a dilator. The canaliculus may require to be slit open; or if it cannot be found, a new one should be made and kept open.

Malposition of the puncta may be forward or backward. If the puncta are tilted slightly forward, epiphoria will be present. This may be corrected by a plastic operation to tilt back the lid, or by enlarging the opening by simply slitting it.

Before such operations are done the patency of the canals and nasal duct should be ascertained by injecting some solution through the puncta to the nose. Foreign bodies should be removed.

Dacryocystitis is usually associated with swelling and occlusion of the canaliculi; and epiphora results. In most cases occlusion of the nasal duct has preceded the inflammation of the lacrymal sac. The acute stage should be treated by hot applications to the skin in the region of the sac. Any disease of the nasal mucosa should be treated. But it is unwise to attempt probing the duct in the presence of an acute inflammation. If the sac becomes distended with pus, it should be incised freely, usually below the internal palpebral ligament, cutting downward and outward. This should be kept clean. When all inflammation has subsided, dilatation of the occluded nasal duct should be done.

In some cases, especially in infants, in which the disease is not acute, the canaliculi may be dilated and the contents of the sac massaged out. By adding mild antiseptic collyria to this treatment, a cure may be effected without incision of the sac.

A **fistula** persisting after rupture or incision of a lacrymal sac is cured by dilatation of the nasal duct through the canaliculus.

Occlusion of the nasal duct is due usually to dense fibrous stricture, having origin both from mucosa and periosteum. It should be treated by dilatation or division of the canaliculus (usually of the lower suffices), and the passage of sounds into the sac and thence into the duct. Under this treatment with proper cleansing and irrigation, the skin opening into the sac heals, and the duct becomes patent. The probes used should be from 1 to 3 mm. in diameter.

When the dacryocystitis becomes chronic or a fistula refuses to heal, injections of the duct with alcohol and water or silver nitrate solution (1 or 2 per cent.) should be used. *Removal of the lacrimal sac* may be done if its

healing is not accomplished or if an operation on the eye must be done. If epiphora persists, the next step is *removal of the lacrimal gland* or extirpation of its palpebral portion. Usually this last operation is not required if the conjunctiva is brought into a healthy condition (see Operations on the Lacrimal Apparatus, page 177).

Diseases of the Orbit

Periostitis requires the same treatment as periostitis in other parts.

Abscess of the orbit commonly originates from disease of the ethmoid sinuses. In such cases the orbital plate of the ethmoid should be perforated, necrotic material removed, and a drainage tube passed into the nose. Phlegmon following erysipelas may require several openings. Wherever incision is required it should be made parallel to the muscle fibers through which it passes, and the muscles of the eyeball should be avoided. Abscess of the orbit associated with panophthalmitis presents a difficult situation. Free drainage should be secured by incision of the orbital abscess, and either enucleation or free incision of the eyeball.

Tumors of the orbit should be removed if possible. Benign tumors, even though causing no trouble, should be removed because of the danger to the eyesight if operation is deferred until they do make trouble. Such growths are removed by operations carried out by incision (1) through the lid, (2) through the conjunctiva, (3) through the conjunctiva after division of the canthus, (4) by osteoplastic exposure of the orbit, or (5) by enucleation of the eyeball. The eyeball should be sacrificed, if necessary, to reach a malignant tumor. The removal of some malignant growths may require enucleation of the eyeball and removal of all the orbital contents as well. A cephalocele should not be confounded with a cystoma.

Vascular tumors of the orbit, giving rise to **pulsating exophthalmos,** vary much in character, aneurismal-varix, varicose aneurism, aneurism, telangiectoma, angioma, etc., represent tumors which require either extirpation or ligation of vessels. The reader is referred to the chapters which deal with these several diseases. If sight has been destroyed, the course to be followed is simplified; enucleation allows of free access to the orbit. If the preservation of the eyeball is desired, approach to the disease is often difficult. It is possible to ligate all of the vessels of the orbit; and, therefore, diagnosis of the disease and the determination of which vessels to ligate is important. If the disease is located in the front part of the orbit, the necessary ligations may usually be done without removing any more bone than some of the orbital rim. I have successfully ligated the supraorbital artery and vein behind and in front of a communication between them by cutting out a section of the supraorbital ridge. The branches of the facial communicating with the orbit are all easily approached.

Ligation of the common carotid or of the internal and external carotid has long been a favorite method of treating these conditions. It is the operation of choice if the lesion is inaccessible, such as rupture of the internal carotid in the cavernous sinus. Such conditions have also been treated by later ligation of the opposite carotid. But in diseases in which the vessels or the tumor are accessible, the vessels near the disease should first be attacked.

Resection of the outer wall of the orbit gives access to all the structures in the orbit (see page 164). *Ligation of the ophthalmic artery* may be done by this route. The artery enters the orbit at the outer side of the nerve, curves still further outward, and then turns inward above the nerve. The

vein accompanies it, but enters the cranium, through the sphenoidal fissure. The terminal branches of these vessels may be ligated in the anterior part of the orbit.

Operations on the Eye

Inasmuch as the eye cannot be sterilized, the best possible cleanliness must be practised. All of the general rules for operating aseptically should be observed. The normal conjunctiva is free from pathogenic organisms, and if the surgeon does his part infection need not occur (see Operations, Vol. I, page 166; Sterilization of Materials, Vol. I, page 33).

Preparation of the region of operation should consist in washing the skin of the face, nose, forehead, and eyelids with soap and water, followed by borosalicylic solution. This cleansing should include the ciliary margins of the lids (see Preparation of Patient for Operation, Vol. I, page 176).

Materials should be sterilized according to rules already given. A copious wet dressing, gauze wet with bichlorid solution, 1 : 5000, is the best covering for the eye (for bandages, see Vol. III). Black silk sutures are most easily seen for removal. Absorbable sutures should be used wherever possible. Adrenalin is invaluable in operations upon the eye.

Instruments used in operations upon the eye are similar in principal to those used in other parts of the body, but much smaller. Knives should be delicate and sharp (Fig. 766*a*).

Anesthesia is best secured by the local anesthetics, although in some operations, such as in children, nervous persons, and for enucleation, glaucoma, and plastic operations on the lids, general anesthesia is preferable. Cocain is the anesthetic most used. It is employed in a 2 to 4 per cent. solution. Still stronger solutions may be used. Dropped upon the conjunctiva, and the eye quickly closed, it permeates to all parts of the conjunctival sac, and causes anesthesia of the conjunctiva and cornea in a few minutes. Infiltration anesthesia is used in operations on the lids and skin. For operations requiring full anesthesia, such as for cataract, the following method should be used: 4 per cent. cocain solution should be instilled on the eyeball, 1 or 2 drops every four minutes, for three or four instillations. The operation may begin four minutes after the last instillation (see Local Anesthesia, Vol. I, page 127).

Dressings for the eye should be nonirritating, and frequently changed. To protect the eye from pressure, or to apply even pressure when desired, an *eye shield* of woven wire is useful. Such a shield should be bent into a concavoconvex form, and bound about the edge with gauze or tape. Tie-tapes to retain it should be provided. It may be made in single form for one eye, or double. A wire screen shield of this sort may be used (1) to retain dressings or (2) without dressings to protect the eye from external harm (Fig. 767) (see also Bandages of the Eye, Vol. III).

Operations upon the Eyelids.—Cysts of the eyelids are best removed from the conjunctival side, although the operation may be done with equal facility through the skin. The lid is grasped in a ring clamp which surrounds the tumor (Fig. 768), or lid, a clamp may be used, and an incision made parallel to the edge of the lid. The cyst is grasped with a fine clamp and dissected out (see Cystoma, Vol. I, page 325).

Operations for ptosis should aim to shorten the levator muscle. It does not suffice to remove an elliptic piece from the skin and connective tissue. Care should be taken not to overcorrect too much the defect lest lagophthalmos, by undue exposure of the cornea, especially during sleep, give rise to serious keratitis. The most effective operation consists in shortening

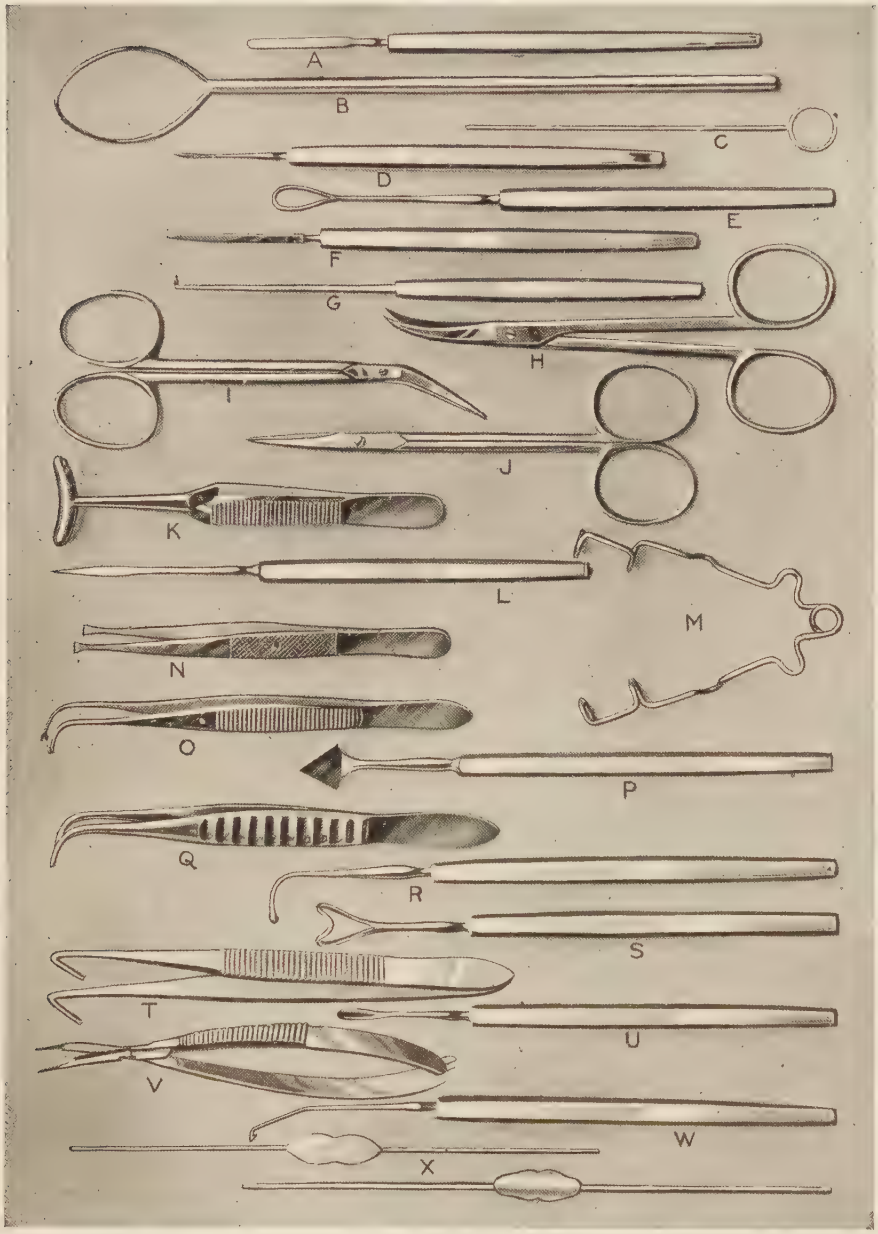

FIG. 766*a*.—THE MORE COMMON INSTRUMENTS USED IN OPERATIONS ON THE EYE.

A, Spatula; *B*, wire loop; *C*, probe; *D*, knife-needle; *E*, curet; *F*, cataract knife; *G*, cystotome; *H*, *I*, *J*, scissors; *K*, cross-bar lid forceps; *L*, paracentesis knife-needle; *M*, wire speculum; *N*, fixation forceps; *O*, curved fixation forceps; *P*, keratotomy knife; *Q*, cilia forceps; *R*, blunt hook; *S*, lid retractor; *T*, iris forceps; *U*, spoon; *V*, tenotomy scissors; *W*, angular cystotome; *X*, lacrimal probes.

the tarsal cartilage. An incision is made about 4 mm. from the margin of the lid and parallel with it. The skin and orbicularis muscle are dissected back and the whole tarsal cartilage is exposed. An elliptic piece is then



Fig. 767.—Eye Shield of Wire, Bound with Tape or Adhesive Plaster, and Provided with Tapes for Tying.

cut out of the middle of the cartilage by making two transverse incisions; the lower one is made parallel with the margin of the lid, the other is made with its convexity upward. The center of the ellipse should be as broad as

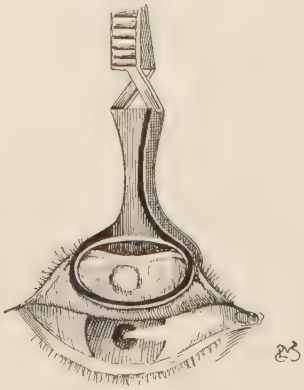

Fig. 768.—Lid Clamp Grasping Upper Eyelid for Operation on Cyst.

the distance which it is desired the lid should be elevated. It is customary to carry these incisions through the conjunctiva. The tarsal cartilage is then brought together with three or four interrupted sutures of fine chromi-

cized catgut (Fig. 769), the skin wound closed, and covered with a piece of silver foil. The tarsal "cartilage," fortunately is not cartilage and grows together promptly. The levator muscle, being inserted in its upper border, has its insertion thus advanced.

FIG. 769.—SIMPLE OPERATION FOR PTOSIS OF UPPER EYELID.
Showing interrupted sutures introduced in tarsal cartilage.

The occipitofrontalis muscle has some power to elevate the lid. This is utilized in an operation devised by Panas. A curved incision, about 3 cm. long, is made through the skin of the lid just below the upper margin of the orbit. From this incision two vertical incisions 1 cm. apart are carried down-

FIG. 770.

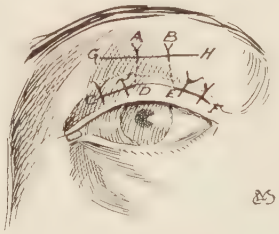

FIG. 771.

FIG. 770.—SKIN FLAP OPERATION FOR PTOSIS OF UPPER LID.
The angles *ACD* and *BEF* are dissected out and denuded of skin. The skin between *GH* and *AB* is undermined. The flap *ABED* is drawn up beneath the skin and sewed to the incision *GH*, and the skin margin *CD* sewed to *CA*, and *EF* to *BF*.

FIG. 771.—OPERATION FOR PTOSIS COMPLETED.
The flap *ABED* is drawn up beneath the skin and sewed to the incision *GH*, the skin margin *CD* is sewed to *CA*, and *EF* to *BF*.

ward to a point about 3 mm. above the margin of the lid. Each of these incisions is continued horizontally in the directions of the angles of the eye to meet the first curved incision. Another incision, 2 cm. long, is made directly above through the skin and muscle in the site of the eyebrow. The tissue intervening between the first and last incisions is dissected free to make a

bridge. The two outer angles of skin enclosed by the incisions on the lid are dissected away to leave a raw surface. The flap of skin and muscle intervening between these angles is dissected away from the underlying fascia and cartilage, carried up under the bridge to the upper wound, and sutured. The skin wounds are then closed (Figs. 770 and 771).

This operation has the disadvantage of having an epithelial surface buried in the wound, which must either become destroyed by inflammation or cause



Fig. 772. Fig. 773.

Fig. 772.—Blepharoplasty.

Plastic operation for restoring upper eyelid or for ectropion. Flap marked out.

Fig. 773.—Blepharoplasty Completed.

Flap swung down into defect on lid and wounds closed. This operation may be used to lengthen the lid in ectropion or to restore a skin defect.

a permanent sinus. It is not a surgically correct procedure, though similar to an operation much used by the ophthalmologists. After union has been secured the bridge of overlying skin should be removed.

The frontalis may be brought to operate upon the lid. A skin incision, 3 cm. long, is made along the site of the brow. Through this the skin is dissected from the orbicularis and frontalis muscles for a short distance upward and downward on the lid. Sutures are passed through the skin of the lid into the wound and brought out through the skin of the brow. When these are tied they slide upward the skin of the upper part of the lid so that it lies on the frontalis muscle. This is called the operation of Hess.



Fig. 774.—Canthoplasty for Enlarging Palpebral Fissure.

Sutures about to be tied.

Another procedure consists in making a curved incision under the upper orbital ridge, dissecting free the skin above and below, picking up the levator muscle dividing it as far back as possible, and attaching its distal stump to the frontalis as it blends with the orbicularis muscle. Fergus brings down a slip of the frontalis and attaches it to the tarsal cartilage. Motais' operation takes a narrow strip from the center of the superior rectus muscle, passes it through an opening in the conjunctiva, and attaches it to the skin at the upper border of the tarsal cartilage.

For *restoring upper eyelid* after the removal of tumors or scar tissue, a skin

flap may be turned into the denuded area from the outer side of the orbit. This flap should be cut about twice the size of the area to be covered (Figs. 772 and 773).

Canthoplasty (blepharotomy) is done to enlarge an abnormally small palpebral fissure. The external commissure is divided outward, preferably with blunt-pointed scissors. The skin wound is carried slightly farther than that of the conjunctiva. The conjunctiva and skin are then sewed together with interrupted sutures (Fig. 774).

In extreme cases of shortening of the fissure, such as follows scar contraction, a flap of skin may be swung down from the temple and split (Fig. 775).

Tarsorrhaphy may be lateral or median. *Lateral tarsorrhaphy* is done to reduce the size of an abnormally wide palpebral fissure, in congenital anomalies, lagophthalmos, ectropion, and in exophthalmos. The operation is as follows: The lids are closed, and a mark made with a scalpel or pencil at the desired end of the fissure. With a spatula between the lids and the ball to protect the latter, the margins of the lids are denuded of epithelium. The hair-bearing epithelium should not be removed. If it is desired to carry the union within the outer limits of the cilia, the denudation should be made on the conjunctival side of the cilia (Fig. 777). The denuded surfaces are then sewed together with fine silk or horsehair.

Fig. 775.—Plastic Operation to Enlarge and Restore the Palpebral Fissure.

Wound and flap marked out.

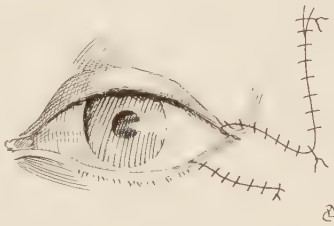

Fig. 776.—Flap Swung Down and Sutured in Defect at Angle of Eyelids.

Wound closed.

Median tarsorrhaphy is done to cover the cornea temporarily in exposure keratitis, to protect the cornea in paralysis of the orbicularis muscle and after operations on the root of the trifacial nerve. The middle of the margins of the lids are denuded of conjunctiva, for a distance of 5 mm., just posterior to the ciliary margins, and sewed together with silk. The edges unite and the cornea may be inspected by turning the eye inward or outward and examining through the narrow chink on either side. When it is desired to release the lids, they are cut apart and the wounds treated with ointment of yellow oxid of mercury (1 : 60) until they heal.

Operations for entropion (inversion of the lid) are much to be preferred to the removal of the offending lashes. In mild cases an incision is carried along close to the margin of the lid, and a second incision having a greater curve is made to connect the two ends of the first. The breadth of the included crescent must vary with the degree of deformity. It should be at least twice as wide as the eversion desired. This crescent of skin is removed and the wound closed. In a still greater degree of inversion, not only the skin but a section of orbicularis muscle also should be removed.

In the ordinary and more pronounced entropion of the upper lid, such as

follows trachoma, a more effective operation must be done. An incision is made the breadth of the lid parallel to the margin and about 3 mm. from it. A more curved incision, corresponding with the upper margin of the tarsal cartilage, then connects the two ends of this. The intervening crescent of skin, measuring 3 or 4 mm. vertically, is excised. A narrow strip of the muscle above the tarsal cartilage is excised for an extent equal to the extent of the entropion. Sutures are passed through the skin at the lower border of the wound, thence through the upper border of the tarsal cartilage, thence



Fig. 777.—External Tarsorrhaphy for Shortening Palpebral Fissure.
Note oblique incisions.

Fig. 778.—Operation for Entropion.
Suture about to be tied.

through the edge of the musculofascial wound, and out through the upper border of the skin wound. Three or four fine silk sutures suffice (Fig. 778). This operation shortens the skin and draws the ciliary border forward around the lower edge of the tarsal cartilage.

In still more aggravated cases there must be added to this operation an incision along the border of the lid on the conjunctival side of the cilia. Through this incision the skin should be dissected free from the lower margin

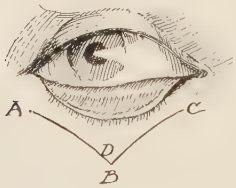

Fig. 779.

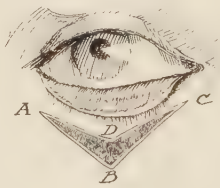

Fig. 780.

Fig. 781.

Fig. 779.—Operation for Ectropion.
Fig. 780.—The Wound is Enlarged by Undercutting the Skin.
Fig. 781.—The Enlarged Wound is Closed in the Form of a Y, thus Increasing the Vertical Measure of the Anterior Surface of the Lid.

of the tarsal cartilage in order to facilitate its sliding forward. A skin graft from some absolutely non-hairy part should be placed in this gap.

Operations for ectropion (eversion of the lid) vary with the degree of the disease. Ectropion due to relaxation of the tissues, as in the senile form, is cured by a V-incision or by the excision of a V-shaped piece of the superficial tissues (Figs. 779, 780 and 781); but when due to cicatricial contraction, or when the structures are more consolidated, a plastic operation of greater extent is necessary. In less aggravated cases a smaller incision may be used (Figs. 782 and 783). Shortening the lid, by cutting out a segment,

rather than attempts at its inversion, is essential in cases of extreme eversion (Figs. 784 and 785).

If there is relaxation of the tissues, eversion of the lower lid, and thickening of the everted conjunctiva, the Kuhnt-Szymanowski operation is valuable (Fig. 786). The lid margin is incised posterior to the cilia, and the tarsus separated from the tissues in front of it. This dissection should be made throughout nearly the whole extent of the ectropion. A triangular piece is then cut out of the conjunctiva and tarsal cartilage. To take up the slack in the skin a second triangle, with the base upward, is removed at the outer part of the lid. The wound from which the triangular piece of conjunctiva

Fig. 782.—Operation for Ectropion by V-incision.

Fig. 783.—The V-incision is Closed as a Y.

and tarsus was removed is closed by interrupted, buried sutures, of chromicized catgut. The wound at the outer part and the wound on the margin of the lid are closed with silk. It is doubtful if this operation has any advantage over the more simple operation of Adams, which accomplishes the same things.

For ectropion of the upper lid, the same principles may be applied as are used for the lower lid. In most cases it suffices to perform a simple V-shaped plastic, closing the wound as an inverted Y. Or a transverse incision may be made across the lid, the skin dissected free sufficiently to allow the correction of the ectropion, and the gap filled with skin either transplanted from some hairless part or by means of a pedunculated flap. Such a flap may



Fig. 784.—Operation for Ectropion by Shortening the Lid.

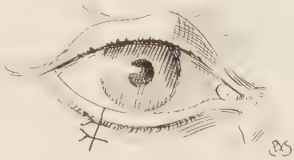

Fig. 785.—A Segment of the Lid is Cut Out and the Wound Closed.

be taken from the skin at the nasal or temporal side of the eye (Figs. 772 and 773).

For ectropion of the lower lid with apparent contraction of the facial skin, a skin incision parallel with the margin of the lid may be made and the wound permitted to gape widely. The two lids are sewed together temporarily to correct the eversion, and into the gaping wound a piece of skin is transplanted from some other part of the body (Figs. 787 and 788). Or the skin may be obtained to fill the defect by swinging in a flap from the inner side of the nose (Figs. 789 and 790).

Extreme cases due to contracture of facial skin may be treated by remov-

ing the skin below the lid in the form of a triangle and covering the defect with a flap from the outer side according to the method of Dieffenbach (Figs. 791 and 792).

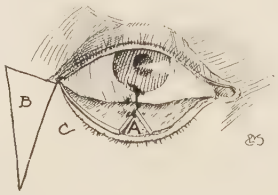

Fig. 786.—The Kuhnt-Szymanowski Operation for Senile Ectropion.

At the triangle *A*, conjunctiva and tarsal cartilage are removed. At *B*, skin is removed. The flap of skin *C* is dissected free to allow the skin to be drawn outward to close the triangle *B*. The wound *A* is closed by interrupted sutures.

Fig. 787.

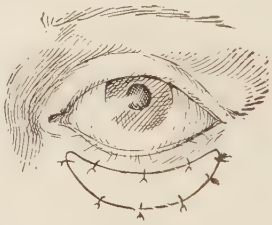

Fig. 788.

Fig. 787.—Skin Flap Grafting for Ectropion.

Incision below margin of lid.

Fig. 788.—Wound has been Spread apart by Undercutting the Skin, the Lower Margin of the Lid Has been Elevated, and the Wound has been Filled with a Graft of Transplanted Skin.

Fig. 789.

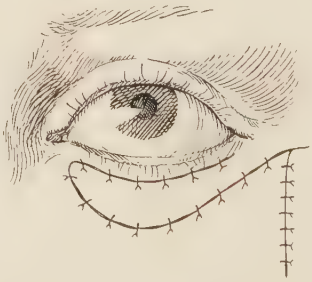

Fig. 790.

Fig. 789.—Plastic Skin Flap Operation for Ectropion.

Fig. 790.—Operation for Ectropion Completed.

The incision below the eye has been widened by undercutting the skin and the flap has been sewed in the wound lengthening the anterior surface of the lid. The space from which the flap was cut has been closed by sutures.

The tarsal cartilage may be shortened at its outer extremity instead of removing a section from its middle. In this operation, as practised by A. E. Davis, canthotomy is carried as far as the orbital margin. The periosteum is exposed. The edge of the lid at its outer extremity is cut away. The outer part of the tarsal cartilage is denuded and a piece somewhat smaller than

the wound in the lid is removed. If there is much redundance of skin a triangular piece should be removed. The tarsal cartilage is then sewed to the periosteum at the outer margin of the orbit by one or two chromic catgut sutures, which should hold it slightly under the overlapping upper lid in the

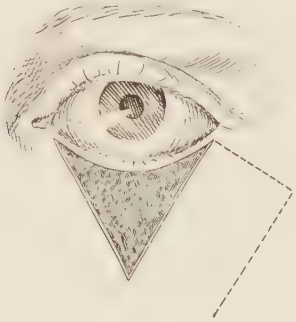

Fig. 791.

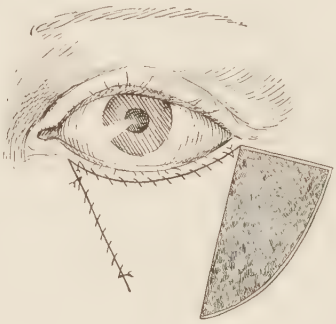

Fig. 792.

Fig. 791.—Closure of Defect, after Removal of Diseased Skin, by External Sliding Flap.

Fig. 792.—The Flap has been Swung across and Sewed in the Denuded Area below the Eyelid. The Area from Which the Flap was Taken may be Covered by a Skin Graft.

case of operation on the lower lid, and just behind the margin of the lower lid in case of operation on the upper lid. Before applying the sutures the tarsus should be placed in this position to see whether enough has been removed. The wounds are then closed with fine silk sutures (Figs. 793 and 794).

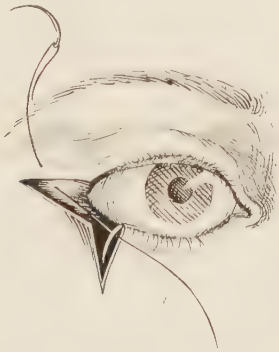

Fig. 793.

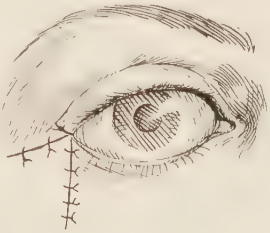

Fig. 794.

Fig. 793.—Operation for Ectropion by Removing Outer Part of Tarsal Cartilage. The triangular piece of tarsal cartilage has been removed, and the fixation suture inserted.

Fig. 794.—Completed Operation for Ectropion. The wound has been closed by interrupted silk sutures.

Blepharoplasty for resection of the lid is best done after the method devised by C. Gibson (Annals of Surg., 1914, vol. 59). Such operations are done for epithelioma of the lid, and are best adapted to cases in which the outer part of the lid is involved. The aim of this as of all operations is to secure a

restoration of the lid with epithelium on both sides. A two-stage operation is done. The first operation may be done with local anesthesia. An incision is made through the skin, from the outer canthus outward and slightly upward as far as necessary. The length of this incision must depend upon

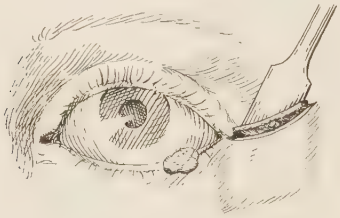

Fig. 795.—Blepharoplasty for Resection of Lid. First Step.

A skin graft is placed in a pocket made by undermining the skin external to the lower lid.

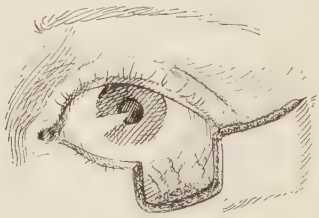

Fig. 796.—Blepharoplasty. Second Step.

The lid has been resected.

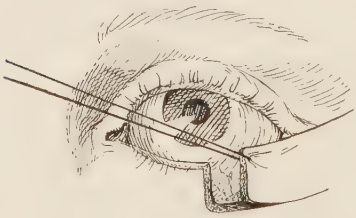

Fig. 797.—Blepharoplasty. Third Step.

The flap having skin on either side is liberated and drawn into the defect.

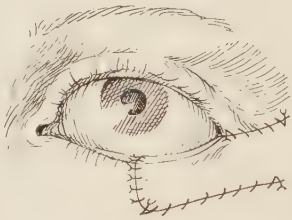

Fig. 798.—Blepharoplasty. Fourth Step.

Flap sewed in place and wound closed.

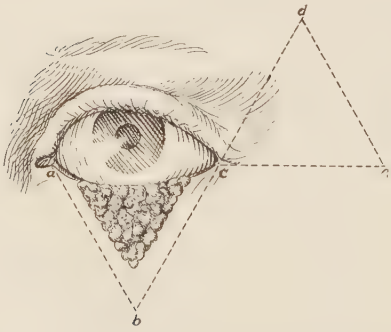

Fig. 799.

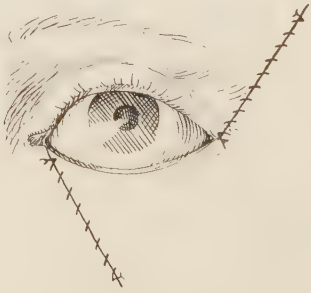

Fig. 800.

Fig. 799.—Restoration of Lower Eyelid by Sliding Flap.

A, The diseased tissue is removed with the triangle *abc*. The area *cde* is denuded; the adjacent skin is undermined; the line *cb* is sutured to *ab;* and the line *de* is sutured to *dc*.

Fig. 800.—Result after Closing Wounds of Sliding Flap Operation.

the location and size of the segment of lid to be removed. The skin below this incision is undermined, and into the pocket thus formed a skin-graft is placed with the epithelial surface looking backward (Fig. 795). The graft should be large enough to cover the raw edge of the flap. The graft and the

prospective flap should be calculated for just the size desired, as no shrinking will take place. The flap should not be made too large. The wound is dressed, and after about ten days the second operation may be done (Fig. 796).

The diseased part of the lid is excised by a quadrilateral resection. The outer edge of the wound should just touch the inner edge of the graft. An incision is then made along the lower side of the graft, and the quadrilateral flap freed (Fig. 797). This flap with skin on either side is drawn inward and sutured into the defect (Fig. 798).

When pathologic tissue is present in the eyelids, which requires to be removed, whether it is new growth, scar tissue, or ulcer, the operation becomes

Fig. 801.

Fig. 802.

Fig. 801.—Operation for Pterygium

Fig. 802.—A Diamond-shaped Piece Has been Excised and the Wound Closed.

a plastic operation to close a defect. Such tissue may be removed by a triangular incision, and the defect covered by a sliding flap. Any remaining gap may be covered by skin grafts (Figs. 799 and 800). Defects at the angles of the lids may be covered by pedunculated flaps (Fig. 775).

The skin about the eyes slides easily, lending itself to these operations. Many of these procedures are known by the names of individual surgeons, but they embrace only the simple general principles of plastic operations (see Plastic Surgery, Vol. III).

Operations on the Conjunctiva.—*Operations for pterygium* are called for when the growth is advancing to the cornea or when it is unsightly. Errors

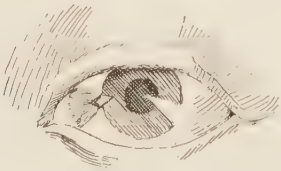

Fig. 803.

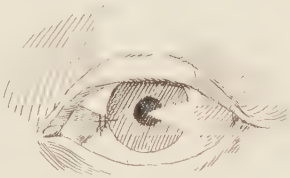

Fig. 804.

Fig. 803.—Operation for Pterygium, in Cases in Which the Growth is too Large to be Removed.

A diamond-shaped piece is removed.

Fig. 804.—The Small Wound is Closed with Interrupted Sutures.

of refraction should first be corrected. If the growth is not too broad, it is seized with delicate forceps near its apex, and dissected from the cornea with a slightly bent iridectomy knife. Its attachments to the sclera are then divided for a distance of 3 or 4 mm. from the cornea. Then the growth is divided with scissors at its base in such a way as to leave a V-shaped notch. The surgeon should not be ambitious to follow the growth too far internally. The edges of the wound in the sclera are then slightly undermined with the point of the scissors, and the notch in the base of the pterygium and the scleral wound sewed with fine silk (Figs. 801 and 802).

When the growth is too broad for this operation, the pterygium may be dissected up and reflected, the subepithelial tissue cut away from its posterior surface with fine curved scissors, its end cut off by taking out a smaller diamond-shaped piece, and the superficial layer sutured back to the sclera (Figs. 803 and 804).

The operation of Knapp dissects up the growth, splits it from tip to base, cuts off the two ends, and sutures the stumps each in its respective conjunctival wound. The operation of Desmarres dissects up the pterygium, makes an incision in the conjunctiva along its lower border, makes a pocket in the subconjunctival tissue, and tucks the end of the growth in it.

Operations for symblepharon (adhesion of the eyelid to the eyeball) should not be done until all inflammation has subsided. In some cases the adhesions may be divided and each wound in the conjunctiva of the lid and on the eyeball sutured. In order to prevent the reformation of adhesions, the principles laid down in the discission of serous surfaces may be applied (see Vol. I, pages 756 and 816). Keeping the conjunctival sac well flooded with vaselin is, perhaps, as effective as any method.

If the raw surfaces are too large to be sutured, flaps of conjunctiva from the adjacent parts must be used. Teale's operation removes the adhesions, turns down two flaps of conjunctiva from the eyeball, sutures one in each

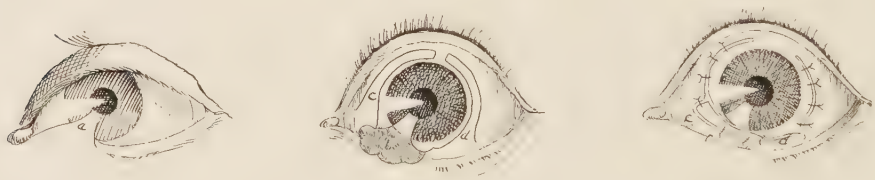

Fig. 805. Fig. 806. Fig. 807.

Fig. 805.—Operation for Symblepharon.
The adherent lid is detached at *a*.

Fig. 806.—The Denuded Area (*b*) is Covered by Two Conjunctival Flaps Cut from *c* and *d*.

Fig. 807.—The Flaps are Turned down and Sutured in Place, One (*d*) on the Eyeball and the Other (*c*) on the Back Side of the Lid.
The wounds are closed.

defect and closes the gaps from which the flaps were taken (Figs. 805, 806 and 807). Flaps may also be taken from the lid. Grafts of conjunctiva from the human or from rabbits' conjunctiva may be transplanted or skin grafts may be used. To immobilize the eyelid after the operation a lead disk should be fixed to its skin surface.

Operations for trachoma are often the most effective treatment. Operation is done only in the chronic cases, follicular trachoma and trachoma with hyaline infiltration. The cutting and traumatizing operations are not called for in the acute stage. There are many operative procedures: scarification of the conjunctiva; removal of the granulations with a curet or stiff brush, and then rubbing the wound with antiseptic; abscission of the granulations; excision of a strip of the diseased conjunctiva; extirpation of a strip of conjunctiva from the fornix; squeezing out the trachoma follicles.

The operation of Knapp for *expression* of the follicles is the most effective. The patient is given a general anesthetic, the lid everted, and as it is folded back it is seized at its conjunctival surface and lifted away from the eye. If there is much infiltration, the tissue should be scarified. The roller trachoma forceps then seize the lid, the blades being pushed well back, the

forceps are strongly compressed, and drawn forward (Fig. 808). This is repeated until all of the follicular contents have been expressed. No area should be neglected. On the following day the lids should be everted, the serofibrinous deposit removed, and the surface touched with a solution of silver nitrate (2 or 4 per cent.). This cleansing of the surface should be done daily, and the silver solution applied until the swelling has gone. This method of treatment is quite invariably successful.

The operation of *grattage* is carried out by making multiple scarifications parallel to the border of the lid, and rubbing the surface with a stiff brush, such as a toothbrush, wet with antiseptic solution. Bichlorid of mercury, 1 : 2000, is used. The after-treatment consists in the daily application of the same solution until the traumatic reaction has subsided. This is usually in a week or ten days, after which the milder treatments are employed. The reaction following this operation is much greater than after expression.

Some surgeons prefer the operation of *excision* of a strip of the affected conjunctiva or of the fornix, and closing the wound with sutures.

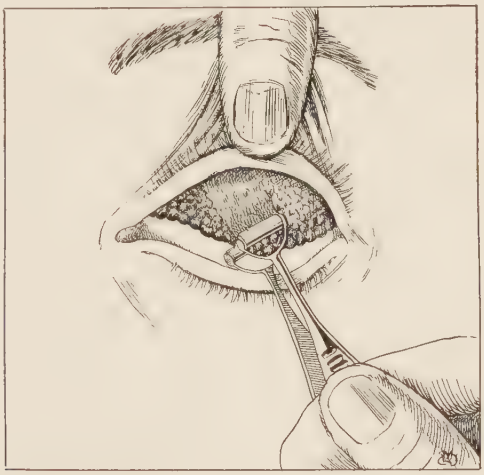

Fig. 808.—The Operation of Expression for Trachoma.

Expression of the follicles is indicated in cases of distended follicles of the conjunctiva and retrotarsal folds. This operation alone does not cure the disease; it makes the application of antiseptics more effective. The old cases with scar tissue require something more. In the cicatricial stage in advanced cases, removal of the tarsal cartilage, its underlying conjunctiva, and the retrotarsal fold is indicated. The upper lid should be everted and an incision made transversely along the angle of junction of the palpebral and ocular conjunctiva. The cut conjunctiva is slightly undermined. A second incision connecting the two ends of the first, is carried along parallel to the margin of the lid. This incision should be 2.5 mm. from the margin and should pass through conjunctiva and cartilage. A thin strip of cartilage is left. The diseased conjunctiva is dissected away. The two edges of conjunctiva are united by three or four sutures. The same operation is done in the lower lid when necessary

Subconjunctival injections are employed for many conditions, especially in inflammations of the uveal tract, inflammations of the sclera, and in some

forms of keratitis. Solutions of bichlorid of mercury (1 :4000), physiologic salt solution, sea water, serum, etc., are used.

Operations on the Cornea.—*Drainage of the anterior chamber* is done through the cornea. *Paracentesis* is employed for temporarily reducing intraocular tension in iritis or uveitis, in corneal ulcers which threaten to perforate, in glaucoma, if an iridectomy or sclerotomy cannot at once be done, and for the purpose of drainage of the anterior chamber when it contains pus or blood. The anterior chamber is tapped by means of a narrow knife or a paracentesis needle. The eyeball should be steadied with a spring speculum or with eye forceps. The instrument should be entered near the lower border of the cornea and passed upward and backward at an angle of 45 degrees. The contents of the chamber should not be allowed to escape rapidly lest the iris be damaged or a blood-vessel ruptured.

For *hypopyon*, or *keratitis* with infiltration of the cornea with pus, the cornea may be incised across its whole diameter. Such a keratotomy drains the cornea and anterior chamber and allows syringing it clean, and the removal of the hypopyon. Its disadvantage is that the iris is apt to prolapse through the wound.

Operations for staphyloma become necessary if preventive measures have failed. A small staphyloma may be excised by an elliptic incision, and the corneal wound sewed with fine silk. If the wound is too broad to be sewed, the eyelid may be covered with a compress and a compressing bandage. Compression should be continued until healing is complete. In some staphylomas there remains enough clear cornea to make it worth while to form a pupil behind it by means of iridectomy.

Complete staphylomas were formerly treated by excision, removal of the lens, and sewing the sclera across the wound. The method of DeWecker consists in detaching the conjunctiva from the margin of the cornea and dissecting it free nearly to the equator of the eyeball. Four or five sutures are then passed through the edges of the cornea and arranged ready for tying. The staphyloma is then transfixed with a knife and divided outward, the flap thus formed is seized and with curved scissors the amputation completed. The lens should be removed. The sutures are then tied, drawing the conjunctiva over the wound. Knapp passes the sutures through the episclera or sclera. No suture should involve the uvea. Panas amputated the cornea, removed the lens and iris, and sutured the wound. These operations give a good stump upon which to rest a prosthesis. The closeness of the uveal tract to the area of operation adds the danger of sympathetic ophthalmia, upon the appearance of which enucleation is called for (see Sympathetic Ophthalmia, page 130). If this condition already exists these operations for staphyloma are contraindicated, and enucleation or one of its substitutes should be done.

Tattooing the cornea is practised to conceal the white deposit of a dense leukoma. A paste is made of India ink and water. The cornea is anesthetized, the eyeball steadied with the fingers, a drop of the paste placed on the leukoma, and pricked into the tissue with tattooing needles. For this purpose a small bunch of fine needles may be mounted on a cork. Occasionally the cornea should be irrigated clean in order to observe the progress of the operation. The tattooing should be continued until the white area is all blackened. It has been suggested to use various colored inks to match the colors of the underlying iris.

F. H. Verhoeff (Jour. Am. Med. Assoc., Oct. 27, 1917) showed that the same result can be secured with less traumatism by injecting the ink with a hypodermic syringe.

F. Allport (Jour. Am. Med. Assoc., Nov. 10, 1917) described a still more simple method. He scraped off the epithelium of the cornea with a knife where he desired the stain. A thick emulsion of India ink is then rubbed into this area. The operation may have to be repeated.

The method of Froehlich consists in cutting a flap of outer layer of cornea the size and shape of the pupil desired. This flap is turned back and the underlying wound treated with an aseptic emulsion of India ink. The flap is then replaced. This gives a covering for the dye.

Operations for conical cornea (keratoconus) are called for in aggravated cases not controlled by glasses, eserin, artificial irides, or compression bandages. Two operations have value: (1) cauterizing the apex of the cone with a cautery at a dull red heat, and depending upon the contracting scar to remedy the defect; and (2) excising a portion of the cone and closing the wound with fine sutures. After either of these operations paracentesis of the anterior chamber is of service to reduce tension. A central opacity resulting from the cauterization requires iridectomy to form a new pupil.

The most satisfactory operation is the following: An elliptic section of the cornea is excised from near the periphery. This should include nearly the entire thickness of the cornea. Descemet's membrane should not be punctured. The edges of the elliptic wound should then be brought together with sutures. This operation has the advantages that it produces a linear scar and the lessened risk in avoiding prolapse of the iris.

The sutures are apt to cut. To prevent this M. Wiener used strips of gold 0.005 mm. thick and 1 mm. wide with holes 1 mm. apart and just big enough to permit the passage of a fine needle. Such a strip is placed on either side of the wound and the sutures tied on the metal.

Transplantation of the cornea is successfully done for the treatment of leukoma or other corneal opacity. The operation fails when cornea of one animal is transplanted to a different species. The human cornea may be transplanted in man with success. The cornea for transplantation may be secured from the eyes of stillborn infants, from the eyes of persons in whom enucleation has been done for some condition which has not affected the cornea, or from the cornea of a person suddenly deceased. The excised globe should be cleansed in several washings of the following solution: distilled water, 1 liter; sodium chlorid, 9 or 10 Gm.; calcium chlorid, 0.20 Gm.; potassium chlorid, 0.10 or 0.20 Gm.; sodium bicarbonate, 0.10 or 0.20 Gm.; glucose, 1 Gm. (Locke). After washing ten times in this solution at body temperature, the globe should be preserved in hemolyzed blood-serum, from a person who is negative to the reaction for syphilis. The tube should be sealed and placed in an ice box at a constant temperature of 5°C. An eye may thus be preserved with the cornea useful for at least a week.

The center of the diseased cornea should be removed as far back as the membrane of Descemet which lines the anterior chamber of the eye. All oozing should be controlled by adrenalin. The resection should be done evenly and preferably in the form of a rectangle with rounded corners or a circle. The same-shaped piece should be resected from the preserved eye. Slight contraction of the latter should be allowed for. It should, therefore, be cut slightly larger than the wound into which it is to be placed. It is only necessary that the graft should be large enough to occupy the center of the cornea. If it is 4 or 8 mm. in diameter it is adequate to admit light for vision. In so small a graft the size of the graft should be about the size of the defect made for its reception. The graft should not include the membrane of Descemet but should have the same thickness as the segment removed from the diseased eye. It should be pressed gently into place, where it will remain

without suture, if the incisions have been made at a right angle to the surface. Both eyes should be bandaged shut. On the third day the dressing may be removed and the eye inspected.

Grafting with thin grafts of cornea, shaved off with a razor as in skin-grafting, have been successfully used. These grafts are sewed directly to the cornea and covered by a conjunctival flap. Failures of autoplastic and homoplastic grafting are due to defects of technic, sepsis, and opening of the anterior chamber.

Operations on the Iris.—*Iridectomy* is done to admit more light, to relieve intraocular tension especially in glaucoma, to relieve congestion of the uveal tract, as a preliminary to extraction of the lens, and for foreign bodies and tumors. The instruments required are a speculum, fixation forceps, bent keratome, narrow knife, iris forceps, iris scissors, probe-pointed scissors, probe, and spatula. (For the Preparation of the Patient, see page 138.)

The speculum is inserted, and the conjunctiva and subconjunctiva firmly grasped with fixation forceps at a point opposite to that where the intended incision is to be made. A narrow straight knife is entered at the corneo-scleral junction from 2 to 4 mm. below the level of the summit of the cornea.

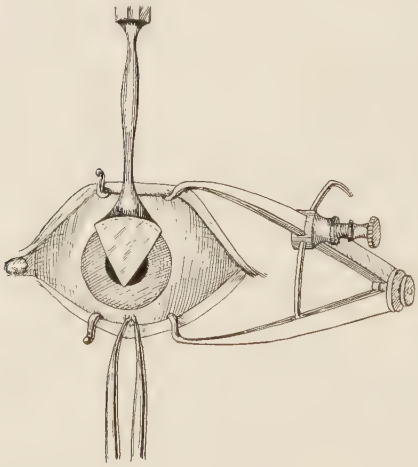

Fig. 809.—Incision of Cornea with Keratome for Iridectomy.

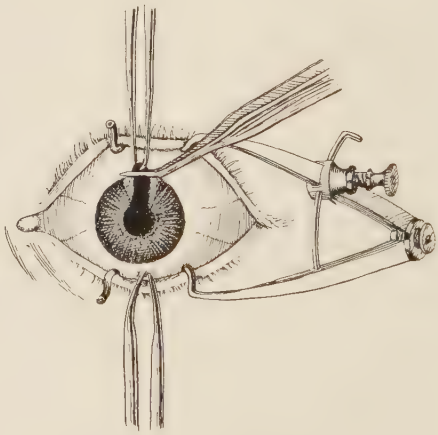

Fig. 810.—Iridectomy. Removal of segment of iris.

The point of the knife is passed through the cornea into the anterior chamber in front of the iris, and thence out through the cornea on the opposite side (Figs. 452 and 456). Then with a cutting motion, not dragging, the blade is passed upward, keeping in the same plane, cutting a flap representing about a fifth to a third of the cornea (see Operations for Cataract, page 165).

Most ophthalmologists prefer to use the keratome for this incision. When this instrument is used, the point is applied opposite the apparent corneo-scleral margin. With the long axis of the knife at right angles to the cornea the point is passed into the anterior chamber. As soon as the cornea is penetrated, the handle of the knife is tilted backward and the point pressed onward through the cornea. As the blade advances it should be kept in a plane anterior and parallel to the iris. When an opening equal to about a sixth to a fourth of the circumference of the cornea has been made, the instrument should be slowly withdrawn (Fig. 809).

Whether the knife or keratome is used the greatest care should be taken not to wound the iris or the anterior capsule of the lens. If the anterior chamber is shallow, the operation with the knife is the safer. After the incision of the cornea has been made, the curved iris forceps are introduced, and made to grasp the pupillary margin of the iris adjacent to the wound. The iris is withdrawn through the wound and the part exposed snipped off with fine scissors (Fig. 810). With a smooth probe and spatula, the stump of the iris is pushed back and smoothed out so that none remains in the corneal wound. No ragged iris tissue should be left. Blood collecting in the chamber from the wounded iris may be gently expressed after separating the wound edges, provided the pressure is not long-continued. Usually it is advisable to instill a drop of atropin solution. The parts should be left smoothly adjusted.

The best dressing consists of an oval piece of soft lint wet with 1:5000 bichlorid of mercury solution placed on each closed lid. Over this is placed a mass of absorbent cotton large enough to come flush with the brow. This is held in place by adhesive strips. Over all may be placed an ocular mask to give additional protection from traumatism. It is best to keep both eyes closed and covered for the first two days. After this, in the case of simple iridectomy no further dressing is necessary, and the bandages may be removed

Fig. 811. Fig. 812. Fig. 813. Fig. 814.

Figs. 811, 812, 813, and 814.—Forms of Iridectomy and Iridotomy.

Fig. 811.—Narrow iridectomy done for optical purposes. Fig. 812.—Small iridectomy preserving ciliary body. Fig. 813.—Broad peripheral iridectomy for glaucoma. Fig. 814.—V-shaped iridectomy.

and the patient caused to wear dark glasses. Usually these wounds heal promptly.

If the iridectomy is done for optical purposes, the knife should be entered at the apparent corneoscleral juncture; if the operation is for the relief of intraocular tension, the knife should be entered about 2 mm. posterior to this, thus beginning the incision in the sclera, in order to make an opening which will permit reaching the periphery of the iris. An artificial pupil, made because of a central opacity, should be in the inner or inner and lower segment of the iris. Otherwise the iridectomy should be done away from the opacity. If it is performed for adhesions of the iris, the artificial pupil should be made through the non-adherent part. For glaucoma, a coloboma with a broad peripheral base is made. For optic purposes, the opening need not be so broad (Figs. 811, 812, 813 and 814).

The operation of *iritoëctomy* is done through an incision about 5 mm. long, made at the corneoscleral border. Through this, the knife divides the periphery of the iris for about 2 mm. The fine iris scissors are inserted and the other two sides of the triangle cut, having its apex at the center. This piece is then picked out with forceps.

Iridotomy is preferred by some surgeons for optical purposes. The iris is drawn out through a small incision and with the scissors cut in a radial direction. It is then replaced and the natural retraction of its circular muscles produces a gap. The operation is usually done in cases in which the

lens is absent and the iris adherent. In some such cases, it suffices to insert a needle-knife and make a radial rent in the iris.

The *V-shaped iridotomy* of Ziegler is done with a needle-knife, in cases in which the iris is adherent as a diaphragm and the lens absent. The knife is entered at the summit of the corneoscleral border. The point is pushed on across the anterior chamber to within 3 mm. of the periphery of the iris, and 3 mm. to one side of a vertical line dropped from the point of entrance. The blade is then caused to perforate the iris membrane and divide it up to just beneath the corneal puncture. The blade is then withdrawn from the gaping rent in the iris and swung to the other side of the anterior chamber and a similar cut made about 4 mm. on the other side of the vertical plane.

Fig. 815. Fig. 816. Fig. 817.

Figs. 815, 816, and 817.—Steps in the Performance of V-shaped Iridotomy.
Fig. 815.—First incision. Fig. 816.—Second incision. Fig. 817.—Result after the two incisions have been made.

This incision through the iris membrane should be carried upward to meet the first incision just below its upper end. This makes a V-shaped flap with the apex upward. If the flap does not drop back it may be pressed back with the knife and the latter withdrawn (Figs. 815, 816 and 817).

Division of anterior synechia (adhesions of iris to cornea) is made by inserting a needle-knife at the most convenient place in the periphery of the cornea, and then by careful dissection dividing the adhesions. The point of entrance should be far enough away from the site of operation to give a sweeping motion as the blade lies across the anterior chamber. W. Lang used a blunt-pointed knife to divide the synechia, after puncturing the cornea with a sharp point.

Operations on the Sclera.—*Anterior sclerotomy* is employed to reduce intraocular tension if iridectomy has failed. It is practised in congenital glaucoma, and to relieve the painful tension in old, blind, glaucomatous eyes. It may be repeated as often as is desired. A narrow sclerotomy knife is caused to make a puncture through the sclera 1 mm. from the cornea. The knife passes into the anterior chamber in front of the iris, and emerges through the sclera on the opposite side at a corresponding plane. The knife is then made to cut toward the periphery, either upward or downward, as though it were intended to form a flap 2 to 2.5 mm. in height. The cutting of the flap is not completed, but the knife is withdrawn, leaving a bridge holding it to the sclera. The operation should be preceded and followed by the use of a myotic to prevent prolapse of the iris. If the iris protrudes through the wound it should be replaced by means of a spatula; if it cannot be replaced the operation should become an iridectomy (Fig. 818).

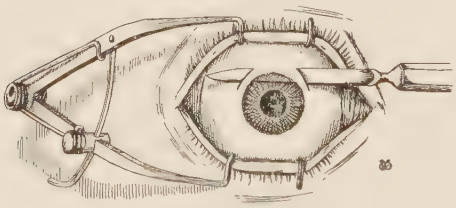

Fig. 818.—Anterior Sclerotomy.

Internal sclerotomy consists in incision into the anterior chamber, as in anterior sclerotomy, and incision of the arches of the pectinate ligament.

Posterior sclerotomy is employed in glaucoma in which iridectomy is not applicable and in detachment of the retina. A thin knife is inserted between the external and inferior rectus muscles, 8 mm. from the cornea, and passed toward the center of the eyeball to a depth of about 5 mm. into the vitreous. The knife is then withdrawn, at the same time making a quarter of a rotation upon its long axis. This makes a small triangular wound through which filtration takes place. This operation may be repeated as often as is required. It reduces the tension preliminary to iridectomy, and is of value especially in hemorrhagic glaucoma.

Combined iridectomy and sclerotomy is begun the same as anterior sclerotomy. The anterior chamber is entered by a puncture 1 mm. external to the limbus of the cornea, the knife emerging at the opposite side. It is then carried upward to the iridocorneal angle, and after the sclera is divided, the edge of the blade is directed backward and upward so as to bevel the sclera

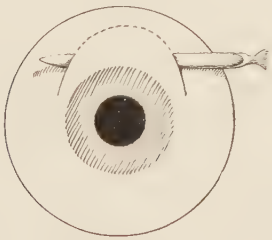

Fig. 819.

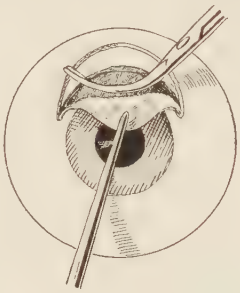

Fig. 820.

Combined Sclerotomy and Iridectomy.

Fig. 819.—Incision of sclera. Fig. 820.—Iridectomy.

and pass beneath the conjunctiva, making a good-sized conjunctival flap. This flap is then turned forward, and with a pair of fine curved scissors a piece of the sclera is cut from the anterior lip of the wound (Figs. 819 and 820). Iridectomy is then done through the wound, and the conjunctival flap replaced. It is claimed by Lagrange, the author of this operation, that a communication is established between the chamber of the eye, the perichoroidal space, and the subconjunctival connective tissue, thus relieving the tension in glaucoma.

Cyclodialysis is aimed to form an artificial communication between the anterior chamber and the suprachoroidal space. It has not yet been determined how long this communication lasts. Under local anesthesia a conjunctival flap is reflected, preferably from the lower outer quadrant of the eyeball. The flap of conjunctiva is reflected and held back with the retractor. An opening 2 or 3 mm. long, is made into the sclera parallel to the corneal margin and about 5 or 7 mm. to the outer and lower side of it. The uvea should not be injured. A spatula is inserted, separating the ciliary body from the sclera, and carefully pushed on through the ligamentum pectinatum into the anterior chamber (Fig. 821). A quadrant of the periphery of the iris is detached. Through this opening an iridectomy is done. This is the operation of Heine, and has been reported upon favorably in secondary glaucoma and in intractable advanced glaucoma (see page 161).

Operations on the Globe.—*Enucleation of the eyeball* is done for: (1) malignant growths of the eyeball or orbit which cannot otherwise be removed;

(2) extensive injury, disorganizing the eye; (3) irremovable foreign bodies, associated with infection; (4) panophthalmitis; (5) painful, unsightly, and inflamed staphyloma; (6) sympathetic irritation from such lesions as iridochoroiditis, staphyloma, etc.; (7) eyes which have become blind from glaucoma, iridochoroiditis, tuberculosis, etc.; (8) blind eyes, with traumatic iridocyclitis, giving rise to sympathetic ophthalmia, or blind eyes in which there is much pain. The following instruments are used; speculum, fixation forceps, strabismus hook, curved scissors, and mouse-tooth forceps. General anesthesia is to be preferred, although the operation may be done with local anesthesia. After separating the lids, the conjunctiva and fascia are divided with scissors around the whole circumference as close to the cornea as possible. The tissues are pressed backward until the insertions of the recti muscles are exposed. A strabismus hook is passed under each rectus muscle, beginning with the superior rectus, and the tendon divided close to the sclera. By inserting the speculum more deeply, so as to retract the divided tissues, the eyeball is made to move forward, the curved scissors are passed to the rear and divide the optic nerve and its accompanying structures close to the eye-

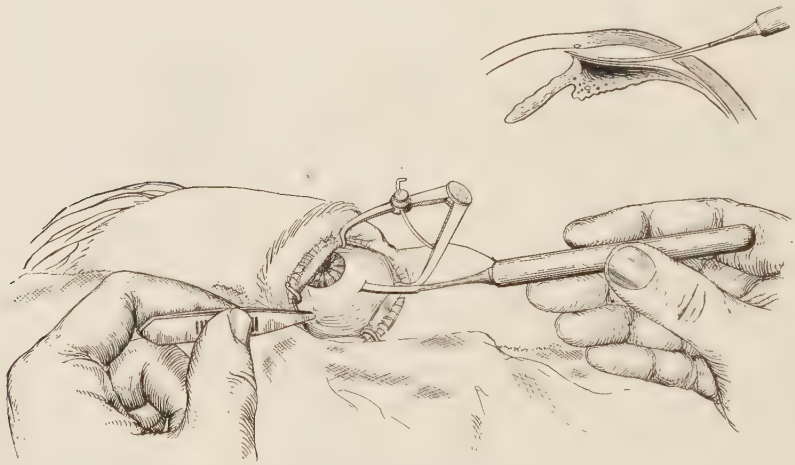

Fig. 821.—Cyclodialysis for Glaucoma.
The incision has been made, and the spatula, held parallel with the surface of the sclera and ciliary body, is passed into the anterior chamber.

ball. The ball then rotates forward, and the oblique muscles and remaining structures are divided. The capsule of Tenon should not be injured if the scissors are always kept close to the eyeball. The hemorrhage is usually inconsiderable. If necessary, it can be checked by pressure.

Some surgeons perform a rapid enucleation by seizing a rectus tendon and adjacent conjunctiva with forceps and dividing them simultaneously. Then the operation is continued by dividing two more recti tendons and conjunctiva together, rotating the eyeball, cutting the optic nerve, and finally the remaining rectus and oblique muscles.

After enucleation the management of the muscles is important. Formerly the muscles were allowed to slip back, and the wound left open. Each rectus tendon should be sewed to the conjunctiva in a position corresponding to its natural course. This may be done after the enucleation, or each rectus may be sewed to the conjunctival margin as it is divided. The edges of the

conjunctival wound are then united by suture, and the closed eyelids covered with a gauze dressing. An artificial eye should be inserted in two weeks.

The operation is practically without hazard, even in the presence of panophthalmitis. Suturing the muscles to the bed in which the prosthesis is to lie gives considerable muscular control over it. An artificial eye should at first be worn for a few hours a day; later it may be worn all day, but at night it should be cleansed with alcohol, dried, and laid aside.

The operation of enucleation is free from the disadvantages presented by evisceration; it has a far wider application; and is on the whole a more satisfactory procedure.

Evisceration of the eyeball is a valuable substitute for enucleation. It is used in panophthalmitis. It should not be done for sympathetic ophthalmitis. The operation consists in, cutting out the portion of the eyeball at a vertical plane 1 mm. posterior to the corneoscleral margin; with a scoop removing the contents of the ball, internal to the sclera; wiping dry the interior of the bulb, leaving a clean white sclera; and suturing the opening with a purse-string suture passed through the conjunctiva. Interrupted sutures and drainage of the cavity should be used if the operation has been done in the presence of infection. The operation is apt to be followed by pain; and subsequent shrinking leaves a stump not so well adapted to an artificial eye as does enucleation.

Evisceration of the eyeball and implantation of an artificial globe (Mules' operation) is done as follows: The conjunctiva is divided at the corneoscleral margin and dissected back as far as the equator of the eyeball leaving the muscles undisturbed. The anterior wall of the eyeball is cut away at a perpendicular plane 1 mm. posterior to the cornea. An evisceration of the contents of the eyeball is then done with a scoop, removing everything, and wiping dry the interior to expose the dense white sclera. Hemostasis is secured by packing the cavity with dry gauze. The opening is then enlarged above and below by a short incision, and a globe of silver, gold, glass, or paraffin inserted within the sclerotic cavity. The sclera and conjunctiva are then sutured separately over this globe. Swelling may be controlled in a measure by the application of cold over the dressings. Good asepsis is essential in this operation. According to deSchweinitz, the operation is indicated in rupture or blinding traumatism to the eyeball, staphyloma of the cornea and sclera, complete leukoma, absolute glaucoma, buphthalmos and non-traumatic iridocyclitis. The chief contraindications are infection and sympathetic ophthalmia.

Implantation of an artificial globe after enucleation is done immediately after bleeding has been checked and the muscles sutured to the conjunctiva. A globe of silver, gold, paraffin or glass is inserted within Tenon's capsule, and the capsule closed in front of it by a purse-string suture. The internal and external recti should be brought together, and the superior and inferior recti thus making a decussation of the recti tendons in front of the globe. The conjunctiva should then be sutured in front of all.

After *remote enucleation* of the eyeball, a globe may be inserted by making a lateral opening through the conjunctiva and by blunt dissection with blunt scissors creating a cavity in the connective tissue. A globe is then inserted and the opening closed with sutures.

Operations for old cicatricial contractures of the orbit are called for when it is desired to implant a prosthesis in an orbit where none had been used. In cases in which the lids are adherent to the orbital scar, they may be dissected free and the wounds covered with skin grafts. These grafts may be introduced either before or after making a cavity for an artificial ball. An epithe-

lial lining for the lids is the first essential. Then a cavity for a prosthesis may be created, either with the view of burying it in connective tissue and covering it over, or with the view of making a cavity with an epithelial lining.

Grafting an Eyeball after Enucleation.—This operation may be done for the purpose of giving a stump upon which an artificial eye may be placed. In children a rabbit's eyeball may be used. It should be attached by four sutures through the conjunctiva. The human eye may be transplanted although much more difficult to obtain. The transplanted globe heals in place, and shrivels about one-half its size.

Transplantation of Fat into the Orbit.—This operation is done after enucleation to give a stump upon which to place a false eye for cosmetic purposes. In performing the enucleation, the conjunctiva should be divided close to the cornea, and the conjunctiva and the capsule of Tenon should be dissected back as far as possible. A hook should then catch the superior rectus muscle, and a double suture of fine chromic catgut pass upward through the muscle, and through the conjunctiva near its edge just above the muscle and be tied. The three other recti muscles are similarly sutured to the conjunctiva. The ends of the sutures are not cut but are held by clamps. The eyeball is then forced from the socket, pressed internally, and the optic nerve divided. As gentle traction is made on the four sutures the socket is exposed and dried. A purse-string suture of chromic catgut is introduced around the cut edge of the conjunctiva. A piece of fat about the size of the eyeball is removed from the abdominal wall. It should include the tough subcutaneous fascia which should be placed anteriorly as the fat is introduced into the socket (Fig. 822). The purse-string suture is drawn up and tied. The four sutures through the muscle are then tied, opposite to opposite. By the end of three weeks the sutures are absorbed, and the prosthesis may be introduced. About one-fourth or one-third of the bulk of the fat will be absorbed. The false eye is moved by the muscles in synchrony with the natural eye.

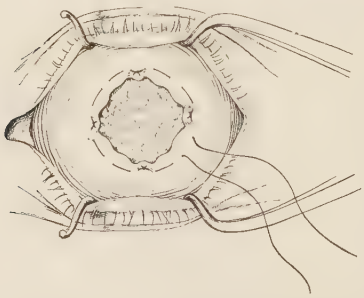

Fig. 822.—Fat Transplantation into the Orbit after Enucleation of the Eyeball.

The recti muscles have been preserved and sewed to the conjunctiva. A purse-string suture is about to close the conjunctival opening.

Removal of iron foreign bodies from the interior of the globe has been discussed (page 129). Small bodies free in the vitreous, gravitate to the bottom. Their position should be determined by the *x*-ray. Then a small incision may be made through the wall at a suitable position, and the body picked out; or, if not close to the incision, it may be brought there by the use of a magnet.

These bodies may best be removed with a large electromagnet. Preparations for an aseptic operation should be made. The eye is anesthetized. The patient is placed in a vertical position with the head supported to steady it. A giant electromagnet, having a conical end to its pole, is made to approach the eye exactly in front of the center of the cornea. The magnet should be made first to act at some distance. As it approaches the eye and the current is opened and closed, the foreign body will often be drawn around the lens and through the pupil into the anterior chamber. This usually means considerable wounding of the ciliary tract.

It is better surgery to locate the body exactly by the *x*-ray, and, having made an incision through the sclera as near it as possible, apply the point of the electromagnet, or an extension point, at the lips of the wound.

Operations for glaucoma are mentioned above (page 131). *Iridectomy* (page 154) *and sclerotomy* (page 156) are the operations most employed. In simple chronic cases with but slight or intermittent tension, sclerectomy produces an adequate filtration cicatrix. Iridectomy must be added in the cases of constant high tension. It is possible to combine these operations in such a way as to meet the permanent tendency to hypertension in severe cases. A sclerotomy may be made to produce a fistulous or infiltrating cicatrix through which the intraocular fluid can escape when tension becomes high. A sclerectomy is done at the level of the canal of Schlemm. This should involve the whole thickness of the sclerotic. The incision should divide the insertion of the ciliary muscle. This incision causes a communication between the choroidal space and the anterior chamber of the eye. The opening through the sclera permits free drainage of the intraocular fluids out under the conjunctiva. By performing iridectomy, the inclusion of the iris is prevented.

The operation of *cyclodialysis* (see page 157) consists in making a communication between the suprachoroidal space and the anterior chamber. Through this channel the aqueous humor escapes. It is indicated in advanced cases in which iridectomy has not succeeded in reducing the tension. It is not as valuable an operation as iridectomy, though easier to perform.

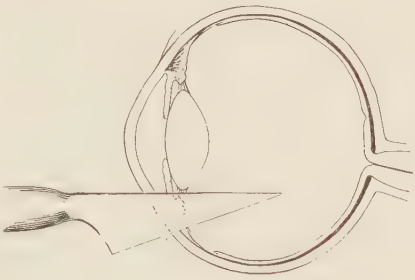

Fig. 823.—Operation of Hancock for Glaucoma.

The *wedge-isolation operation* of Herbert is aimed to produce a permeable scar. The anterior chamber is opened with a narrow knife which is passed horizontally across it. A short flap of sclera is cut and left attached at its apex. The direction of the edge of the knife is then changed so that two cuts forward and backward are made, and a narrow strip of sclera is freed from the flap at the limbus. The operation is subconjunctival. The wedge of sclera which is detached is left adherent to the conjunctiva. It is held loosely in the groove which is cut in the sclera. A small iridectomy may be done to prevent prolapse of the iris.

The *operation of Hancock* consists in piercing the globe with a sharp-pointed broad-bladed knife at the lower sclerocorneal junction. The incision in the sclera is 4 or 5 mm. long. The cutting edge of the knife is downward and the point passes backward and slightly downward. A meridianal section is thus made which opens both the anterior and posterior chambers and divides the ciliary body. The knife is rotated slightly as it is withdrawn, and the aqueous and some vitreous permitted to escape (Fig. 823).

The *operation of Abadie* makes an incision 1.5 cm. long through the conjunctiva and subconjunctival tissue meridianally in the upper outer quadrant of the globe. It begins at the corneal margin, passes toward the equator and lays bare the sclera for 7 or 8 mm. The lips of the wound are separated and two sutures passed to be used later in closing the conjunctiva over the sclera. The globus is then held with forceps and a triangular knife inserted just behind the iris at the junction of sclera and cornea, and caused to pierce the globe toward its center. The incision is 7 or 8 mm. long and passes

through sclera and ciliary zone. The knife is then removed and the conjunctival wound sutured (Fig. 824).

The operation of *sclerotomy with a trephine*, for the purpose of relieving the intraocular tension of glaucoma is one of the older operations. As it is now done, a flap of conjunctiva is dissected up toward the cornea and turned up over the surface of the cornea. With a scleral trephine a small disk of sclera is removed 1 or 2 mm. from the apparent margin of the cornea (Fig. 825). An iris repositor is passed from the trephine opening into the anterior chamber. The instrument should be kept in close contact with the sclera and the cornea. This guarantees a passage for fluid, and constitutes cyclodialysis in addition to trephining. The instrument is withdrawn, the flap of conjunctiva is replaced, and sewed.

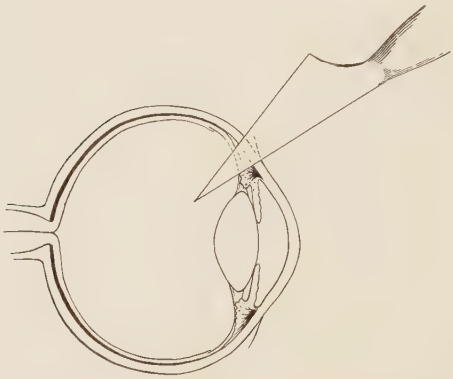

Fig. 824.—Operation of Abadie for Glaucoma.

The operation of *simple trephining* of the sclera, devised by R. H. Elliot (Ophthalmoscope, Aug., 1911), is done as follows: An incision is made running concentric with the corneal margin and ending on either side about 4 mm. below the uppermost limit of the cornea and the same distance from the inner and outer sides of the limbus. The triangular flap of conjunctiva thus outlined is dissected up from above the cornea. The flap is turned down on the cornea, and the dissection continued until the rounded edge of the limbus can be seen as it overhangs the surrounding scleral tissue. In old cases of glaucoma the separation of the conjunctiva is carried still further from the cornea with the aid of the points of the scissors. This permits that the cornea can be seen to be split. The splitting of the cornea creates a thin dark-colored crescent, about 1 mm. broad which embraces the base of the flap. When this appearance is created, the anterior chamber may be entered with a trephine.

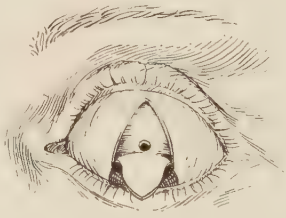

Fig. 825.—Sclerotomy with the Trephine.

The eyeball is rotated downward, a triangular flap of conjunctiva is turned down, and the trephine opening made.

In making this dissection the points of the scissors should be kept directed toward the plane of the posterior pole of the lens. If this is not done a puncture may be made in the conjunctival flap. Connective tissue is carefully cleaned away from the area in which the trephine is to be applied. This should be as close to the limbus as possible, or the trephine will not enter the anterior chamber. The trephine should not be larger than 2 mm. in diameter—1.5 mm. is, perhaps, better. If the trephine fails to tap the anterior chamber, a curet must be passed in to make the opening (Fig. 826).

As the anterior chamber is entered by the trephine, the fluid flows forth. If the iris appears at the opening it may be incised in a radial direction. If it does not return, the bulging piece should be abscissed. Tags of iris should be removed from the trephine opening. The conjunctival flap should be replaced. Sutures need not be applied, unless it is found misplaced at the

first dressing. Eserin solution (1 : 120) need be dropped in the eye only if the pupil is found displaced upward. If the pupil is not active and dilated after the third day, atropin drops should be used.

Removal of tumors of the orbit should not sacrifice the eyeball unless absolutely necessary. For subconjunctival operations, hemorrhage may be controlled by a spatula pressing the ophthalmic and supraorbital vessels upward toward the roof of the orbit. Temporary division of the recti muscles may be required. Cysts, which cannot be removed without sacrificing the eyeball, should first be treated by incision, curettage, injection of some irritating substance such as tincture of iodin, and the use of drainage. If this does not effect a cure, it remains to be determined whether the sinus or the loss of the eye is more objectionable. Tumors growing from the walls of the orbit should be removed early if they are of progressive character.



Fig. 826.—Sclera Trephines.

Resection of the outer wall of the orbit is done for exposure of the eyeball and the other contents of the orbit. An osteoplastic operation is to be pre-

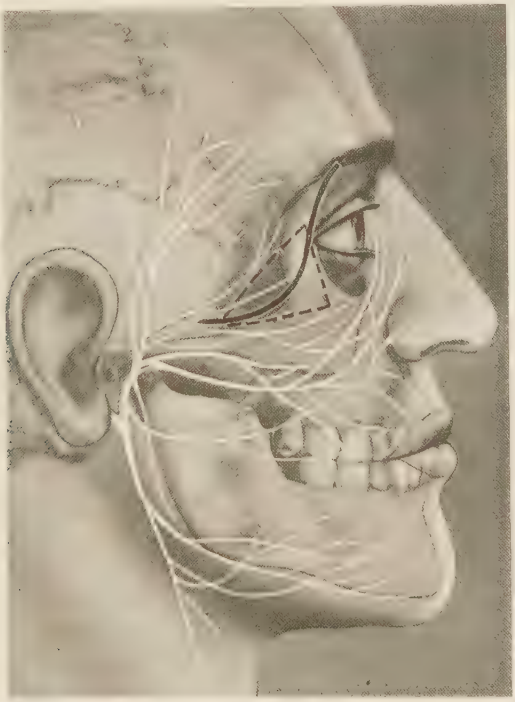

Fig. 827.—Resection of Outer Wall of Orbit.
Showing incision which spares the facial nerve from injury. If the incision is confined to the external orbital triangle no damage of the nerve is sustained.

ferred. The orbit, posterior to the eyeball, even to the nasal side, may be exposed. This operation is done for the treatment of disease and the removal of tumors. The filaments of the facial nerve should be spared as much as

possible. If lines are drawn from the upper and lower borders of the orbital rim, backward to the condyle of the lower jaw, the triangle thus enclosed will be found to be quite free from facial nerve trunks. The incision through the soft parts should lie within this triangle.

A curved incision begins in the eyebrow, at the front of the temporal ridge, above the external angular process, passes downward, making a curve with its convexity forward, to the outer border of the orbit, and thence passes downward and backward along the upper border of the zygoma to the mid-zygomatic point (Fig. 827). This incision should go down to the bone, and at the orbit it should open the orbital connective tissue. An elevator is then used to separate the periosteum from the outer wall of the orbit. This is reflected inward as far as the sphenomaxillary fissure. With a saw or burr the bone is cut through in a line from the anterior end of the fissure to a point above the external angular process of the frontal bone. Another

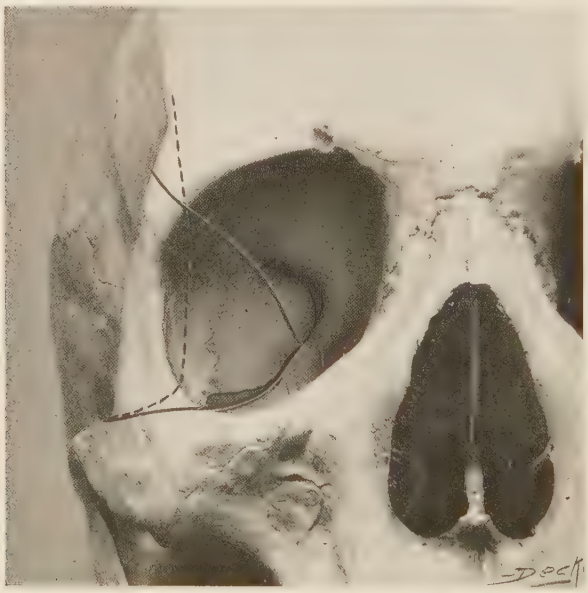

Fig. 828.—Resection of Outer Wall of Orbit.
Dotted line represents skin incision; heavy line represents bone incision.

division of the bone is made from the anterior end of the sphenomaxillary fissure, forward and outward through the malar bone to the upper border of the anterior root of the zygoma (Fig. 828). This wedge of bone, internally representing outer orbital wall and externally representing the wall of the temporal fossa, retaining its temporal attachments is pressed outward and backward. Free access to the orbit is thus secured. The periosteum which has been reflected inward, should be split from before backward, and retracted upward and downward. The external rectus muscle may be divided at its insertion and later sutured back in place. With thin retractors and careful dissection, the eyeball may be held aside and the orbit explored. *Exposure of the optic nerve* and vessels is secured by this route. The operation concludes with suturing the osteoplastic flap back in place by periosteal sutures.

Operations for Cataract. The indications for operation (page 132), the preparation of the patient (page 138), and the anesthetic (page 138), have been described. The following instruments are required; speculum, fixation forceps, lid elevator, spatula, wire loop, spoon, probe, curet, cystotome, capsule forceps, iris scissors, iris forceps, and cataract knife (Fig. 766*a*, page 139).

Simple extraction (extraction without iridectomy) is done as follows: The first step of the operation is the same as that for iridectomy (see page 154). The eyeball is steadied by grasping the conjunctiva with fixation forceps. The tendon of a rectus muscle may be included in the grasp. If the right eye, for example, is to be operated on, the surgeon stands behind the patient, and grasps with forceps in the left hand a fold of conjunctiva and the tendon of the internal rectus. Some surgeons prefer to grasp the conjunctiva below the cornea. Some surgeons of skill dispense with the speculum and fix the eyeball and retract the lid by grasping the superior rectus with forceps. The point of a cataract knife is entered at the corneoscleral junc-

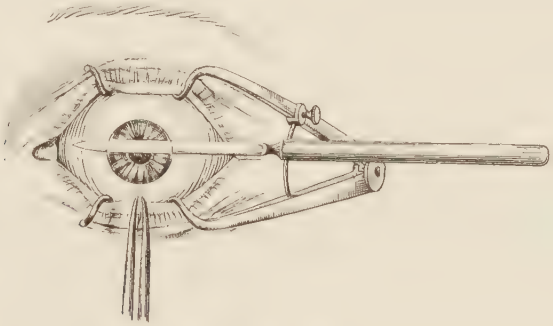

FIG. 829.—INCISION OF CORNEA FOR CATARACT EXTRACTION.

The knife has pierced the cornea, passed through the anterior chamber and emerged at the corneoscleral border on the other side. It will then cut directly upward, emerging at the corneoscleral border, leaving a flap of cornea and a wound opening the anterior chamber.

tion on a horizontal line 3 or 4 mm. below the summit of the cornea, and passed across the anterior chamber between cornea and iris, to emerge at the corneoscleral border on the opposite side (Fig. 829). The surgeon should be sure that the cutting edge is upward before entering the knife. The knife is then made to cut directly upward, emerging at the corneoscleral border above and leaving a flap of cornea and a wound opening the anterior chamber. This flap usually should involve about half of the cornea.

In the second stage of the operation the eyeball is drawn downward with the fixation forceps, and the capsule of the lens incised. This is done with the cystotome, which is introduced flatwise through the wound and then after passing through the iris opening, is turned with its cutting edge toward the lens. The capsule is incised in such a way as to make a triangle with its apex downward and its base upward. The transverse part of this incision, or base of the triangle, should be at the periphery. The triangular opening thus made lies just within the pupil. The knife should be used carefully and with little force lest the lens be dislocated. If the anterior capsule is thickened it may be picked up and opened with capsule forceps.

The third stage consists in the delivery of the cataract. The patient is directed to look downward or the eye is drawn downward by fixation forceps.

The speculum is then held away from the eyeball by an assistant, or removed and the upper lid held away from the incision by a lid elevator, in order that there shall be no pressure on the eyeball. The lower part of the cornea is now pressed with the convex surface of a metal spoon. Firm pressure causes the upper margin of the lens to appear in the pupil. The pressure is continued gently and made to follow the lens as it escapes through the pupil, and thence through the corneal wound (Fig. 830).

The wound is now inspected. Any cortical tags or bits of capsule should be removed. The iris should be smoothed out if necessary with a spatula and the corneal flaps adjusted. Pressure upon the lower border of the cornea will usually cause the iris to fall in place. Some surgeons prefer to irrigate gently the anterior chamber with physiologic salt solution. This washes out loose particles and adjusts the iris. The current should be from within the chamber outward through the wound.

Simple extraction presents the advantage that the iris is left intact. It has the disadvantage that the extraction is more difficult.

Combined extraction (extraction with iridectomy) is similar to the above, excepting that iridectomy is added. The first stage of the operation is the same, and similar to that of iridectomy. The second stage consists in the performance of iridectomy. The patient is directed to look downward, or the fixation forceps are held by an assistant, who gently draws the eyeball downward, while the surgeon introduces the iris forceps, grasps the iris midway between the pupil and periphery, and with the iris scissors cuts off a fold of iris out to the corneal border. A large opening in the iris is not necessary. The edges of the coloboma are smoothed out with a spatula and the iris left smoothly in place with no part of it engaged in the corneal wound.

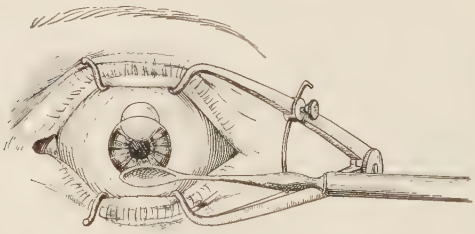

Fig. 830.—Operation for Cataract. Delivery of the Lens.

The spoon presses the lower part of the cornea and causes the lens to move upward through the corneal wound.

In the third stage, the capsule is divided much as in the operation without iridectomy. It may be divided by introducing the cystotome, passing it to the bottom of the coloboma, and making a vertical incision, passing to the top of the coloboma, where a transverse cut is made. The incisions should pass through the capsule, and make the least possible pressure.

The delivery of the cataract is the same as in simple extraction except that it is more expeditious because of the larger opening through the iris. Cases in which the ball is hard, the lens large, the pupil not easily dilated, the anterior chamber shallow, or with ciliary irritation, require the combined operation. Some surgeons as a routine remove a small piece of iris in all cases.

The *after-treatment* in all cataract cases should begin preferably with placing a piece of soft lint, soaked in 1 : 5000 bichlorid of mercury solution, upon each closed lid. Over this, sterile cotton is placed to the level of the eyebrow. All are held in place with adhesive strips making only enough pressure to retain the dressing. To prevent traumatism during the first two days, it is well to add an ocular mask. The eye should be inspected twenty-four hours after simple extraction. If the corneal wound is found closed, the iris in place, 1 drop of atropin solution should be instilled. If

the anterior chamber has not reformed, the atropin should be omitted. If a prolapse of the iris in the corneal wound is found, the iris should be excised. Local anesthesia does not act well in the presence of inflammation, and it may be necessary to use general anesthesia. If combined extraction has been done, the eye need not be examined until the end of forty-eight hours. The anterior chamber will usually be found reformed. A drop of atropin solution should be instilled, and the dressings renewed. Usually the wound will be found closed at the end of twenty-four hours. Delayed healing may be caused by a bit of tissue between the lips, which should be removed. If there is simply a lack of reparative power, it may be stimulated by touching the wound with silver nitrate stick.

The eye which was not operated upon may be uncovered at the end of three days; and by the sixth day the affected eye may be left without dressing. During the second week colored glasses should be worn by day, and a protective covering, to prevent traumatism, by night. Many surgeons apply no dressing at any stage of the treatment, but simply cover the eyes with a shield or cage. At the end of six weeks or two months glasses for distance and for near reading should be adjusted.

Accidents of treatment may occur. If the iris falls forward in the path of the knife while the first incision is being made, the knife should continue, cutting out a coloboma, which later may be trimmed evenly.

Blood in the anterior chamber is expelled by the pressure which expels the lens. If it is present after expression, it may be removed by gentle irrigation with salt solution. Remaining blood is absorbed during the first day or two.

Two much pressure upon the lens may cause it to escape posteriorly. In such an event the speculum should be removed and all artificial pressure abated. A loop should be passed behind the lens to bring it forward. Vitreous escaping into the anterior chamber should be wiped away. If the escape of vitreous is sufficient to cause collapse of the eyeball, it should be filled with salt solution. The same should be done to the anterior chamber if the cornea collapse.

Intraocular hemorrhage, usually manifested by pain and nausea, and sometimes by the appearance of blood in the dressings, should be treated immediately. Morphin is required for the pain. If the hemorrhage is from the iris and does not escape externally, it may be left to take care of itself; if oozing through the corneal wound is present, the blood should be washed out with warm salt solution. If the bleeding continues, adrenalin chloride may be added to the solution. Hemorrhage from the choroid, displacing the vitreous, is a more serious condition. If such hemorrhage escapes through the wound, the loss of the eyesight may be expected. An attempt to save the eye may be made by washing out the clot with salt solution through an incision posterior to the ciliary tract. If the bleeding does not stop, adrenalin chloride should be added to the solution. Whatever is done the conjunctiva should be kept clean. If such a hemorrhagic eyeball becomes infected, enucleation is practised.

Infection following the operation for cataract is rare in these times. Pain, swelling of the lids, and injection of conjunctiva are the signs which call attention to infection. Antiseptic washes should be used. If the infection involves the anterior chamber, it should be irrigated frequently with salt solution. Some surgeons use weak bichlorid of mercury solution. Suppuration invading the vitreous usually destroys the eye. In such cases incision to drain the vitreous posterior to the ciliary tract may be of service.

The appearance of iritis or iridocyclitis between the fifth and twelfth day

augurs bad for the eye. Iritis may be checked by atropin and dionin locally. Recurring iridocyclitis gives a bad prognosis, unless the disease can be checked and the closed pupil remedied by iridotomy or iridocystectomy.

As a result of traumatism or some sudden increase of intra-ocular pressure as may be caused by sneezing or coughing, prolapse of the iris through the wound takes place. If the prolapse occurs soon after the operation, usually it will be found slightly adherent to the wound; in such an event, the prolapsed iris should be excised, the stump pressed away from the wound and smoothed out, and the wound edges again smoothly coapted. A small prolapse which has become adherent may be left until later and then excised as a staphyloma.

Fig. 831.—Preliminary Capsulotomy for Immature Cataract.

Showing point of entrance of knife at upper outer quadrant of the cornea. *N*, Nasal side; *T*, temporal side.

Preliminary capsulotomy for immature cataract is practised as follows by the method devised by Homer E. Smith (Jour. Am. Med. Assoc., vol. 63, Sept. 5, 1914). The peculiar capsulotomy knife is used. The length of the blade should be 2 mm., the point obtuse, the belly rounded, and the edge acutely sharp. A vertical and a transverse incision are made across the front of the capsule. The pupil should be dilated with 2 per cent. homatropin and the eye anesthetized. For the right eye the surgeon stands at the head of the patient and grasps the conjunctiva and internal rectus with forceps in the left hand. The knife, held as a pen, with the cutting edge downward, is thrust through the middle of the superior temporal quadrant of the cornea (Fig. 831); passed across the anterior chamber until

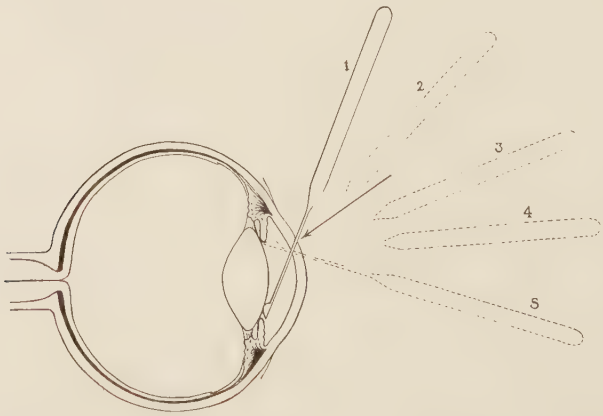

Fig. 832.—Preliminary Capsulotomy for Immature Cataract.

Vertical section through right eye. The knife has pierced the cornea at the point indicated by the arrow, and passed down to the lower margin of the dilated pupil. The handle is then moved downward through the positions indicated by 1, 2, 3, 4 and 5, as the blade moves upward. The operator is standing above the patient's head.

the blade reaches the lowest possible point on the dilated pupil at the vertical meridian of the lens. The handle then describes the arc of a circle as the blade is carried across the front of the lens cutting through the anterior capsule along the vertical meridian (Fig. 832). Without removing the blade from the anterior chamber, it is passed across to the inner side,

and by a similar movement the anterior capsule is incised on the transverse meridian (Fig. 833).

For operating on the left eye the surgeon stands at the left of the patient, and the knife enters the cornea at the inferior temporal quadrant. The first incision in the capsule begins at the top of the vertical meridian of the lens. After the capsular incisions have been made, the speculum is removed, a drop of ⅓ of 1 per cent. physostigmin (eserin) solution is dropped in the eye, and a dressing applied.

Six hours after the capsulotomy the operation for extraction of the cataract is done. The section for removal of the lens should involve the upper

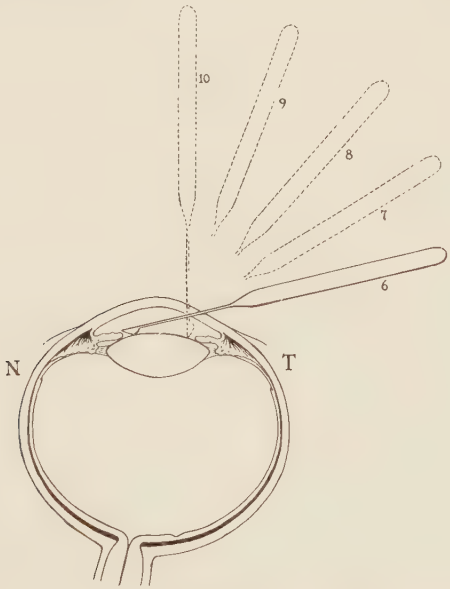

Fig. 833.—Preliminary Capsulotomy for Immature Cataract.

Horizontal section through right eye. The blade of the knife is withdrawn from the position 5 and is passed to the nasal side (*N*) of the dilated pupil. It is then carried successively through the positions 6, 7, 8, 9 and 10, thus making an incision in the capsule of the lens at right angles to the first incision, and passing from the nasal (*N*) toward the temporal (*T*) side. The operator is standing above the patient's head.

two-fifths of the circumference of the cornea. The danger of iris prolapse is reduced by using atropin immediately after the operation.

Other operations for cataract are used to meet peculiar conditions. *Discission* (needle operation) is used in congenital, juvenile, and soft cataracts in which there may be either complete or partial opacity. The operation is done as follows: The pupil is dilated and a knife-needle is introduced at the corneoscleral junction and passed into the anterior chamber. The point of the instrument penetrates the capsule of the lens and divides it crucially. Some surgeons cause the point to enter the capsule and then cut forward. At subsequent operations the lens itself may be slightly scratched. The effect of this is to admit the aqueous fluid to the lens, which completes the opacity if not already complete, and acts as a solvent upon the lens. It is usually necessary to repeat the operation—in some cases several times before solution is secured. The pupil should be kept dilated and the eye covered until reaction has subsided. Complete solution requires from three to six months.

Discission is a dangerous operation because of the possibility of doing injury to the ciliary tract. Dragging or rough handling must be avoided. The instruments should be sharp. Atropin must be used freely. Glaucoma following the operation requires myotics, and, if this fails, iridectomy or paracentesis.

In the same class of cases in which discission is employed, or in which it is not desired to repeat the needling, *linear extraction* may be used. This operation is applicable especially in soft congenital cataracts and in complete juvenile cataracts in patients under thirty years of age. It is also used in traumatic cataract, and in cases in which needling has been followed by swelling with glaucomatous symptoms. For high progressive myopia, some surgeons practise discission, followed by extraction or removal by suction. The pupil should be widely dilated. A keratome is inserted at a point 1 mm. within the periphery of the cornea. The instrument is passed onward until a wound 5 mm. in width is made. Through this the cystotome is

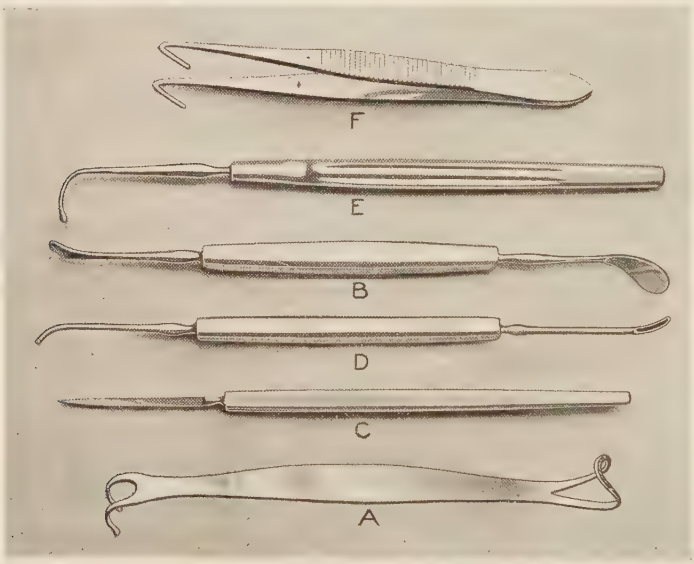

Fig. 835.—Instruments Used in Intracapsular Cataract Extraction.
A, Lid elevator; *B*, spoon; *C*, knife; *D*, iris replacer; *E*, compression hook; *F*, capsule forceps.

inserted and the capsule of the lens freely incised. Pressure is made with a spoon or spatula against the cornea below while pressure is also made above the wound. The pressure should be gentle lest the hyaloid be ruptured and vitreous escape. Some surgeons insert a fine canula connected with rubber tubing by means of which the soft lens is removed by *suction*.

Extraction of the lens without incision of the capsule is in favor with some surgeons. The first stages of the operation are similar to the ordinary operation. It may be done with or without iridectomy. The lens may be lifted out by means of a curet or loup. Henry Smith perfected this operation. The surgeons in India deliver the lens through the corneal wound by careful and systematic pressure, without rupture of the capsule. This gives a clean result if the surgeon has sufficient skill to perform the operation without the escape of vitreous. Loss of vitreous is the common accident in inexperienced hands. Special instruments are necessary (Fig. 835).

The *operation in two stages* consists in preliminary iridectomy, and removal of the lens several weeks later, and is practised by some surgeons as a general rule. It is to be followed in cases in which the cataract is not ripe, or in which extraordinary care is necessary, as after the loss of one eye. The dangers of operation by this method are reduced.

Extraction of cataract with capsule after subluxation with capsule forceps is recommended by Arnold Knapp (Arch. of Ophthal., vol. 44, No. 1, 1915). A drop of atropin is instilled, in addition to the anesthetic solution. The eye is exposed and steadied by speculum. The speculum is used throughout the operation unless prolapse of vitreous is threatened. The incision should involve nearly half the circumference of the cornea. A conjunctival flap should be made. Iridectomy is done. The capsule forceps are inserted and a fold of capsule grasped below the center. Care should be taken not to tear the capsule. The forceps, holding the capsule, are moved in all the lateral directions until the capsule is freely movable. The forceps are then removed. With a cataract hook pressure backward is made on the lower

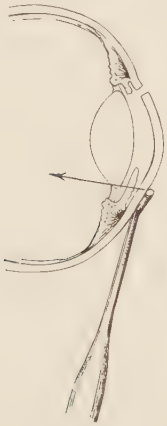

Fig. 836.—Intracapsular Cataract Extraction. First Stage.

Showing point for applying pressure in extraction of immature cataract.

Fig. 837.—Intracapsular Cataract Extraction. Second Stage.

Pressure is continued, the cornea being pressed in behind the lens as it moves along.

part of the cornea. The lens is seen to rotate and come out of the wound. It is separated from its attachments by a lateral stroking motion. The coloboma of the iris should be replaced, the conjunctival flap adjusted, the speculum removed, atropin ointment is introduced, and both eyes covered with a dressing. The dressing is left undisturbed for four days unless complications develop. After the fourth day the good eye is left uncovered.

The *intracapsular extraction of immature cataract* has come to be a popular procedure as a result of the work of Henry Smith. The danger of loss of vitreous has been materially reduced by the use of the spoon and properly constructed and handled lid retractor. When vitreous escapes, the spoon is passed behind the lens; pressure is made with a blunt hook upon the bottom of the lens; this dislocates it upward, and prevents pressure upon the vitreous. The removal of immature cataract saves the patient the long period of anxiety and increasing defect of vision entailed by waiting for the cataract to ripen.

The incision involves half the circumference of the cornea. If it passes

into the conjunctiva, some hemorrhage will obscure the operation. Iridectomy is done. The hook of Smith is placed flat against the cornea, and pressure made toward the optic nerve (Fig. 836). As the lens is dislocated upward, if the pressure is relaxed too soon the lens will slip back; if the pressure is too great the capsule may be ruptured or the vitreous may escape (Fig. 837).

The pressure is continued gently, the hook being moved toward the wound following the lens as it escapes (Fig. 838). If the lens is swollen, it may be rolled over and brought to the wound opening by pressing the cornea downward (Fig. 839). As the lens escapes, the hook is pressed behind it (Fig. 840).

For intracapsular cataract with a spoon, the cornea is incised, iridectomy is done, and the spoon is introduced behind the lens. Pressure is made on the front of the cornea with the compression hook at the lower pole of the lens. This causes the lens to move upward. The spoon prevents its displacement into the vitreous (Fig. 841).

Fig. 838.—Intracapsular Cataract Extraction. Third Stage.

The compression hook squeezes the lens out of the opening.

Fig. 839.—Intracapsular Cataract Extraction with Swollen Lens.

A lens which is swollen may be rolled over and brought to the wound opening by pressing the cornea downward.

The operation of *couching* or *depressing* consists in forcibly pressing the lens backward so that it is detached and dislocated back into the vitreous humor. It is rarely used, but it may be employed in patients greatly enfeebled by old age or other disease. It is used also in the insane or patients whose actions cannot be controlled, and in cases in which chronic conjunctivitis or dacryocystitis cannot be cured.

The operation of *suturing the corneal wound after cataract extraction* is practised by some surgeons. It is the ideal method of terminating the operation. It is little employed by ophthalmologists, perhaps, because of their limited grasp of the general principles of surgery; although any one who is competent to remove a cataract is competent to close the wound in a surgical manner. But one suture is used; that should be the finest silk in the finest possible curved needle. The suture is passed before the tissues are cut. The suture may be passed vertically or transversely in the cornea and transversely in the episclera. The bite of each suture need not be much more than 1 mm. The suture naturally enters and emerges on the surface. The punctures may be so close together that the knife may pass within 1 mm. of them (Fig. 842). The loop is left long so that the threads may be held out of the way during the operation. After the corneal incision, capsulotomy and

delivery of the lens, the suture is drawn up and tied snugly. This operation minimizes the danger of prolapse of the iris and vitreous. A dressing is applied. The suture is removed on the third day. It may be removed earlier, as the wound will be found adherent by the end of the second day.

The *immediate removal of traumatic cataract* should be practised in cases in which the lens is hopelessly destroyed. As soon after the injury as possible, when the patient has recovered from shock, the lens should be removed. A local anesthetic may be sufficient, but often, because of inflammatory reaction, a general anesthetic is best. If there is much local traumatic reaction present, operation should be deferred for four or five days. Operation should be done before secondary inflammation has developed. Cases in which there is a laceration of the cornea and decided mutilation of

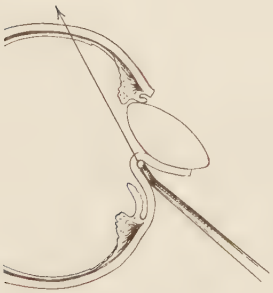

Fig. 840.

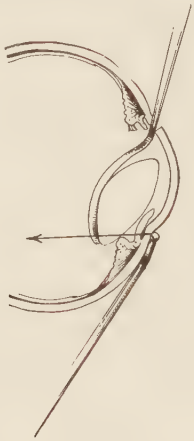

Fig. 841.

Fig. 840.—Intracapsular Cataract Extraction with Swollen Lens.

The cornea is pressed behind the lens as it advances toward its exit.

Fig. 841.—Intracapsular Cataract Extraction with Spoon.

The cornea has been incised and iridectomy done. The spoon is introduced behind the lens. Pressure is made on the cornea with the hook at the lower pole of the lens. This causes the lens to move upward and be delivered in front of the spoon. The spoon need not be used except when the vitreous has escaped.

the lens are best treated by cutting the lens with a cystotome and washing it out. In the young, the lens may be sucked out. A regular typical cataract extraction may be done in some cases. Cases complicated by the presence of foreign matter require especial care. A typical extraction is best in cases with foreign body. If washing is practised there is danger of washing lens and foreign matter back into the vitreous.

Iridectomy should be done in most cases. Foreign body in the iris calls for iridectomy. The corneal incision should be made near the foreign body.

The use of *suction in cataract extraction* may facilitate many operations. Traumatic cataract in children and in the young, seen immediately after the injury, is best treated by being sucked out. This may be done with a simple hypodermic syringe. Suction is employed in adults to advantage as a means of holding and controlling the lens in the ordinary extraction. A cup on the end of a handle, connected with a vacuum bottle, may be introduced through the wound, and caused to hold the lens, to rotate it, draw it out, or otherwise manipulate it.

The *vacuum extraction of cataract* is based on the hypothesis that cataract should be removed with the least possible traumatism. For this purpose a little cupping instrument is made which may be connected with an aspirator. The cup fits over the anterior surface of the crystalline lens. It is introduced through the pupil. The iris is not injured. The cataract comes out clinging to the instrument when it is withdrawn. The cup sucks out the cataract together with the minute shreds of tissue without introducing any instrument behind the lens. This operation may be done in cases of ripe senile cataract, in unripe, and in overripe cases. This is the method of I. Barraquer (Siglo Medico, Madrid, Apr. 21, 1917). By thus removing all of the contents of the capsule postoperative iritis is minimized. Vitreous is not lost because pressure is not made. Iridectomy is rarely needed, the operation requiring only the corneoconjunctival incision and the cup. This is probably destined to supersede the methods of forcible extrusion.

Operations for after-cataract (secondary cataract) vary with the degree of the opacity. A delicate membrane remaining across the pupil after cataract operation is best treated by entering a cataract needle as in the operation of discission. The operation as done by Knapp is as follows: The pupil is dilated widely and the knife-needle is passed through the cornea 3 mm. within its margin on a horizontal at a level with its centre. The point is

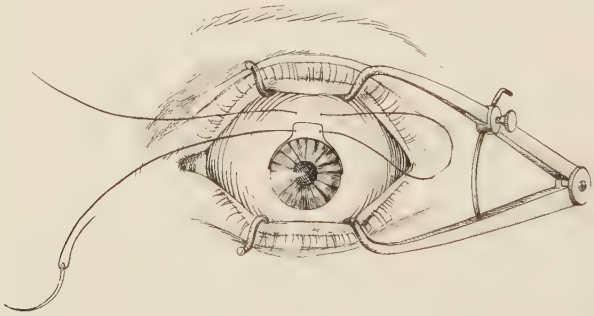

Fig. 842.—Suturing Corneal Wound in Cataract Extraction.
The suture is passed before the tissues are cut.

passed across the anterior chamber to the opposite side and a horizontal incision, 4 or 5 mm. long, is made. The knife is then made to cut a perpendicular incision of similar length crossing the first at its center but made by two cuts each approaching the center. The membrane should be cut, not torn; thickened places should be avoided; and the vitreous should not be penetrated. Iridotomy must be substituted in cases in which the membrane is thick and resistant. V-shaped iridotomy is of service.

Operations upon the Eye-muscles.—These operations consist in tenotomy of the muscles which move the eyeball, and advancement or readjustment of their insertions. There is a growing feeling that operations for strabismus should be done early. The sooner the divergence is corrected the sooner normal restitution is possible. Children as young as two years old may be operated upon. Cocain usually suffices. Young children may require general anesthesia. The internal rectus most frequently requires division; next in frequency is the external rectus. The other straight muscles sometimes require operation. Strabismus appears usually about the third year of life. Glasses, exercises of the muscles and improvement of the general health may fail to secure correction. The internal rectus muscle is inserted

in the sclerotic about 5 mm. posterior to the border of the cornea; the external, 7 mm.; the superior, 8 mm.; the inferior, 6 mm. The tendons are about 9 mm. broad. *Complete tenotomy of the internal rectus* is done for convergent strabismus. The *subconjunctival operation* is as follows: The lids are separated with a speculum. A fold of conjunctiva and subconjunctival tissue at the lower border of the tendon of the muscle is picked up with fine forceps. An opening large enough to receive a strabismus hook is cut with scissors. If the cut has not involved Tenon's capsule, it must be picked up and divided. The wound is held open with the forceps while the strabismus hook is passed beneath the muscle close to the sclerotic and the tip made to appear under the conjunctiva above the muscle. The hook is now drawn forward until checked by the insertion of the tendon. The scissors, having a bulb on one point to prevent wounding the sclera, are inserted in front of the hook, and by several cuts the tendon is divided. The hook is then moved forward, and any undivided fibers cut.

The *open operation* is as follows: A vertical fold of conjunctiva and underlying tissue is picked up with toothed forceps at the insertion of the muscle and a horizontal opening made through it and the capsule of Tenon. Through this opening the tendon is exposed, the strabismus hook is passed between the sclera and muscle, and the latter divided at its insertion. The effect of the operation may be diminished by suturing the wound so as to make a vertical line. Usually the wound is closed horizontally. The open operation is to be preferred to the closed (Fig. 843).

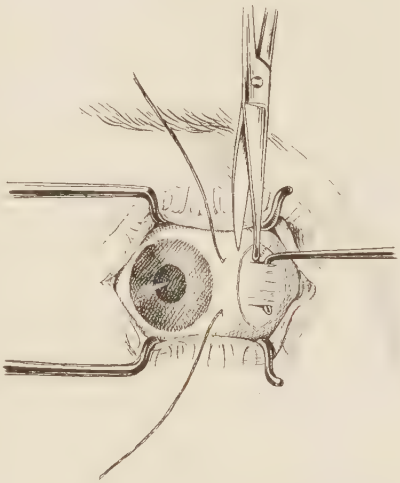

Fig. 843.—Open Operation for Tenotomy of Internal Rectus.

The suture in the sclera is used to fix the tendon when advancement is to be done. The probe-pointed scissors are about to cut the tendon.

After tenotomy the conjunctival sac should be washed out and the patient should immediately wear the corrective glasses. Some surgeons bandage the eyes for one or two days. Whatever is done, the same after-treatment should be applied to either eye.

In some cases with extreme strabismus the inner third of the superior or inferior rectus, one or both, must also be divided.

The *indications* for these operations should be studied before the operation is done. Each case is peculiar. A convergent squint of 15 or 20 degrees is cured by tenotomy of the internal rectus. Correction should not be complete. A convergence of 2 to 5 degrees after operation will prevent overcorrection or divergent squint.

A deviation over 20 degrees can rarely be cured by this operation. If the case is one of *alternating strabismus*, with good vision in each eye, tenotomy of each internus is indicated. Should this not cure the disease, the externus of the most convergent eye should be advanced.

In the case of *unilateral strabismus*, exceeding 30 degrees, and the eye amblyopic, tenotomy of the internal rectus must be combined with advancement of the external rectus. In many such cases it is also necessary to do a

slight tenotomy of the internus of the other eye. Extreme cases demand division of both interni and advancement of both externi.

At the best, it is difficult to regulate the result of tenotomies; and in recent years the operation of advancement is much employed.

Certain *special conditions* require attention. If the capsule of Tenon is not divided, it will be impossible to pass the hook under the muscle. Perforation of the sclera may occur unless probe-pointed scissors are used. Hemorrhage is usually slight; and pronounced hemorrhage is least likely to occur in the open operation. Retraction of the caruncle occurs because of retraction of the muscle, some of whose fibers are inserted in it, and because of later scar contractures of the subconjunctival tissues. To correct this condition the caruncle should be dissected free and sutured back in place.

Partial tenotomy (graduated tenotomy) is done for heterophoria, a disturbance of the normal balance of the muscles of the eye, which is not sufficient to cause strabismus. A transverse opening in the conjunctiva is made opposite the insertion of the muscle. The tendon is grasped by forceps at its insertion and the middle fibers divided at their insertion. The opening thus made is enlarged by cutting upward and downward with the scissors. The anterior and posterior lamellæ of the muscle are left, also the borders of the muscle. The operation is carried as far as necessary to give the required relaxation. This may be determined by testing the vision during the operation.

Advancement (readjustment) consists in bringing the tendon of a rectus muscle forward to a more anterior insertion. An opening transverse to the muscle is made in the conjunctiva, at the insertion of the tendon. It should be about twice the width of the muscle. The conjunctiva between the opening and the cornea should be undermined for a short distance by blunt dissection. The tendon is separated from the sclera by passing a strabismus hook between them. This separation should come well forward to the insertion and surely involve the whole width of the tendon. A curved needle, threaded with fine chromicized catgut, is passed between the tendon and sclera and thence through the middle of the tendon close to its insertion. A similar suture is passed at the other side emerging at the middle of the tendon near the first suture. These sutures are then tied on the free side of the tendon, each one grasping half of it, and the ends left long. The tendon is then divided at its insertion; the needle on the end of each suture is passed beneath the conjunctival bridge and made to engage the episcleral tissue nearly as far forward as the cornea; the sutures are tied; and the conjunctival wound closed with three sutures. The degree of advancement is regulated by the place of insertion of the episcleral sutures. While the sutures are being tied, the eyeball should be rotated toward the divided muscle. Both eyes should be kept bandaged for at least four days.

Instead of a conjunctival incision, a flap of conjunctiva may be turned back from near the cornea. Some surgeons include only one-third of the tendon in each suture which is tied around the edge (Landolt) (Fig.844). In convergent squint, surgeons are coming more and more to practise advancement of the external rectus, leaving the internal rectus untouched.

The operation of *shortening the muscle* consists in making a tuck, folding the muscle upon the tendon.

The *muscle-folding operation* is best done with a catgut suture. The conjunctiva is incised so as to expose the attachment of the tendon. A loop of the muscle is lifted up on a blunt hook. The needle, carrying a double thread, is passed through the tendon at its insertion in the sclera and

then through the muscle posterior to the hook (Fig. 845). Three interlocking sutures suffice. The fold of muscle may be left uncut.

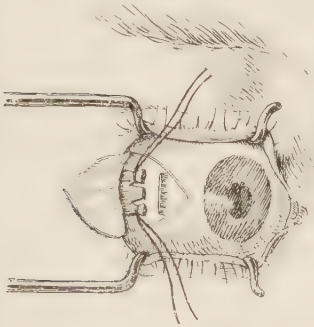

Fig. 844.—Advancement of External Rectus Tendon.

The tendon has been caught by two sutures and divided. The sutures are now ready for reinsertion.

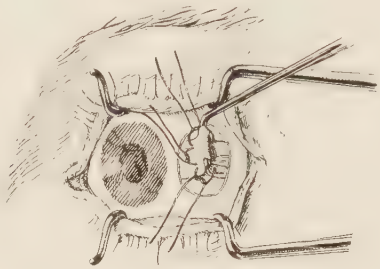

Fig. 845.—Folding Operation for Shortening Muscle.

The tendon is lifted up on a hook, and three sutures placed through the fold.

Advancement of the capsule of Tenon is done through an incision, 1 cm. long, parallel to the corneal border, and 5 mm. posterior to it. The capsule is incised on either side of the insertion of the tendon. Through these two openings the capsule and tendon are undermined, and sutures passed transfixing the tendon, capsule and conjunctiva, and thence through the sclera near the cornea. This makes a fold in the tendon and advances the capsule. It is used in slight divergences.

Operations on the Lacrimal Apparatus. Enlarging the lacrimal canals to give better escape for the tears, should first be attempted by the use of *lacrimal sounds*, if nonoperative treatment has failed. These sounds are from 1 to 3 mm. in diameter. The passage of sounds in the nasal duct, it should be remembered, is through a bony canal, which is directed downward, slightly backward, and slightly outward. The probe should first pass horizontally inward in the canaliculus until it reaches the lacrimal bone, and thence downward into the nasal duct (Fig. 846). If the canaliculus cannot be entered, it must be cut. The lower one usually is dealt with. A filiform bougie can often be made to enter the opening and a small eye-knife passed along beside it; or the special canaliculus knife, with a probe point may be used. The canal should be cut upward and backward. When this has been done, sounds can be introduced. Strictures of the nasal duct may also be divided.

Fig. 846.—Passing Lacrimal Probe through Lacrimal Duct.

Note that the probe passes downward, forward and outward.

Sometimes when the punctum will not receive the point of a lacrimal syringe, it may be dilated with a silver pin.

Excision of the lacrimal sac is required when its infection is intractable. The sac should first be washed out with antiseptic solution. An incision, 2 cm. long, is made along the inner margin of the orbit, the center of the incision being opposite the caruncle. The upper border of the sac is a trifle higher than the level of the upper punctum. The sac lies close to the periosteum in the groove formed by the lacrimal bone and the nasal process of the superior maxilla. The tendo oculi and the tensor tarsi muscle, which covers it, need not be divided. The sac should be dissected free, after the manner of removal of a cyst, and cut off at the nasal duct. If the operation is intended to eliminate the lacrimal drainage system, the canaliculi also should be destroyed. Epiphora follows this operation; and the only excuse for its performance is that a discharge of tears is less objectionable than a discharge of pus. Usually dacryocystitis can be cured; consequently this operation is rarely justified. Skillful surgeons cure dacryocystitis in preference to performing dacryocystectomy.

In chronic suppuration in the lacrimal sac a chip of the nasal process of the superior maxilla and the lacrimal bone may be removed. The inner half of the lacrimal sac is then removed. A sound is passed, and a free opening established.

In skilled hands the endonasal approach to the lacrimal sac is to be preferred. It restores better the natural pathway of tears, probing is made unnecessary, the lacrimal gland is spared, and scar is avoided.

Endonasal operations on the lacrimal sac avoid skin incisions, and in the cases of stenosis give a better access for free opening and drainage. The operation of West is applied to the lacrimal sac. A quadrangular flap of mucous membrane, with its base below, is dissected free along the inner side of the nasal process of the inferior maxilla. The flap should be at a position opposite the lacrimal sac. The area thus denuded represents a space limited by the anterior extension of two lines: the upper marks the attachment and the lower the inferior border of the middle turbinated bone. A part of the posterior border of the nasal process is cut away with the chisel. The lacrimal sac is exposed, and its inner wall cut away. The posterior part of the mucous flap opposite the sac is removed. The flap is replaced and held in position for a day with gauze packing. The nose should be kept free from crusts and the sac should be irrigated through the canaliculus. The operation may be facilitated by first passing a probe and cutting down upon it from within .

Removal of the lacrimal gland is accomplished through an incision beginning at the middle of the upper orbital border, and carried outward and downward just below the level of the outer canthus. The fascia is divided, and the gland is found in the depression of the frontal bone, at the upper and outer aspect of the orbit, just behind the orbital margin. It measures about 1.5 cm. by 0.5 cm. All bloody oozing must be checked so that the gland can be distinguished from the surrounding connective tissue and fat.

The *palpebral portion* of the gland lies anteriorly and is sometimes removed instead of the whole gland. This may be reached through the conjunctiva. The upper lid is everted, the eyeball turned downward, and the enlargement under the conjunctiva at the outer part of the lid is recognized as the gland. This is grasped with forceps, and excised through a wound in the conjunctiva. The wound should be sutured.

Blindness with brain tumors and steeple-skull may be averted by decompression operations.

Treatment of diseases of the eye by subconjunctival injections has a wide range of application. The best points for injection are midway between the recti muscles, and as far from the cornea as possible. Fluid should be used to the amount of 1 to 2 c.c. (15 to 30 minims). Injections may be made painless by adding acoin to the solution. When mercuric solutions are indicated, acoin (1 per cent.) may be combined with a 1:1500 cyanide of mercury solution. Morphin and dionin, 0.008 Gm. (1/8 grain) each, may be added to the solution if much pain is anticipated.

After mercurial injections extreme edema develops. It may extend over the whole side of the face and last for three or four weeks.

The use of salt solutions and glucose is discussed under Glaucoma (pages 131 and 132). Dionin has a wide range of usefulness (see page 118).

THE NOSE

Anatomy.—For purposes of treatment the nose includes the two nasal cavities which are separated by the septum, the accessory sinuses which communicate with the nasal cavities, and the external nose. The *septum* (Fig. 748) is composed of bone and cartilage, covered with mucous membrane.

FIG. 847.—NASAL CAVITY.

Section at a vertical transverse plane, looking forward through nasal cavities. Orbital cavities are above and at the sides.

Of the three *turbinated bones* (or turbinals), the two upper are part of the ethmoid, the lower is a separate bone. The *superior meatus* is situated between the superior and middle turbinals, and into it open the sphenoidal sinus and the posterior ethmoidal cells. The *middle meatus* is between the middle and lower turbinals, and into it opens the frontal sinus, the maxillary sinus, and the anterior ethmoidal cells. The *inferior meatus* is between the lower turbinal and the floor of the nose, and contains the inferior orifice of the nasal duct which is about 2 cm. (3/4 inch) from the floor of the nose (Fig. 847).

The several accessory sinuses all communicate with one another and with the nasal cavity. The largest, the antrum of Highmore (maxillary sinus), opens in its upper part and consequently does not drain well when infected (Fig. 848). The frontal sinus lies in

the frontal bone just above the inner aspect of the orbit. The ethmoidal sinuses are in the body of ethmoid bone; and the sphenoidal sinuses are in the body of the sphenoid. All of these sinuses are lined with epithelium.

Instruments.—For the treatment of diseases of the nose certain special *instruments* are required. These are nasal specula (Fig. 849), tongue depressor, illuminator, applicator, and atomizer (Fig. 850). An electric head lamp is most useful (Fig. 851).

For *nasal splint* purposes many devices are used. A most effective splint is made of simple soft rubber tubing, large enough to fill the nostrils. The tubing should be perforated with fenestra. It may be wrapped with gauze

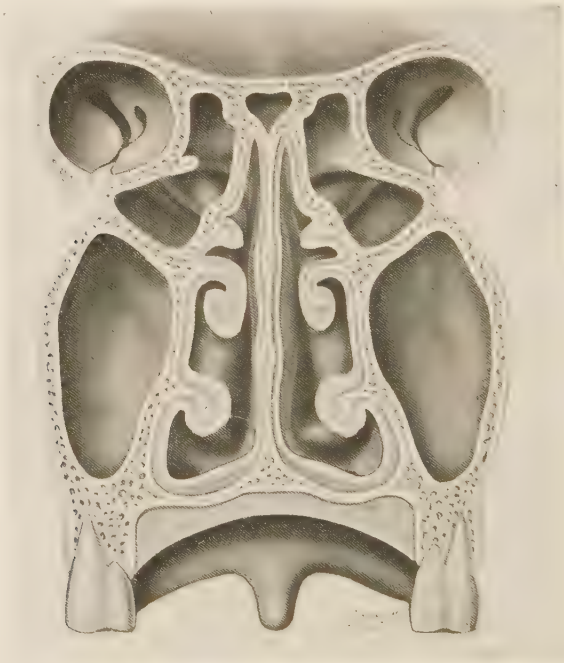

Fig. 848.—Nasal Cavities and Accessory Sinuses.

Section at a vertical transverse plane, looking backward. Maxillary sinuses are below and laterally; orbital cavities are above and laterally; ethmoidal sinuses are internal to orbits.

or it may lie against the mucous membrane. Such pieces of stiff rubber tubing, about 2.5 cm. (1 inch) long, are self-retaining if the front end lies just within the anterior opening and is caught by the upper fold of the nostril. Tubes of this sort do not interfere with breathing as does a solid packing.

In other cases an effective splinting of the nose may be accomplished by packing the nose with gauze. A rubber tube, such as a piece of catheter, should be first inserted and the gauze packed about this. Gauze may thus be packed into the nose to make pressure where desired. The gauze may be controlled better if a sheet of rubber dam is made to surround the tube and the gauze is packed inside of the rubber dam as an envelop. The rubber dam should be perforated so that discharges may pass into the gauze.

A mechanical device of much value is the splint contrived by W. W. Carter (Jour. Am. Med. Assoc., vol. 53, Dec. 4, 1909). This splint is in the form of a clamp which embraces the nose externally. A bobbin is inserted

in each nostril and connected to the splint externally by a silk thread which is passed through the wall of the nose (Fig. 852).

Other splint methods are described under Fractures of the Nose (Vol. I, page 539). See also the packing methods used in epistaxis.

Fig. 849.—Nasal Speculum.

Anesthesia.—For purposes of *local anesthesia* of the mucous membrane cocain solution applied directly is used. The part to be operated upon should be well exposed by means of the nasal speculum, mucus wiped away,

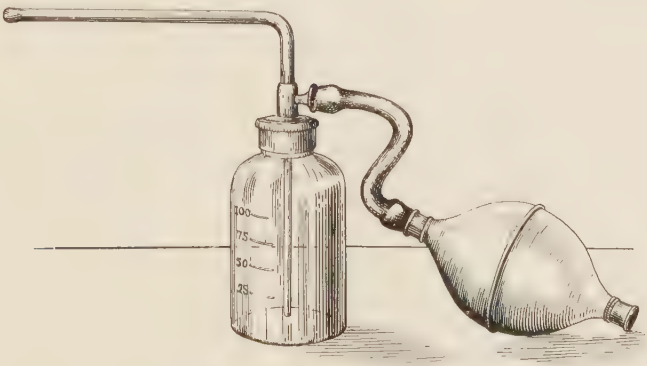

Fig. 850.—Atomizer.

and a 4 per cent. solution of cocain, made up with normal salt solution, should be applied with cotton or gauze on an applicator or forceps. It should be remembered that only the solution which touches the spot is effective, and that it is only necessary to anesthetize the area where pain might be inflicted.

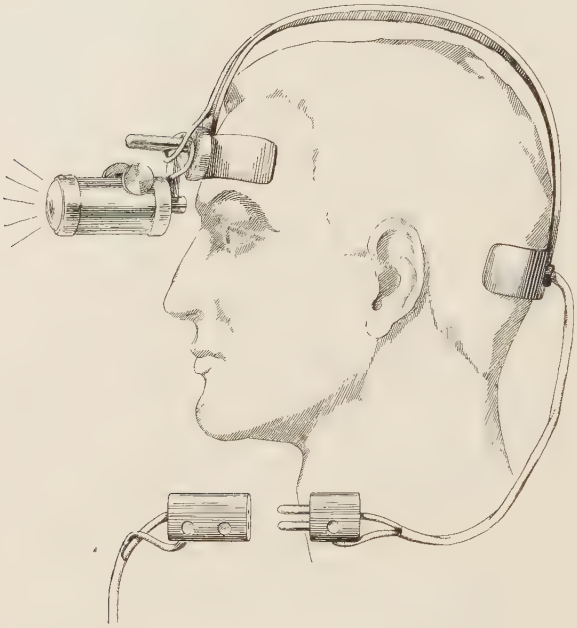

FIG. 851.—ELECTRIC HEAD LAMP.

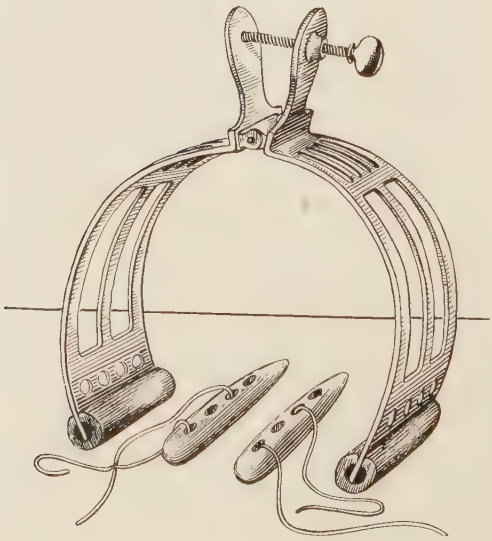

FIG. 852.—NASAL SPLINT.

The metallic bridge presses on the outer parts of the nose; the bobbins are placed within the nostrils. The threads are passed through the wall of the nose and made fast to the outer bridge.

For operation upon a deviated septum the solution should be left in contact with the parts for twenty minutes. To prevent its absorption and action beyond the area of operation, the saturated pledget of cotton may be enclosed in a little pocket of rubber tissue having an opening on one side where the cotton is exposed. The lines of incision may be painted with a 10 or 20 per cent. solution. Before operating, adrenalin chlorid solution should be applied to make the effect of the cocain more lasting. For small operations the solution need be applied only a few minutes.

It is always undesirable to use cocain solution in an atomizer because of the uncertainty of the dosage, the large area exposed to absorption, and the uncomfortable sensation caused in the throat. The substitutes for cocain are also used (see Local Anesthesia, Vol. I, page 127).

Local Vasoconstriction.—For purposes of *hemostasis* and local *vasoconstriction, adrenalin chlorid* is used. To produce local vasoconstriction, a 1 : 1000 solution is applied directly the same as the anesthetic. The use of this substance causes a blanching of the mucous membrane. In local congestion a 1 : 5000 or a 1 : 20,000 solution is employed. As the effect wears off, it may be reapplied. It is even more effective when used in an ointment or in liquid petrolatum.

Cleansing and Antiseptic Preparations.—Sterilized normal salt solution has the widest range of usefulness for cleansing the nasal mucous membrane. When slight antisepsis is desired the following is useful: Sodium bicarbonate, 4 Gm. (1 dram); sodium biborate, 4 Gm. (1 dram); phenol, 2 Gm. (½ dram); glycerin, 30 c.c. (1 ounce); water, 1000 c.c. (1 quart). This is used for irrigation or as a spray and is unirritating, if applied warm. Another useful preparation is made by substituting for the phenol in the above combination the following: sodium salicylate, 0.2 Gm. (3 grains); menthol, 0.06 Gm. (1 grain); and thymol, 0.06 Gm. (1 grain). There are proprietary preparations, such as alkalol, borolyptol, glycothymolin, and listerin, all of which are of value. As a protective application to the mucous membrane, liquid petrolatum is of service. It may be used to carry bland antiseptic substances which are not soluble in water. Camphor, 0.6 Gm. (10 grains), to liquid petrolatum, 30 c.c. (1 ounce), is sedative and mildly astringent. Menthol, substituted for camphor in the same amount, used with an atomizer, is analgesic as well as antiseptic.

A solution of antipyrin, 0.6 to 2 Gm. (10 to 30 grains) in 30 c. c. (1 ounce) of water used with the atomizer, is antiseptic and vasoconstricting. A 50 per cent. solution painted locally is decidedly analgesic.

A powder which has analgesic and antiseptic properties for use in acute congestive conditions of the nasal mucous membrane is the following: menthol, 0.06 Gm. (1 grain); sodium bicarbonate, 0.12 Gm. (2 grains), magnesium carbonate (light), 0.2 Gm. (3 grains); cocain hydrochlorate, 0.25 Gm. (4 grains); and milk sugar, 6 Gm. (90 grains). This is employed as a snuff, the dangers of cocain being borne in mind.

For use in the nebulizer the following is useful: oil of cinnamon, 1.2 c.c. (20 minims); oil of eucalyptus, 1.2 c.c. (20 minims); menthol, 2.5 Gm. (40 grains); camphor, 5 Gm. (80 grains); fluid petrolatum, 240 c.c. (8 ounces). An effective antiseptic, analgesic, vasoconstrictor preparation is—adrenalin chlorid solution (1 : 1000), 1.2 c.c. (20 minims); menthol, 2.5 Gm. (40 grains); oil of gaultheria, 1.2 c.c. (20 minims); glycerin, 60 c.c. (2 ounces); water, 240 c.c. (8 ounces).

Injuries of the Nose.—*Wounds of the nose* should be treated with especial reference to cosmetics. Skin edges should be sutured with niceness. *Fractures* of the nose have been discussed (Vol. I, page 539).

Epistaxis (nosebleed), may result from disease or injury. Usually disease is the cause, and when the constitutional or local disorder is removed, the attacks cease. In most cases the bleeding subsides spontaneously. In children, foreign bodies should be thought of. Stimulation of the vasoconstrictor nerves by stretching the cervical sympathetic in the following manner stops mild nosebleed: The surgeon stands behind the seated patient, places his hands at the sides of the head and under the angles of the jaw, and lifts the head upward, at the same time rotating the face slightly upward.

Slight bleeding may be checked by elevating the head, inhaling through the nose and exhaling through the mouth. Pressure upon the nasal alæ is of service. Snuffing into the nose iced water, powdered alum, tannin, 10 per cent. solutions of these drugs, or vinegar is useful. Sodium perborate powder insufflated into the nose with a blower checks small hemorrhages. Other astringents are employed, such as acetate of lead, sulphate of copper, sulphate of zinc, in 10 per cent. solutions. These may be used on pledgets of gauze.

It is best to locate the site of the bleeding, if it is not easily stopped, and apply the necessary treatment to the bleeding point. Usually it comes from a small vessel in the anterior lower part of the septum, which may be dealt with directly. If the bleeding is a general oozing from a congested mucosa, adrenalin (1 : 1000) applied on a pledget, may control it. This is rarely the case, and when it is, it is difficult to bring the drug in contact with the mucosa because of the blood.

Ulcerated spots which are bleeding may be touched with the silver nitrate stick or with 15 per cent. solution of chromic acid. Collodion applied to the bleeding region is of service. Simple pressure may be made by grasping the nose between the fingers and holding the nostrils pinched together. If the bleeding is from an anterior vessel this suffices.

Of more value than all of these tentative procedures, is the usual surgical treatment of hemorrhage, namely, pressure upon the bleeding vessel. This should be done by the aid of sight. A speculum should be introduced and with a good light the bleeding point should be discovered. Gauze should be packed directly upon it and that part of the nose filled with gauze. A rubber tube may be admitted and the gauze packed around it. This is the best treatment of intractable cases.

When the bleeding point cannot be seen, then simple packing of the lower chambers of the nose should be practised. The packing need not involve the extreme posterior part unless it is known that the blood comes from there. In these cases needing gross packing, pressure is best made by means of a packing of gauze. A piece of fine sterile muslin, linen or rubber dam, about 15 cm. (6 inches) square, should be folded over the end of a pair of forceps or other straight instrument, which should impinge against its center. The instrument, carrying the square should be passed back beyond the bleeding point to the posterior wall of the pharynx. The edges are spread out externally on the face. The instrument is withdrawn, and the end of a sterilized gauze bandage is passed with a straight probe or forceps through the anterior nares and is packed inside of the square well back into the nose. The bandage should be packed in with considerable force until the nose is full. In most hemorrhages this suffices. The gauze should be about 2.5 cm. (1 inch) wide. It will remain sweet and cause less irritation if it is impregnated with some mild antiseptic, such as 8 per cent. solution of antipyrin, europhen powder, or the pulvis antisepticus of the National Formulary.

Instead of the square described above, the thumb of a large, thin rubber glove may be covered with a mild antiseptic powder or ointment and inserted

in the nose. The open end anteriorly is held open with four hemostatic clamps while the interior of the finger is packed with dry gauze. This packing is continued until the rubber finger is distended sufficiently so that its pressure stops the bleeding. If desired, more pressure may be secured by wetting the gauze after it is inserted. This gauze may be removed without fear of pain or of reawakening hemorrhage. Another device is a simple cigarette roll of gauze enveloped in rubber tissue.

Whatever method of packing is used, it should be removed at the end of twenty-four or forty-eight hours, and renewed if necessary. The gauze packing is first pulled out. The external covering should be left for twelve hours longer.

When these methods fail, or when the bleeding is from a vessel far in the back of the nose, packing of the posterior naris is called for. This is easily done by the aid of the canula of Bellocq (Fig. 853), a rubber catheter, or any other instrument which can be made to carry a loop of string to the back of the nose. The instrument is armed with a string, and passed from before backward through the nose. When the string appears below the palate it is seized in the mouth with long forceps and drawn forward. A plug of gauze or wool large enough to plug the naris is tied to it. This is then pulled back through the mouth and up over the palate by making traction

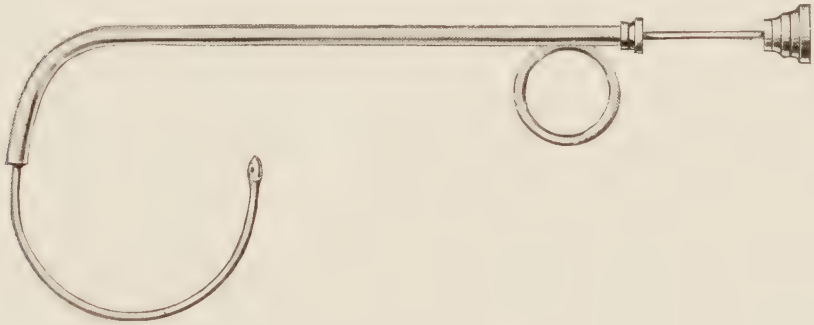

Fig. 853.—Canula of Bellocq.

upon the other end which emerges through the anterior naris. The posterior end may be left emerging through the mouth for removing the plug. The nasal string may then be tied down upon an anterior plug, thus effectually occluding the nose anteriorly and posteriorly. It is well to fill the nose with gauze before tying in the anterior plug. In some cases each nostril may require to be plugged in this way.

Packing of the nostrils should not be so tight as to cause pressure-sloughing of the mucous membrane, which sometimes occurs in unskillful hands. The amount of pressure sufficient to stop the bleeding does not require to be great. Packing should not be left in longer than two days. If these rules are not observed, undrained septic material may accumulate and provoke serious infection. After carefully removing the packing, the nasal cavity should be irrigated with warm solution, and the patient kept quiet for several days.

The surgeon should bear in mind that nose bleed is often salutary. If the blood-pressure is above 160 mm. the surgeon should allow the bleeding to continue. In all cases the patient should be kept quiet. Morphin may be used if necessary. The feet should be made warm. Constitutional causes should be looked for and remedied by the physician.

Infections of the Nasal Cavities.—*Simple acute rhinitis* should be met by the correction of constitutional derangements of etiologic importance. Fresh air and freedom from auto-infections are essential. Locally the nose should be irrigated or sprayed with one of the cleansing antiseptic applications (page 183). Adrenalin chlorid, combined with one of these or alone, contributes much to the comfort of the patient and shortens the disease. Hot applications to the nose and brows relieve the feeling of tension and increase the curative hyperemia. When the congestion is extreme and the discharge disagreeable, comfort is secured by the internal use of camphor, 0.03 Gm. (½ grain); extract of belladonna, 0.007 Gm. (⅛ grain); quinin, 0.06 Gm. (1 grain); every hour until dryness of the mucous membrane is secured.

After the acute stage the nostril should be kept washed with one of the alkaline antiseptic solutions, which may simply be poured into the nose and allowed to run back to the pharynx. If the discharge continues and is thin and profuse, astringents, such as 2 per cent. formalin or chlorid of zinc solution, may be used. Or a few drops of watery extract of hydrastis (1 part) in water (3 parts) may be introduced in the nostrils three times daily.

For the prophylaxis of this condition free nasal breathing is essential. Persons with narrow nostrils or nasal obstructions should have the condition corrected by dilatation, plastic operation, or removal of the obstruction.

In the presence of nasal infection, *blowing the nose* does not give good drainage. It drives infective material into the accessory cavities. Better cleansing and some increase of hyperemia is secured by forcible inhalation through the nose, and expectoration of the material thus sucked back through the posterior nares. Blowing the nose is unsurgical.

In *young children*, the local treatment should consist in dropping into the nose warmed normal salt solution, followed by warmed boric acid solution (1 per cent.). The nose is emptied by grasping it between the fingers, and drawing them forward a few times. After the cleansing a few drops of liquid petrolatum may be introduced.

Membranous rhinitis should first have remedied the underlying constitutional disorders. A warm alkaline douche should be used often, and hydrogen peroxid several times daily. After the membrane has come away, one of the oily preparations should be employed.

Chronic Rhinitis.—*Simple chronic rhinitis* demands the discovery and removal of the cause and relief of the local disturbances. Constitutional toxemias play an important rôle, and local treatment is of little avail unless the general disorders are corrected.

The *suction treatment* of rhinitis is of decided value. A negative pressure of 120 mm. Hg. is used. This not only gives the benefit of suction to the diseased mucous membrane but also cleans out the accessory sinuses.

Hypertrophy of the turbinates, remaining after the above conditions have been met, if sufficient to cause some obstruction, should first be treated by compression. This is accomplished by means of a silver tube which shall crowd aside the swollen structure. This should be worn at first for a few hours each day; and later it may be worn all day. Another method consists in making multiple incisions down to the bone. Only when there is an actual increase in the bony structure is the bone to be removed.

The operation of *removal of the turbinate bone* is not called for if it is not producing obstruction. Nor should the operation leave one nasal passage larger than the other. As little scar as possible should be left. Cauterization is objectionable. A portion of the bone is best removed by making

an incision through the soft tissues, elevating them from the bone, and cutting out the latter with bone forceps.

Hyperplastic rhinitis should be treated at first as simple chronic rhinitis. The mucous membrane being gotten into the best condition possible, removal of hypertrophied tissue is called for. This removal should include the bony turbinate tissue if it also is hypertrophied. The object of the operation is to give adequate breathing room. Many methods of operating have been devised—complicated by a multitude of names and apparatus. Simple surgical principles require the removal of the obstructing tissue with as little traumatism, scar and hemorrhage as possible. Cocain and adrenalin chlorid make the operation simple. Anterior hypertrophies are easily removed, the surgeon using scissors, cutting forceps, wire snare, saw, saw-scissors, or knife, whichever suits his convenience. It is neither necessary nor wise to perform long and extensive operations. Several sittings may be given to aggravated cases. Some surgeons employ the actual cautery, galvanocautery, or chromic acid cauterization to destroy anterior hypertrophies. These methods require especial skill, should not be used posteriorly, leave much scar, and ultimately do not give as good results as the cutting operations. A clean operation may be done by making a V-shaped incision or cutting out an ellipse and undermining the mucosa so that it falls together over the wound.

Hypertrophies in the posterior part of the nose are best removed by the snare. In order that it shall engage posteriorly a mirror in the back of the mouth or the finger passed up back of the palate may be of assistance. The wire should be tightened slowly to minimize bleeding. Posterior hypertrophies which cannot be snared are best removed with scissors.

After these operations the cavity should be cleansed several times daily with an alkaline antiseptic wash.

Atrophic rhinitis requires cleansing of the nose several times daily with an alkaline antiseptic wash. Crusts must be kept removed. The use of an oily application once or twice daily is of service. A good preparation is oil of eucalyptus, 1 part, in liquid petrolatum, 80 parts. Stimulation and antiseptic action may be secured every third day by the insufflation, after cleansing and drying the nose, 0.3 or 1.2 Gm. (5 or 20 grains) of silver nitrate in 30 Gm. (1 ounce) of stearate of zinc.

The method of Gottstein has found much favor. This adds to the cleansing treatment the application of a roll of absorbent cotton placed the full length of the floor of the nasal cavities. A cotton cylinder is made by rolling the cotton about a smooth applicator to a bulk which will easily pass through the nose. It is placed upon the floor of the nose and the applicator withdrawn by turning it in the opposite direction. The patient should do this himself, removing the plugs when they become saturated. This treatment stimulates the mucous membrane, removes discharges, and prevents inspissation. It is curative in a small proportion of cases. When discontinued it is apt to be followed by recurrence of the unpleasant symptoms.

The important feature in the treatment of this disease is the removal of exciting causes both constitutional and local. Diseases of the accessory sinuses especially should be cured. When infection gives rise to profuse purulent discharge, astringent douches should be used. Sulphocarbolate of zinc, 1.2 Gm. (20 grains) in 30 c.c. (1 ounce) of water is of value.

Scab formation in the nose requires the treatment given above for atrophic rhinitis. Iodid of potash internally in large enough doses to keep the nasal secretion in a thin fluid state also prevents scab formation.

Ozena is a symptom of nose disease which requires treatment according

to its etiology. Besides remedying the local disorder, vaccine treatment has proved of value. The typical symptoms are found associated with the presence of the *Coccobacillus fœtidus ozœnæ* of Perez, and most gratifying results have been obtained by vaccine treatment with this organism. Vaccine treatment with *Micrococcus catarrhalis* of Friedländer is useful in some cases.

Specific Nasal Infections.—These infections require the same treatment as in other parts (see Syphilis, Tuberculosis, Glanders, Leprosy, Actinomycosis, Rhinoscleroma). The nose should be kept cleansed, and obstructions should be removed.

Tumors.—*Benign tumors of the nasal cavity* should be removed if they cause obstruction, irritation, or reflex disturbances. Usually they should be removed. Pedunculated tumors are best treated by means of the wire snare. The constriction should be made slowly to avoid bleeding. Cysts may often be incised and curetted. In removing sessile growths a curved incision, turning a flap of mucosa upward, is to be preferred. Angiomata may be removed by the snare, ligature, excision, or cauterization. *Malignant tumors* should be removed if recognized early. Tumors which are not easily accessible are approached by an osteoplastic flap (see Resections of the Superior Maxilla, Vol. I, page 717).

Rhinophyma, the unsightly result of acne rosacea, may be excised with much satisfaction. Under general anesthesia, an incision is carried around the anterior borders of the alæ and across the middle line. If necessary, this may be joined by a median incision on the dorsum of the nose. The redundant tissue is dissected up from the nasal cartilages in the form of a flap. The redundant part of this flap is then cut off, and the wound closed. Irregularities remaining may be shaved off at a later sitting. This latter step of the operation is feasible because of the great depth to which the skin follicles penetrate in this disease. In aggravated cases the mass may be removed as a tumor and the remaining surface covered with skin grafts (see Plastic Operations, Vol. III).

Foreign Bodies.—Foreign bodies may be removed by grasping them with curved forceps. *Rhinoliths* sometimes require to be crushed by strong forceps and washed out. Smaller bodies may often be washed out, or blown out by having the patient inspire, block the other nostril and mouth, and exhale forcibly through the affected nostril. *Animate foreign bodies*, such as maggots, insects, leeches, intestinal worms, etc., may usually be washed out with mild antiseptic solution. If this fails, chloroform is effective. It should first be used by inhalation through the affected nostril, preferably in strong vapor as secured by the Junker inhaler. This failing, the fluid should be injected into the nose. It should be diluted with equal parts of water, and the patient should be anesthetized on account of the pain. Other substances, such as turpentine, formalin solution, and iodoform emulsion are used. A foreign body in the nose of a child may be removed by inserting a rubber tube in the other nostril, covering the child's mouth with the hand, and blowing suddenly into the tube.

Foreign bodies in the accessory sinuses or buried in the tissues often require a cutting operation for their removal.

Malformations of the Nasal Septum.—*Deflections of the septum* require to be corrected because of the inequality of caliber of the nasal passages which are caused by them. If there is no inequality or obstruction, operation is not necessary. In deflections of the septum, the turbinates in the enlarged nostril will be found hypertrophied. This hypertrophy is compensatory and physiologic, and will usually correct itself after the deflection has been cured.

In mild cases of deviated septum, if the cartilage is soft, as determined by

pressure of the finger, no operation is needed. The septum should be pressed in place and held by means of a nasal tube (Fig. 854). Such a tube should be entirely in the nasal cavity. The tube is best made of silver, in order that its shape may be changed. Hard rubber is also used. In lieu of such an appliance, ordinary rubber tubing may be employed. Soft tubing may be reinforced by drawing a second tube inside of it. The inner tube may be one of smaller caliber or of the same as the outer tube but made to fit by having a longitudinal section removed. The tube should have its ends smoothed and be perforated for drainage. It should not make much pressure. At first it should be worn for a few hours each day. As tolerance develops, it may be worn all day. Several times daily the nose should be irrigated with cleansing solution. Ulceration from pressure should not be permitted. After a while the tube may be left out for a day at a time, or worn on alternate days. The surgeon should keep in touch with the condition. The change of position and the pressure set up a slight inflammation which ultimately fixes the parts in their new position. Six weeks at least are required for the completion of the cure; but for several weeks longer the septum should be watched, and treatment renewed if there is a tendency to relapse.

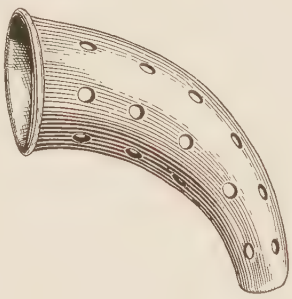

Fig. 854.—Nasal Tubular Splint.

Bulges of the septum, involving one side only, are best treated by cutting the deflection as though it were a tumor. A curved incision with its convexity downward, reaching to the bottom of the bulge, is used to turn up a flap of mucous membrane. The deformity is then cut off with a sharp knife, saw, or forceps, and the mucous membrane flap replaced, to be held by a suture or tampon (Fig. 469).

In cases in which the septum is not easily pressed in place, and this is the case in most instances, it must be incised to render it flexible. The incision has the advantage also of producing plastic inflammation. In incising a deflected septum it is usually best to make a groove rather than a simple incision, the removal of tissue facilitating the change of position. A V-shaped file has been invented for this purpose by G. Fetterolf. In making such incisions, wherever possible, it is best to turn up a flap of mucous membrane so that the wound of the cartilage is covered after the operation. When this cannot be done the results from a practical standpoint seem to be about as good if the mucous membrane and cartilage incisions are made by the same stroke. If within reach, a suture may be put in the mucous membrane flap; or it may be held in place by the nasal tube. Unless much care is taken in its adjustment, it will curl up. Some of the usual conditions to be met and the incisions required are shown (Fig. 855). The incisions in the cartilage are made with an angular knife (Fig. 856) which is made to cut out a long ellipse involving nearly the whole thickness of the septum. It is best to avoid passing through both mucous membranes of the septum.

These operations may be done under cocain anesthesia, although in aggravated cases, general anesthesia is more satisfactory. Adrenalin may be depended upon to keep the field free from blood. For bending the septum into place and making temporary overcorrection, septum forceps (Fig. 857) are used. I have found strong pedicle forceps sufficient, both for grasping the septum and for dilating an occluded nostril. After the operation the nasal tube should be used as above described. In some cases a tube in each

nostril is useful. The parts do not become much fixed with exudate until after forty-eight hours. If there is great swelling the tube should be removed for several hours each day.

The incisions usually required are two parallel incisions, one on either side. In irregular deflections, I have secured perfectly satisfactory results by making an H incision or an X incision, involving the whole thickness of the septum. These wounds may be expected to heal without leaving a perforation; although the operation is not the ideal one. The operator should

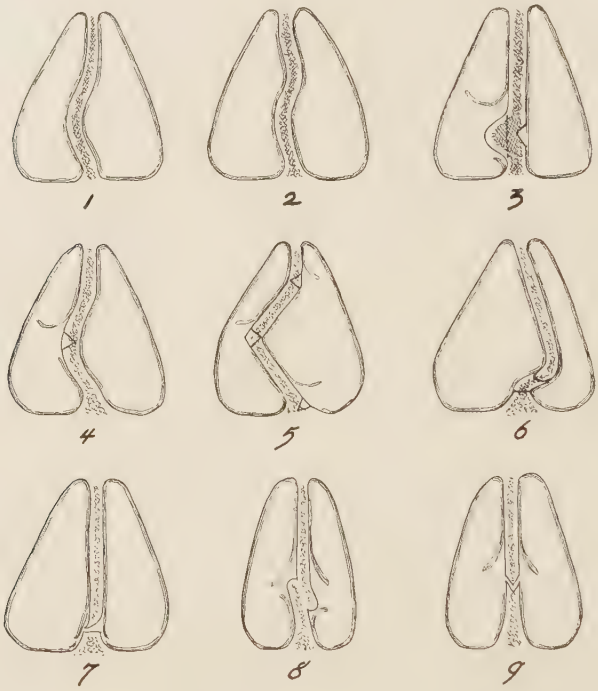

Fig. 855.—Deflections of the Septum.

1, If the cartilage is soft, this can be corrected by pressure alone; 2, does not require treatment; 3, mucous membrane flap should be elevated and the bulge removed along the dotted line; 4, showing mucous membrane flap elevated and gutter of cartilage to be removed, after which pressure will correct the deformity; 5, gutters of cartilage in three places must be removed and correction maintained by pressure of a tube in the nostril; 6, this must be treated by removing a piece of the septum as shown between the two incisions; 7, the condition in 6 is corrected in this; 8, flaps of mucous membrane are reflected and a segment of the over-riding cartilage removed; 9, correction of 8 is shown in this.

not be satisfied until he has broken up the resistance of the septum, and made it possible to keep it in its new position without undue pressure. No operation is adapted to all cases; the peculiar conditions in each case should be met. If the surgeon has in mind a sufficient number of expedients, every condition can be coped with.

The *submucous resection* of septal cartilage has certain advantages over the other operations, especially in angular deflections with redundancy of tissue. If there is obstruction due to hypertrophied turbinates that should first receive attention. The operation may be done in either nostril. If possible it is best done on the convex side. If done in the concave side more

room is had. The surgeon stands on the side to be operated upon. For a right-handed operator, the left nostril is most accessible. Local anesthesia is used in adults. The deflected septum should be forced back by instruments or with the finger to render it pliable. The nose is held open with retractors. A vertical incision is made along in front of the deflection, if possible posterior to the free anterior border of the septal cartilage. It should pass down to the floor of the nose. It should curve backward at its lower end, and proceed back below the deflection. The incision should pass through the mucous membrane and slightly into the cartilage. A

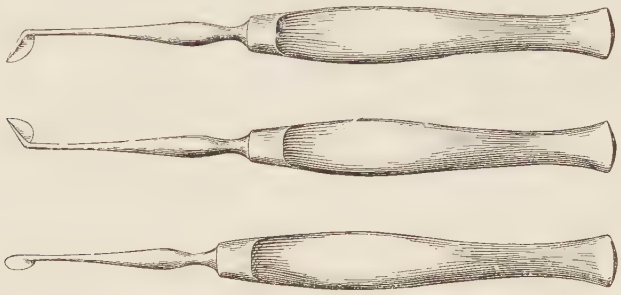

Fig. 856.—Angular Knives Used for Operations on the Septum.

sharp and narrow elevator should be inserted and the mucous membrane and perichondrium covering the deformity lifted away from the cartilage as far back as possible. With a sharp curet or swivel knife an opening is scraped through the exposed cartilage. Through this opening the elevator is passed and the mucous membrane and perichondrium lifted away from the septum on the other side.

Care should be taken not to penetrate the mucosa. The bulging part of the septum is now cut away by pieces with the fine rongeur forceps. As



Fig. 857.—Septum Forceps.
For holding, bending and shaping septum.

the morcellement progresses the elevation of the uncut mucosa proceeds, a finger in the nostril protecting it from penetration. The operation may be continued until all of the bulging cartilage has been removed. It is necessary to leave a bridge of cartilage at the anterior border to prevent falling of the tip of the nose. The flap of mucous membrane is put back in place and fixed by one or two sutures or it may be held by a carefully applied tampon. The tampon should be saturated with petrolatum. The dressing may be removed in twelve hours. Some surgeons obviate the need of dressing by passing a few quilting sutures through and through. Fine catgut is used. No nasal

tube is required. The lines of incision through the mucous membrane may vary to meet the conditions present. After resection of the septum, there is danger of deformity if the nose receives a traumatism which flattens it.

Instead of making an incision with the horizontal limb posteriorly, many rhinologists prefer to make the vertical incision at the back of the deformity, and carry the horizontal incision forward from its lower end. Whatever operation is done, sharp edges and angles projecting under the mucous membrane should be removed.

The *transplanting of cartilage* is practised with success in many of these cases. The cartilage which must be removed from the septum is excised in the form of a piece, large enough for use, and placed in warm salt solution. One or two pieces may be employed. These pieces are placed between the mucous flaps, and the wound sutured. This operation may also be used in the treatment of perforation of the septum.

Lateral deflection of the nose is treated by making a short incision parallel with the long axis of the nose, at the anterosuperior border of the convex side, about the junction of the cartilage and nasal bone; through this a narrow

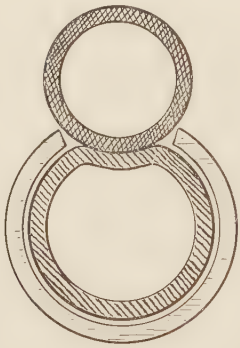

Fig. 858.—Method of Using Rubber Tubes to Support a Depressed Nose.

Three tubes are here shown. The lower outer one is split lengthwise. The tubes should be of thick rubber. If they are too soft they may be reinforced by drawing one inside another. This apparatus may be held together by two silk sutures or silver wire at either end. It is of use also in fractures of the nose. A new set must be made often, as the tubes soon lose their resiliency.

knife cuts out an ellipse of cartilage, along the lower border of the nasal bone and the upper part of the nasal margin of the superior maxilla. If possible this operation should not open the mucous membrane, but if it does, no great harm is done. The removal of this ellipse should allow the nose to be pressed over in its normal line. A suture of chromic catgut should be put through the cartilage below and caught in the periosteum above without penetrating the skin. The skin wound should be sutured and the nose held in a corrected position by a pad of gauze and adhesive strips. At least a month should be given to the consolidation of the cartilage. Deflection of the septum, which is usually present in these cases, should also be treated.

Saddle-nose.—This condition, due to disease destroying the lateral and triangular cartilages or to injury displacing them backward, should, if possible, be treated in its early stages. After an injury the depressed and broken cartilages should be lifted up by instruments passed in the nose. They may be kept elevated by the introduction of perforated rubber tubes, preferably a large one below supporting a smaller one resting upon it (Fig. 858).

In old cases there is often depression of the nasal bones and sometimes separation of the nasal processes of the superior maxilla. This should first be corrected. A short incision is made along the front edge of the nasal process and an osteotomy done, severing the process from the body of the bone. This is done on each side. The nasal bones are then broken loose from their attachments by forceps thrust into the spaces made by elevating the skin and mucous membrane from their upper and lower surfaces. The bones, thus loosened, are elevated within the nose by a rubber or metal splint, and the nasal processes compressed from the outside (see Fractures of the Nose, Vol. I, page 539). After the bony parts have healed, in about two months, an attempt to restore the soft structures may be made.

There are many operations confined to the intrinsic structures of the nose, for this purpose, none of which is wholly satisfactory. A procedure applicable to the largest range of cases will be described. An incision is carried around the anterior margins of the alæ and tip of the nose, and the skin dissected free as far back as the bony margin of the nares. A flap is

Fig. 859.—Saddle-nose, Treated by Swinging up Half of the Lateral Cartilage from Either Side.

then cut from the upper part of the lower lateral cartilage. This flap should represent about half of the lateral surface of the cartilage and have its base toward the median line (Fig. 859). This is done on each side. A suture of chromic catgut is then passed through the junction of the upper lateral and septal cartilage close to the nasal bones. This suture should cross the median line from one side to the other and include only enough of the cartilage to give a good hold. Each end of this suture is then passed through the outer end of the flap of cartilage. As the suture is drawn up and tied, the flaps are drawn up to the median line at the nasal bones and made to overlie the superior lateral cartilages which are usually atrophied and depressed. The skin flap is then brought down and sutured in place.

At the same time that this operation is done or at another sitting, the septum should be straightened and elevated. Usually it is found distorted and depressed. A good practice is to make long horizontal incisions through one mucous membrane and the cartilage at each bend, and not only correct the deflections but insert such a nasal tube as shall lift up the whole nasal bridge.

A method which I have applied with better success than it deserves consists in the *introduction of a bridge of hard rubber* under the skin. A waxen impression of the contour of the nose is first made, and a bridge of hard rubber constructed which shall fill the depression (Figs. 860 and 861). The

Fig. 860.—Saddle-nose before Operation.

prosthesis should be perforated to permit the ingrowth of fixing tissues. The skin should be dissected up from the edges of the alæ and tip of the nose back to the nasal bones and nasal process. Bleeding should be stopped and the prosthesis slid into place, to be covered by the skin. The operation must

Fig. 861.—Saddle-nose Treated by the Subcutaneous Implantation of Hard Rubber Prosthesis.

This is a case operated upon by the author twenty years ago, before osteoplastic surgery had been perfected. The picture shows the condition three weeks after operation.

be clean. It has the disadvantage of leaving a foreign body which may at any time make trouble. If the septum is not straightened and the bridge lifted up the physiologic defect remains.

The same objections inhere in the use of *paraffin*. It has been much

employed for the cosmetic treatment of saddle-nose. It is more prone to cause ulceration and abscess than one might judge from the literature (see Paraffin in Surgery, Vol. III).

The *plastic operations*, in which tissues external to the nose are used, is described elsewhere (see Plastic Operations on the Face, Vol. III).

Collapse of the Alæ.—This condition may be remedied by systematic exercise of the dilator muscles of the nostrils. The use of a perforated silver tube, placed just within each nostril, and worn as many hours of the day as possible, not only helps correct the deformity but gives better breathing. When these methods do not suffice, the nasal openings may be enlarged by carrying the bases of the alæ slightly outward; or by making a horizontal incision through the middle of each ala and closing it as a vertical wound. This latter procedure is indicated when the edges of the alæ are curled inward (see Plastic Surgery of Face, Vol. III).

Nasal Synechia.—When the condition interferes with nasal respiration, it should be operated upon. Bony growths should be removed by the saw or forceps. Synechia of soft structures may be divided with the knife. If possible, tissue should be removed so that there is enough separation to prevent recurrence. The wound surfaces should be kept covered with gauze. Frequent cleansing should be practised. Exuberant granulations, if they coalesce, will defeat the operation. They should be suppressed with silver nitrate.

Perforation of the Septum.—This condition, if due to ulceration, should be met by treatment of the infection and necrosis. When the perforation is clean and no ulceration is present it usually requires no treatment. If treatment is called for, a sliding flap of mucous membrane on either side, not taken from opposite areas, may be used.

Acute Catarrhal Inflammation of the Antrum of the Superior Maxilla.—This should be treated as acute rhinitis. To facilitate drainage through the one small opening into the nose, adrenalin chlorid solution should be applied to the *orifice*. This is located just above the middle of the inferior turbinate bone, a trifle below the level of the floor of the orbit. Ichthyol, 25 per cent., in hydrated wool fat, may be applied to the middle fossa of the nose. Should secretions be retained, drainage at a dependent place becomes necessary. Any diseased teeth should receive attention.

Chronic Catarrhal Inflammation of the Antrum.—This may be cured by irrigation of the antrum through the ostium. Rarely can this be done easily or satisfactorily. Usually drainage at the lower part of the antrum, as for empyema, is required before a cure is affected.

Empyema of the Antrum.—This should be treated by first emptying the cavity of pus. The place of choice for *drainage of the antrum* must depend upon the cause of the suppuration. If it is of dental origin, the offending tooth should be extracted and the antrum opened through its socket. In infection of nasal origin, the nasal disease should receive treatment. Many surgeons prefer to make an opening from the inferior fossa of the nose into the antrum. This should be made at a level with the floor of the nose below the natural opening, about 3 cm. behind the anterior end of the inferior turbinate. A sharp-pointed curved knife or an angular knife is used to make a small V-shaped cut. A trocar may be used. Through this opening the antrum may be irrigated and treated as any other abscess cavity. Insufflations with boric acid or iodoform are also used. Such an opening should be enlarged, if drainage is not adequate.

For drainage of the antrum, preference is to be given to the opening through a tooth socket. Rarely is it necessary to sacrifice a sound tooth.

When there are no diseased teeth an opening may be drilled in the interval between the first molar and bicuspid teeth on the palate side. If there is a diseased tooth or an absent tooth between the first bicuspid and the first molar, the opening should be made in its socket. The opening can best be made with a dental drill, although a hand drill suffices. The hole should be not smaller than 5 mm. in diameter. Local anesthetic injected into the gum gives analgesia. After the cavity has been washed out the opening should be kept plugged with gauze. Irrigation should be practised daily. A small canula of silver, slightly flanged at the upper end, may be fitted in the opening. Food does not enter this small opening. The patient can make the daily irrigations with a hand bulb syringe. If the tube or gauze packing is left out the sinus usually will close spontaneously.

If the secretion does not steadily diminish, and has not ceased entirely in the course of three or four months, it should be assumed that there is present a local disturbance which requires more radical treatment for its removal. Granulations, a foreign body, a polyp, or necrosis of the walls of the sinus may be present.

The sinus not healing, *free opening of the antrum* should be made. The operation may be done with local anesthesia. An incision is made through the mucous membrane and periosteum horizontally along the outside of the alveolar process from the canine tooth to the second molar. The soft tissues are elevated upward away from the bone, and the wall of the antrum opened by a trephine or chisel. The opening should be enlarged with the rongeur until the interior of the sinus can be freely inspected. If, on account of bleeding, a good view cannot be had, the cavity may be packed with gauze and further treatment deferred. Inspection should reveal the cause of the continued suppuration. Granulations should be cut down and cauterized, tumors, foreign material, or necrosed bone should be removed. Septa, which are retaining secretions, should be broken down. If there is disease of the ethmoid cells, communicating with the antrum, the ethmoid should be curetted out. The subsequent treatment should consist in daily irrigation and packing with gauze. Iodized gauze answers admirably. The opening into the mouth will persist for months or years, and may never close. The patient should learn to irrigate it and care for it daily. A rubber or gold obturator should be made by a dentist to cover it.

When it becomes necessary to secure a large opening for free drainage, the opening should be made in the nose. Such an opening may be expected speedily to cure chronic suppuration. The anterior half of the inferior turbinated body should be removed. An opening extending from the floor of the nose as far up as the middle meatus is made. If it is desired to make a permanent opening, the mucous membrane should be removed. This is done in bad cases. If temporary drainage is aimed at, the mucous membrane should be elevated on either side of a vertical incision in the outer wall of the nose, and bone alone removed. The mucous lining of the antrum is also retained. This constitutes a submucous resection of the outer wall of the nose. A burr or a chisel may be used for this operation. Free drainage having been secured it is best not to destroy the mucous lining of the antrum by curetting. The drainage alone will suffice to cure most cases of suppuration.

When the patient wishes to be rid of the opening at the price of cosmetics or when the treatment requires more radical measures, *obliteration of the antrum* may be done. The elevation of periosteum and soft tissues from the front of the bone should be carried up to the infraorbital canal, inward to the nose, and outward to the malar bone. The whole front wall of the

antrum should then be cut away. The mucous membrane lining the antrum should be destroyed by the curet. The soft tissue covering its front is then pushed into the cavity so that it snugly enters it. An internal and external vertical incision of the periosteum may be required. A ball of gauze is applied to the skin of the face to keep the soft tissues pressed into the antrum. Bönninghaus, in performing this operation, cuts away the inner bony wall of the sinus, leaving the nasal mucosa which may be pushed outward by packing gauze about a rubber tube in the nose. It is possible to expose the antrum by lifting up an osteoplastic flap, made by dividing all of the margins of the anterior bony wall, except the upper which is to be broken. This gives free access, by means of which the interior may be treated, curetted, or cauterized, packed with gauze and drained either through the mouth or lower nasal fossa.

Instead of pressing the tissues of the face into the cavity, the antrum may be filled with fatty tissue transplanted from elsewhere. After removing the facial wall of the antrum, the mucous lining should be destroyed with the sharp curet, this destruction should be complete and should be supplemented by the cautery if necessary. The cavity should be packed with gauze until a lining of granulations appears. Then a piece of fat should be cut from the abdomen, in the shape of the cavity and inserted. It should approximate the shape and size of the cavity. The skin should be closed over it, and its primary union should be expected.

The *closure of sinuses* between the maxillary antrum and the mouth is not difficult. It is often difficult to keep such a sinus open. To close a sinus which refuses to close, an opening should be made between the nose and the antrum to provide drainage; necrotic bone of the alveolar process should be removed; a flap of alveolar mucous membrane should be dissected back on either side of the opening; if possible a flap should be lifted up within the antrum; the mucous membrane is then sutured in the mouth; fine silver wire or horsehair should be used for the suture.

Tumors of the Antrum.—Tumors require the same treatment as when arising in other parts. Benign growths, such as *mucocele, cysts*, and *polyps* may be approached by the same routes as described for empyema. Mucocele usually requires curettage of the antrum.

Foreign Bodies in the Antrum.—Whether foreign bodies are inanimate or animate, an artificial opening is required for their removal. This is best made in the lower fossa of the nose, where, by means of irrigation, the material may be brought to the mouth of the opening. Animate things may be dislodged by the methods given for the nasal cavities.

Suppuration of the Ethmoid Sinuses (Consult Fig. 848).—Operations upon the ethmoid sinuses for septic conditions are dangerous because of the frequency with which meningitis develops in these cases. In certain rather rare cases, there is natural drainage, and by irrigation and treating the sinuses with hot air, healing may be brought about without operation. Usually better drainage must be provided. Hypertrophy of the nasal mucous membrane should be cured. To reach the ethmoid cells, the anterior two-thirds of the middle turbinate bone must be removed. This wound overlies the cells. The ethmoid cells are opened with a sharp curet or gouge. Gentle curettage should be practised. Care should be exercised in curetting out the ethmoid lest the cribriform plate above or the outer wall be punctured. The cavity should be kept irrigated and dried out with hot air. Irrigation should never be forcible lest infection be driven into adjacent spaces. The older the disease the more thorough should be the curettage. Acute

cases should simply have the nasal opening made, but no curettage or other traumatism.

Operation on the ethmoid cells by the *orbital route* is called for when the outer wall of the ethmoid has become perforated and infection of the orbit is present. Some days before this operation is undertaken, the nose should be cleared of obstructive disease, and the anterior two-thirds of the middle turbinate bone removed. A curved incision is begun at the supraorbital notch, carried inward just below the upper margin of the orbit, and thence curving downward on the inner side of the orbit nearly to the infraorbital foramen. This incision passes through skin and periosteum. This flap is then elevated from the bone until the orbital surface of the ethmoid (os planum) is exposed. The os planum is freely opened with a gouge, and all suppurating cells exposed and curetted. The anterior and posterior cells should be made to communicate and an opening made in the nose. This operation allows of inspection of the sphenoid cells and the frontal sinus. If infection does not extend into these, a light packing of gauze should be introduced, brought out through the nasal opening, and the orbital wound sutured. This external operation gives an approach which permits the operator to see what he is doing, and to determine whether infection has extended into the adjacent sinuses.

The after-treatment should provide an unobstructed nasal exit for discharges, but much care must be used in irrigation.

Suppuration of the Sphenoid Sinuses.—This condition usually follows disease in the adjacent sinuses, and, therefore, often may be treated in connection with the preëxisting disease. Both sinuses may be involved at once, but usually the infection is unilateral. The first essential is the treatment of any nasal inflammation which may be present. Nasal drainage should be made perfect. A mild alkaline antiseptic wash should be used. The middle turbinate is the guide. If the upper border of this bone is followed it leads to the sphenoid sinus. Some surgeons prefer to remove the middle turbinate some days before in order to have a clear view. A probe-pointed irrigator should be introduced into the sinus through the natural ostium. If the opening is free the sinus may be washed out; if the irrigator fits snugly, it should be aspirated. The application of adrenalin will cause the swollen mucosa to contract. If treatment by irrigation is not effective, or if urgent symptoms demand immediate and free drainage, the opening should be enlarged. The sinus should be opened with a gouge or small sharp curet (Fig. 483). Often the mouth of the sinus close to the septum can be seen discharging pus, and a probe can be introduced as a guide. The floor of the sinus may be broken away freely in all directions, but it is dangerous to traumatize the roof or outer wall. If the nose is free of obstruction, and the middle turbinate has been removed, this is not a difficult operation. Cleansing of the nose is the essential part of the after-treatment.

Extranasal approach to the sphenoidal sinus is described under Operations on the Pituitary Body, page 82. The sphenoid may be opened through the frontal sinus when the latter also is diseased. It may be opened through the ethmoid sinuses when they are diseased.

The direct approach through the nose is the same as for the first steps of the intranasal operations to expose the pituitary body. Ordinarily 20 per cent. cocain solution, in 1 : 1000 adrenalin is applied to the lateral wall of the nose and the septum. The posterior half of the middle turbinate is then removed. The posterior ethmoidal cells are then broken through with hook and curet. This breaking down of cells is carried back into the sphenoid. If the anterior wall of the sphenoid sinuses is thick, a stronger in-

strument may be required. Curetting granulations out of the sinus is rarely justified. It may be done only in the old chronic cases, and then with the greatest care.

Acute Catarrhal Inflammation of the Frontal Sinuses.—This condition should receive the same treatment as acute catarrhal rhinitis with which it is commonly associated. Hot applications over the brow and hot nasal douches are of service. Swelling of the mucosa can be allayed and better drainage secured by the application of adrenalin solution or cocain (4 per cent). to the middle fossa of the nose. A drying of the excessive secretions may be secured by the internal use of belladonna.

Chronic Catarrhal Inflammation of the Frontal Sinus.—This condition should be treated the same as chronic catarrhal rhinitis. A tampon, saturated with a 10 to 25 per cent. solution of ichthyol, placed in the upper part of the nose, is of help. When secretions are retained, the treatment becomes that of empyema. Adrenalin applied to the mucous membrane in the upper part of the nose helps the drainage.

Empyema of the Frontal Sinus.—Any nasal disease present should receive treatment. By applying adrenalin to the upper part of the nose cavity, the shrinkage of the mucous membrane may be relied upon to give better drainage. If drainage is still hindered by swelling of the mucous membrane, the front half of the middle turbinate bone should be removed and the opening into the nasofrontal duct enlarged. Sometimes irrigation of the sinus, by means of a curved canula, can be conducted through the nose. In most cases when empyema has developed the presence of granulations, swollen mucosa or necrotic material prevents this. The conditions to be met are similar to those in the antrum. Before any operation, all obstructions in the nose should be removed; and the ethmoid cells should be examined for empyema and, if necessary, freely curetted.

The *free opening of the frontal sinus* is best accomplished as follows: An incision is begun at the supraorbital notch and carried inward just below the superior margin of the orbit to the nasofrontal juncture. This should divide skin, muscle and periosteum. The periosteum and soft parts are then elevated from the bone with a periosteal elevator and retractors inserted. A small trephine, about 1 cm. in diameter, is applied to the frontal eminence. The opening should be 1 cm. external to the median line, on a level with the upper border of the orbit. Granulation tissue and detritus should be removed from the sinus, the nasofrontal duct enlarged, the interior dried and treated with tincture of iodin or nitrate of silver solution, and a wick drain inserted into the duct and passed on into the nose. Usually the communication with the nasal cavity must be enlarged before the drain is inserted. The skin wound is closed with a subcuticular suture. The drain is drawn out through the nose on the second day. If caries of the ethmoid is present, it should be curetted by way of the frontal sinus. When this is necessary, a large opening should be made into the nose and a packing of nosophen gauze brought out through the nose.

The sinus may be reached by retracting the periosteum and soft tissues from the inner, upper, and anterior aspect of the orbit. The floor of the sinus is here opened, and treated as above. This opening is so close to the os planum of the ethmoid, that the ethmoid cells are easily opened at the same time.

Daily irrigations of the upper nose and sinuses should be practised. When there is necrosis of bone or when after many weeks the sinus refuses to heal, a radical operation for its obliteration should be done.

H. A. Lothrop (Annals of Surg., vol. 59, 1914) devised an operation which

is less formidable. It begins with an incision along the inner part of the superior orbital margin and curves downward toward the inner canthus. The supraorbital nerve should not be cut. The incision is about 2.5 cm. (1 inch) long. The bone is bared by lifting up a flap of soft parts and periosteum. An oval opening about 2 cm. (¾ inch) long is made into the sinus. Pus and granulations are removed, and a probe is passed through the ostium into the nose. This probe is left in place as a guide. A small curved curet is then passed down in front of the probe and the cells on the floor of the sinus broken up. The posterior angle of the sinus should be avoided on account of its closeness to the cribriform plate. With a burr or rasp the dense bone between the floor of the sinus and the base of the nose is reamed out. This bone includes the nasal crest, the spine of the frontal bone, and the end of the nasal process of the upper jaw. The interfrontal septum also should be cut away with the burr to open the other sinus for exploration. Next the perpendicular plate of the ethmoid should be removed. Through the large opening thus made the dense bone below the opposite sinus is



Fig. 862.—Line of Incision for Widely Opening Both Frontal Sinuses.

burred away, until there remains a thin shell of bone representing the two sinuses. Even when only one sinus is infected, experience has showed the wisdom of opening both. Sufficient bone should be removed from the perpendicular plate to open the ethmoid cells. If the maxillary antrum is infected, a large opening should be made in the nose below the inferior turbinate. The periosteum-skin flap is sewed back in place and the wound closed without superficial drainage. Subsequent treatment may be applied through the nose. Some surgeons complete the operation by placing a rubber tube in the sinus and the nose, passing a wick drain through it, and filling the sinus with the wick. The wick can be withdrawn through the nose leaving the tube in place.

For the *wide opening of both frontal sinuses* an incision should be made in the bed of the eyebrows. These two incisions should curve downward and join by crossing the nose just above the place where the bow of spectacles would rest. A practically concealed incision is thus made (Fig. 862). The frontal flap of scalp is dissected up and retracted. An osteoplastic flap, broad above and narrow below, representing the anterior walls of the

sinuses, is next cut. This may be done with a small drill to make the holes, followed by the wire saw. After the first holes have been bored, a fine probe may be used to determine the size of the sinus. The flap is left attached at its base at the root of the nose. The flap is turned down by fracturing across the base, the periosteum being left unbroken (Fig. 863). The diseased sinus is treated, the opening into the nose enlarged, drainage into the nose provided, the osteoplastic and scalp-flaps replaced, and the wound sutured.

Sinus infections perforating into the orbit may come from the frontal or ethmoidal sinuses. They are best exposed by an incision along the inner border of the orbit. If necessary the incision may be extended upward below the eyebrow. After elevating the soft tissues with the periosteum, the diseased sinus may be opened, curetted and drained.

The intranasal treatment of sinus infections should always be considered before external operations. The sinuses naturally drain into the nose. By patiently cocainizing the mucous membrane, the entrance of the sinus

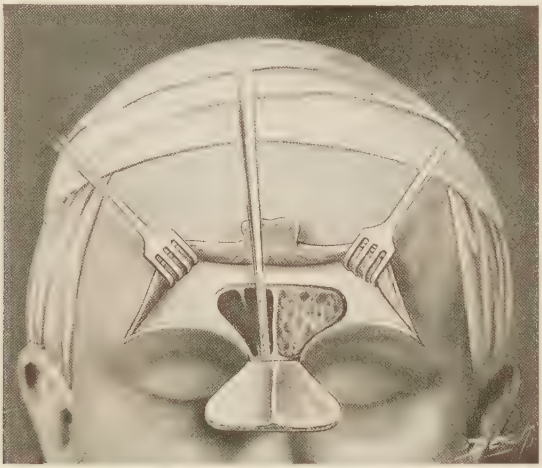

Fig. 863.—Operation for Widely Opening Both Frontal Sinuses.
Showing scalp retracted upward, bone-flap turned down and probe enlarging opening into nose.

may be reached and a free drainage secured. Even in cases in which there are swelling, edema, redness, and heat showing on the face, intranasal treatment may obviate extranasal operation.

Intranasal drainage of the frontal sinus may be accomplished in most cases. Local anesthesia suffices. In chronic cases, the anterior end of the middle turbinate is removed and the nose well cleansed. The preliminary steps may be taken in a few days before operation on the sinus. Under local cocain and adrenalin influence a probe is passed into the nasofrontal sinus. The sinus having been located, the opening is enlarged with the burr operated by an engine, or it may be rasped out. The sinus should be irrigated with warm salt solution. Some rhinologists place a tube in the sinus, fix it in the nose, and irrigate through it daily with warm boric solution. Care should be taken not to penetrate the cribriform plate of the ethmoid.

If the usual treatment of frontal sinus disease by suction and irrigation fail, a more radical operation may be done. The anterior end of the middle turbinate is cut off and the anterior ethmoidal cells cut away with biting forceps (Fig. 864). The inner wall of the ethmoidal labyrinth should not

be injured. The operation should keep close to the orbital wall, which should not be penetrated. A curved curet, rasp, or forceps easily enters the frontal sinus (Fig. 865).

For *obliteration of the frontal sinus*, the *operation of Killian* is performed as follows: (*a*) An incision is carried from about the junction of the upper and

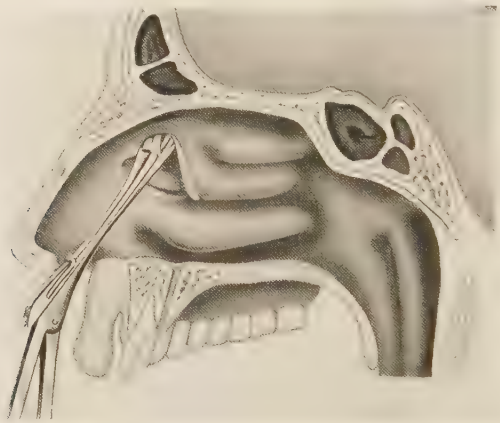

Fig. 864.—Nasal Approach to Frontal Sinus.
The anterior end of the middle turbinate has been removed, and the forceps are cutting away the anterior ethmoidal cells.

outer margins of the orbit inward along the upper margin to the root of the nose, lying wholly in the area of the eyebrow. The incision then passes downward upon the nasal process of the superior maxilla, following the margin of the orbit, and curves outward to end below the inner canthus

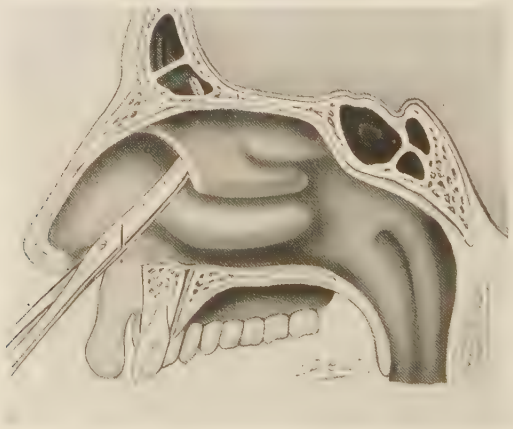

Fig. 865.—Nasal Approach to Frontal Sinus.
The forceps enter the frontal sinus after removal of its floor.

(Fig. 866). One or two transverse cuts across the wound may be made in order to facilitate exact coaptation at the close of the operation. The incision is carried to but not through the periosteum. The overlying soft tissues are dissected back and retracted on either side of the incision, uncover-

ing the superciliary ridge, the nasal eminence, and the anterior aspect of the upper and inner walls of the orbit. *(b)* An incision is made through the periosteum parallel to the supraorbital margin, and 5 or 6 mm. above it. This

FIG. 266.—OPERATION FOR OBLITERATION OF FRONTAL SINUS

FIG. 267.—OPERATION FOR OBLITERATION OF FRONTAL SINUS.
The soft tissues are retracted. Line [illegible].

extends from the outer end of the skin wound to the median line at the root of the nose. *(c)* Another incision through the periosteum begins at the anterior aspect of the juncture of the upper and inner orbital walls just internal to

the attachment of the pulley of the superior oblique muscle, and follows the line of the descending skin incision to its termination (Fig. 867). (*d*) The periosteum is then elevated from the superior incision upward over the anterior wall of the frontal sinus; and from the inferior periosteal incision it is elevated backward, exposing the bone of the inner and upper walls of the anterior part of the orbit. Between these two areas of denuded bone, there remains a strip of periosteum which is to be left covering a bridge of bone intended to support the soft parts at the close of the operation. (*e*) The wall of frontal sinus should then be opened by a small trephine, or gouge applied just above the periosteal bridge. The lining mucous membrane of the sinus should not be ruptured, and should be carefully pushed away from the bone as the anterior wall of the sinus is freely removed by gouge or rongeur. As the bone is cut, the mucous lining is kept pushed away with a probe or fine elevator. If a rongeur is used the edges of the bony opening should be smoothed with a chisel. All of the angles of the sinus should be

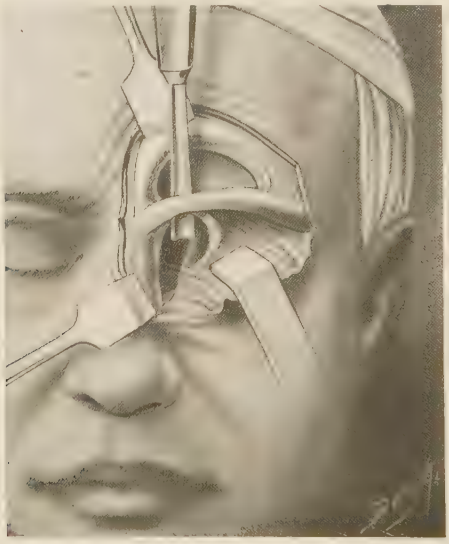

Fig. 868.—Operation for Obliteration of Frontal Sinus

The sinus has been uncovered, leaving bridge of bone. The floor of the sinus is to be removed with chisel. The ethmoidal cells are exposed.

uncovered. (*f*) Having done this, the lining of the sinus should be liberated throughout the rest of its extent, and removed. The presence of granulation tissue will often cause the mucosa to tear, and require the use of the curet. All of the soft contents of the sinus should be removed, and septa broken down.

(*g*) The floor of the sinus is then removed with the gouge. The bone is thin. An opening into the orbit results (Fig. 868). The nasal process of the superior maxilla is removed, and the removal of the floor of the sinus completed throughout. In order to avoid tearing the nasal mucous membrane, it should be perforated with the point of a knife at the edge of the nasal bone; then with a probe-pointed scalpel the incision should be continued upward and backward to a point 5 mm. below the cribriform plate of the ethmoid; from here the incision should pass a short distance downward to make a

tongue-shaped flap. This flap is turned outward and used to cover the parts of the wound adjacent to the nasal cavity. A permanent communication is thus established between the frontal sinus and the nasal cavity.

(*h*) Next the ethmoid cells, anterior and posterior are examined, and, if found diseased, removed with the curet. The middle turbinate may also be removed. At this stage the sphenoid sinus is accessible, and, if diseased, its anterior wall may be opened and the sinus curetted. If necessary, in order to reach the posterior ethmoid cells and the sphenoid cavity, a part of the nasal bone may be cut away. (*i*) The wounds should be irrigated; and a wick drain should be passed from the outer part of the frontal sinus inward through the nasofrontal opening into the nose. The soft parts are then replaced, and carefully sutured with the view of securing primary union.

(*j*) The patient should lie on the sound side. Care should be taken that he does not blow his nose lest septic material be forced into the sinuses. The drain should be removed through the nose on the second day, the sutures on the fifth day. The after-treatment consists in keeping the nose clean. If irrigation becomes necessary it should never be used with sufficient force to drive fluid into the sinuses. Granulations springing up about the nasofrontal orifice should be suppressed with silver nitrate. From two to six months are required for healing. The depression at the brow may later be remedied by an osteoplastic operation.

NASOPHARYNX AND FAUCES

The inflammatory diseases of the nasopharynx (Fig. 869) require about the same treatment as those of the nose.

In **hyperplastic nasopharyngitis,** the hypertrophied tissue should be removed, either by a snare passed through the nose and guided by pharyngeal illumination, or by the retropharyngeal snare (Fig. 870) or cutting-forceps (Fig. 871). In **syphilitic pharyngitis,** adhesions are prone to develop between the soft palate and posterior pharyngeal wall. Such *adhesions* should be divided, but unless the palate is kept retracted anteriorly, they surely will reform. This is prevented by the use of a palate retractor, which the patient should use twice daily, drawing the palate forward. No operation should be done until the patient is thoroughly under antisyphilitic treatment. Local antiseptic applications should be used.

Retropharyngeal Abscess.—The treatment of this disease depends upon its cause (see Abscess, Vol. I, pages 251 and 258). As a rule, it may be said that all abscesses except those of tuberculous origin should be opened. In order to avoid edema of the glottis, evacuation of the abscess is often urgent. In acute abscess evacuation is always imperative. A local anesthetic suffices except in the case of children or very nervous persons, when general anesthesia is used. The operation should not be done with the patient fully narcotized. A mouth gag, a tongue depressor, and a long straight bistoury are required. If there is danger of wounding the palate or tongue, the blade should be wrapped with adhesive plaster excepting its point. The operation should be done with the patient's head lowered so that the pus shall run up into the nose and mouth rather than downward. This is because of the great danger of aspiration of infective material into the trachea. The danger is an imminent one, because of the closeness of the pus to the glottis, and the large amount which may at one moment bathe the epiglottis. It is certain to be inspirated if the patient happen to inhale at the moment it gushes forth. The head should be kept dependent not only at the operation but for several hours afterward, until the pus has become evacuated.

A less dangerous route is through the side of the neck. This is by all means indicated if enlarged or suppurating lymphatics are present. An incision is made along the anterior border of the sternomastoid muscle

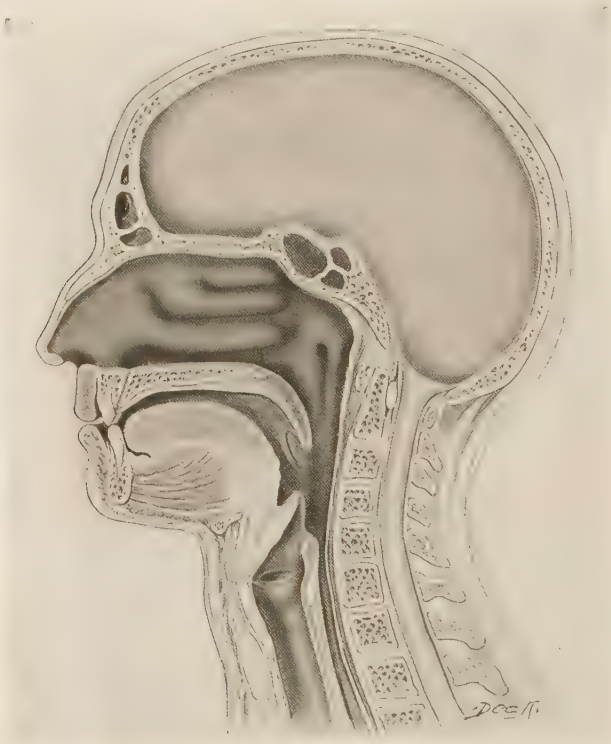

Fig. 869.—Anatomy of Nasopharynx and Fauces.

which should be retracted strongly backward. The deep fascia is divided posteriorly and the sheath of the carotid and internal jugular retracted forward. With the anterior scalenus muscle as a guide, a blunt dissection is

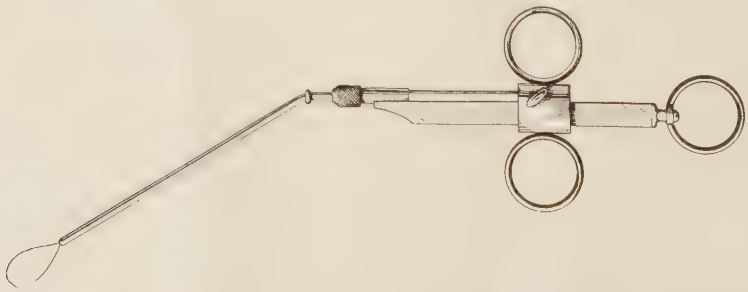

Fig. 870.—Snare for Removing Pedunculated Growths from Nasopharynx.

carried directly inward to the space between the longus colli and the constrictors of the pharynx, where the abscess will be found. A drainage tube, a few sutures, and a copious dressing complete the treatment.

Abscess due to spinal caries should be opened externally through the neck and with great aseptic care. A small incision is made posterior to the sternomastoid muscle, the fascia is divided, and a pair of forceps inserted through the tissues to the front of the transverse processes. The abscess having been located, it is given the necessary treatment.

Diphtheria (Klebs-Löffler membranous pharyngitis) is quite as much a surgical disease as erysipelas, hospital gangrene, or suppurative tonsillitis. Its treatment should best be carried out by the laryngologist. It will be found best described in works on internal medicine. The pediatrists have the most experience in its treatment. Briefly: The strength of the patient should be conserved. Diphtheria antitoxin should be injected as soon as the diagnosis is made. The curative dose is 1000 antitoxic units. The earlier the injection, the better the results. Persons who have been exposed should be immunized with an injection of 500 units. The patient should be isolated.

If the symptoms grow worse the antitoxin should be injected every six hours, increasing the dose 1000 units at each injection. If begun early one or two doses suffice. Usually three doses are enough. Laryngologic skill is required in the local examinations and applications, to inflict the least

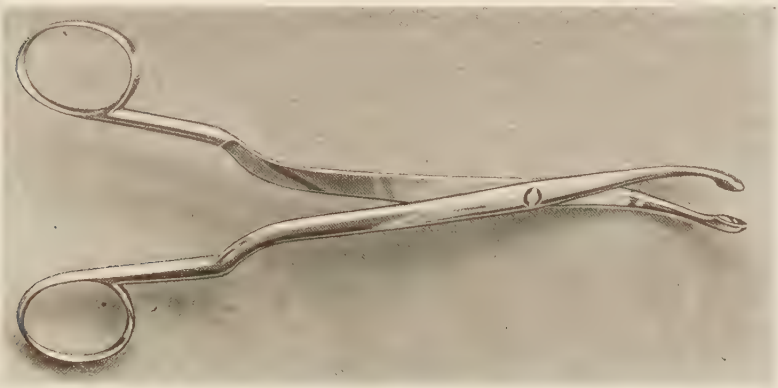

Fig. 871.—Cutting Forceps for Removing Growths from the Nasopharynx.

strain upon the patient. If a weak solution of iodin does not keep the throat clean, peroxid of hydrogen may be used. When the false membrane reaches the upper part of the pharynx or nose the parts should be sprayed every hour with equal parts of hydrogen peroxid, cinnamon water, and watery extract of witch hazel. Loose pieces of membrane should be removed with forceps or swab. Progressive asphyxia, as shown by dyspnea, stridor, cyanosis, and retrocession of the soft parts of the chest wall during inspiration, calls for intubation or tracheotomy (pages 226 and 237).

Tuberculosis of the pharynx should be treated the same as tuberculosis elsewhere. The constitutional treatment is most important. Pain may be relieved temporarily by cocain or orthoform locally. Dilute nitric acid in an equal amount of water, applied directly to ulcers or used as a spray, relieves pain. Pineapple juice as a local application is also of value. If all of the ulcerated area can be brought into view, good results follow its complete excision by means of the sharp curet. *Lupus* is best treated by curettage of ulcers and nodules. The object of the treatment should be to remove all of the diseased tissue. Antiseptic astringents should be used in the wounds (see Tuberculosis, Vol. I).

Glanders, actinomycosis, herpes, and **mycosis** should be treated according to the rules given elsewhere. Mycosis is best treated by cleansing with hydrogen peroxid and touching the infected areas with tincture of iodin once daily. The cautery may be required in obstinate cases. **Keratosis** of the pharynx and tonsils is best treated by curettage followed by chromic acid (30 per cent.).

Tumors of the Nasopharynx.—*Benign tumors* are usually *fibromata* which when pedunculated can be removed with the snare. Sessile fibromata usually require an osteoplastic operation to gain access. Temporary resection of the superior maxilla is often necessary (see Operations on the Superior Maxilla, Vol. I, page 717). In the case of large tumors, temporary occlusion or ligation of the external carotid arteries facilitates the operative work. Preliminary tracheotomy is to be done if the tumor is of such size as to occlude the pharynx. The injection into the substance of the tumor of monochloracetic acid in saturated solution has been reported curative.

Adenoids of the nasopharynx should be prevented by securing the best hygiene for the child. Next to a good general bodily vigor, *fresh air* is most important. This is not an all-important factor because children of good general health, who live out of doors day and night, still develop adenoids. A damp climate, especially in which there are sudden and great changes of temperature, seems to be an etiologic factor. Children which are reared in climates where the temperature is equable, where the air is less damp than at the seashore, and where they live out of doors most of the day, are least prone to have adenoids. Dirty and dusty air aggravates the disease. Anemia and toxemias are also causative.

Adenoid vegetations should be cured because they cause obstruction to the free passage of air through the nose, distortions of the bony framework of the nose, mouth, pharynx, ear, and thorax, mental defects depending upon these conditions, diseases of the structures adjacent to the nasopharynx, and a general deterioration of health and physique. Successful treatment demands early recognition and removal of the adenoids. The first step in the treatment should be the removal of causative factors. In some cases this will be sufficient to convert a mouth-breathing child into a nose-breather. In most cases some operative treatment must be added to this. The disease should not be thought of as a neoplasm, but as a hypertrophy of normal glandular tissue, the removal of which is called for when it produces disturbance.

In the *soft adenoids* of young children, but a simple operation is required. These friable growths in infants can be removed with the finger. If they are simply abraded or lacerated, they become absorbed and disappear. No anesthetic is required. The after-treatment should be the same as that in the older cases. The ordinary case of adenoids requiring operation is between two and six years of age; obstructive symptoms are already present; and the effect of the vegetations upon the child's health is easily seen.

Some surgeons prefer *to operate without an anesthetic.* The child is wrapped in a sheet which confines its arms and legs. A nurse or assistant sits facing the operator and holding the child on her lap. The child sits upright and looks in the same direction as the assistant. The latter holds the child's legs between her legs, passes the left arm around the front of the child's body to hold the trunk and arms, and with the right arm against the child's forehead presses its head back against her left shoulder. The operator sits facing the patient. By cultivating a good *entente* with the child, the surgeon may go about his work leisurely, giving the patient an opportunity to spit and wash out the mouth and receive some cheerful word of encouragement. When the child is intractable to suasion, then the operation may proceed with the same

expedition as is employed when an anesthetic is used. The operation without anesthesia has the advantages that there is less bleeding, the surgeon may work more deliberately, and the hazards of narcosis are obviated; the disadvantages are that the child is slightly hurt and often much scared, and the operator must have greater tact and dexterity. Operation without anesthetic is to be practised only when there is some good reason for withholding anesthesia.

Most operations are best done with the patient under the influence of an *anesthetic.* Local analgesia should be thought of only in the cases of adults. For children the best anesthetic is ether and oxygen or nitrous oxid and oxygen. Ethyl chlorid, somnoform, and chloroform have their advocates.

Fig. 872.—Cutting Curet for the Removal of Adenoids from the Nasopharynx.

More important than the agent employed is the employer. None but a skilled anesthetist, should be intrusted with this responsibility, as these children are usually of depleted vitality, with deranged respiratory organs, and the anesthetic has to be discontinued and resumed at the convenience of the operator. The child should be anesthetized in the recumbent position.

The best *position* for operating is with the head low in order that blood shall not run into the larynx and esophagus. This position is secured by placing a small sand pillow behind the shoulders or better still by an exaggerated lowered head position. If the head becomes congested and the veins dilated, the head may be elevated for a few minutes until the circulation becomes balanced.

Fig. 873.—Adenotome.

This instrument has a flexible cutting blade which slides at the floor of the instrument and closes it. The amputated tissues find themselves enclosed in a box.

Some surgeons prefer to operate with the patient in the *sitting position.* My friend Thomas R. French, brought this method to a high state of perfection. He invented a chair in which the patient is strapped as soon as the anesthesia is established. The chair is so arranged that it may be tilted backward at any moment and the recumbent position secured. Operating with the patient erect is accompanied by decidedly less bleeding, less anesthetic is required, there is less congestion of the vessels of the head, and the blood runs forward out of the mouth and nose. The surgeon should use the method to which he and the patient are best adapted.

Special *instruments* are required. The adenoid curet (Fig. 872) and the adenotome (Fig. 873) are used. The mouth gag (Fig. 874) should be so constructed and applied as not to injure the teeth. Schultz has invented an

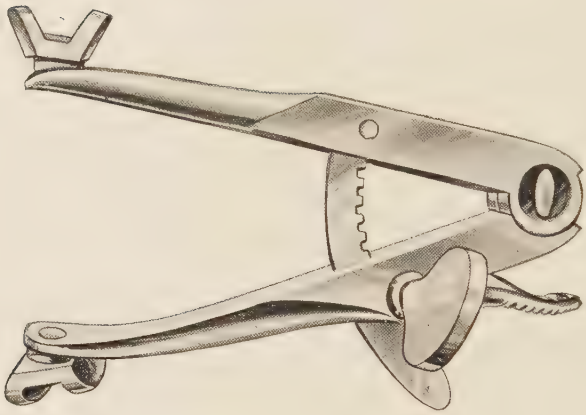

FIG. 874.—HINGED MOUTH GAG.

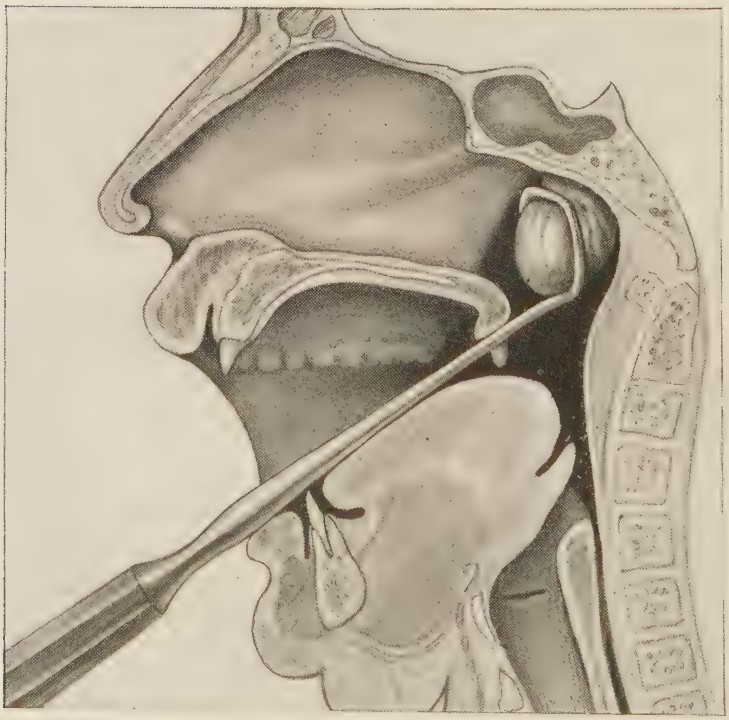

FIG. 875.—REMOVAL OF NASOPHARYNGEAL ADENOIDS.
Showing proper position of adenoid curet for the removal of the whole mass with one stroke of the instrument.

adenotome which is an effective instrument. Small pledgets of gauze in sponge holders are used for sponging away the blood. Instruments for performing tracheotomy should be at hand in case of accident.

The patient having been anesthetized for *the operation*, he is placed in position, and the mouth gag inserted on the left side and intrusted to the anesthetist. If the tonsils require operation, which they usually do, this should be done before the adenectomy (see Tonsillectomy, page 213). By drawing the tongue forward and elevating the uvula a fair view of the pharynx is secured. With the modified Gottstein curet, the adenoid mass is cut away from the posterior wall of the pharynx. The size and shape of the instrument must depend upon the size of the throat and the location of the disease. It is not necessary to do a thorough scraping operation. The skillful surgeon, with one stroke of the curet, usually removes all that is required (Fig. 875). If the growth is high in the pharynx above the reach of the curet, a small straight curet may be used. This is passed straight back through the nose and guided by the finger in the pharynx. When adenoids are large, or hard, as in adults, the adenoid forceps are useful. When forceps are employed the soft palate is held forward by the left forefinger, and the blades are opened so as to grasp nearly all of the lymphoid tissue. The curet should then be used.

The operation should not be carried so far laterally as to injure the mouths of the Eustachian tubes. The index finger should precede the instrument to determine just what is to be done. After the growth, or its major part has been removed, the finger should be used to break down the lateral masses and separate adhesions between the growth and the faucial pillars and sides of the nose. This latter should be depended upon to clear the Eustachian orifices.

The wound should be sponged dry. The after-bleeding should be but slight. If bleeding persists it may be controlled by pressure with a gauze tampon. The patient should be watched for hemorrhage during the first twelve hours. Should bleeding recur, packing may be depended upon to control it. If it is severe, packing through the nostrils may also be used. Healing usually is rapid. No irrigation is necessary unless a purulent discharge develops. The patient should take soft food for a few days, and then his regular diet. Freedom from dust aids healing. Fresh air is essential. Recurrences are not uncommon even when a complete operation has been done. They are observed usually in children in whom the etiologic factors have not been eliminated or in whom there exists a predisposition to lymphatic hypertrophies.

The *treatment of adenoids during the first year of life* must often be operative. No anesthetic is necessary. The child should be wrapped in a sheet which holds its arms at the sides. It should be held upright by the nurse, with the back of the child's head against the front of the nurse's left shoulder. One arm should envelop the body and the other hand should press back against the forehead. A gag is held by the assistant. The operator holds down the tongue, then passes in an adenoid curet (Gottstein), and with one stroke removes the growth. The head is quickly brought forward to let the blood escape, and a small piece of ice enveloped in a square of gauze is pressed into the pharynx. When the bleeding has stopped, the child is again held up, the gag and tongue depressor inserted, and an examination made by passing the finger into the pharynx to see that the operation has been satisfactorily done.

Such young children, even in the fourth or sixth month of life, with cough, snuffles, malnutrition, and some temperature, seem to do well after this operation.

Tonsils.—*Acute tonsillitis* may be an expression of constitutional disease or it may be a distinctly local infection or irritation. In any case the cause should be sought and removed if possible. *Acute catarrhal tonsillitis* should be met by first purging the system of toxins. The inflamed tonsil should be painted with pure guaiacol or a similar drug. The drug should be carried down into the crypts by means of cotton tightly wound about the end of an application probe. The guaiacol should not run over the surrounding mucosa. This should be done every four hours; and by the fourth application, it will usually be found that the disease is controlled. If no good results are observed by the third application the drug should be discontinued. Internally the ammoniated tincture of guaiac, 1 to 1.3 Gm. (15 to 20 minims) every two hours may be given. Fasting or a fluid diet should be prescribed. For cleansing the tonsil of discharges a gargle should be used every hour. Hydrogen peroxid is effective. Hot applications to the side of the neck aid hyperemia. The local application of 4 per cent. cocain solution relieves pain. A tonsil which has become greatly enlarged and tense, and is causing difficulty in swallowing may be relieved by multiple punctures and hot-water gargles.

In *follicular tonsillitis*, the early stage should receive the treatment described for the acute catarrhal variety. The tonsil should be anesthetized with cocain solution and each crypt opened with a probe, followed by a fine angular curet, and emptied of its contents. The crypts should then be treated with pure guaiacol on cotton swabs. *Suppurative tonsillitis* (peritonsillar abscess, quinsy) should be treated the same as the above. When abscess has formed, or even before, incision is called for. This is best done with a sharp-pointed straight bistoury. The blade should be wrapped with gauze or adhesive plaster, leaving exposed about 1.5 cm. of the tip. Incision should be made at the lower part or where the abscess seems to point, and should be toward the median line in order to avoid the great vessels which lie just external to the tonsil. *Membranous tonsillitis* of nondiphtheric origin should be treated by dissolving the membrane with peroxid of hydrogen, applied with a pledget of gauze, several times daily. This should be followed by the application of an antiseptic solution. None is better than Löffler's solution, which consists of alcohol, 60 parts; toluol, 36 parts; and liquor ferri sesquichlorid, 4 parts. If peroxid of hydrogen cannot be had, the membrane may be digested away by the local application of an animal or vegetable enzyme.

Chronic tonsillitis may manifest itself as a continuation of any of the acute forms, and require the same treatment as they. *Caseous tonsillitis*, retention of caseous secretions in the tonsillar crypts, should be treated by freely incising the crypts throughout their whole depth, curetting or sponging out their contents, and applying tincture of iodin or pure phenol on a pledget of cotton to the interior of the cavity. If the tonsil contains multiple distended crypts and is chronically inflamed it had best be removed. *Mycosis of the tonsil* is treated by correcting any disease of the mouth, and applying tincture of iodin to the tonsil.

Chronic hypertrophy of the tonsils should not be confused with enlargement due to dilatation of the blood-vessels or to the presence of serous exudate. The tonsils of children are normally comparatively large. An acutely inflamed tonsil is enlarged, but will return to its normal state when the inflammation has subsided. Such tonsils may require treatment but not necessarily extirpation. Extirpation is reserved for tonsils which are so enlarged that they cause obstruction to the respiratory tract, the throat or to the Eustachian tubes; which are the seat of chronic inflammation which is intractable to

treatment; or which contain septic material which is causing auto-intoxication. When any or all of these conditions exist the tonsils should be removed.

In the case of the soft tonsil, local applications and the correction of defects of personal hygiene, such as are recommended for acute tonsillitis, will often be of service. Fresh air is essential in these cases. The relief of intestinal disorders is important. If the tonsil is not occupied by septic crypts, the removal of the part of it which projects medianward beyond the pillars of the fauces may be expected to be followed by a cure. In the case of the hard, fibrous, or cryptic tonsil, more of the organ should be removed than just the projecting portion.

Removal of the tonsil (tonsillectomy) or *enucleation* of the tonsil, has supplanted the old operation of partial removal (tonsillotomy). The operation is indicated (1) in simple hypertrophy which causes interference with respiration, and (2) in infections of the tonsil causing local or constitutional dangers or disturbances. In the first class, tonsillotomy or incomplete removal may be done; in the second class, the whole gland should be removed.

Removal of tonsils is not to be regarded lightly. The operation is best done in the hospital, where the patient should have been sent the day before the operation. The operation should not be done in the presence of acute inflammation. Women should not be operated upon during menstruation. The tonsils should not only have been inspected but palpated also, to detect arterial pulsation, bony or cartilaginous deposits, or the presence of a dis-



Fig. 876.—Tonsillotome (Guillotine).

placed styloid process. The danger of hemorrhage may be reduced by giving calcium lactate for a week before the operation. The index of coagulability may be taken. A hypodermic injection of atropin will reduce the amount of secretion during the operation.

General *anesthesia* should be used in the cases of children and nervous adults. Ether is the anesthetic of choice. Local anesthesia is useful for older children and calm adults. By painting the surface of the tonsils, pillars of the fauces, posterior wall of the pharynx, and lower part of the velum palati, with 10 per cent. cocain solution, rubbing it also into the recesses, a satisfactory anesthetization may be secured. Adrenalin solution (1 : 1000) is then applied to the same surface. Then a milder anesthetic solution, such as 1 per cent. cocain, novocain, or stovain, etc., containing adrenalin is injected in the tonsil in four places so that the solution reaches the periphery. If there has been much inflammation local anesthesia will be found not altogether satisfactory.

The *position of the patient* is a matter of choice with the operator. Some prefer the patient with the head lowered in extreme dorsal extension, others operate with the patient sitting; and others prefer the patient lying on the right side. The first position has the most to recommend it.

The *incomplete operation*, which consists in the removal of a larger or smaller part of the tonsil, was once the common operation. It is done with a tonsillotome (Fig. 876). It still has its value. The tongue is depressed, the

tonsillotome is slipped over the tonsil and with a quick cut the organ is divided. Some surgeons become so dexterous that they are able to operate on the opposite tonsil before the blood from the first has obscured the view. Usually it is best to sponge away the first blood and dry the wound between operations.

It is possible, by drawing the tonsil forward and upward after the ring of the tonsillotome has been slipped over it, to compress it against the alveolar eminence of the lower jaw, and thus press it practically through the ring and remove the whole tonsil (G. Sluder).

In children the preparation and methods of operating are the same as for adenoids (page 208). Usually hypertrophy of the faucial tonsils and of the pharyngeal adenoid tissue appear together, and should be operated upon together. The tonsils should receive first attention. They come better into view when the child is in the sitting position. A tenaculum may be passed through the ring of the instrument to draw out the tonsil to be cut in case the tonsillotome does not reach it well.

In operating upon adults, local anesthesia is best; the tonsillotome is not necessary; the operation may be done with laterally curved scissors or an ordinary narrow bistoury, after grasping the tonsil with a tenaculum. The so-called tonsil punch is a useful instrument for removing parts of a tonsil or for securing portions which the tonsillotome fails to grasp. It is a cutting forceps with lateral grasp.

Usually after these operations there is no *hemorrhage*. Sometimes on account of the presence of an anomalous vessel, bleeding persists or comes on as a secondary hemorrhage. This condition should always be anticipated with watchfulness. Slight oozing may be controlled by pressure made for a few minutes, or by the application of peroxid of hydrogen, tannic acid solution, or alum powder. When the bleeding is active, the pillars of the fauces should be retracted apart and the bleeding point seized with curved forceps and ligated. If a ligature cannot be applied, it may be possible to pass a suture around the stump. In the event of failure to secure the vessel, pressure should be employed. For this purpose the tonsillar hemostat is best. It is a forceps with two light blades, the end of each being armed with a hard rubber button, one of which is applied to the wound, the other to the outside of the neck. A pad of gauze should be placed over each. The instrument may be left on from six to twelve hours. It should be applied only with sufficient force to stop the bleeding. When the bleeding is not controlled or serious anemia threatens, ligation of the external carotid may be depended upon to check it, provided it does not come from a wound of one of the great vessels.

The *after-treatment* is the same as that for adenoids: fluid diet, rest, and fresh air; and antiseptic applications only in the event of suppuration or sloughing. Usually no application is needed. When necessary, tincture of benzoin may be applied, or a douche used. The *results* of the operation are gratifying. This is especially so in the obstructive cases in children. The removal of the tonsils in children does not damage the voice; in most instances it improves it. In older persons, there may be some change in the quality.

The *enucleation* or complete removal of the tonsil (tonsillectomy) is the operation which is now most employed. It is the only operation that should be done for infected tonsils. The tongue is depressed, the tonsil is grasped with tenaculum forceps. With a knife the tonsil is cut free above and at the faucial pillars. Scissors, curved on the flat, may be used for this purpose (Fig. 877). The tonsil is separated from its attachments by means of the blunt end of the scissors or a tonsil separator (Fig. 878), which is

curved and about as sharp as a periosteal elevator. Some surgeons use the index-finger. By blunt dissection the organ is detached from all its connections excepting the base externally. As the tonsil is lifted inward out of its bed, a snare is placed around the remaining pedicle, which is crushed. Bleeding is less than in partial tonsillotomy; more skill is required. It is incorrect to speak of the operation as complete if some portions of tonsillar tissue remain (Fig. 879).

Some surgeons, after freeing the tonsil from its bed, place the wire snare about the pedicle, tighten it, and then proceed with the other tonsil. When the other tonsil has been liberated, the first tonsil is detached by crushing off its pedicle with the snare, and then the same thing is done with the second tonsil after hemorrhage has stopped. Care should be taken to see that the uvula is not included in the loop of the snare.

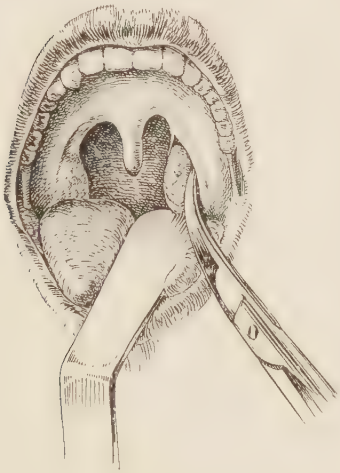

Fig. 877.—Enucleation of Tonsil (Tonsillectomy). First Stage.

Incision has been made between tonsil and the anterior and posterior pillars of the fauces and above. The tonsil is being liberated by blunt dissection.

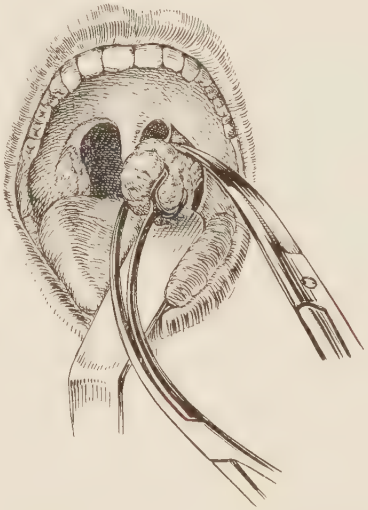

Fig. 878.—Enucleation of Tonsil (Tonsillectomy). Second Stage.

The tonsil is dissected free from its upper, posterior, and anterior attachments, and drawn inward by the tenaculum forceps.

This operation should remove the whole tonsil. If some portion of tonsil remains, especially in the upper part of the fossa, it should be removed with the tonsillar punch or the snare. During the operation, blood should be removed by gauze sponges on holders. A skillful assistant is valuable in this work.

The patient should not be sent from the operating room until the cessation of bleeding is assured. If pressure does not control bleeding, a search should be made for the bleeding vessel. Hemorrhage will usually be found to come from the tonsillar artery or the venous plexus near the middle of the wound. The vessel should be seized with a curved clamp. It may be twisted or tied; the hemostat may be left on; or a tampon may be pressed into the wound and the pillars of the fauces sewed over it.

Care should be taken in all operations to remove no tissue except the

tonsil. Careless operators have sacrificed the muscular tissue of the faucial pillars with the result that adhesions and discomfort have followed.

The *removal of tonsils by means of the guillotine* has been facilitated by drawing the tonsil forward and upward and then pressing it outward against the alveolar process of the lower jaw. In order to do this a guillotine tonsillotome, having a ring through which the tonsil may protrude, is used. The blade should not be sharp, but dull—not rounded, but simply not sharp. The distal part of the ring is pressed back of the tonsil so far that the tonsil may be lifted forward by it. The alveolar process then stops the tonsil anteriorly, as the blade of the guillotine is pressed home. The ring passes external to the tonsil, and ultimately around it, lifting it out of its capsule and detaching it. The tonsil may by this method be quickly enucleated with one instrument and one hand. The distal ring part of the instrument should be thin, strong and rounded, so that it may be pressed well out behind the tonsil.

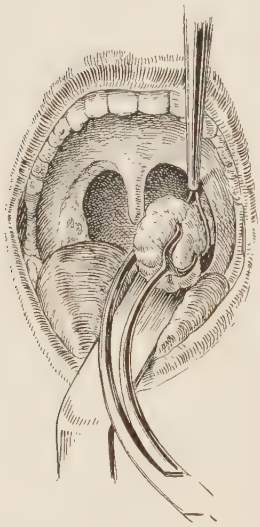

Fig. 879.—Enucleation of Tonsil (Tonsillectomy). Third Stage.

The remaining basilar attachments of the tonsil are crushed by the wire snare which is passed about the pedicle.

Imbedded or adherent tonsils sometimes are so covered by the pillars of the fauces as to be almost hidden. Usually such tonsils are found high up and often causing Eustachian trouble. The pillars must be separated by blunt dissection and the tonsil brought into view. Such tonsils should be removed.

Foreign bodies in the tonsils and pharynx, such as fish bones, often become lodged. Frequently such objects cannot be seen because of the muscular spasm. This may be relaxed with cocain. Often bodies which are supposed to be lodged lower down are found by careful search behind the tonsil. In searching for these bodies the localizing sense of pain is often misleading. The first examination should be without instruments in order to have the patient relax the throat as much as possible. The foreign body may usually be picked out with forceps. Even after the body has been removed the sense of irritation remains, and the patient will often insist that it is still present.

Tumors of the tonsils should be removed. Malignant tumors may be approached through the mouth, or by the external route. The latter is that which is described for epithelioma of the posterior part of the tongue. Temporary division of the lower jaw facilitates the approach. The general principles of operation are the same as upon the tongue.

Many of these cases are inoperable, and nonoperative and *palliative treatment* are indicated. If there is foul secretion, antiseptic gargles should be used. Excellent *analgesics* are cocain or orthoform applied locally. Equal parts of thymol, chloral, and camphor, rubbed on the skin of the neck give relief. Dyspnea may require tracheotomy. Dysphagia is overcome by the use of a tube passed by the obstruction and into the esophagus. Hemorrhage may be controlled by local styptics or ligation of the external carotid.

Exposure of the Nasopharynx.—Many operations have been devised for gaining access to the upper part of the pharynx for the purpose of removing tumors and performing other operations. Some of these operations will be found described under operations on the bones of the head. The

operations used for gaining access to the body of the sphenoid bone, for entering the sella turcica to remove the pituitary body, may be used. Most satisfactory exposure of the nasopharynx may be secured by dividing the lower jaw in the middle line, retracting the two halves laterally, drawing the tongue down into the cleft, separating the soft palate from the hard palate by a long transverse incision, and retracting the soft palate downward upon the tongue. This gives wide access to the nasopharynx. After the operation the divided parts are all restored to their natural positions by sutures.

LARYNX AND TRACHEA

Anatomy.—The *larynx* is a cartilaginous box, seated on top of the trachea. It is made up of several cartilaginous plates, the most important of which are the thyroid, cricoid, and the two arytenoid. It is attached above to the hyoid bone by the thyrohyoid membrane and muscles. The cavity of the larynx is closed above by the epiglottis, a valve which prevents the entrance of foreign matter (Fig. 869). Two dense elastic bands, the vocal cords, stretch across the interior of the larynx and divide it into an upper and lower chamber. Two folds of mucous membrane above the vocal cords constitute the false vocal cords. Between the two is the laryngeal ventricle. The sensory nerve supply of the mucous membrane of the larynx is through the internal branch of the superior laryngeal nerve. This nerve passes through the thyrohyoid membrane with the thyrohyoid artery. The arytenoid muscle and the cricothyroid muscle are supplied by this nerve. The recurrent laryngeal nerve supplies the other muscles. Sensory acuteness is present to a very high degree in the mucous membrane of the larynx above the vocal cords. Traumatism here is highly capable of producing shock. The lymphatics communicate with the chain along the internal jugular vein. The larynx lies in front of the bodies of the fourth, fifth and the upper margin of the sixth cervical vertebræ.

The *trachea* is a tube composed of cartilages and intervening membrane. It is about 12 cm. (4¾ inches) long, and in the male its transverse diameter is from 2 to 2.5 cm. (¾ to 1

Fig. 881.—Laryngoscopic Mirror.

inch). It extends from the larynx to the fourth dorsal vertebra, where it divides into the right and left bronchi. The cartilages of the trachea number eighteen or twenty, are in the form of incomplete rings, the gaps being posteriorly. The rings and their interspaces are connected by elastic fibrous membrane. The orifice of the right bronchus is more in a line with the long axis of the trachea than the left.

In the neck it has in front of it from above downward the isthmus of the thyroid gland, the inferior thyroid veins, the sternohyoid and sternothyroid muscles, and anastomosing branches between the anterior jugular veins. In the thorax, it has in front of it the manubrium, the remains of the thymus gland, the arch of the aorta, the innominate and left carotid arteries, and the deep cardiac plexus of the sympathetic nerves. Behind is the esophagus, which deviates to the left at the arch of the aorta. Laterally in the neck are the common carotid arteries, the lateral lobes of the thyroid gland, the inferior thyroid arteries, and the recurrent laryngeal nerves. In the thorax the pleuræ are on either side, and the pneumogastric nerve lies between the pleura and trachea.

Satisfactory **examination and treatment** of the interior of the larynx and trachea can be made only by one who has skill and experience in this special line of work. The gross external operations fall easily within the realm of the general surgeon. For securing a view of the interior of these organs a good light, back of the patient's right shoulder, a reflecting mirror on the surgeon's forehead and a laryngeal mirror, held in the back of the pharynx, are employed (Fig. 881). Better than a tongue depressor is to have the patient protrude the tongue, wrap it with a piece of gauze, and hold it with his own fingers (Fig. 882). **Local anesthesia** and **hemostasis** are secured by the same means

as in the nose (page 181); and the same antiseptic and cleansing solutions may be employed.

In performing **endolaryngeal operations,** a spray of 4 per cent. cocain is used, or, better still the part to be operated upon may be touched with a stronger solution. Especial skill and practice are required because the anterior and posterior pictures are reversed by the laryngoscope, and the operating instrument must be directed in the direction opposite to where the point of attack seems to be. The lateral reflection is not thus reversed. Cocain in the larynx, it should be remembered sometimes gives a patient the sensation of suffocation, which is entirely a sensory disturbance. If prolonged treatment is required, such as the removal of an intralaryngeal growth, it is best to accustom the patient to the manipulations by repeated preliminary examinations and mechanical irritation of the parts. A patient by practice may be made able to tolerate such manipulations without their exciting spasm of the throat muscles.

Fig. 882.—Laryngoscopic Examination.
Showing positions and methods of illumination for the ordinary laryngeal treatments.

Malformations of the Larynx and Trachea.—*Congenital stenosis* usually is in the form of webs or bands stretching across the glottis, and other abnormalities are usually present. Nasal and pharyngeal obstructions to breathing should first be corrected. The surgeon should be ready to perform tracheotomy at any time. If the stenosing membrane is delicate the introduction of an intubation tube should suffice to give dilatation. Dilatation may be secured by means of the angular laryngeal forceps passed through the constriction and opened. Sounds are also employed. A cutting dilator is sometimes useful.

Aërocele occurs as a pouch filled with air which pushes out between the cartilages of the larynx or trachea in the neck. It should be treated the same as any other hernia. The sac should be exposed, excised, the opening closed by sutures, and the wound sewed.

Acquired stenosis, due to traumatism, inflammation, ulceration, or caustic inhalation, should be relieved by tracheotomy whenever required. For the

local disease, inflammation and ulceration should be overcome by appropriate applications. The rest secured by tracheotomy is often of help. The method of dilatation of the stenosis must depend upon its character. Intubation with the O'Dwyer tubes may be indicated. The use of dilating forceps, sounds, or a cutting instrument must depend upon the case. In extreme cases an external operation should be done. Thyrotomy or tracheotomy should expose the lesion, and appropriate treatment may be applied.

In stenosing *hypertrophic subglottic laryngitis* the surgeon has to deal with a condition usually following tracheotomy for diphtheria; although it may be associated with other forms of irritation. When the tracheotomy tube is removed, it is found that the patient has stenosis above the tracheal opening. In cases in which the new tissue is soft, treatment consists in the use of an intubation tube for as many hours each day as it can comfortably be worn. Or a smooth rubber tube may be passed through the larynx, the lower end resting upon the tracheotomy tube and the upper end just reaching above the stenosis (Fig. 883). The tube may be secured by engaging its lower end in the tracheotomy tube, or a silk suture may pass out through the mouth and be fixed to the face by adhesive plaster. When the disease is older and the hypertrophic tissue is firm, laryngotomy gives access, and the stenosing bands may be divided or removed. A rubber tube may then be put in place, and left for two or three days. Urethral sounds passed upward through the tracheal opening are useful dilators.

Fig. 883.—Soft Rubber Tube for Maintaining Patency of Trachea after Operation for Stenosis.

John Rogers invented an intubation tube which passes down below the tracheal opening, and receives a second tube or plug at right angles through the tracheal opening (American Jour. of the Med. Sciences, Nov., 1905). This plug holds the tube and prevents its displacement (Fig. 884).

Injuries of the Larynx and Trachea.—*Burns* should be treated by total rest of the voice, and cold applications to the outside of the neck. The surgeon should be prepared to perform tracheotomy and insert a tube in the event of progressive edema or stenosis.

Contusions may cause submucous hemorrhage which should take care of itself unless so great as to produce stenosis, in which event tracheotomy is called for. Contusions of the larynx may be serious because of the intimate relation of its nerves to the blood-pressure regulating mechanism. Fatal cases of shock have resulted from such contusions without gross lesions. The surgeon should beware of this, and be ready to treat shock when contusions of the trachea are threatened or have occurred.

Fractures of the larynx and trachea are rare and serious conditions. Fractures of the laryngeal cartilages often result fatally from the entrance of blood into the trachea or from laryngeal edema. Tracheotomy and the insertion of a tube should be done as soon as possible, before serious symptoms appear. Blood should be aspirated from the trachea. Then any displacement which needs attention may be remedied. In fractures of the trachea, tracheotomy below the injury should be done. Unless tracheotomy is done early in these cases, a rapidly developing emphysema may make the operation difficult. If the operation cannot be performed at a place lower than the injury, then the lower end of the tube should reach below the level

of the injury. If the ordinary trachea tube is not long enough a rubber tube should be used. Any wounds of larynx or trachea which are accessible may be sutured.

Dislocations of laryngeal cartilages are easily reduced by manipulation, aided by swallowing movements or flexion and extension of the head.

Wounds of the larynx and trachea require first that a free respiratory channel shall be secured. If the wound has not caused bleeding into the lumen, its treatment as an ordinary wound is all that is necessary. If sufficiently large, it should be sewed. Sutures should involve all of the layers except the mucosa. Usually bleeding into the trachea is present. This calls for a free exposure of the injury and ligation of the bleeding vessels. Tracheotomy below the wound is commonly an advisable expedient. This allows of free exposure of the wound and treatment while respiration goes on unhampered. Wounds of the larynx call for tracheotomy because of the danger of fatal edema of the glottis which may develop at any minute. In

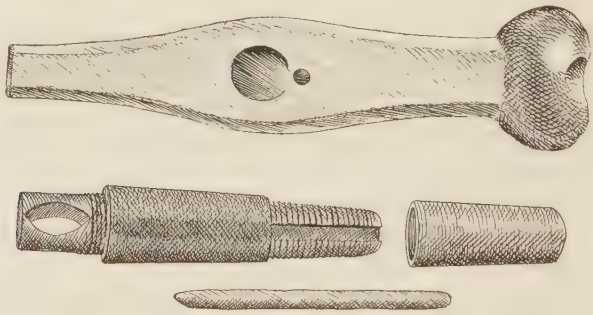

Fig. 884.—Laryngeal Intubation Tube, Combining a Tracheotomy Tube, Devised by Rogers.

The intubation tube with the bulb is inserted through the mouth into the larynx. The straight tube is passed through the tracheotomy or laryngotomy wound and screwed into the former at a right angle. The pin prevents unscrewing.

the event of much loss of substance or great laceration, it often becomes advisable to place a good-sized rubber tube in the lumen of the larynx and trachea, above the tracheotomy tube, in order to obviate stenosing contractures during healing. Such a tube may be removed by a silk thread passed through its upper end, brought out through the mouth, and fastened to the ear and face by adhesive plaster. After its removal, an intubation tube should be introduced at frequent intervals (see Cut Throat, Vol. II, page 360).

A wound of the extreme lower end of the trachea or of a bronchus may be sealed by including the apex of the lung in the suture to cover the wound. Wounds of the trachea or larynx with loss of substance may be covered by a bone-and-skin flap, including a layer of the anterior plate of the upper end of the sternum. The skin is turned in to take the place of absent mucous membrane. The clavicle may be used for the same purpose. The opening may be covered by soft tissue and a cartilage graft from the rib inserted to give stiffness.

Inflammations.—*Acute catarrhal laryngitis* is treated largely internally by medical means. Inhalation of the compound tincture of benzoin by pouring two teaspoonfuls upon half a pint of boiling water is of help. A tablespoonful of paregoric added to the above may be inhaled for extreme irritability. The same effect is secured by the use of a spray or nebulizer carrying a bland oily antiseptic. The following is useful for this purpose:

liquid petrolatum, 30 c.c. (1 ounce); oil of sandalwood, 0.3 c.c. (5 drops); oil of tar, 0.2 c.c. (3 drops). Hot applications to the skin of the neck are of service. Rest of the voice is called for.

Laryngeal spasm occurs both in adults and children. *Laryngismus stridulus* usually yields to medical treatment. The application of hot wet cloths to the front of the throat, as hot as can be borne, may be expected to relieve alarming acute attacks. If the patient is made to vomit, the spasm will relax. Even when these measures are not employed, relaxation of the spasm usually takes place as a result of carbon dioxid intoxication before death occurs. Traction on the tongue by grasping it with the fingers and pulling it forward at intervals corresponding with the frequency of respiration tends to relieve spasm of the glottis. If the jaws are tightly closed, the same effect can be produced by pushing the lower jaw forward by means of the fingers behind the angles. Sometimes the condition becomes so alarming and intractable that tracheotomy or intubation is called for.

Other methods for relieving *spasm of the glottis* are cold applications to the front of the neck, hot foot baths, and the exhibition of relaxing drugs. A few inhalations of chloroform or amyl nitrite are effective. The general health of the patient should be improved. In adults the correction of nasal disease, such as adenoids, polyps, turbinate hypertrophies, or other causes of obstruction or irritation, is required. If there is acute inflammation, it may be treated as acute catarrhal laryngitis.

In children *stridulous laryngitis* is most quickly relieved by immersing the child in a hot bath up to its chin. After fifteen or twenty minutes, or the relief of the spasm, the child should be rubbed until the skin is dry and warm. Any of the methods described above for the relief of laryngeal spasm may be used.

Edema of the glottis, whether due to laryngitis, traumatism, cellulitis, circulatory derangement, or infective inflammation in adjacent structures such as the thyroid gland, tonsils, or cellular tissues of the neck, is an extremely dangerous condition, and demands active treatment, careful watching, and preparation for immediate tracheotomy or intubation. Attention should be addressed to the relief of the causative condition. Free drainage of any adjacent infection is imperative. The edema may be relieved by multiple punctures of the mucous membrane of the glottis, to allow the escape of serum from the submucous connective tissue spaces. The punctures may be followed by the application of a mild astringent, such as silver nitrate, 1 per cent.; or liquor ferri subsulphatis, 0.6 c.c. in 30 c.c. of water (10 drops to the ounce). In these cases the edema may rapidly become worse at any moment, dyspnea and cyanosis becoming distressing. The surgeon should be ready to perform tracheotomy or intubation at any moment. It is true that adrenalin will cause a temporary contraction of the swollen mucous membrane, but when its effect wears off the edema is apt to be made worse. The drug may be used in emergency, preliminary to the introduction of a tube.

Membranous laryngitis should receive the appropriate treatment which is indicated by its cause. But, whether fibrinoplastic, croupous, or diphtheritic, the respiratory canal should be kept clear of obstruction. Peroxid of hydrogen is an effective mechanical solvent. It may be used in the form of a spray. Equal parts of hydrogen peroxid, fluid extract of hamamelis, and cinnamon water are useful. Lime water is also of value. The inhalation of the steam rising from slacking lime is of decided help. The air which the child breathes should be kept warm and moist. It may also be medicated. This is done by making a tent over the bed, providing openings for ventila-

tion, and conducting into it steam from boiling water. This may be done with a simple tea kettle, the nozzle of which has been lengthened by a tin pipe. Some soothing and antiseptic action may be secured by adding to the boiling water oil of eucalyptus, oil of pine needles, or oil of tar—1 c.c. in 1 liter (15 drops to the quart) of water. Hot applications to the skin of the throat, or other measures to produce hyperemia, are of decided value. These measures failing to relieve dyspnea, if the child is becoming cyanotic and suffering with air hunger, intubation or tracheotomy should be done. The first of these is to be preferred.

Chronic laryngitis is benefited by the local application of silver nitrate solution (1 or 2 per cent.). The cure requires the removal of the cause. *Dry laryngitis* is relieved by inhaling the steam of boiling water containing 4 c.c. (1 dram) of compound tincture of benzoin, in 500 c.c. (1 pint) of water. Spraying with antiseptic oil, as in acute laryngitis, is of service.

Singers' nodules, usually located on the margin of the vocal cord, single or multiple, are to be treated first by rest. The voice should not be used even for ordinary speaking. This treatment should continue so long as the nodules are growing smaller. When the nodules cease to diminish in size, it means that fibrous tissue is present, and the further reduction of the growth cannot be expected without operation. It is possible to remove the growth, but the operation may leave a permanent damage to the voice tone. Some laryngologists have crushed the nodules by means of laryngeal forceps. Others have reported good results from the application of 3 per cent. solution of zinc chlorid, or 12 per cent. solution of ferric chlorid.

Tuberculosis of the larynx is to be treated by the same means as are described for tuberculosis in general. Ulceration is usually present, and should be treated by local cleansing. A spray of hydrogen peroxid is most effective. This may be followed with a mild alkaline antiseptic spray (page 183). The laryngeal spray apparatus should be used. Dilute hydrochloric or dilute nitric acid should be applied directly to the ulcer after cleansing and drying. Lactic acid, phenol, guaiacol and tincture of iodin have been applied with satisfaction. The laryngeal applicator is used for this purpose. Curetting the ulcers has been practised with success. Some surgeons have preferred to do this operation through a free external laryngotomy opening.

Nervous patients are often made worse by operation; and other methods of treatment are better. In properly selected cases curetting the ulcer is often curative. The actual cautery is of service. Distressing pain may be relieved by a spray of orthoform, 10 per cent., in ether. Cocain may be depended upon to give temporary relief.

Laryngectomy has been resorted to in extensive disease. Tracheotomy is of value in cases of stenosis. Cures sometimes follow this operation. The complete rest of the larynx, secured by tracheotomy, is most beneficial.

None of these measures is apt to be successful if the disease is complicated by pulmonary tuberculosis. The injection of alcohol to block the superior laryngeal nerve arrests the pain and makes swallowing easier in advanced cases. By making pressure externally over the course of the nerve a painful point can be located. The needle is introduced perpendicular to the skin at this point to a depth of 1 or 1.5 cm. (3/8 or 5/8 inch). The point of the needle is then moved about till it touches the nerve. This is evidenced by a sharp pain which radiates to the ear. From 1 to 4 c.c. of a warmed 75 or 85 per cent. alcohol solution are injected. The injection is continued till the pain in the ear stops. The nerve will usually be found at the upper edge of the thyroid cartilage, about one-third of the distance from its outer

edge. The anesthesia, following each injection, lasts from one to forty days.

The tender point will usually be found where the internal branch of the superior laryngeal nerve penetrates the thyrohyoid membrane. This point is about midway between the upper border of the thyroid cartilage and the hyoid bone and about 1 cm. anterior to the superior cornu of the thyroid cartilage.

In some cases of laryngeal tuberculosis swallowing becomes so painful that the patient suffers also from inanition. If injections of alcohol do not give sufficient relief, resection of the superior laryngeal nerve may be done.

Syphilis of the larynx requires first the application of constitutional treatment (Vol. I, page 283). Locally the ulcers should be cleansed the same as in tuberculosis and then touched with phenol, tincture of iodin or silver nitrate solution (5 per cent.). The local treatment is of little momene compared with the great importance of vigorous constitutional treatment. Stenosing contractures must be prevented by constitutional antisyphilitic treatment (see Operations for Laryngeal Stenosis, page 226).

Perichondritis and chondritis, due to tuberculosis or syphilis, require the specific treatment appropriate for these diseases. Typhoid perichondritis is prone to suppuration and necrosis of cartilage. When abscess forms, except in tuberculosis, it should not be temporized with. The pus should be evacuated externally, and not be permitted to rupture spontaneously through the mucous membrane. It will commonly be found that necrosis of a cartilage, once begun in the presence of suppuration does not stop until the whole cartilage is destroyed. By free drainage and careful removal of the necrotic cartilage, edema of the glottis may be averted.

Laryngeal Hemorrhage. -When not due to an open wound, bleeding under the mucous membrane, should be treated by incision and liberation of the clot. A capillary oozing is controlled by the local use of adrenalin. The voice should not be used. Sedatives should be employed to control irritation.

Tumors of the Larynx.—*Benign tumors* constitute the great majority of laryngeal growths. They should be removed. Temporizing with sprays, etc., while followed in a few cases by amelioration or even disappearance of the growth, can not be relied upon. Endolaryngeal growths are best removed by means of cutting forceps, the snare, or curet, in the hands of the experienced laryngologist. In the case of nervous persons, children, and when dealing with extensive or subglottic growths, better success is secured by doing a low tracheotomy and laying open the larynx from the outside (see Laryngotomy, page 230). This exposes the interior of the larynx. The growth may be removed with scissors or knife, and if an open wound remains it may be touched with an antiseptic such as silver nitrate or phenol. Tumors above the vocal cords may be approached externally by subhyoid pharyngotomy (page 229). Laryngotomy is apt to cause changes in the voice and disturbances of phonation; subhyoid pharyngotomy is free from this objection.

Malignant growths are represented chiefly by carcinoma. The *intrinsic* growths are confined wholly within the larynx. *Extrinsic* growths occur at the superior aperture and are not confined by the laryngeal cartilages. The former usually develop more slowly, and infect the lymphatics later. Carcinoma occurs most frequently on the vocal cords. Diagnosis has been made possible by laryngoscopic examinations and the removal of tissue for microscopic examination. The treatment of malignant growths of the interior of the larynx by operation through the mouth is difficult and unsatisfactory.

The same may be said of subhyoid pharyngotomy. Laryngotomy, done by a median incision through the thyroid and cricoid cartilages, is to be preferred in all cases of lateral growths, and tumors not requiring laryngectomy. The interior of the larynx being exposed, the growth should be removed with a safe zone of healthy tissue on all sides. If it is found that the cartilage has been invaded or is dangerously close to the disease, a partial laryngectomy may be done. Total laryngectomy is indicated in cases of bilateral disease with involvement of the cartilage. It may be done in cases with lymphatic involvement. Inoperable cases may require tracheotomy, and nonoperative treatment (see Carcinoma and Sarcoma, Vol. I, page 331).

The results which are being secured in malignant growths of the larynx have steadily improved until now it has become one of the hopeful fields of treatment. No cures were reported before the discovery of the laryngoscope. Glück, in a series of 24 consecutive cases of laryngectomy has had no operative deaths; and in a series of 27 cases of partial excision of the larynx, he had 1 operative death. In 22 cases of laryngectomy for cancer, he had 1 operative death. Pneumonia is the danger to be apprehended in these operations. There are reports of permanent cures not only following simple laryngotomy and laryngectomy, but also following operations in which there have been involvement of the tongue, pharynx, esophagus, and lymphatics of the neck. Cases of intrinsic cancer of the larynx, in which the disease is discovered early, may permanently be cured by median laryngotomy or laryngectomy. It should be remembered that the curable stage gives no symptom but hoarseness, which may come and go. To wait until cough, difficult phonation, pain, odor, swelling, glandular involvement and cachexia are present is to defer until hope has passed. In late cases, operation may prolong life—or shorten it—but if the patient is able to endure an operation, and desires the chance, he should not be denied it (see Laryngotomy and Laryngectomy, page 231).

Tumors of the Trachea.—The treatment of tumors of the trachea is in general the same as that of tumors of the larynx. The benign internal tumors are best exposed by tracheotomy, and removed with knife or scissors. It is possible to remove pedunculated growths by means of the tracheoscope, but the external operation is simpler. In malignant growths, the trachea should be opened, and an operation, sufficient to remove all of the disease, performed. In early cases removal of the mucous membrane may be sufficient. If the tumor fixes the mucous membrane to the surrounding structures, a segment of the whole thickness of the trachea should be removed. The opening may be closed by a plastic operation, or a permanent trachea tube may be used. Before excision of the trachea, a temporary low tracheotomy should be done, if possible (see Resection of the Trachea, page 237).

Foreign Bodies in the Larynx, Trachea and Bronchi.—Usually foreign bodies which enter the respiratory passages cause so great reflex coughing that they are expelled. The lower down they pass, the more difficult is their expulsion. When not forced out by expiratory effort, they become a serious menace to life. It is estimated that the mortality in all cases is about 33 per cent. If the body is not removed, pneumonia, infection and suppuration, or edema may be expected to lead to a fatal termination. In some cases the body passes downward and becomes encysted in a bronchial tube and ceases to be a serious factor. Foreign bodies remaining in the trachea or larynx cannot easily become encysted unless lodged under the mucous membrane; and the sooner they are removed, the better the prognosis.

If the coughing, which the body excites, does not cause its expulsion, the patient should be placed on his back with the head and neck lower than

the thorax, or completely inverted. A child may be held up-side-down and given a few sharp slaps upon the back of the chest at the end of inspiration. If these measures do not cause the extrusion of the body, they should at least prevent it passing deeper toward the lungs. The use of emetics is to be deprecated. If dyspnea is severe or if life is threatened by choking, tracheotomy should be done at once. The offending substance will often be expelled through the wound. If it is above the tracheal opening, the patient has air, and the body may be sought deliberately. It if is below the opening, it may be reached with tracheal forceps.

If there is not sufficient urgency to call for immediate tracheotomy, the next step to be taken is the determination of the character of the body and its location. The modern use of the laryngeal mirror, the *x*-ray, the tracheoscope, palpation, auscultation and percussion may be depended upon to give a pretty accurate location of the foreign body.

A body located between the vocal cords or above them may be extracted with the aid of the laryngeal mirror and forceps (Fig. 885). In some cases it has been possible to dislodge it with the finger. When the finger is used, care should be taken not to force the body downward. When the foreign body is in the larynx below the vocal cords, or in the trachea, it is most easily reached by tracheotomy.

Fig. 885.—Laryngeal Forceps.

In using the laryngeal mirror and in intralaryngeal manipulations, a preliminary cocainization of the mucous membrane by a cocain spray renders the operation more facile. If tracheotomy is done general anesthesia is not advisable because it destroys or diminishes the respiratory and coughing reflexes, and these must often be depended upon to throw out the offending substance. Local anesthesia is entirely satisfactory for the opening of the trachea.

A low tracheotomy is to be preferred. In some cases the body, if in the larynx, can be pushed upward into the pharynx. If it is anywhere between the vocal cords and the bronchi it can be reached with tracheal forceps through the tracheal opening. Bodies impacted low in the trachea or in the bronchi are best removed by the aid of sight, through the tubular tracheobronchoscope. Iron objects may be secured by means of the electromagnet.

The great progress made by tracheoscopy and bronchoscopy in recent years, as a result of the pioneer work notably of Killian and Jackson, has quite revolutionized the surgery of foreign bodies in the respiratory tract. The tubes which have been perfected for this purpose, now make it possible to remove foreign bodies from the trachea and bronchi through the mouth. Pieces of bone, buttons, pins, nails, and other objects have thus been removed. A nail has been removed from a third bronchial division by bronchoscopy through a tracheal opening. It is the opinion that, in these tube operations, general anesthesia should be used in children; in late cases, with irritation and infection, bronchoscopy should be done through a tracheal opening; and bronchoscopy through the mouth should be confined to early cases or cases in which there is but little infection and irritation.

Formerly, bodies in the bronchi were reached only by operation through the chest wall. These operations are still called for when bronchoscopy fails.

If, after the study of one of these cases, the location of the body cannot be determined, but that it exists is quite certain, tracheotomy is called

for as an explorative measure (see Tracheotomy, Tracheoscopy, Bronchoscopy, and Operations on the Chest).

Operations

Tracheotomy.—This is one of the oldest and most important operations in surgery. It is indicated, (1) for the relief of obstructions in the larynx and upper trachea in order that the respiratory air may be admitted below the obstruction, (2) for the direct removal of foreign bodies from the larynx and trachea, (3) for the passage of the bronchoscope, (4) for the direct access to diseases of the trachea, (5) as a preliminary step in operations about the nose, mouth, pharynx, and larynx, in order that the trachea may be occluded above the tube to prevent the inspiration of blood or other matter into the bronchi, (6) for the purpose of preventing the inspiration of infectious matter in certain diseases of the upper respiratory tract, (7) in order to give rest to the trachea in certain diseases, (8) as a preliminary in operations about the head and mouth in order to place the apparatus for anesthesia away from the field of operation, and (9) as a preliminary to certain operations upon the chest wall in order to provide for apparatus for artificial respiration and anesthetization. The operation is done in the median line where there are no important structures except some transverse veins and the isthmus of the thyroid gland. The division of these is not a matter of moment (Fig. 886).

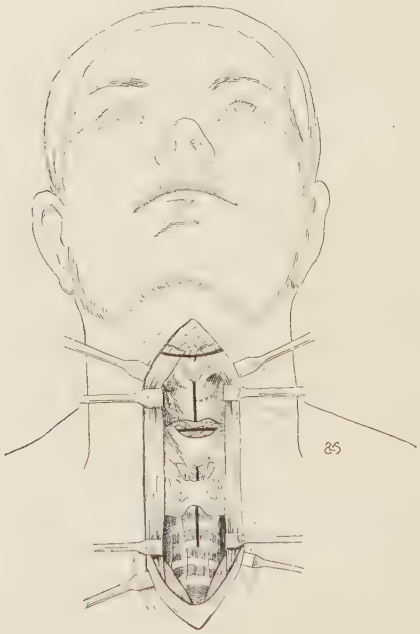

Fig. 886.—Incisions for Operations on the Larynx and Trachea.

Showing transverse incision through hyothyroid membrane, median bisection of thyroid cartilages, transverse thyrocricoid incision, and median tracheotomy.

The special instrument required is the tracheal canula. This instrument, commonly called tracheotomy tube, is made of aluminum, hard rubber, or silver, and is constructed with an inner and outer tube, the latter of which is provided with a broad flange for the attachment of a retaining bandage (Fig. 887). It is well to have several sizes at hand. The largest size that will easily fit the trachea without undue pressure should be used. In emergency a tracheal canula may be made of rubber tubing (Fig. 888). Other instruments needed are a narrow scalpel, four small retractors, mouse-tooth forceps, hemostats, needles, thread, and the special instruments to meet the special conditions present.

Either general or local anesthesia may be used; and in desperate, cyanotic cases, no anesthetic is required. The patient should be in the lowered-head position with the head extended by dropping the head-rest part of the table (Fig. 508) or with a sand pillow behind the shoulders, to bring into strong relief the structures in the front of the neck. If there is great engorgement of the veins of the neck the sand pillow without the lowered-head position

should be used. Either high or low tracheotomy is performed. The two may be combined, and the isthmus of the thyroid divided. If the cricoid cartilage is divided in the operation of tracheotomy, it is a *laryngotracheotomy*.

If the operation is done above the isthmus of the thyroid gland it is called *high tracheotomy*. This is the easiest and most commonly performed operation. The prominent thyroid cartilage of the larynx is the landmark. Below it the cricoid cartilage can be felt. An incision in the median line is made through the skin from above the level of the cricoid downward for 4 or 5 cm. (1½ or 2 inches). The veins lying in the superficial fascia are usually transverse branches of the jugular which may be retracted or divided and tied. The superficial and deep fascias are divided in the same line, and the small communicating veins retracted or divided. The space between the bellies of the sternohyoid muscles and sternothyroid muscles is located and the muscles retracted to either side. Retraction and the position of the patient's head should all be geometrically correct, so that the

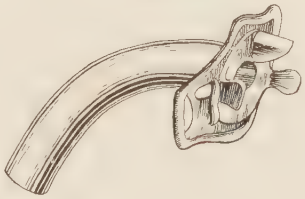

Fig. 887.—Tracheotomy Tube of Aluminum or Silver.

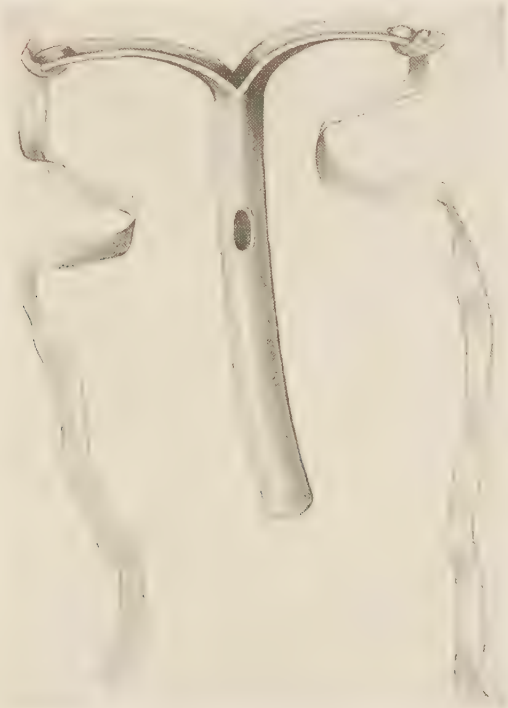

Fig. 888.—Tracheotomy Tube of Soft Rubber.

surgeon shall have no trouble in keeping exactly in the median line. The deep layer of the deep fascia lies across the floor of this space and splits to enclose the isthmus of the thyroid between its layers. The isthmus is recognized as a bulge of soft glandular tissue lying in front of the trachea. Usually one ring of tracheal cartilage lies above the level of the isthmus. The isthmus should

be retracted downward. If it fills too much of the wounds, as is often the case, an incision of the fascia on either side will liberate it, and permit its downward displacement. If necessary the isthmus may be ligated in mass on either side and divided in the middle line. In some cases it is most convenient to retract upward the isthmus, or to divide part of it. The trachea should be cleared of the loose connective tissue lying in front of it, and freely exposed by retraction. The larynx should then be steadied and drawn upward by the fingers or by a small tenaculum, hooked in the cricoid cartilage, and the upper two or three rings of the trachea divided in the middle line. This should be done with a fine knife which divides also the mucous membrane. It is best that the incision be made upward. L. S. Pilcher practised removing a small piece of the tracheal rings to make a free opening.

When it is desired to make a permanent tracheal opening or to reach low-lying foreign bodies, *low tracheotomy* is done. The preparation is the same as for the high operation. The skin incision is made in the middle line from just below the cricoid cartilage nearly to the sternum. The veins and small arteries are retracted or tied and cut. The same fascial layers are encountered. The thyroid isthmus is retracted upward, or it may be best to divide all of it or part of it. The surgeon should remember that a middle thyroid artery is sometimes given off from the innominate artery, and passes up in front of the trachea; the innominate sometimes is found as high as the seventh ring of the trachea; and the thymus gland, in the young especially, may completely overlie the trachea below the thyroid gland. Two or three rings of the trachea should be divided in the middle line sufficiently far above the sternum so that at inspiration the lower end of the opening does not sink below the upper border of the manubrium.

The cartilages and mucous membrane having been incised, the necessary thing should be done. If the operation is for diphtheria, false membrane should be removed. This is accomplished with forceps and swab. Often long strings of membrane may be pulled out. But even though much of the obstruction is removed, a trachea tube should be inserted. If done for obstruction which is not to be removed at once, a tube is inserted. When disease, such as ulcer is treated, it is well to insert a tube in order to continue the treatment. If done for a foreign body, which is removed, the wound may be closed at once. After operations upon the head, the bleeding having been checked, the tube may be removed and the wound closed. The same course is to be followed when the higher disease for which the operation was done no longer threatens complications.

The insertion of the tube is accomplished by retracting laterally the divided rings with the small retractors. The tube should be provided with tape for fastening it. It should be slipped gently through the wound and downward until the flange engages against the skin. Force should not be used. The tube should just nicely fit the trachea. It should be held by a tape passed around the neck. One suture should be put in the wound above the tube and preferably none below. A small strip of gauze should be packed into the lower and upper parts of the wound, and a layer of gauze placed between the skin and the collar of the tube. A few layers of gauze, moistened with water, should be kept over the mouth of the tube. This gauze should be moistened frequently. It is to filter out dust and give some moisture to the inspired air. The comfort of the patient will be contributed to by keeping the air in the room moistened with steam.

There are certain *operative complications* which may occur. These are not so much to be expected when the operation can be done deliberately; but when a hurried emergency tracheotomy must be performed, damage may be

done to the adjacent structures. It sometimes becomes necessary, without preliminary preparation, or assistance to open the trachea with the knife that comes quickest to hand. In such emergency operations the bleeding from the distended veins may be profuse, and as the trachea is opened much blood may be aspirated. The bleeding may be checked by grasping each edge of the wound between the fingers, or, if a free hand is needed, by making pressure on either lip of the wound with the index-finger on one side and the middle finger on the other. As the patient gets air and the cyanosis subsides, the venous engorgement abates. Aspirated blood itself may become a serious menace and add to the dyspnea. When it is not promptly coughed out, it may be removed by passing a soft rubber catheter down to the bifurcation and sucking it out or forcing air in. The lowering of the patient's head and elevation of the lower part of the trunk is of service. In incising the trachea false membrane may not be incised but left clogging the opening, this should quickly be removed.

The *postoperative complications* most to be guarded against are in the nature of infections. Pneumonia should be guarded against, by cleanliness of the wound; by keeping the patient's skin healthy; by maintaining the vital resistance; by protecting the skin from chill; and by providing fresh, clean, moist, filtered air.

Complications may be avoided by *postoperative care.* The inner tube should be removed and cleaned in warm water several times daily. Mucus appearing in the tube can be caught with a swab during expiration. In order that the inner tube shall not have to remain out too long, it is well to have two, one being ready to insert as soon as the other is taken out. The outer tube should be taken out by the third day to be cleansed, and in order to inspect the trachea. The interior of the trachea may then be cleaned of mucus. Any pressure-ulceration calls for another tube. Granulations line the opening by this time, and replacing the tube is not difficult. Retractors may be required. The filtering gauze over the tube should be changed as often as it becomes soiled by mucus coughed into it. Mucus should be kept wiped away from the skin, and if the skin becomes red a mild antiseptic powder should be applied. Granulations may require to be suppressed with silver nitrate. When the tube has served its purpose and is no longer required it should be removed and the wound allowed to close by granulation under an aseptic dressing.

Suprahyoid Pharyngotomy.—This operation is, perhaps, less hazardous than the operation below the hyoid. A transverse incision is carried along the upper border of the hyoid bone from sternomastoid muscle to sternomastoid (Fig. 504). This divides the platysma, mylohyoid, geniohyoid, and part of the digastric and hyoglossus muscles. After hemostasis is secured the mucous membrane is opened transversely. A good approach to the lower pharynx, back of the tongue, and upper larynx is secured. The wound should be closed by layer sutures, with provision for drainage anterior to the posterior layer of fascia. Healing is best secured if a preliminary tracheotomy has been done and the canula retained for a few days.

Subhyoid Pharyngotomy.—This operation is rarely performed. The operation is sometimes indicated to reach the structures in the region of the upper aperture of the larynx. The same preparation as for tracheotomy is required. A transverse incision is made just below the hyoid bone (Fig. 504). This divides skin, superficial fascia and platysma. Hemostasis is secured, and the wound deepened by transverse incision of the sternohyoid and thyrohyoid muscles. This exposes the thyrohyoid membrane, which is incised horizontally together with the mucous membrane. By keeping close

to the hyoid bone, the superior laryngeal vessels and nerves which pierce the membrane close to the thyroid cartilage on either side are avoided. This operation gives a good exposure of the epiglottis and upper laryngeal aperture. At the conclusion, the wound is sutured in layers with provision for drainage of the tissues anterior to the thyrohyoid membrane. The operation cannot be aseptic. Edema of the glottis, infection and pneumonia make the mortality high. A tracheotomy should give rest to the wound in healing and reduce the hazard.

Transverse Laryngotomy.—This operation is done through the cricothyroid membrane in persons over thirteen years of age (Fig. 504). In younger persons the cricothyroid space is too small to make it worth while. The operation is a valuable emergency expedient when the disease or obstruction is high. It is the easiest of the operations for external opening of the air passages. The space between the thyroid and cricoid cartilages is located, and a median incision made. The fascia is dissected away from and the space exposed by retracting laterally the sternohyoid and sternothyroid muscles. The cricothyroid artery comes off from the superior thyroid and passes transversely across the membrane to meet its fellow from the opposite side. This should be looked for and avoided. A transverse incision is made through the membrane and mucosa. The necessary thing may be done, and the wound left to heal by granulation, or a short canula inserted as in tracheotomy.

Median Laryngotomy (Thyrotomy).—This operation consists in laying open the larynx for the purpose of removing foreign bodies or tumors, or for the treatment of disease (Fig. 504). The preparation is the same as for tracheotomy. Local or general anesthesia may be used. A preliminary low tracheotomy should be done and a canula inserted. In some cases it is best to do this tracheotomy a week or two before, in order that the patient may become accustomed to breathing through a tube and the trachea made tolerant. To prevent blood flowing down to the bronchi, the operation should be performed with the patient in the lowered-head position, or the trachea above the canula should be packed with gauze, or the sponge-covered canula should be used. The thyroid cartilage of the larynx should be exposed by a median incision. The soft tissues are retracted laterally, and hemostasis secured. The thyroid cartilage is then divided exactly in the median line, the incision involving the mucous membrane. Retractors are applied and the interior of the larynx is exposed. To minimize shock and bleeding, all of the exposed mucous membrane should be touched with a 4 per cent. solution of cocain in adrenalin solution. The conditions for which the operation is done should then be given attention.

In most cases it will be best to carry the opening still lower by dividing the cricothyroid membrane and the cricoid cartilage in order to secure good retraction. In other cases the operation is required to be continued downward into the trachea (laryngotracheotomy).

If the operation has left a defect of tissue, a tracheal canula should be retained in place. If no considerable traumatism has been inflicted upon the mucous membrane the canula may be removed. The laryngotomy wound should be closed by sutures of chromicized catgut through the cartilage but not involving the mucous membrane. The soft structures should be sutured over this or the wound may be allowed to drop together without sutures. Some advantage in healing may be secured even in uncomplicated cases by leaving in the canula. If it is well borne, it should by all means be retained for a few days. If no canula is used, one ready sterilized should be

at hand for the first few days, ready to be introduced in the event of edema of the glottis developing.

By means of this operation, exploration is most successfully made, foreign bodies removed, cicatrices divided or excised, ulcers or other disease treated, and tumors extirpated. If it is found that the operation must be converted into a partial or complete laryngectomy, it may easily be continued as such. Before closing the wound the presence of packing should not be forgotten.

Partial Laryngectomy.—This operation is a continuation of median laryngotomy. When it is found that a portion of the larynx should be sacrificed for carcinoma, an incision should be made from 0.5 to 1 cm. ($\frac{3}{16}$ to $\frac{3}{8}$ inch) from the outer margin of the disease; and the adjacent cartilage may be cut away with scissors or knife. A similar operation is done for necrosis of cartilage. In tuberculosis and benign tumors it is usually necessary to sacrifice only the mucous membrane. When a large defect of mucous membrane is left after removing the disease, if the scar contraction which must follow its healing is going to narrow seriously the lumen of the larynx, the defect may be covered with epithelium by turning in a flap of skin, and suturing it to the mucous membrane. After several days, when it has united, the pedicle is divided, and the remaining mucous membrane and skin edges sutured together. After the success of the transplantation has been assured, the tracheal wound, which has had to be left open, should be sutured. In the course of ten days more, the low tracheotomy canula may be removed. In cases in which so much of the wall of the larynx has been sacrificed that inspiration causes a serious collapse of the soft coverings, it should be practicable to turn up an osteoplastic flap containing the anterior table of the manubrium, as in the trachea (page 237), or a piece of costal cartilage may be transplanted.

Total Laryngectomy.—The complete removal of the larynx is done for bilateral intrinsic cancer, in hopeful cases of extrinsic cancer involving both sides of the larynx, and in extensive tuberculous laryngitis. In cases of marked stenotic contractures and in extensive necrosis of the cartilages, the operation is not called for if the mucous membrane is not ulcerated. Under the best conditions, the operation is not free from shock, and should not be done upon feeble patients. Glück's consecutive series of 24 cases, with no deaths due to the operation, and Crile's 27 laryngectomies with 2 operative fatalities, by no means represent the average mortality in the hands of the average surgeon, for most surgeons know of pneumonia, reflex inhibition of the heart and respiration through irritation of the superior laryngeal nerves, mediastinal abscess, neuritis of the vagus, sepsis and shock as frequent complications if the patients who are entitled to laryngectomy are operated upon as they come.

For intrinsic cancer, this operation offers the greatest hope; and recent results show a low degree of mortality. The disease is recognized early; it does not tend to invade the cartilages; it does not produce early metastases; and for these reasons can be wholly eradicated, and is, perhaps, the most curable of any internal cancer.

Laryngectomy in one stage is a much more hazardous operation than the two-stage procedure. For all cases local anesthesia is best. The general anesthetic of choice is nitrous oxid and ether. If a tracheotomy has been done, the anesthetic may be given through the tube. Even though general anesthesia is used, the lines of incision should first be infiltrated with novocain.

The lowered head position is used, with the knees flexed and the legs fastened to keep the patient from sliding. The head should be extended

upon the trunk to bring the front of the neck into prominence. The lowering of the head should not be so great as to cause a swelling of the veins of the neck, but simply sufficient to give the aid of gravity in preventing blood from running into the bronchi. Better than a sand-pillow behind the shoulders is a table with a head-rest which can be dropped.

An incision is made in the median line from the hyoid bone nearly to the sternum. If necessary, a transverse incision may cross the upper end of the median incision. The skin, superficial fascia and platysma should be dissected free, exposing the larynx and the overlying muscles from the hyoid bone to the second ring of the trachea. The sternohyoid, the anterior belly of the omohyoid, sternothyroid and thyrohyoid muscles are divided on either side at both the upper and lower limits of the larynx, and retracted laterally. The superior thyroid arteries should be ligated (see Vol. I, page 411). This vessel passes downward from the cornu of the hyoid bone, under the above-mentioned muscles, and is easily identified, as it gives off its branches at the

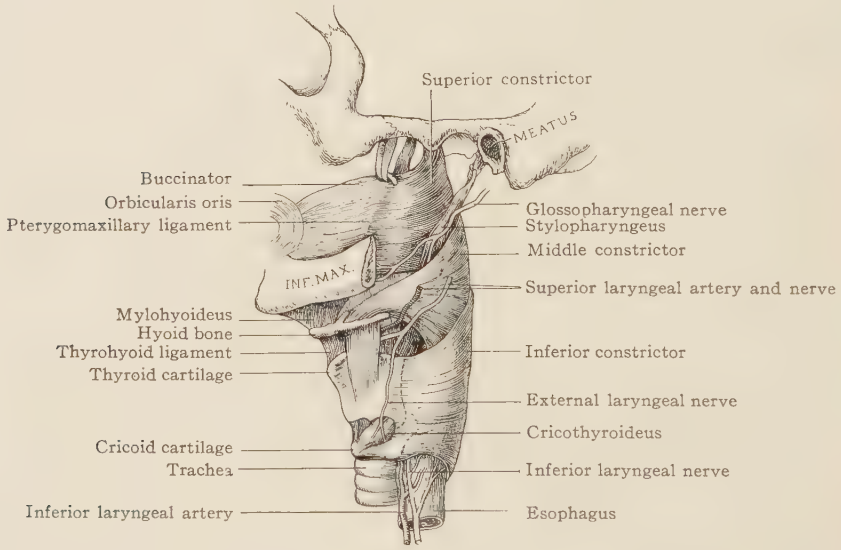

FIG. 889.—MUSCLES OF PHARYNX AND EXTERNAL RELATIONS OF LARYNX. (*After Luther Holden.*)

thyrohyoid membrane. The larynx is then freed partly by blunt dissection just as though it were a tumor. The dissection should be carried back to the esophagus, from which it should partly be separated. Novocain solution should be injected under the mucous membrane at the level of the incision and the trachea divided at the first ring. The division may be made below or above the cricoid cartilage, depending upon the location of the disease. The trachea is then brought forward through the lower end of the wound, the isthmus of the thyroid having been tied in two places and divided between. The stump of the trachea is fastened to the skin on either side by a suture. The anesthetic is then continued through a tube in the trachea.

The larynx should be lifted forward and dissected free from the esophagus. Novocain solution should be injected about the mucous membrane, and the thyrohyoid membrane divided close to the hyoid bone. A packing of gauze is inserted in the pharyngeal wound, the larynx is drawn forward and removed.

The mucous membrane of the trachea should be treated with a 10 per cent. solution of cocain, applied with a pledget of gauze before inserting the tube. After the trachea has been sewed to the skin, a good-sized tracheal canula should be introduced. The sutures are tied about the canula to hold it in place. This tube should fit so snugly that blood can not enter the trachea. The anesthetic is continued through the canula if general anesthesia is employed.

In dividing the inferior constrictor of the pharynx, as much as possible of the muscle should be left for the later closure of the wound (Fig. 889). As much of the pharyngeal mucous membrane as possible should be left for the same reason. The place of amputation, below and above, should be well beyond the disease, the location of which should have been predetermined by

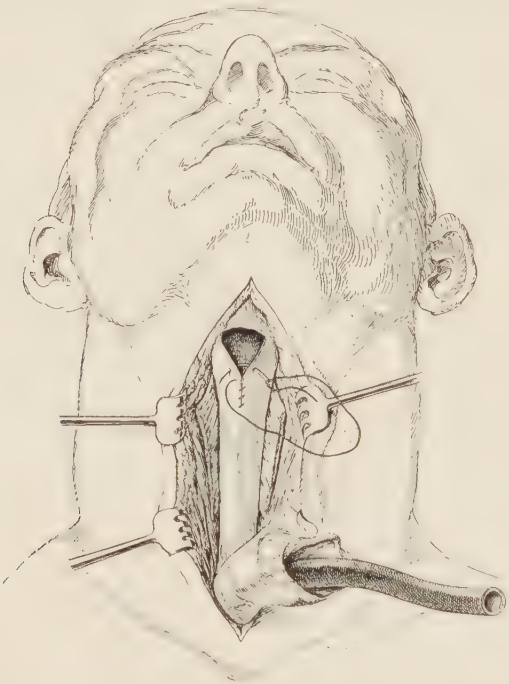

FIG. 890.—LARYNGECTOMY.
The larynx has been freed and permitted to fall forward. The pharyngo-esophageal opening is in process of being sutured.

laryngoscopic examination. Usually the division will be made above the third ring of the trachea.

The opening into the pharynx should be closed by two rows of sutures, and the sternohyoid and sternothyroid muscles sutured across in front. The wound should be dried and packed with gauze saturated with 1 per cent. iodin solution. The skin wound should then be closed, leaving an opening for the gauze drain. A moistened gauze covering should be placed over the canula opening.

The operation of Glück makes the division of the thyrohyoid membrane first. A tracheotomy tube is then inserted into the upper opening of the larynx and the dissection continued downward. The amputation at the first ring of the trachea is then done (Fig. 890).

Exceptional Conditions.—In this operation should the esophagus be opened by accident, or a part of it removed by design, the wound should at once be sewed by a suture passing down to but not through the mucous lining. In more extensive disease, involving esophagus and pharynx, the structures invaded should be removed. Such an operation may require removal of the base of the tongue, part of the pharyngeal wall, esophagus and lateral structures of the neck. It is possible to remove in such an operation part of the common carotid artery, internal jugular vein, and pneumogastric nerve of one side, together with the adjacent structures. If so much of the pharynx or esophagus is removed that it cannot be united over the feeding tube, a permanent pharyngeal or esophageal fistula in the neck must be made by sewing the skin to the mucous membrane.

A rubber deglutition tube is used. It has a funnel at the upper end. Artificial feeding is avoided by passing this tube through the mouth, into the esophagus well beyond the fistula, the funnel at the upper end resting upon

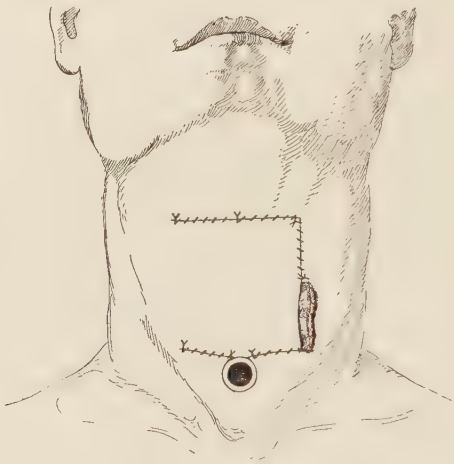

Fig. 891.—Wound Closed after Laryngectomy with Rectangular Flap.

Note tracheal tube and drainage gauze.

the base of the tongue and pharynx and preventing its slipping downward. With this tube the patient is able to swallow fluids which are placed in the mouth. The removal of the epiglottis should depend upon its involvement in the disease. If possible it should be saved.

Other Operations.—Glück made a rectangular skin-platysma flap, having its base at one side, the two sides of the flap representing the upper and lower limits of the larynx. This flap is turned aside. A straight median incision passes down in front of the trachea from the middle of the lower transverse incision. Before closing the wound he introduces a rubber feeding tube through the nose and pharynx into the esophagus. At the close of the operation the stump of the trachea is sutured in the vertical wound and the rectangular flap is sutured back with provision for drainage. The free side of the flap should be directed to the side upon which the patient prefers to lie, preferably the right side (Fig. 891). Most surgeons now use only the median incision, and remove the epiglottis whether it is diseased or not. Perier's method begins with a T-incision; the trachea is divided early at the first ring; the great cornua of the hyoid bone are divided; and the anterior

wall of the esophagus is sewed to the thyrohyoid membrane. In some cases it may seem best to perform a preliminary tracheotomy.

Laryngectomy in two stages has recently come to be most highly prized. It is the operation of choice. At the first operation the larynx is isolated from its surrounding connections, but not cut loose from the trachea or pharynx. It is left in place, and packed about with gauze. This packing with gauze in the presence of a clean wound results in the formation of granulations; there is no danger of infection; and when the larynx is taken out later, the remaining cavity is found lined with granulation tissue. This is most important because the danger of mediastinal infection is obviated. In the one-stage operation the cavity left after removal of the larynx presents a great wound-surface with feshly opened cellular tissues; in the two-stage operation the myriads of cellular mouths are closed by granulations. The second operation may be done five or ten days after the first operation.

Crile performed a preliminary tracheotomy and packed the larynx and trachea about with gauze as a first operation (Fig. 892). This two-stage

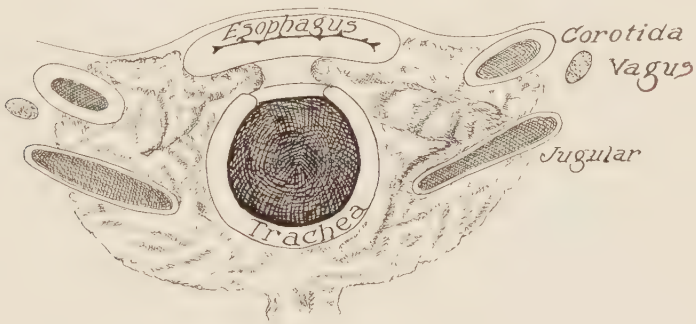

FIG. 892.—LARNYGECTOMY.
Diagram showing method of packing gauze about larynx as a preliminary operation.

operation, combined with preliminary tracheotomy, is the ideal procedure, and should give the lowest mortality.

In the one-stage operation, the deep packing with iodin gauze is intended to serve this same purpose—exciting the throwing out of a protective barrier of connective tissue and exudate to prevent infection of the mediastinum.

Conclusions.—Whatever operation is done a happy outcome should not be expected unless the patient's mouth was clean and free from infected teeth and the anesthetic administered by skilled hands. The lowered-head position and the coughing reflexes should be depended upon to keep the bronchi free of blood. If the lowered-head position is not used, the inspiration of blood may be prevented by tracheotomy and a gauze tampon above the tracheal canula as the first steps in the invasion of the respiratory tract. The cocainization of the mucous membrane of the larynx before introducing a canula is an important step for the prevention of shock.

Sébileau (Bull. et Mém. Soc. de Chir., Paris, Feb. 15, 1910) practised first a preliminary tracheotomy which was done twenty days before the final operation. Second, the stump of the trachea was carefully sewed to the skin just above the sternum, the sutures including the edge of the tendon of the sternomastoid muscle. Third, the pharyngeal wound was closed and the hyoid muscles sewed in front of the line of suture. Fourth, the cavity was obliterated by sewing the divided hyoid muscles and the subcutaneous

fatty tissue in front of the esophagus, and applying a firm compression dressing. Fifth, a drain was placed in the upper angle of the wound to provide for the escape of pharyngeal secretions. Sixth, the patient was fed by a nasal tube for a week on ten days.

After-treatment.—The after-treatment of these cases requires as much skill and more zeal than the operation. All the rules for the after-treatment in tracheotomy (page 229) apply here. Besides these, especial care is needed to see that no regurgitated gastric contents or discharge enter the trachea. Every precaution should have been taken to prevent postoperative vomiting. The anesthetic should have been discontinued as soon as possible, and the patient should have regained consciousness before the end of the operation. The patient should be propped up in bed on the day after operation, and if his strength will permit he should be sitting up in a reclining chair on the second day after operation. If he feels like it, he should be encouraged to walk about on the third day. Care should be taken that the strength of a weak patient is not overtaxed. Feeding should be by nutrient enemata for the first five days. The mouth and teeth should be swabbed every hour with a mild antiseptic, such as mentholated boracic acid solution. As soon as stomach feeding is begun, only sterile foods, served in sterile receptacles, should be used for the first ten days. If the patient requires more nourishment than can be supplied by the enemata, a sterilized rubber tube should be passed by the mouth or nose into the esophagus, and the food administered through that. If nutrient enemata have been used for five days, feeding by the esophageal tube may be begun on the sixth day and continued till the tenth day. Then food may be swallowed from the mouth, unless a fistula has appeared in the neck, in which event the esophageal tube should be continued. The patient should be watched every minute day and night by a competent nurse for the first two days. Morphin or drugs which inhibit the bronchial reflexes should not be given.

The gauze drain should be removed on the second day. If there is discharge and evidence of leakage from the mouth, it should be changed sooner. If the wound is clean, only a small bit of drain should be inserted. The entrance to the trachea should be kept scrupulously clean. The gauze around the tracheal canula should be changed as often as it is soiled. It is best to use gauze moistened with weak bichlorid solution. The whole canula should be removed and replaced by a sterile one every four hours. The inner tube should be cleaned or changed for a sterile one every hour or two. For keeping the throat clear, the suction apparatus employed by dentists may be used with advantage, during the first few days.

A soft rubber tube may be introduced through the nostril and pharynx into the esophagus before the wound is closed. This tube may be left in place, and the patient fed through it as soon as the stomach is ready for food.

Vomiting and deglutition can prevent healing by dragging upon the suture line. Some surgeons prefer to avoid feeding-tubes because of the muscular action of the throat caused by their presence.

Phonation.—After laryngectomy, without apparatus, patients may develop the power of pharyngeal articulation by which they are able to make themselves understood by persons near by. The artificial larynx has not been perfected to the degree to make it satisfactory. Its chief objection is that it requires an opening of the pharynx. Glück has devised an apparatus which can be used after closure of the pharynx. The apparatus consists of a metal cap which is connected with the tracheal canula. A valve permits inspiration but not expiration. Between the valve and the canula a tube goes off which contains a small reed. This is connected with a tube which

passes through the nose to the pharynx. Expiration takes place through this, and causes the reed to vibrate. The sound is conveyed to the pharynx, where, by the muscles of phonation, it is transformed into articulate speech.

Resection of the Trachea.—This operation sometimes is required in connection with laryngectomy. When the disease for which the larynx is removed involves also the trachea, the latter is resected at the same time. It may require independent resection for malignant disease, tuberculosis, cicatricial contracture, necrosis of cartilages, or destructive wounds. The preparation, and position for operation are similar to that for tracheotomy or laryngectomy. A median incision is made, the isthmus of the thyroid ligated in two places and divided between, and the trachea dissected free from its lateral attachments. The recurrent laryngeal nerve lies in the angle on either side between the trachea and esophagus, and should be spared if possible. The trachea having been isolated, it should be divided below the disease, a canula inserted, and the anesthetic continued here. The diseased part should be separated from the esophagus and the trachea divided above the disease. If the gap in the trachea is not more than 3 cm. (1¼ inches) it can be united with chromic catgut sutures, and normal breathing restored. If the gap is too great to be sutured, a special tracheal canula may be fitted to conduct the respired air across the gap. I believe in such cases it would be feasible to turn up an osteoplastic flap containing the anterior table of the manubrium, to give stiffness to the tracheal wall and to furnish an epithelial lining, this to be covered by a second flap with the epithelial side externally. Costal cartilage may be transplanted to give stiffness to the reconstructed tube.

Intubation of the Larynx.—This operation, perfected by Joseph O'Dwyer, consists in placing in the larynx a tube of metal or hard rubber for the relief of dyspnea due to certain forms of laryngeal obstruction.

The *indications for intubation* are found in obstructive conditions not due to spasms which cause dangerous dyspnea, and which are dilatable or capable of being passed by an instrument. The operation has found its greatest field in diphtheria in which the membrane has grown into the larynx. It is applicable also in edema of the glottis. It has no place in the case of tumor, or in conditions in which it is desired to give rest to the larynx. If the obstruction is below the reach of the intubation tube it is of no use. If force is required to introduce the tube through the glottis, it should not be used. In other conditions, producing cicatricial contraction which is steadily encroaching upon the lumen of the larynx, the tubes are used to maintain the patency of the laryngeal tube. The operation is well suited to children because in these tracheotomy produces more shock and takes more time. The operation has the disadvantage that special instruments and special experience are required.

The *instruments for intubation* are essentially those devised originally by O'Dwyer. They consist of a set of tubes, made in various sizes, each provided with a flange at the upper end which rests upon the false vocal cords, and prevents the tube slipping downward (Fig. 893). With these are used an instrument for inserting and extracting the tubes, also a mouth gag and other accessory instruments. A tracheal canula and the instruments for tracheotomy should always be at hand, in readiness for employment, in case the false membrane is pushed ahead of the tube, and occludes the trachea, or in case the tube is too small, and slips through the larynx.

Many modifications and a few improvements of the O'Dwyer instruments have been made. Perhaps the best of these are those of Max Thorner. These instruments are more simple than those of O'Dwyer. The tubes have

the upper opening funnel-shaped and the lower end oblique. The inserter and extractor are combined in one simple instrument.

The *technic of intubation* is simple. No anesthetic is required. If the danger of shock is great the laryngeal mucous membrane may be cocainized or a hypodermic injection of atropin may be given. In children these are rarely required. Most operators have the patient in the sitting position facing the surgeon. The child is held on the lap of an assistant just as in the operation for adenoids without an anesthetic (see page 208). Another assistant extends the head upon the neck and holds the mouth gag. With the arms and legs pinned in a swathing sheet all of this can be done by one



Fig. 893.—Intubation Instruments.

assistant. The mouth is held widely open; a tube of correct size, fixed upon the introducing instrument, and having a loop of thread passed through a hole in its upper end, is taken in the right hand; the surgeon introduces the index-finger of his left hand into the mouth of the patient, hooks its tip laterally back to the epiglottis, and draws the epiglottis and base of the tongue forward thus widely opening the larynx; the tube is then introduced, passing along the left forefinger as a guide, until its tip enters the larynx, and passes down between the vocal cords; the tube, being well engaged in the larynx, is steadied by the finger, and the introducer is removed; the tube is then pushed gently into place, being steadied by the loop of thread which is used

to withdraw it in case it slips too far downward; if the tube fits nicely and the patient breathes satisfactorily, the loop of thread is cut and removed, and the tube left in place. If the surgeon is not quite sure of the fit of the tube, the thread may be fastened around a tooth or an ear and left.

Some laryngologists prefer to place the patient swathed in a sheet in the dorsal position on a table with the head hanging over the end, or in the position described for laryngectomy. An assistant leans over the patient with his elbows on either side of the trunk, and grasps the head laterally with his hands. The surgeon sits or stands on one side facing the patient's face, and introduces the tube as above described. This position has the advantage that the patient may be held more steadily, there is less shock, the light comes from above, there is less danger of the tube slipping down, and in the event of necessity the patient is ready in position for tracheotomy. This position is coming more and more into use.

The manipulations in the operation should be gentle. The instruments should not press upon sensitive parts. The tube and introducer should be kept accurately in the middle line. The passage of the tube into the larynx should be easy.

The description of this operation is easy, the execution is fraught with difficulties. The patient struggles and gags. In diphtheria he coughs bits of membrane into the surgeon's face. A sudden motion may displace the mouth gag, and the surgeon may be bitten badly. The tube may be lost from the holder, and pass into the esophagus. It may force false membrane ahead of it and occlude the trachea, demanding immediate tracheotomy to save the child's life. Spasm of the glottis may be so severe as to make intubation impossible. Some of these conditions are present in most cases, and success is secured only through experience, patience, and gentleness.

The *postoperative care* requires constant watching of the patient as long as the tube is in place. Unless the loop of thread is left in the tube so that the nurse may withdraw it, the patient should not be left without some one present who can take out the tube. Its withdrawal is necessary in case it should become clogged. If difficulty is found in removing the tube the patient should be inverted and given a smart slap on the back while gentle traction is made on the thread. If the tube is coughed out, as is often the case, it will be found usually that it is no longer necessary. If it is still needed, it should at once be replaced.

The feeding of the patient is usually not difficult. Fluids may be taken without trouble. In some cases deglutition is much interfered with, and the patient can take only very small amounts at a time or must be nourished from a nursing bottle. Some cases require that the head shall be lower than the thorax in order to swallow. When these difficulties are insurmountable, nutrient enemata must be resorted to. Rather than that the patient should suffer from lack of nourishment, tracheotomy should be performed and the laryngeal tube removed.

When the need for the tube has passed it is best removed by the extracting instrument. The operation should be conducted the same as the introduction. The paralysis of the vocal cords which follows the wearing of the tube is temporary.

Tracheoscopy and Bronchoscopy.—The principles applied in these operations are the same as employed in *direct laryngoscopy*, *esophagoscopy*, and *gastroscopy*. It consists in passing a straight tube into the organs designated, through which examination and treatment may be conducted. The instruments which are most effective are those perfected by Killian, of Freiburg, and by Jackson, of Pittsburg. They consist of straight tubes of various lengths

and sizes, with and without electric lamps at their lower or upper extremities (Fig. 894). For the larynx, the laryngoscopic speculum (Fig. 895) is useful. This instrument is employed as a guide also for the passage of the deeper instruments. Forceps (Fig. 896) and other appliances, which may be

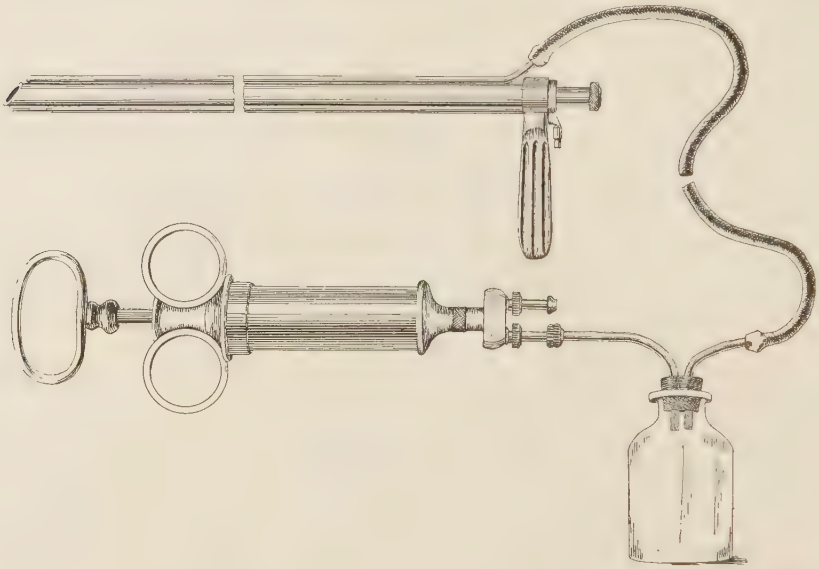

Fig. 894.—Instruments for Tracheoscopy, Bronchoscopy, and Esophagoscopy. Esophagoscope with aspirator.

passed through the long tubes are used. The successful handling of these instruments is only acquired by practice. In order to avoid the shock arising from manipulation or pressure upon the laryngeal mucous membrane, it should be cocainized, whether general anesthesia is used or not. The amount of secretion may be lessened by a preliminary dose of atropin.



Fig. 895.—Laryngeal Speculum Through Which Esophagoscope is Passed.

The position of the patient best for these operations is lying on the back with the head hanging over the end of the table and resting upon a movable extension. In this position, with the mouth widely opened, and the epiglottis and tongue drawn forward, a good view below the vocal cords may be had without any tube. These operations are best performed under general anesthesia, although Killian succeeded wonderfully with a local anesthetic. The mouth should be well cleansed and the instruments made aseptic.

For *direct laryngoscopy*, Jackson uses the separable illuminated slide speculum alone. This instrument may be used with the patient under general anesthesia or with local anesthesia. For local anesthesia, the pharynx is cocainized with 4 per cent. cocain on a swab; and the larynx is cocainized with a 20 per cent. solution applied with laryngeal forceps guided by the

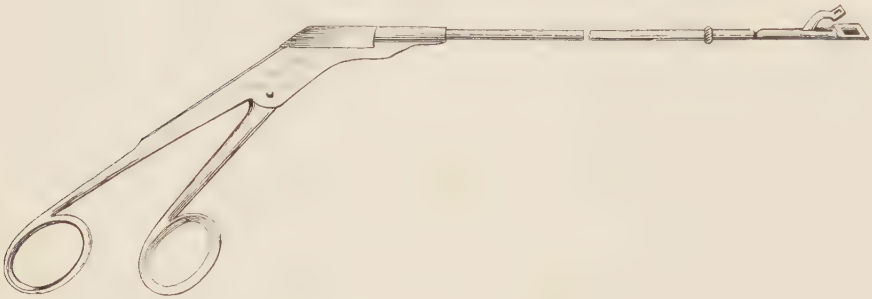

FIG. 896.—ESOPHAGOSCOPIC AND TRACHEOSCOPIC FORCEPS.

FIG. 897.—BRONCHOSCOPY.
Showing use of head-lamp and reflector.

laryngoscopic mirror. The instrument is used as in superior bronchoscopy and constitutes the speculum through which the bronchoscope is passed. With this short speculum in position, the larynx and the region of the pharyngo-esophageal orifice are brought in full view. Foreign bodies may be removed, new growths excised, edematous swellings incised and punctured, or applications made. When these instruments are used without an internal lamp the head lamp and reflector of Kirstein are useful (Fig. 897).

For *superior bronchoscopy*, according to the method of Jackson, the patient is fully anesthetized and placed in the dorsal position with the head

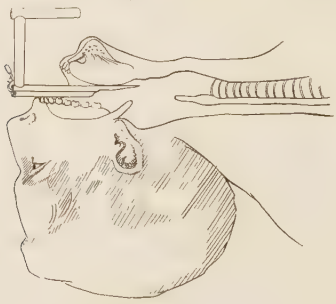

Fig. 898.—Tracheobronchoscopy.
Tracheal speculum in position.

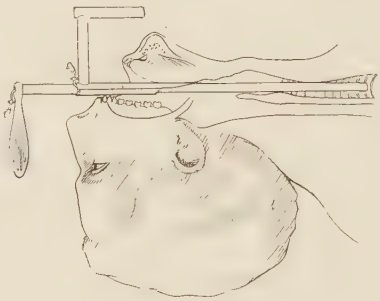

Fig. 899.—Tracheobronchoscopy.
Bronchoscope passed through speculum.

extended at the occipito-atloid and atlo-axoid joints. The extension of the neck should not make a curve distributed along the whole cervical spine. The head while resting on the head-extension of the table should still be controlled and rest in the hands of an assistant.

The illuminated slide speculum is passed into the mouth directly in the median line close to the dorsum of the tongue until its tip has just passed the epiglottis. The tip is then tilted strongly forward by lifting the handle.

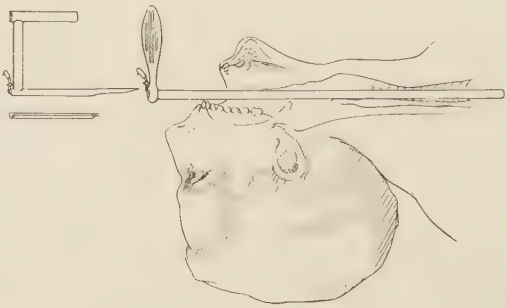

Fig. 900.—Tracheobronchoscopy.
Speculum removed, leaving bronchoscope in position.

This presses forward the epiglottis and the base of the tongue and exposes the glottic aperture (Fig. 898). The bronchoscope is lighted and passed through the speculum into the trachea (Fig. 899). The speculum is then removed, and the bronchoscope passed to the desired point (Fig. 900). Care should be taken in first introducing the instrument that it is not passed too far beyond the epiglottis. The closure of the upper esophageal orifice by the pharyngeal constrictors may be mistaken for the glottic orifice, and the instrument passed into the esophagus.

The instrument can be made to enter either bronchus by swinging it to one side. Secretion which is in the way may be sponged out, or if excessive it may be aspirated through a rubber tube. The lamp, becoming covered with blood or dimmed by some other means, may be removed and cleaned without withdrawing the bronchoscope. The bronchoscope is provided with side openings so that it shall not occlude the bronchus which it does not enter. Forceps of various forms and probes are employed to remove foreign bodies. By observing from which orifice the most secretion pours or which shows a reddened and swollen mucosa, a hidden foreign body may be located.

The operation of *lower bronchoscopy* is practised through an opening made in the trachea (Tracheotomy, page 226). This greatly facilitates access to the bronchi. A shorter tube may be used, the view is better, the mouth and larynx are avoided, an aseptic operation may be done—and in many respects the operation has advantages over the high bronchoscopy. Its disadvantage is that a tracheotomy is added. It is by this operation that the second and third divisions of the bronchi are made accessible.

The operation of **esophagoscopy** is performed with the patient in the same position as for upper bronchoscopy, or in the lateral position. The same



FIG. 901.—ESOPHAGOSCOPE.
The direct illumination instrument of Green.

instruments may be used as for bronchoscopy, or the esophagoscope of Von Mikulicz. The slide speculum may be used, and the esophagoscope passed through it. Experience enables the operator to pass the esophagoscope without a speculum. Some prefer to use the finger as a guide, starting the instrument at the right side of the mouth, guiding it to the right side of pharynx, and thence into the esophagus. The entrance to the esophagus is opened by lifting forward the base of the tongue and hyoid bone. The method now much in favor is by the use of a flexible guide, which is first passed and then followed by the esophagoscope.

The direct illumination instrument of N. W. Green (Annals of Surgery, vol. 59, 1914) is highly satisfactory (Fig. 901). R. Lewisohn (Annals of Surgery, vol. 57, 1913), devised a very effective telescoping esophagoscope. He showed the dangers and disadvantages of the straight, rigid, and flexible instruments; and perfected an instrument which can be introduced with the patient sitting, and cause no serious discomfort (Fig. 902).

For the operation of esophagoscopy, a general anesthesia is not so necessary as in bronchoscopy. A tractable patient, with an empty stomach, and the esophageal orifice anesthetized with 10 per cent. cocain solution, can coöperate in the operation, if conscious. The lateral position is preferred for the rigid-tube instrument, the head being supported by an assistant. The patient is instructed to breathe quietly, to let the saliva flow, and to raise

his hand if he experiences severe pain. The instrument should glide into the esophagus without force. The pain in the larynx, following the operation, can be relieved by cold applications to the throat.

The location of the disease should be known beforehand in order that the shortest tube may be employed. Through the esophagoscope, foreign bodies may be removed, tumors excised, strictures incised or dilated, ulcers treated, fissures cauterized, and diverticula treated.

A longer instrument is used for **gastroscopy.** Jackson and others have even passed the pylorus with these instruments and entered the duodenum (see Esophagus and Stomach).

The **removal of foreign bodies** from the larynx, trachea, bronchi, esophagus, or stomach is accomplished through the tubes used in the above operations. Forceps for use in these instruments are helpful. Many forms are made. The wire snare may be of service in some cases. It is possible

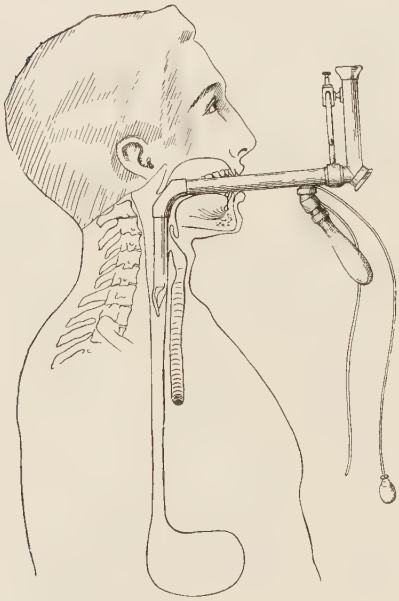

FIG. 902.—ESOPHAGOSCOPE.
The telescoping instrument of Lewisohn.

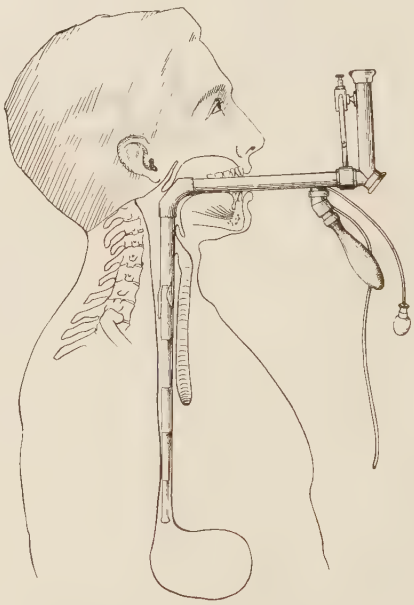

FIG. 903.—ESOPHAGOSCOPE.
Telescoping instrument released and tube extended to stomach.

to slip a snare over an open safety pin and close it before attempting its removal. This has been successfully done. A magnet on the end of a rod may be used to remove iron bodies.

THE MOUTH

Two peculiarities of the oral cavity are of moment in the treatment of its injuries and diseases: asepsis can not be attained; and all of its structures are extremely vascular. The high degree of vascularity usually insures healing notwithstanding the infection which naturally is present.

Cleansing the Mouth.—While an aseptic state of the buccal mucous membrane cannot be attained, still a high degree of cleanliness is possible.

Before undertaking important operations in the mouth, such as excision of the tongue or for cleft palate, the state of the teeth should be looked to, and any decayed or septic teeth should receive appropriate attention; the teeth should be kept well cleaned; spongy gums should be treated with a mild astringent; nasopharyngeal disease should be cured; and infected tonsillar follicles should be treated. A 1 per cent. hot solution of sodium oleate is an effective mouth disinfectant. The soapy taste may be removed with a 5 per cent. solution of potassium chlorate. For several days before operation the nose should be sprayed with a mild alkaline antiseptic solution (page 183), and the mouth should be washed several times daily with the above solutions, or with equal parts of alcohol and water.

The **hygiene of the mouth** must not be neglected by the surgeon. To remove particles of food from between the teeth, the teeth should be brushed after each meal with a brush of bristles. Seriously sick patients should have their mouths cleansed several times during the day. This is one of the important functions of nursing. The mouth should be rinsed with warm water, containing sodium chlorid, boric acid, tincture of myrrh, cologne water, or alcohol. Sore places should be treated with boric acid. If the tongue is dry, it should be moistened with 25 per cent. glycerin solution.

A useful mouth wash consists of glycerin (1 part), alcohol (3 parts) and boiled water (6 parts).

Examination of the Mouth.—In examining the mouth preliminary to treatment the patient should either sit facing the light or lie recumbent. With a good light, a laryngeal mirror, and a tongue depressor, all parts of the mouth may be brought into view for treatment. In the case of children a gag may be necessary. Before such examination and treatment the surgeon should wash his hands in the presence of the patient.

For prolonged exposure of the mouth cavity the *mouth-gag* must be used. There are many forms of this instrument (Fig. 524 *a*, *b*, *c*). Care should be taken that pressure is made on the teeth, and not on the soft tissues. During operation, an aspirating apparatus, on the principle of the air pump, such as used by dentists, may be employed to remove saliva and other fluids.

Position for Operation.—In bloody operations in the mouth, the best position for operation is with the head lowered. To prevent blood running into the larynx it is the practice of some surgeons to perform tracheotomy, insert a tracheal canula, and pack the lower pharynx with gauze. This operation has the advantage that it removes the anesthetic apparatus from the field of operation. The entrance of blood into the larynx and esophagus can be nearly as well prevented by the lowered-head position. The disadvantage is that the blood runs from the nose and mouth instead, and requires to be sponged away.

Hemostasis.—In most wounds of the mouth bleeding stops when the wound is sutured. As a preliminary to small operations, to prevent excessive bleeding from small vessels, adrenalin, locally applied, is of value. In operations involving large vessels, to prevent serious loss of blood, temporary or permanent ligation of the contributing artery may be practised. In cavities or wounds, which are not to be sutured, packing with gauze is an effective hemostatic.

Anesthesia.—For operating under general anesthesia, the ordinary mask may be used, and operation and anesthetization made to alternate. Pressure hemostasis may be made while the mask is on the patient's face. The operation is continued until the patient begins to show reflexes, and then it is interrupted and the anesthetic resumed. The use of the nasal tube, through which the patient may breathe and at the end of which the anesthetic

mask may be applied, takes the latter away from the field of operation. Local anesthesia is effective for a large proportion of operations in the mouth. Cocain may be applied directly to the mucous membrane, or the anesthetic may be injected through a previously benumbed mucosa. A mouth gag having tubes attached for carrying anesthetic vapors into the mouth is often useful (see Anesthesia, Vol. I, page 124).

Wounds of the Lips.—Contusions and wounds of the lips may result in much swelling. Often an extensive wound may be found through the mucous membrane as the result of crushing the lip against the teeth. If such a wound of the mucous membrane is seen at once, the mouth should be cleansed with boric acid solution, the teeth should be cleaned, and if the wound is large and gaping, the lip should be everted and the wound sewed with fine silk. Whether the wound is sewed or not, the mouth should be washed frequently with boric acid solution.

Wounds involving the exposed mucous membrane or skin should be sutured with fine silk, pains being taken to secure niceness of apposition.

Inflammations of the Lips and Mouth.—*Cellulitis of the lips* is always difficult to treat. The causative factor should be discovered and eliminated, if possible. Often an infected hair follicle or mucous gland can be discovered. This should be incised with a sharp-pointed knife. Causative eczema or herpes should be treated. For the cellulitis itself hot applications are effective. They should not be applied to the mucosa. As soon as suppuration is focalized an incision should be made. In the female, the incision should be through the posterior surface of the lip even though the pus is nearer the skin surface. With local anesthesia, a horizontal incision should be made. In a man the hair should be shaved from the lip, and a horizontal incision made at the place nearest to the pus. An opening sufficiently large for free drainage is demanded.

Chapped lips may be prevented by anointing the mucous membrane of the lips with oil, fat, glycerin, or ointment before exposure to the cold, wind, or other causative conditions. The treatment consists in the use of applications. If a *fissure of the lip* has developed, and, because of induration about its base, refuses to heal, it may be touched with silver nitrate. If this does not effect a cure the best treatment consists in excising a small wedge containing the fissure and sewing the wound. This operation may be done with local anesthesia. It has the advantage that it cures the disease and diminishes the possibility of the development of epithelioma at the site of the fissure.

Herpes of the lips should be treated first by removal of the cause. Often this is an infection of the nasal or buccal mucous membrane. In adults, when due to auto-intoxications, the patient should be given a laxative, put on a reduced diet, and the lip touched with spirits of camphor or alum. If scabs or ulcers have formed, an ointment should be used (see Herpes, Vol. I, page 829).

Ulcers of the lips should not be permitted to become chronic. If they do not heal under the treatment recommended for ulcers (Vol. I, page 308), after the constitutional cause has been removed, the ulcer should be curetted, or removed by a wedge-shaped excision and the wound sewed.

Stomatitis is an inflammation of the lining of the mouth, which may represent any of the many varieties of mucous membrane infection. The treatment is similar to that which is given for inflammations of the nose, throat, or other mucous membranes. In most cases a wash of saturated solution of boric acid will effect a cure. The teeth should be kept clean. The wash should be used every hour at least. *Thrush* should be prevented by cleanli-

ness in the feeding of infants. When, as a result of ignorance or carelessness, it occurs, the swabbing of the infected areas with boric acid solution should be sufficient. If this does not check the disease, stronger antiseptics should be used. Unless the progress of thrush is stopped, infection and even perforation of the intestine, as shown by H. P. deForest (Am. Jour. Obstet., Jan., 1910), may occur. *Gonorrheal stomatitis* should be treated the same as gonorrheal infection elsewhere. The local application of silver nitrate solution to the infected area is most effective. *Membranous stomatitis* is treated by hydrogen peroxid and the same applications as recommended for membranous tonsillitis.

Gangrenous stomatitis (cancrum oris), due to the inoculation of virulent organisms into the tissues of the lips and cheeks of feeble persons, usually children, requires vigorous treatment. The nourishment of the patient should be improved. This is best done by feeding with top milk and eggs, and keeping the child in the open air. Sloughs should be cut away. Burrowing pus should be freely evacuated. Pure phenol followed by alcohol, or other strong antiseptics, should be applied. The infected external parts should be kept covered with a large, hot, wet, antiseptic compress. The mouth should be washed with boric acid solution.

Bites of insects upon the mouth may cause edema or cellulitis. If it is known that the insect has come from putrid material, tincture of iodin should be applied (see Stings and Bites of Insects, Vol. I, page 275).

Epithelioma of the Lower Lip.—This slow-growing disease is most susceptible of radical cure if operated upon early. The presence of enlarged lymph nodes in the neck should not militate against operation. The enlarged lymphatics may be due to bacterial infection; and even though due to secondary deposits of epithelioma, there is always hope that the last-involved gland may be removed. When no enlargement of the lymphatics is palpable, it should be assumed that the lymph-nodes of the neck are involved, and they should be removed, except in the very early cases; and many surgeons operate on the neck even in the early cases. The proportion of surgeons in this last class is steadily increasing. When a surgeon says that he does not open the neck in early cases and has only 20 per cent. of recurrences, we should ask him, why not try to prevent some of the 20 per cent. recurrences? It should always be borne in mind that the glands are involved before they become enlarged, and that they become enlarged before they can be felt. The question is, why take any chances with a curable disease which is fatal if not cured?

If the disease is on both sides of the median line an incision should be made below the lower border of the lower jaw from one facial artery to the other. The facial arteries and veins should be ligated and cut. The superficial skin flap should be dissected down as far as the middle of the larynx, or farther if necessary. The subcutaneous fat should not be included in the flap (Fig. 904). Having turned down the flap, the superficial fat, lymphatics, and connective tissue should be dissected up in a mass extending back to the great vessels and especially in the spaces below the jaw. The tissues should be dissected away from the muscles connecting the jaw and the larynx so that the outer surfaces of these muscles is exposed. The mass of tissue that is dissected up should include the submaxillary salivary glands, because the first lymphatics to become involved lie in the embrace of these glands. This mass should not be disintegrated but should be in one body (Fig. 905).

The tumor, growing in the lip, should then be removed by incisions on either side of it far enough away to escape the disease. These incisions should preferably be vertical and involve the whole thickness of the lip.

When the lower limit of the disease is reached, the incisions should be connected by a transverse incision. If the diseased area is not small the two

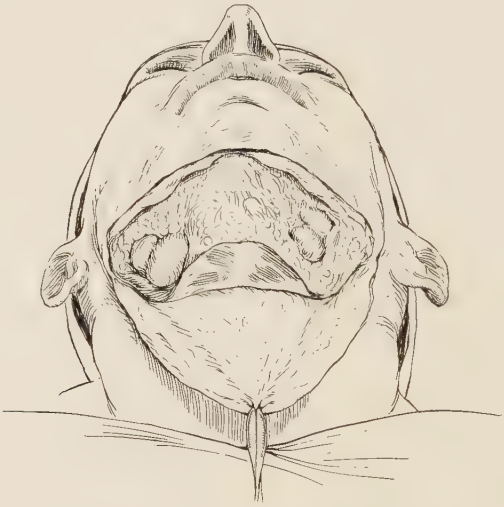

Fig. 904.—Operation for Epithelioma of Lip. First Stage.
Superficial flap turned down, exposing lymphatics and connective tissue.

vertical incisions should pass from the lip down to the submaxillary incision (Fig. 906). The tumor with the attached skin and the mass of connective tissue and glands from the neck should all be removed as one mass.

Fig. 905.—Operation for Epithelioma of Lip. Second Stage.
Lymphatic and connective tissue dissected up in a mass.

If the segment of the lip removed is too large to permit easy closure of the wound, lateral incisions should be carried outward through the cheeks from the angles of the mouth. This permits sliding flaps inward, and the

turning out of mucous membrane to cover the new-formed lip (Fig. 907). The mucous membrane inside of the mouth should be sewed to close the

FIG. 906.—OPERATION FOR EPITHELIOMA OF LIP. THIRD STAGE.

After the neck dissection, the lip is incised on either side of the disease, and the isolated segment of lip removed with the tissues of the neck. The lymphatics and connective tissue which have been dissected from the neck are placed on a piece of gauze which covers the wound.

FIG. 907.—OPERATION FOR EPITHELIOMA OF LIP. FOURTH STAGE.
Result after closure of incisions.

wound from mouth secretions. A drain should be placed in either side of the neck.

In cases of more extensive growth, involving the whole lip, the primary

incisions may be wider (Fig. 908) (see Plastic Operations, Vol. III, and Surgery of the Neck, Vol. II, page 360).

In early cases of disease of one side only the neck operation may be confined to one side; in older cases both sides should be operated upon. In recurrent cases, following the old-fashioned V operation, a wide dissection

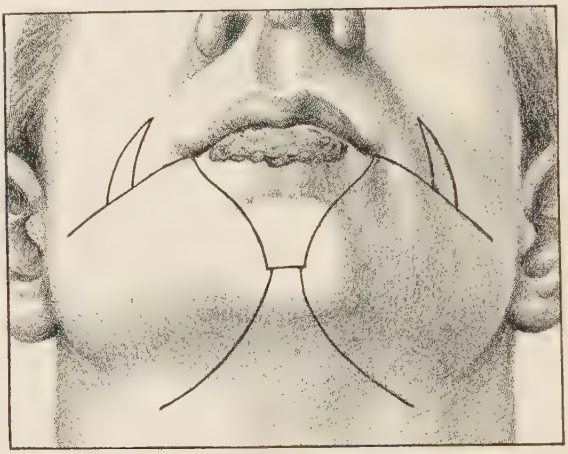

Fig. 908.—Operation for More Extensive Epithelioma of the Lip. Lines of incision.

may be made and life saved. Apparently hopeless cases may be cured by boldness of dissection. The amount of tissue that may be removed from the neck is very great. One carotid artery one deep jugular vein, one pneumogastric nerve, the larynx, trachea, lower jaw, tongue, esophagus, muscles, lymphatics and skin may be removed if necessary to save life.



Fig. 909.—Epithelioma of Lip. The V-Incision.

Although progressive surgeons now operate on the lymphatics in all cases, still the old incomplete operation made many cures. Twenty years ago I removed by V-shaped section an epithelioma of the lip of four months' standing. Eighteen months later, an enlarged nodule appeared in the neck, and was removed under local anesthesia; one year later I removed a second

enlarged nodule from the neck; and though microscopic examination showed epithelioma in all three operations, still no further recurrence took place, and the man remains well today. Had the lymphatics been operated upon at

FIG. 910.—RESECTION OF LOWER LIP WITH PROVISION FOR SLIDING FLAP.



FIG. 911.—RESECTION OF LOWER LIP. Sliding flap sutured in place.

the first operation, the hazard of recurrence in this case would have been avoided.

The surgeon should not be encouraged by the cures in the old methods to neglect the neck. The following technic may be followed, but in all of

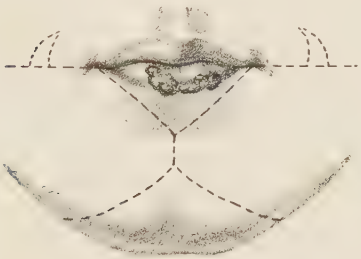

FIG. 912.—EXCISION OF LOWER LIP WITH PROVISION FOR PLASTIC SLIDING FLAPS TO CLOSE WOUND.

FIG. 913.—WOUND CLOSED AFTER EXCISION OF LOWER LIP.

these methods there should be added the dissection of the neck. From the incisions of excision, in all of these cases, there should be carried downward an incision connecting the lip wound with the submaxillary incision.

FIG. 914.—RESECTION OF LOWER LIP BY V-INCISION WITH ADDITIONAL LATERAL INCISIONS.

FIG. 915.—WOUND CLOSED AFTER V-RESECTION OF LOWER LIP.

The technic in the cases of very small tumors consists in making a V-shaped incision through the whole thickness of the lip. The incision should be so placed as to remove 1 to 2 cm. of apparently sound tissue on either side

of the growth (Fig. 909). If as much as a half of the lip is removed, or so much that a disfiguring tightness of the lower lip or redundancy of the upper lip results, a transverse incision should be carried outward from the corner of the mouth and from the bottom of the wound to permit a flap to slide inward (Figs. 910 and 911). In making the horizontal incision from the

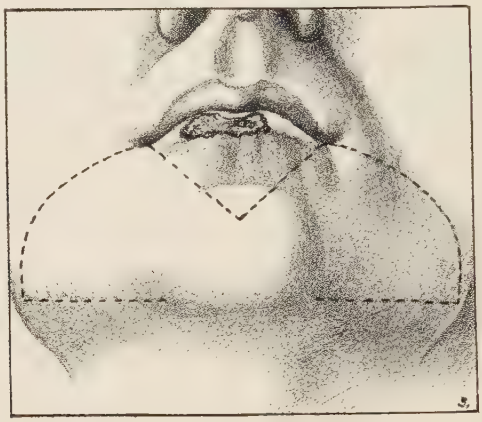

Fig. 916.—Excision of Lower Lip with Provision for Plastic Flaps to Cover the Defect.

angle of the mouth, the mucous membrane lining the cheek should be divided on a level about 1 cm. higher than the division of the skin on the outer side of the cheek in order to provide mucous membrane to be turned out to form a covering for the newly constructed part of the lip (Figs. 912 and 913).

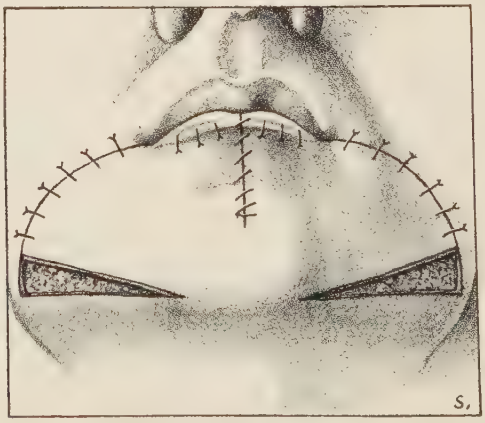

Fig. 917.—Lip Restored by Plastic Flaps.

In cases in which the whole or nearly the whole of the lower lip is removed, the V should have a wide angle (Figs. 914 and 915) or the excision should be in the form of a U. As much of the chin as possible should be preserved. Horizontal incision should be carried outward from the corners of the mouth as described above. These incisions should be made higher in the mucous membrane than in the skin. Two lower incisions should curve

FIG. 918.—EXCISION OF LIP WITH PROVISION FOR LATERAL FLAPS.

FIG. 919.—LATERAL FLAPS USED TO RESTORE LOWER LIP.

FIG. 920.

FIG. 921.

FIG. 920.—RESECTION OF LOWER LIP WITH FLAP FROM ABOVE TO FILL DEFECT.
FIG. 921.—RESECTION OF LOWER LIP.
Defect filled by flap from above.

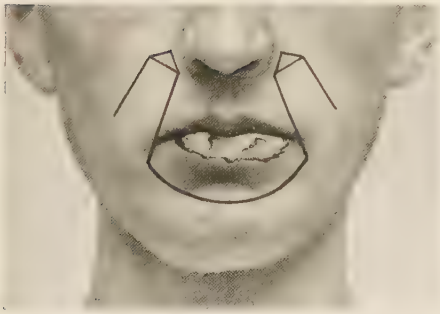

FIG. 922.—REMOVAL OF WHOLE LOWER LIP.
Defect to be corrected by flaps from cheeks.

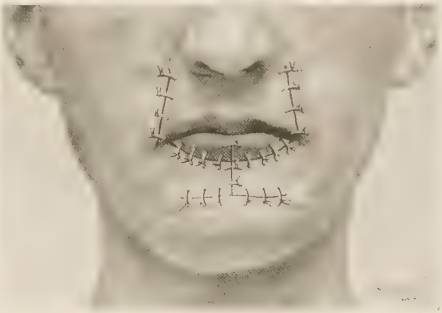

FIG. 923.—LIP RESTORED BY FLAPS FROM CHEEK.

downward and backward from the bottom of the wound, passing upon the cheeks or the neck below the jaw (Figs. 916 and 917). These two lower incisions serve for the loosening of the sliding flaps and also for the dissection of the submaxillary lymphatics (Figs. 918 and 919). Other incisions are required to meet special conditions. A flap from the upper lip may be turned

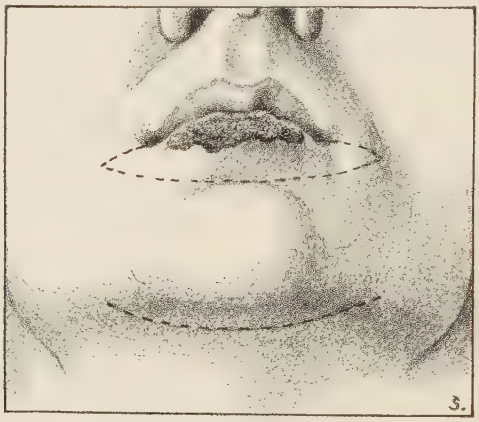

Fig. 924.—Excision of Lower Lip with Provision for Sliding Chin Flap.

down to fill the defect in the lower lip if the mouth is not small (Figs. 920 and 921). Flaps may be turned down from the cheeks to reconstruct a whole lower lip (Figs. 922 and 923). A new lower lip may be reconstructed by sliding up the tissues of the chin (Figs. 924 and 925).

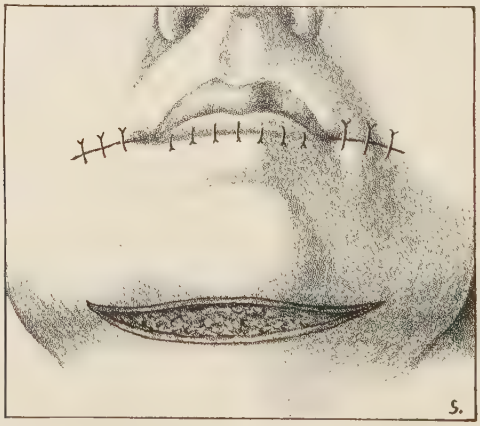

Fig. 925.—Lip Restored by Sliding Chin Flap.

Benign Tumors of the Lip.—*Angioma of the lip* may be treated by the methods already given for that disease (Vol. I, pages 325 and 842). If it involve much of the thickness of the lip the tumor may be excised. The free mobility of the tissues here renders excision of the growth and plastic closure of the wound very satisfactory. *Cystomata, horny elevations* and other benign tumors should be removed as elsewhere.

Macrocheilia.—Permanent enlargement of the lip or lips, whether congenital or due to lymphangiectasia, may amount to a disfigurement. A very satisfactory improvement in the appearance may be made by removing a broad wedge from the whole width of the lip and sewing the wound. The base of the wedge should represent the junction of the buccal and orificial surfaces of the lip. It should be planned so that enough tissue is removed to bring the lip down to the desired thickness (Fig. 926). A thin sharp knife is essential. The wound should be closed with deep and superficial sutures of horsehair or celluloid thread (see Plastic and Cosmetic Surgery, Vol. III).

Fig. 926.—Macrochelia. Operative removal of a wedge of tissue to reduce the size of the lower lip.

Diseases of the Soft Palate and Uvula.—*Acute infections* of the soft palate should at first be treated by a boracic acid spray and the relief of adjacent infections. If the edema becomes marked, multiple punctures should be made. This may be done by passing a retractor behind the palate to support it, and then making ten or twenty punctures into its substance with a sharp-pointed bistoury. The punctures should be about 3 mm. deep, and should be made especially in the uvula and lower part of the palate. *Abscess of the palate* should be incised. For Mycosis, see Vol. I, page 838.

Ulcers of the uvula and soft palate, when of syphilitic or tuberculous origin should receive their appropriate treatment (see Syphilis and Tuberculosis, Vol. I, pages 283 and 276). Simple ulcers are best treated by being touched with silver nitrate. Fluid diet should be used.

Bifid uvula may be treated by grasping the tip of each part and denuding its inner surface of mucous membrane with knife or scissors, and then suturing the cleft.

Elongation of the uvula may be said to exist when it impinges upon the tongue or epiglottis during inspiration. If it gives rise to symptoms of irritation, it should receive treatment. The cause of the relaxation should be sought. Anemia, constitutional weakness, or chronic nasopharyngeal disease should be corrected. Often there is nothing to be found but a relaxed condition of the tissues of the pharynx. Astringents such as nitrate of silver (5 or 10 per cent.) or chromic acid (10 or 20 per cent.) may be applied to the relaxed structures by means of a cotton-covered applicator two or three times each week. Relaxation due to diphtheria or other paralyses should receive general treatment.

If these measures fail *uvulotomy* should be done. The whole uvula should never be removed except for malignant disease. The uvula is anesthetized by applying strong cocain solution at its anterior surface and then making infiltration injections of mild anesthetic. For elongated uvula, only enough of the tip should be cut off to make it normal in length. If the section is made transversely and not sutured an open wound is left at the tip. The irritation of food may cause hyperplasia and a consequent enlargement of the stump. This may be obviated by grasping the tip with forceps, removing a wedge with the apex upward, and closing the wound with a fine catgut suture (Figs. 927 and 928). In some cases three sutures may be required. Distressing cough, nausea and vomiting may be relieved by this operation. Uvulotomy should not be done at the same time that adenoids are removed lest adhesions take place.

Tumors of the palate should be removed by wide excision if malignant. Benign tumors should be removed if they produce any disturbance of function or distress. Certain hypertrophies of the soft tissues under the hard

palate and osteomata of the hard palate cause a swelling in the middle of the roof of the mouth which develops up to a certain point and remains stationary. These tumors require no treatment.

Adhesions of the soft palate to the pharyngeal wall, commonly due to syphilis, have been referred to under adhesions of the pharynx (page 205). Many operations have been devised for this condition. None will be success-

Fig. 927.—Cuneiform Uvulotomy. Incision.

Fig. 927*a*.—Cuneiform Uvulotomy. Wound Closed.

ful unless after their separation the parts are kept apart. Whether this is accomplished by an obturator, by repeated retraction, or by continuous retraction, it all comes to the same thing—separation of the parts until the wounds made by the incision have become covered with epithelium. A method which has been ineffective in some cases may be effective in others. In all cases a horizontal curved incision should pass across the back of the

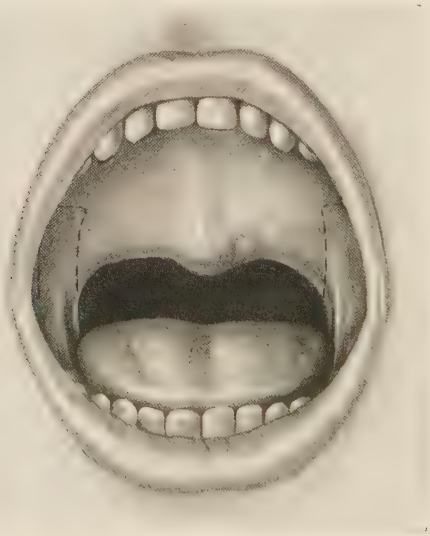

Fig. 928.—Adhesion of Palate to Pharynx.
Showing incisions for making mucous membrane flaps.

palate dividing it from the pharyngeal wall. This should be sufficiently wide to make a free opening from the buccal pharynx to the nasal pharynx, turning down the soft palate as a flap. A method of maintaining the separation until healing of the surfaces is complete, which may be tried, consists in holding the flap of soft palate forward by suturing it temporarily to the under surface of the hard palate. A leaded weight may be sewed to the flap to keep it down.

After cutting free the palate from the pharyngeal wall the raw surface on the palate may be covered by flaps of mucous membrane. A flap may be taken from the side of the palate and inside of the cheek. This may be placed so that it folds under the free edge of the soft palate. Its free end may be held by sutures passing through the palate. Laterally it may be sewed to the mucous membrane of the under surface of the palate. This operation is done on either side (Figs. 928 and 929).

Cleft-palate.—The satisfactory treatment of this condition requires an understanding of its causation.

In early fetal life the nose and mouth make one cavity. At the eighth week the palate begins to grow in from either side in the form of two horizontal processes. These processes meet and coalesce in the middle line. When their development is arrested a median cleft of the palate results. This may be complete or the processes may unite in some of their

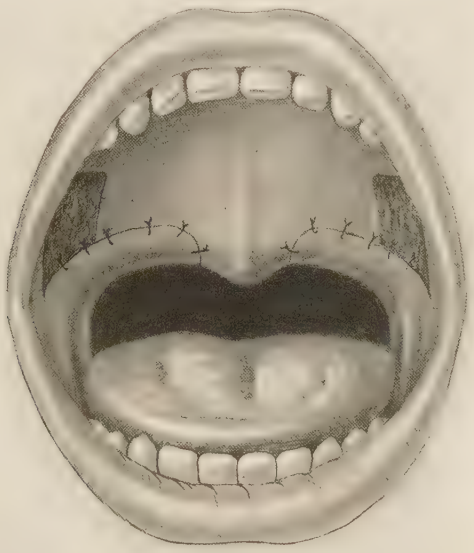

FIG. 929.—ADHESION OF PALATE TO PHARYNX.
Adherent palate has been separated, mucous membrane flaps cut and sutured over the raw surface produced by dissecting free the palate from the pharynx.

parts in front or behind. The roof of the mouth is not wholly formed by these two processes. In the middle line and anterior to them a median process of mesoblastic tissue comes down from above, and goes to make up the front part of the hard palate, the anterior part of the nasal septum, and the middle portion of the upper lip. The intermaxillary bone is represented in this tissue. When this intermaxillary process fails to unite with the rest of the maxilla a lateral cleft results. Such a cleft may be on one or both sides and is found running through the base of the nostril. Thus the cleft in cleft-palate which is required to be repaired may be represented by a Y or any of its parts. The anterior intermaxillary process may be dislocated forward if both arms of the Y fail to unite, so that a median portion of the lip and palate, together with alveolar process, bearing the middle incisor teeth, may project forward. For this reason cleft-palate is apt to be associated with hare-lip (Fig. 930).

Unless these clefts are closed, sucking is impossible or difficult, food passes into the nose from the mouth, speech is imperfect, and the individual suffers the moral harm arising from the deformity.

The infant with cleft-palate must be fed in the vertical position so that the food will flow easily into the esophagus.

If operation cannot be done at once, the mother should press the bones of the upper jaw together several times daily. This treatment tends to reduce the width of the fissure. As soon as operation can be done it should be proceeded with. The surgeon should not be ambitious to complete the work at one operation. It is much better to do what can be done easily and satisfactorily, and finish the operation later. Several operations may be required. The harelip should be operated upon after the palate has been made entirely satisfactory.

Operation by all means should be undertaken before the child is over three months of age. The mortality among infants not operated upon is very high. Although the modern tendency is to operate early, many surgeons still prefer to wait until the child is stronger. Some surgeons prefer to operate for cleft-palate when the child is five or six years old, and for harelip at the age of six months.

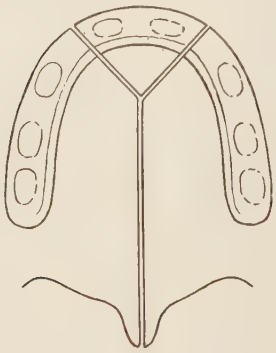

Fig. 930.—Diagram of Anatomy of Cleft Palate and Premaxillary Process.

The most favorable *time for operating* is as soon as possible after the child is one day old. It seems that the undeveloped state of the nervous system at this age makes shock less of a factor. The parts are pliable, and vocalization is not developed. If the child is poorly nourished, or weak, or possessed of incurable defects, operation had best not be undertaken until it is gotten into a better state of resistance. An operation which is done after vocalization is established, may correct the anatomic defect, but the defect of speech will remain.

The best *position for operation* is the lowered-head position so that blood may escape by the nose and mouth. The child should be swathed to confine its arms and legs; and fixed with its head lowered on the operating table.

If the *intermaxillary segment* is free, it should be sutured back in place after freshening the edges. Fine silver wire is best for this purpose. If it is held away by a short septum a wedge may be removed from the front of the latter. Usually it is easily pressed into place. A later plastic operation may be done, if necessary, to elevate the front of the flattened nose. In young infants this segment requires no attention, as the pressure of the lip will hold it back after the cleft has been operated upon. The repair of the harelip should be deferred until the operation on the palate has proved itself successful.

The *later operation*, which must be performed upon children whose jaws have become firm, must deal especially with the soft tissues. The mouth should be gotten into as healthy a condition as possible. Diseased teeth and tonsils should receive attention. Adenoids should be removed. The child should be made accustomed to the antiseptic spray. It should not be operated upon unless its health is good.

The *instruments* required are mouth gag, tongue depressor, palate knives (narrow scalpels), elevators for separating the soft tissues from the hard palate, small swabs for sponging, needles, needle-holders, silk and fine wire sutures. The anesthetic should be begun with an ordinary mask, and

continued with a nasal inhaler or tube. Operation cannot be done well without a good light and good assistants.

The *simple operation for closing a narrow cleft* is done as follows: A silk suture is passed through the tip of the tongue to draw it forward. Care should be taken that the tongue is not pulled so far forward that the glottis is opened for the entrance of mucus and blood. With the child in the lowered-head position, the edges of the cleft are freshened by removing a thin strip of mucous membrane from either side, or by incising each edge longitudinally and spreading the wounds wide apart. This latter is better than sacrificing tissue, although more difficult. An incision is then made along the inner aspect of the alveolar process (Fig. 931) on either side. The closer these incisions are made to the teeth, the broader will be the flap for suturing and the less will be the tendency to slough. Bleeding should be

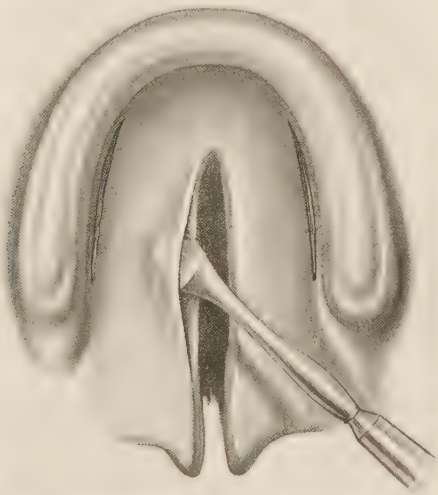

Fig. 931.—Operation for Closure of Narrow Cleft in Cleft Palate.

Edges freshened and lateral incision made along alveolar margin. This incision and the subsequent loosening of the mucous membrane should not injure the descending palatine artery.

checked by pressure. If necessary a little adrenalin may be used in the wounds. The elevator is introduced in these incisions, and the mucous membrane with the periosteum separated from the bone as far inward as the cleft. The extent of this separation and the length of the lateral incisions must depend upon the facility with which the flaps can be made to close the cleft. Surgical judgment is demanded. Thus two flaps are formed, each being attached anteriorly and posteriorly, which are capable of being displaced inward until their edges come together, and are sutured.

If the tension upon the sutures is too great, union will not take place. If the tissues are separated too much from their blood supply sloughing will occur. The descending palatine vessels should be spared. If they must be divided to complete the closure posteriorly, that should be done at a later operation.

One reason why the tissues are tense in the middle line is because of the resistance offered by the aponeurosis and muscles of the velum palati which

connect it to the hard palate. Attached to the posterior border of the hard palate are the fascia of the velum, the tensor palati and the levator palati muscles. These must be detached before the soft structures can be moved inward. The lateral incisions having been carried back to the posterior margin of the hard palate, a knife or scissors curved on the flat to nearly a right angle, is passed into the lateral wound, and by a transverse cut the velum palati is divided from its bony attachment (Fig. 932). The extent

Fig. 932.—Showing Method of Dividing the Inelastic Aponeurosis Which Holds the Soft Palate to the Hard Palate.

The mucous membrane has been separated from the lower surface of the hard palate and the knife (*K*) cuts the aponeurosis.

of this cut must depend upon the amount of relaxation required. It is best to use the knife, and cut upward only through the aponeurosis, without penetrating the superior layer of mucous membrane. This requires skill. Usually the mucous membrane on the nasal side is cut. Some surgeons use scissors and make a through-and-through cut. This is unnecessary mutilation.

Fig. 933.—Cleft Palate Operation Completed.

Central wound closed with sutures. Lateral wounds packed with gauze.

The cleft is closed by interrupted sutures of silver wire or silk. In twisting the wire a uniform method should be followed, always from left to right. As these sutures are tightened, if it is observed that undue tension is being made, the lateral incisions must be lengthened or the separation of tissue extended, until union without tension is secured. The lateral spaces should be packed with antiseptic gauze (nosophen, formidin, or iodoform) flush with the surface (Fig. 933).

Sliding-flap operations are most effective. They are done with flaps of mucous membrane and periosteum. In doing these operations failure is invited if the main blood supply of the flaps is destroyed, and no one factor will contribute more to the success of the operation than preserving the blood supply. The descending palatine artery is the important vessel. It passes down from the sphenomaxillary fossa, emerges from the posterior palatine foramen, and runs forward in a groove on the hard palate close to the alveolar process. A short lateral incision close to the alveolar process avoids this vessel. The ascending palatine artery is less important (Fig. 934).

In the operation of W. A. Lane the descending palatine artery is divided on one side only. The child is operated on preferably when it is one day old,

Fig. 934.—Incisions for Cleft Palate.

This incision shown by dotted line divides both branches of the descending palatine artery and destroys the main blood supply to the flap. The incision should be external to the artery as shown by the solid black line. The vessels should be lifted away from the bone and preserved in the flap.

or as soon as possible thereafter. After placing the mouth-gag and drawing forward the tongue with a ligature, a mucoperiosteal flap is cut. If the soft parts underlying the edges of the cleft are vascular and thick the flap is made in such a way that its base is at the free margin of the cleft. The incision is made external to the alveolar process, where the mucous membrane is reflected upon the cheek. This flap is turned inward (Fig. 935).

In cutting this reflected flap, the incision (*BC*) passes from the anterior limit of the cleft forward and outward to the cheek; thence it passes along the cheek external to the alveolar margin (*CD*) and then inward along the free posterior border of the palate to the uvula (*DE*).

The palatine blood supply is divided and nourishment must come from the small vessels at the free margin. The descending palatine artery is divided and clamped as the flap is reflected inward, and its mucous membrane turned upward.

To make the raised flap, an incision is then made along the free margin of the other side of the cleft (*BH*). This is carried along the edge of the cleft about half way back where it is continued obliquely outward and backward on the upper surface of the soft palate (*HG*). This is met by a transverse incision (*GF*) along the posterior margin of the soft palate to the uvula. If necessary an oblique anterior incision (*AB*) is also made. This flap (*BHG*) is then lifted up with the elevator. The soft palate is freed from the posterior margin of the hard palate. The palatine vessels are not injured on this side.

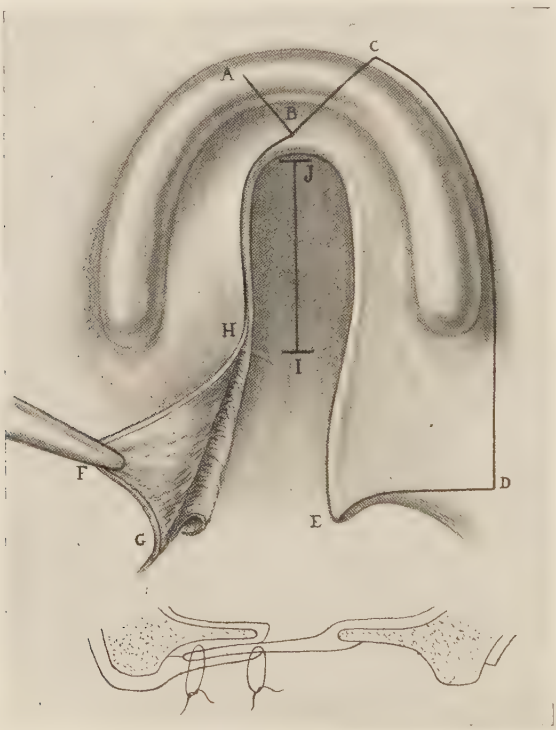

Fig. 935.—Operation for Median Cleft Palate in Infancy.
Lines of incision. Below is shown a cross-section of the bone and flaps, after the flaps have been placed.

The reflected flap which is first turned down, with its scant blood supply is then placed between the raised flap and the bone, and fixed in place by two rows of sutures. The blood supply of the raised flap is ample, as the palatine vessels are not destroyed. The poorly nourished flap is thus attached to a surface which is well supplied with blood (Fig. 936).

If the septum of the nose has a free lower margin, this margin should be incised longitudinally (Fig. 935 *JI*), and the two ends of this incision crossed by short transverse incisions (*I* and *J*). Two small flaps should be turned up, and these sutured to the upper surface of the reflected palatine flap.

In the case of *wide clefts* in the newborn, an incision is made around the

entire alveolar process (Fig. 937). Two incisions (*C* and *D*) are carried from the front of the cleft outward to join this first incision. From the posterior ends of these two incisions an incision is carried along the margin of the cleft on either side as far back as the tip of the uvula (*EE* and *FF*). The two flaps (*ACEE* and *BDFF*) are elevated from the bone, care being taken not

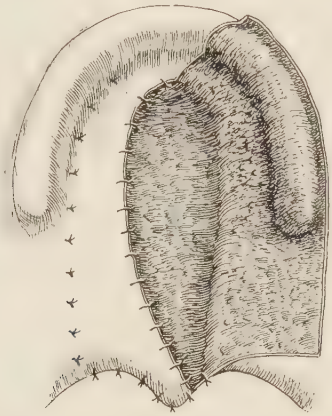

Fig. 936.—Operation for Cleft Palate.
Result after flaps have been sutured. The large raw surface is left to granulate.

to injure the descending palatine vessels. The anterior central flap (*G*) is elevated from before backward, left attached at the front of the cleft where it receives the anterior palatine vessels, and turned back to provide mucous membrane for the floor of the nose (Fig. 938).

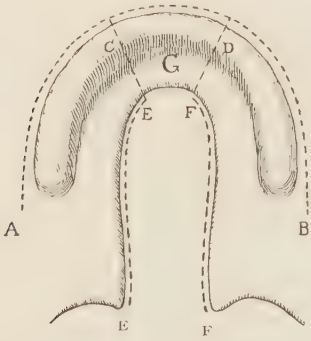

Fig. 937.—Operation for Wide Cleft in the Newborn.
Lines of incision.

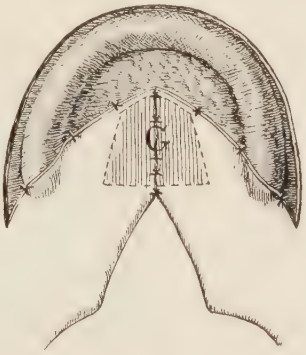

Fig. 938.—Operation for Wide Cleft.
Showing flaps sutured in place.

The two lateral flaps are swung inward and sutured together in the middle line as far back as can be done without tension. The closure of the extreme posterior part should usually be done as a later operation (Fig. 938).

These same principles of operating may be applied to older children or adults. In older cases in which the cleft is wide and the sides ascend obliquely into the nose, similarly, a reflected flap and a raised flap may be used. Two flaps are created of mucous membrane, submucous tissue, and perios-

teum. One, the reflected flap, is made by an incision close to the teeth on the alveolar border. The other, the raised flap, is made by an incision as high in the nose as possible along the edge of the cleft (Fig. 939). In the

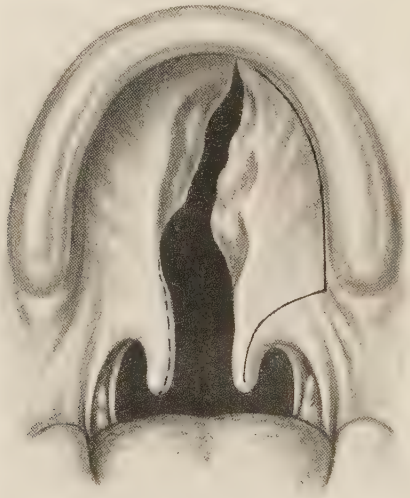

Fig. 939.—Operation for Cleft Palate by Double Flap.

Showing incisions. The heavy black line represents the incision through which the flap is dissected free from the bone. The dotted line represents the posterior part of the incision which passes as high in the nose as possible and through which the opposite flap is dissected free from the bone.

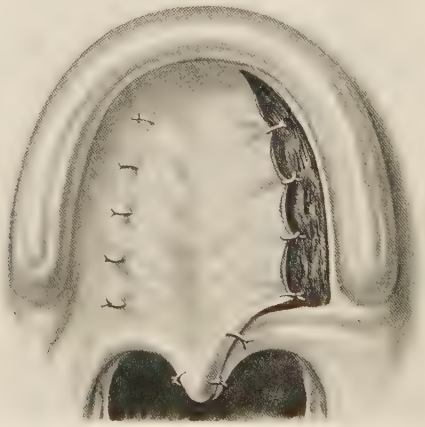

Fig. 940.—Completed Operation for Cleft Palate by Double Flap

The flap from one side has been turned inward and interposed above the flap which has been dissected free from the other side.

first the superior palatine vessels are divided; on the other side, they are spared. The reflected flap is hinged at the edge of the cleft, inverted with its mucous membrane upward, and drawn above the raised flap on the other side. Each is fastened by a row of sutures (Fig. 940).

The *jaw-compressing operation* aims to press together the separated bony structures. In the early operation for cleft-palate, T. W. Brophy forced the two maxillary bones together to close the defect. He contended that there is an actual separation of the bones about equal to the width of the cleft. He, therefore, freshened the edges of the cleft, forcibly brought the two superior maxillæ together, and held them in this position until union was secured. By this operation union of the soft palate with restoration of its function, and union of the harelip are facilitated. The operation may be done without anesthesia. The technic is as follows: A strong needle on a handle, or a straight drill provided with an eye, is entered within the mouth, and thrust horizontally through the upper jaw just behind the malar process and above the level of the horizontal process of the palate bone. The needle carries at its point a strong silk thread, the loop of which is pulled down into the mouth through the cleft. The same operation is repeated on the opposite side. The first thread is passed through the loop of the other side and pulled through both sides, crossing the nasal fossa. A thick silver wire, sharply bent at the end, is hooked into the loop, and pulled. A second wire, parallel to the first, is passed through the anterior part of the jaws. These two wires may be seen through the cleft as they pass across the lower nasal fossa. A small oblong lead plate having a hole near either end is laid against the outer side of the right maxilla, inside of the mouth, above the alveolar process. The posterior wire is passed through the posterior hole and the anterior wire through the anterior hole. These ends of the wire are twisted together from left to right as the plate is tightly pressed inward and the left ends are held taut. The twisted ends are then flattened down against the lead plate. The left ends of the wire are similarly treated under the left cheek. As the wire is being twisted the maxillæ should be pressed together by the strong hands of an assistant. If the bones have become too firm to allow closure of the cleft, they should be divided with a scalpel or chisel applied above the lead plates. The freshened border of the entire cleft is then sutured. Fine silver wire or silk sutures are used for the soft palate and other soft parts. The lead plates and wires should be left for three weeks. The mouth should be kept clean. Only sterile food should be used. Some ulceration will take place under the plates, but it quickly heals after their removal.

This operation was once very popular. Now most in favor with surgeons doing much of this work are the sliding-flap operations.

The after-treatment, following operations for cleft-palate, should be scrupulously carried out. The success of the operation depends much upon it. The child should be placed on its side with the face rotated downward so that saliva may flow easily from the mouth upon a towel.

The child should not be fed until the stomach surely will retain food. Small amounts of sterile water should first be given. No solid food should be taken for five days or a week. Milk, orange juice, meat juice, soft egg, custard, beef jelly, strained gruels, legume soups, and such should be used. Sterile water should be given after each feeding. Sutures will often slough out. Those which remain at the end of a week should be removed.

The head should be held so that fluid will run out of the mouth and the palate sprayed with mild antiseptic solution 3 times daily. If the child resists and fights against this cleansing, it should be omitted unless the wounds look infected.

Infection, too great tension, or too little blood supply may cause *failure of union*. Usually when this occurs, it does not involve all of the wound. As granulations cover the ununited edges, secondary sutures may be applied. A small hole remaining after operation may close itself. Spontaneous healing

may be expected in openings not larger than 2 or 3 mm. in diameter. If they do not heal the application of the actual cautery will produce granulations which should fill the opening and cause its closure. If the opening persists, it may be closed by means of a simple plastic operation. Such operations should be deferred until the palate is plump and succulent, and not done while it is still thin, tense and pale (see Plastic Operations, Vol. III). Unless the operation for cleft-palate is done during the early weeks of life *disturbed phonation* will be persistent.

When an older child has been cured of cleft-palate the training of the voice becomes an important matter. These children should be given systematic training in voice culture. Every sound and word in which they are defective should be practised persistently until it can be pronounced correctly. A great help is in watching the teacher's lips, tongue and expression while making the sound. Patience and persistence bring success. Learning to speak in another language is useful for children which have matured a bad pronounciation of their mother tongue. It is as great a sin to neglect the voice culture of these children as it is to deny them the benefit of operation.

Perforations of the Palate.—Perforations whether congenital, or due to disease, or following an operation for cleft-palate, should be closed according to the general principles of plastic surgery (see Vol. III).

Harelip.—This condition is easily amenable to cure. The operation is one of the oldest and most satisfactory in surgery. When cleft-palate is

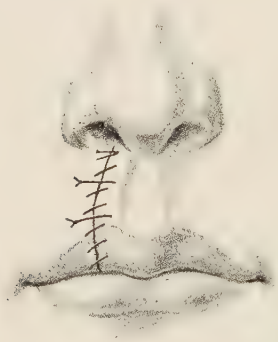

Fig. 941.—Simple Harelip Operation.

Perfect-looking result immediately after operation.

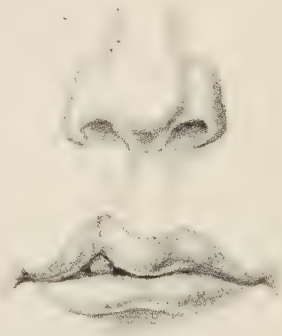

Fig. 942.—Result of Simple Harelip Operation.

The perfect-looking result immediately after operation becomes an imperfect-looking result five years later because of contraction of the scar.

associated with harelip, the former should be cured first as the smaller mouth resulting from the operation for harelip greatly diminishes the accessibility to the palate. If there is no cleft-palate, the harelip should be operated upon during the first days of life, provided the child is healthy. Operation is best done on the day after the child is born. The lowered-head position is best. Every bit of blood possible should be saved, as these little people do not bear hemorrhage well. The coronary arteries should be caught as soon as cut. Tissue should preferably not be removed. The edges should be freshened by incision and dissection in preference to resection.

The first step in the operation consists in freeing the lip from the alveolar margin so that easy apposition can be made. This should be done by an incision through the labio-alveolar fold and a similar incision in the cleft on either side. The incisions for making the edges raw for suturing should

be made with a small, thin, sharp knife. Allowance should be made for the contracture of the scar tissue which will invariably take place. If the operation ends with a symmetrical-looking mouth, the result will not be good, because a dimple will occur later as the result of scar contraction. At the close of the operation, there should be a slight redundancy or fulness of



FIG. 943.—IDEAL HARELIP OPERATION.

Note slight projection at lower end of wound which in the course of time will become even.

FIG. 944.—LATER RESULT OF IDEAL HARELIP OPERATION.

The operation that was so planned that a projection marked the lower end of the scar shows a perfect result five years later.

tissue at the edge of the lip in the line of the cleft (Figs. 941 and 942). The simple operation is undesirable because of the difficulty of this calculation. A plastic flap obviates to a degree the objection of the old operation, although scar contraction should still be considered (Figs. 943 and 944). Another

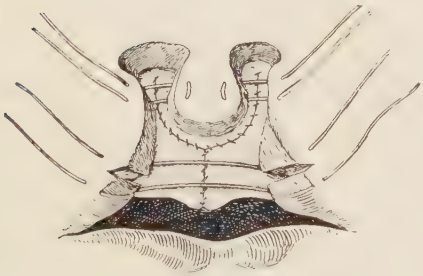

FIG. 945.—OPERATION FOR HARELIP.

The mucous membrane has been sewed; the skin sutures are ready to be tied, and the lateral incisions have been made.

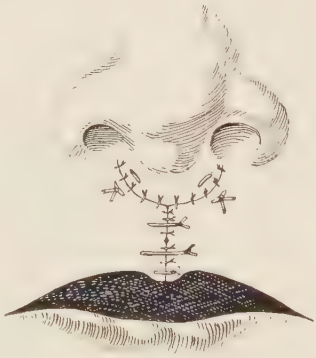

FIG. 946.—OPERATION FOR HARELIP.

Result after closure of wound.

objection to the old operation is that it sacrifices tissue in paring away the margins of the cleft; and the preservation of tissue is a decided advantage.

The operation devised by Christian Fenger is most effective. It is a *split-flap operation*, similar to that done for restoration of the lacerated perineum. After the lip has been freed from the alveolar margin, an incision

is made at the skin-mucosa border of the cleft. The mucous membrane flap is dissected back from either side and united by sutures which are tied posteriorly (Fig. 945). This dissection leaves the surfaces of the cleft lip widely denuded. To produce a slight elongation of the line of suture to



Fig. 947.—Spring for Holding the Cheeks after Operation for Harelip.

Fig. 948.—Simple Operation for Harelip.
Showing lines of incision.

compensate for later contraction of the scar, short transverse incisions should be made on either side. Deep stay sutures are then inserted. Finally the skin sutures are introduced (Fig. 946). Silk, thoroughly impregnated with paraffin, is used. The wound should not be covered with a dressing.

Fig. 949.—Simple Operation for Harelip.
Flaps adjusted and wound sutured.



Fig. 950.—Harelip Operation to Remedy a Simple Notch in the Lip.
Transverse incision made above notch through whole thickness of the lip.

A child should be prevented from opening its mouth widely after the operation. By taking a piece of zinc oxid adhesive plaster, 2.5 cm. (1 inch) wide and about 30 cm. (12 inches) long, placing the middle under the chin, drawing it tightly up across each cheek, and crossing the two ends at

the root of the nose, the jaw and face may be held so that the child can do no harm by opening its mouth. The strip may be rolled into a cord as it passes in front of the eyes (A. H. Ferguson). H. L. Smith (Surg. Gyn. and Obst., Nov., 1916) devised a simple wire spring for holding the cheeks (Fig. 947).

The operation best adapted to the average case of *lateral harelip* is the following: The outer side of the cleft is freshened by peeling away the mucous



Fig. 951.—Notch Deformity Corrected by Converting Transverse Incision into Vertical Wound.



Fig. 952.—Wound Sutured.

The scar contracture a few months after the operation will remove the downward projection at the site of the wound.

membrane. This denudation should extend also outward upon the margin of the lip for a short distance. The inner side of the cleft is then seized at the lip margin with fine mouse-tooth forceps, and a flap cut by transfixing the whole thickness of the lip. This flap should not be a thin paring but should have bulk. Its apex should be swung downward to the outer part of the denuded lip surface. Thus a part of the vermilion border of the

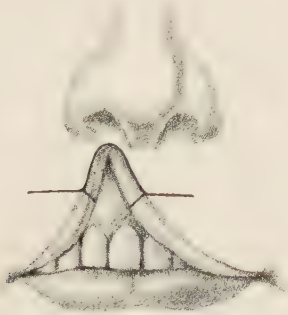

Fig. 953.—Harelip Operation with Transverse Incisions. First Stage.

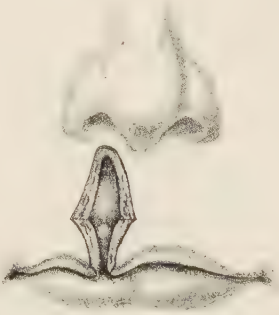

Fig. 954.—Flaps Drawn Down into Position. Second Stage.

cleft comes to form a part of the border of the reconstructed lip. Each case is peculiar and requires judgment in calculating the size and shape of the flap and the area of denudation. The wound should be sutured with horsehair or celluloid-treated thread. A deep suture close to the coronary artery will control it. A row of sutures should be used on both the facial and dental sides of the lip. Every other suture should be passed deeply, the skin sutures just to the mucous membrane, and the mucous membrane sutures just to the

skin. Every other suture should be for superficial approximation. The deep sutures hold the muscle and prevent bleeding (Figs. 948 and 949).

Care should be taken that no epethelium is left upon the surface to be covered. The tissue removed should come just to the skin. The preservation of the lines representing skin-mucous-membrane juncture should be exact. The vertical wound will ultimately contract, and to secure a final perfect result, there should be a slight fulness of the lip directly below it. Harelip pins have no advantage over sutures, and many disadvantages.

Fig. 955.—Wound Sutured Vertically. Third Stage.

Fig. 956.—Harelip Operation with Long Oblique Incisions. First Stage.

Many other operations suggest themselves, according to the principles of plastic surgery, to meet special conditions. A simple harelip of slight degree, constituting a notch in the lip, is remedied by making a transverse incision passing through the whole thickness of the lip (Fig. 950), drawing its two ends together (Fig. 951) and sewing it as a vertical wound (Fig. 952). In more aggravated cases transverse incisions to form a flap are useful (Fig. 953). Such flaps are drawn downward (Fig. 954) and the wound sutured

Fig. 957.—Wound Ready for Suture. Second Stage.

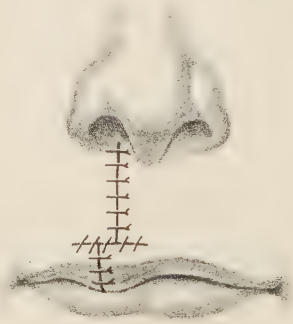

Fig. 958.—Wound Closed. Third Stage.

vertically (Fig. 955). More pronounced cases require oblique incisions (Fig. 956) to secure longer flaps (Fig. 957). These may be sewed and adapted in both vertical and horizontal lines (Fig. 958).

Still more aggravated cases require larger flaps such as may be secured by incisions passing upon the cheeks (Fig. 959). These flaps are swung down and adjusted to give a slight projection at the lip margin (Fig. 960). They may be sewed with interrupted and continuous sutures (Fig. 961).

In *double harelip*, the prolabium should be utilized. An operation combining on either side the principles used in the single operation is applicable. The median bud may be so hypertrophied that a wedge of its tissue

Fig. 959.—Harelip Operation with Cheek Flaps. First Stage.

Fig. 960.—Harelip Operation with Cheek Flaps. Flaps Drawn Down.

Fig. 961.—Harelip Operation with Cheek Flaps. Wounds Sutured.

Fig. 962.—Operation for Double Harelip.
First stage. Lines of incision.

Fig. 963.—Operation for Double Harelip.
Second stage. Flaps turned down.

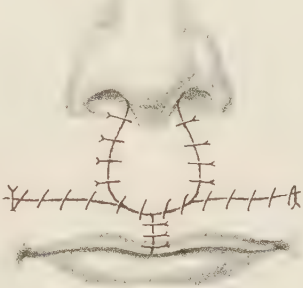

Fig. 964.—Operation for Double Harelip.
Third stage. Wounds sutured.

should be removed. When necessary it may be lengthened by making a transverse puncture through it, and closing it by a transverse suture. Each case offers a different problem.

FIG. 965.—OPERATION FOR DOUBLE HARELIP WITH TRANSVERSE INCISIONS. FIRST STAGE.



FIG. 966.—OPERATION FOR DOUBLE HARELIP WITH TRANSVERSE INCISIONS. FLAPS TURNED DOWN. SECOND STAGE.

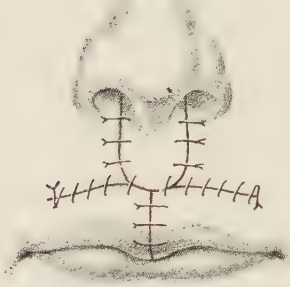

FIG. 967.—OPERATION FOR DOUBLE HARELIP WITH TRANSVERSE INCISIONS. WOUNDS SUTURED. THIRD STAGE.

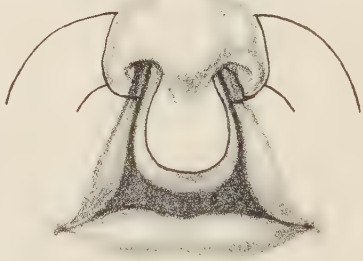

FIG. 968.—OPERATION FOR DOUBLE HARELIP WITH CHEEK FLAPS. LINES OF INCISION. FIRST STAGE.

FIG. 969.—OPERATION FOR DOUBLE HARELIP WITH CHEEK FLAPS. FLAPS SUTURED. SECOND STAGE.

The raw surfaces may be covered with grafts or by sliding flaps from the cheek.

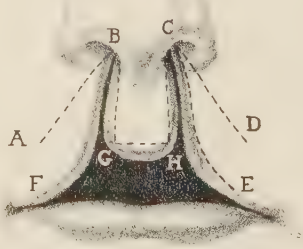

FIG. 970.—DOUBLE-FLAP OPERATION FOR DOUBLE HARELIP. LINES OF INCISION.

The flaps *ABF* and *ECD* are turned down; the point *C* is sutured at *A*; the point *B* is sutured at *E*.

The operation is similar to two operations for single harelip (Fig. 962). Usually lateral flaps must be turned down below the central bud (Fig. 963). The suturing should adapt the flaps to their new position (Fig. 964). In some aggravated cases two lateral incisions are well adapted to secure the flaps (Fig. 965). After bringing down the flaps (Fig. 966), it may then be determined just how the sutures must be applied (Fig. 967). By providing for flaps from the cheeks (Fig. 968), the most aggravated cases may be remedied (Fig. 969). The defect left in the cheek may be closed by further plastic or it may be covered by a skin-graft. Incisions providing for overlapping flaps are applicable to most of these cases (Fig. 970). In such cases the possibilities of scar contraction must always be considered in closing the wounds (Figs. 971 and 972).

The *notched-lip*, following operation for harelip or of congenital origin, is easily cured by making a transverse incision through the lip above the notch and closing it by transverse sutures as a vertical wound (Figs. 973 and 974).

Fig. 971.—Double-flap Operation for Double Harelip.
Wound closed.

Fig. 972.—Exceptional Double-flap Operation for Double Harelip.
If the prolabium is large, the wound may be closed thus.

The *deformed nostril*, associated with harelip or following operation for harelip, may be treated at the time of operation or later. In some cases the nostril is wide and flat. It may require that the nose shall be made higher by a septum operation (page 190). Usually it is also well to detach the outer implantation of the alar cartilage and move it inward. In some cases it is well to cut out a part of the cartilage to reduce the size of the nostril (see Plastic Operations, Vol. III).

The *after-treatment* of harelip cases should be carried out with scrupulous care. After suturing the wound, the skin should be dried and a strip of adhesive plaster placed under the chin to hold the mouth closed (page 268). Dressing on the wound is rarely necessary. The child's hands should be watched or restrained so that it shall not touch its mouth. Its food should be sterile fluids administered from sterile containers. Only sterile water should be given the first day. Several times daily a little boracic solution should be sprayed between the lips. On the third day all but one of the deep sutures through the skin may be removed to prevent scars. On the fourth day the remaining deep skin suture may be removed. The sutures to be taken out are first the deep ones and those which seem to be cutting or which threaten ulceration. The deep posterior mucosa sutures and the superficial skin sutures may be left for seven to ten days.

Secondary operations may be required to improve the symmetry of the lip or nose. If the upper lip is thin and tight, it may be relaxed by sliding in tissue from the check. If the lower lip is out of proportion and larger than the upper lip, a V-shaped piece may be removed from it. After operation, *dyspnea* may require attention. This is because of the narrowing of the respiratory orifices. The lower lip should be depressed at each inspiration until the child becomes accustomed to the new conditions. The nose should be kept cleaned of blood and discharges. Some surgeons pass a suture through the back of the lower lip and fasten it under the chin with adhesive plaster, thus holding the lip down to prevent dyspnea.

If *failure of union* is present as a result of infection or defective nourishment, infected sutures should be removed and the wound frequently dressed. After the surfaces have become covered with clean granulations, secondary sutures should be put in after trimming the edges. Victory may thus be snatched from defeat.

Fig. 973.—Operation for Notched Lip.

A transverse incision is closed vertically. Overcorrection is made because the later scar-contraction will restore the normal contour.

Fig. 974.—Result after Vertical Closure of a Horizontal Incision.

The result with downward projection of dimple is here somewhat exaggerated.

The Teeth and Gums

The **cleansing of the mouth** and teeth has already been discussed in connection with oral asepsis (page 244), and as a preliminary essential to success in all operations upon the mouth, respiratory passages and esophagus. The good condition of the teeth is necessary for two reasons: (1) an essential part of digestion is good mastication; and (2) the presence of carious teeth constitutes a constant menace to health by furnishing infection to the alimentary canal, to the lymphatics and blood, and to the adjacent tissues. Teeth capable of physiologic mastication and uninfected teeth are an essential prerequisite for good health.

To **prevent the decay of teeth,** the child must first be born with a good organism to start with. Good general health helps to preserve the teeth. Exercise of the teeth is essential for their health. It is important that, especially in childhood and adolescence, food requiring mastication shall be fed and masticated. Children should be taught to masticate thoroughly. But they cannot be taught this if they are fed on gruels and mush. Healthy children as soon as they have teeth enough should have foods which give some resistance to the jaws. Dates, nuts, dry bread, fruits, a meat bone—these are some of the things which should constitute a part of the daily ration.

Children should early begin to work for their living with their teeth. The profession of dentistry is an outgrowth of the tendency to pamper the mouths of infants with soft and fermentable foods which the dear little things may take easily.

Caries of the teeth begins in openings in the enamel in which bacteria penetrate and establish foci of disintegration. Such openings are usually the result of the breaking down of the enamel by the products of fermentation in the mouth; but they may be congenital. They may be caused by traumatism, by strongly acid foods, or cracks may be caused by taking into the mouth extremely hot or extremely cold materials. Once having begun, the infection slowly spreads, breaking down and destroying the tooth substance as it advances. As soon as the advancing process of infection approaches the pulp chamber and the interior nerve-supplied parts of the tooth, the irritating products of infection cause pain, just as in inflammation elsewhere. Asepsis of the mouth reduces the bacteria and prevents the chemical erosion of the enamel. The deposit, precipitated upon the teeth from the oral secretion which increases in a ratio with ill health, is a culture bed of microorganisms. The acid products of fermentation in this substance have the power of dissolving the enamel of the teeth. It is, therefore, important that it should be kept removed. Good hygiene diminishes it; but few people are free from it. Particles of food, lodged at the bases of the teeth also act as culture beds for microörganisms whose acid products erode enamel.

The removal of these destructive substances from the mouth is best accomplished by mechanical means. The tooth brush should be used at least twice daily, and as much of the surfaces of the teeth as are accessible should be brushed. Particles of food should not be allowed to remain lodged between the teeth. They may be removed by means of a silk thread engaged between the teeth. Once daily or every other day, some cleansing substance should be used with the tooth brush. For this purpose *tooth powder* is to be recommended.

The following formulæ are used for tooth powder:

Calcium carbonate (pure, fine, precipitated) 100, powdered castile soap 25, sodium bicarbonate 25, orris root 100, myrrh 100, oil of wintergreen 10.

Calcium carbonate (pure, fine, precipitated) 95, castile soap 4, saccharin ⅛, oil of peppermint ½, oil of birch ⅜.

Calcium carbonate (pure, fine, precipitated) 35, magnesium carbonate 12, orris root 18, oil of peppermint ⅗.

The destructive power of the buccal precipitate may be reduced by neutralizing its acids by rinsing the mouth once daily with milk of magnesia.

When once caries has begun, it will continue until the tooth is destroyed, unless the disease is stopped. This demands that all of the carious part of the tooth shall be removed down to healthy structure, that the cavity shall be rendered sterile and free from culture material, and that the further access of bacteria shall be prevented by filling the cavity with some resisting material which can be made to penetrate every crevice. Scientific dentistry has solved these problems. The most effective filling is the inlay held by cement. Teeth which do not lend themselves to being filled are protected by covering with a cap of gold. Teeth which can neither be filled or capped are made capable of mastication by fixing a new crown to the root by means of pins and other mechanical devices. Irreparably decayed teeth should be extracted.

Besides the diseases entering through the enamel of the crown, infections often begin at the root of the tooth. Such **root infections** may, perhaps, be conveyed by the blood or lymph-channels but they most probably enter by

way of the canal or at the side of the root. The infection in such cases destroys the nerve and circulatory channels entering the root, and the tooth becomes dead. If suppuration is present at the root, drainage should be provided either by opening the root through the crown, by making an incision through the gum, or by extracting the tooth. If none of these things is done, spontaneous opening may take place through the gum, pus may escape at the side of the tooth, infection of the alveolar process may occur, the antrum of the upper jaw may become infected, or the natural resistance of the tissues may overcome the infection. Such infection is prone to cause recurring attacks of inflammation and suppuration, although the intervals between such attacks may be long. There is always danger that the infection will penetrate to the alveolar process of the jaw, and cause periostitis or necrosis.

One of the modern dental sins is the filling or crowning of "dead" teeth without cleaning out the root canal, removing all animal matter from it, and filling it with rubber or some other non-decomposable substance. The complete cleaning out of root canals, down to and through the apical foramina, and the complete filling of the canals, is one of the triumphs of modern dentistry. If a tooth with a dead root is filled or capped, and the animal material in the root canal (nerve, lymph and blood-channels) is left, this unnourished material is apt to become infected; drainage is prevented by the filling or cap which seals the outlet of the canal; and the patient is a candidate for general systemic infection from the confined products at the apex of the tooth. Patients would be much better off to leave their dead teeth uncrowned and unfilled rather than to have the uncleaned canal sealed up. It is from such bad therapy as this that streptococcic infections of the teeth develop and produce the secondary manifestations—"rheumatism," arthritis, neuritis, infective valvular disease of the heart, arteriosclerosis, necrosis of the jaw, etc. It is possible that by preventing streptococcic infection of the teeth a causative factor in gastric and duodenal ulcer may be eliminated.

The common streptococcus infection which occurs at the apices of unfilled roots should be treated by removing all animal matter from the root canals. In this work the *x*-ray is indispensable. This simple drainage usually suffices to effect a cure of the infection. Electrolysis and antiseptic medication forced through the canal also are used. After all inflammatory reaction has subsided, the thoroughly dried canal is then filled with rubber and rubber in chloroform solution, which should be pressed in until it just passes through the apical foramina and enters whatever extradental cavity may be present.

If a cavity of considerable size has developed at the apex because of rarefaction and absorption of bone and tooth, it is usually best to trephine through the alveolar process, pack the cavity with gauze and secure its healing by granulation. Often the apex of the tooth, projecting into such a cavity, may be cut off. The tooth can often be saved. Its sacrifice should not be considered necessary in most cases.

Teeth should be examined every three months, or every six months at the most, by a dentist, in order that beginning disease may be discovered and its advancement checked. Prophylaxis in the care of the teeth repays well for every inconvenience which it may entail. Dentistry, besides preventing and curing infections, with all the constitutional harm arising from them, is able by the application of prosthetic surgery to preserve the function of mastication. In the treatment of many diseases of the alimentary tract and many constitutional ailments, it will be found that defective mastication is the chief causative factor, and that when the teeth have been made efficient the disease has been cured. For proper mastication there should be at least two efficient molar teeth in each jaw on each side. In the absence of such

teeth, they may be supplied by some of the above-mentioned methods, by bridges, or by the use of false teeth supported on plates. Plates bearing false teeth are best made of gold, or some other substance which is a good conductor of heat, in order that the warmth of the covered mucous membrane may be radiated. Hard rubber does not serve well for this purpose.

Alveolar abscess, resulting from root infection, should be freely evacuated. If an effort is to be made to save the tooth, the mucous membrane should be incised at the place of swelling. The mouth should be washed out frequently. As the opening becomes a sinus, the dentist can determine what may be done to preserve the tooth or whether it is best to preserve it. Sometimes these abscesses in the lower jaw become large and are surrounded by much cellulitis, the pus appearing under the skin below the jaw. In such cases, incision should be made in the submaxillary region where the pus indicates, and the tooth whose root is involved in the disease removed. Denudation of bone will usually be found, but unless necrosis is clearly evident the removal of the bone need not be undertaken as the power of recovery in this region is very great. Later, if necrosis demands operation, the diseased bone may be removed (see Caries and Necrosis, Vol. I, page 692; and Osteomyelitis of the Jaw, Vol. II, page 283). If a sinus persists after operating on alveolar abscess, its opening in the mouth should be closed by denuding the surfaces and suturing it. As soon as it is reduced to a simple external sinus it will heal unless there is dead bone.

Pyorrhea alveolaris (Riggs' disease) caused by the *Endameba buccalis* and, perhaps, other species which destroy the peridental membrane, characterized by alveolar suppuration and loss of teeth, should be treated by the general surgical principles laid down for suppuration. The mouth should be cleansed; the teeth should be cleared of tartar; hopelessly decayed teeth should be removed and remediable teeth should be treated; suppurating foci should be sought and drained by incision or by the removal of teeth; carious bone should be removed; and suppurating sinuses should be opened. Washing and cleansing of diseased foci should be practised. Sound teeth should be preserved. This treatment is recommended because the pyorrhea is due largely to secondary bacterial infections.

The specific treatment, aimed to destroy the ameba, consists in the hypodermic injection of 0.03 Gm. (½ grain) of emetin hydrochlorid on from three to six successive days. The same result is secured by the internal administration of two or three tablets of *Alcresta ipecac*, each containing 0.6 Gm. (10 grains); these should be taken by mouth 3 times daily for from four to six successive days. This treatment must be repeated in bad cases. Rinsing the mouth with fluidextract of ipecac is of value in early cases.

If the secondary infection persists the organisms which are causing the trouble should be identified, and a vaccine made (see Vaccines and Bacterins, Vol. I, page 255).

Gingivitis.—Inflammation of the gums, whether a part of a general stomatitis, whether due to pyorrhea alveolaris, or whether a local manifestation of rickets, scurvy, lead poisoning, mercurial poisoning, or phosphorus poisoning, should be treated by first treating the causative factor. The teeth should be cleaned, carious foci should be removed, cavities should be filled, and an antiseptic mouth wash should be used. If the gums are soft and spongy, permanganate of potash solution is an effective mouth wash.

Exuberant swelling calls for removal of hypertrophied tissue or its incision to permit the escape of blood. Massage of the gums with a stiff brush is helpful.

The following mixture, painted on the gums every day, is useful: 3 Gm. zinc iodid, 3 Gm. iodin, 10 c.c. glycerin, 10 c.c. water.

Extraction of Teeth.—The removal of teeth is called for in cases of irreparably decayed teeth, teeth in malposition, to gain access to diseased alveoli, for feeding in cases of tightly closed jaws, and as a preliminary to certain operations such as excision of the jaw and draining the antrum. The instruments used are forceps and elevators. Forceps are made in many shapes to fit teeth of various forms and positions, but the handy surgeon does not require a great variety.

Extraction may be done without any *anesthetic*, with local anesthesia, or with general anesthesia, according to the rules already given (Vol. I, page 92). If the tooth is loose or if there are contraindications, no anesthetic need be used. For local anesthesia, the mucous membrane may be numbed on either side by touching a spot with phenol solution. Through this area the hollow needle may be introduced, and all of the soft tissues about the fang and neck of the tooth infiltrated with analgesic solution.

Fig. 975.—Extraction of Teeth.
The wrong way.

Fig. 976.—Extraction of Teeth.
The right way.

This permits extraction without pain. Fairly good analgesia may be secured by spraying the gum with ethyl chlorid after covering the surrounding parts with cotton for protection. The inferior dental nerve may be anesthetized as it enters the canal in the lower jaw. For anesthetizing the nerve supply of the jaws, see Local Anesthesia and Neuralgia of the Trigeminal Nerve, Vol. I. For general anesthesia nitrous oxid is to be preferred.

Before using, the forceps should be sterilized. The *technic* requires that the tooth shall be grasped, not by the crown (Fig. 975) but well down upon the neck (Figs. 735 and 736). In order to do this properly the gum must be pressed away from the tooth by the jaws of the forceps or as a preliminary step by means of an elevator. This should not be done in a half-hearted way, but the forceps should grasp the tooth well down on the root (Fig. 976). This separation of the soft tissues from the tooth gives rise to some bleeding. The tooth should be firmly grasped by the forceps, loosened by a lateral rocking motion, and pulled out. This lateral leverage motion is the important movement in extraction. It should be carried far enough to free the tooth from its attachments, but not so far as to break the fang or alveolar process. The wrong way is to attempt the loosening of a tooth by

traction in the direction of its long axis. The tooth having been loosened by lateral leverage is then easily removed by traction in the direction of its long axis combined with rotation. The tooth to be removed should have been identified beyond question before the operation.

Extraction by means of the *elevator* is practised in the absence of forceps, and in cases in which the mouth cannot be opened. The elevator is used as a lever, passed down into the socket, and made to pry out the tooth.

The *bleeding after extraction* usually stops after a few minutes. The mouth should be rinsed with clean water. If the bleeding does not stop promptly, a gauze packing in the socket may be expected to be sufficient. Some adrenalin chloride may be added to this. Styptics which are irritating or corrosive should not be used because of the danger of sloughing. If an antiseptic styptic is required, one of the mild powders, such as zinc oxid, diluted subgallate of bismuth, aristol, or formidin may be employed. The pressure of a clean gauze packing should be the main reliance in all cases of hemorrhage. Bad cases may require that the pressure shall be maintained by holding the jaws firmly together by means of a chin-and-head bandage; or a clamp, screwing the gauze into the socket, may be required; or continuous digital pressure, in the absence of mechanical apparatus, may be necessary. Ligation of the external carotid is the last expedient (see Hemorrhage, Vol. I, page 409). Death from hemorrhage following tooth extraction is not uncommon. It does not occur in the presence of competent surgery and modern surgical facilities.

Tooth Grafting.—After the removal of a sound tooth by accident or as a temporary expedient, it is possible to press it back into its socket and have it become reattached. It is essential that the fang and neck of the tooth shall be free from decay and that the alveolus shall not be infected. In the presence of infective disease grafting is impossible. If the tooth is to be replaced immediately, as may be the case in the accidental or purposeful removal of a sound tooth, the fang and neck should not come into contact with any thing which is infective, the socket should be washed out with warm sterile salt solution until it is free from blood, the tooth should be pressed back into its normal position, and held there immobilized until it becomes united to the soft tissues.

In the case of a tooth which has become soiled, or in which some time has elapsed since its removal, or in which the socket has required treatment, replacement should be deferred until the best possible asepsis can be insured. A tooth, for example, has been knocked out and fallen upon the ground; it is brought to the surgeon for replacement after some hours or days; here the problem is more difficult. The tooth should be cleaned and immersed in warm antiseptic solution which should be kept at body temperature. Borosalicylic solution is suggested. The socket should be syringed out several times daily with warm saline solution until the traumatic reaction has subsided. The other teeth and the rest of the mouth should be brought into the best state of cleanliness possible. If the removed tooth presents any caries which should demand filling, it should be filled, being handled with the utmost aseptic care. The aseptic tooth is then pressed firmly back into the cleansed socket, and held by fixation apparatus, which exerts some constant pressure upon its crown.

The immobilization of teeth after grafting is an important step in the operation. This is best accomplished by making an impression of the teeth of the affected jaw, and preparing a gold plate from this, which shall fit over the adjacent teeth, protecting and immobilizing the grafted tooth. This immobilization should be maintained for three months.

The mouth should be kept clean. Particularly is it important that no particles of food shall become lodged about the grafted tooth. Careful syringing of the mouth must be relied upon to prevent this. To insure immobilization, mastication should not be practised for the first month; and for the next two months, no masticatory pressure should be made on the grafted tooth. Success is secured by vigilance; a fatalistic policy means failure.

Not only may the natural tooth be thus replaced, but it is possible to graft teeth from another jaw. The same principles as already set down apply to the heteroplastic operation.

Tumors of the Gums and Teeth.—*Odontoma* is an abnormal growth of dental tissue which should be removed to prevent interference with normal teeth and because of its irritation. Odontoma of the fang requires removal if it give rise to trouble. *Cysts* arising in connection with the teeth are treated by removal of their walls. Odontomata may give rise to cysts which require eradication of the cyst wall. Excision of the jaw is not called for in these cases. *Angioma* of the gum is to be treated the same as angioma elsewhere. *Myeloid sarcoma* is the least malignant of the sarcomata; it should be eradicated by extraction of the adjacent teeth, excision of the growth, and, if it lay close to the bone, the adjacent bone should be removed with the rongeur. All other forms of *sarcoma* should be treated by wide, systematic excision of soft tissue and bone. *Epithelioma* of the gum should be treated by wide excision.

One of the most common tumors of the gum is called *epulis*. This may mean any one of several forms of growth, but the treatment applied should be that for *fibrosarcoma*. The adjacent teeth should be extracted so that a margin of about 5 mm. of sound tissue may be removed with the growth. The adjacent bone should be removed. For this purpose the rongeur forceps may be employed or a quadrilateral section of alveolar process may be cut out with the saw and chisel (Vol. I, page 717). Artificial teeth may later be adjusted to the defect (see Tumors of the Jaws, Vol. II, page 286).

The Jaws

Deformities of the jaws, resulting from thumb sucking in infancy, from adenoids, and from scar contractures, are all to be treated by prophylaxis. *Thumb sucking* may be prevented by simply lengthening the child's sleeves by the addition of some stout, washable material, and closing the ends of the sleeves beyond the finger tips with a shirr string. Such an addendum should be worn at that part of the day when finger sucking is practised. Unless this bad habit is cured, the alveolar process will be pressed forward in the upper jaw and backward in the lower jaw, and overlapping teeth result. An apparatus to correct the deformity may be called for. The plastic, growing jaw is easily moulded to a desired shape by any pressure long continued. The dentists, by what is called *orthodentistry*, apply apparatus to correct the shape of the jaw as the child grows.

Underdeveloped lower jaw, following ankylosis of the temporomaxillary joint or disease which fixes the jaw, may be greatly improved by osteoplastic operation and liberating the joint. The deformed and small jaw (Fig. 977) may be improved by moving forward the chin by means of transverse section of the rami and forward displacement of the lower segment (Fig. 978). The operation on the bone should be a plastic with the insertion of a graft of bone on either side. If this does not give enough forward projection of the chin, a piece of costal fibrocartilage may be transplanted

(Fig. 979). At a later operation, if necessary, a joint plastic operation may be done (see Operations on Bones and Joints, Ankylosis, Vol. I).

FIG. 977.—MALOCCLUSION OF LOWER JAW.

Operation for lengthening body of jaw. The bone is exposed by an incision below the jaw. The soft tissues are dissected up, and the bone is divided on either side by a Z-shaped incision.

In other cases, a plastic operation may be done for changing the contour of the body of the jaw. Tilting forward of the jaw may be secured by dividing the rami and inserting a wedge of bone (Fig. 980).

FIG. 978.—RESULT AFTER OPERATION FOR MALOCCLUSION OF LOWER JAW.

The median segment of the body of the jaw has been moved forward, and separation maintained by inserting bone-grafts taken from the tibia.

Defective occlusion is treated by wedge-shaped resection and horizontal division of the mandible (Fig. 981). The wedges of bone are removed and inserted as grafts in the horizontal gap (Fig. 982). *Prognathism* is cured

by resection of a wedge of bone on either side of the body of the lower jaw (Fig. 983).

Fig. 979.—Perfected Result After Operation for Malocclusion of Lower Jaw. A Transplant of Costal Fibrocartilage has been Added Later to Improve the Symmetry of the Chin.

This transplant is simply slid under the soft tissues of the chin through the smallest possible wound.

In treating malocclusion in the adult the lines of division of the bone must be adapted to the peculiar conditions of each case (Fig. 984). The result differs with vertical division through the ramus (Fig. 985), division at the

Fig. 980.—Changing Contour of Jaw.

Wedge of bone-graft inserted in divided ramus for the purpose of tilting the body forward.

base of the neck, of the condyle (Fig. 986), or vertical division between the ramus and the body of the jaw (Fig. 987).

Deformities of the lower jaw with defective occlusion in adults are treated by osteoplastic operations. Forward displacement of the lower alveolar process is remedied by removing a V-shaped segment and making a transverse cut below (Fig. 981). The segment is tilted upward and held by a transplanted wedge (Fig. 982).

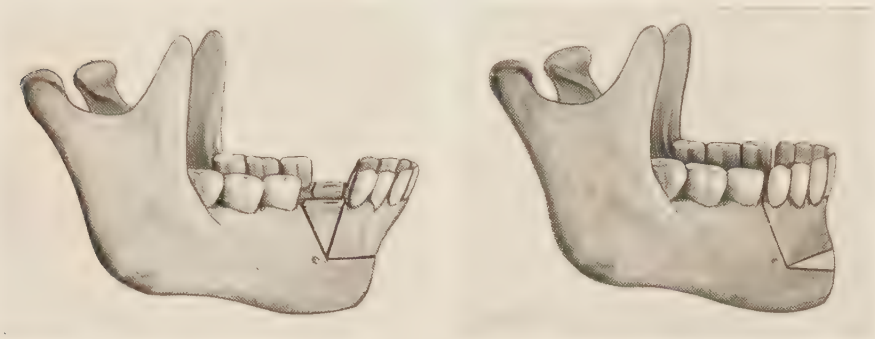

Fig. 981. Fig. 982.

Fig. 981.—Defective Occlusion Treated by Wedge-shaped Resection and Horizontal Division of Mandible.

Fig. 982.—Result After Operation for Defective Occlusion.

The wedges of bone have been removed and inserted in the horizontal gap.

The treatment of *prognathism with malocclusion* is by the same principle. Osteotomy may be done alone or combined with the grafting of a piece of bone from the tibia or rib (see Operations on Bones; Bone Grafting, Vol. I, page 772).

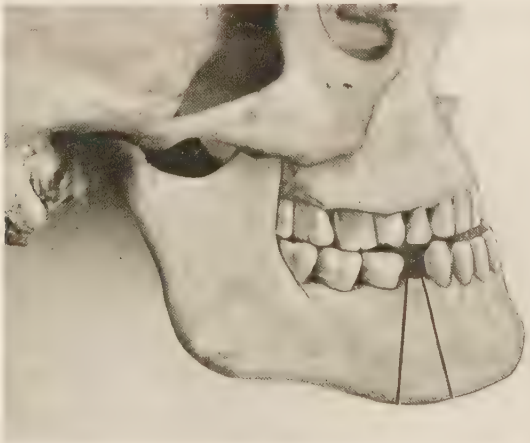

Fig. 983.—Prognathism Treated by Resection of a Wedge of Bone on Either Side.

Periostitis and osteomyelitis of the jaw have been discussed under Alveolar Abscess (page 277). Osteomyelitis demands immediate and active treatment (Vol. I, page 692). As soon as possible, the bone should be drilled or trephined. This can be done through a small incision in the skin below the lower border of the jaw. Even though the operation has been

done before pus has collected, it will abort the disease. An early opening of the inferior dental canal is the one important step in acute osteomyelitis.

If the disease has progressed to necrosis and exfoliation of bone every effort should be made to save the teeth. Even though the alveolar process

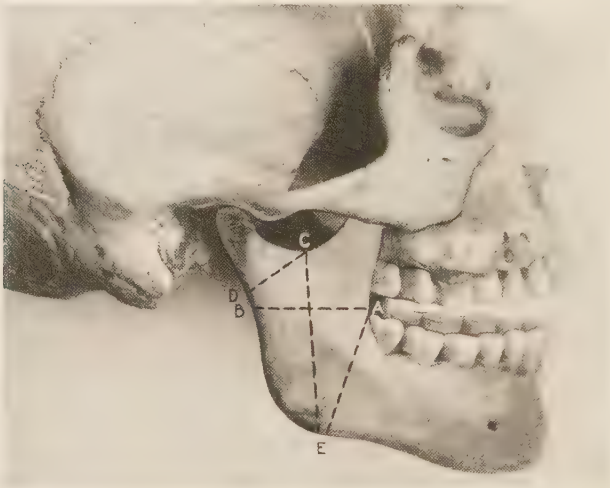

Fig. 984.—Operations for Malocclusion.
Showing lines of division which may be used to tilt body of jaw upward.

with the tooth sockets is gone, if the teeth are attached only by alveolar mucous membrane they may be saved. Granulations grow about the roots and they again become attached.

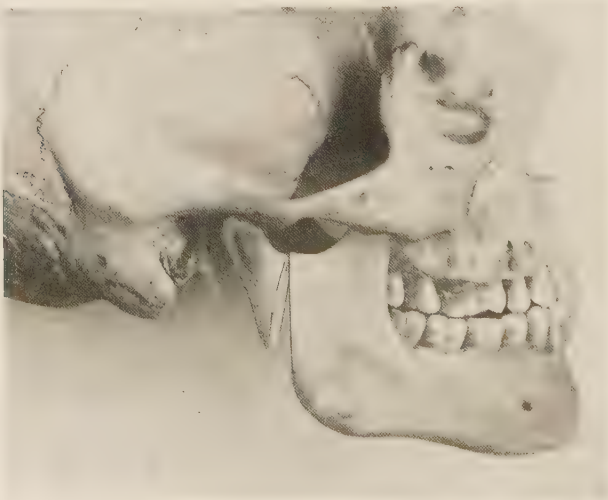

Fig. 985.—Showing Occlusion Secured by Vertical Division of Ramus.

Hopelessly decayed teeth should be removed. Because of difficulty in opening the mouth it is often impossible to identify the diseased tooth. If

forceps cannot be introduced the tooth should be removed with the elevator. It is poor surgery in acute cases to "wait until things have quieted down." If pus is present free drainage should be secured either through the skin below

Fig. 986.—Showing Occlusion Secured by Division of the Neck from the Ramus of the Lower Jaw.

the jaw or through the mucous membrane of the mouth. Osteomyelitis calls for trephining of the jaw or cutting away enough bone to freely drain the cancellous interior. The diseased tooth can usually be identified through

Fig. 987.—Showing Occlusion Secured by Vertical Division of Ramus from Body of Lower Jaw.

the external wound by following up the abscess cavity to its alveolus. The injection of hydrogen peroxid may help as a guide.

Necrosis of the jaw whether from local infection or constitutional poisoning requires removal of the sequestrum. This should be carried out according to the principles already laid down (Vol. I, page 688). Acute septic conditions should be relieved, but it is generally best not to remove a sequestrum until its detachment is complete. In some cases the operation for removal of the sequestrum may be done through the mouth and an external scar avoided. The best drainage is always secured by an external opening. In some cases a resection of much of the jaw may be necessary (Resection of Jaw, Vol. I, page 717).

Tumors of the jaws, benign or malignant, should as a rule be removed. Benign tumors should be removed if they are steadily growing, if they interfere or are about to interfere with function, if they cause pain, or if they are unsightly. Malignant tumors should be removed, if removable. If the benign central *fibromata* of the upper jaw or *odontomata* are removed while small, the operation is easy; but to defer operation until the tumor has become enormous is to invite a serious condition only to be remedied by a serious operation. *Cysts* are cured by laying them freely open, and removing the lining membrane with the curet. This is sufficient in the cysts of odontomatous origin. Cystic degeneration of sarcoma demands wide excision. In odontomata the rudimentary tooth which is the focus of the disease should be sought and removed. *Osteomata* and *enchondromata* may be removed with the gouge.

Of the malignant tumors of the jaws, *sarcoma* is the most to be feared. It starts from the marrow or from the periosteum. The former, *myeloid sarcoma,* is more encapsulated and produces metastases but slowly: it is, therefore, more easily cured. Curetting out the growth from the interior of the bone, and then with a sharp gouge removing a thin layer of the surrounding bone suffices to cure the disease. Strong curettage alone down to healthy bone, and the destruction of the peripheral cells with pure phenol usually cure the disease. Wide resections in this form of sarcoma is not necessary. Every effort should be made to preserve the lower jaw in one piece. *Peripheral sarcoma,* usually of the spindle-cell or small round-cell type, starting from the periosteum, is an extremely malignant disease, and demands early and wide excision.

Carcinoma of the jaw is usually by extension from the adjacent mucous membrane, but inasmuch as epithelium is found lining many cavities and alveoli and lying close to the bone, the disease may from the beginning closely involve the osseous structures. Early and wide eradication of the growth is imperative, together with removal of the draining lymphatics (see Lymphatics of the Neck, page 363). In advanced cases of carcinoma, operation has something to offer. The lymphatics of the neck should be removed. Then after a week or two, the extirpation of the primary disease should be attempted. If a wide operation involving the mouth is to be done, preliminary tracheotomy is advisable. Temporary ligation of the external carotid may be relied upon to save blood. Hemorrhage, shock, and pneumonia are the dangers inherent in operation (see Resection of Jaws, Vol. I, page 717; Tumors, Vol. I, page 323). The starvation treatment of ineradicable tumors, by ligation, injection, and removal of the blood-vessels, is sometimes applicable in this region (Vol. I, page 333).

The Tongue

Congenital Defects.—*Bifid tongue,* if pronounced, is cured by removing the mucous membrane from the inner surfaces of the cleft and suturing the wound with interrupted non-absorbable sutures. The sutures may be

removed on the fifth day, except the anterior suture which should be left a day or two longer. Soft food only should be taken during the first three days.

Tongue-tie, in which the tongue is held to the floor of the mouth by a short frenum, usually remedies itself as the child grows. The division of many normal frena is demanded by many anxious mothers; and many unnecessary operations are performed upon this organ. If the tongue can not be lifted by the fingers away from the floor of the mouth on account of a short frenum, the frenum should be divided. This is accomplished by raising the tip of the tongue with the fingers, putting the frenum on the stretch, and cutting it with scissors close to the jaw. The cut should involve the mucous membrane, but not the underlying muscles.

Swallowing the Tongue.—This accident should be guarded against in operations upon persons with mental diseases, in cases of division of the frenum, operations on the genioglossi muscles, and in cases of congenitally relaxed tongue. In such cases during and after operation the tongue should be held forward or watched lest its tip enter the pharynx or even the esophagus, and cause suffocation by closure of the glottis.

Injuries.—*Foreign bodies in the tongue*, if not removed, are prone to cause induration, or a sinus, which persists until the body is removed.

Wounds of the tongue should be treated by the methods already given (see Wounds, Vol. I, page 186). Even small wounds should be sutured. The best material is black silk, because it is most easily seen for removal. If there is a loss of substance, the wound should be closed by suturing the adjacent mucous membrane over it. In cases in which the tissue is almost separated, it should be sutured back in place with the hope that the naturally vigorous circulation of the parts will cause its union. The sutures should not be tied tightly because the parts will swell. Bleeding from small vessels is controlled by the sutures. Bleeding from larger vessels should be checked by the ligature before suturing the wound. Foreign matter should be removed and blood clots should be sponged from the mouth. Before applying the sutures, it is a wise precaution to irrigate the wound and to sponge off the mucous membrane around the wound with the view of removing gross infective material.

After suturing a wound the mouth should be kept as clean as possible. The teeth should be cleansed, and a mild aseptic mouth wash frequently used (see Cleansing the Mouth, page 244). A fluid diet has the advantage that it is least apt to irritate the wound. The mouth should be washed out after food is taken. Open wounds sometimes become persistent ulcers. In such cases decayed teeth should be treated and all sources of infection minimized.

Wounds in the posterior part of the tongue may be reached by passing a silk suture through the tip of the tongue to draw it forward and steady it. Digital pressure may be required to control bleeding. In some cases it has been found necessary to expose and ligate the lingual artery in the neck.

A local anesthetic suffices for suturing wounds of the anterior part of the tongue, but for operations on the posterior part a general anesthetic is best. If there is much bleeding from wounds of the back part of the tongue a tracheotomy with packing should be done.

In suturing these wounds, it is well to leave one end of the wound open for drainage. If much swelling occurs, sutures which cut should be removed. The friability of the tissues about old infected wounds renders suturing inadvisable until the cellulitis has been controlled by drainage and cleansing.

Gunshot wounds of the tongue are prone to carry infection and a careful watch should be kept. If a bullet is lodged in the base of the tongue, persistent bleeding calls for tracheotomy and packing of the back of the throat. This having been done, under general anesthesia, the surgeon may proceed to deal with the foreign body. Even though the ball is not lodged in the tongue, the dangers from hemorrhage and edema are so great that tracheotomy is always advisable. Secondary hemorrhage is to be expected in these cases, which is another advantage of having done a tracheotomy.

Burns of the tongue may be due to heat or to caustic substances. A slight burn requires that the mouth shall be kept clean and washed with a mild antiseptic solution (see page 244). Extensive burns, producing much edema of the tongue, may require, in addition to the above, incisions to liberate serum. If the back of the tongue is involved, the danger of edema of the glottis renders tracheotomy advisable. Ulcers are discussed below (page 289).

Inflammations of the Tongue.—*Acute superficial glossitis* is usually associated with some other disease against which treatment should be aimed. Beside removing the cause, an aseptic astringent mouth wash should be used (see Mouth Cleansing, page 244; Mucous Membrane Medications, page 183).

Acute parenchymatous glossitis should be met by removing the cause when it is known. As the disease usually occurs in debilitated adults and often gives rise to profound sepsis, constitutional treatment is important. Whether the infection is caused by streptococci or staphylococci, treatment by bacterial vaccine or serum is of value. The acute symptoms may be expected to abate in three or four days although a chronic induration may persist.

If the swelling is great, it is best relieved, drainage secured, and hyperemic reaction brought about by free incisions. Such incisions should be made on the dorsum on either side, 0.5 to 1 cm. ($\frac{3}{16}$ to $\frac{3}{8}$ inch) from the middle line. The incisions should go into the musculature and be about 1 cm. ($\frac{3}{8}$ inch) deep. A packing with nosophen, iodoform, or formidin gauze may be inserted. Other incisions may be required if the swelling is great. Abscess should be watched for and opened. Gangrene should be met by cutting away the slough as fast as it forms; and so long as a sloughing base is present, it should be treated frequently with phenol, followed by alcohol, and covered with antiseptic powder.

Edema of the glottis should be expected; and facilities for momentary tracheotomy should be at hand. The neck should be kept clean and covered with antiseptic dressing. Especially in the streptococcic infections is the disease apt to spread to the deep structures of the neck. Streptococcic angina should receive radical treatment as soon as it is recognized. The same with cellulitis or abscess of the neck (see Neck, page 360). Septic pneumonia must be guarded against.

The patient should breathe fresh, clean air. The mouth and nose should be kept cleansed with antiseptic solution (pages 183 and 244). Milk, eggs, and fruit juices are the best food. The mouth should be washed after each ingestion, and ulcers should be covered with antiseptic.

The glossitis due to mercurial poisoning rarely requires incision; it is more of an edema than cellulitis. When the tissues of the mouth are soft and boggy and the discharges foul, permanganate of potash solution is indicated for washing the mouth.

Chronic superficial glossitis represents a number of conditions. The conditions described under diseases of the skin may appear here and require the same treatment as when occurring in the skin. Such a disease is *herpes*.

Exfoliative glossitis requires antiseptic mouth washes (pages 183 and 244) and improvement of the general health. *Painful exfoliative glossitis* may be relieved by means of applications of silver nitrate or the actual cautery. The application of orthoform and the compound tincture of benzoin are of service. The *dyspeptic tongue* is to be treated by correcting the gastro-intestinal and general disorders. A permanganate of potash wash is useful. The tongue may be painted daily with silver nitrate solution (1 per cent.) or with chromic acid solution (2 per cent.). *Furrows* and *cracks* in the tongue should be treated by the correction of bad habits. Alcohol and tobacco should be inhibited. Constitutional disorders should receive attention. The mouth should be kept clean. Carious teeth should be treated. Cleansing of the cracks is best secured by the application of peroxid of hydrogen after each meal. Every second day the cracks should be opened and a weak solution of silver nitrate applied. Unless healing of these furrows is secured they are prone to become the seat of epithelioma. If persistent induration appears, it should be treated as epithelioma.

Leukoplakia (called also psoriasis of the tongue, although it may involve also the lining of the cheeks and lips) requires first that constitutional disorders, especially syphilis, shall be corrected. Inasmuch as the disease is incurable when once well-established, prevention is most important. Syphilis is a strong etiologic factor. Mercurialization and low states of resistance conduce to the disease. Locally the irritations of smoking and taking into the mouth such irritants as alcohol and spices are to be guarded against. A syphilitic who smokes is inviting the disease.

The active treatment demands that the causes shall be corrected. The hygiene of the mouth should be looked to. Decayed teeth should be remedied. The mouth should be cleansed, at least after each meal, with diluted peroxid of hydrogen or other mouth wash. The discomfort of dryness may be relieved by rubbing the patches at night with ointment of balsam-of-Peru. Painting the patches daily with glycerite of tannic acid is recommended. Tincture of iodin, chromic acid (2 per cent. solution), and silver nitrate (2 per cent.) are used. Possibly the actual cautery has helped some cases. It seems that the more the parts are irritated with applications the greater is the danger of epithelioma.

At the best the disease is quite intractable. Excision of the diseased area in the early stage has been done with the result that the disease has recurred and spread from the scar. When a persistent chronic indurated patch or ulcer appears, excision is the only treatment, as the probability of cancer is so great as to make any other course unwise.

Ulcers of the Tongue.—Ulcers should be prevented by keeping the mouth in an hygienic state especially when the general resistance is lowered by constitutional disease. The hygiene of the mouth demands not only that the teeth shall be in order but that the tongue shall be spared the irritation of tobacco, alcohol, spices and hot foods. Glossitis should receive appropriate treatment. *Simple ulcers* should have in addition to the above treatment a daily application of chromic acid solution (1 per cent.). A mild antiseptic mouth wash should be used several times daily. Tincture of iodin and nitrate of silver, while of benefit in many cases, produce irritation which may result in cancer. This latter condition should always be watched for. An ulcer, which does not make progress toward healing, and which has an indurated circumference, should be treated as epithelioma, and removed with 0.5 to 1 cm. ($\frac{3}{16}$ to $\frac{3}{8}$ inch) of the surrounding tissue. An elliptic incision is best. The wound should be closed with silk sutures.

The treatment of *dyspeptic ulcer* requires correction of the gastrointestinal

disorder. A laxative is valuable. Restriction of the diet is called for. If the disorder does not yield, chromic acid solution (1 per cent.) may be applied daily. A mild antiseptic mouth wash should frequently be used.

In the *herpetic or aphthous ulcers* of childhood, which are usually complicated by involvement of the lining of the cheeks, the general health of the child must be improved. If the disease is not controlled there is danger of gangrenous stomatitis. The child should be placed in the fresh air; its bowels should be kept open; and a liberal, simple diet instituted. Milk and eggs, with a little fruit juice, constitute the best medicine. Some fresh vegetable may be added to these. The ulcers should be touched frequently with boracic acid solution.

The cause of *traumatic ulcers* should be removed; the sharp edge of a tooth or pressure from a misfitting plate should be corrected. When the cause has been removed a simple antiseptic mouth wash may be used. If healing does not take place promptly, the suspicion of epithelioma should be entertained, and the disease excised. *Ulcer of the frenum* resulting from frequent spasmodic coughing requires treatment of the cause of the cough. Boric acid solution should be applied several times daily.

The ulcers resulting from ptyalism, *mercurial ulcers*, are to be treated by discontinuing the mercury, and using a mouth wash of permanganate of potash. Iodids should not be given. Belladonna may be used to check salivation (see Hydrargyrism, Vol. I, page 289).

Tuberculosis of the Tongue.—The vigorous circulation in the tongue prevents invasion by the tubercle bacillus. When *tuberculous abscess* does occur, it is best met by free incision and frequent cleansing of the cavity until a lining of healthy granulation tissue is secured. *Tuberculous nodules* are treated by removing the disease with a sharp curette or by an elliptic excision.

Tuberculous ulcers of the tongue should be treated the same as tuberculous ulcers elsewhere (see Tuberculosis, Vol. I, page 276). The improvement of the constitutional resistance is most important. In general it may be stated that the ulcer should be extirpated. Painful ulcers, even though a cure is not to be expected should be removed. If excision is not practised, the pain in incurable cases may be relieved by orthoform powder applied locally; or by the use of a powder made of iodoform, 0.06 Gm. (1 grain); cocain, 0.015 Gm. (¼ grain); and morphin 0.01 Gm. (⅙ grain).

Syphilis, Actinomycosis, Trichinosis, Leprosy.—Lesions of these conditions in the tongue are treated the same as when occurring in other parts. For actinomycosis, excision is the only effective treatment.

Diseases of the Lingual Tonsil.—These conditions require the same treatment as those of the faucial tonsils (Tonsils, page 212). There is the especial danger of edema of the glottis for which reason greater watchfulness and readiness for tracheotomy are necessary. In incising abscesses of this region, the patient should be with the head lower than the trunk so that pus shall run into the pharynx and mouth and not into the larynx.

Macroglossia (Hypertrophy of the Tongue).—This condition, when due to chronic inflammation, syphilis, hydrargyrism, idiocy, cretinism, or other discoverable etiologic factor should be met by treating the cause; and, when macroglossia remains after everything has been done, then operative treatment is called for.

True macroglossia, which is a cavernous lymphangioma, requires operative treatment. Usually the condition is congenital. The operation should be done before speech begins and before deformity of the jaws has been produced. Ulcers and excoriations should be cured by methods already de-

scribed. Usually the disease involves chiefly the front part of the tongue. The operation essential for cure consists in the removal of a V-shaped piece from the front of the tongue (Fig. 988). This is a simple operation. It can be done rapidly. The tongue is grasped posteriorly on either side by the fingers of an assistant. A tenaculum seizes the middle of the section to be removed, and draws it forward. After the wedge, with its base forward, is cut out, the main branches of the lingual artery are grasped and ligated, and the wound closed with silk sutures.

Calculi of the Salivary Ducts.—Small stones sometimes lie so close to the dilated mouth of the duct that they may be removed with forceps or a curet. When this cannot be done the mouth of the duct may be enlarged by incision and the calculus removed.

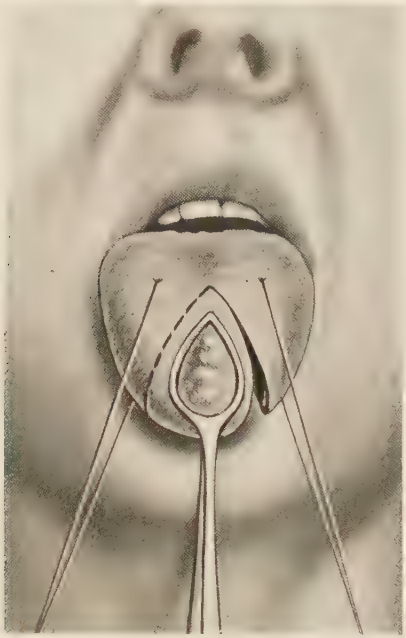

Fig. 988.—Macroglossia Treated by V-shaped Resection of Tongue.

Tumors of the Tongue.—*Ranula*, due to obstruction in the ducts under the tongue, requires removal of the obstruction. If the obstruction is caused by a calculus, its removal may be expected to effect a cure. Usually the cystic dilatation of the duct remains, if it is caused by stricture or inflammation, unless the cyst is removed. Whether the ranula be caused by obstruction of a mucous gland or a salivary duct, if it is of sufficiently long standing to have caused a well-formed cyst, the cyst should be dissected out. This dissection need not be complete. Most of the cyst should be removed, and the part of the cyst which remains connected with the gland or duct should be sutured to the mucous membrane of the mouth (Figs. 989 and 990). A submaxillary ranula, bulging below the jaw in the neck, may be excised through the skin; but if the gland still functionates it is necessary that the patency of the opening in the mouth shall be insured. If the opening is closed, a new opening through the mucous membrane should be made, and the glandular end of the duct sutured to it.

Cysts of the tongue should be excised either through the mouth or below the jaw (see Cystomata, Vol. I, page 325).

Benign tumors of the tongue are treated the same as benign tumors elsewhere (see Tumors, Vol. I, page 323). The exception to this is that papilloma should be removed as though it were a malignant growth.

Malignant tumors should be removed as soon as recognized (see Tumors, Vol. I, page 327).

Carcinoma of the tongue should be prevented by the measures which prevent inflammations and ulcerations of the tongue. Decayed and broken teeth are noteworthy etiologic factors. The treatment of cancer consists in free and wide extirpation. Warts, papillomata, and apparently benign growths on the surface of the tongue, in persons past middle life, should be removed by wide excision, because of the fact that they are almost certain to become cancerous. The same is true of indurated ulcers and inflamed areas, although not to the degree as papillomata. So important is this that, it may be said, the best time to operate on cancer of the tongue is before it becomes cancer.

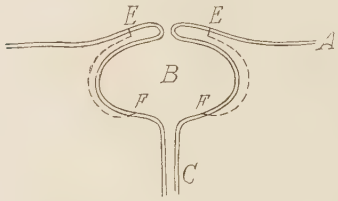

FIG. 989.—OPERATION FOR RANULA.

A, Mucous membrane of mouth; *B*, ranula; *C*, duct to gland; *EF*, dotted lines show part to be excised.

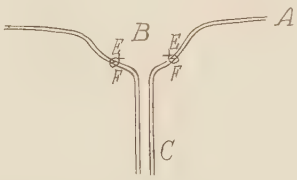

FIG. 990.—RESULT AFTER RESECTION OF RANULA.

The mucous membrane at *F* has been brought up and sewed to the mucous membrane at *E*. The cyst has been converted into a dimple (*B*).

If the growth in the tongue is small and the disease has been discovered early, it should be removed together with 1 or 2 cm. (3/8 to 3/4 inch) of sound tissue on every side. Usually a wedge-shaped incision is adapted to small growths and lends itself to being sutured to the best advantage. A growth, involving the front of the tongue laterally, should be treated by removing the most of that half of the tongue. As a rule, a lateral half of the tongue should alone be removed only in cases in which the disease is in front of the middle, is on the edge, and is not far advanced. If there is considerable growth involving both sides anteriorly, the whole front part of the tongue should be cut away; and if the growth is situated at the base of the tongue, the whole tongue should be removed, even though the disease is apparently confined to one side.

The lymphatics of the neck from the tongue are so arranged that the two sides communicate. Cancer of one side of the tongue soon infects the lymphatics of both sides of the neck. The further posterior the growth is situated, the greater is the liability of bilateral lymphatic involvement. A growth well forward on the side of the tongue causes later infection of the opposite side of the neck. In any case, if the disease is seen so late that a diagnosis of epithelioma is easily made, involvement of the lymphatics of the neck should be taken for granted, and the operation planned for their removal. This means that in every case operated upon for epithelioma of the tongue, the adjacent lymphatics of the neck should be removed. But

one side of the neck need be operated upon if the operation is done early and the disease is at the front of the side of the tongue; but if the disease involves the back of the tongue, not only should the whole organ be removed, but the lymphatics of both sides of the neck should be dissected out. Some surgeons have come to the belief that both sides of the neck should be operated upon wherever the growth.

The operations on the neck and tongue may be done in two stages if necessary. The mortality is highest in the cases in which both operations are done at one stage. In the cases in which the glandular involvement is slight or not palpable, it is preferred to remove the tongue first, and then after eight or ten days to remove the glands of the neck. In advanced cases, in which the glands are decidedly involved, it is best to remove the glands first, and then after a week or so, remove the tongue. This is because the growth in the glands in these advanced cases proceeds much more rapidly than that in the tongue.

It is a good practice to expose the anterior triangle and remove the lymph glands, the submaxillary salivary gland, the fat and connective tissue close up to the skin, the platysma, the upper part of the omohyoid muscle, the veins lying in the connective tissue, sometimes part of the internal jugular vein, and in some cases a segment of the external carotid artery . The superficial tissues lying just below the maxilla and under the skin along the upper course of the jugular vein should be removed. The tissues lying between the submaxillary salivary gland and the skin should be removed so thoroughly that but a thin flap of skin remains. It is best to take out in one mass all that is to be removed. Special attention should be given to the space between the mylohyoid and the hyoglossus muscles. The digastric triangle should be dissected out. The glands lying along the internal jugular vein and under the sternomastoid muscle should be removed. (For details of the technic, see Operation for Carcinoma of Lymphatics of the Neck, page 363.)

Removal of the Tongue for Carcinoma. The operation should be preceded by *preparation* aimed to prevent the complications which are prone to follow this operation. The mouth should be made as clean as possible. For several days before the operation a mouth wash (page 244) should be used. Carious teeth should have been filled or extracted. Tartar should be removed. Loose, dirty teeth had better be taken out. To operate when the mouth is in a foul state is to invite sepsis. As a final preliminary, after the anesthetic is established, the ulcerated surface should be dried and asepticized. This may be done with tincture of iodin or phenol; or, if sloughing tissue is present, the actual cautery should be used. The face and neck should have been shaved if the skin is to be incised.

Besides the ordinary *instruments* for dissection and hemostasis, the surgeon should be provided with mouth gag; tongue forceps or tenaculum; cheek retractor; strong, blunt, curved-on-the-flat scissors; sponge holders; aneurism needles; soft clamps for temporary compression of large vessels; materials for suturing vessels; and materials for closing the wounds.

In order to diminish venous engorgement, the best *position* is with the head and thorax slightly elevated, the patient lying on an inclined plane. This position is not to be recommended for patients with low blood-pressure; and, in any case, the head must be lowered if shock appears or if a serious fall in blood-pressure occurs during the operation. American surgeons are inclined to operate in the lowered-head position when tracheotomy is not used.

A loop of thread should be passed through the patient's tongue to give the anesthetist better control of it. The anesthetist and his assistant stand at the head of the table, the surgeon at the patient's right side or at the side

to be operated upon. The patient's face should be turned toward the well side.

The *complete operation*, if it is the intention to remove the lymphatics first, and then the whole tongue, is proceeded with as follows: An incision is begun behind the angle of the jaw, carried downward and forward to the level of the hyoid bone, and thence curved upward and forward to the symphysis of the lower jaw. A vertical incision is carried along the anterior border of the sternomastoid muscle from the first incision down nearly to the sternum (Fig. 991). The anterior edge of the muscle is exposed, retracted backward, and the internal jugular vein and carotid artery uncovered. The flap formed by the upper curved incision is turned up and the submaxillary gland laid bare (Fig. 992). The façial vein and artery are tied and divided (Vol. I, page 412). The tissues lying between the submaxillary gland and

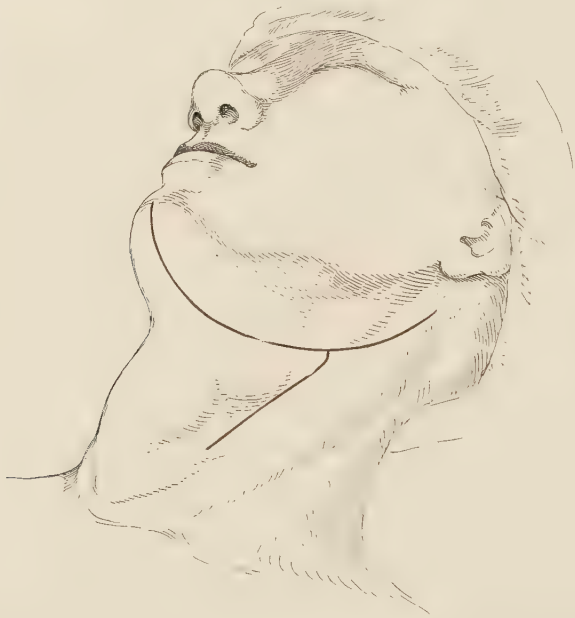

Fig. 991.—Incision for Removal of Tongue and Lymphatics of Neck.

the skin are removed. The whole gland with the surrounding connective tissue and lymphatics is removed. This excision should clean out the submaxillary space inward as far as the hyoglossus muscle.

The lymphatics lying along the jugular and carotid and under the sternomastoid should now be dissected away. The surgeon should not be discouraged, because every enlarged gland is not necessarily carcinomatous; septic absorption from the ulcerated tongue is the foremost cause of enlargement of the lymph nodes.

Glands lying under the lower end of the parotid should be removed. The dangerous glands are those lying above the level of the cricoid cartilage. Here the jugular or carotid may be so closely incorporated with the glands that resection of a part of the wall of one or both vessels may be called for. If indicated, this part of the operation is well worth doing.

The lingual artery is next ligated (Vol. I, page 411). The previous dissections make this ligation easy. The wounds are closed and covered with a tem-

porary dressing. If it is determined to operate upon both sides, the patient's head is then turned and the same operation repeated on the other side (see page 248). If it is intended to remove the tongue without operating on the lymphatics of both sides, the ligation of the lingual artery of the second side remains to be done (Vol. I, page 411).

Both linguals having been tied, the anesthetic may be continued through a nasal tube inhaler. The gag is inserted in the mouth on the side least affected, and attention to its security given over to the anesthetist's assistant. A silk thread is passed through the tip of the tongue and another posterior to the place of division to control the stump.

The use of the cheek retractor will give still more room. The tongue is drawn forward. With strong curved scissors the tongue is then cut out,

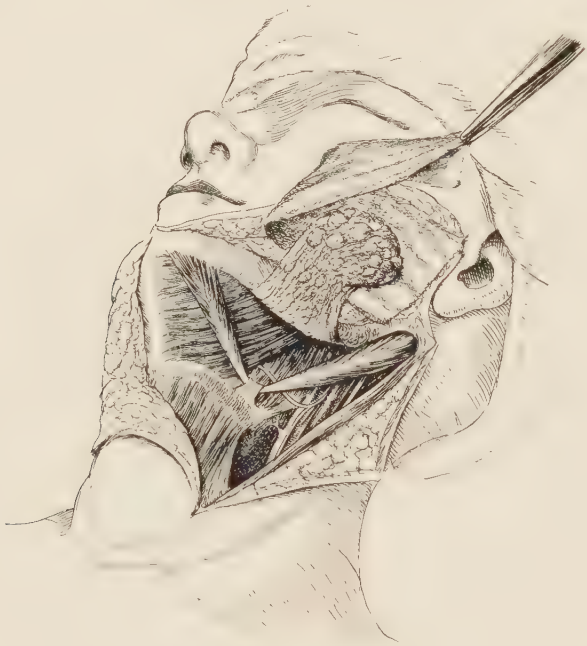

Fig. 992.—Removal of Carcinomatous Lymphatics of Neck.
Lymphatics with connective tissue of neck have been dissected up; a pad of gauze protects the wound from cancer cells.

the cut being made well back of the disease. The ligation of the two lingual arteries causes the bleeding to be but slight. Sponges in holders quickly take up the blood; and, if the patient's head is turned to one side, blood should not flow back to the pharynx (Fig. 993).

After removing the tongue, the dorsal mucous membrane of the stump should be sewed to the mucous membrane of the floor of the mouth, provided this can be done without making so much forward traction upon the epiglottis as to prevent its closing the glottis. In some cases the stump may be held forward by suturing it laterally to the wound in the mouth. If the raw surface of the stump is not covered by suturing mucous membrane over it, it should be dried and treated with compound tincture of benzoin, containing 5 per cent. of iodoform. A useful varnish is made of compound tincture of

benzoin, in which, for the rectified spirit, is substituted a saturated solution of iodoform in ether, the ether having mixed with it 10 per cent. of turpentine.

It is a wise precaution to leave the silk ligature through the base of the tongue, in order to make traction in case the patient has intractable closure of the glottis. This may be removed in twenty-four hours. A drain should be placed under the sutured mucous membrane and brought out in the neck wound to be left for twenty-four hours (Fig. 994). Gauze packing should not be left in the mouth as it quickly becomes saturated and foul.

This operation ordinarily can all be carried out, and free removal of the tongue secured. The dissection of one side of the neck should not take longer than half an hour. The removal of the tongue requires but a few minutes. If the condition of the patient demands it, the operation may be

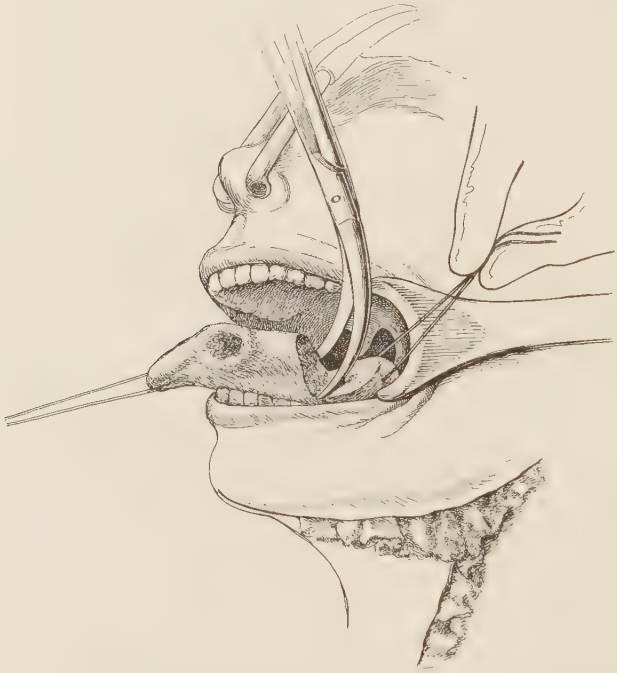

Fig. 993.—Removal of Tongue after Dissection of Neck.
The wound is temporarily covered with gauze and the flaps replaced while the operation in the mouth proceeds.

brought to a close at any of its stages, and completed at a second sitting. H. T. Butlin advised excision of the tongue, preceded by tracheotomy; and then, after two weeks, operation on both sides of the neck.

Excision, without preliminary ligation of the vessels is preferred by some surgeons. A thread is passed through the tongue. The anesthetic is administered through a nasal tube; or the pharynx is packed and a tracheotomy done. The mouth is widely opened with a gag. The operation is performed with strong curved scissors. The surgeon rapidly divides the frenum and the structures under the tongue and then the connections between the tongue and the anterior pillars of the fauces. This permits the organ to be pulled far forward. The lateral cuts are continued until the lingual vessels are reached. These are grasped with clamps and ligated through the mouth.

The division of the tongue posterior to the disease is then made, and the operation completed. Depending upon the condition of the patient, the removal of the lymphatics of the neck may be proceeded with immediately or at a subsequent operation.

In experienced hands, this operation is carried out with facility. The location of the lingual arteries is quite constant; and in the hands of a surgeon who has mastered the art of securing them, the operation has much to recommend it. This is seen to be true when it is realized how much time may be consumed in making the ligation of the arteries in the neck a distinct operation.

Excision through a submaxillary incision, first described by T. Kocher, is carried out through an incision on the diseased side. The incision begins opposite the lobe of the ear, passes down along the anterior border of the sternomastoid muscle to the level of the hyoid bone, and thence along the anterior belly of the digastric muscle to the symphysis of the lower jaw. The flap is turned up, and the facial and lingual vessels are ligated. Beginning posteriorly the surgeon removes the lymphatic structures, the sublingual and submaxillary salivary glands. The mylohyoid muscle is cut through and the mucous membrane of the floor of the mouth divided. The tongue may now be drawn into the wound and cut away by scissors passed through the mouth orifice. The operation is applicable to extensive lateral disease or disease far back.

Fig. 994.—Carcinoma of Tongue. Wounds closed. Drain in place.

If the whole organ is to be removed, it has been the custom to ligate the lingual artery on the other side of the neck, although it is possible to secure it through the mouth.

Excision after division of the lower jaw has much to recommend it. A median incision is made through the lower lip and carried down over the chin and neck as far as the hyoid bone. Bleeding is checked, a central incisor tooth is removed, and a hole drilled through the jaw on either side of the median line. The jaw is now divided by two oblique cuts so planned as to give immobilization after uniting the divided parts (Fig. 995). The two halves of the jaw are then retracted and the mucous membrane and muscles divided in the floor of the mouth. The tongue is drawn forward by a transfixion thread and its detachment proceeded with from below. Scissors are used. Bleeding vessels are secured. Most vessels can be controlled by twisting. The lingual vessels are clamped preferably before their division. The operation should be conducted with deliberation. As much of the tongue and tissue in the floor of the mouth as is necessary may be removed. After treating the stump the jaw is wired together and treated thereafter as a fracture. Drainage is provided in the lower end of the wound. The dissec-

tion of the lymphatics of the neck may precede or follow the operation on the tongue.

This operation has the disadvantages that the after-treatment must be prolonged, and the attachments of the tongue are so loosened that the larynx is apt to lack anterior support. Its advantages are that it gives free access for securing the lingual vessels through the mouth, and lends itself especially to cases in which the floor of the mouth is involved.

Comments.—Removal of the tongue through the mouth is most satisfactory. Excision through a submaxillary incision and excision after division of the lower jaw are best reserved for the peculiar cases.

It should be borne in mind that recurrence after operation for epithelioma of the tongue is usually in the lymphatics, showing that the difficulty has not been in getting beyond the disease in the mouth. If a diagnosis of epithelioma is made clinically, the glands of the neck should be removed in all cases.

In order to secure more room for operating through the mouth, if that which is afforded by the use of the gag and cheek retractor is not sufficient,

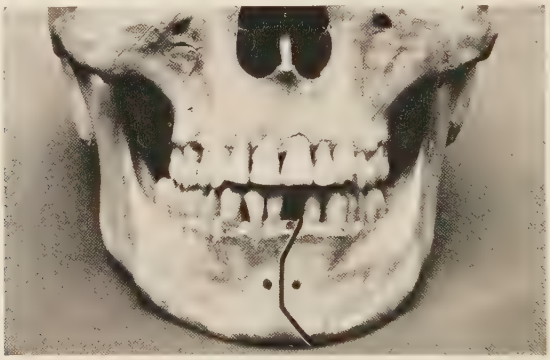

Fig. 995.—Method of Dividing Lower Jaw for Exposure and Removal of the Tongue.

The jaw is divided in such a manner that at the close of the operation a single suture will hold it in place.

an incision may be carried outward from the angle of the mouth through the cheek. If the disease involves the floor of the mouth, the operation is much facilitated by extracting the lower incisor teeth.

Whether preliminary ligation of the lingual arteries is practised must depend upon the surgeon's facility. It has the merit of saving blood and allowing the operation to proceed with greater deliberation. It consumes much time, and the facile surgeon is able to secure the vessels through the mouth.

When the disease extends beyond the tongue, the operation will have to be modified accordingly. Excision of part of the jaw, of the larynx, or of the deep structures of the neck may have to be done. If the primary disease can be removed, the surgeon is justified in its removal. Death from the progressive advancement and breaking down of epithelioma of the tongue is a condition from which the surgeon should endeavor to save his patient. Recurrence in the lymphatics leads to a less distressing end.

The mortality following operations for epithelioma of the tongue has been reduced by preventing sepsis, pneumonia, hemorrhage and shock. The well-equipped surgeon has about 3 deaths following operation in 100 uncompli-

cated cases, and 25 deaths following operations in 100 badly complicated cases. Butlin estimates that the mortality in all cases should be about 12½ per cent. We have no adequate statistics as to recurrence.

After-treatment.—Immediately after the operation the patient should be made to lie on his side with the head lowered and turned to one side so that fluids will run out of the mouth. He should have fresh air which is as free from dust as possible. Morphin should not be given as it diminishes the reflexes upon which the patient must depend to cough up matter which enters the larynx.

He should be caused to sit up in bed as soon as he has recovered from the anesthetic. This should be within the first thirty-six hours, if possible. The mouth should be washed out with boric solution every half hour or every hour for the first two days. The patient should be instructed not to swallow saliva or mouth secretions, but his head should be so placed that they may flow from the mouth.

Rectal feeding should be used for the first two days. Then a tube should be passed through the mouth or nose into the esophagus, and fluid food administered. This stomach feeding may be begun earlier, if the patient seems to need it.

The mouth must be kept clean. An occasional washing with an irrigator should be practised. If the mouth becomes offensive, phenol, peroxid of hydrogen, or other stronger solution should be used (page 244). The patient should be up out of bed by the third or fourth day. He may be allowed to swallow without the tube before the fifth day.

THE EAR

Anatomy.—The ear is divided into three parts: the external ear, made up of the auricle or pinna and the external auditory canal; the middle ear, comprising the tympanic membrane, the tympanic cavity, the mastoid cells, and the Eustachian tube; and the internal ear comprising the vestibule, the semicircular canals, the cochlea, and the end-apparatus of the auditory nerve (Fig. 996).

The external auditory canal, ending at the drum, is arched slightly upward, and is directed inward and slightly forward. In using the speculum, it should be remembered that the curve in the canal may be straightened by drawing the ear outward, upward and backward.

The tympanic membrane closes the middle ear externally from the outer air. The outer surface is concave. This membrane is divided into two portions. The upper portion is flaccid (Fig. 756), the lower portion is tense. The chorda tympani is at the upper portion. The little chain of three bones, the malleus, incus, and stapes, is attached to the inner surface of the drum membrane. The handle of the malleus is contained between the layers of the drum. These bones connect the drum with the nerve mechanism of the internal ear. The Eustachian tube passes from the tympanic cavity downward, forward and inward to the outer wall of the nasopharynx just posterior to the lower turbinate bone.

The roof of the middle ear cavity is formed by a thin plate of bone separating it from the middle fossa of the cranium. The floor is formed by this bone separating it from the jugular fossa.

The mastoid antrum and the mastoid cells are situated in the mastoid process of the temporal bone and all communicate. The antrum is located in the upper and anterior portion of the process, just behind the tympanic cavity, and behind and slightly above the external meatus. The antrum is about the size of a pea, is lined with epithelium, and contains air which communicates with the tympanum. The opening into the tympanic cavity is above the level of the floor of the antrum. The roof of the antrum is separated from the cranial cavity by a thin plate of bone which is perforated by veins emptying into the superior petrosal sinus. It is on a level with the lower border of the posterior root of the zygoma.

The floor of the antrum is in relation to the mastoid cells. The Fallopian canal, transmitting the facial nerve, lies at the inner side of the passage between the tympanum and antrum. The posterior wall of the antrum is thin and perforated by veins passing to the sigmoid sinus.

The postmeatal triangle is bounded above by the posterior root of the zygoma, in front by the osseous part of the external auditory meatus, and behind and below by a line connecting these two. If the osseous external auditory meatus is bisected by a horizontal line, the upper half would be on a line with the antrum. This triangle, lying just behind the meatus, represents the outer wall of the antrum, through which the antrum should be opened (Fig. 997).

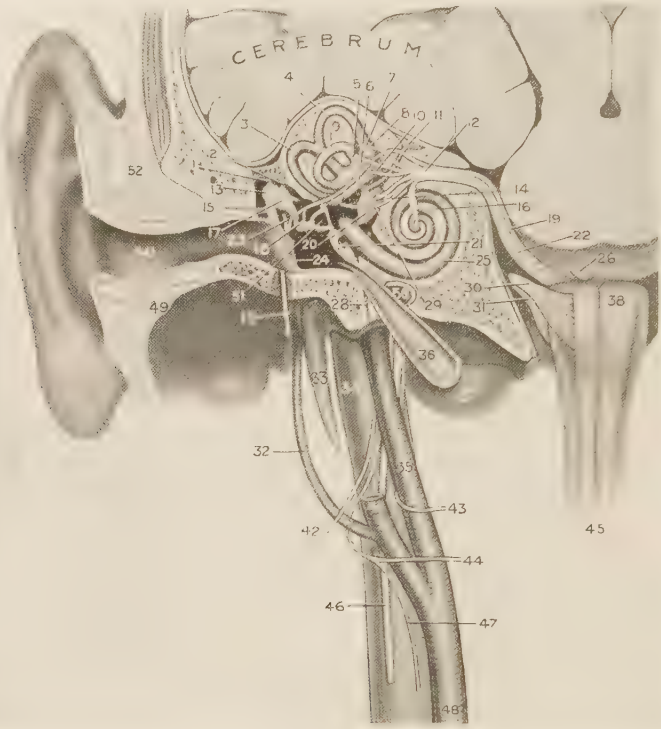

FIG. 996.—ANATOMY OF EAR.

Showing relations to brain, nerves and vessels. 1, Superior ligament of malleolus; 2, superior ligament of incus; 3, cerebral semicircular canal; 4, cerebellar semicircular canal; 5, ampullary branch of vestibular nerve to 9 ampulla; 6, utricle; 7, ampullary branch of vestibular nerve to 3 ampulla; 8, ampullary branch of vestibular nerve to 4 ampulla; 9, tympanomastoid semicircular canal; 10, utricular branch; 11, saccus endolymphaticus; 12, vestibular nerve; 13, head of malleus; 14, saccular branch; 15, external ligament; 16, cochlear nerve; 17, body of incus; 18, stapedius nerve; 19, facial nerve; 20, saccule; 21, membrane of cochlear window; 22, auditory nerve; 23, chorda tympani nerve; 24, drum membrane; 5, ductus cochlearis; 26, abducens nerve; 28, aqueductus cochleæ; 29, ductus utriculosaccularis; 30, hypoglossal nerve; 31, glossopharyngeal nerve; 32, occipital artery; 33, styloid process; 34, internal jugular vein; 35, internal carotid artery; 36, Eustachian tube; 37, condyle; 38, medulla oblongata; 39, mastoid process; 40, external auditory canal; 41, external carotid artery; 42, spinal accessory nerve; 43, glossopharyngeal nerve; 44, hypoglossal nerve; 45, spinal cord; 46, pneumogastric nerve; 47, descending branch of the hypoglossal nerve; 48, common carotid artery; 49, fissura santorini; 50, internal carotid artery; 51, stapes in vestibular window; 52, cut cartilage of auricle.

It is important for the surgeon to remember that, in opening the antrum he should keep close to the posterior, osseous wall of the external auditory canal and follow its direction. If the opening is made too high the cranial cavity will be invaded; if the opening is made too far posteriorly, the sigmoid sinus will be injured; if the bone is penetrated for a distance greater than 1.75 cm., (⅝ inch) the facial nerve, will be encountered.

When the surgeon, in operating for middle ear and antrum suppuration, cannot locate the antrum, the soft parts may be elevated from the posterior wall of the osseous auditory

canal, and a probe with a hooked end passed into the tympanum. It will find the opening into the antrum at the upper and outer part of the tympanum, where it may be retained as a guide. Or the posterior wall of the canal may be chiseled away until the antrum is reached.

The external auditory canal contains a cartilaginous incomplete tube, between the bony wall and the skin.

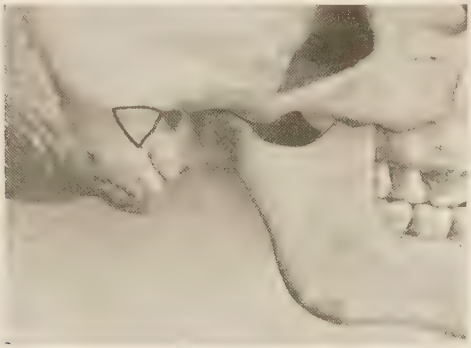

FIG. 997.—POSTMEATAL TRIANGLE, WHICH CORRESPONDS WITH THE MASTOID ANTRUM.

This triangle is bounded above by the posterior root of the zygoma, in front by the posterior osseous margin of the external auditory meatus, and behind by a line continuous with th anterior surface of the mastoid process on a line from the end of the root of the zygoma. It is through this area that the mastoid antrum may be opened with safety.

General Principles.—*Wounds of the tympanic membrane* made by the surgeon heal promptly. *The patency of the Eustachian tube* requires to be determined in treating middle-ear diseases. This may be done by making an expiratory effort while the mouth and nostrils are closed. Swallowing relaxes the opening of the tubes and permits the air to escape. The method of Politzer for inflating the middle ear consists in blowing into the nostril with a rubber bag (Fig. 998) at the instant that the patient swallows water. The bag should have a capacity of 300 c.c. (10 ounces); the nozzle should be large and connected by a short rubber tube with an end piece fitting tightly into the nostril. The patient takes water into his mouth; the opposite nostril is compressed and the tube held in place by grasping the nose between the fingers; the patient is then told to swallow; and as the larynx is seen to rise at the beginning of the act, the bag is forcibly compressed. Or without swallowing the water, the same effect may be secured by having the patient inhale deeply and then forcibly blow between the partly closed lips while the operator performs the inflation as described above.

FIG. 998.—POLITZER'S BAG FOR INFLATING EAR IN OPERATION.

Catheterization of the Eustachian tube is accomplished by means of a metal catheter. The instruments should vary in size from 1 to 3 mm. in diameter. The tip should be slightly curved, knobbed and rounded. The operator sits facing the patient, lifts up the tip of the nose with the thumb of the left hand, and with the right hand lightly inserts the instrument, its tip gliding along the floor of the nose (Fig. 999). It is passed back until it reaches the pos-

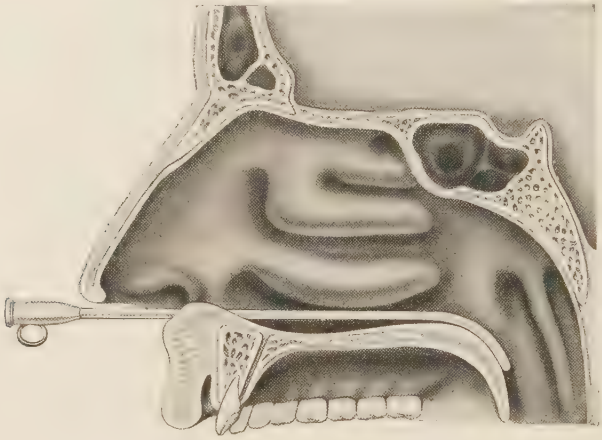

FIG. 999.—EUSTACHIAN CATHETER IN NASAL CAVITY.

The catheter lies on the floor of the nose; it has just passed over the soft palate; when it is rotated the point will strike the lateral wall of the nose at the entrance to the Eustachian canal.

terior wall of the pharynx; the tip is then rotated inward 90 degrees and drawn forward until it is felt to be stopped by the posterior edge of the septum; it is then rotated outward and a little less than 180 degrees, and it should then be at the mouth of the Eustachian tube. Or the catheter, with its tip downward, may be drawn forward until it hugs the posterior surface of the soft palate; if the tip is then rotated outward a little more than 90



FIG. 1000.—AURAL SPECULA.

degrees, or until the guide points to the outer canthus of the eye, the tip will be at the Eustachian opening. It is possible to catheterize the tube from the opposite nostril by using a catheter with a longer tip.

Examination of the external canal and tympanic membrane is made with a speculum and a good light. The latter is secured by means of a concave head mirror or an artificial light. The small electric lamp worn upon the forehead is useful. The aural speculum (Fig. 1000) serves to straighten out

the canal. In order to secure access to the drum membrane in the infant the auricle should be drawn downward, backward, and outward. In the adult, the membrane is best exposed by drawing the auricle upward, backward and outward. Bulging outward of the membrane is important as it indicates abnormal internal pressure. Bulging which is uniform indicates inflammation in the tympanic cavity (atrium); but when the bulging is limited to the upper posterior portion of the membrane, it indicates inflammation in the tympanic vault, a much more serious condition.

The External Ear

Congenital Defects.—*Malformations of the auricle, absence of the auricle,* and *excessive development of the auricle* are remedied by plastic operations (see Vol. III). In *stenosis of the canal* an operation may be done to construct a new canal; but these operations have not much improved the function of hearing. *Supernumerary auricles* are to be excised.

Hematoma of the Auricle.—If seen early, hemorrhage may be checked by cold applications or by light pressure. To make pressure, a pad of gauze or cotton should be placed between the ear and the scalp, the ear covered with another pad, and the whole compressed by a bandage around the head. The pressure should not be so great as to cause pain. If the blood does not become absorbed and is soft and fluid, the skin may be sterilized with iodin, and aseptic aspiration done. If the blood cavity becomes infected, it should be opened freely and treated as an abscess. Necrotic cartilage should be removed.

"Cauliflower ear" is best treated by making a small incision, inserting a curet and scraping out clots and detritus. The cartilage should be scraped. The cavity shoulg then be washed out, and a compressing dressing applied. This dressing should be moulded to fit the ear and side of the head. It should be placed on each side of the ear; and a bandage around the head should hold it. The ear should be in normal position so that it does not become distorted.

Othematoma is hemorrhage under the perichondrium, and requires aspiration or incision.

Wounds of the Auricle.—Wounds should be given the best possible aseptic treatment because infection is prone to cause necrosis of cartilage (see Wounds, Vol. I, page 186). Attempts should be made to restore all parts of the ear when mutilated; and even when completely torn away, restitution should be attempted. *Cleft lobule,* such as results from the tearing out of ear-rings, should be repaired by the same operation that is applied to cleft palate. To prevent suture-hole scars, a fine subcuticular suture may be used for the outer part of the wound; or interrupted sutures may be passed from the inner side of the lobule and only through the deep layer of the skin on the outer side of the lobule.

Perichondritis and Cellulitis.—These should be treated the same as inflammations elsewhere. The collection of fluid or pus demands early and free opening. Necrotic cartilage should be removed. The loss of cartilage results in deformity. To prevent this deformity, the ear should be kept supported on a splint of some stiff material until healing has reached a point where asepsis can be secured; then a piece of cartilage from the sternocostal interval or elsewhere may be grafted in the defect. Chronic perichondritis is treated by removing the cause. Ichthyol ointment (20 per cent.) is applied locally.

Cutaneous Diseases.—The treatment is the same as cutaneous diseases elsewhere. *Frost-bite* (see Vol. I, page 318) requires that the temperature of the ear should be restored gradually. This may be done by gentle friction with snow or broken ice. Gentle massage should follow. If only the skin becomes inflamed, 10 per cent. ichthyol ointment is of service. Perichondritis, following frost-bite, should be treated by the methods above described.

The External Auditory Canal

Wounds.—Fractures of the base of the skull may lay open the external auditory canal. If the fracture is compound, the canal should be cleansed and kept protected with a wet antiseptic dressing.

Acute Circumscribed Inflammation (Furuncle).—This is a cellulitis beginning usually in the outer end of the canal and soon extending to the cartilage and bone. The most swollen parts should be incised freely. This should be the first step of the treatment. The operation should be done with aseptic care. The incisions should be parallel to the long axis of the canal and should be carried completely through the soft tissue. Without anesthesia, the operation is very painful. Even though no pus is present the incisions will hasten recovery. The wounds should be lightly packed with antiseptic gauze, a bit of gauze inserted into the canal, and the whole covered with a wet antiseptic dressing. The dressings should be renewed twice daily, and once daily the canal should be irrigated with antiseptic solution. Unless these precautions are taken successive reinfections are apt to occur. Suction treatment, applied directly to the furuncle, is useful.

Diffuse Inflammation of the External Auditory Canal.—(See Cellulitis, Vol. I, page 228).—When *acute*, the treatment of this condition is the same as the circumscribed form. Hot applications are of value. By free incision, invasion of cartilage and bone may be prevented, although the disease will often subside under artificial hyperemia, cleansing the canal and dusting it with calomel. When *chronic*, the disease should be treated as a dermatitis. The parts should be cleansed and antiseptic applications made. Usually the treatment of *eczema* is indicated (see Vol. I, page 830). *Mycosis* is readily cured by antiseptics (see Vol. I, page 838). Silver solutions are effective.

Exostoses of the External Auditory Canal.—Bony growths encroaching upon the canal do not require operation if small. They should be removed when large enough to confine secretions against the eardrum or occlude the canal to such a degree as to interfere with hearing. Pedunculated growths may be removed through the meatus. For sessile growths, the best method is the subperiosteal operation. A curved incision is begun at the tip of the mastoid process and carried upward back of the ear to a point above the middle of the meatus, keeping about 0.5 cm. ($\frac{3}{16}$ inch) away from the auricle. The incision should go through the periosteum. The flap of soft tissue, periosteum, and cartilage should be elevated from the bone, and the elevation continued into the canal until the tumor is uncovered. Care should be taken not to injure the eardrum. With a fine sharp chisel, the exostosis should be removed in one piece by cutting into the underlying bone. These masses are usually so hard that it is not wise to attempt chiseling them off in pieces. It should be remembered that the facial nerve and semicircular canals are near the drumhead posteriorly. If the growth is extensive, enough bone should be removed to make a good free canal. The wound should be closed by sutures and a packing of gauze inserted in the ear to hold the soft tissues against the bony canal. If the above operation does not give sufficient

room the soft structures of the canal may be split. Recurrence is not apt to follow.

Foreign Bodies in the External Auditory Canal.—*Inanimate objects*, such as seeds, beads, buttons and pebbles may be grasped by fine forceps and removed. Care should be taken not to push the body further in. If too large to be grasped, a fine wire hook or loop may be used. Often a hook can be used to roll the object out. Syringing is the most effective method. A fine syringe, or a hypodermic needle with the end rounded, may be used to inject water or oil to the inner side of the object. It is not necessary that the nozzle of the syringe should pass the object. The fluid will pass it if injected in the direction of its periphery, and gradually wash it out. Cement may be applied to the outer surface of the body and cotton caused to adhere to it; after a day or more, when the cement has dried, the cotton may be twisted into a cord and the body pulled out. The manipulations should never be prolonged. The surgeon should do the right thing, and not consume time and cause irritation by unsuccessfully picking at a foreign body. The ear-drum should not be injured.

Seeds and other bodies which have become swollen with moisture may be dehydrated by alcohol and their size thus reduced. If the skin has become swollen and edematous, time should be given for its treatment, by antiseptic irrigation. If the drum is perforated, the body should be removed at once if it totally occludes the canal; if drainage is possible, irrigation should be practised frequently.

If the body cannot be removed, the curved incision behind the ear, described above for the removal of exostoses, should be made, the cartilage elevated from the bony canal, the soft structures split lengthwise, and the parts retracted. This gives room for the removal of the body by taking the cartilage out of the way. If more room is desired bone may be chiseled away from the posterior wall. The body being removed, the wound behind the ear is sutured and the canal packed with gauze which should be renewed at least once daily.

Animate objects, such as flies, ticks, ants, and other insects, larvæ, and moulds, often require treatment. Insects can be dislodged by means of gentle irrigation with water or antiseptic solution. The syringe may be used to wash them out. A living insect will usually come running out if water is dropped in the ear. Ticks sometimes attach themselve to the wall of the canal and require to be dislodged with camphor water, diluted ammonia water, alcohol or oil. A drop of chloroform on a piece of cotton will make most insects change their plans. The death of a tick is not always followed by its loosening its hold. It may be necessary to introduce a speculum and grasp the animal with forceps. If it is attached to the drum it should be removed by a twisting motion. Larvæ can be killed by chloroform vapor, alcohol or antiseptic solutions.

Impacted Cerumen.—As ear wax is mixed with oily matter it is easily dissolved by alkalies. If a strong solution of bicarbonate of soda is dropped in the ear and retained for a few hours or until the following day, the cerumen may then be washed out with warm water injected from a syringe. Impacted cerumen may be softened by filling the ear with olive oil at night; in the morning the cerumen may be washed out with a warm saturated solution of borax. A good solution for the purpose of softening cerumen is made of 0.6 Gm. (10 grains) each of sodium bicarbonate and sodium biborate, dissolved in 15 c.c. (½ ounce) each of glycerin and water. Ten drops of this may be put in the ear twice daily.

If cold water, hot water or too much force is used in syringing, the

patient may suffer pain, dizziness or syncope. In some cases a hard, dry plug may be grasped by a hook or fine curet, and removed. Patient syringing with alkaline solution is the safest treatment.

Epithelial Plug (Keratosis Obturans).—This condition is different from impacted ear-wax in that the plug is made up of layers of epithelial cells. It is not capable of being broken up by solution, but must be removed by forceps, curet or hook.

Cholesteatoma.—Cholesteatoma of the ear is treated by following the disease into all of its ramifications, and thoroughly cleaning it out with a sharp curette.

The Middle Ear

Traumatic Rupture of the Tympanic Membrane.—Whether the rupture of the drum is associated with fracture of the temporal bone or forms a communication only with the middle ear, asepsis is most important. If the discharge of blood or cerebrospinal fluid is profuse, the ear should be irrigated every two hours with antiseptic solution. If the discharge is but slight, irrigation once or twice daily is sufficient. The fluid should run in easily with the view of cleansing the outer surface of the drum membrane, but should not be driven into the middle ear. If the rupture is linear and the discharge stops in a few days, healing may be hastened by mopping the canal and membrane with a 1:3000 alcoholic solution of bichlorid of mercury, and applying to the drum membrane a sterilized disk of writing paper, soaked in bichlorid solution, to act as a splint and dressing. This gives the minimum scar.

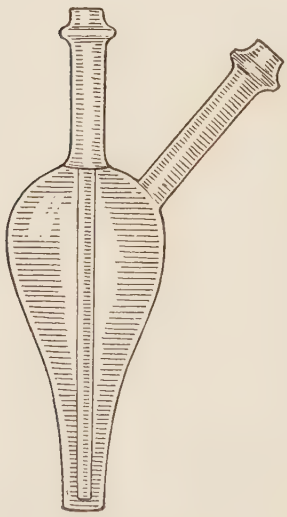

Fig. 1001.—Ear Douche Point which Permits Inflow and Outflow.

A constant stream of irrigation may be maintained.

Blood accumulating in the middle ear and preventing healing may be removed by blowing through the Eustachian tube after the method of Politzer. Simple ruptures are best treated by applying by means of a powder blower a layer of boric acid upon the drumhead and leaving the ear undisturbed unless pain or suppuration demand interference. This is the best treatment for simple uncomplicated wounds of the drum.

Ulcerative Rupture of the Tympanic Membrane.—Perforations resulting from otitis media or other disease permit air and dust to enter the ear and set up repeated attacks of otitis. Their early healing is desirable. When the causative disease has subsided and discharge ceased healing should be stimulated. An opening lined with granulations may be touched with alcohol or tincture of iodin. If epithelium is growing over the granulations or if they are feeble the edge of the opening may be stimulated by touching it with pure nitric acid applied on a fine cotton-wrapped probe. If the membrane is clean the paper disk, described above, may be used with advantage.

Acute Inflammation of the Middle Ear.—In the milder cases healing may be secured by increasing the local hyperemia. This is done by hot applications. Large wet compresses applied to the side of the head and ear may be kept hot by means of a hot-water bag. In connection with this treatment heat may be introduced against the drum by hot irrigation the of

external canal. For this purpose a douche point which has an opening for return flow is useful (Fig. 1001). Through this a continuous stream of heated water 44° to 49°C. (112° to 120°F.) may flow in and out of the ear. Warm glycerin dropped into the ear is useful in some cases. Dry heat, in the form of a stream of heated air, or the application of heated bags of salt or clay, or the hot coil, are useful.

When the disease begins as a nasotubal infection, repeatedly blowing out the ear by the method of Politzer or by Eustachian catheterization is of service in draining the fluid from the ear.

In any of these conditions, when the disease has produced exudate in the middle ear which causes bulging of the drum and pain, especially if there is pronounced fever, incision of the drum is called for. Some surgeons practice incision of the drum at once in every case of acute inflammation of the middle ear.

The operation of *incision of the drum* is done to secure drainage. It should be preceded by swabbing the ear canal with 1:5000 bichlorid alcoholic solution. The operation should be done with aseptic precautions. Not a puncture but a free incision should be made (Fig. 1002). Incision of an inflamed drum is very painful and a general anesthetic for a few seconds is desirable. The knife should be very sharp. The drum should be well exposed by the speculum and a good forehead light. The incision should be made where the fluid is, whether in the attic or atrium. If the atrium is filled with fluid, the knife may be inserted just behind the short process of the malleus, below the posterior fold, near the tympanic ring, and the incision carried downward parallel to the posterior segment of the ring as far as the bottom of the membrane. The fluid gushes forth, and as soon as drainage ceases the wound heals promptly. The reparative power of the drum is so great that healing often occurs before the need of drainage has passed.

Fig. 1002.—Paracentesis Knife for Incising Ear Drum Membrane.

If drainage is not free, and especially if the secretion is tenacious or thick, blowing through the Eustachian tube or the application of a suction cup to the external ear will hasten healing.

Following incision of the drum for infection of the middle ear, irrigation with warm bichlorid of mercury solution (1:5000) should be employed. The irrigation should be practised several times daily. Gentleness should be used. Care should be taken that the fluid has free exit so that it shall not be driven into the middle ear. The irrigation should be done every three hours during the day and every four hours at night. Later the intervals may be lengthened. Once daily the surgeon should swab out the canal with bichlorid solution. The patient should be kept quiet. The dressing should be done with aseptic care. A light protection of cotton should close the outer ear. At the same time any other ear complication or nasal disease should receive attention. Inflation of the ear through the Eustachian tube should be continued daily; it helps clean out the ear and prevents the retention of exudate which may become organized and bind together the structures of the ear. As healing progresses and the tympanum becomes clean, inflation may be done less frequently.

In *acute suppurative otitis media*, incision of the drum membrane should

be done as soon as possible. If perforation has already taken place the surgeon should make an examination, and if the opening is not ample it should be enlarged. The best drainage is secured by having the patient lie on the affected side with the face turned somewhat downward.

The *indications for mastoid operation in acute otitis media* are based on the knowledge that in every acute inflammation of the middle ear the mastoid is involved to some extent. Pain, temperature, local tenderness, and canal symptoms are important indications. The bacteriologic examination of

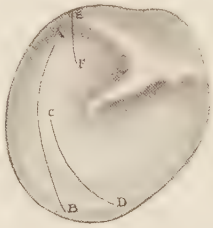

Fig. 1003.—Lines of Incision for Incising Drum Membrane.

AB, Incision made from above downward in case the atrium is filled with fluid; *CD*, incision for evacuation of exudate; *EF*, incision made from below upward in case the mucous membrane of the attic is much inflamed. The incision (*EF*) is carried through the drum as far as the upper limb of the ring and then continued outward through the skin of the postero-superior wall of the external meatus.

discharge, the amount and duration of discharge, history of previous attacks, and symptoms of involvement of labyrinth must all be taken into consideration. If several punctures of the drum membrane have had to be done in previous attacks, if the disease progresses without abatement, if pronounced defect of hearing develops, or if meningeal symptoms appear, operation is indicated.

Chronic Suppurative Otitis Media.—When not due to tuberculosis or some other rare chronic infection, the disease is a continuation of acute



Fig. 1004.—Ear Syringe.

otitis media. Neglected cases become chronic. The cause of the continuous discharge cannot always be discovered. The presence of hardened exudate or necrotic material in the middle ear should be blown out by Eustachian insufflation. If the opening in the drum is not large enough for free drainage it should be enlarged. Exuberant granulations should be removed with the curet or caustic. Frequent cleansing with antiseptic solution should be practised. Irrigation should be done often enough to keep the ear clean and the skin of the canal healthy. In the milder cases simple cleansing is sufficient to effect a cure. The syringe should have a point which does not obstruct the flow of fluid out of the ear (Fig. 1004). For the attic a special syringe is used which must be inserted through a speculum.

Often the discharge is kept going by granulation tissue in the middle ear or some inaccessible focus of infection. Silver nitrate solution (1 per cent.) is of service. The patient should lie with the diseased ear upward after irrigation and drying out have been done. A few drops of the silver solution are allowed to run into the ear. This may be repeated every third or fourth day for two weeks.

A method which I have found effective has been to clean the ear thoroughly by irrigation, then dry it out with cotton, then fill it with alcohol, then dry out the alcohol, then drop in 2 or 3 drops of tincture of iodin and quickly follow it with an equal amount of alcohol. This is then diluted with more alcohol, the ear again dried out, and some antiseptic powder, such as formidin, blown in.

Inspissated matter sometimes is attached to the drum membrane or lodged in crevices. For this reason, inspection with a good light should be made and such material removed with hooks or curets. If the opening in the drum is large, peroxid of hydrogen may be used to dissolve it and throw it out. Yeast is of value for this purpose. It also has the power to antagonize suppurative organisms. When it is used antiseptic drugs should be washed out with salt solution, and the yeast introduced with sterile water.

There are other methods of using *ear-drops* which are effective. A solution of boric acid, 1.2 Gm. (20 grains), in alcohol, 30 c.c. (1 ounce) , may be applied after cleansing and drying the ear. This is used once daily, the patient lying with the affected ear upward. After a few drops have been introduced the auricle should be grasped and, in the adult, drawn upward, backward and outward, to straighten the canal. The finger is then placed against the tragus and the tragus repeatedly and rapidly pressed into the external meatus. This operation pumps the fluid into the middle ear and forces it into cavities and interstices.

Instead of boric acid some of the other above-mentioned solutions may be used. Kuyk employs silver nitrate, 2 Gm. (30 grains) in 30 c.c. (1 ounce) of water. This he forces into the remotest recesses every second day by means of air pressure. If no improvement is observed in two weeks, the strength of the solution is doubled, and if necessary, gradually increased until a 25 per cent. solution is used. Good results are secured in mild cases from the use of the following solution: zinc sulphate, 0.3 Gm. (5 grains); glycerin, 4 c.c. (60 minims), saturated solution of boric acid, 30 c.c. (1 ounce).

The treatment of middle-ear suppuration by *hot air* is effective. After removing all accessible foreign matter the cavity should be dried with cotton. The larger the opening in the drum, the more effective the treatment. Heated air is blown into the ear by means of some of the devices especially for that purpose. This treatment has the advantage of the healing effect of dryness upon granulations and infections together with the hyperemia which it induces. Before applying it, it is well to send through the Eustachian tube a cleansing solution to remove débris.

The use of *drying powders* is indicated if the opening in the drum is large; if it is small or if there is detritus in the middle ear, powders are not of service. Care should be taken that powder is not packed against the drum so as to occlude the opening. Before applying a powder the canal and middle ear should be thoroughly cleansed and dried. The best method of application is by a powder blower. The applications may be made every day or two. Boric acid, finely powdered and dry, is of much service. Formidin, nosophen, xeroform and iodoform are of value. Silver nitrate, 0.6 Gm. (10 grains) in zinc stearate, 30 Gm. (1 ounce), may be used once or twice a week.

Another dry treatment is by means of *gauze drainage*. After cleansing

and drying the ear, a strip of sterile gauze, 1 or 2 cm. (3/8 or 6/8 inch) wide and free from ravelings, is lightly packed into the canal. This is of service only if the opening in the drum is large. The inner end of the gauze should enter the middle ear. The gauze should be folded loosely. Its inner end excites hyperemia, and drains off the discharge at the same time. As soon as it becomes saturated, it should be removed, the ear cleansed, and the drain renewed. This may be once daily or after several days. Instead of plain gauze, the drain may be impregnated with antiseptic to keep it sweet. In appropriate cases, the results of this treatment are good.

The treatment of subacute and chronic otitis media by means of *bacterins* has given encouraging results in many cases. The best results seem to be secured in cases in which the treatment is begun on from the seventh to the sixteenth day of the disease. When there is continuous high temperature, nephritis, or other complications the treatment with bacterins is not to be used. It is of especial value in scarlatinal otitis. Autogenous bacterin is to be used. When two organisms are found a bacterin should be made from each, and each administered separately (see Vaccines, or Bacterins, Vol. I, page 255). This treatment should be used in addition to the other treatments but should not displace them.

Treatment by *suction* is applied through the nose, after stopping the external auditory meatus with a rubber-covered cork. Ten minutes, twice daily, of this treatment is useful.

Injections of *bismuth paste* have proved effective in the hands of some surgeons. It should not be used in acute cases. The paste does not reach the mastoid cells; if they are involved, paste can only be employed after a mastoid operation (see Bismuth Paste, Vol. I, page 305).

The *indications for operation* are present when other treatment fails and discharge persists. In some cases, after the eardrum has perforated, the patient feels comfortable and suffers no inconvenience except the discharge and the deafness. If the discharge persists in a person past middle life the condition should be regarded as serious. Mastoid operation should be done in these patients if the suppuration has lasted for six or eight weeks. This is particularly important in persons over forty-five, even though no other symptoms exist. If facial paralysis develops, operation should be done at once in all cases.

If pus appears soon again after the ear has been washed out, it means that there is a reservoir of pus somewhere in the mastoid, and mastoid operation should be performed.

All cases of chronic suppurative otitis media are dangerous to the patient. All cases, if properly operated upon, may be expected to recover.

Operative Treatment of Chronic Suppurative Otitis Media.—When the above treatments fail to cure the disease an attempt at a more accurate diagnosis should be made. If after several weeks the discharge continues unimproved or but slightly diminished, it means that foci of necrosis are present, and demand to be eradicated. It is not safe to allow the infection to continue because of the danger of intracranial complications. A "running ear" is always a hazard. When the case is first seen by the surgeon, he may be able to determine that there is necrosis which cannot be removed by tentative measures, cleansing and medicinal applications, and he should proceed at once to its eradication. There are other conditions, such as polypi, adhesions, obstruction to drainage from swollen mucous membrane and detritus, which prevent healing and demand more radical measures.

The operative treatment may be applied either (1) through the drum or (2) by a posterior incision turning forward the soft parts and freely expos-

ing the middle ear. The latter is the more useful method. It possesses so many advantages that some surgeons do not bother with the former at all. There are in some cases procedures which may be carried out by the first method.

Operations through the drum should be conducted through the largest speculum that fits the ear and with the best possible light from the forehead of the operator. Incision of the drum membrane has been described, but if the opening is not large it should be still further incised. Polypi will sometimes be found to be the cause of the continuation of the discharge. They may be removed with the curet (Fig. 1005) or with the snare which is similar to the nasal snare (Fig. 1006) excepting smaller in all its parts.



Fig. 1005.—Aural Curet.

In some cases it will be found that the ossicles are necrotic and the mucous membrane of the tympanum granular or polypoid. *Removal of the ossicles and curettage of the middle ear* may be done. A general anesthetic is best, although local anesthesia, combined with adrenalin chlorid, is effective. A strong patient needs no anesthetic. Cocain should be used with caution in the ear as it is quickly absorbed. It is best for the patient that he be in the recumbent position, but most operators use the upright position in order to orient correctly. The first step is to liberate the malleus from the drum membrane. The subsequent steps consist in dissecting out, one by one, the necrosed ossicles, and then curetting the diseased mucous membrane. The removal of the individual ossicles requires experience, patience and gentle-

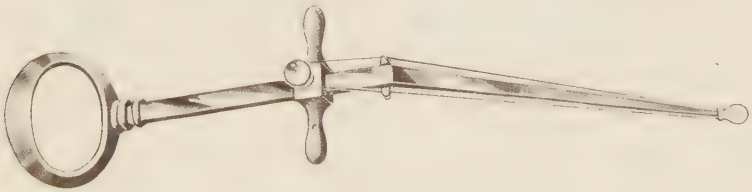

Fig. 1006.—Aural Snare.

ness. It is best that the stapes should not be removed from the oval window unless it is completely necrotic. Curettage of the attic is best accomplished with the angular curet made for that purpose. The outer attic wall may be removed by a bone gouge; this enlarges the canal and gives better room and drainage. After the operation a gauze packing is inserted. The dressing should be changed with precaution to prevent infection. Gauze packing should be continued until healing is secured. Irrigation is not necessary if the discharge remains clean. Purulent infection calls for irrigation. Wide opening of the drum, removal of the ossicles and curettage of the middle ear, will fail to cure if all disease foci are not reached.

The indications for radical mastoid operation for chronic suppurative otitis media are to be considered in cases which have lasted for a year or more.

The cases may be divided into three groups: (1) Cases with cerebral or cerebellar symptoms due to encroachment of the infection or exudate upon the meninges or brain urgently require operation. (2) Cases with caries of the temporal bone, fistulous opening in the mastoid cells, cholesteatoma, continuous growth of polypi, and inflammatory stricture of the external meatus call for radical mastoid operation but are in no sense urgent symptoms. Operation is not a matter of immediate necessity. (3) Operation is indicated in those cases of chronic suppurative otitis media in which no positive symptoms other than the discharge are present and in which the discharge cannot be cured by nonoperative measures.

Radical operation for chronic suppurative otitis media and mastoiditis, by turning forward a flap of soft tissue, is called for when treatment and operation through the drum have failed, when there is necrosis of temporal bone in connection with the middle ear, mastoid disease, narrowing or atresia of

Fig. 1007.—Line of Postauricular Incision for Opening the Mastoid Antrum.

the external auditory canal. It is applicable to all cases of chronic suppuration of the middle ear and mastoid. The *technic* of the operation is as follows:

The operation is similar to that for mastoid disease (page 317).

The patient should be prepared for general anesthesia. The hair should be shaved for a distance of 7 or 8 cm. (3 inches) around the attachment of the auricle in women, and in men and children the whole side of the head should be shaved and the rest of the hair cut short. The pre-operative cleansing should involve the meatus and auricle as well as the scalp. The anesthetic is important. Ether increases the bloody oozing and obscures the field of operation, unless given by a highly skilled anesthetist. The patient lies with the affected side upward. A curved incision is made from the tip of the mastoid process, upward behind the ear, 0.5 to 1 cm. (3/16 to 3/8 inch) from the auricular attachment, and ends just above the upper attachment of the auricle (Fig. 1007). It passes through the periosteum,

which, with the overlying soft tissues, is elevated from the bone, and hemostasis secured. The flap is elevated with the cartilage of the canal, until the posterior, inferior, and upper walls of the canal are exposed as far inward as the drum. With a sharp bone gouge or chisel (Fig. 1008) the posterior



Fig. 1008.—Chisels for Mastoid Operations.

wall of the canal is cut away in layers, and the mastoid antrum opened (Fig. 1014). The antrum being opened, the rest of the posterior wall of the canal is cut away, the inner end of the upper wall, and the outer wall of the tympanic cavity (see Bone-cutting Instruments, Vol. I, page 688). The cutting away of the external wall of the tympanic cavity, which is the inner end of the upper wall of the external meatus, should be carefully done. The semicircular canal and the facial nerve may be injured if the cutting away of the posterior wall is carried too low. The cranial cavity may be entered through the roof of the tympanum if the roof of the inner end of the meatus is cut too high.

It is for these reasons that the antrum should be opened early and then the well between the antrum and the middle ear cavity cut away until a free communication is secured (Fig. 1009). A good view is then obtained. The ossicles may be removed, and rough edges of bone smoothed. An occasional packing with adrenalin gauze will control the bleeding. All necrotic areas should be curetted.

Fig. 1009.—Mastoid Operation.

The antrum has been exposed and its outer wall removed. The wall between the antrum and external auditory canal is being removed. The inside of the mastoid cavity is left smooth and even.

There are certain precautions to be observed. As the wall between the antrum and tympanum is cut away the roof of the semicircular canals comes in view. The facial nerve lies just below the horizontal semicircular canal, whence it passes backward, downward and outward to its exit. It passes close to the meatal canal in its inner and posterior wall. The inner third of the posterior wall of the meatus must be approached with care; its upper third may be cut away, but its lower two-

thirds should slope upward and inward to the roof of the horizontal semicircular canal. The floor of the middle ear is slightly lower than that of the meatus; the step should be removed with the sharp curet. Here the dome of the bulb of the jugular vein rises in the floor of the tympanum. It may encroach upon the meatus. Care should be taken to avoid it. If wounded, gauze packing controls the bleeding. The carotid artery may be wounded by careless curetting of the Eustachian tube.

The upper end of the Eustachian tube should be closed by curetting its orifice. The disease may be found confined to the middle ear alone. Commonly the antrum also is involved. It may embrace all of the cells of the mastoid, in which event the mastoid should be cut away until all of its cells are removed. Necrosis of the roof of the antrum or tympanum calls for removal of the diseased bone. Even without necrosis there may be infection within the cranium. The surgeon should not hesitate to expose the lateral sinus or the dura mater over the roof of the tympanum. Many operators, as a routine measure, remove the thin shell of bone between the ear cavity and the dura.

Before operation, the surgeon should have assured himself whether symptoms of *labyrinthine disease* are present. (Vertigo is the prominent sign.) Whether they are or not, the wall of the horizontal semicircular canal should be examined for perforation and discharge of pus; likewise the oval window. A suppurating sinus may communicate with the semicircular canal. Labyrinthine suppuration is apt to be associated with granulations about the oval window. Free drainage should be secured by removing the bony wall of the labyrinth. The lower wall of the horizontal canal should be left to protect the facial nerve. If the involvement is slight, but a small area of the labyrinth need be exposed; if it is extensive the whole labyrinth should be destroyed. The facial nerve lies above the oval window. In order to drain the labyrinth, the window should be enlarged downward and forward.

Having removed all dead bone and foci of disease, smoothed off rough edges, and secured hemostasis, the wound should be closed in such a way as to secure the early covering of the denuded bone with a layer of skin. If the wound is simply sutured and packed, skin must grow in slowly from the periphery. It is, moreover, desirable for the sake of subsequent cleanliness and inspection to provide an enlarged meatal opening. These ends are secured by plastic operation. The method of *Körner* is as follows:

The entire thickness of the fibrocartilaginous meatus is cut through, at its posterosuperior aspect, from the tympanum outward to the concha. A second similar incision is made at the postero-inferior aspect parallel with the first and about 6 or 8 mm. ($\frac{4}{16}$ or $\frac{5}{16}$ inch) from it (Fig. 1010). This produces a tongue-like flap, attached only at the concha, which is destined to be applied to the posterior wall of the mastoid wound. The cartilage and connective tissue of the meatus are then dissected entirely away, leaving only the pliable skin of the meatal tube. The flap is then fixed by a few sutures into the mastoid excavation. If possible its tip should be sutured to the periosteum of the posterior border of the wound. The loose meatal skin is spread out over the meatus and extended as far into the tympanic cavity as it will reach. This plastic procedure, by removing the cartilage of the meatus, greatly enlarges the external auditory canal and partly covers the bony excavation with skin. If the cavity is sufficiently clean, a skin graft may be placed at once in the tympanic cavity. If there is some question about the cleanliness of the wound the grafting may be deferred for a week (see Skin Grafting, Vol. III). The graft should be pressed in so that it adheres everywhere to the raw surface. A hole may be snipped in its center to per-

mit the escape of air which might prevent pressing it down into place. The postauricular wound is then closed by sutures (Fig. 1011). A light packing of gauze is pressed smoothly into the greatly enlarged meatus to keep the skin against the bone. Packing too tightly causes sloughing of the flaps; packing too loosely causes failure of adhesion of the flaps; the latter is the least objectionable of the two; a medium degree of pressure should be secured. Over all is applied a copious gauze dressing, held in place by a head bandage (see Bandages, Vol. III).

In cases in which a larger excavation has been made, as in complete removal of all the mastoid cells, or in case of exposure of the dura mater, larger flaps of skin should be secured by the method of Panse, which is as follows:

An incision is carried through the whole thickness of the middle of the posterior wall of the soft tissues of the external auditory canal from the tympanum outward well into the concha. The outer end of this incision is crossed at right angles by a vertical incision about 12 mm. (½ inch) long,

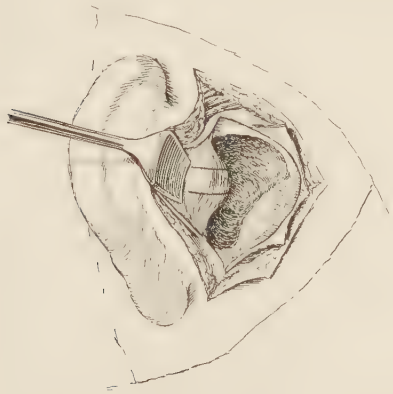

Fig. 1010.—Operation of Körner for Closing Mastoid Wound.

The mastoid has been excavated. Two parallel incisions are made through the cartilaginous posterior wall of the external auditory canal.

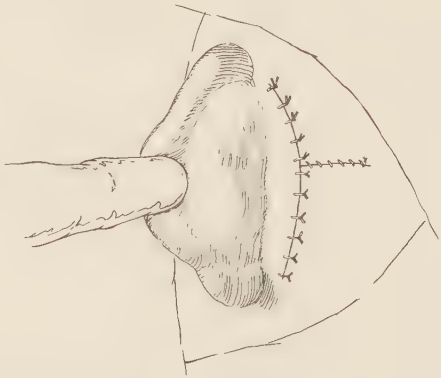

Fig. 1011.—Radical Mastoid Operation Completed.

Drainage is secured through the enlarged external auditory meatus.

making a ⊢. These cuts involve the whole thickness of the concha (Fig. 1012). The length of the first incision, as well as the second, must depend upon the size of the cavity to be filled. The vertical incision is best given a slight curve. The cartilage should then be dissected out of the canal and the flaps, in order to make the flaps more pliable and the canal larger. The flaps should be pressed into the wound, their denuded surfaces lying against the denuded bone, and sutured to the periosteum and skin (Fig. 1013). The post-auricular wound may then be closed, and a gauze packing inserted into the meatus to hold the flaps secure.

Skin grafting may be added to this operation to cover the tympanic surface, after thorough sterilization of the wound. The grafts are best held in place by small tampons impregnated with soft paraffin, containing 1 per cent. phenol. The tampons may be softened with hydrogen peroxid on the fourth day and removed. Granulations appearing at the edges of the grafts should be suppressed. If time does not justify or if the presence of infection forbids plastic closure of the wound, it may be packed with gauze

and drained. It may be allowed to heal by granulation or after a week it may be again opened and the plastic operation done.

Operation for chronic mastoiditis does not differ essentially from the above. A few modifications are occasionally necessary. The incision should be carried slightly lower than the tip of the mastoid process. The posterior lip of the wound should be elevated and retracted. The muscles attached to the process may need to be cut away with scissors or knife. If the first incision is not adequate a second incision may pass backward at right angles to it. Free exposure of the surface of the skull is essential.

After securing hemostasis the surgeon should take account of the landmarks. The posterior root of the zygoma passes backward horizontally above the external meatus. This ridge is on a level with the floor of the middle fossa of the cranium. Removal of bone above the ridge will expose the dura mater. If the ridge cannot be found a line just above the meatus passing backward and slightly upward may be taken instead. The post-meatal triangle should be had in mind (page 301).

The antrum should be open first. A gouge is the best instrument for this purpose. The cutting should be directed toward the meatus. Thin

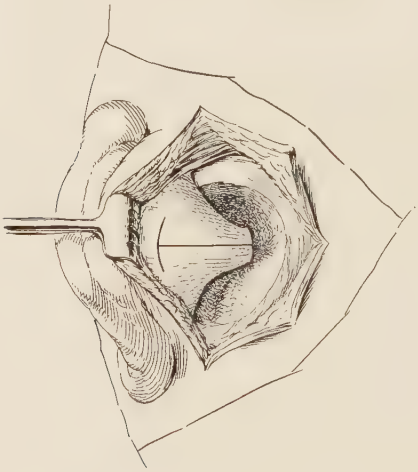

Fig. 1012.—Formation of Flaps for Lining Mastoid Cavity.

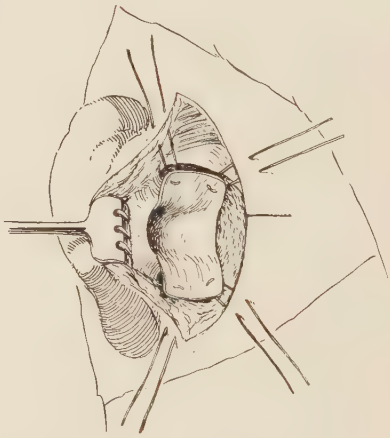

Fig. 1013.—Flaps for Lining Mastoid Cavity are Sutured in Place.

slices of bone are cut away, after each cut the surface being observed. After opening the antrum, bone-cutting forceps may be used. A well-curved probe is of service in exploring cavities. If the examination or the previous symptoms show that the cells of the tip are involved, the covering of the rest of the mastoid cells is removed. A small sharp curet will discover any areas of softened bone or unopened cells. If the disease has resulted in perforation of the drum membrane or if middle-ear infection is present, the wall between the antrum and the tympanum should be cut away. This is the step of the operation which threatens the facial nerve and the external semicircular canal. The key to the situation is the aditus ad antrum (the opening between the middle-ear cavity and the antrum). If a probe or a guide is passed through this opening, the bone may be cut away freely external to it, the aditus representing the inner limit of the cutting (see Operation for Chronic Suppurative Otitis Media, page 311). This means removal of the posterior wall of the external meatus.

Removal of the external wall of the attic is to be done if the attic is diseased. Remaining drum membrane or necrotic ossicles may be removed. It is usually best to leave the stapes, and, accordingly, the incus should be disarticulated from it.

The object of the operation is to remove dead bone, other necrotic tissue, granulations, and polypi, and to secure drainage. The amount of bone to be removed must vary with each case. After opening the antrum, it may be necessary to open only the aditus and the attic of the middle ear, or all of the pneumatic cells of the temporal bone may require to be drained. While one part is being explored the other should be packed with gauze to check bleeding. Rough edges should be smoothed, and the wound should be closed as above described.

Operation for acute mastoiditis is carried out the same as that for chronic mastoiditis, except that the wall of the meatus is not cut away unless

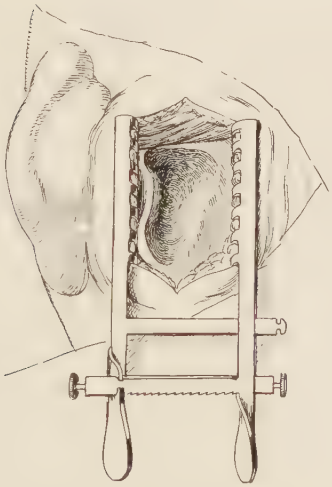

FIG. 1014.—OPERATION FOR ACUTE MASTOIDITIS.

The antrum has been opened, its outer wall removed, and the cavity smoothly excavated. Posteriorly is seen the rounded projection of the thin wall of the sigmoid sinus.

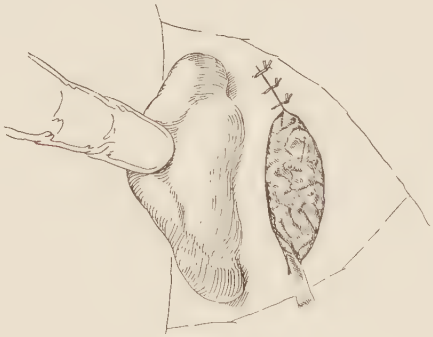

FIG. 1015.—OPERATION FOR ACUTE MASTOIDITIS.

Wound partly sutured and lightly tamponed with gauze.

there is destructive disease of the middle ear. The soft tissue, therefore, is not to be retracted from the external meatus, but only the bone of the mastoid region exposed. The overlying soft tissues are often edematous and pus can be traced, oozing from sinuses. The bone is often so soft that the mastoid cells can all be curetted away without using the chisel. Overhanging bone should always be cut away so to leave a bowl-shaped excavation. After exposing and cleaning out the diseased cells and securing hemostasis by pressure, the aditus ad antrum should be gently curetted in an outward direction with a small sharp curet in order to insure a free communication. The curet should not penetrate the tympanic cavity far enough to injure the ossicles, the drumhead, or other structures. It will sometimes be found that air cells in the posterior root of the zygoma are infected; these should be looked for and cut out. After irrigating the wound to remove all débris

an inspection should be made for other foci of infection. A communication may be found leading into the middle fossa of the skull above or into the sigmoid groove behind. If pus is oozing from such openings they should be enlarged, great care being taken not to wound the dura mater. If the dura is found covered with plastic lymph, it should be exposed, but not removed, as it forms an effective barrier against infection. Such plastic deposit should be removed only in case the dura or sinus is to be opened.

It will be seen that in this operation the bone between the antrum and middle ear and that of the meatus has not been cut away (Fig. 1014). Suppuration within the middle ear is usually present, but by providing good drainage through the *aditus ad antrum*, it may be expected to heal without great damage to the function of hearing. The wound should be packed with gauze, the packing beginning at the opening into the tympanic cavity, and a couple of sutures passed through the periosteum and scalp at its upper end (Fig. 1015). The external auditory meatus should be cleansed, and packed so as to press back against its bony wall the soft tissues which may have been loosened. A copious dressing of gauze should be placed over the wound, care being taken to see that the pinna is not confined in a painful position.

The first *change of dressing after mastoid operations* need not be done until the fifth day, provided the patient is comfortable, the temperature persistently below 100°F., and the discharge slight. If there is persistent discomfort, if the temperature suggests considerable septic absorption, or if blood, serum or pus saturates the dressing, the wound should be inspected.

After removing the gauze packing the wound should be found lined with intensely hyperemic granulations. Irrigation is not called for. The meatus should be dried and repacked. The subsequent treatment of the mastoid opening is that of a granulating wound. Dressing should be done every day or every second day. New areas of necrosis should be watched for, and curetted away when discovered. The skin should not be permitted to close over the opening until it has become filled by granulations from the bottom.

The patient should be well enough to be out of bed a week after the operation and in ten days to go about. A month to six weeks is required for the complete healing of the wound.

In *operations upon babies*, it should be remembered that under two years of age the antrum is the only mastoid cell. The tympanic ring should be exposed as a guide, and the antrum opened just behind and slightly above it. The bone is very thin, and the utmost care should be taken lest the cranium be opened by using too much force.

Intracranial Complications of Infections of the Temporal Bone.—*Infections and thrombosis of the venous sinuses* usually require operation. The patient is prepared as for mastoid operation except that the whole side of the head should be shaved and the neck should be included in the preparation. The mastoid cells are removed as above described. Often the infected opening through the bone leading to the inside of the skull can be found. The bone between the mastoid cavity and the sigmoid sinus should be removed, and at least 2.5 cm. (1 inch) of the vessel exposed. This exposure should be free. It may be necessary to continue the removal of bone as far backward as the torcular or downward to the jugular bulb. The first opening through the bone may be made with a sharp chisel, and the wound enlarged with bone-cutting forceps. An extradural abscess may be encountered as a guide. The thrombosed vessel being exposed, before it is opened the wound should be thoroughly cleansed and all of the utensils of operation cleansed or sterilized as though another operation were to be begun (Fig. 1016).

If an operation for mastoid disease has already been done, and the wound healed, the incision for exposure of the sinus should be made posterior to the old scar and the scar elevated. If the incision is carried down through the scar, the knife may open the sinus inadvertently. The jugular should be ligated in the neck before opening the sinus for the removal of a thrombus. (For the technic of the further treatment, see Sinus Thrombosis, page 70).

Intracranial abscess of otic origin requires operative relief. The operation should begin as for mastoid disease. The antrum and adjacent cells should be widely uncovered, and if tympanic suppuration is present, the middle ear should be freely opened. This removes the original focus of infection, gives access to the cranial cavity, and often enables the surgeon to discover the opening in the bone through which the infection passed into the cranium. If no guide is found, the roof of the antrum should be removed. Infection of the extradural space will often be discovered. An *extradural abscess* evacuates itself through the antrum. After the pus has been removed and the dura dried, further examination should determine whether a subdural abscess is present. When the diagnosis is not clear, the wound may be packed and further study of the case made.

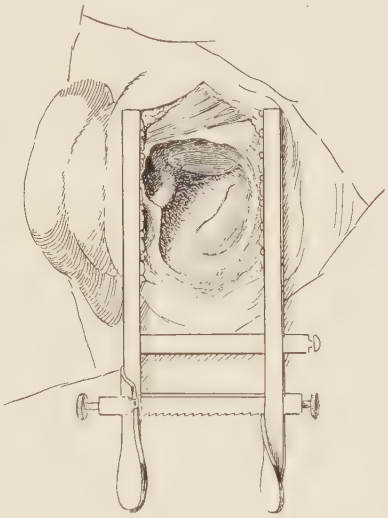

Fig. 1016.—Operation for Mastoid Disease with Intracranial Infection.

Showing dura mater above bulging through the roof of the antrum and sigmoid sinus exposed below.

If the signs of *brain abscess* are sufficient an attempt to evacuate it at once should be made. If the dura bulges into the bony opening, and especially if it is dark or edematous, it may be touched with iodin or phenol and alcohol, and an aspirating needle passed into the brain. Pus being found, the brain should be incised for its evacuation and a drainage tube inserted. In cases in which there seems to be a dangerous infection in the tympanomastoid wound, the abscess should be opened through a clean area in the temporal region (see Abscess of the Brain, page 73).

Chronic Nonsuppurative Otitis Media.—The treatment of this disease by nonoperative measures has met with little success. A small proportion of cases have been helped by operation. In properly selected cases a fair measure of success may be expected. Incision and excision of the membrane of the drum have been practised with temporary improvement in hearing. Removal of the ossicles has given good results in the hands of some.

The *treatment of advanced tympanic deafness* requires the patient skill of the otologic specialist. Inflation of the middle ear by air, driven through the Eustachian catheter, has little or no value. Good hygiene is most important. If a chronic inflammation of the Eustachian is present, the best treatment consists in cocainizing the entire length of the tube and injecting it with 5 or 10 per cent. silver nitrate solution or 25 or 50 per cent. argyrol. Removal of the ossicles of the ear is helpful in cases in which the bones are bound by adhesions.

Labyrinthine Disease.—*Labyrinthine hemorrhage* (*Ménière's disease*), if the patient is seen early in the attack, should be treated by measures to

relieve cephalic congestion. The patient should be kept quiet with the head elevated and hot applications to the lower extremities. Constriction of the limbs to confine the blood by producing venous obstruction may be of

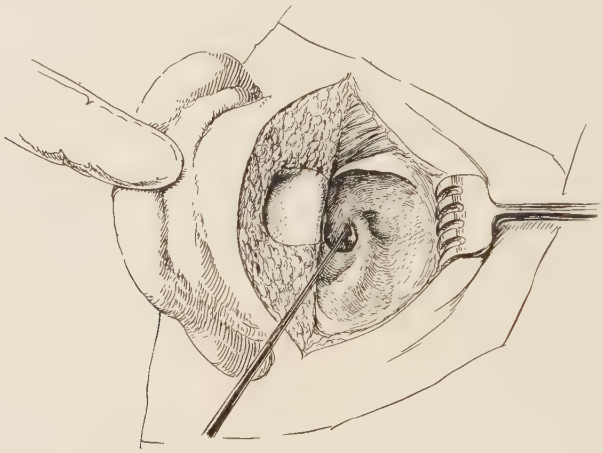

Fig. 1017.—Operation for Suppurative Infection of Labyrinth.

The semicircular canals have been ablated. Posterior drainage has been provided for the vestibule. The auricular flap has been sewed in place. The probe is seen passing upward and backward through the enlarged oval window into the vestibule. The bridge of bone contains the facial nerve.

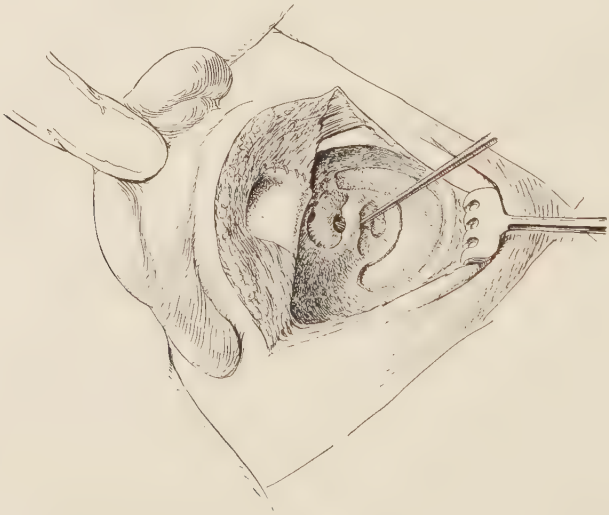

Fig. 1018.—Operation for Middle-ear Suppuration with Dural Infection.

The mastoid has been opened and its inner wall removed, exposing dura mater. The vestibule has been drained. The probe is seen passing forward and outward beneath the bridge of bone containing the facial nerve. The probe lies in the canal made by opening the first and second turns of the cochlea.

help. The blood is ultimately absorbed, but the lost hearing is rarely restored.

Labyrinthine and perilabyrinthine involvement, following middle-ear suppuration, are operated upon as follows: The curved incision behind the

ear is made and the flap containing the external ear is turned forward exposing the bony meatus. The horizontal semicircular canal is opened with a small gouge at its most prominent convexity. This opening is enlarged downward and backward until a probe can easily enter the vestibule. The facial nerve lies just below the horizontal semicircular canal. The cochlea is then opened by removing the small bridge of bone between the oval and round windows. A probe may now be passed into the horizontal semicircular canal downward and forward and then outward beneath the facial ridge, and coming out at the middle ear (Fig. 1017). Iodoform gauze should be packed lightly into the cochlea, semicircular canal and middle ear. Ten days later skin grafts may be applied to the mastoid cavity. This is the method used by E. B. Dench.

In cases in which pronounced constitutional symptoms show approach of the infection to the meninges, the operation of Neumann is to be preferred. The radical mastoid operation is performed, and the lateral sinus is exposed in the posterior part of the wound. The dura in the middle cranial fossa is also exposed. The dura is gently separated anteriorly from the overlying bone by means of a probe or elevator. The bone is then removed anteriorly, care being taken not to wound the dura. Presently the posterior semicircular canal is opened. The openings from the superior and the horizontal canals next come into view as more bone is taken away. A fine probe is then passed into the upper opening and caused to pass into the vestibule. The opening into the vestibule is then enlarged with the gouge. The cochlea is drained as described above (Fig. 1018).

If there is infection of the dura the dura should be separated from the bone still further inward, and a wider exposure made by removing still more bone until the sheath of the auditory nerve is reached. Usually a meningitis secondary to labyrinthine disease is found in the subtentorial space near the auditory nerve.

THE SPINE

Anatomic Considerations.—The spinal cord extends from the skull to the second lumbar vertebra, below which point the spinal canal is occupied by the bundle of nerves destined for distribution to the lower abdomen, pelvis and lower extremities. The nerve-roots do not correspond with individual peripheral nerves but with parts of several nerves; and for this reason division of a root does not cause *complete* paralysis of a muscle or sensory area. Complete paralysis means an extensive lesion. The trophic centers of the motor fibers are in the anterior horn of gray matter. The trophic centers of the sensory fibers are in the ganglia located on the posterior roots. The fibers of the cord itself lack neu-

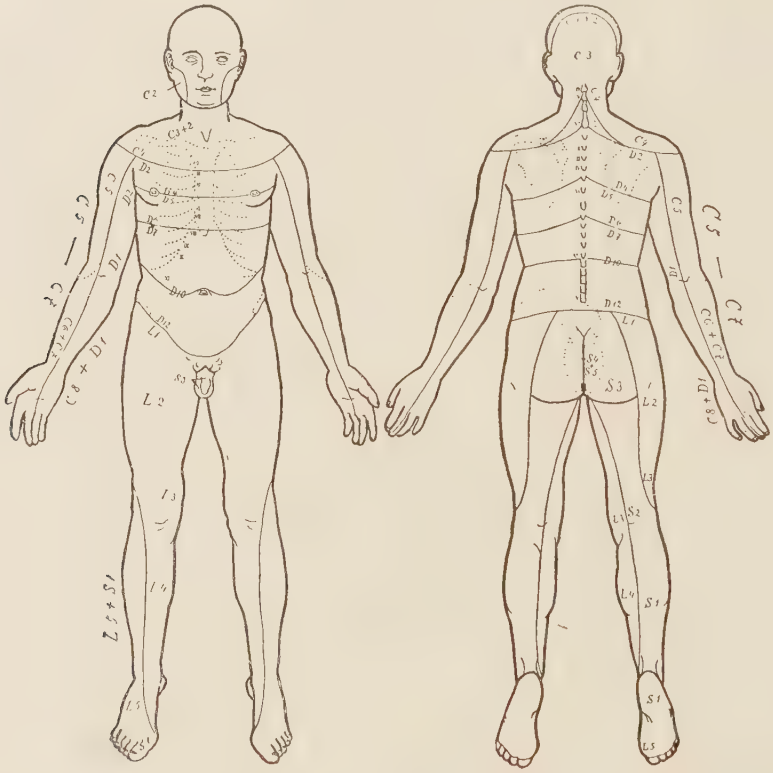

Fig. 1019.—Sensory Distribution of Posterior Spinal Roots. (*According to Seiffer.*)

rilemma sheath; and when the nerve elements of the cord are divided they are not capable of regeneration. So far as is known, when the cord is divided, reunion and the reëstablishment of nerve impulses is impossible. It is futile, so far as known, to attempt suture of the wounded spinal cord.

Between the dura mater, lining the spinal canal, and the pia mater, covering the cord, is the arachnoid space, filled with cerebrospinal fluid, communicating with the ventricles of the brain, and serving to preserve the cord from jar and friction. The structure of the spine is peculiar because of its numerous and complicated joints and because of the strong ligaments which embrace the bones on every side. The relations of the cord to its periphery are shown in Figs. 1019 and 1020, and in the accompanying table.

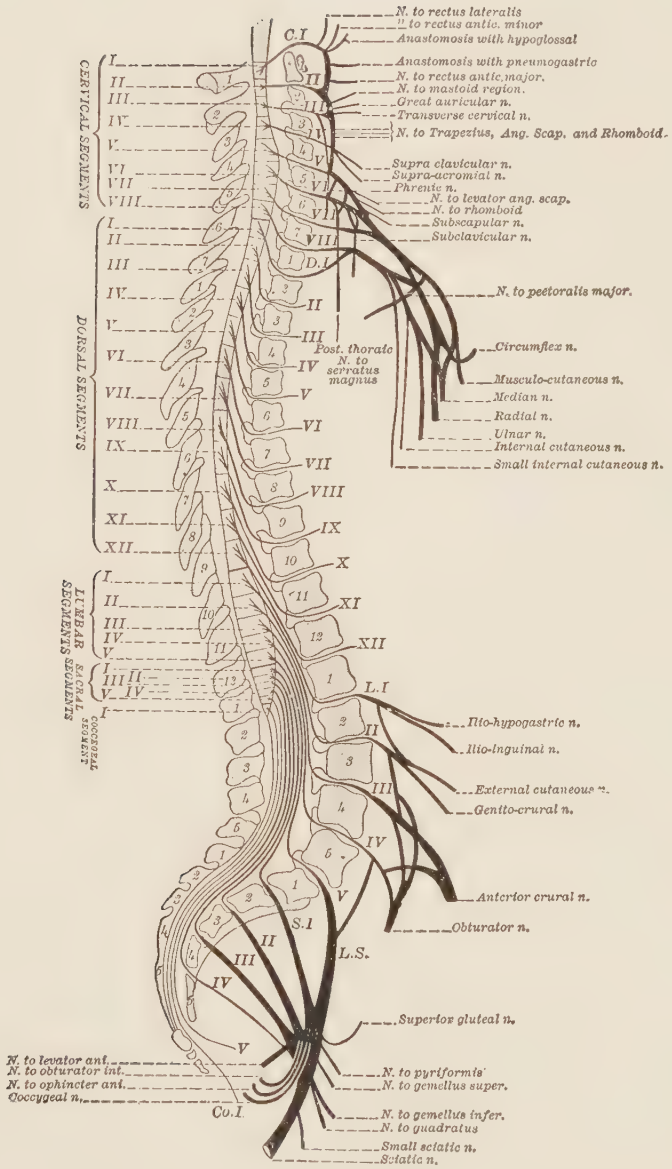

FIG. 1020.—RELATIONS OF THE NERVE ROOTS TO THE VERTEBRÆ. (*According to Déjerine and Thomas.*)

Segments.	Muscles.
C. IV.	*Diaphragm.* *Supraspinatus.* *Infraspinatus.* (*Teres minor*[?].) Biceps. Deltoid. Supinator longus. Rhomboids. Scaleni.
C. V.	*Biceps.* *Brachialis.* *Deltoid.* *Supinators.* Spinati. Pectoralis major. Serratus magnus. Rhomboids. Scaleni. Teres minor.
C. VI.	(*Subscapularis.*) *Pronators.* (*Teres major.*) (*Latissimus dorsi.*) *Pectoralis major.* *Triceps.* *Serratus magnus.* Biceps. Brachialis. Extensors of wrist and fingers.
C. VII.	*Extensors of wrist and fingers.* Triceps. Flexors of wrist (?). Pronators. Pectoralis major. Subscapularis. Latissimus dorsi. Teres major.
C. VIII.	*Flexors of wrist and fingers.* Interossei. Extensors of thumb (?).
D. I.	*Interossei.* *Other intrinsic muscles of hand.* Extensors of thumb.
L. I.	Abdominal muscles. Iliopsoas. Cremaster. Sartorius.
L. II–III.	*Flexors and adductors* (III)* *of thigh.* *Sartorius* (III).*
L. III–IV.	Extensors of thigh. *Adductors of thighs* (III).* *Abductors of thigh* (IV).* *Quadriceps femoris* (IV).* Tibialis anticus.
L. V.–S. I.	*Flexors of knee* (L. V.).* *Glutei* (S. I–II).* *Calf muscles* (S. I–II).* External rotators of thigh. *Peronei* (S. I–II).*
S. I–II.	*Calf muscles.* (*Glutei.*) *Peronei.* *Intrinsic muscles of foot.* (*Long extensors of toes and foot.*)° Erector penis (II–III).*
S. III–IV.	*Perineal muscles* (III).* *Ejaculator muscles* (III.)* *Bladder* (IV).* *Rectum* (IV.)*
S. V.	Levator ani. Sphincter ani.

* Bracketed numbers refer to the segment in Thorburn's table.
° Dorsal flexion of ankle.

Sprains of Spinal Joints.—The treatment should be carried out upon the same principles as are applied to sprains of other joints (see Sprains, Vol. I, page 650). Immobilization may be secured by rest in bed, or, if this is not sufficient, by means of a plaster-of-Paris support such as is used for spondylitis. The early pain may be relieved by hot applications. Stiffness and swelling may be relieved, after the acute symptoms have subsided, by massage.

Contusion and Concussion of the Spinal Cord.—The shock attending these injuries is often severe and is the chief condition demanding treatment (see Shock, Vol. I, page 213). Whatever is done, rest is an essential. If there are local or general symptoms the spine should be treated locally as for sprain or contusion. The general treatment should secure rest of both body and mind (see Traumatic Psychoses, page 102).

Extrapial Hemorrhage Compressing the Cord.—Usually this condition is associated with fracture, dislocation or other severe traumatism, and the treatment must be directed to the causative lesion. When due to local disease or hemorrhagic diathesis, if external to the dura, the latter may be caused to press upon the cord. In such a case the recognition and treatment are the same as for extradural tumor. Hemorrhage into the arachnoid space diffuses itself with the cerebrospinal fluid. Unless the source of the bleeding is known, it is difficult to locate it. The bleeding stops when the pressure within the spinal canal becomes sufficiently raised. The hope of treatment is to identify the site of the hemorrhage. If that can be done, it may be exposed and the bleeding checked. If the arachnoid space is opened while hemorrhage is still going on, and the bleeding point is not found and controlled, the condition is only made worse, because when the pressure is relieved the bleeding increases.

Hemorrhage into the Cord (Hematomyelia).—Whether traumatic or a spontaneous apoplexy, localization of the hemorrhage is usually not difficult, but even then the question of the expediency of operation is a difficult one. Most cases are best kept quiet, and it will be found that the paralyses almost or entirely subside. Operation is often militated against by the extension of the hemorrhage for a long distance in the length of the cord. When the clot is distinctly localizable, and the pressure symptoms are serious, the lesion may be treated the same as a tumor, and the clot removed by laminectomy. But it should be borne in mind that when hemorrhage has ceased, from that time on, without operation, the tendency is toward improvement.

Stab Wounds and Bullet Wounds of the Spine.—In stab wounds the important thing is to prevent sepsis. The wound should not be probed. It should be covered with an antiseptic dressing, and the patient kept quiet. Operation is indicated for the same conditions as in compound fracture—bone or clot pressing upon the cord, which can be removed. Any foreign body, such as a broken knife blade, should be removed. Infection developing in the wound tract and involving the meninges demands free opening of the wound, the removal of splintered bone, and the uncovering of the meninges by laminectomy.

Bullet wounds should be treated the same as above. When a bullet is lodged in the spine and does not encroach upon the cord, it may be removed, but its removal is not necessary (see Bullet Wounds, Vol. I, page 222). If the bullet or any other foreign body or splints of bone occupy the spinal canal and press upon the cord, they should be removed. The operation should not necessarily follow the path of entrance, but after a careful localizing examination, supplemented by the *x*-ray, laminectomy (see page 339) should be done at the site of the foreign body. Later operation may be required for the removal of compressing exudate.

In cases of bullet wounds of the spine, if the symptoms point to complete transverse lesion of the cord, operation is not to be advised unless the *x*-ray shows that the bullet or a fragment of bone lies in such a position that it may be responsible for pressure upon the cord. If the lesion of the cord is incomplete the cord should be exposed by laminectomy to remove the foreign body or splinters of bone. Even when no compressing body may be removed, the laminectomy as a decompressing operation may be expected to relieve the symptoms which are due to edema. In the event that suppuration along the track of the bullet is present the danger of infecting the cord by exposing it should not be incurred.

In any case of injury to the cord the laminectomy may reveal edema of the meninges or fluid compressing the cord, and simple incision may give relief.

Traumatic Spondylitis (Non-tuberculous, Rarefying Osteitis).—The local treatment is similar to that of tuberculosis of the spine. Gentle manipulation under anesthesia should be applied to correct recent deformity. Extension, immobilization and recumbency are the essential measures in the early treatment. Later a jacket is required, to be followed by massage during the later stages. Repair is slow, and support and immobilization should usually be continued for at least six months.

Osteomyelitis of the Spine.—As soon as the disease is recognized it should be exposed and drained (see Osteomyelitis, Vol. I, page 469). Necrotic bone should be removed. In the cervical region the operation is done posterior to the sternomastoid muscle. In the dorsal region, excision of transverse processes and the adjacent ribs permits access to the bodies. The lumbar vertebræ may be approached through an extraperitoneal incision such as is made for exposing the kidney.

A transverse incision at one side of the median line should expose the muscle. This incision should be fully 15 cm. long. The heavy mass of spinal muscles is crossed transversely by two parallel lines of hemostatic sutures, divided between, and the muscles retracted upward and downward. The laminæ and transverse processes are thus exposed, and the transverse process of the diseased vertebra is removed with rongeur forceps. In the dorsal region the inner end of the rib also is resected. The nerves should be protected from injury. The psoas muscle is separated from the body of the vertebra by means of an elevator, and retracted by means of a long retractor. This exposes the side of the body which may be penetrated by a burr or gouge, and the diseased area opened and drained. This is practically the operation described by L. Mayer (Jour. Am. Med. Assoc., March 2, 1918). The spinal nerves should be watched for and spared from injury. A jacket, brace or splint should be applied as in tuberculosis. The spine should be held in slight lordosis until the body of the vertebra becomes strong.

Typhoid Spondylitis.—Rest, recumbency, immobilization and artificially induced hyperemia are the essentials of treatment. The patient should be kept in bed or on a frame stretcher until the acute condition has subsided. Hot applications or other hyperemic treatment is of service at the beginning. A brace or jacket should be applied as soon as the acute stage is passed. At least six months are required for recovery.

This disease should be watched for in typhoid cases. Pain in the back in the third or fourth week of typhoid should be met by immobilization of the spine at once. An autosensitized autogenous vaccine should be given. The culture may be gotten from the blood, urine or feces. If an autogenous vaccine cannot be made, stock vaccine should be used. By applying a light jacket of leather or felt the pain is relieved. Abscess is prevented. The pain must be met by hot applications. Dry air or the actual cautery are to be employed for the relief of the radiating pains.

Anterior Poliomyelitis.—This disease, although medical in its acute stage, leaves paralyses which are amenable only to surgical treatment, and therefore is entitled to surgical consideration. The treatment is best carried out with injections of specific serum. The mortality has been decidedly lowered by serum treatment. It seems to possess the power of preventing paralysis when given early. The serum is injected intraspinally in small doses and at the same time intravenously in larger amounts.

Spondylitis Deformans.—The general treatment is that described for arthritis deformans (Vol. I, page 661). Massage and hot baths give comfort. Immobilization and support by means of a brace or jacket are of service during the progressive period of the disease. Later the stiffened spine may

be helped by vibratory massage and painless passive movements. Attempts to break up adhesions under anesthesia to increase the suppleness of the spine seem to do more harm than good. Support is no longer needed when the progress of the disease has stopped; although the comfort of the patient may require its continuance for an indefinite period.

Non-tuberculous Abscess of Spine.—Whether arising from osteomyelitis or other non-tuberculous disease, the abscess should be opened, necrosed bone removed and drainage established (see Abscess, Vol. I, page 251). Abscess connected with the bodies is reached the same as tuberculous abscess (see page 335).

Tuberculosis of the Spine (Tuberculous Spondylitis, Pott's Disease).—The general treatment is the same as that for tuberculosis elsewhere (see Tuberculosis, Vol. I, page 276). Local treatment is aimed to secure the best possible immobilization, to hold the vertebræ in good position preparatory to the inevitable ankylosis, and to relieve as much as possible the softened bones from superimposed weight. Immediate, forcible and complete correction is no longer used. Gradual correction of the deformity is best.

Treatment by recumbency is usually employed in children under five years of age, in all very acute cases, in cases with much pain, in cases which have not done well in the upright position, in cases with abscess, paralysis or threatened

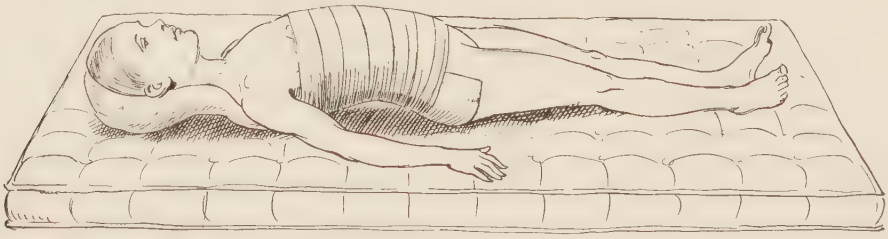

Fig. 1021.—The "Reclining Plaster-bed," in the Treatment of Tuberculosis Spondylitis.

paralysis, in dangerously high cervical disease, and in cases with pronounced lateral curvature. For all classes of cases it gives more effective rest to the diseased parts. Its objection is that it confines the patient closely. Horizontal fixation should be in a position of overextension, thus placing the pressure upon the articular processes and taking it from the bodies. In the adult, horizontal fixation is not so essential because the spine is more rigid and can be held by appliances which do not necessitate confinement in bed. Moreover, young children tolerate recumbency better than adults.

For securing *horizontal fixation* my former teacher in Vienna, Lorenz, made a "reclining plaster-bed." The patient was placed upon its abdomen with the shoulders and pelvis slightly elevated thus giving an increased extension of the spine. The body was covered with a tricot shirt and a piece of cloth was placed on the back of the head and neck. Several layers of crinolin, impregnated with plaster-of-Paris, cut in such a shape as to extend from the top of the head to the middle of the sacrum and wide enough to embrace the posterior half of the head, neck and trunk, were rubbed together with water. This cuirass was laid upon the patient, molded so as to conform to its posterior aspects, and held in place by a few turns of gauze bandage until it became hard. The child could then be turned over and was found to lie in a well-fitting and comfortable bed, in which it could be carried

about and deposited wherever desired. The use of this simple apparatus gives much satisfaction (Fig. 1021). In high dorsal disease a jury-mast may be attached to this splint and extension upon the head secured (Fig. 1022).

Treatment upon the tubular frame of Bradford (see Vol. I, page 666) is most in favor in America. The frame should be about 10 cm. (4 inches) longer than the child.

The width of the frame should correspond to the distance between the two shoulder joints. The covering of the frame should be tight. Strong canvas, laced across and protected in the middle with rubber cloth, is the best covering. Two pads of felt should be sewed to the canvas on either side of the diseased bone so that the disease shall be lifted away from the canvas and sustain no pressure. These pads should be about 15 cm. (6 inches)

Fig. 1022.—Reclining Plaster-bed in the Treatment of High Tuberculous Spondylitis.

Jury mast added for high dorsal or cervical disease.

long and 2.5 cm. (1 inch) thick. The child wearing only an undershirt is fixed to the frame by a broad band about its trunk and bands about the legs.

An opening in the canvas, back of the anus, covered with a separate strip allows of defecation and urination without taking the child from the frame. This frame may be carried about, and the child deposited wherever desired. As the patient becomes accustomed to the frame, the lateral tubes should be bent backward in order to give overextension to the spinal column (Fig. 1023). The frame may be made with sliding tubes or a turnbuckle so that its length and width may be regulated. Once daily, the fixation should be liberated and the child gently turned on its side to have its back washed and rubbed with alcohol and the underclothes smoothed out.

In disease of the upper dorsal or cervical region a chin and occiput halter is applied. Extension may be made by connecting this with a weight and pulley; but what is still better is simply to fasten it to the top of the frame and secure traction by raising the upper end of the latter. Thus the weight

of the body makes the extension and the patient is in a better position to see what is going on about. Fixation to prevent lateral motion and rotation is also desirable in cervical disease. In disease of the upper parts of the spine the legs need not be confined, but in disease in the lumbar region the legs should be fastened. The curvature in the frame should correspond to the site of the disease. In upper dorsal and cervical disease, it is desirable that the head should be dropped well back so as to insure extension. Flexion of the thigh from psoas abscess should be met by continuous traction upon the leg in the flexed position, gradually lowering the leg as the disease improves.

Fig. 1023.—Frame Bent to Secure Overextension of Spine.

Ambulatory treatment is carried out with jackets of stiff material, such as plaster-of-Paris, and with braces. It does not meet the local requirements as well as treatment by horizontal fixation, but it gives the patient greater liberty. It is not used in children younger than four years, except as a support after all active disease has subsided. In older children it may be applied after treatment by recumbency has been used for a short time. In adolescents and adults the ambulant method is used from the beginning. Jackets are used in the early stage; in the convalescent stage, braces are preferable. Jackets of plaster-of-Paris are applied by winding smoothly about the body moistened plaster-of-Paris bandages, the spine having been placed in the desired position. When the plaster has dried, a firm support is se-

Fig. 1024.—Suspension Hammock for Application of Plaster Jacket in Tuberculous Spondylitis.

cured. The jacket should extend as high as possible and as low as possible. The jacket is of greatest value in disease of the lower dorsal and upper lumbar regions.

Jacket Applied with Patient in the Prone Position.—A hammock of unbleached muslin, slightly narrower than the width of the thorax, is suspended from a frame, and the patient placed upon it longitudinally, face downward (Fig. 1024). The amount of curve can be increased by increasing the slack. An ordinary iron bed-frame or a tubular iron frame is useful for this purpose or the hammock may be swung from two hooks or rings. The smallest possible number of layers of muslin to support the patient should

be used. One thickness suffices for a small child. A tricot cotton covering or a cotton jersey underskirt is used to cover the skin. A small pad of gauze or cotton should be fixed over bony prominences such as the anterior-superior spines of the ilium. A pad of gauze or felt at least 2 cm. (¾ inch) thick should be placed on either side of the spinous processes of the diseased vertebræ in order to prevent pressure. The hammock is then lowered to extend the spine to the desired degree. Extension may be carried to the point of causing slight discomfort. The plaster bandages then are applied, covering the trunk. The bandages should be from 8 to 13 cm. (3 to 5 inches) wide and 6 meters long. From three to six are required for a child's jacket (see plaster-of-Paris Bandages, Vol. I, page 477. The bandages should be applied with even tension, and the layers well rubbed together. The thickness of the jacket should be from 3 to 7 mm. (⅛ to ¼ inch). It should fit with especial snugness around the pelvic brim. Some strips should run ob-

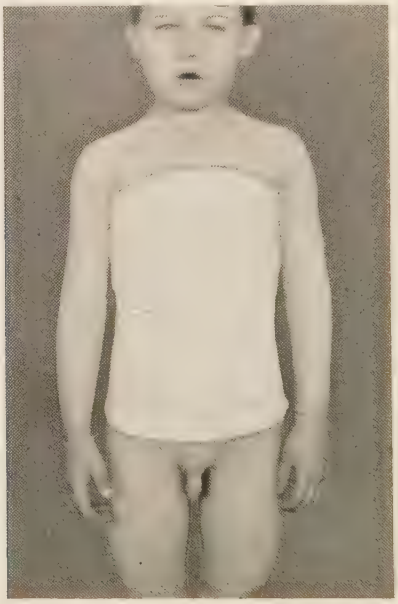

Fig. 1025.—Plaster-of-Paris Jacket to Immobilize Spine.

liquely. When it is nearly hard its edges should be trimmed. In most cases, in front, it should reach from the upper end of the sternum to the front of the pubes; behind, from the spine of the scapula to the lower end of the sacrum. It should be cut away around the axilla to prevent pressure on the arms, and across the groins to allow flexion of the thighs (Fig. 1025).

The muslin of the hammock may be trimmed off above and below and left in the jacket. It is possible to so place the muslin of the hammock under the shirt that it can be pulled out and removed. It is a good plan to place a strip of linen about 5 cm. (2 inches) wide under the shirt, back and front, and a little more than twice the length of the jacket. The two ends of each strip are sewed together, their purpose being to give cleansing friction to the skin. The upper end of the shirt or a separate collar should fit snugly around the neck to prevent crumbs dropping under the jacket. A nice covering for the jacket is secured by having the tricot lining long enough to

be doubled up over the outside and sewed end-to-end after the jacket is hard. The health of the skin is most important. When the skin becomes broken, the discharge of the sore has a peculiar odor, which should call for removal of the jacket.

Jacket Applied with Patient Lying on the Back.—The preliminary dressing should be the same as above. The head and shoulders may rest on

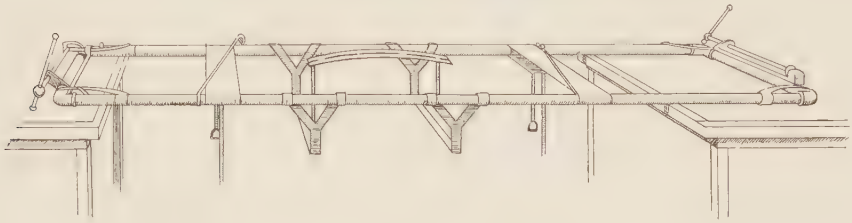

Fig. 1026.—Frame for Applying Plaster Jacket with Patient in Recumbent Position.

one support and the buttocks on another (Fig. 1026). Support of the spine may be secured by passing a piece of canvas about 13 cm. (5 inches) wide and 150 cm. (60 inches) long, under the back. This should be well padded and support the kyphosis. It is attached to a spreader about 75 cm. (30 inches) long, which is supported by a rope passing over a pulley. Sufficient elevation is made to give the desired correction and the plaster is applied over the canvas which emerges at the sides. When the plaster has hardened the

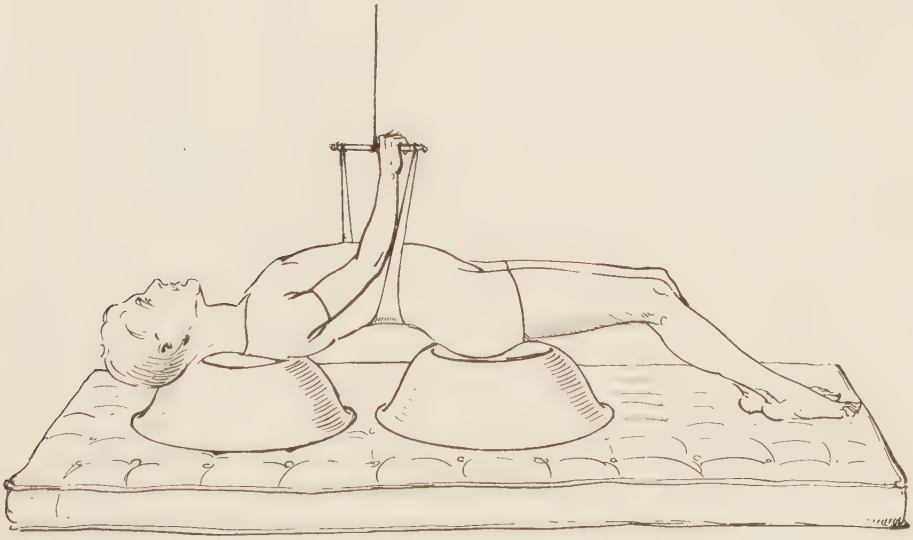

Fig. 1027.—Supoprt for Application of Plaster Jacket.

ends of the canvas are cut off. This method should be used very carefully lest the rope or canvas become loosened and the spine suddenly fall because of the loss of support (Fig. 1027).

Jacket Applied with Patient Suspended.—This method serves for adults but is not well adapted to children. It does not give as good extension as the above methods. The patient is prepared as above, and the suspension

apparatus adjusted. The apparatus consists of a bridle which is capable of making traction under the chin and occiput, and rings to which the patient holds with his hands elevated (Fig. 1028). An apparatus can be extemporized with rope, pulleys, a stick of wood and a little cotton cloth. Traction should be made until discomfort begins to be felt, the traction desired should partly lift the body of the patient so that the heels are slightly raised, or the patient is slightly lifted from the sitting position. By maintaining some of his weight with his raised arms the ribs are raised and the chest expanded. One person may sit behind the patient and one in front and a third may hold the apparatus to prevent swaying and rotation. While the jacket is hardening the assistants rub in the plaster and make corrective pressure in order to secure some extension of the spinal joints. If the patient becomes fatigued or must be taken down before the jacket is hard, he should be laid on a hammock face downward or in the recumbent position with an elevating support behind the back opposite the disease. This vertical suspension method has been superseded by the horizontal position in the treatment of tuberculous spine.

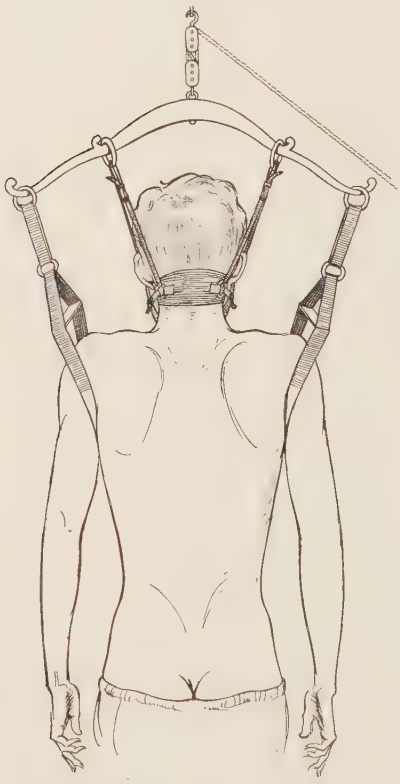

Fig. 1028.—Suspension for Application of Plaster-of-Paris Jacket.

For Cervical and Upper Dorsal Disease.—The jacket above described is most effective for disease in the lower dorsal or upper lumbar regions. If the disease is higher than the ninth dorsal vertebra, the upper dorsal vertebræ should be included in the jacket. This may be done by carrying the plaster over the shoulders, as in the high jacket, or by supporting the head by braces. Disease above the middle dorsal vertebra requires support of the head.

In applying the *high jacket* (Calot) the patient is prepared and suspended as usual. An additional layer of cotton is placed on the front of the chest, and the neck and shoulders are covered with a layer of cloth. The head suspension is best secured by two strong strips of muslin, 2 cm. (2 inches) wide, under the chin and occiput, connected above the ears, and prevented from displacement forward and backward by having sewed to them a connecting strip on either side of the neck. The supporting strips are fixed to the crosspiece of the suspension apparatus. If the hammock is used, traction is just as easily applied. Counter-extension is made through adhesive straps to the thighs, and to facilitate breathing a hole is cut through the hammock or a pad placed under the forehead. An opening must be cut under the neck to permit the bandage to pass in and out. The dorsal position may be used with the patient supported upon a frame. The arms should be at right angles to the body. The plaster is applied as usual except that the jacket is made thicker and carried over the shoulders and about the neck.

In disease in the upper dorsal region the jacket should come well up against the occiput and chin. In cervical disease, the head should be covered with cloth and the plaster made to embrace all of the head, leaving exposed only the face and ears. The head should be tilted back by upward pressure on the chin.

The front of this jacket may be cut away so as to make a large fenestrum exposing the mid-thorax and abdomen (Fig. 1029). Calot cut an opening in the back over the dorsal disease, placed pads over the deformity, and pressed it forward by additional turns of plaster bandage, repeating the process at intervals of a month and carrying the pressure to the point of toleration. This pressure should not be made at the apex of the deformity but by pads

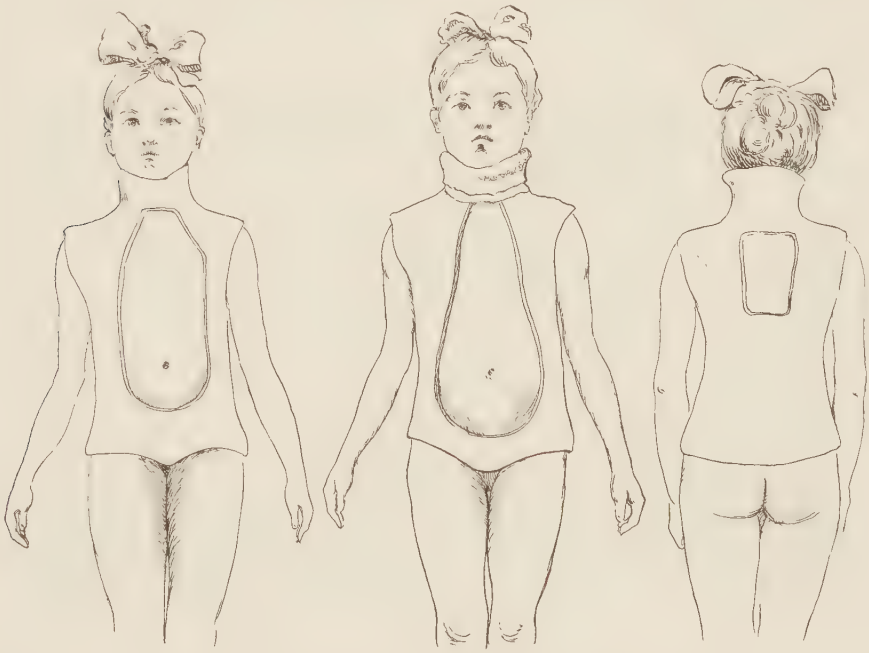

Fig. 1029. Fig. 1030. Fig. 1031.

Fig. 1029.—Plaster-of-Paris Jacket for Dorsal Disease.
Note large window to give freedom for respiration.

Fig. 1030.—Plaster Jacket for High Dorsal or Cervical Disease. Front view.
Fig. 1031.—Plaster Jacket for High Dorsal or Cervical Disease. Rear view.

close to it on either side. The proper application of this jacket requires experience. For cervical disease, the plaster jacket need not embrace the pelvis, but it should support the head (Figs. 1030 and 1031).

More comfortable and better than these appliances is treatment, with traction in the recumbent position (Fig. 1032). *Metallic braces* are used in connection with the jacket in treating high disease. In high dorsal disease, the jury-mast (Fig. 1033) band or head-support is of service (Fig. 1034). The head bands are as effective as the jury-mast and less conspicuous. This apparatus is commonly connected with metallic body-braces, but the head-supporting part may be incorporated in a plaster jacket. If deformity of the chin occurs as a result of pressure, a forehead band should be applied with occipital support.

In the later stages of spondylitis, and in the early stages, in experienced hands, the whole treatment may be conducted in braces. The most effective consist of two steel rods, lying on either side of the spine, connected by transverse pieces, and strapped to a broad apron of canvas or leather in front of the body (Fig. 1035). Braces should be made to order for each patient.

After treatment on the recumbent frame, a plaster jacket may be applied to a child by placing it face down in the muslin hammock and returning it to the frame before the plaster has hardened. This gives the exact position of the frame to which the spine has become accustomed.

The *care of the skin* demands that braces should be removed frequently and the skin bathed and rubbed with alcohol. A plaster jacket should be left on for about three months. If not comfortable, or if there are signs of skin irritation, it should be removed sooner. In many cases a jacket may be

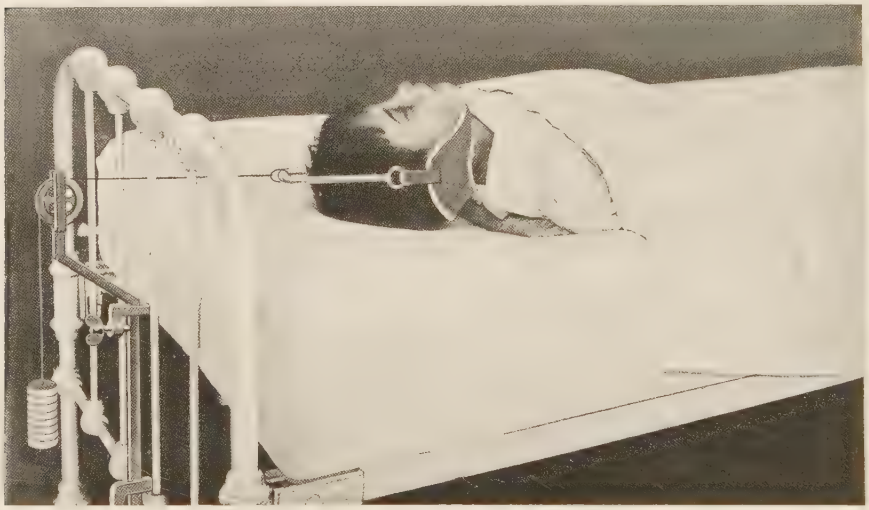

Fig. 1032.—Treatment of High Dorsal or Cervical Disease by Traction in Recumbent Position. (*After G. R. Fowler.*)

left on six months or longer. Before removing the jacket everything should be ready for applying another. When the jacket is taken off the patient should be kept suspended or in the horizontal position. If the skin is sore the old jacket should be replaced and held by adhesive plaster until the health of the skin is restored.

Treatment by corset is employed in the later stage of the disease (Fig. 1036). A corset is made by cutting a strip, 1 or 2 cm. wide, out of the thickness of the jacket in the median line in front. Any necessary extra padding is added, the front edges are bound with leather, provided with hooks for lacing, the top and bottom are bound, and the corset laced in place. A more elegant corset may be made by making a plaster cast of the torso in the original jacket as a mould. About this cast a corset of paper, celluloid, wood, aluminum or other composition is made.

In *lumbar disease*, especially low down, the body jacket alone does not suffice. Here braces are most effective. They should be constructed in combination with a crutch-like top to press up in the axillæ; a support should rest upon the crest of the ilium on either side; and a band should

embrace the pelvis. In some cases of low disease, this will fail to give the necessary immobilization; then there must be added to the above, splints for immobilizing the hip-joints. This is done by continuing down back of each thigh a flat rod, such as is used in the hip splint of Thomas.

The *prognosis in tuberculous spondylitis* varies with the location of the disease, the earliness of treatment, and the general hygiene that can be secured for the patient. In the lower spine the prognosis is good, although psoas abscess and contracture are often present; healing with but little deformity is usually secured. In the middle dorsal region, although the symptoms are easily controlled, deformity usually results. In the upper dorsal and lower cervical regions recovery with no apparent deformity may be expected. In the upper cervical region, if the head is well supported to take the weight from the small neck bones, recovery without deformity may be expected; but if the support is not secure, paralysis and death may easily occur.

FIG. 1033.—JURY MAST IN TREATMENT OF HIGH DORSAL AND CERVICAL DISEASE.

FIG. 1034.—HEAD SUPPORT IN TREATMENT OF HIGH DORSAL DISEASE.

Treatment of abscess has already been described (see Tuberculous Abscess, Vol. I, page 281). The greatest care should be taken to prevent mixed infection. *Retropharyngeal abscess* usually should be evacuated promptly because of the danger of invasion of the larynx and the obstruction to swallowing which it often causes. In an emergency the abscess may be incised in the middle line of the pharynx through the mouth. The free evacuation is best done through an incision along the posterior border of the sternomastoid muscle. This muscle and the omohyoid are retracted upward and the splenius

capitis is exposed. The fibers of the longus colli are separated and the side of the vertebra reached. The vertebral artery should be avoided (Vol. I, page 410). If the abscess is purely tubercular, and there is no emergency threatening, a better result can be secured by aspiration. This may be done through the neck wound when the dissection has nearly reached the abscess, or it may be done through the mouth and mucous membrane. In the latter operation the tongue is depressed, the mucous membrane bulged forward by the abscess is touched with cocain, it is then dried and touched with tincture of iodin, and the aspirating needle inserted. The needle should be connected to the syringe or bottle by a non-collapsible rubber tubing.

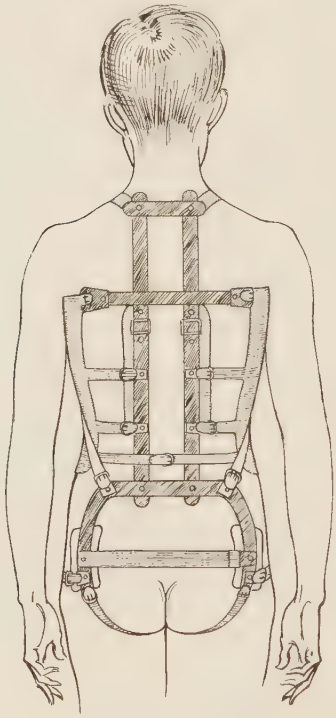

Fig. 1035.—Metallic Brace for Spondylitis.



Fig. 1036.—Corset for Immobilization of Spine.

The corset has been divided, and is provided with hooks for lacing.

An *abscess of the middle cervical region* may be aspirated or opened in the side of the neck. *Abscess of the upper dorsal region* may become urgent because of pressure on the trachea or bronchi. When the thorax is invaded and urgent pressure symptoms demand relief, a vertical incision is made just to one side of the spinous processes exposing one or two costovertebral articulations, and the joints resected. Blunt dissection along the side of the bodies of the vertebræ discovers the abscess. If the abscess gives no lateral symptoms the opening should be made preferably on the right side.

In *abscess of the lower spinal region* urgency is not apt to arise. Here tentative measures should first be taken. Aspiration should be practised if spontaneous rupture threatens or if the presence of the abscess interferes with proper treatment of the bone disease. Aspiration should be repeated so

long as mixed infection is not present or permanent evacuation is not demanded. Aspiration may prevent the abscess from becoming large even though it does not cure it. Incision should be the last resort as a confession of defeat. It should be about 1 cm. long, just large enough to admit a rubber tube; it should be at the most dependent point; it should be made under the most rigid asepsis; a tube should be inserted and a dressing of antiseptic gauze applied covered with a copious mass of dry gauze; dressings should be done as infrequently as possible, and always with strict asepsis; and the tube should be left out as soon as it can wisely be dispensed with. These rules apply to *lumbar, psoas, femoral* and *inguinal abscess*, or abscess in any part of the flank or pelvic region.

Spinal abscess due to mixed infection, as evidenced by temperature, leukocytosis and other signs of pyogenic infection, must be incised at once. If the incision permits, any accessible dead bone should be removed at the same time.

Treatment of paralysis should first be prophylactic. The earlier and more effective the immobilization and the hygienic treatment, the less apt is paralysis to occur. Treatment by recumbency should be practised as soon as the first sign of paralysis appears. Traction or extension may with advantage be added to this. If there is much deformity, considerable corrective force is justified. The best position is on the stretcher frame. A radiograph should be of service in showing whether the pressure upon the cord is due to crushing of the bodies of the vertebræ or to abscess. Abscess causing paralysis should be opened. If the disease is in the upper dorsal or cervical regions, traction by weight and pulley may be applied. A paralyzed patient must receive careful treatment of the skin. To prevent bed-sores in adults a water mattress is of service. Fortunately most cases occur in children and the prognosis is good. Extension may be secured by drawing a strong band of muslin transversely behind the lesion; and by making it tight to a lateral framework, the body is elevated at the site of the disease and extension secured.

Laminectomy is rarely of service, and it has the disadvantage of weakening the posterior part of a canal with an already weakened anterior part. In cases in which everything else has been done to relieve paralysis, if the paralysis steadily grows worse or persists after a year or eighteen months despite extension, it may be assumed that there is some pressure within the spinal canal which may be removable. Laminectomy, with or without opening the dura, is done as for tumor (see page 339). Often some plastic exudate or other product of the disease will be found within the canal. This should be removed. The whole operation should be conducted with expedition, as these patients are very susceptible to shock and the mortality is high.

Operations upon the bodies of the vertebræ are indicated when an abscess at the disease requires to be opened, or when much bony débris or sequestra are present. The opening of an abscess made near the disease gives an opportunity for the removal of dead bone. It is not advisable to attempt to curet away all of the necrotic bone, but what is loose and accessible may be removed. The bodies of the cervical vertebræ are reached through the incisions described for retropharyngeal abscess (see page 205). The dorsal vertebræ are reached by an incision lying back of the transverse processes; the heads of the adjacent ribs and the transverse processes are removed (see page 326). The lumbar bodies are reached by an incision from the last rib to the ilium just back of the transverse processes at the border of the quadratus lumborum. The dissection is carried to the psoas muscle, some fibers of which should be detached from the transverse processes and

the sides of the bodies reached by blunt dissection. The transverse processes may be divided if necessary. If dead bone is removed the cavity may be packed with iodoform gauze.

The duration of treatment of tuberculous spondylitis varies greatly. At best the healing is slow. The first stage of the disease is the active and destructive stage, in which the vertebral body breaks down. It is then especially that support, immobilization and extension are zealously to be maintained. Treatment should be continued as long as tuberculosis is present. This may be determined by test for tuberculin reaction. When pain and discomfort have ceased, it should not be assumed that the disease is well. Muscular spasm usually persists until the disease has nearly disappeared. So long as pain or muscular spasm appear when passive motion is applied, it may be assumed that treatment must be continued. When the active stage has ended, consolidation and fixation take place, and the spinous processes of the diseased vertebræ become more prominent.

Tuberculosis heals most quickly in the cervical region. Here at least two years must be given to treatment. In the dorsal region at least four years elapse before treatment can be discontinued. When pain, tenderness, abscess and spasm are absent, the support may be removed. The removal of support should always be regarded as tentative, and it should be reapplied at once upon the reappearance of symptoms. It is best to go from the horizontal frame to the jacket; from the jacket to a light corset or brace; from braces to a light corset or lighter braces. When no more tuberculosis is present, massage and electricity to the back muscles are of value in restoring their strength. While the muscles are being developed braces or a corset should be worn to hold the spine from becoming distorted. Kyphosis is very apt to develop in the upper dorsal region. The deformity in the cervical and lumbar regions may be slight or not present.

Operative Treatment of Tubercular Spondylitis.—Operations for complications have been described above. The operative treatment, applied as a curative measure to the disease itself, consists in operations for immobilizing the intervertebral joints. This was first done by implanting metallic bars on either side of the spine. Later bone grafting, transplantation and operations to cause ankylosis have supplanted all other operative measures. This treatment has the merit of effectively fixing the spine, and giving better immobilization than can be secured by any form of jacket, corset, or brace (for Operative Treatment, see Vol. I, page 776).

Tumors of the Spine and Cord.—*Tumors of the Vertebræ.*—As the great majority of tumors of the spine are secondary and malignant, operation has little to offer. Primary sarcomata of the vertebra have been removed. Benign growths become serious only when they press upon the cord or nerves or seriously weaken the vertebral column. Operations for secondary malignant deposits may be regarded as useless. Such tumors should be treated by conservative measures. Collapse of the spine may be prevented or delayed by fixation as for tuberculosis. Operations for callus and exostoses are promising.

Intraspinal tumors may be extradural, subdural or medullary. Histories show that most of these tumors are located posteriorly or laterally rather than anteriorly. Before operating, the question of help from antisyphilitic treatment should have been settled. Even though syphilis is the cause of the disease inflammatory tissue may remain and act as a tumor, and relief may be secured only by its operative removal. As soon as diagnosis of a compressing tumor is made, if the tumor is not yielding to antisyphilitic treat-

ment and if it is not associated with incurable primary malignant disease, operation for its removal should be attempted by laminectomy.

Laminectomy is done not only for tumor of the spinal canal but for the exposure of the canal, for operations on the nerve roots, and for the removal of foreign bodies and the products of inflammation. When there is much uncertainty about the location of the disease, it is well to wait until the anesthesia reaches a constant upper level. The operation is not difficult. It is usually done under general anesthesia, but the operation is easily done with 0.5 per cent. novocain solution. From 50 to 100 c.c. of this solution are required.

The patient is placed on his side, rotated toward the prone position, and held by sand pillows so as to elevate slightly the part to be operated upon. The convenience of the operator is secured by having the patient on his left

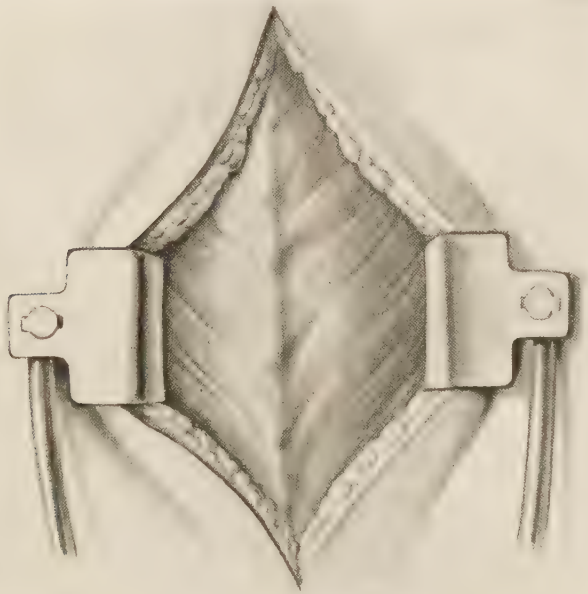

Fig. 1037.—Laminectomy.
Dorsal muscle and tips of spines exposed.

side. A long incision is made slightly to one side of the median line of the back, following the spines of the vertebræ. The middle of the incision should be opposite the disease, and at least three or five vertebræ should be exposed (Fig. 1037). The muscles should be separated from the sides of the spinous processes and ligaments by means of knife and elevator. At the angle between the spines and laminæ the periosteum should be divided and reflected back with the muscles, until the laminæ are exposed to their outer limits. The exposure of the laminæ is done first on the lower side and then on the upper side of the median line and hemorrhage checked. Strong right-angle retractors hold the muscles outward. To secure better exposure the deep fascia may be divided transversely at the ends of the wound, and the muscles may be separated from the backs of the articular processes.

While working on one side of the spines the wound on the other side should be kept packed with gauze.

The spinous processes are cut off with angular bone-cutting forceps or the rongeur (Fig. 1038). For removing the laminæ, the rongeur is most satisfactory. Care should be taken not to injure the dura mater or make undue pressure upon the cord. At no stage of the operation is the hemorrhage anything more than venous oozing, easily controlled by pressure. As the laminæ are cut away the surgeon should be on the lookout for the cause of the pressure. During these steps of the operation, an extradural tumor, inflammatory exudate, fragment of bone, blood clot or other cause of pressure may be discovered and removed. After the laminæ of three vertebræ

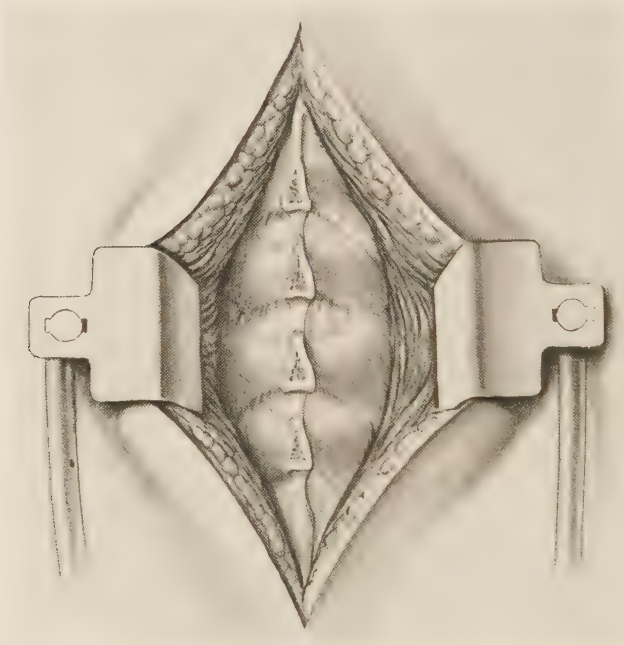

Fig. 1038.—Laminectomy.
Spines have been cut away, muscle retracted and laminæ exposed.

have been removed and no extradural pressure has been found, a probe may be passed carefully between the dura and the bone, above and below, to palpate for the cause.

If the dura does not pulsate, it may be judged that there is tumor, exudate, or some other condition which closes the subdural space. A subdural tumor cannot often be palpated through the dura. A tumor of the substance of the cord or an intradural tumor is apt to obstruct the flow of cerebrospinal fluid. If the dura is opened below the tumor the first flow will be slow; if above the tumor, the first flow of fluid will be vigorous and indicative of tension.

To open the dura it should be picked up with fine forceps and incised longitudinally in the median line. The flow of cerebrospinal fluid will not obstruct the view if that part of the spine has been elevated. This is best accomplished by lowering the head of the table. The dura should be

retracted carefully by fine retractors or silk sutures passed through its edges, and a good view of the cord secured (Fig. 1039). The tumor may be found covered by edematous arachnoid, which must be teased apart to expose it. Tumors of the cord are often encapsulated and easily shelled out with a small scoop or, by blunt dissection. The incision of a slight thickness of cord substance may be necessary. This should always be in the longitudinal direction. Thin bands of tissue may require to be cut, and small vessels ligated with finest catgut.

It may be found that a nerve root is so involved that it has to be divided or resected. The simple division of a nerve root should be remedied by suture. Cysts may be evacuated. The sponging should be most gentle. Blood

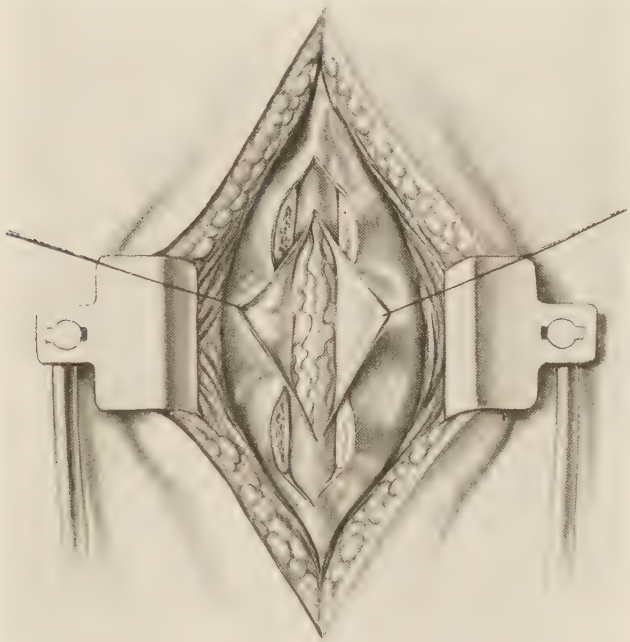

Fig. 1039.—Laminectomy and Exposure of Cord.
Laminæ of three vertebræ have been removed, the dura mater exposed and opened. Retraction of dura is made with silk threads.

is best washed away by a stream of warm saline solution. In working about a solid tumor, it may be best to remove it in pieces to prevent undue pressure upon the cord.

In operating for localized *medullary tumors*, C. A. Elsberg and E. Beer (Am. Jour. Med Sci., cxlii, No. 5, Nov. 1911), after laminectomy and free incision of the dura mater, advised making a small incision not more than 0.5 or 1 cm. ($\frac{3}{16}$ or $\frac{3}{8}$ inch) long, in the posterior median column a few millimeters from the posterior median fissure, where the growth seems to be nearest to the surface. The incision should pass down to the tumor. The deepening of the incision is best made with a blunt instrument. When the tumor is reached it will then bulge into the incision. Now the surgeon should not make the mistake of attempting to remove the tumor; for he will do serious injury to the cord. It must be left to nature. Nature will slowly

extrude the tumor with the least amount of damage to the cord. The dura should not be sewed. The muscles and skin should be sewed over the cord, and the wound dressed. At the end of about a week the wound should be opened and the tumor will usually be found lying outside of the cord. Its removal requires only dividing a few adhesions. If any injury to the cord is required in removing the tumor, if it is benign, it is best to defer its removal. The pia should then be closed. The dura, muscles, and skin should be sutured over all.

Intramedullary tumors which extend the height of several vertebræ may be treated in this same manner, even though they infiltrate the cord substance. A small incision, made at the place where pressure seems greatest, or at the level of the most pronounced symptoms, may result in extrusion sufficient to give relief. This method of treatment may also

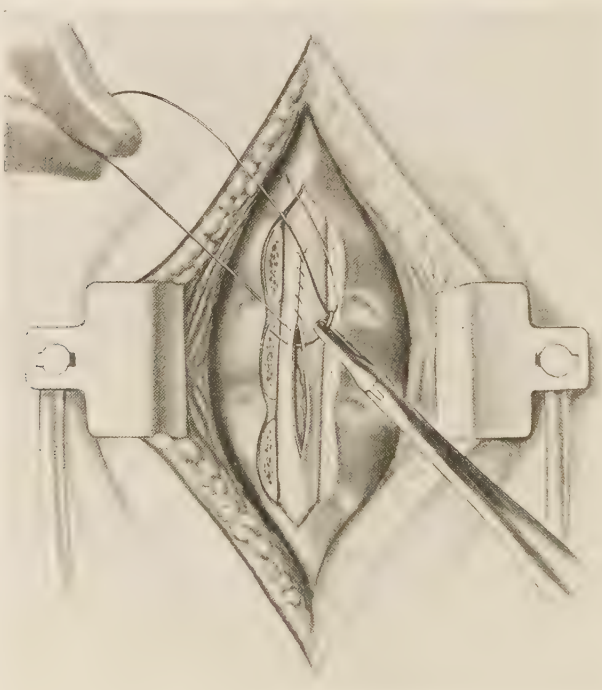

Fig. 1040.—Laminectomy.
Closing dura with continuous suture.

be applied to blood clot in the cord, spinal gliosis, and syringomyelia. A central cavity may thus be drained into the subarachnoid space.

In incising the cord, the utmost gentleness should be used. The incision should be made slowly with an exceeding fine knife. Sponging should be so gentle that no pressure is made on the cord. The cord should not be grasped with forceps or anything else. If it is necessary to lift it from its bed, the dura or pia may be grasped. This treatment of intramedullary tumors, which Elsberg has named "the method of extrusion," is the most important modern advancement in the treatment of these lesions (see C. A. Elsberg: "Surgery of the Spinal Cord," W. B. Saunders Co., 1916).

For exposure for operation on a tumor the laminectomy should be

complete. Not less than three lamellæ and spinous processes should be removed. The lamellæ should be removed well out to the articular processes. The anterior surface of the cord may be exposed by dividing a slip of the dentate ligament, grasping the stump of the ligament with fine forceps and rotating the cord. If still more exposure is desired, a posterior root must be divided.

If the tumor cannot be removed division of the posterior nerve roots at and above the level of the tumor may be done to give relief from pain. Additional laminæ may be removed to expose the growth. If symptoms of tumor have been present and no tumor is found, laminæ should be removed to the highest limit corresponding to cord disturbance. This may require the removal of laminæ of four or five vertebræ above the original wound. The disease is apt to be higher than suspected. If the operation is done for kyphotic paralysis or old dislocation or fracture paraplegia, enough of the laminæ should be removed to free the cord from pressure. The operation should be discontinued at any time when the patient shows severe depression. Some surgeons as a rule prefer to do all operations for tumor in two stages, closing the first wound with a few temporary sutures.

At the termination of the operation the dura should be sutured with fine catgut (Fig. 1040). The muscles should be replaced and held with sutures of chromic catgut, obliterating all cavities. The deep fascia should be sewed separately. The skin is best closed with a subcuticular suture.

Postoperative care in laminectomy cases is important. If there is no disease which has softened the bodies of the vertebræ, support by jacket or braces is not necessary. A water or air mattress is always of advantage if paraplegia is present. It is not necessary for the patient to lie always on the back, but he may be turned to one or the other side for relief. Even though pressure was relieved by the operation, the subsequent traumatic edema keeps up the pressure for some time. Improvement may not occur for two weeks, or it may be immediate. The pain following the operation is apt to be severe because of edema about the sensory roots. It should be relieved by morphin. The length of time which the patient should be kept in bed varies with the pathologic conditions present. At least three weeks should elapse before the patient is allowed to sit up. So far as the strength of the spine is concerned, it should be remembered that its support is not in the posterior parts but in the bodies and articular processes.

The results of laminectomy for approach to the cord have steadily improved. Deaths have been due to shock and meningitis. Loss of blood is borne poorly by these patients and every drop possible should be conserved. When much damage has been done the cord by long pressure the removal of the compression has not been followed by the hoped for results. In cases, especially of extradural tumor, in which operation has been done without delay the results have been striking and gratifying. Improvement sometimes continues to go on after two years. Operations on medullary tumors offered little hope of success until Elsberg's two-stage operation was introduced. In tuberculous lesions the results are best after the infection has subsided. Operations in the presence of the tubercle bacillus are not apt to give as good results as the ordinary orthopedic treatment, and moreover there is always danger of setting up tuberculous meningitis.

To secure the best results operation for pressure, if it is to be done, should be done early. The results in chronic meningitis with effusion have been good. I have given a patient permanent relief from pressure symptoms by removing long strips of plastic lymph, of unknown origin, from the dura. Often the decompression secured by laminectomy gives relief even though

no tumor is removed. It is possible that in subpial tumors a two-stage operation is best. Elsberg has reported a case in which, after incising the cord over the tumor, he has temporarily closed the wound, and one week later found a tumor, 5 cm. (2 inches) long, spontaneously extruded and lying outside of the cord.

Spinal decompression is the operation described above. It consists in laminectomy, to expose the cord, and incision of the dura mater. It is indicated in the same conditions as decompression in the cranium. Because there are intradural conditions which present symptoms similar to tumor, this operation has a considerable field of usefulness. In obscure cases of spinal disease, even though there is no increase of subdural pressure, decompression often gives relief.

Osteoplastic laminectomy was advocated by F. J. Gaenslen (Jour. Am. Med. Assoc., Oct. 6, 1917). It consists in splitting the spinous processes in the median line as is done in the bone-grafting operations for spondylitis fixation. One-half is fractured at its base and reflected laterally with its periosteum unbroken. This is done with all the split spines on one side. The other half is then fractured at their bases. The posterior periosteum of the laminæ is peeled up with that holding the fragment of spine. This elevation of periosteum is carried out well upon the transverse processes. The laminæ are then removed, and the cord exposed. After the operation on the cord the two halves of the spines are brought together with their attached flaps of periosteum and soft tissue, and sewed in place. If desired a graft of bone may be implanted in the median line between the fragments.

Operations on the Posterior Nerve Roots.—This field of surgery owes its development to Munro, Abbé, Bennet, Foerster and Kuettner. The sensory roots of the spinal nerves are easily exposed in the vertebral canal by laminectomy (see page 339). Division of the posterior roots (rhizotomy) is done for intractable neuralgia, spastic paralysis, spasticity, gastric crises of tabes, and other conditions in which it is desired to cut off centripetal impulses from the periphery.

Only lesions with true reflex spasticity, as the result of loss of cortical inhibitory fibers, are suitable for rhizotomy. Such conditions as chorea, athetosis, mobile spasms, and spasmodic torticollis are not usually amenable to this operation; although some cases of athetoid and choreiform movements have been entirely cured. Cases with but slight spasm and considerable paralysis are not helped. Innervating fibers of the pyramidal tract must be present. The operation is possibly worth while in cases with severe spasms and total voluntary paralysis, in which there remains considerable voluntary excitability which is only obscured by the spasms and only apparent after they have been eliminated. It is not wise to do the operation until the disease has become stationary. Progressive diseases, such as disseminated sclerosis, are not benefited; although slowly progressing diseases, such as spastic spinal paralysis, may be helped. In these spastic cases the operation must be followed by years of faithful attention to exercises of the muscles. Such limbs should be held in corrective splints, only to be removed for exercises several times daily. Operations on tendons and muscles may also be required. It is in cases of spasm, with lesions in the pyramidal tract, that the operation has its largest field. The mortality following the operation up to 1918 was between 15 and 30 per cent. The operation, therefore, is too serious a procedure to be employed in any but the most desperate cases.

The operation is best done within the dural canal. If attempted outside of the dura (Fig. 1041), motor fibers are apt to be cut, and this is undesirable unless the motor fibers go to an amputated limb or athetoid movements are

present, or some other condition exists which renders the motor fibers of little importance. Division of the posterior root external to the ganglion is apt to be followed by regeneration unless the ganglion is destroyed. Hemilaminectomy is best done when dealing with the brachial roots. The lumbosacral roots are best divided at the cord rather than at the dura.

Division between the ganglion and the cord can only be done within the dural tube. This operation results in permanent degeneration of the fibers from the point of section up the posterior columns of the cord. If but one side requires operation, the laminectomy may be unilateral, leaving or re-

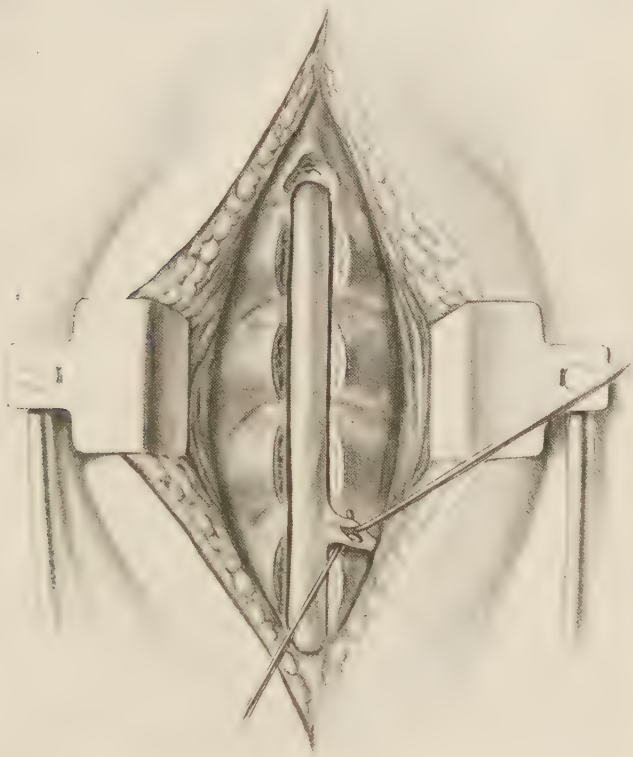

Fig. 1041.—Division of Posterior Nerve Roots Outside of the Dural Canal. The posterior and anterior roots are being separated by fine hooks. This is difficult and less satisfactory than the operation within the dura.

moving the spinous processes as seems best. The local use of adrenalin renders the field bloodless.

A careful study should determine what roots need to be attacked (see page 322). It should be borne in mind that the division of a single root is not sufficient to cause sensory paralysis of any area, as the nerves to a given area emerge by several roots. A case is reported in which the division of the upper five lumbar roots gave no appreciable loss of sensation.

Four or five laminæ should be removed and the exposed dura opened its whole length. The head should be lowered to prevent too free an escape of cerebrospinal fluid. The roots may be identified by recognizing their place

of exit through the dura. If it is desired to identify a motor root, it may be done by weak faradic stimulation. But one root need be identified, the others may be counted from that. The four of five roots to be cut may be caught up on a blunt hook and divided at their point of entrance in the dura and again close to the cord. This represents a resected segment of 7 to 13 mm. (¼ to ½ inch) (Fig. 1042).

In operating for *neuralgia*, it is possible that the laminectomy may uncover the cause of the pain—a tumor or inflammatory deposit involving the sensory roots—and a radical and curative operation may be done. The

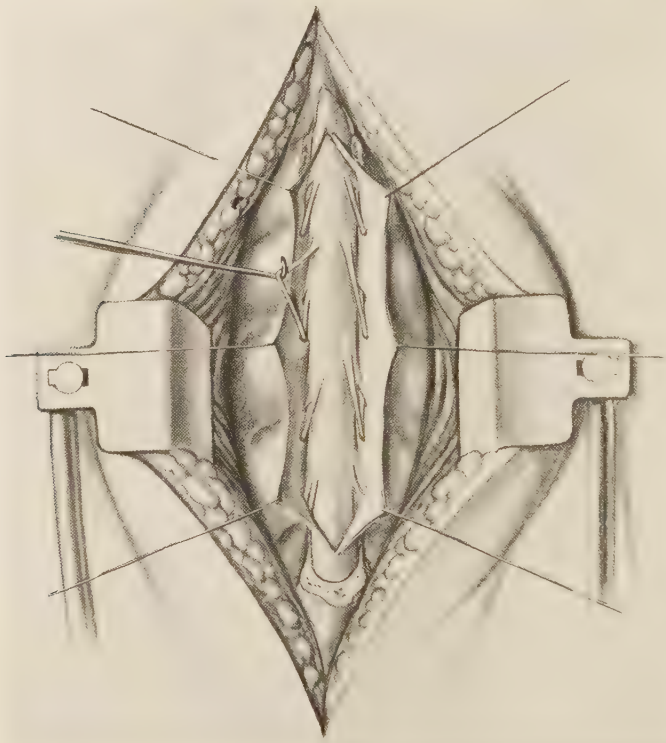

Fig. 1042.—Intradural Division of Posterior Nerve Roots.
The dura has been incised and is held open with fine silk retractor threads. The posterior root is picked up with a hook.

hazard of this neurectomy, in patients not depressed by serious disease, is not great. If all of the roots supplying the painful area are divided, the results are good. The resection of too few roots may give relief but not cure. When the pain is in the arm, the third to the eighth cervical and the first three dorsal roots must be divided. For pain in the leg, the tenth to the twelfth dorsal, all the lumbar and all the sacral roots must be divided. Only in localized pain in which the affected nerves may be identified may fewer be cut.

The treatment of *spastic paralysis* by this method gives fairly gratifying results in cases either of spinal or cerebral origin. The exaggerated reflexes

are cut off and involuntary contractions cease, but voluntary contractions are under control. Following the operation the patients must be trained to use and control the muscles normally. Apparatus must often be used for a while to prevent the continuation of unnatural movements. Better results have been secured in the legs than in the arms. Children which have not been able to take a step are made to walk. Spasticity due to trauma to the spine is benefited by this operation if motor power is not lost. Three or four of the lumbosacral roots are divided for leg spasticity.

Cerebral diplegia, hemiplegia, compression myelitis, and even multiple sclerosis may be benefited if the case displays spasmodic contractures. Fair results have been had in cases of spastic contractures due to tuberculous spondylitis and hydrocephalus. The operation should be reserved for cases in which other treatment has failed. Often the disease has caused such atrophy of the parts that cure of the spasticity has little to offer. After operation daily massage, passive motion, and active motion of the parts should faithfully be carried out.

A. Stoffel (Presse Méd., March 23, 1912) did partial division of the nerve roots supplying innervation to the affected muscles, leaving some fibers to supply enough innervation to balance the antagonistic muscles.

Rhizotomy for *tabetic gastric crises* gives fairly uniform and satisfactory results. The operation should be done only in the severe cases, such as require morphin and suffer with inanition. The operation aims to resect the sensory gastro-intestinal fibers of the sympathetic nerve. This may require resection of the posterior roots of the twelfth up to the fifth dorsal nerves, or higher. Failures follow division of too few roots. By studying the location of the pains and the hyperesthetic areas in the skin, the exact nerves that require resection may be mapped out. Thus a case is reported in which the crises recurred after resection of the seventh to the ninth roots, but ceased entirely after the tenth and eleventh roots had been resected. In some cases it will be necessary to continue the resections down to include the first lumbar roots. The operation, of course, is of no value if the crises are due to vagus irritation or to direct irritation of the vomiting center in the medulla.

Franke advocated and practised avulsion of the intercostal nerves outside of the spine instead of the intraspinal operation. Each nerve is exposed, lifted up on a hook and pulled away from its spinal attachment. By doing this on both sides from the fifth or sixth to the ninth or tenth dorsal nerves inclusive, long-standing relief has been secured in many cases. The object of the operation is to tear away the ganglion with the root, thus destroying the communicating branches which are the origin of the splanchnic nerves. If it fails to do this it fails to cure. It is a rather uncertain procedure. It may be expected to cure about half of the cases operated on. The mortality is lower than in the intraspinous operations. It should be borne in mind that only the pains which have to do with the splanchnic nerves are amenable to operation.

Ligation or division of the roots between the ganglion and the dura mater blocks the reflex and causes degeneration of the sensory fibers. A laminectomy is required for this operation. The anterior motor root may be included in the ligature or incision. This need not be so serious as it might seem, because the slight paresis of the abdominal muscles which results may be treated by wearing a belt.

The vagus being responsible for the crises in a certain proportion of cases, division of the posterior roots should be done only in the cases in which there is a zone of hyperesthesia in the gastric region and the epigastric reflexes

are increased. When careful diagnosis is thus made, relief of the symptoms may be expected in half of the cases operated upon.

The treatment of *paralysis agitans* by division of the posterior roots has given some encouragement. Sensory stimuli which keep the muscles in a constant state of agitation are shut off by this operation. The operation may be done by the extradural technic. The nerves to be divided must be determined by the area which seems most affected. There may be value in partial division of the roots and in dividing alternate roots instead of each successive one.

The *excision of the spinal ganglia* was done by Sicard and Desmarest (Presse Méd., Nov. 6, 1912, vol. xx) for the relief of gastric crises. Laminectomy is done but the dura is not opened. The operation is applicable only in the dorsal region. The root in its sheath is ligated close to the cord, and grasped with forceps further outward. It is then cut close to the ligature, and torn loose peripherally by twisting it upon the forceps. The nerve tears beyond the ganglion. The stump, containing the ganglion is thus brought away.

Recapitulation.—Division of posterior spinal nerve roots should be done in severe cases only, as the mortality is high, and success is usually secured only by doing an extensive operation.

For *pain*, the operation gives permanent relief only when a large number of roots are divided because of the overlapping of the sensory nerve supply.

For *gastric crises* (visceral crises of tabes), relief may be expected in most cases.

For *spasticity* and spastic paralysis, due to disease of the corticospinal path, especially the pyramidal tract, the mortality is lower. C. A. Elsberg had no deaths in a series of twelve cases. At least five roots must be resected.

The second, third or fourth lumbar root should not be divided as it is necessary for the extension of the knee. The nerve which controls this function should be determined by the electric current.

The general rule is to resect for the leg from the second lumbar to the second sacral, inclusive, excepting the fourth lumbar. For the arm, it is necessary either to resect from the fourth cervical to the second dorsal, inclusive, excepting the sixth cervical; or to resect the larger part of the nerve bundles of all of these roots, including the sixth cervical.

Anastomosis of the anterior nerve roots within the spinal canal may be done to supply innervation to paralyzed muscles in cases in which the paralysis is due to a spinal lesion and a functionating nerve root may be found which is accessible. In a case of paralysis of the bladder due to injury to the cord, C. H. Frazer (Surg., Gyn. and Obst., xvi, 1913) removed the laminæ of the twelfth dorsal and the first and second lumbar vertebræ, divided the first lumbar anterior root at its point of exit from the cord, divided the third and fourth sacral roots, and did an end-to-end anastomosis with fine silk between the lumbar and the two sacral roots. The sacral roots to be used were identified by the electric current. The nerves functionated and the patient regained urinary continence.

Tapping the Arachnoid Space (Lumbar Puncture).—For the technic of the operation, see Spinal Anesthesia, Vol. I, page 155.

This operation is done for purposes of introducing medication into the subarachnoid space, for withdrawing fluid for therapeutic and diagnostic purposes, and for cleansing.

Subarachnoid puncture is useful in cerebrospinal meningitis. The cerebrospinal fluid, if rich in pus may be drawn off to advantage and replaced

with salt solution or antimeningococcus serum. As much as 60 c.c. of the purulent fluid have been withdrawn by lumbar puncture. This procedure is more fully discussed under meningitis. In tumors of the brain, lumbar puncture is so dangerous that it should rarely be undertaken.

Spina Bifida.—The prognosis is very unfavorable. Most cases die, with or without treatment. The tendency of the tumor is to increase in size. Ulceration and perforation of the thin wall is common. If the child survives the first few weeks, paralyses are apt to prove intractable. The cases which survive five years are usually meningoceles. Myelomeningoceles are usually fatal. Even though a closure of the cleft is accomplished by operation, death may result from increase of cerebrospinal pressure or paralyses. Hydrocephalus, complicating the disease, is the more important of the two; if it is not remedied, it is not worth while attempting operation for the spina bifida.

Meningoceles are most hopeful for operation, but both myelomeningoceles and myelocystoceles may be helped by operation if not cured. Without such treatment the prognosis is positively bad. When ulceration of the skin is present it should be cured if possible before the sac is incised; if it is not cured it may be sterilized by phenol or tincture of iodin.

For *operation*, the patient should lie on the side on a table which permits quick lowering of the head. Any ulcerated area should first be excised before opening the sac. An incision should be made about the base of the tumor, planned to remove an ellipse of skin of such a size as to permit easy coaptation of the wound edges. The skin should be dissected free outward from the sac. The sac should then be dissected free down to its pedicle. In large myelocystoceles a considerable portion of the sac can be removed without harm. In meningoceles, after dissecting free the sac, it should be opened by a longitudinal incision placed so as to avoid the nerves as much as possible. Usually this incision will be on the side. This gives a view of the interior of the sac.

Any nerves running in the sac wall should be dissected out or that part of the sac should be isolated and replaced in the vertebral canal. Nerves which are not trunks but which seem to end in the sac need not be preserved. If there is any question as to their importance, their distribution may be tested by a mild faradic current. Rather than take time to dissect out nerve trunks, it is best simply to save that part of the sac. The sac wall should be cut laterally in such a way as to give enough tissue to close the canal. This closure should be made snugly and smoothly, apposing the inner surfaces. It is desirable that there should be no leakage of fluid. A running suture of chromicized catgut is best.

Myelocystoceles may be opened in the middle line or where the wall is thinnest. Care should be taken that the cauda equina shall not be damaged. In opening the sac, the cerebrospinal fluid should not be permitted to escape too fast. At this stage of the operation it is well to lower the head of the table, and to obstruct the flow by a sponge or by pressure at the neck of the sac.

It is probably not worth while to attempt closing the bony defect by osteoplastic methods. Recurrence will take place if there is obstruction or other disease which causes hydrocephalus. If hydrocephalus is present closure of the spina bifida will probably make it worse. The skin having been dissected free laterally, the superficial layer of the deep fascia is exposed, and by lateral incisions liberated so that it may be sewed across the middle line to support the closed sac. In this part of the operation it is often possible to liberate a bundle of muscle on either side and place it also over

the spinal opening. It is best to plan the skin incision so that when the skin is sutured the line of closure lies to one or the other side of the suture of the fascia. A subcuticular suture is best for the skin, and a collodion covering to prevent soiling.

The operation is apt to be attended with serious depression. It should be done with despatch and every effort made to save blood and prevent shock and rapid loss of cerebrospinal fluid. Infection occurs easily. Hydrocephalus, even though not observed before operation, may develop apparently as a result of slow infection. The mortality following operation is about 50 per cent., and is due to shock, meningitis, hydrocephalus, and paresis. Paralysis of the lower extremities, rectum or bladder are not apt to be cured by operation. The operation entails certain risks, and offers the removal of an unsightly and uncomfortable tumor and obviates the danger of its spontaneous rupture and infection. Its advantages outweigh its disadvantages. Paralysis is an indication for operation. Hydrocephalus cannot be regarded as a contraindication. If the tumor is not growing larger and is causing no serious symptoms, operation may be deferred until the child has reached the sixth or twelfth month of age.

In cases in which the meningocele has been controlled and the patient is left with defect of the posterior wall of the spinal canal, which causes weakness and lordosis, the spine may be strengthened by inserting a long bone graft on either side according to the method used by Albee in spinous process fixation.

Spondylolisthesis.—If the disease is recent and due to traumatism, a jacket, corset or brace is indicated to prevent the forward curvature. In congenital cases, massage, vibratory massage, and position to prevent the deformity are indicated, and may be expected to control the disease.

Rachitic Spine.—The constitutional treatment is most important (see Rickets, page 321). The correction of deformity is accomplished by the same measures as are applied to spondylitis. For kyphosis the child should be placed in a position of extension of the spine and put in a jacket or brace. The support should be removed once or twice daily and massage applied. Active motions to strengthen the erector spinæ muscles should be practised. Hyperextension should be applied at the same time. In pronounced cases treatment on the horizontal frame is indicated.

Lumbago (Lumbosacral Pain, Painful Back).—The scientific treatment of this condition aims to discover and remove the cause of the pain; but often after everything in this direction has been done, the symptoms persist. Then if motion causes pain, rest should be secured by confinement in bed, or by a brace or corset of plaster-of-Paris, fixing the pelvis and lumbothoracic spine. Some patients obtain comfort by the tight envelopment of the pelvis in a broad strip of adhesive plaster. Counterirritation is of much help in some cases.

The search for the cause should never be abandoned. There is a wide range of difference between the treatment of aneurism of the aorta and fatigue in a neurasthenic, both of which give rise to lumbago. Fracture of the transverse process of a vertebra, curvature of the spine, and disease in the psoas muscle should be corrected. Examinations during intervals of freedom from pain should be made to find the tender point. Even when disease of the vertebra cannot be found, an immobilizing jacket often gives relief. When the cause is not known, hot applications (either moist or dry) offer the best chance of relief. Massage and vibratory treatment are also effective.

At the old Chambers Street Hospital in New York, we treated these cases with the actual cautery. The metal, heated to a cherry red, was rapidly waved back and forth over the affected area, as children play with a fire stick to make the appearance of streaks of fire in the air. The hot point in its rapid movements was brought nearer and nearer to the skin, occasionally touching it, as indicated by the patient's jumps, the faint cloud of smoke, the odor, and the series of long, slightly curved red stripes, which told the story of treatment well administered. Our percentage of cures seemed to be very high, because the patients were told to come back for another treatment if there was any return of the lumbago, and I do not recollect that any ever returned.

Kyphosis.—Non-tuberculous kyphosis, usually habitual and called "round shoulders," requires correction of the cause such as weak feet, and then treatment by forcible extension of the flexed portion of the spine.

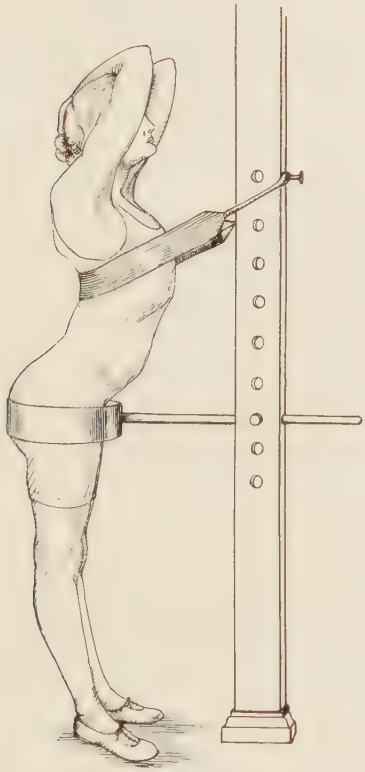

Fig. 1043.—Exercises for the Correction of Curvature of the Spine.

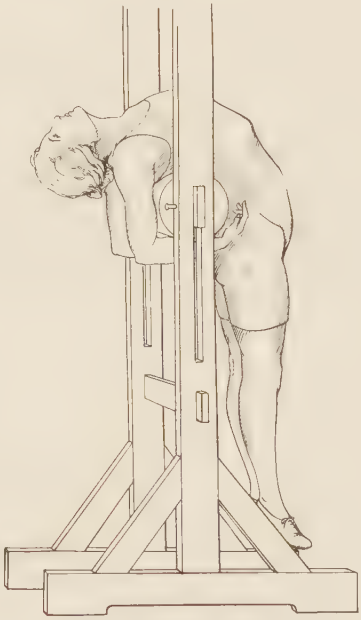

Fig. 1044.—Extension Exercises for Kyphosis.

This is best done over the edge of a table. Forcible correction under anesthesia is required in advanced cases. Massage to strengthen the erector spinæ muscles is of help. Exercises to stretch the contracted ligaments are of service (Figs. 1043 and 1044). Heavy clothing should not be hung from the shoulders. The erect position in standing should be encouraged. By having the patient to lie prone when reading, extension of the spine is secured. A light brace may be used at times during the day, but never constantly. Such exercises as are employed in the treatment of scoliosis are of service (see below).

Lordosis.—The treatment of this symptom should be directed to the cause. When this has been done some relief may be secured by a jacket or brace, applied in the position which is secured by having the patient lie on the back with the thighs flexed.

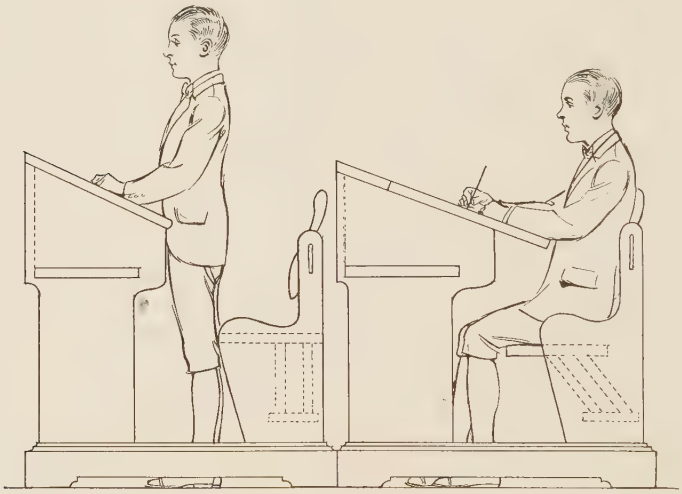

Fig. 1045.—School Desk which is Adjustable to Standing and Sitting Postures.

Scoliosis (Lateral Curvature of the Spine).—Prophylaxis has much to offer. The causes should be avoided and corrected. Among these are to be noted: (1) deformities in other parts, such as shortening of one leg; (2) unequal paralyses of muscles of the back; (3) distorting thoracic disease,

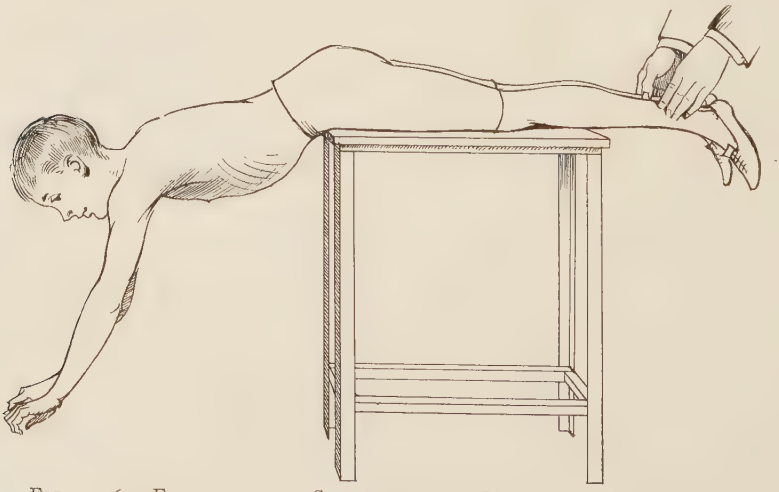

Fig. 1046.—Exercises for Strengthening Muscles of the Back.

such as empyema; (4) distorting disease of the spine, such as spondylitis or fracture; (5) bad habitual posture; and (6) rickets. Posture in the young is most important. Correct school desks and seats should be insisted upon (Fig. 1045). Improvement of the general health and the local tone of the

muscles of the back are essential, and best accomplished by work in the open air which requires the use of all the muscles of the back up to the point of fatigue. If this cannot be done then gymnastic exercises may be used (see Teschner: Annals of Surgery, Vol. XXII, page 230).

Heavy dumb bells are of service. Muscle-building exercises are used, especially applied to the back muscles. The patient is held prone with the body above the groins projecting over a table and caused to extend the spine as many times as possible (Fig. 1046). He is caused to stand and bend downward and upward (Fig. 1047), and to flex the spine laterally as far as possible (Fig. 1048). A tendency to recur between treatments should be overcome by a corset, applied with the patient suspended (see Spondylitis, page 332) and with lateral bandages so applied as to make pulling pressure

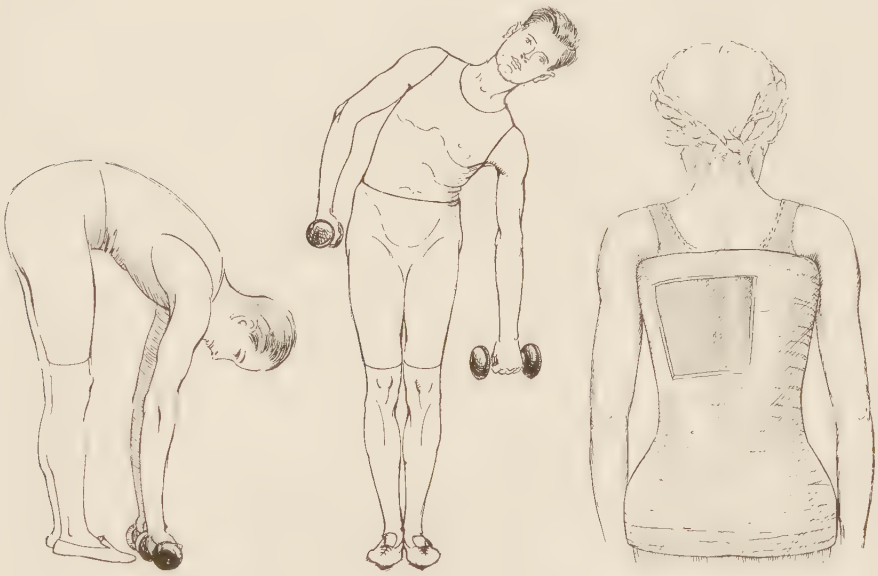

Fig. 1047. Fig. 1048. Fig. 1049.

Fig. 1047.—Exercises for Strengthening Extensor Muscles of Back.

Fig. 1048.—Lateral Bending Exercises to Strengthen Muscles of the Spine.

Fig. 1049.—Plaster-of-Paris Jacket for Treatment of Curvature of Spine. The jacket may be reinforced by a steel brace. The window is cut on the concave side.

upon the convexities. The corset should be removed for treatment daily, and reapplied with the patient suspended. It should be worn only at such times as the patient is in repose and apt to relapse into scoliotic positions (Fig. 1049).

Self-suspension, in the suspension apparatus used for applying spinal supports, aids in straightening the spine. The inclined plain seat, raising the side of the pelvis so as to overcorrect the curvature is of service and may be used in all of the patients' sitting places (Fig. 1050). The same correction may be secured in the standing position by a lift of 1.3 to 4 cm. (½ to 1½ inch) under the shoe. The correcting corset may be worn at night; or in its place the patient may lie recumbent in a plaster-of-Paris bed-trough.

The treatment of *functional* or *postural scoliosis* requires especial attention to the general hygiene of the child. The weight of the clothing should be taken from the shoulders. Clothes should be suspended from the waist.

Errors in vision should be corrected. The corrective gymnastic exercises are most important.

Treating *organic* or *structural scoliosis* is a more difficult matter. It should be borne in mind that while there are changes in the bone contour bone may be made to change its form also in the direction of correction. The spine should be forced into normal position and held there while nature makes the changes in the structure of the bone. Gymnastic exercises have little to offer in pronounced cases any more than they would have in a case of club-foot or knock-knee. Gymnastics may be used alone in slight curvatures to restore flexibility and strengthen the muscles on the convex side. A support should be used to hold what is gained. In these cases jackets are necessary.

Fig. 1050.—Lateral Inclined Seat for Scoliosis.
The dotted line shows the curvature which is present when the pelvis is level. The overcorrection is secured by tilting the pelvis.

The method of treating scoliosis devised by E. G. Abbott (Monde Médical, February, 1915) has given better results than have been secured by most other methods. The principles laid down by Abbott are that overcorrection must first be made, and that lateral correction is best secured in the flexed condition of the spine rather than in the extended condition. For this purpose the patient is placed in a hammock with the vertebral joints all flexed, while lateral correction is made (Fig. 1051). A plaster jacket is then applied as the child is held in the overcorrected position. This jacket has a large decompression window on the back and side (Fig. 1052). This window is over that part of the chest which it is desired should be moved toward the opening. Two anterior loop-holes are made and one posterior loop-hole (Figs. 1053 and 1054). The jacket grasps the pelvis firmly.

Through the anterior loop-hole strips of felt padding are introduced to overcorrect the deformity. The great opening permits the displacement

necessary (Figs. 1055, 1056 and 1057). This correction may go on gradually as the state of the patient permits. The patient is allowed to be about.

The removal of the jacket at the end of two months may be followed by the application of another if the desired overcorrection is not found. When satisfactory overcorrection is secured a removable celluloid or other thin jacket is applied, to hold what has been gained, and gymnastic exercises inaugurated (Figs. 1058 and 1059).

Hysterical Spine (Neurotic Spine).—The treatment of this condition rests upon accurate diagnosis, the removal of causes, and the treatment of the neurosis (see Traumatic Psychoses, page 102).

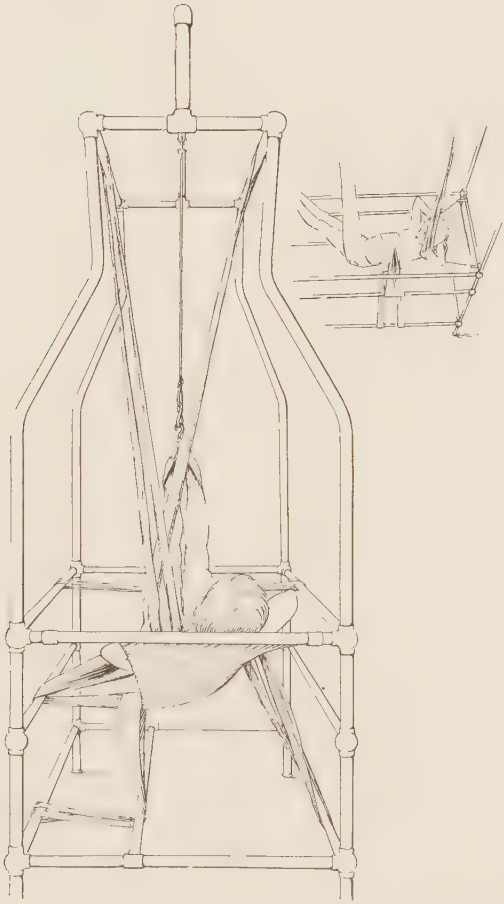

FIG. 1051.—HAMMOCK FOR FLEXION OF SPINE AND LATERAL CORRECTION.

Diseases of the Sacro-iliac Joint.—*Tuberculosis* requires rest and protection. This can be secured best by recumbency. The only splint that is effective must fix the thorax and pelvis and cause the weight of the body to be transmitted to the axillæ while standing, walking or sitting. Because of the difficulty of immobilization, perhaps, the best treatment of this condition is exposure of the joint, resection or erasion, and local treatment with iodoform or other antitubercular agent and artificial hyperemia.

FIG. 1052.—CORSET WITH DECOMPRESSION WINDOW OVER RIBS WHICH WERE FORMERLY DEPRESSED.

FIG. 1053.—DECOMPRESSION CORSET.
Showing anterior openings.

Sprains or *relaxation of the ligaments* occurring as a result of injury, long confinement in bed, childbirth, or obliteration of the natural lumbar lordosis, should be treated by correction of position in a plaster jacket, by avoidance of the positions or movements which give pain, by rest in bed if due to violent

Fig. 1054.—Decompression Corset.
Side view.

traumatism, and by massage and artificial hyperemia if due to constitutional weakness. A broad snug band of adhesive plaster about the pelvis gives relief in some cases.

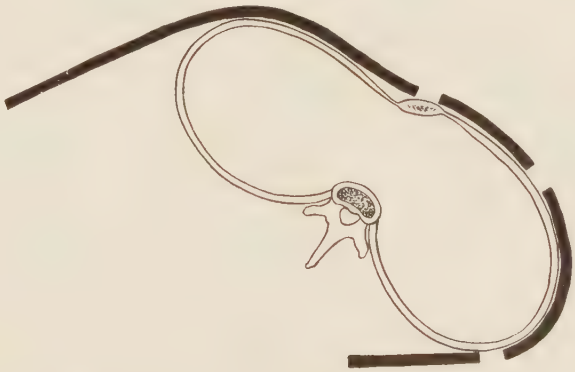

Fig. 1055.—Section Showing Openings in Decompression Corset.

Coccygodynia (Coccygeal Neuralgia).—In a few cases a constitutional or local cause may be discovered and removed. Tumor, constipation, sacrococcygeal joint disease, or nerve disease may be reached. Often there is a displacement of the coccyx and undue mobility. Relief may often be

secured by vibratory massage. The most effective treatment is massage by means of the index-finger in the vagina or rectum and the thumb on the outside, holding the coccyx and the sacrococcygeal joint between them. The bone should be moved up and down and the soft parts should be moved on the bone and joint. At first the manipulations should be very gentle; the force may be increased as the pain becomes less. A few treatments every other day will cure most cases.

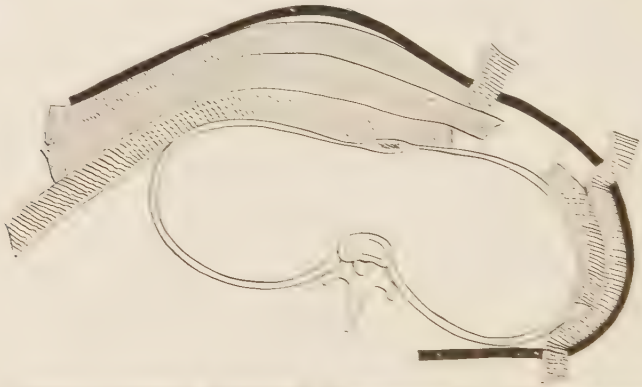

Fig. 1[illegible].—Section Showing Moderate Compression in Decompression Cursus. The pressure is made [illegible]

There are a certain number of cases which yield to injections of alcohol. The patient, with the rectum empty, lies in the lateral pelvic position, with the thighs flexed on the abdomen. A syringe containing 1 c.c. (15 minims) of 70 or 80 per cent. alcohol and having a 5-cm. (2-inch) needle is used. The index-finger is inserted in the rectum and the place of greatest tenderness is



Fig. 1[illegible].—Section Showing [illegible] Correction in Decompression Cursus.

discovered by pressure between the thumb and index-finger. The needle is inserted in the skin in the median line and the point passed to the painful point, and the contents of the syringe injected. This operation should be repeated every week. From two to six such injections are used. Each injection should be made in the most tender spot.

Removal of the coccyx should be done if the above methods fail. This

is done with the patient on the side with the thighs strongly flexed or on the back with the pelvis elevated and the thighs flexed. An incision is made in the middle line from above the last sacral vertebra to the tip of the coccyx. The soft tissues are divided down to the bone and strongly retracted laterally. The lateral muscular attachments are divided close to the bone. The

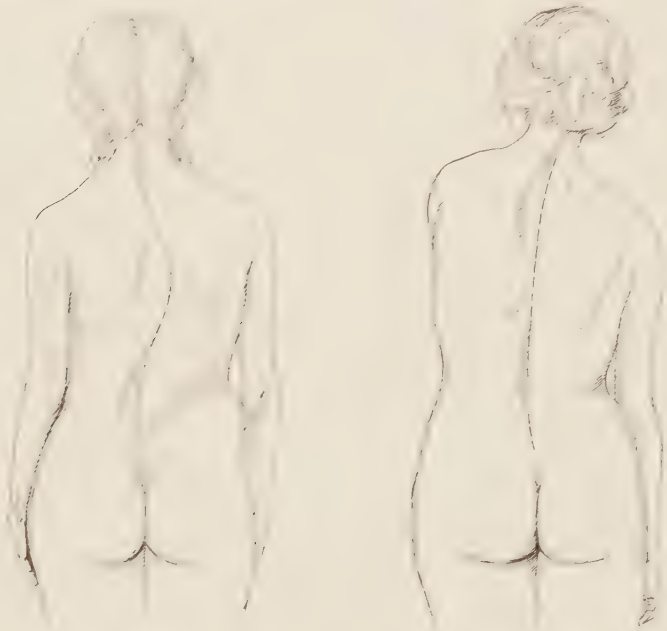

Fig. 1058. Fig. 1059.

Fig. 1058.—Scoliosis in Girl of Seventeen.

Scoliosis of four and a half years' duration, before treatment by forcible correction and continuous overcorrection with corset.

Fig. 1059.—Scoliosis in Same Girl after Four Months' Treatment.

connections to the sacrum are cut, bearing in mind the two cornua. The bone is then grasped with forceps, and with curved scissors its superior and terminal connections are separated. The wound is closed by deep sutures to obliterate the cavity, and the skin is closed with a subcuticular suture. Prompt and permanent relief is secured by the operation.

THE NECK

General Injuries.—*Cut-throat, with wound of the air passages*, when no large vessels are cut, is serious because of the danger of cellular infections and of pneumonia. The insufflation of blood may cause dyspnea. For these reasons prompt closure of the wounds is imperative. The wound should receive the treatment already described for wounds (Vol. I, page 186). Each divided structure should be identified and separately sutured. Any penetrating wound of the trachea, larynx, or esophagus, should be sutured independently, best with fine chromicized catgut. These structures should be snugly closed so that leakage may not occur either from within or from without (see Wounds of Larynx and Trachea, page 219). *Wounds of the esophagus* should be closed with two layers of suture, and the overlying connective tissue should be sutured so as to obliterate cavities. A small drain may be placed in the most dependent part of the wound. If the wound of the esophagus is a punctured wound or bullet wound, the danger of infection of the deep cellular structures of the neck is so great that it is usually best to enlarge the opening down to the esophagus, suture the esophageal opening and place a drain down to the esophagus.

Cut-throat, with wound of blood-vessels, is serious even though the vessels are not large. Aside from the dangers of infection, even small vessels, such as the lingual, thyroids, or facial, may lose an amount of blood which is fatal. They should be ligated at once on either side of the wound. *Wounds of the carotid artery* or *internal jugular vein* are fatal unless the bleeding is checked within a few seconds. In the case of these large vessels life may be saved by prompt occlusion of the vessel. Pressure should be made at the anterior edge of the sternomastoid muscle and applied backward so as to press the vessels against the transverse processes of the cervical vertebræ and their muscles. Occlusion of both distal and proximal sides of the vessel wound should be secured. If external pressure is not promptly effective, the thumb or two fingers should be introduced into the wound and pressed directly against the bleeding place. The hemorrhage being controlled, the pressure should be continued while the parts are cleansed and the vessel exposed, if necessary, by incisions above and below the bleeding point (see Ligation of Carotid, Vol. I, page 406). Or pressure may be made above and below the wound and the vessel dealt with directly in the wound.

After exposing the vessel on either side of the wound, it may be ligated in two places or sutured (see Wounds of Vessels, Vol. I, page 334).

In these wounds the surgeon should beware of a sense of security arising from a cessation of bleeding from pressure alone. A clot may temporarily occlude the wound, but infection and an increase of blood-pressure are apt to produce secondary hemorrhage. The ligature or suture of vessel wounds and drainage of the infected overlying tissues are the essentials. Large cut-throat wounds may be closed, leaving ample provision for drainage. Each divided structure which can be identified should be separately sutured. The mistake should not be made to thrust clamps into the depths of the wound and blindly grasp for bleeding vessels.

Wounds of Nerves of the Neck.—These injuries may require treatment in cut-throat, bullet or other wounds and in operations. The presence of the wound may become known only through the resulting paralysis. The

important nerves which may require attention are the pneumogastric, hypoglossal, phrenic, spinal accessory, recurrent laryngeal, and the brachial plexus. Division of these nerves should be treated by free exposure of the nerve and suture (see Suture of Nerves, Vol. I, page 852). None of these are so important that their suturing need be regarded as a matter of emergency, but as soon as the patient's condition will warrant, the nerve should be sutured.

Wounds and Diseases of the Thoracic Duct.—It should be borne in mind that, while usually the duct empties in the left subclavian vein, it may empty on the right side or on both sides. A mouth on either side may account for some of the successes secured after injury or destruction on one side. When the duct is opened in the neck the outflow of chyle is so great as to seriously interfere with nutrition, and it must be checked. The method most in favor consists in packing the wound tightly to occlude the outflow. In the cases which have been cured by this method, it is not known whether the chyle found its way into the proximal segment of the wounded duct or whether the duct became wholly occluded; perhaps the latter is the case, and accessory mouths emptied the chyle into other vessels.

Compression by packing should be given the first trial. If the patient is losing a serious amount of chyle, despite packing, and there is deficient nutrition, great thirst, weak heart, emaciation, or syncope, ligation of the duct should be done to stop the waste. When this is done it is hoped that there is another outlet into another vein; commonly there is. This is so often the case that some surgeons regard immediate ligation as the operation of choice. The ideal operation, of course, would be suture of the wounded duct or implantation of the duct into a vein. These operations have been attempted, but it is doubtful whether they have succeeded in their aim.

In dealing with *rupture of the thoracic duct in the thorax* or *abdomen*, aspiration is called for to remove the chyle from the pleural or abdominal cavities. Such cases have recovered after repeated aspirations. When the chyle does not pass through the pleura or peritoneum, but dissects its way in the connective tissue, it does not require treatment unless its pressure causes serious disturbance. If it bursts through the skin in the neck, groin or elsewhere the sinus should be kept well protected against infection.

In *septic infection of the receptaculum chyli*, a transperitoneal exposure of the viscus may be made, gauze packing introduced to provoke protective adhesions, and after two days the infected viscus opened and drained.

Emphysema of the Neck.—The treatment of this condition is not different from that of emphysema elsewhere. The causative lesion should be remedied. The surgeon should be ready to perform tracheotomy or intubation for swelling of the glottis. The swelling tends naturally to subside.

Infective Processes in the Neck.—*Cellulitis and abscess of the neck* should not be put off with palliative or tentative treatment. Free incision into the infected area is the one and imperative thing to be done. This is urgent because of the dangers of deep phlegmon of the neck. An indurated area in the neck should be exposed by incision if it is associated with symptoms of infection. The surgeon should not wait for swelling or redness of the skin as may be done in other parts of the body. The incision should not be made blindly but should be a dissection down to the center of the infection. It may be made in front of the sternomastoid muscle, behind it, or through it, preferably in the lines described for operations upon the neck (see Anatomy of Neck, Vol. I, page 404; Operations on the Neck, below).

Having reached the infected area, the dissection should be continued downward to secure drainage of its lowest limit. This is important, even

though the operation be carried to the sternum or clavicle. Pus may not be discovered, but the operation is more timely and effective if it is not. A continuous skin incision need not be made, the lower opening may be independent. There is always danger that the surgeon may stop short on one side of a plane of fascia when infection lies on the other side. Unless the infection is reached, uncovered and drained a fatal invasion of the thorax may result. The dissection should be largely a blunt dissection, done with round-pointed scissors, artery forceps, or the handle of the scalpel. Gauze, wick or rubber-tube drainage should lead from the infected regions (Fig. 1060). In *superficial cellulitis* the operation should be done because of the danger of deeper extension.

In *Ludwig's angina* (sublingual phlegmon) the operation is necessary to save life. The incision should be just below the border of the jaw. It should expose the submaxillary salivary gland, and extend through the mylohyoid muscle.

Fig. 1060.—Incisions and Drainage for Deep Cellulitis and Abscess of Neck.

In *ligneous induration* (woody phlegmon) incision seems to have little effect in shortening the course of the disease; nevertheless it is the rational procedure. The disease, being due to impairment of resistance to infection, is naturally chronic, and should not be confused with neoplasm. The tendency is toward recovery. After the mass has been incised freely to its depths, and drainage provided, wet, hot applications are most useful. Excision of the infiltrated tissues may be practised in some regions. Autogenous vaccines may be employed.

In these infections of the neck, the surgeon should be ready always to do a tracheotomy or intubation. This same condition of woody phlegmon may occur in other parts of the body and require the same treatment as here described.

Diseases of the Lymphatics of the Neck.—These diseases are usually secondary to lesions in other structures.

Anatomy of the lymphatics of the neck should be had well in mind, as they lie in intimate relation with the important structures. The *retropharyngeal glands* lie between the pharynx and vertebræ, and drain the nasopharynx and middle ear. The *occipital glands* receive lymph from the posterior part of the scalp. The *retro-auricular glands* drain the outer ear and auricular region of the scalp. The *parotid glands* lie in the substance of the parotid salivary gland and adjacent to it, and drain the ear and temporal region. The *subparotid glands* lie between the parotid and the pharynx, and drain the lateral pharynx and posterior nasal region. The *submaxillary glands* lie in a chain below the lower border of the lower jaw, and drain the cheek, lips, nose, gums, and sides of the tongue. One of these glands is closely adherent to the submaxillary salivary gland. The *submental glands* are just below the symphysis of the lower jaw, and drain the tip of the tongue, middle of

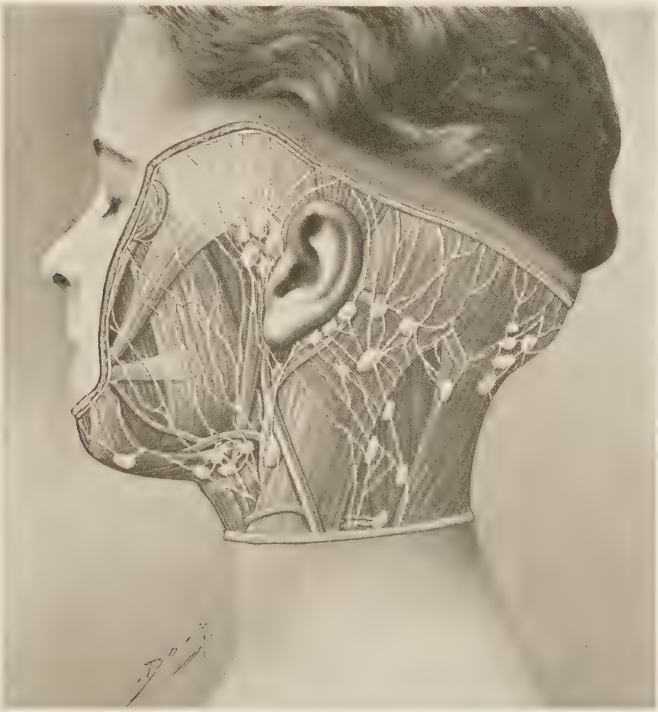

Fig. 1061.—Lymphatics of the Neck. Upper Chain.

the lower lip, gum and chin. The above-described groups of glands represent a horizontal chain or collar encircling the upper part of the neck. From this collar lymph-vessels pass downward to empty into a descending chain which follows the internal jugular vein, and empties into the thoracic duct near its termination.

The *internal jugular glands* (descending or substernomastoid glands) not only drain the upper group or collar, but also receives special tributaries from the same regions as are drained by the upper group. Independent glands are also scattered about the neck in the posterior triangle. The *supraclavicular glands* are located in the angle bounded by the clavicle, sternomastoid and trapezius, and receive tributaries from the scalp, neck, shoulder, upper arm, axilla, breast, and the interior of the thorax (Figs. 1061 and 1062).

Carcinoma of the Lymphatics of the Neck.—Operation for this condition is called for in carcinoma of the tongue, lip, cheek, jaw and other regions of the head. In carcinoma of the tongue and lip it should be done as a routine (see Treatment of these Diseases and Regions). The operation performed as adjunct to that for carcinoma of the tongue will be described. In cases

with palpable carcinomatous glands of the neck, it is best to operate on the neck first, and the tongue a few days later. If the condition of the patient seems good the tongue operation may follow at once. The radical operation should be done.

The patient is placed on his back with a sand pillow behind the shoulders and the face rotated away from the diseased side. A curved incision is carried from the middle line below the chin along below the lower jaw back to the tip of the mastoid process, thence the incision curves downward along the anterior border of the sternomastoid muscle, and backward along the upper border of the clavicle as far as the middle third of the bone (Fig.

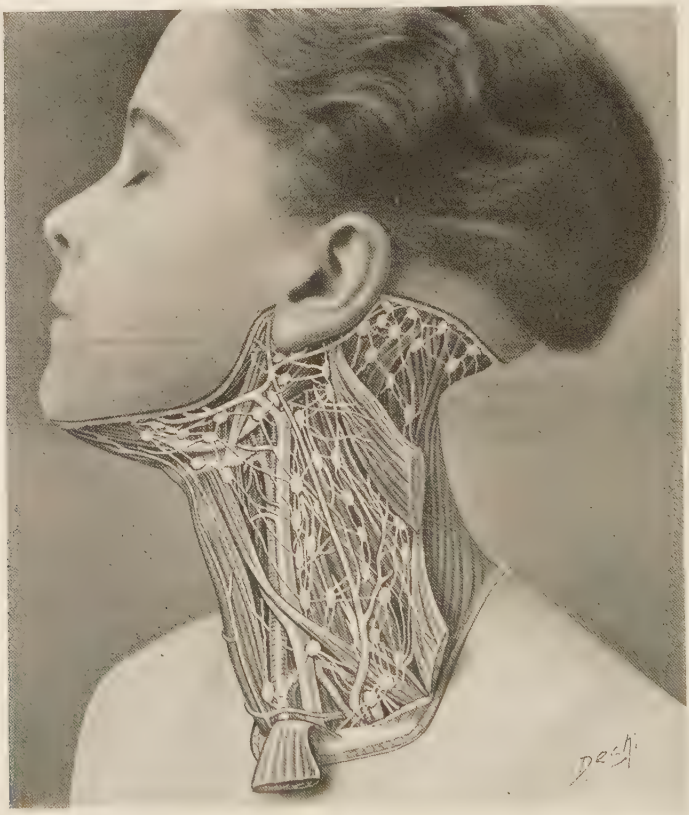

Fig. 1062.—Lymphatics of the Neck. Deep Chain.

1063). The anterior flap is dissected up, care being taken that it consist only of skin in the submental and submaxillary regions and along the upper part of the external jugular vein. The thin flap is important because in these regions are glands which lie close to the skin. The digastric triangle is then clearly dissected out, all of the fat and loose connective tissue being removed. A gland is often found between the outer edge of the mylohyoid and hyoglossus muscles. The deep fascia covering the submaxillary gland is then opened and the gland retracted forward. The facial artery is tied and cut. The dissection of the digastric triangle is then completed, the dissection being carried up over the lower border of the jaw and some of the facial fat removed. The back part of the digastric triangle, posterior

to the stylomaxillary ligament, is cleaned out. The lower portion of the parotid gland, which often encloses glands, is removed, also the subparotid glands. The anterior triangle of the neck is then dissected out from before backward. This means a systematic removal of the loose fatty and connective tissue, enclosing the lymphatics, lying on the muscles and fasciæ.

When the anterior border of the sternomastoid is reached, the posterior flap is dissected free. The sternomastoid is divided at the level of the omohyoid and the lower portion is turned down. The clearing out of the anterior and posterior triangles from below upward is proceeded with. The fascia covering the great vessels is dissected up in this operation, and the dissection is continued upward beneath the parotid gland. The dissected-up contents of the triangle are kept together with the upper part of the sternomastoid muscle, and the whole mass is cut off together with the muscle at its insertion. This mass of tissue contains the chain of internal jugular glands. To make

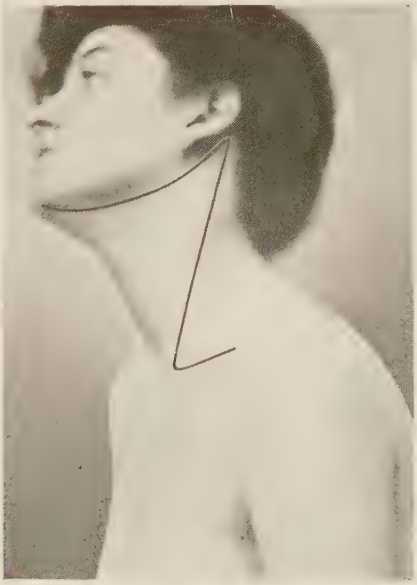

Fig. 1063.—The Z-Incision for Exposing the Lymphatics of the Neck.

sure of the removal of this most important chain of glands, the internal jugular vein must be removed.

A less wide exposure is secured by carrying an incision from the mastoid process to the sternoclavicular joint along the anterior border of the sternomastoid muscle, and a second incision from the bottom of the symphysis of the lower jaw downward and backward to meet the first incision at the level of the upper border of the thyroid cartilage (Fig. 1064). The sternomastoid muscle is cleaned off and retracted backward. The anterior triangle is dissected out from below upward, followed by dissection of the digastric and submental regions.

In operating for cancer of the tongue the anesthetic is best administered through two tubes passed to the pharynx through the nostrils, the back of the mouth being packed with gauze. Blood may be saved by temporarily clamping the carotid low down and high up with soft arterial clamps. The structures of the neck are best removed in one mass. The common carotid



FIG. 1064.—SINGLE INCISION FOR EXPOSURE OF LYMPHATICS OF THE NECK.

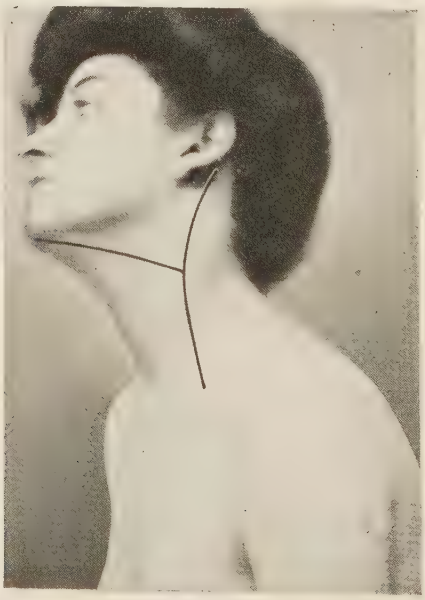

FIG. 1065.—DOUBLE FLAP INCISION FOR REMOVING LYMPHATICS OF THE NECK IN OPERATION FOR CANCER OF THE TONGUE.

is exposed by an intermuscular incision above the clavicle, and the temporary soft clamp applied. An incision is made below the lower jaw from the chin to the mastoid process. A second incision is begun at the angle of the jaw and carried down to the junction of the inner and middle thirds of the clavicle (Fig. 1065). The flaps are reflected back to expose the anterior and digastric triangles and submaxillary and internal jugular regions. The sternomaxillary muscle is divided near the clavicle; the internal and external jugular veins are tied at the base of the neck and divided. The dissection is then carried upward, dissecting free everything external to the deep plane of the

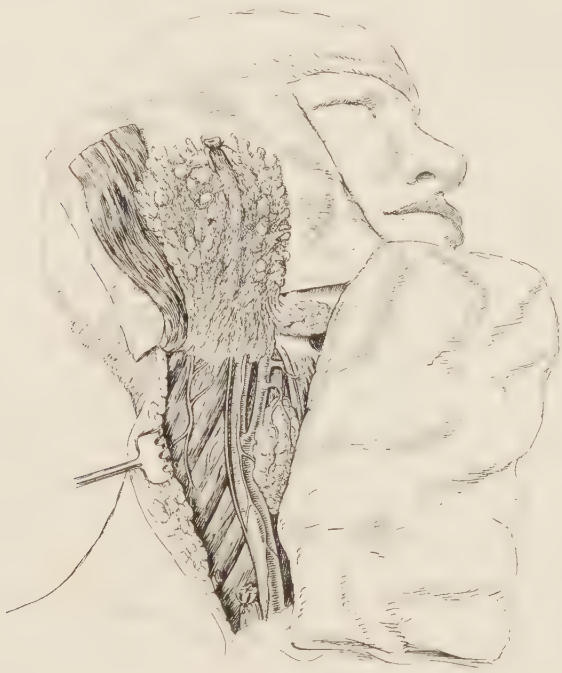

Fig. 1066.—Dissection Upward of Lymphatics of Neck.
Folded towels or gauze protect the environment. The internal jugular vein has been dissected out with the glands and connective tissue.

neck. All the fascia, the muscles, veins, fat and connective tissue are dissected free up to the floor of the mouth (Fig. 1066). If the operation is for cancer inside of the mouth, the jaw is then divided, and the diseased focus extirpated along with the cervical mass. The pneumogastric nerve is not injured. The clamps are removed from the carotid as soon as possible. If the growth is not extensive and no operation is to be done in the mouth, the dissection may be made from above downward (Fig. 1067). The sternomastoid muscle may be preserved and sutured back in place, although its loss does not cause any considerable disturbance of function (Fig. 1068).

In any of these operations if deeper structures are found involved in disease which must be removed to effect a cure they should be excised. Such excision may involve not only the internal jugular vein, but the carotid and vagus nerve as well.

Operations on the Tonsil and Pharynx Through the Neck.—Tumors of the tonsil, pharynx and the adjacent regions may be reached by operation

laterally through the neck, called *lateral pharyngotomy*. An incision is made along the upper half of the anterior border of the sternomastoid muscle. A second incision is carried forward from the upper end of the first below the lower jaw for about 8 cm. The deep fascia is divided and the muscle retracted backward. By drawing aside the great vessels and nerves the wall of the pharynx is exposed. With retractors in place the pharynx is opened and the disease attacked. If this does not give room enough the jaw may be sawed through between the second and third molar teeth. This is the most satisfactory approach to tonsillar neoplasms. After the operation the wound may be partly or completely closed. The safest

Fig. 1067.—Dissection of Lymphatics of Neck.
Dissection from above downward. The mass of glands and connective tissue is placed on a pad of gauze as the dissection proceeds.

method is to suture the mucous membrane, partly close the external wound, and insert a drain down as far as the mucous membrane.

Tuberculous Lymph Glands of the Neck.—The general treatment of tuberculous adenitis of the neck should be the same as that for tuberculosis in other regions (see Tuberculosis, Vol. I, page 276). Most cases should be cured by general treatment.

The first step in treatment is to improve the hygiene of the patient. It may be assumed that a healthy person does not develop tubercular glands of the neck. Diseases of the tonsils, teeth, and adenoids should be corrected. The patient should live out of doors and in the sunshine. The value of tuberculin and the *x*-ray is probably not inconsiderable. Surprisingly good results are secured by *x*-ray treatment.

Small glandular swellings should always be expected to disappear under appropriate treatment. When the glands become fairly large, or if the

general resistance of the patient is not good, or if the disease is clearly progressing, operative removal of the glands is called for. Operation offers the advantage that it expeditiously removes the tuberculous focus, which is always a hazard, and leaves less scar than will remain if the glands are left to break down without surgical treatment.

Usually after removal of tuberculous glands the health of the patient improves. If all of the infected glands have been removed the patient is cured, but there is no guarantee that reinfection of other glands may not take place just as before. If all the tubercular glands are not removed the tendency of the remaining glands is to continue to grow and ultimately demand operation. Recurrence is common after these operations if

FIG. 1068.—DISSECTION OF NECK.
Structures sutured to close deep wound after removal of lymphatics. The platysma is sewed to the sternomastoid muscle.

all of the infected glands were not removed. So large a percentage of these patients ultimately succumb with tuberculosis of other organs that the operation should be made much more thorough and the disease thought of more seriously than it has been. If cellulitis or sinuses are present, the non-tuberculous infection should first be cured before an extensive dissection is attempted.

K. Ewald (Wiener Klin. Woch., xxiii, Nos. 35 and 36), reviewing a large experience, came to the conclusion that most of these cases are better off not to be operated upon. He advised operating upon only single isolated, unchanging glands which have persisted for years. Opening up the lymph spaces, he claims, in the ordinary case, spreads the infection, and recurrence is the rule. He employs general hygienic and antitubercular measures. If the glands become soft and cheesy, the broken-down matter should be gently curetted out, but other tissue should not be attacked.

T. von Mutschenbacher (Beiträge zur klin. chir., September, 1912, vol. 80), basing his opinion on 1344 cases treated in four years, concluded that treatment should be absolutely conservative or absolutely radical. Systematic constitutional and antitubercular treatment is most important. If a gland breaks down, its contents should be aspirated through the smallest needle possible. The cavity should then be injected with iodoform-glycerin. Such an injection should be made every third or fourth day. Five or six such treatments will heal most such foci.

This conservative treatment is coming to be more and more accepted by surgeons who once operated upon all of these cases as a routine measure.

The *technic of operation for tuberculous glands* is similar to that for carcinomatous glands, excepting that in tuberculosis it is not so important that impalpable glands shall be removed. The incisions may be similar. Inasmuch as tuberculosis is more common in the young and hopeful, the cosmetic

Fig. 1069.—Posterior Incision for Dissection of Tuberculous Glands of the Neck.

This incision is placed posteriorly within the hairy scalp.

results must be considered, and the scar should be as small and inconspicuous as possible. Usually it is not necessary to carry the submaxillary incision farther forward than a point midway between the angle of the jaw and the symphysis of the chin. An incision which leaves a less conspicuous scar begins on the side of the neck just below the jaw, passes backward below the tip of the mastoid process to the hairy scalp, thence curves downward and then forward and passes along above the clavicle as far forward as necessary. It may end at the middle of the lower end of the sternomastoid (Fig. 1069). Another useful incision is made transversely, and lies about 2 cm. (¾ inch) below the angle of the jaw.

Whatever incision is used, the skin is turned back with the platysma, and the sternomastoid and deep fascia are exposed. The muscle is freely

exposed so as to be easily retracted. The dissection of the neck is facilitated by division of the sternomastoid muscle if the glands are extensive (Fig. 1070). Removal of the glands is best begun below (Fig. 1071). They are removed from the supraclavicular triangle, cleared away from the subclavian and internal jugular veins. Care should be taken not to wound the thoracic duct, which may be on either side. The lymphatic mass is kept together and dissected upward, following the internal jugular vein. A more satisfactory dissection is made if the vein is freely exposed at once and kept exposed as the operation progresses than if it is left covered with fascia and avoided as much as possible. The small veins which pass to the jugular vein from lymph nodes must be watched for and tied.

Fig. 1070.—Tuberculous Glands of Neck Exposed by Posterior Incision. The sternomastoid muscle has been divided, and the skin flap is drawn forward.

If there is no mixed infection of the glands or periadenitis the removal of the glands may be affected largely by blunt dissection. If infection and adhesions are present the dissection is much more difficult. It is accomplished with scalpel, scissors and blunt instruments. The sternomastoid is retracted both forward and backward.

The spinal accessory nerve leaves the sternomastoid at its middle and passes back to the trapezius; it should be saved. The dissection of the glands is continued upward. The muscle is retracted outward and backward to expose the region of the bifurcation of the carotid. The submaxillary and submental glands are next removed. Glands must often be removed from the substance of lower part of the parotid in which they are embedded and

from close relation to the submaxillary salivary gland. In order to have the least scar, the wound should be closed with a carefully applied subcuticular suture.

Tumors of the Neck.—*Cysts* of the neck should be excised. *Congenital cysts* and *echinococcus cysts* should be removed (see Cystomata, Vol. I, page 325). *Lymphatic cysts* cannot often be excised unless very small; in childhood they are prone to disappear spontaneously; incision and tamponing, to cause obliteration of the sac, is, perhaps, the most effective treatment. *Hemorrhagic cysts* may be dissected out; when the dissection reveals connection with a blood-vessel, the opening in the vessel must be closed or the vessel ligated (see Aneurism). *Bursal cysts* in the thyrohyoid region require excision, or incision and destruction of the lining.

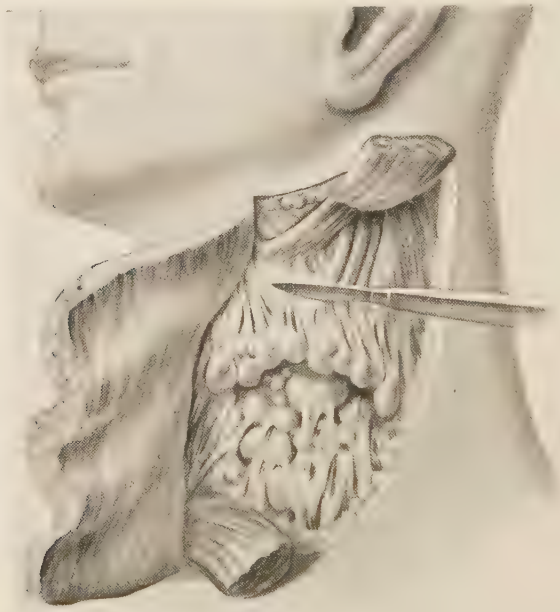

Fig. 1071.—Dissection of Tuberculous Glands of Neck from above Downward.

Solid tumors of the neck should receive the same treatment as in other regions. Benign tumors require more urgently to be removed because of disturbances incident to pressure and for cosmetic reasons. *Secondary carcinoma* has already been discussed (page 363). *Malignant lymphoma* may sometimes require excision for the relief of distressing pressure.

Branchial fistulæ and *cysts* require the dissection of the mucous tract. The fistula should be injected with methylene blue solution in order to trace it. A fine probe kept in the lumen is also of help. A cyst is but a stopped-up fistula. The surgeon should be prepared for a long dissection as these fistulæ often lead to the great vessels and thence in devious ways. They may be expected to have an internal opening in the laryngobuccal cavity. Unless every trace of the mucous membrane of the fistula is removed, recurrence will take place. *Median fistulæ* of the thyroglossal tract are more easily removed. Unless these fistulæ are removed the only treatment that

remains consists in keeping the fistula clean and dry by injections of such a fluid as equal parts of alcohol and water. No treatment but excision is curative.

Burns of the Neck.—Burns in this region should receive the most careful treatment (see Vol. I, page 821). To secure healing with the least possible infection and scar is necessary to prevent deforming contractures. When healing has been secured massage with oil may help to relax the scar. The injection of fibrolysin may be of service. The best results will be secured by plastic operations (see Vol. III), which should be done before the distortion has caused changes in other structures.

Cervical Ribs.—These ribs arising usually from the seventh, sometimes the sixth, cervical vertebra, require treatment when they cause unpleasant symptoms. Most cases give no symptoms. But it should be borne in mind that the presence of these ribs means high position of the vertebral artery and the pleura, which should be guarded in operations. Removal of the anomalous rib should be done if it causes symptoms. It is best that operation should be done even when the symptoms are slight—anesthesia, tingling or neuralgic pain in the arm—as more serious disturbances may supervene. Only the troublesome side need be operated upon. The operation may be depended upon to give relief. The rib is exposed by a horizontal incision just above the outer end of the clavicle. If necessary this may be combined with a vertical incision between the sternomastoid and the trapezius. The subclavian vessels, pleura, phrenic nerve, brachial plexus, and thoracic duct are to be looked out for. The nerves and muscles should be retracted and the rib divided close to the vertebra. Sharp edges and exostoses often connected with the vertebra should be smoothed off. The rib should then be followed forward to its anterior attachment—usually to the first rib—and cut free. Care should be taken not to stretch or compress unduly the brachial plexus.

Torticollis.—*Acute torticollis* presents pain or tenderness. Removal of the cause is the first requisite of treatment. The ordinary *stiff neck* is best treated by hot applications. These may be employed in the form of woolen cloths wrung out steaming hot with warm water. The treatment must be applied to the sternomastoid or posterior muscles, whichever are affected. *Ironing* consists in repeatedly passing a hot smoothing iron over a thin cloth laid on the skin. This gives heat and massage. Massage alone or vibratory treatment is often effective. Aggravated cases require fixation of the head and neck.

Fixation is best preceded by massage or hot applications. The apparatus used in spondylitis of the neck is employed. The plaster-of-Paris cuirass, embracing the head, neck and thorax, is most useful. It need not extend below the thorax. The jury-mast is also of service. In cases with contracture of muscles which is not overcome by massage, heat or gentle force, an anesthetic is required and forcible correction followed by fixation in an overcorrected position. Cases in which the above measures fail, should have the contracted parts cut.

Chronic torticollis embraces the great majority of cases which come to the surgeon's hands both acquired and congenital. Acquired torticollis is usually preventable. Most cases of more than six months' standing may be called chronic. The contracture of the sternomastoid or posterior muscles is resistant. Pain and tenderness are not present. In infancy the contractures may be overcome by systematic *stretching* and *manipulation* of the contracted parts. Several times daily the child should be placed on a firm surface; the shoulders should be held down by a pair of hands; the head should be rotated; and flexed or extended, in the direction opposite to the

deforming tendency; and the contracted parts massaged. When the child lies in bed or in its mother's arms, the position of overcorrection should be given to its head. These measures should be given a fair trial; if they fail, operation should be done. Operation will rarely be required if the patient is seen early enough and given proper treatment.

Operative treatment is indicated in most cases of torticollis when seen by the surgeon. When the contracture is limited to the sternomastoid muscle, division of its lower tendon is practised. *Subcutaneous tenotomy* is done

Fig. 1072.—Torticollis, Showing Head Fixed in Plaster-of-Paris Dressing in a Position of Overcorrection.

through an opening just large enough to admit the tenotome. It may be employed in mild cases. The patient should be anesthetized and placed on his back, with a sand pillow behind the upper thorax to permit the head to drop back. The head should be held rotated and abducted so as to put the contracted muscle well on the stretch. The structures to be avoided are the subclavian vein, the thoracic duct, the internal jugular vein and the great arteries. The tenotome is inserted at the inner border of the sternal attachment, 1 or 2 cm. (3/8 or 3/4 inch) above its insertion. The blunt-pointed tenotome is then substituted for the sharp point, passed outward behind the muscle, to the outer edge of the sternal fasciculus, rotated, and the muscle

cut forward toward the skin. If this does not relieve the contracture, the clavicular attachment may be divided in the same way.

Open tenotomy is the preferable operation. In the case of a broad insertion two longitudinal incisions should be made, one over the middle of each tendon; in most cases a single incision is adequate. The patient is placed in the same position as for subcutaneous tenotomy. An incision is begun about 3 cm. (1¼ inches) above the clavicle, between the sternal and clavicular fasciculi of the muscle, and carried downward to the clavicle. The skin is dissected back a little, and the muscle exposed. A director is passed behind the sternal portion and the muscle divided upon it as a guide. The clavicular portion is similarly divided. Resistant bands of fascia and the sheath of the muscle toward the clavicular side will also require division. This may be done by retracting the wound edges and operating by the aid of sight. These incisions of fascia require to be but slight nicks of resisting fasciculi. The parts should be put well on the stretch to bring out these resisting bands. The fascia and skin are then sutured separately, and the head, neck and upper thorax put up in plaster-of-Paris (Fig. 1072) in the overcorrected position, after having thoroughly stretched and broken up all resisting fibers not divided.

Division of the posterior muscles also will be found necessary in aggravated cases. This is done through an incision, concealed by the hair, extending backward from the mastoid process. The front edge of the trapezius and any other contracted muscles or fasciæ inserted in the occipital bone are divided as extensively as is necessary.

The *after-treatment* is important. After dividing the resisting parts, overcorrection, to stretch the uncut tissues, is applied. After passive motion has overcome all resistance, the head should be put up in plaster-of-Paris. The head should be rotated so that the chin is over the middle of the clavicle of the side operated upon. The head should be abducted toward the opposite shoulder. The neck should be kept straight in the middle line. A fenestrum may be cut to remove the dressing. The splint should be worn for one or two months. Following this passive motion should be practised and massage should be given to the neck on both sides. At least twice daily the head should be placed in the position of extreme overcorrection. Traction applied daily by means of the suspension apparatus is of service.

If the tendency to recurrence is pronounced the splint should be applied again in overcorrection and the treatment continued for from three to six months. If the head rotates into place when suspension is applied, the jury-mast may be used instead of the plaster splint. This support may be used for several months. More rapid progress will be made if the appliance is put on so that it may be removed daily, and massage and passive motion given. Following operation in adults usually no apparatus is needed. In *bilateral* contractures, the treatment is conducted upon the same general principles as in unilateral contractures.

Some surgeons do not use retention apparatus after tenotomy. The head is placed in an overcorrected position and held between pillows. Passive motion is begun on the second or third day. These movements are increased and are later followed by massage.

Excision of the sternomastoid muscle was advocated by Mikulicz, because he regarded simple division of the muscle as inadequate for confirmed cases. Loss of the muscle does not materially impair the movements of the head. An incision is made along the lower two-thirds of the contracted muscle, and the sternal and clavicular attachments lifted up and divided. The muscle is then separated from its bed up to a point above the spinal accessory

nerve. The nerve leaves the muscle about the middle of the neck. The lower two-thirds of the muscle are cut away and the wound closed. The after-treatment is as above.

Spasmodic torticollis occurs in adults, is not associated with discoverable structural changes, involves usually the sternomastoid, but the trapezius and other muscles may become affected, the spasmodic clonic spasms sometimes involving the facial and upper thoracic muscles. The treatment is the same as that of muscular cramps elsewhere. Discovery and elimination of the local or general cause is the first thing. In mild cases, improvement of the general hygiene combined with massage of the affected muscles is sufficient. Overcorrected position by means of supports cures some cases. Rather than resort to these appliances, much quicker results are secured by dividing the nerves supplying the affected muscles. If the sternomastoid and trapezius alone are affected, resection of the spinal accessory nerve gives relief.

Resection of the spinal accessory nerve accomplishes the same results as excision of the lower two-thirds of the sternomastoid muscle as above described. The operation paralyzes the sternomastoid and the trapezius (see Spinal Accessory Nerve, Vol. I, pages 885 and 890). Simple resection of the nerve is a less mutilating operation. The nerve emerges at the jugular foramen, passes downward and backward, and enters the anterior part of the sternomastoid muscle about 2 cm. (¾ inch) below the level of the tip of the mastoid process, which is about opposite the angle of the lower jaw. The incision should extend from the tip of the mastoid process downward for about 8 cm. (3 inches), exposing the muscle. The anterior border of the muscle is retracted backward, and the lower part of the parotid gland forward. At the bottom of the wound, lying in a direct line below the mastoid process, is the transverse process of the atlas, which is easily exposed by blunt dissection. Running downward and forward from the mastoid process is the posterior belly of the digastric muscle. The carotid and internal jugular lie internal to this belly; the tip of the transverse process of the atlas is about on an anteroposterior plane with its middle. The nerve usually is found a few millimeters in front of the tip of the transverse process, where it is easily identified in the connective tissue. By strongly retracting backward the anterior border of the sternomastoid muscle, the nerve will be seen passing under the posterior belly of the digastric, just in front of the transverse process of the atlas, to enter the inner surface of the muscle near its anterior border at a point opposite the angle of the lower jaw. If there is any question about it, mechanical or electric stimulation of the nerve will be found to cause contraction of the muscles. About 2.5 cm. (1 inch) of the nerve should be resected. Some surgeons have been satisfied to stretch it in each direction. Some do both. No fixation apparatus is necessary. If the disease has been of long standing, division of contractured parts may be required. The operation should be followed by massage, and passive and active motion of the neck muscles.

Resection of the posterior cervical nerves is done in cases in which the spasm involves, besides those supplied by the spinal accessory nerve, the posterior neck muscles on the same or the opposite side. Paralysis of these muscles is secured by division of the posterior branches of the upper spinal nerves. The nerves to be paralyzed are those which supply the splenius capitis, rectus capitis posticus major, and obliquus inferior. They are supplied from the second and third cervical nerves and the suboccipital nerve from the first cervical. A transverse incision 5 to 10 cm. (2 to 4 inches) long, terminating at the middle line, is made 2 cm. (¾ inch) below the level of the lobule of the

ear. The trapezius muscle is divided transversely. The nerve to the occipitalis major is found where it leaves the complexus muscle, about 1 or 2 cm. ($\frac{3}{8}$ to $\frac{3}{4}$ inch) below the level of the skin incision, by lifting the trapezius. Sparing this nerve, it is followed through the complexus muscle, the muscle being cut transversely, until its junction with the second cervical is reached. The posterior branch of the second cervical is then resected. The first cervical is then located just above, and resected. The third cervical is located 2 or 3 cm. ($\frac{3}{4}$ or $1\frac{1}{4}$ inches) below the second; the external branch of its posterior division should be resected as far as the main trunk. The wounds in the muscles may be sutured.

The nerves may be reached by an incision, about 8 cm. (3 inches) long, carried from the occiput downward parallel to the cervical spines and 2.5 cm. (1 inch) from them. This incision is continued through the trapezius to the edge of the splenius capitis. The complexus is divided so as to expose the occipitalis nerve. With this as a guide, the posterior branches of the three upper cervical nerves are exposed and resected.

Exceptional forms of torticollis require the treatment peculiar to the disease which they represent. In *paralytic torticollis*, such as complicates diphtheria and anterior poliomyelitis, it should be remembered that the turning of the head is not done by diseased muscle, but by a normal muscle which is unopposed. Later contractures may take place and require correction by massage, forcible motion, or division of tissue; but the curative treatment at first should be directed to the relaxed muscles, and not the contracted ones. Care should be taken that *imbalance of the cervical muscles*, due to asthenia or central irritation is not treated for cervical tubercular spondylitis. The same may be said of *rachitic torticollis* and *rheumatic torticollis*. *Habitual torticollis* and *ocular torticollis* require attention to their respective causes.

SALIVARY GLANDS

The **parotid gland** is under the deep fascia; it embraces the ramus of the lower jaw in front; it is bounded by the zygoma above, and the external ear behind. Its lower lobes occupy the space between the styloid process and the sternomastoid muscle. Stenson's duct passes forward across the masseter muscle 2 cm. ($\frac{3}{4}$ inch) below the zygoma, and enters the mouth opposite the second upper molar tooth.

Parotid salivary fistula, an opening of one of the ducts of the parotid through the skin, occurs usually as a result of a wound; and in treating and making wounds of this region, the duct should be had in mind. The fistulous opening may be closed by the old method of Deguise. A silver wire is passed from the mouth of the fistula inward and forward through the cheek to emerge in the mouth. This is done by means of a small trocar and canula just big enough to receive the wire (Fig. 1073). The other end of the wire is similarly passed 3 or 4 mm. from the first. This leaves the loop of the wire in the mouth of the fistula. The two ends are then tightly tied or twisted on the inner side of the cheek (Fig. 1074). This forms a new canal by which the saliva is conducted into the mouth. The external opening may be dissected free and sutured, or this may be done at a subsequent operation. If it is not sutured, the tendency is for it to close. The suturing of the external opening is aimed to make a plastic operation to overcome the dimple which otherwise results (Fig. 1075).

This operation is not apt to be successful if the wire is passed through the masseter muscle; the opening should be anterior to the masseter. If the fistulous opening is much posterior to the front edge of the masseter, the

salivary tube must be lengthened. It may be possible to find the natural opening in the mouth, and by passing a filiform bougie through it and then a few strands of thread, the distal part of the duct may be dilated and the severed ends of the duct united.

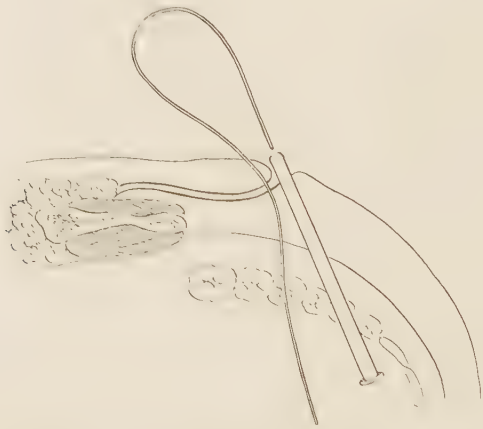

Fig. 1073. Operation for Salivary Fistula. First Stage. Wire being passed through cheek by means of trocar and canula.

Fig. 1074.—Operation for Salivary Fistula. Second Stage. Wire twisted on inner side of cheek.

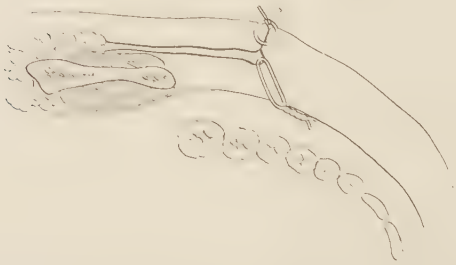

Fig. 1075.—Operation for Salivary Fistula. Third Stage. Wire twisted on inner side of cheek, and opening on outer side of cheek freshened and closed by sutures.

Nicoladoni advised reconstructing a canal of mucous membrane. The skin opening is excised by a transverse elliptical incision; the outer surface of the mucous membrane lining the cheek is then uncovered anterior to the masseter; an oblong piece of this mucous membrane is freed on three sides,

turned back and constructed into a tube, which is sewed to the discharging end of the duct; the external wound is then closed over all (Fig. 1076). It is not necessary to fold the mucous membrane into a tube. If the strip of mucous membrane is simply drawn through from the mouth to the parotid, and sewed to the gland opening or to the stump of the duct, a tube will form. The patency of the mucous channel may be assured by leaving a pair of strands of chromic catgut lying on the mucous surface. The wound in the mouth from which the strip was cut should be sewed.

Cellulitis and abscess of the parotid are serious because of the danger of secondary intracranial infection. This may begin in the gland or in its embraced lymphatics. The general and local treatment of cellulitis should be expeditiously applied. Streptococcus infection and tubercular infection demand their specific treatment. As soon as an abscess forms, or sooner, the gland should be incised. Incisions should be placed so as not to injure the facial nerve or the great vessels.

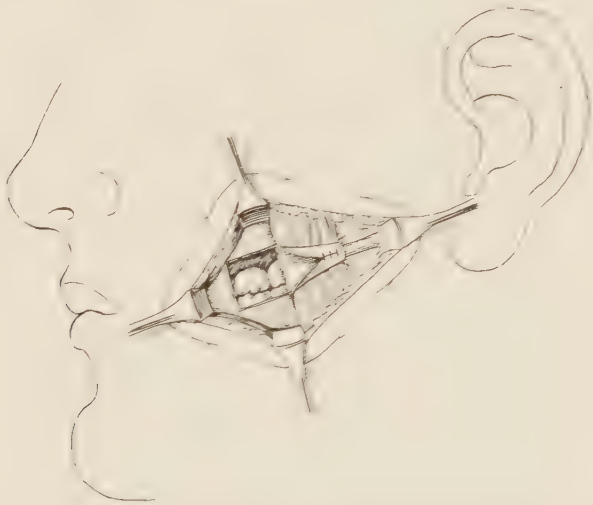

FIG. 1076.—PLASTIC OPERATION FOR SALIVARY FISTULA OF CHEEK.

The cheek has been opened by a short incision parallel with the filaments of the facial nerve. The fibers of the buccinator are separated and widely retracted, exposing the mucous membrane of the mouth. A flap is cut from the mucous membrane, turned back and sewed as a funnel about the end of the duct. The mucous membrane wound is to be sewed, and the muscles allowed to go back into place.

Salivary Calculi.—Stones form usually in the duct of the submaxillary gland, although they may be found in any of the salivary ducts at their mouths or in the substance of the glands. Appearing in the terminal ducts near their mouths, it is best to incise the duct at the stone and lift it out. The wound heals without further attention. Stones developing in the substance of the submaxillary gland are best treated by removal of the gland. This is not difficult, and if the stone alone is removed a fistula and a disorganized gland are apt to remain. Stone in the substance of the parotid gland should be exposed and removed; removal of the gland should not be attempted, but, if the stone is near the periphery, the disease lobe may be removed.

Tumors of the Salivary Glands.—(See Tumors, also Anatomy of the Neck.) The surgeon should not withhold his hand from these tumors because they involve important structures. Any and all of the lateral structures of the

neck on one side may be sacrificed; and so far as the trachea, larynx and esophagus are concerned, they also may be excised.

THE THYROID GLAND

Anatomy.—The thyroid gland is behind the anterior muscles—the platysma, sternomastoid, sternohyoid, sternothyroid and omohyoid. It is surrounded by a layer of the deep fascia which forms an external capsule. This fascia also embraces the great vessels which lie in relation to the external posterior border of the gland. The top of the isthmus lies just below the larynx, and the *processus pyramidalis* arises in the median line in front of the larynx. Posteriorly the fascia, constituting the outer capsule, is adherent to the fascia and connective tissue embracing the trachea and esophagus. The *recurrent laryngeal nerve* lies in a groove on the median posterior aspect of each lobe, in the angle between the esophagus and trachea, enclosed in the external capsule. A large number of accessory

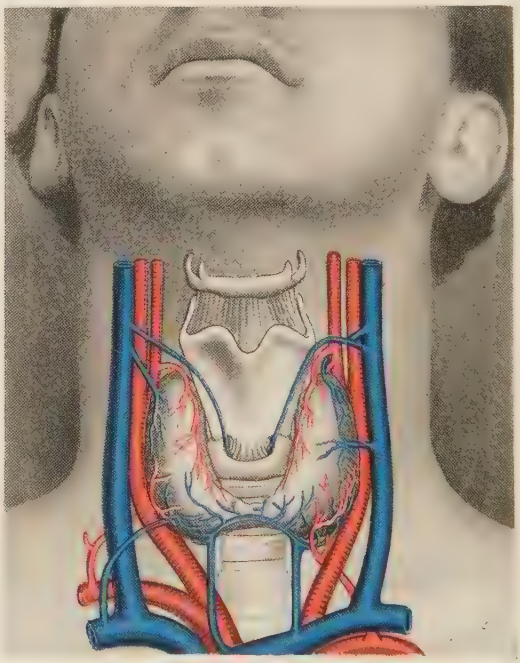

Fig. 1077.—Thyroid Gland.
Showing relations to larynx, trachea, and the vessels of the neck.

veins course in the external capsule. The gland rests in the arms of a great vascular U (Fig. 1077).

The *parathyroid glands* vary in number and location, but usually there are four, two upper and two lower, embedded in the connective tissue of the external capsule. They are brownish-red; 2 to 10 mm. long, and 1 to 4 mm. thick. The upper pair are at the posterior median edge of the upper part of the lobes. The lower pair are just below the lower ends of each lobe. The *accessory thyroids* vary much in size and location, but may be found about the hyoid bone, larynx, trachea or the root of the tongue.

Inflammations of the Thyroid.—Acute thyroiditis is treated the same as other inflammations. Hot applications are used. Abscesses should be opened. Necrosis demands removal of the affected portions. *Acute strumitis* (inflammation of a goiter) should be treated as above, and it will usually subside.

When suppuration occurs, the abscess should be incised. If the abscess is confined to the goiter, and the surrounding tissues are not infected, the goiter may be taken out at this time. If infection has invaded the surrounding tissues excision of the goiter is best not undertaken. Abscesses should be incised promptly and drained.

Chronic thyroiditis should be treated by discovery and elimination of the exciting cause. The general hygiene should be improved. If so much of the gland is diseased that the patient is suffering from insufficiency of thyroid secretion, thyroid preparations should be given. If the gland is chronically enlarged and hyperthyroidism is present, the enlarged portion may be removed. In operating for chronic inflammation it should always be borne in mind that the functional activity of the remaining part may be impaired, and an adequate amount of gland should be left. *Chronic strumitis* should be prevented by the removal of goiter before it becomes inflamed. Extirpation of the chronically inflamed goiter is the most satisfactory treatment. If there is central softening and the condition of the patient forbids excision, the broken-down parts may be incised and treated with antiseptic packing. For such treatment iodoform, iodin, nosophen, formidin or other powder may be used. *Syphilis* of the thyroid gland should be recognized and treated specifically. *Tuberculosis* is to be given the general treatment of that disease and the infected portion of the gland excised.

Malignant Tumors of the Thyroid (Carcinoma and Sarcoma).—In order that treatment of these grave conditions may be successful, extirpation of the growth must be attempted before it has reached a point at which positive diagnosis can be made. The frequency of malignant disease in the thyroid makes it imperative that tumors of this gland should be removed. This must mean the removal of benign as well as malignant growths, for to wait for the purpose of clinical differentiation is to delay too long. A thyroid gland which continues to enlarge steadily after puberty should be suspected of malignancy; and an enlargement beginning and steadily continuing after middle life should suggest carcinoma, and be removed. Operation before the capsule has become involved is imperative. The capsule should be removed with malignant disease. If metastases have developed, operation is rarely worth the pains.

The extension of the disease may require the removal of important structures of the neck. The extent to which such operations may be carried must depend upon the general condition of the patient (see page 363, Carcinoma of the Neck). If operation for radical cure is impossible, tentative measures may be of service (see Inoperable Cancer, Vol. I, page 331). *Tracheotomy* may become necessary. At the best it is difficult; it may require partial removal of the growth to make it possible; and fatal infection is apt to follow.

Goiter (Struma).—Although a benign disease, goiter is serious because its natural tendency is to increase in size; it may cause serious dyspnea from compression upon the trachea or blood-vessels; it impairs the action of the heart, by causing pressure-dyspnea, compression, obstruction in the great vessels, or thyreotoxicosis; and it may undergo malignant degeneration. For these reasons treatment is important. Hygienic treatment may do something for these patients. A change of abode where water from a different source may be had sometimes checks or cures the disease. In some patients, the disease ceases to progress or it may recede, after the fiftieth year. Hygienic treatment has much to offer in most cases with mild hyperthyroidism.

Rest, both physical and emotional, is essential in treatment. In connec-

tion with rest, an abundance of pure drinking water is, perhaps, the next most important factor. If there is any doubt about the water, it should be boiled. Operation should be considered when the above measures fail. The patient should usually not be subjected to operation during an exacerbation of hyperthyroidism. Rest and care should carry her through the attack, and operation should be done in the interval when her physical condition is better and her mind more hopeful (see Hyperthyroidism, page 389).

Operation is indicated: (1) in goiter which causes pronounced pressure symptoms, either from pressure on the trachea or blood-vessels; (2) in nodular goiter; (3) in goiter which grows rapidly; (4) in painful goiter; (5) in goiter situated or growing down into the thorax, where compression will be serious and operation more difficult with the lapse of time; (6) in goiter that is producing symptoms of thyreotoxicosis; (7) in colloidal goiter which does not improve under treatment; (8) in any goiter which continues to enlarge despite treatment; and (9) in goiter which causes the patient distress because of its unsightliness.

Operation is contraindicated by: (1) extreme impairment of the general health, amounting to a moribund state; (2) greatly damaged heart; (3) the fact that the goiter is small and receding; or (4) absence of all of the above indications for operation.

Operative treatment may consist of excision, resection, enucleation of the thyroid or ligation of vessels. Complete removal of both lobes and the isthmus should never be done because of the danger of thyreoprivic cachexia.

For *excision* of simple nontoxic goiter, the patient should lie on the back with a sand pillow behind the upper thorax to cause the head to fall back and render the front of the neck prominent. The whole upper end of the table should be elevated to diminish congestion. The field of operation is best screened from the face by means of a bow opposite the chin, over which a sterile cloth is draped, making a screen. Local anesthesia with novocain or 1 per cent. cocain with adrenalin may be used. Infiltration anesthesia is most satisfactory. A preliminary injection of morphin is helpful. If general anesthesia is employed it is wise to inject the local anesthetic just the same as though no general anesthesia were to be used.

The important thing about the *incision for goiter* is that it should be adequate. A free exposure is essential. If but one side is to be operated upon, a unilateral incision suffices. This should begin on the side of the neck posterior to the tumor on a level with the junction of its upper and middle thirds. It should pass forward and then curve downward to end well below the tumor, keeping just external to the inner border of the lobe to be removed (Fig. 1078, *AB*). In low-lying unilateral tumors, this incision may be reversed, and the inner end be above and the outer end below (Fig. 1078, *CD*). For a median-lying tumor of small size, a median incision may be made from a point well above the tumor down to the sternum. In large tumors, especially if bilateral, the horizontal incision is to be preferred (Fig. 1078, *EF*). This passes transversely between points external to the tumor on either side of the neck and crosses slightly below the middle of the mass. It should make a slightly downward curve. An incision following the anterior border of the sternomastoid or a combination of the above incisions may best be adapted to smaller tumors. A low transverse curved incision is preferred by most surgeons.

The skin, fascia, platysma and deep fascia are divided. Vessels are ligated in two places and cut between. The thinned-out sternothyroid, sternohyoid and omohyoid muscles should be retracted. If adequate re-

traction is difficult, they should be divided. These muscles should be divided high, because the nerve supply enters at about the middle of the muscle. By cutting the muscles above the middle, their function is restored after they have been sutured (Fig. 1079). The underlying fascia should be similarly treated. Lying close upon the surface of the tumor will be found a plexus of veins. These should be ligated in a line with the long axis of the tumor and cut between the ligatures. Uncontrolled bleeding should not be permitted. Every bleeding point should be clamped or tied. Nothing should be cut unless the surgeon knows what it is. Occasionally the head may be lifted forward to permit the filling of veins which may be obscured by compression.

The surgeon should identify the surface of the goiter, and the dissection should be made bluntly, between the planes of tissue, with rounded curved

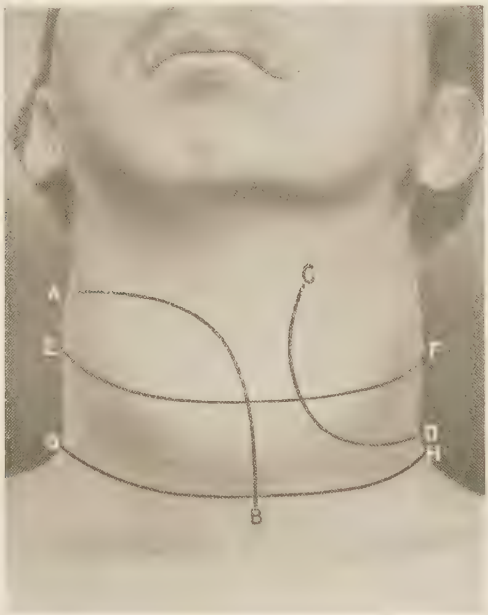

Fig. 1078.—Incisions for Operations on Goiter.
AB, Incision used for unilateral tumor; *CD*, incision for low unilateral tumor; *EF*, collar incision for bilateral exposure; *GH*, incision for low bilateral tumor.

scissors (Fig. 1080). As the outer margin of the tumor is reached it may be retracted inward or lifted forward. Careful work is now required because the sheath of the great vessels is apt to be adherent to the sheath of the goiter. The superior thyroid artery should be discovered entering the goiter above and posteriorly. The artery and vein should be ligated in two places and cut. If the vessels cannot be identified, the pedicle containing them should be encompassed by a ligature and cut close to the tumor. The lower lateral border is then retracted inward, upward and forward, and the inferior thyroid vessels ligated. The surgeon should be familiar with the anatomy of the two thyroid vessels (see Vol. I, pages 410 and 411), and should make allowance for the distortion caused by the growth of the tumor. The search for the two thyroid arteries should be from without inward.

Some surgeons, after clearing the front of the lobe and tying the superior thyroid vessels, prefer to divide the isthmus, turn the tumor downward and then tie the inferior thyroid vessels.

The tumor is lifted forward and retracted inward and bluntly freed from its posterior attachments (Fig. 1081). If but one side is enlarged sufficiently to demand removal, the isthmus is ligated and the tumor cut away. If both lobes are to be removed, the dissection is continued on the other side in a similar manner. The whole of both lobes should not be removed. The surgeon should attempt to discover a part of the gland that shows the least evidence of disease, and leave that. If some normal-appearing gland can be identified, it should be left in amount about equal to the size of the normal thyroid. When no particular part of the mass can thus be preferred for

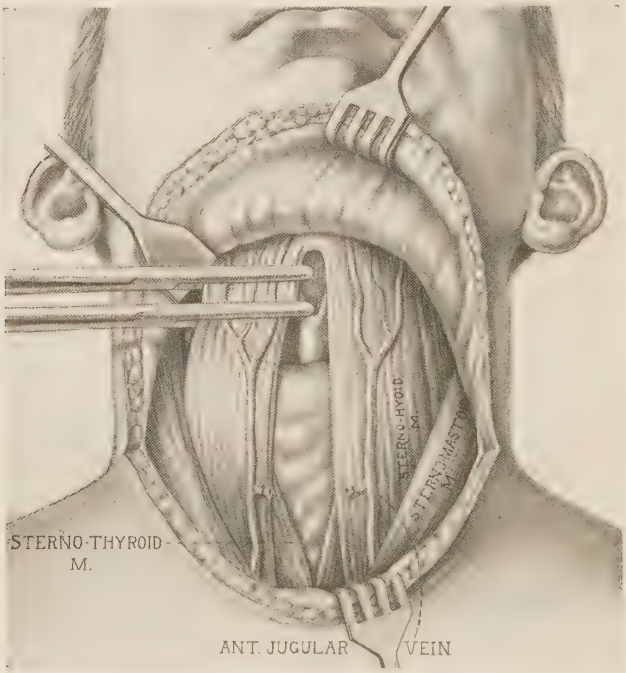

Fig. 1079.—Operation for Goiter.
Flap of skin and platysma retracted and deeper muscles exposed. The sternohyoid muscle is about to be divided between clamps. (*After Mayo.*)

preservation, one-third or a half of the smaller lobe should be left. It is best to leave the upper pole of the lobe rather than the lower, because in the event of recurrence the growth is more difficult to attack and the symptoms which it produces are more serious if it is low in the neck. The part to be left should not be dissected free, but should be left with all its vascular connections.

In resecting for hyperplasia, it is well to introduce a mattress suture to prevent oozing, and then whip over the edges of the cut gland. A ligature should be thrown about the lobe, after freeing the part to be removed, and the gland tissue cut through close to the ligature. If the lobe is thick, bleeding may be prevented by multiple ligatures instead of one, or the angiotribe may be used. After resecting from two sides of the thyroid,

Mayo warns against letting the two stumps fall together at the median line, lest they unite and the scar contracture later compress the trachea. If pressure of an old goiter has caused absorption of rings of the trachea, and the trachea collapses when the goiter is removed, a tracheotomy tube must be inserted, or a piece of costal cartilage put in to hold the tissues from collapsing.

Sponging should be most gentle. All bleeding should be controlled. The muscles and fascial planes should be restored by suture (Fig. 1082). The wound may be closed without drainage by a subcuticular suture. It is wise to leave in a drain for a day. A dressing, making even and gentle pressure, should be applied. The patient should lie quietly in bed, on his back, with the head and thorax slightly elevated.

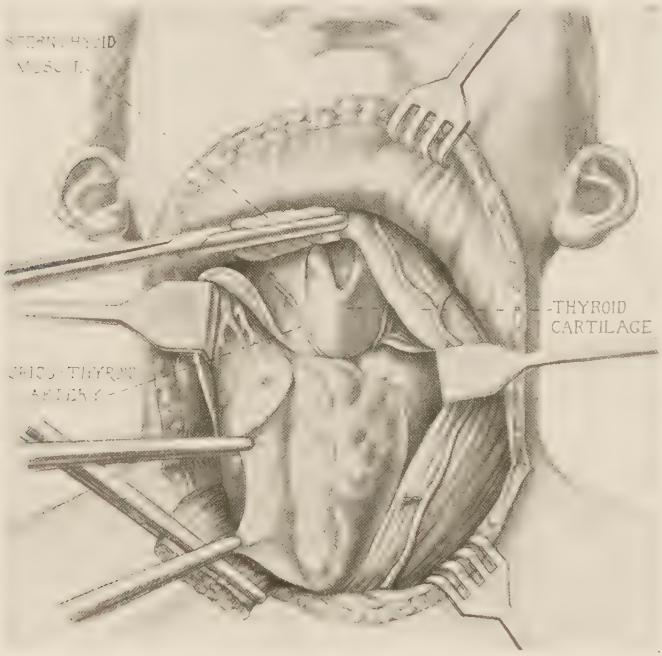

FIG. 1080.—OPERATION FOR GOITER.
All muscles retracted and capsule incised. The superior thyroid vessels are seen at the upper pole of the gland. (*After Mayo.*)

For *enucleation* of a nodule, cyst or localized tumor, growing in the thyroid, the fascia or gland tissue overlying the tumor is incised, and bluntly dissected back to expose the growth to be enucleated. As the dissection proceeds, wide retraction should be maintained and vessels passing between thyroid and tumor should be divided. Sometimes there may be but little of the gland left outside of the growth; in which case mass ligature of the main vessels may be required. When the growth to be removed constitutes most of the thyroid, and there is but little gland outside of it, this remaining gland tissue should be accorded the greatest deference. It should not be traumatized, its blood supply should not be harmed, and the raw surface left after the enucleation should be covered with fascia to protect it.

The *double resection* of nontoxic goiter, which is called for because of the

mechanical inconvenience of the swelling, is an operation which should have no mortality. The tumor is best exposed by the horizontal incision extending from one external jugular vein to the other. The upper flap is dissected up as far as the thyroid cartilage and the lower flap as far as the interclavicular notch. After separating the muscular structures by a median incision the thin capsular covering of the gland should be drawn aside. The finger, under this capsule, sweeps about the gland upon an exploratory tour. Some lateral veins may require ligation. The sternomastoid muscle on one or the other sides may have to be divided. If the gland is found uniformly diseased, colloidal, cystic or adenomatous in both lobes, both should be resected.

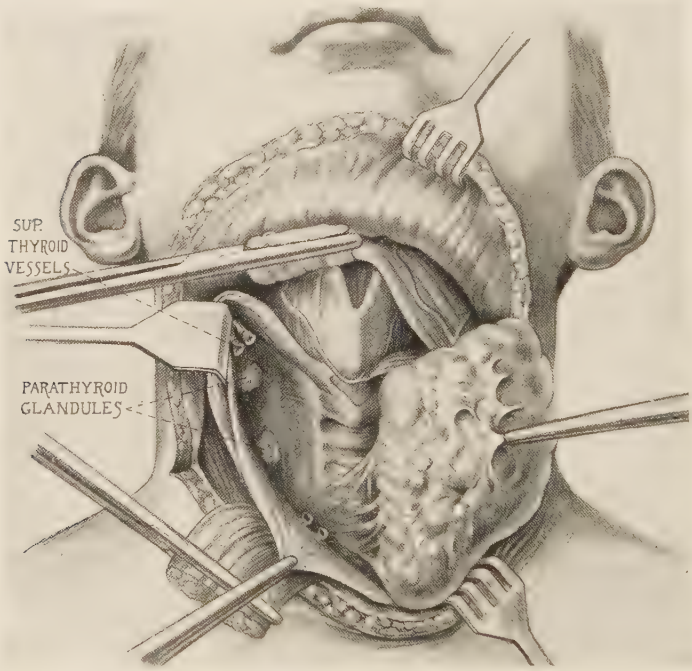

Fig. 1081.—Operation for Goiter.
The tumor is lifted forward and freed from its posterior attachments. The superior and inferior thyroid vessels are seen ligated. (*After Mayo.*)

After dissecting free the two lobes so that they are brought forward and lie upon the retracted muscles the isthmus should be divided between two forceps in its narrowest part (Fig. 1083). The gland still has its posterior and vascular connections. Each side is then dissected away from the trachea. Complete removal of all gland tissue is not to be considered, but a resection of part of each lobe should be proceeded with. A row of clamps is placed about a lobe, catching the larger vessels which are exposed but especially for the purpose of holding the stump. The part of the gland anterior to these clamps is resected. This is done in such a manner as to leave a wedge-shaped excavation in the remaining portion.

A mattress suture of chromicized catgut is then applied behind the clamps, through the stump, in such a manner as to close the cavity. A second run-

FIG. 1082.—OPERATION FOR GOITER.
Operation completed. The divided muscles have been sewed, a drain has been placed, and the wound closed with subcuticular suture.

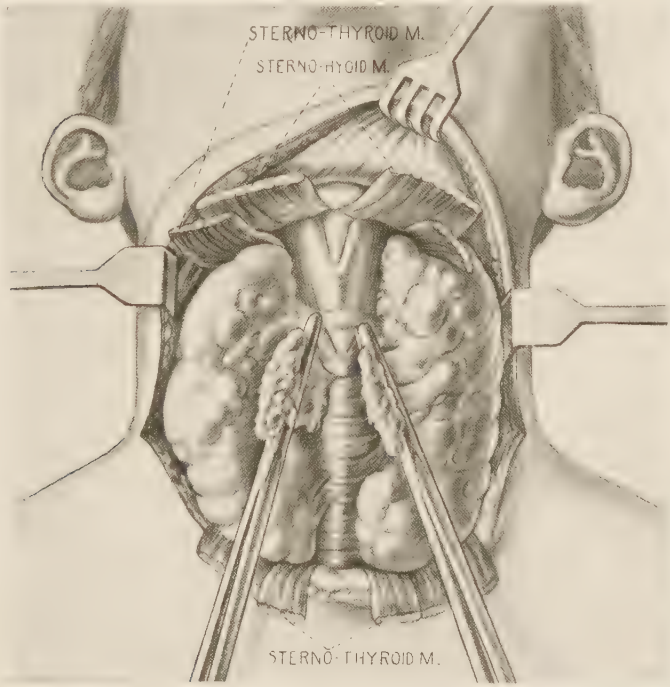

FIG. 1083.—OPERATION FOR DOUBLE GOITER.
Goiter exposed by transverse incision. Isthmus clamped and divided.

ning suture is carried along the edge of the wound (Fig. 1084). The same operation is done in the other lobe. The amount of gland tissue to be left in the two lobes must be determined by the judgment of the surgeon. It should be planned that the patient shall be left an amount of thyroid tissue capable of satisfying the physiologic needs. The fact that the gland is diseased should be taken into consideration, as more diseased gland is required than normal gland.

For operating upon extremely *vascular goiter* with greatly dilated capsular veins, preliminary ligation of the arteries facilitates the procedure. The low transverse collar incision is used. It passes through the platysma. The sternomastoid is retracted strongly outward until the fascia covering the small muscles is exposed. This fascia is divided vertically, and the carotid exposed on its inner side. The inferior thyroid artery is identified as it

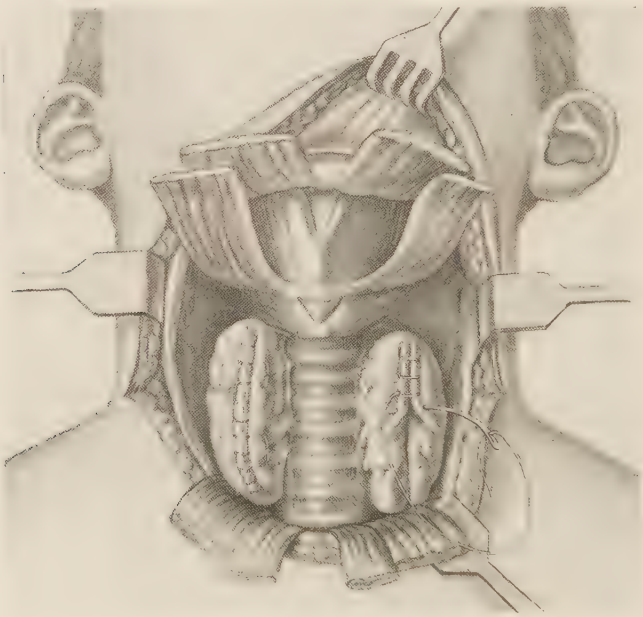

Fig. 1084.—Operation for Double Goiter.
The two lobes have been resected. The remaining portions of the gland have been sewed over with mattress sutures.

emerges horizontally from beneath the artery, and tied. The recurrent laryngeal nerve is separated from the artery by the thyroid fascia. The artery should be tied so as to avoid the parathyroid.

The goiter is then freed and retracted downward, and the skin upward, while the superior thyroid artery is tied. How much of these vessels is ligated depends upon the character of the goiter. In the case of a double-sided operation requiring resection of both lobes, ligation of the two inferior arteries and ligation of the anterior branches of the two superior arteries should suffice. This will be found to control hemorrhage. The operation of resection may then go on as above, or the isthmus may be left (Fig. 1085).

For *controlling bleeding*, L. Freeman (Surg., Gyn. and Obst., xix, 1914), used two pieces of stiff wire, placed on either side of the lobe to be removed,

and drawn together by ligatures tied about the ends and passed through the pedicle.

For *resection* of a part of a lobe, the preliminary exposure is made as for excision. The part to be resected is dissected free and cut away after crushing or multiple ligation beyond the line of incision. The friability of the diseased thyroid sometimes makes suture of its substance difficult or inadvisable.

The performance of *tracheotomy*, in a wound through which an excision of a goiter has been done, is apt to lead to infection and cellulitis reaching the mediastinum. It is rarely justifiable. When compression of the trachea is great, division of the isthmus and outward retraction of the compressing lobes should be the first step of the operation. If an emergency arises which cannot be met by intubation, and tracheotomy must be done, the great wound should be left widely open, and the skin of the lower margin pressed backward so as to leave as small an inferior cellular area as possible.

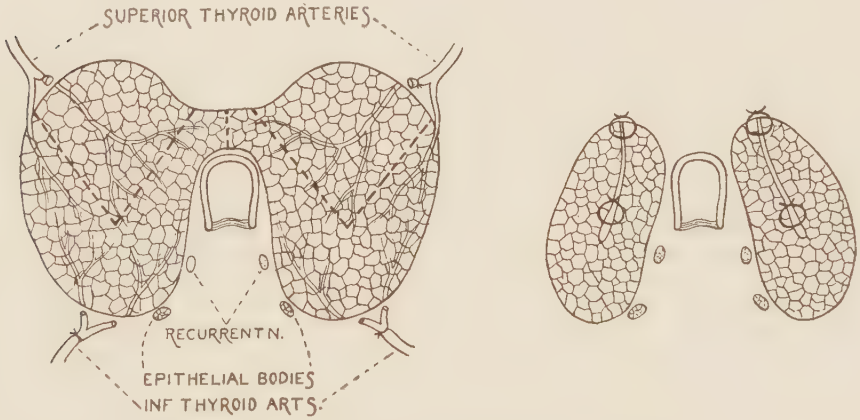

Fig. 1085.—Operation for Double Goiter.

Diagram showing segments of thyroid to be resected and result after closure of wounds. All arteries are tied excepting a large branch of the superior thyroid on either side.

The *results* of the operation are good, provided adequate thyroid tissue has been left, the parathyroids have not been removed, the recurrent laryngeal nerves not damaged, and the operation conducted with surgical circumspection.

Aberrant goiter, forming in the accessory thyroid glands, should be treated by removal provided the function of the thyroid is normal. Degenerative disease of the thyroid gland proper may be followed by a compensatory hypertrophy of an accessory thyroid. To remove such an organ would be a serious mistake.

Aberrant goiter in the region of the hyoid bone is removed without great difficulty. Goiter developing in the lingual thyroid, or other *tumor of the root of the tongue*, is difficult to reach. Access may be secured by an incision carried in a horizontal plane under the lower jaw, bisected by the middle line. The superficial soft tissues are retracted downward, and the tongue muscles are separated laterally from the middle line. If necessary, temporary median division of the lower jaw may be done.

Hyperthyroidism (Conditions in which there is a thyrotoxicosis incident to excessive secretion of the thyroid or parathyroids, such as in *Graves'*

disease or *exophthalmic goiter*).—It should be remembered that this serious condition often can be prevented by removing simple goiters before they produce this disease. All cases are benefited by rest in bed, and quieting influences. The general treatment consists in improvement of hygiene by fresh air, freedom from worry, rest, baths followed by cold douches, and systematic non-fatiguing exercise. Carbohydrate and proteid metabolism is very active and must be met by a generous diet and rest. Iron and arsenic are often needed and bromids and valerian for nervousness. Strophanthus may be used when the heart symptoms are distressing. But all drugs should be used carefully and sparingly and not continued unless giving positive results.

The vascularity may be reduced and the thyroid function improved by *faradism* and *galvanism*. In acute cases, cold may be applied. The *x-rays* have a similar effect. A hard tube of 3½ ma. with 16x as the largest dosage, is used for two or three months. *Thyreoprivic serum* and *thyreodectin*, obtained from the blood of animals from which the thyroid has been removed, seem of benefit in some cases so long as it is given. The effect does not last, it seems not to influence the diseased gland, and it has failed in most hands.

The *radium treatment* has given results in some cases which have not responded to other methods. Radiation treatment is given in dosage of 70 to 100 mgm. hours with a large radium plaque applied externally (see Radium Therapy, Vol. III).

Improvement has been secured by inserting a bit of *radium*, sealed in a tube, into the substance of the gland. For this purpose 10 cgm. of 300,000 strength for twenty-four hours, and 60 mgm. of 1,800,000 strength for eight hours, are used.

The *serum treatment* of hyperthyroidism can not be ignored by the surgeon. Human thyroid glands are finely chopped, suspended in physiologic salt solution, and the thyroid protein extracted. This is used as an antigen. It is injected into the peritoneal cavity of sheep in increasing doses. The blood of these sheep is used for the preparation of the serum. This is the serum of S. P. Beebe (Jour. Am. Med. Assoc., Jan. 30, 1915, vol. 64, No. 5). Its injection in cases of hyperthyroidism in 3000 cases reported by Beebe gave 50 per cent. of cures; and marked improvement in 30 per cent. of the cases.

The *injections of boiling water* have given good results in the hands of M. F. Porter (Annals of Surg., October, 1916). Under local anesthesia several areas are injected. This may be done in both lobes through one median puncture. From 3 to 30 c.c. (45 to 450 minims) may be injected at one sitting. Improvement takes place in twenty-four hours. Several injections may be made at intervals of two weeks. This treatment is of value in the cases which are too bad for operation. It is capable of giving quick relief. It is curative in the mild cases. In these mild cases with small goiter it is best to make a small incision over the isthmus under local anesthesia, and inject each lobe with the aid of sight.

The *injections of quinin* and *urea* proved effective in the hands of L. F. Watson (Jour. Am. Med. Assoc., September 25, 1915). The site of the injection is anesthetized. The empty needle is inserted into the body of the tumor, then the syringe is connected and from 1 to 4 c.c. of a 30 to 50 per cent. solution of quinin and urea hydrochlorid are slowly injected. The injection is repeated about every third day. Eight to fifteen injections must be made before any marked improvement is noticed.

It is best to precede the drug by a few injections of normal salt solution.

There is less pain if the same site is used for all injections. The treatment is not recommended in advanced toxic cases.

The *dangers of nonoperative methods* should not be lost sight of. Any of these measures may produce unexpected hyperthyroidism. When the thyroid gland is in that unbalanced state which is characterized by hyperthyroidism, manipulation, traumatism, or the effect of chemical or physical stimulation may be expressed in hypersecretion which, though destined to be but temporary and transient, may result fatally before it recedes. P. Verning (Hospitalstidente, Aug. 1, 1917) reported cases of fatal results following *x*-ray treatment.

The important features of nonoperative treatment are rest, fresh air (preferably at an altitude of 2400 to 5400 feet in the mountains), warm baths, cold rubs, and a liberal diet of simple food. An abundance of pure water should be drunk. It should not be the water used by the patient while the goiter was developing. The best foods are milk, eggs, butter, rice, fish and meat—all slowly eaten and well masticated. Salt should be used only very sparingly. If the patient is not restored to comfort or efficiency by the above measures, thyroid activity should be checked by operation on the gland, aimed to remove some of its substance or diminish its blood circulation. Patients should not be operated upon until they have had three months of treatment, unless no improvement is being derived. Operation should be preceded by two weeks of rest in bed.

Operative treatment has much more to offer than the above-described measures. Thyroidectomy is indicated in cases which have not yielded to hygienic and medical treatment after three months of treatment. In the presence of serious degeneration of the heart, low blood-pressure, irregular heart, periodic attacks of cardiac delirium, ligation of the superior thyroid arteries and veins on both sides is advised as a preliminary operation, or the mass ligation of Crile. This operation gives relief in most cases and may be followed later by thyroidectomy, if necessary. Much of the benefit of these operations lies in cutting off some of the nerve connection between the brain and the gland. The operation gives relief for the same reason that psychic rest does, for undoubtedly the disease is not one primarily of the thyroid gland.

In cases in which the condition of the patient does not warrant thyroidectomy, the surgeon should only do such an operation as the patient can bear. Ligation of one, two or three of the thyroid arteries may be done. If the patient can bear more than that removal of one lobe may be attempted. The wise surgeon does no more than the patient can safely tolerate.

If ether anesthesia is used the smallest possible amount of ether should be employed. By anesthetizing the patient, and then elevating the head of the table so that the body lies at an angle of 45 degrees, the brain anemia thus produced permits the operation to be done without any more ether. The danger of pneumonia is very great if full ether anesthesia is used. Washing out the stomach with warm water after ether anesthesia helps reduce the danger of postoperative thyrotoxicosis. Local anesthesia is always to be preferred.

The injection of boiling water is less dangerous than ligation, and is to be preferred in the serious cases in which thyroidectomy can not yet be done.

For *extreme exophthalmos*, in which the thyroid is not much enlarged but the nervous symptoms pronounced, removal of the cervical sympathetic ganglia has given good results. In this operation the superior thyroid vessels should be ligated at the same time. Each side is operated upon. The in-

cisions lie along the anterior border of the sternomastoid muscle. The muscle is retracted outward, the sheath of the great vessels is exposed, and the sympathetic ganglia exposed (see Removal of Sympathetic Ganglia, Vol. I, page 899). The superior and middle ganglia are removed. This operation is capable of preventing the corneal ulcerations which are so prone to complicate extreme exophthalmos. Jaboulay (Bull. de l'Acad. de Med., 1897, xxxviii) resected the superior ganglion and 2 or 3 cm. of nerve on either side. This operation benefits also the nervous symptoms of the disease. Rapid benefit is first observed, and then a prolonged and progressive improvement of all the symptoms extending over a period of years.

Thyroidectomy is done in the cases with pronounced symptoms and thyroid hypertrophy. Excision of the larger and more vascular lobe, together, if possible, with the isthmus and pyramidal process, constitutes the operation. If the other lobe cannot be felt, some of the lobe operated upon should be left with the isthmus. Not more than half of the gland should be removed in the cases of small glands. In the ordinary case about three-fourths of the total gland is removed. The operation is more difficult than the operation for ordinary goiter because of the extreme vascularity and friability of the gland. Blood should be saved as much as possible. Every vessel should be clamped. Unnecessary traumatism should be avoided.

The choice of *anesthetic* must depend upon circumstances. Local anesthesia is much to be preferred, but it should be taken into account that the patient is apt to be in a highly nervous state and unless the surgeon is a master of local anesthetization, it should be combined with some general narcosis, or a general anesthetic should be used. Ether, given by the open or drop method, is satisfactory. General anesthesia has the advantage that the patient is spared the fear during operation. Morphin should be injected half an hour before the anesthetic.

The parathyroid bodies should neither be traumatized nor removed. They are best avoided by care in leaving behind the posterior part of the capsule. This is the same care necessary for the avoidance of the recurrent laryngeal nerves.

The recurrent laryngeal nerve is greatly endangered when the inferior thyroid artery is exposed. If an attempt is made to ligate the artery external to the point where it crosses the nerve, the nerve is bound to be injured more or less, and at least a certain amount of temporary paralysis is apt to follow. Ligation external to the nerve is apt also to interfere with the blood supply of the inferior parathyroid gland. For these reasons the artery should be ligated in front of the posterior capsule of the gland; and that part of the posterior capsule which lies against the trachea should be left undisturbed.

The great danger of the operation is in a superadded hyperthyroidism, occurring before the patient's organism secures the benefits of the removal of the thyroid. This condition is manifested in a psychic storm with increase of pulse-rate; acute cardiac dilatation, tremor and fever. This is partly due to the use of general anesthesia, and markedly to psychic influence and trauma. By trauma is meant, not necessarily injury to the thyroid, but any traumatism capable of causing pain, peripheral irritation, or fear. When excision is to be practised, Crile proceeds as follows: The effects of small doses of morphin and scopolamin are ascertained. As the patient lies in bed, daily inhalations, of volatile oils, presumably for therapeutic purposes are given by the anesthetist. Ether is experimentally dropped in the inhaler to observe the patient's reaction to it. It may be carried to the point of

anesthesia. Consent to operation is obtained but the patient is not allowed to know when the operation is to be done. Morphin and scopolamin are given prior to operation; the patient is kept quiet in her bed; she is then anesthetized with ether to the second stage as though it were a treatment, and taken to the operating room and the anesthesia continued with nitrous oxid. The field of operation is then cocainized as though no general anesthetic were to be used. The skin and fascia of the opposite side are incised about 2.5 cm. (1 inch), and through this incision a ligature is carried with a curved needle around the upper pole of the gland and the overlying tissue and tied. Then the other lobe is excised with the least possible loss of blood and with painstaking minimization of traumatism to any uncocainized area. Pain and psychic stimuli should be controlled. For the technic of thyroidectomy, see Goiter, page 382.

Ligation is done by Crile as follows: Morphin and scopolamin are given, and when the patient is comfortably under their influence, she is told what she will experience. The operation is done with the patient in bed. Cocain anesthetization of the skin is used. A transverse incision not longer than 2.5 cm. (1 inch) is made through the skin and fascia over the upper pole of each lobe. A well-curved needle is passed from without inward so as to include in a ligature the upper pole and all of the structures between the incision and the larynx. The ligature should be tied close to the gland or should include some gland tissue, in order to prevent a reversal of the circulation in the anastomotic branches which communicate with the inferior thyroid artery. After the ligature is tied, the wound is closed. The same operation is done on each side.

Kocher advised ligation of two or three arteries. The easiest to ligate are the two superior thyroids (see Vol. I, page 411). In *struma vasculosa*, ligation is the operation of choice.

Crile says: "The disease may be cured in one or more ways: (1) if the brain-cells are sufficiently repaired by absolute rest; (2) if the nerve connection between the brain and thyroid be interrupted in part by tying the upper thyroid poles, which include half or more of the nerve supply; or (3) if the secreting structure of the thyroid be diminished by partial excision or by cytolytic serum. Of these three methods excision is the most effective. The immediate relief to the patient following excision is one of the most striking clinical phenomena in surgery." The value of ligation, he believes, is in the ligation of the nerves rather than the blood-vessels.

Double ligation gives great improvement in early cases. Cases in bad general condition, with feeble hearts and inanition, may be treated by ligation of the left superior thyroid vessels. This does not cause quite so severe a reaction as double ligation. The right superior vessels may then be ligated a week or two later. It will be observed that the second operation causes much less reaction than the first. If the condition of the patient permits, at the second operation, the right lobe, and possibly the isthmus and part of the left lobe may be removed.

The *after-treatment*, following either thyroidectomy or ligation, should be *rest*. Psychic stimuli, worry, responsibility, and pain should be prevented. If, after operation, a patient soon returns to the environment and conditions in which the disease was contracted, recurrence may be expected. The case demands psychic treatment, because the disease has an extrathyroid origin; the disturbance of the thyroid is only one of its results. The patient should have much rest and fresh air. Alcohol, tea, coffee, and tobacco should be avoided. Excess of salt should be avoided; this means broths as well as table salt. Ripe fruits and vegetables are desirable. An abun-

dance of pure water should be drunk. A cheerful and hopeful state of mind should be maintained.

The Parathyroid Glands.—Much experimental evidence seems to point to the parathyroids as having to do with **tetany,** and to indicate that their removal or elimination by disease gives rise to that disease. **Parathyreopriva** seems to be associated with tetany-like symptoms, and to be benefited by parathyroid medication. Amelioration of symptoms has been reported as following the subcutaneous administration of parathyroid extract, and the ingestion of Beebe's nucleoproteid, and also of calcium lactate.

Transplantation of parathyroid from animals to man has failed always to give results. Transplantation from man to man has given beneficial results in some cases. The glands are secured by carefully dissecting out one parathyroid in the course of a goiter operation, preferably on a young person. The implantation may be made in a pocket just external to the peritoneum in the abdominal wall. The best results have been obtained when the transplantation was made immediately.

The results of treatment are so uncertain that prophylaxis should receive every attention. In operations upon the thyroid, not only must enough thyroid be left to prevent myxedema, but care must be taken not to remove the parathyroids lest tetany ensue. Even when only one lobe of the thyroid is operated upon, the parathyroid should be spared. The sparing of these glands is best secured by making dissections of the thyroid within the capsule of the gland. The safest plan is to leave the posterior part of each thyroid lobe, because the two parathyroids lie in contact with it. The operations which ligate all of the thyroid vessels widely external to the gland are dangerous because of the possibility of damaging the nutrition of the parathyroids.

Hypothyroidism (Conditions in which there is a Deficiency of Thyroid or Parathyroid Secretion, such as in Myxedema, Cretinism, Thyreoprivic Idiocy, Mongolism, Dwarfism, Thyreoprivic Obesity, Tetany, Certain Neuroses, Psychoses, Sexual Disturbances, and Epilepsy).—The treatment of these hypothyroses consists in supplying the body with the products of the thyroid gland. The average internal dose of the dried and powdered glands of the sheep (1 part representing about 5 parts of the fresh gland) is 0.25 Gm. (4 grains), 3 times daily. The patient's diet should be rich in proteids and carbohydrates. The earlier this treatment is begun, the better the results. It has not been determined how much these diseases are due to parathyroid deficiency, excepting that it is known that tetany belongs to that class. The implantation of normal living thyroid gland tissue taken from man or from an animal is the physiological method of treatment. Kocher has made such implantations in the marrow of the long bones. Christiani made multiple subcutaneous implantations. Kocher's method is the best. The fresh warm gland tissue should be used at once. The implantation of parathyroid tissue is still experimental.

Implantation should be done only after the internal administration of thyroid extract has benefited the patient and thus shown the nature of the disease.

THE THYMUS GLAND

This gland grows until the second or third year of life. At this time it extends from the thyroid nearly to the pericardium, lying in the middle line, flattened, pinkish, elastic, bilateral, embracing the trachea and in the mediastinum lying just behind the sternum. It gradually atrophies, and has disappeared by puberty. *Thymic asthma,* the *status thymicus, thymic*

epilepsy, *thymic dyspnea*, *thymic tetany*, *status lymphaticus* associated with *enlarged thymus*, and other conditions, due to abnormal thymus activity, call for treatment. In some cases the *x*-rays have been of benefit in checking the malign action of the gland. General hygienic treatment should be applied in all cases.

Thymectomy is indicated when the thymus persists beyond the period in which it is required, and when its activities are productive of serious disturbances not amenable to other treatment. Usually it can be reached by a median incision exposing it in the root of the neck. If the gland is enlarged, it appears as a pinkish tumor rising behind the sternum. The cervical portion of the gland is easily removed through this and much of the thoracic portion can be drawn up and removed.

The curved transverse incision across the front of the neck gives better access. The inner borders of the sternomastoid muscles are divided and the sternohyoid muscles are cut across at their insertions.

In a case in which the physical examination had showed the gland to be wholly poststernal, I secured a very satisfactory exposure of the space, bounded below by the pericardium, and laterally by the two pleuræ, by turning back an osteoplastic flap. A ⊃-shaped incision was made in such a way that the lower transverse arm crossed the sternum on a level with the second intercostal space and the upper arm on a level with the top of the first rib. The curved vertical incision, connecting the ends of the two transverse incisions, passed down across the first and second ribs about 2 cm. (¾ inch) from the left border of the sternum. The first and second ribs and the sternum were divided in the line of the skin incision and the corresponding ribs on the right side were divided with little injury to the flap. The flap containing the section of sternum with the sternal ends of the two ribs was turned outward upon its base and the mediastinum and its contents exposed. At the close of the operation the flap was replaced and held by chromicized catgut sutures and the soft tissues sutured over the bone.

CAROTID GLAND

This small body, varying in size from that of a grain of rice to a grain of corn, and attached to the wall of the carotid at or near its bifurcation, becomes the seat of neoplasm, usually perithelioma, which on account of its close relation to the vessel often pulsates like an aneurism. The growth should be removed early, otherwise the carotid becomes involved in the neoplasm. When operation is deferred resection of a part of the common carotid and of the external and internal carotids may be necessary. When this is done we have to consider the probability of serious cerebral disturbance which follows in fully half of the cases and gives a mortality of about 25 per cent. Whenever it becomes necessary to ligate or resect the common carotid, gradual occlusion of the vessel should have been practiced, if possible, for several days before the operation. It is the *sudden* shutting off of the blood supply to half of the brain that constitutes the danger.

THE THORAX

Anatomy.—The thorax contains the lungs, heart and trunks of the great vessels (Fig. 1086). Its rigidity is maintained by the ribs which prevent collapse of the chest wall. A state of negative pressure exists within the normal thorax. Fluids and air tend to rush into it, and are expelled only by

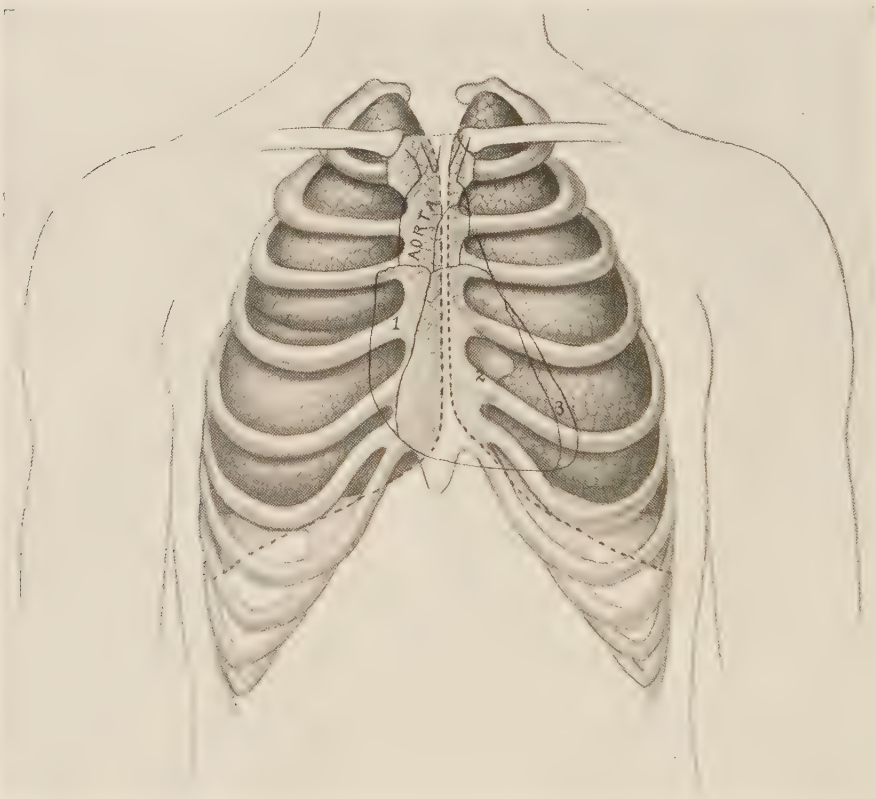

Fig. 1086.—Diagram of Front of Thorax.

The dotted lines represent the borders of the pleuræ. The heart and its compartments and the great vessels are shown in dark lines. 1, Right auricle; 2, right ventricle; 3, left ventricle.

muscular effort. The surgical anatomy of the various organs (Fig. 1086*a*) of the thorax will be found in connection with each organ.

Contusions of the Thorax.—Without causing discoverable injury of the thoracic wall, contusions may injure the heart, lungs, or important nerves to such a degree as to require treatment for cardiac rupture, valvular injury, pulmonary hemorrhage or shock. Aside from these conditions, contusion may produce a strain of the ligaments and muscles of the thorax which should be

treated by rest. If the respiratory movements are painful, the pain may be relieved by hot applications or by applying an adhesive strap as for fracture of the ribs (Vol. I, page 549). *Concussion* of the thorax, causing serious irritation to the great sympathetic centers, should receive the treatment described for shock (see Vol. I, page 213).

Chest Wall. *Non-penetrating wounds,* if small should be covered quickly with a wet antiseptic dressing, and the movements of the chest somewhat inhibited by the retaining bandage. One of the objects of this dressing is to exclude air which may be sucked in and produce emphysema. Larger and gaping wounds should be sutured and dressed as above. No chances should be taken with the possibilities of retained discharges; thorough cleansing should be done and drainage should be provided, because of the danger of infection invading the pleura or pericardium (see Wounds, Vol. I, page 186).

Penetrating wounds of the chest wall are treated the same as other wounds except that the damage to the special organs of the thorax may require at-

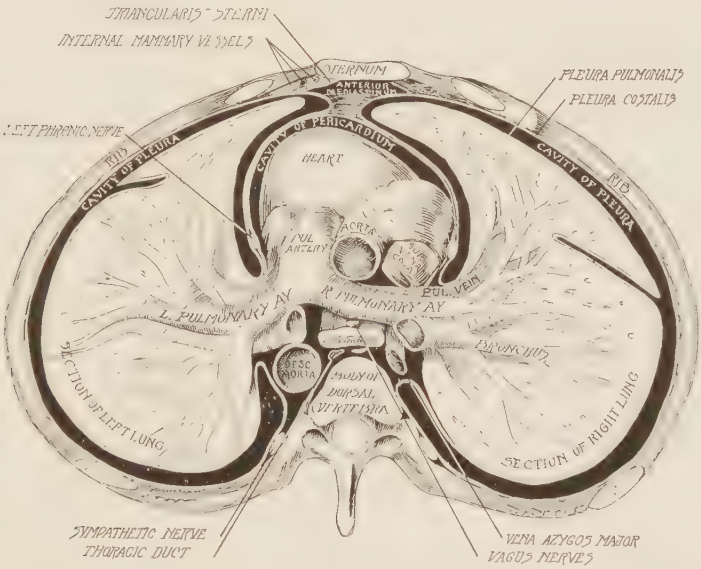

FIG. 1086*a*.—DIAGRAM OF TRANSVERSE SECTION OF THORAX SHOWING POSITIONS OF THE IMPORTANT VISCERA. (*After Gray.*)

tention (see Wounds of the Pleura, page 399; Lungs, page 413; Pericardium, page 422; Heart, page 428; Esophagus, page 431). If the symptoms of serious shock, hemorrhage or injury of important structures are not present, the wound should be asepticized and covered simply with a protective dressing. It is usually best that such a wound should not have instruments introduced into it to discover whether or not it is a penetrating wound. Suture of the wound need not be done unless the laceration of tissue is extensive. If the wound is sutured it should not be closed wholly but an opening should be left for a drain to carry off pleural exudate or other fluids.

The patient should be kept quiet. Rest in bed is most important. Sedatives and strapping the chest as for fracture of ribs, may be called for to control cough and pain.

In case of doubt, as to whether a penetrating wound involves one of the

above-mentioned important structures the wound should be enlarged and treatment conducted under exact information.

Wounds of the diaphragm are best treated by being sutured, if they are larger than 1 cm. (3/8 inch) in size. Suture is aimed to prevent hernia. The diaphragm is best exposed through the thorax. The transpleural operation is much easier and safer than through the abdomen. Wounds of the diaphragm lying near the chest wall may sometimes be sutured to the best advantage by passing the sutures so that the wounded area is sutured to the chest wall.

The approach to the diaphragm is secured by resecting one or more ribs. The wound of the diaphragm being exposed, it is best closed with absorbable sutures. Whether drainage of the pleural sac or peritoneum is required depends upon the possibilities of infection. Usually drainage of the abdomen is not required if there is no penetration of the stomach or intestine. If the wound in the diaphragm cannot be sutured the lips of the diaphragmatic wound may be sewed to the lips of the wound of the chest wall, thus obviating hernia and much reducing the possibilities of pleural infection.

Wounds of the internal mammary artery may produce serious hemorrhage into the mediastinum without much external show of bleeding. Packing the wound is not to be depended upon. The best treatment consists in compressing the vessel by means of a ligature. If the wound is sufficiently large, a well-curved needle carrying a ligature should be passed through the tissues so as to embrace the vessel. The ligature should be passed from within forward, by means of a needle on either end. If the wound is not large enough for this it should be enlarged. The vessel passes down behind the ribs, lying about 1.3 cm. (1/2 inch) from the edge of the sternum. While the ligation is proceeding, firm pressure upon the subclavian may be made at the root of the neck, behind the clavicle, just external to the sternomastoid, with a small pad held by the fingers. Both proximal and distal ligation should be done. The operation should be carried out with the utmost regard for asepsis because of the danger of infection of the anterior mediastinum.

Wounds of the intercostal artery occur in connection with fractures, external accidental wounds and in operations, and produced hemothorax if there is penetration of the pleura. This artery is so small that packing of the wound will often control it. It lies in the groove on the lower and inner aspect of the rib. A small firm plug of gauze, pressed outward and upward by means of a retractor or ligature tied about it, will control the bleeding. The most satisfactory method is to secure the vessel by means of a ligature passed on a small well-curved needle. Some surgeons have carried a ligature around the rib.

Inflammations of the Chest Wall.—*Caries* and *necrosis* of the ribs and sternum are amenable to the same treatment as is applied to other bones (see Inflammations of Bone, Vol. I, page 467). The same may be said of *arthritis of the sternoclavicular joint* and of the *costal joints* (see Arthritides, Vol. I, page 657). *Abscess of the chest wall* should be treated with aseptic care because of the possibility of its communicating with the pleura. *Syphilis* and *tuberculosis* of the ribs and their joints should receive the same treatment as elsewhere.

Costal chondritis, expressing itself in the form of *necrosis of the costal cartilages*, whether following typhoid or other infection, demands radical treatment. Usually it comes to the surgeon with a sinus or sinuses opening on the wall of the chest or abdomen, an abscess having opened or been opened previously. My own experience with this condition leads me to the

conclusion that it should not be temporized with. A wide excision of all of the diseased cartilage should be done. It is not easy to identify the place of demarcation between diseased and healthy cartilage. The cases which I have been able to cure most promptly have been those in which all contiguous cartilage was removed at the operation. The vitality of this tissue is so poor that if it is not all removed, infection and continuation of the necrosis is prone to occur in the rest of the cartilage. The best method of attack is to inject the sinuses with methylene blue solution and follow them to their utmost. The sinuses should be freely laid open and the diseased cartilage excised. If any cartilage is left the sinuses should be sterilized with phenol and alcohol, and the wound and cut cartilage surface treated the same. The whole wound tract should then be dried and throughout treated with tincture of iodin. Unless a complete sterilization of all of the wound can be secured, all cartilage in relation to the wound should be removed.

THE PLEURA

Anatomy.—The pleura is represented by two sacs which line the chest wall and cover the viscera of the thorax. The parietal layer of the *costal pleura* covers the inner sides of the ribs and the sides of the bodies of the vertebræ, and then passes to the side of the pericardium and the root of the lung where it becomes the *pulmonary pleura.* The visceral layer covers the lungs, dips between the lobes, and continues with the parietal layer at the root of the lung. The *cervical pleura* is that part which covers the apex of the lung and rises from 1.3 to 4.5 cm. (½ to 1¾ inches) above the first rib. The subclavian artery curves over it and grooves its antero-internal surface just below the apex. The scalenus anticus and scalenus medius muscles are in contact with it externally. The *diaphragmatic pleura* covers the upper surface of the diaphragm, excepting the central part which is covered by the pericardium and the extreme outer part which lies in contact with the chest wall.

Anteriorly the *margin of the pleura,* extending from the apex of the lung to the sternoclavicular joint, passes downward behind the sternum and lies in contact with the opposite pleura from the upper end of the sternum to the fifth costal cartilage. The right pleura continues downward to the xiphoid appendix and thence passes outward. The left pleura diverges and lies 1.5 cm. (⅝ inch) from the left border of the sternum at the fifth costal cartilage; 2 cm. (1 3/16 inch) at the sternal end of the sixth; and 3.5 cm. (1⅜ inches) at the level of the sternal end of the seventh cartilage. The lower margin of the pleura is reflected from chest wall to diaphragm on the right side along a line extending from the lower end of the gladiolus outward behind the seventh costal cartilage nearly to the sternal end of the rib; on the left side this line follows the lower border of the sixth costal cartilage. At the following points the lower border of the pleura corresponds with the height of the following structures: in the nipple line, with the eighth rib; in the mid-axillary line, with the ninth rib on the right and the tenth rib on the left; in the posterior scapular line (a line drawn vertically from the inferior angle of the scapula), with the twelfth rib; and at the spinal column, with the vertebral end of the twelfth rib. In some cases the pleura is as low as the transverse process of the first lumbar vertebræ.

The lower border of the lung does not extend to the limit of the pleura, but lies about two ribs higher on each side. This interval of the width of two ribs leaves the two marginal surfaces of pleura (diaphragmatic and costal) lying in contact or separated by pleural fluid.

Wounds of the pleura communicating with the outer air cause pneumothorax and collapse of the lung. If aseptic healing of the wound can be secured, the air becomes absorbed just as in emphysema and the lung gradually expands to its normal place. For this reason, the first thing that should be done with a penetrating wound of the chest and pleura is to apply an occlusive dressing. For this purpose nothing is better than a copious covering of gauze wet with antiseptic solution. If the wound of the chest wall is so large that it gaps, the occlusive property of the dressing can be improved by applying first a small dressing, covering this with rubber dam, extending well beyond its circumference, and then over all applying a larger mass of gauze. If the wound of the thorax is extensive, of course, it should

be sutured. The question as to whether drainage should be provided or no must be determined by the probabilities of infection. A small clean-looking wound need have no treatment but the occlusive antiseptic dressing. In the case of a larger wound, one that is ragged, or one that is to be sutured, the surrounding skin should be cleansed after the method described under the treatment of wounds (Vol. I, page 186). Wounds made by the surgeon, in the course of an aseptic operation, should be closed by suture, completely sealing the pleural cavity. Wounds which are known to be infected, it may be assumed, will be followed by pleuritis, and drainage should be provided.

Emphysema, occurring in connection with these wounds, usually requires no treatment, even though it spread extensively over the body. The air which finds its way under the skin will be absorbed, and will cease to enter as soon as the connective-tissue spaces in the wound become filled with exudate. If the air gives distress it may be liberated by incisions or pressure.

Pneumothorax, with collapse of the lung, without infective pleuritis, requires only the treatment of the wound through which the air entered, as described above. Associated with infection, its treatment is described under empyema. The danger of pneumothorax is from infection, and for this reason the wound should be occluded as quickly as possible. While the wound is open a gauze pad should cover it to filter the air. For artificially induced pneumothorax, see page 416.

Hemothorax is best treated by evacuation of the blood. This course is to be recommended in the cases in which the hemorrhage is from a penetrating wound and associated with pneumothorax. Then the wound may be enlarged, if necessary, the bleeding vessel secured, and the blood washed out with the aid of the blunt curet. If the wound is high in the chest, or anteriorly, it is best to make a new opening low down and posteriorly as for empyema.

Hemothorax without an external wound, as occurs in laceration of the costal pleura by a fractured rib, may be assumed to be aseptic. If the amount of blood is small, it need not be removed. If the hemorrhage is considerable, easily revealed by percussion, and producing a collapse of the lung, which is clearly manifested by diminished respiratory murmur, the blood should be evacuated. The time and site of operation must depend upon the condition of the patient and the hemorrhage. If the bleeding is not progressing, there is no urgency. If depression, due to some other conditions than hemorrhage and lung compression, is present, operation may be deferred. But at the earliest time consistent with the general interests of the patient, and at once if the bleeding is progressing and the compression is embarrassing the heart or respiration, the chest should be opened and the blood removed. Such an opening should be made as for empyema, unless the bleeding is continuing, in which event the location of the hemorrhage should be exposed, a rib resected on either side of the fracture, if necessary, and the vessel tied.

Small collections of uninfected blood in the pleural sac do not require operation. Rest in bed and a binder to diminish the respiratory movements suffice. When operation is done the question of drainage must depend upon infection. If the surgeon is reasonably confident that no infection has been introduced, and the bleeding has stopped, the wound may be closed throughout. If there is a probability that infection has been planted upon the pleura, drainage should be provided. This should be such as is used in empyema, excepting that but one short tube is necessary. It should be borne in mind that a small amount of infection can be overcome by the

pleura, and that the presence of a tube in an uninfected pleura always threatens it with infection. Uninfected collections of blood are capable of absorption. If infection occurs later, the condition may then be treated as for empyema.

Hydrothorax, or non-purulent serum in the pleural sac, usually becomes absorbed spontaneously. When the amount of fluid is so great as to embarrass respiration or the heart, or when, even though causing no distress, it is not being absorbed it should be evacuated. The treatment of tuberculous effusions is discussed elsewhere (page 413).

Aspiration of pleuritic fluid should be done with an aspirating needle, preferably connected by non-collapsible rubber tubing with a vacuum bottle (Fig. 1087). The operation should be conducted with rigid asepsis. This is distinctly a surgical operation. A general anesthetic is not required. Accurate percussion and auscultation should have located the level of the fluid.

Fig. 1087.—Aspirating Chest for Hydrothorax.

Usually the best result is secured by having the patient sitting on a table with assistants on either side. Or the patient may lie close to the edge of the table. A little cocain may be used for the skin in a sensitive adult; it is rarely needed. The arm on the side to be aspirated should be raised to elevate the ribs.

If the fluid rests on the top of the diaphragm, and is not confined by adhesions, the needle should be entered in the midaxillary line through the sixth or seventh intercostal space. If the fluid is encapsulated or confined by adhesions the needle should be entered about in its center. Unnecessary accidents may occur if this operation is not carefully done. The lung, pericardium or diaphragm may be penetrated. The chest wall is 2 or 3 cm. thick—less than this in a young child. The needle should be entered nearer the upper border of a rib than the lower in order to escape the intercostal

vessels. The sensitive hand easily recognizes the cessation of resistance when the needle has penetrated the costal pleura. The needle need be carried no farther. The trocar should be withdrawn, and fluid will run. If fluid does not flow, it may mean that a bit of fibrin has blocked the needle. This may be removed by reinserting the stilet or by applying suction. If a needle without a trocar is used it sometimes happens that a bit of tissue occludes it; this may be cleared in the same way. As the fluid runs out a dry cough develops as the lung expands. Presently the lung will be felt to strike the needle with each respiratory motion. When this occurs the needle should slowly be withdrawn until no more fluid runs, and then removed. A small pad of gauze held by an adhesive strap may be placed on the puncture. Hydrothorax may be aspirated several times before a cure is effected or the disease changes to an empyema.

Insufflation of air is of value in cases with a large amount of effusion. Air is admitted as the fluid is drawn off. This has the advantage that the compressed lung is not rapidly expanded, cough, dyspnea, and albuminous expectoration are obviated. Achard (Semaine Médicale, vol. xxviii, No. 38) in a large experience finds that the cases heal more rapidly with this method. The lung expands as the air is gradually absorbed. The evacuation should be done through sterile apparatus. As the fluid is pumped out, for about every half liter, some air should be pumped in, simply by changing the suction syringe for an injection syringe. The air sterilizes itself in passing through the syringe, tubes and bottle, provided their interior is wet. The insufflation should be stopped when the pressure of the air produces the least discomfort.

A still more simple method consists in placing the patient in a comfortable position across two beds, the chest spanning from one to the other. A trocar 6 or 8 cm. (2½ or 3 inches) long and 0.4 mm. (⅙ inch) wide, is introduced between two ribs at the lower limit of the effusion, and the fluid allowed to flow into a receptacle between the two beds. As much fluid as will is allowed to run out. Air naturally enters with inspiration. The trocar is removed at the end of a deep expiration, and the opening is closed with a piece of adhesive plaster. It has never been shown that atmospheric air does harm in the pleural cavity. It is gradually absorbed.

Autoserotherapy is effective is some early cases. Exploratory puncture is made with a glass syringe. If the aspirated fluid is found to be clear and free from pus, it is injected immediately into the subcutaneous tissue. This is done without withdrawing the needle from the chest wall but simply altering the position of its point. The injections are repeated every second or third day. From 1 to 5 c.c. (15 to 75 minims) of serum are injected each time. This method, introduced by Gilbert of Geneva, has been reported upon favorably by many surgeons. The injections probably stimulate the formation of antisubstances. This treatment has proved effective in serofibrinous pleurisy.

Pyothorax, or **empyema,** demands opening the chest wall and evacuation of the pus contained in the pleural sac. Unless this is done, a fatal termination may be expected, from prolonged septic absorption; pyemia; nephritis; embarrassment of the heart and respiration from pressure; rupture of the abscess into the lung, causing suffocation; or chronic fistula and sepsis, following rupture through the diaphragm. Some cases have healed by rupture through the chest wall or by spontaneous sterilization and absorption of the pus. Such an outcome should not be awaited.

The removal of thin pus by aspiration has in some cases been sufficient. Usually aspiration must be followed by more radical operation. Aspiration

is justified in cases in which operation cannot be done, but relief is demanded at once. It should not be expected to cure the disease.

Simple intercostal thorocotomy is performed if the case is so urgent that the operation of choice cannot be done. It consists in an incision between the ribs. It requires only a knife. After the puncture of the chest wall a drainage tube may be put in. The operation is accomplished much more quickly than aspiration. If desired, a more deliberate dissection may be made, and aspiration done before the pleura is incised. Unless the tube is very rigid the ribs will compress it and drainage will soon be shut off. A metal tube may be used to obviate this.

The operation for empyema which should be called the operation of choice consists in the removal of a section of one or more ribs, opening of the pleura, evacuation of the pus, the introduction of a large drainage tube, and subsequent protection from external infection. This is the operation of choice for all conditions in which drainage is required. The patient should lie on the sound side. Light general narcosis or local anesthesia may be used. For local anesthesia, I have found general infiltration of the tissues with weak

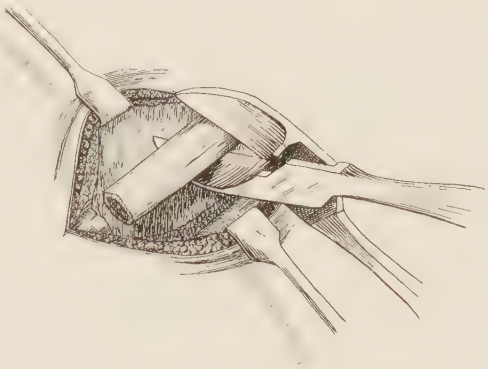

Fig. 1088.—Resection of Rib for Empyema.

anesthetic solution most satisfactory, combined with an injection of a stronger cocain solution in the region of the intercostal nerve. The cutting of the rib is painful unless the periosteum of its whole circumference is cocainized. The positive presence of pus should be determined by aspiration. Ordinarily the excision of one or two ribs is sufficient. If the pus is thin or haste is required, but one need be excised. Usually the opening should be made in the midaxillary line, at the seventh rib or in the eighth or ninth intercostal space. When the pus is sacculated or confined by adhesions, the opening should be made at its center.

An incision, about 7 cm. (2½ or 3 inches) long, is made upon the seventh rib parallel with the rib. The soft tissues are quickly dissected back and the rib exposed. The periosteum on the outer surface is incised in the middle of the rib parallel with its long axis, and peeled from the bone with a sharp elevator. The periosteum is peeled from the whole circumference of the rib, carrying with it the vessels which run in the groove on the lower border. The denuded segment of rib, 3 or 5 cm. long, is then excised by means of bone-cutting forceps or a wire saw (Fig. 1088). The section of the rib being cut out, an incision is made into the pleural sac through the periosteum and pleura. This should not be done by plunging the point of a knife through the tissues but by strokes of the knife with a decent regard for uncertainties

which may be underneath. As the pleura is penetrated, and pus rushes forth, the patient should be turned further toward the recumbent position to permit its free escape. During inspiration a sponge may be held over the opening.

Strings and lumps of fibrin should be pulled out with forceps. When the cavity has emptied itself of this material, a large drainage tube should be introduced. It is only necessary that the tube should pass well through the chest wall; it need not pass far into the pleural sac. The outer end of the tube should be secured by a suture or safety pin (Fig. 1089) to prevent its slipping into the thorax. (I once operated for an apparently incurable empyemic fistula, and found a drainage tube lying unknown in the pleural cavity, the removal of which resulted in rapid healing of the opening. The safety pin prevents this accident.)

Some surgeons remove sections of two ribs, making the incision in the eighth intercostal space. In most cases one is sufficient. Irrigation of the cavity is necessary only when masses of coagulated lymph cannot otherwise be removed. The ends of the wound are closed by sutures down to the tube. A copious dressing of gauze and cotton is held on by a chest binder.

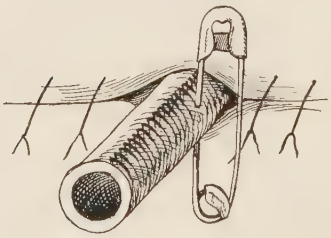

Fig. 1089.—Wound after Operation for Empyema.

The *after-treatment* consists in keeping the wound covered with sterile dressing to take up the discharge and protect the wound. Rigid asepsis should be continued without relaxation until the wound is healed. The dressings should be changed only when soaked with discharge. This is usually once daily. Irrigation is not to be used unless the discharge becomes fetid or the drainage inadequate. For irrigation a chlorin solution, a 1:10,000 bichlorid solution, a 1:1000 tincture of iodin, a 1:500 potassium permanganate, or a saturated boric acid solution may be used. The fluid should flow in without force.

Delayed healing in empyema may be due to several causes. It often happens in these cases that a rise of temperature takes place without any apparent cause. This may be due to the drainage becoming ineffective because the tube, not reaching the most dependent part of the abscess, and being surrounded by a wall of fibrin, is prevented from draining the main cavity; or because of intercurrent infection of the lymphatics. It should be seen to that the tube lies unobstructed in the suppurating cavity. If the tube is not well placed a counter opening lower down should be made. Small collections of pus may become walled off by adhesions. These should be felt for with a blunt instrument. Suppuration continuing, irrigation of the cavity may be practised daily to wash out any material which may delay healing. Careful examination may show that a tubercular pleuritis is present. Necrosis of the rib may sometimes be found to account for continued suppuration.

Ordinarily an empyema, provided with adequate drainage, should be healed in from three to six weeks. Most cases should be healed in a month. The most common cause of failure to heal is not a persistence of infection but failure of the lung to expand and occupy the whole pleural cavity. So long as there is such an unoccupied space, discharge will flow from it.

If the empyema has been of long duration or slow in development before operation was done, it may be assumed that the plastic deposit on the surface of the lung will be so great that expansion will be delayed. In such cases the

dressing applied at the time of operation and thereafter should be, not the simple dressing described above, but such dressing as is described below for the treatment of non-expansion. The surgeon may as a routine measure pursue the latter course.

To promote expansion of the collapsed lung is one of the most important desideratives after operation for empyema. The earlier the operation is done the less plastic exudate is deposited upon the pleura and the more of its natural elasticity resides in the lung. Many devices are used to promote expansion.

Sealing the wound in order to prevent the further entrance of air into the empyemic cavity is not difficult. To do this the wound is snugly closed about the drainage tube, the surface of which should be smooth. The tube is then passed through a small hole in a piece of rubber dam about 15 cm. (6 inches) square. An adhesive strip external to the rubber dam, prevents the tube from slipping (Fig. 1090). A very small bit of gauze is flatly placed on the wound, the rubber dam lying on the surrounding skin. A long tube is connected with the drainage tube and carried into a large-mouthed bottle

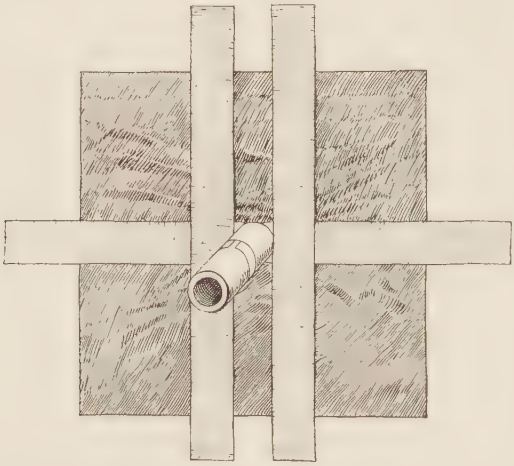

Fig. 1090.—Diagram of Occlusive Dressing to Seal Empyema Cavity. Rubber dam pierced by drainage tube and both held in place by adhesive plaster strips.

setting on the floor at the bedside. This bottle should be about three-fourths filled with bichlorid or other antiseptic solution, and the end of the tube should be submerged in the fluid. A smooth gauze dressing is placed on the rubber dam and held in place snugly by adhesive straps and a binder (Fig. 1091). As the air in the pleural cavity is forced out by expiration and is absorbed, it can not return; and what the lung gains in expansion, it keeps. When the fluid in the bottle becomes much soiled, the tube is clamped and the solution renewed. The rubber dam should be lifted up once daily and cleaned; and the skin should be dried and rubbed with alcohol. If necessary for the health of the skin zinc ointment may be used. This method may be combined with the following.

Increase of intrapulmonary pressure may be secured and expansion of the lung aided by means of blowing against resistance. Wolff devised a simple apparatus for this purpose. It consists of two bottles containing a liter or so of water, connected by a tube, and each bottle provided with an air tube. By blowing into the air tube the fluid is forced from one bottle

to the other. The patient is required to perform this exercise, once or twice daily, blowing the fluid over into one bottle and back again. Theoretically this should be effective; I have never seen much advantage from it.

Suction is applied by means of a glass suction cup and syringe (see Vol. I, page 228). In children this must be used carefully lest the lung be sucked into the wound and injured. The suction may be applied once or twice daily. It serves to remove the air from the pleural cavity and cause the lung to expand, and it also removes the pus. A rubber bulb may be attached

FIG. 1091.—OCCLUSIVE DRESSING FOR EMPYEMA COMPLETED.
The discharge is conducted into an antiseptic solution hermetically sealing the wound and the drainage.

to the drainage tube. The tube is provided with a stopcock so that the bulb may be emptied without admitting air to the cavity. The bulb is compressed and left attached to the drainage tube to exert continuous suction. When it has been filled with air and pus, it is emptied and the process repeated.

The same object is better attained by conducting the tube through the cork of a two-mouthed flat bottle. The other mouth is fitted with a cork carrying a tube to a rubber bulb. The bottle from which the air is exhausted by the bulb receives the pus. The whole apparatus may be carried suspended from the opposite shoulder (Fig. 1092).

A valve device for causing the lung to expand is made by fixing a rubber

drainage tube firmly in the wound, holding it securely by passing it through a shield, cutting the tube off closely and smoothly, and applying a piece of rubber dam over its mouth. The tube may be fixed to the shield by rubber cement. A piece of rubber douche bag may be used for the shield, or instead

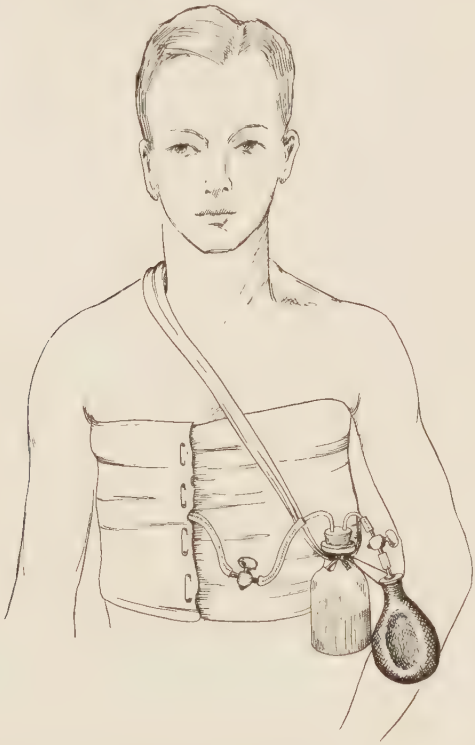

FIG. 1092.—EMPYEMA TREATED BY CONTINUOUS SUCTION.
The air is removed from the bottle at intervals by means of the suction bulb. The whole drainage system is hermetically sealed.

of this, a flanged tube may be used (Fig. 1093). All are held by bandages or adhesive straps. The rubber, covering the mouth of the tube, acts as a valve, permitting escape of pus and air with the expiratory movements but closing with inspiration. This tends to produce a rarefaction of the air in the cavity and to encourage expansion of the lung (Fig. 1094).

Ambulatory treatment may be carried out by having the patient wear a flat bottle suspended from the shoulder. The end of the tube from the thorax is enclosed in antiseptic fluid in this bottle. In acute and recent cases, the tube may be clamped and continuous drainage not allowed. Every two or three hours the clamp is released, and not more than 200 c.c. of pus allowed to escape at a time. This gives gradual dilatation of the lung.



FIG. 1093.—FLANGED TUBE FOR AIR-TIGHT SEALING OF EMPYEMA CAVITY.

Rib-trephining for empyema was recommended by S. Robinson (Boston Med. and Surg. Jour., Oct. 13, 1910). An incision is made upon the rib under local anesthesia. The outer periosteum is then anesthetized, and the

rib trephined, leaving a bridge of rib of at least 3 mm. above and below the opening. As soon as the bone is penetrated the inner periosteum is anesthetized. The button is then removed. An aspirating needle is inserted to confirm the diagnosis. A metal tube, having a screw-thread externally at one end, and the other end made to receive a rubber tube, is screwed snugly into the bone. The inner end should rest against the periosteum; the outer end should extend but slightly beyond the level of the body. The wound on either side of this tube is tightly sutured around the tube and painted with collodion. With a narrow-bladed knife, the circle of periosteum and pleura, closing the inner end of the tube is excised. The pus gushes forth without soiling the wound. No dressing is used by Robinson. A short rubber tube is fixed to the outer end of the metal tube and closed with a clamp. Suction drainage or any other device for treatment may be used. The sealing of the wound is hermetical. It should be borne in

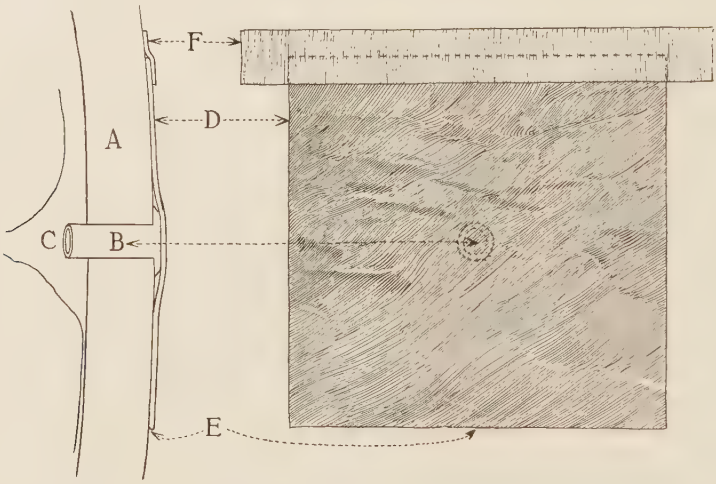

Fig. 1094.—Valve Device for Sealing Empyema Drainage.
A, Chest wall; *B*, flanged drainage tube; *C*, empyema cavity; *D*, rubber dam; *E*, lower edge of dam under which pus escapes; *F*, adhesive plaster to hold rubber dam.

mind that any metal body fastened to bone causes rarefaction, and this tube tends soon to become loose.

Operation for empyema without rib-resection according to the method of Thiersch is done as follows: A small preliminary puncture-incision is made down to the pleura, and a trocar and canula inserted between the ribs into the thorax. The trocar is withdrawn and the largest possible rubber catheter passed through the canula into the chest. The canula is withdrawn and the catheter left. A large piece of gutta-percha membrane is slipped over the tube to make an air-tight closure. The rubber membrane is fixed to the chest with adhesive strips. The catheter is connected with an especially thin-walled rubber tube which collapses with every inspiration and prevents the entrance of air. This tube empties into a pus receptacle. The catheter is prevented from slipping out by a thread tied around it and fixed by adhesive plaster and a compression dressing. Later, if the drainage proves inadequate, a rib or two may be resected at the place of puncture, when the patient has recovered from the primary disease.

Colton (Jour. Am. Med. Assoc., Vol. 54, Nov. 18, 1910) employed a non-

collapsible silver tube (Fig. 1095). He made a short incision in the intercostal space down to the pleura. The opening through the pleura is just large enough to admit the tube. The wound is snugly sutured about it. A combination trocar and tube has been used by some.

Comment.—It is doubtful whether any of the schemes for valvular protection and drainage give better ultimate results than the uncomplicated tube.

Operating for empyema through small openings and without resection of rib fails in cases with fibroplastic exudate which requires a good-sized opening for its removal. This is so commonly present that, excepting in extremely sick patients, resection of rib remains the operation of choice.

In desperately ill persons with much compressed lung, it is best not to place them on the sound side and still further embarrass their breathing, but they should be brought close to the edge of the table, and operated upon lying recumbent.

The longer an empyema exists the more does the lung loose its elasticity. The pleura is much contracted and covered with exudate which becomes firmer and tougher as time elapses. The cases in which it is found difficult to secure expansion of the lung are usually the cases in which evacuation of the pus has been long delayed.

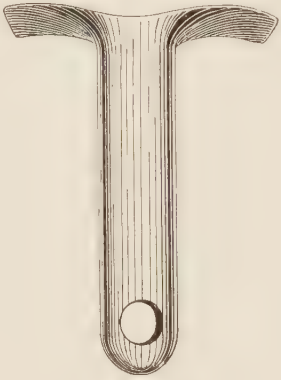

Fig. 1095.—Silver Tube for Empyema Drainage.

In making an incision for resection of a rib in the axillary line, the arm should be abducted not above a right angle. In doing so the skin is carried upward, and the surgeon should plan his incision so that when the arm is brought down the wound in the skin and muscle shall not slide down below the level of the pleural opening.

The drainage tube should be well secured lest it slip in the thorax. At each dressing it should be looked at the first thing, lest a misdirected operation later may be done to recover from the thorax a tube which had been thrown away with the dressings.

Chronic Non-tuberculous Empyema.—This condition may yield to better drainage. Under all circumstances the surgeon must assure himself that a large drainage opening has been provided at the lowest part of the cavity. Bismuth-paste injections may cure small cavities. The cases in which thick plastic exudate covers the contracted lung, in which adequate drainage has failed to bring about expansion, must come to operation. Operation should be undertaken deliberately, with a full understanding of the local and general condition, and with the purpose of saving the patient. A fatal outcome may be avoided by not attempting too much. The formidable bloody thoracoplastic operations should not be done or at least not completed in one stage. The appearance of shock should not be the signal to stop; the patient should be sent back to bed before the symptoms of shock appear. Bleeding should be prevented. The least depressing anesthesia should be administered.

Failure of the lung to expand after empyema, leaves a cavity between the lung and thoracic wall, which must be cured by expansion of the lung or by collapse of the chest wall. Unless one or the other of these is accomplished the patient will succumb to long-continued suppuration. Exercises to expand the lung and increase the mobility of the chest, and measures to improve the general health should be exhausted before operation is attempted. The

parietal pleura in old cases will be found enormously thickened. This condition is best prevented by the early evacuation of the pus in empyema. In cases which are not of long standing, expansion may be secured by inserting the finger in the pleural sac and breaking up adhesions. This, of course, fails if the plastic deposit is thick as it is apt to be in old cases.

Operations upon chronic empyema cavities to accomplish their obliteration should not be done until a large drainage opening at the lowest level has been made, and a period of six weeks at least allowed for it to effect a cure. This opening should represent the resection of at least 2.5 cm. (1 inch) of rib, and should be provided with a large drainage tube. The new drainage may cure the case. If it does not, then operation may be proceeded with. No radical operation should be done upon a patient whose toxic state might have been relieved by better drainage.

Removing *plastic deposits* from the surface of the lung should be practised when the material is so thick that it is impossible for the lung to expand. Access is secured by resecting 4 or 5 cm. (1½ or 2 inches) of five or six ribs. This may best be done through an incision passing upward from the old drainage wound. The pleura lying on the lung should be incised vertically and the index-finger inserted and used to dissect the pleural deposit from the surface of the lung. A pair of blunt scissors may then pass along with the finger and cut the thickened deposit as far up as possible. The finger is then used to dissect this membrane from the surface of the lung. It is removed as far as possible in every direction. The wound of the chest wall should be closed with drainage, and expansion should be encouraged by the same methods of dressing as are used in primary cases of empyema.

Decortication of the lung, first described by G. R. Fowler (Medical Record, Dec. 30, 1893), is done as follows: The pleural cavity is freely exposed by resecting portions of three or four ribs or by making an osteoplastic flap. The fibrinous deposit on the surface of the lung is incised and peeled off with the aid of scissors. If the lung has not undergone fibrous changes, it will expand. The operation is most successful in children. If more than five months have elasped since the empyema was first drained, success is not apt to be secured. In cases in which the fibrous covering of the lung is intimately connected with interstitial fibrous deposits, the surface membrane cannot be peeled off without tearing the lung tissue, and the operation is impossible and thoracoplasty must be done.

Thoracoplasty is done to obliterate a pleural cavity which is not filled by lung. Whatever operation is done, it must be modified to fit the case, and no operation is complete unless all of the cavity is obliterated. These operations should be preceded by a thorough determination of the position and size of the cavity. S. Robinson (Surg. Gyn. and Obst., vol. xxii, May, 1916) showed how this may be done by packing the cavity with a narrow bandage or tape, which has been soaked in a cream made of barium sulphate and water, and taking stereoscopic radiograms.

The operation of *Estlander* consists in removing portions of several ribs covering the cavity, and causing the soft chest wall to collapse against the lung and become adherent to it. Pressure by pads and a bandage holds the parts together. The ribs may be removed by a U-shaped incision or by one incision in an intercostal space for every two ribs to be removed. By this means four ribs can be removed through two incisions. The extent of the operation must depend upon the size and position of the cavity. A single vertical incision opposite the middle of the cavity may be made. Removing the intercostal muscles, deep fascia, the thickened parietal pleura, and as much of the plastic membrane as possible from the surface of the lung,

was advised by Estlander. Decortication may advantageously be combined with this operation. The operation fails to obliterate the cavity if imperfectly done; and, as a one-stage procedure, it is formidable. By performing the operation in two, or three or more stages, it has much to recommend it.

An operation devised by *Schede* is aimed to obliterate larger cavities. The incision in each case should outline the cavity. It can be used when the lung is completely retracted and is nowhere in contact with the parietal pleura. In such a case, for example, an incision is begun at the costal cartilage of the second rib, carried downward to the cartilage of the tenth rib, along the tenth rib as far as its angle, and thence upward along the inner border of the scapula to the second intercostal space. This large U-shaped flap is dissected up, carrying with it everything external to the ribs and intercostal muscles. The scapula is included. Bleeding is controlled at every point as the operation proceeds. The costal cartilages and the ribs are divided; the latter near their tubercles. The intercostal vessels are tied posteriorly and anteriorly. The entire chest wall, encompassed by these incisions, exclusive of the flap, is removed. This means ribs (from the second to the tenth or eleventh), intercostal structures, and underlying parietal pleura. The surface of the lung is curetted, and the great flap turned down and placed in contact with the lung. It is sutured in place with heavy sutures. The muscles are sutured separately, and the skin over all. Drainage is provided at the lower posterior part of the wound. A smooth dressing of gauze is so applied as to hold the soft tissues of the flap against the lung (Fig. 1096).

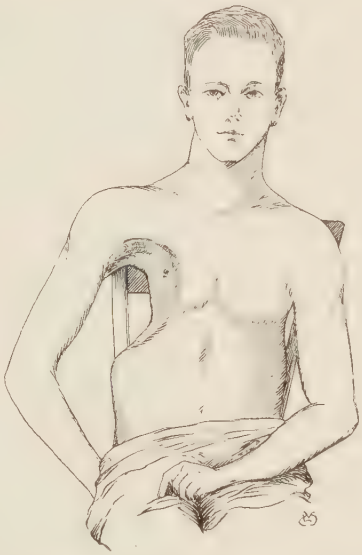

Fig. 1096.—Result after Thoracoplasty to Obliterate Large Cavity in Chest.

This operation is formidable, and should not be undertaken in one stage. It fails to cure some cases because the overhanging costal margin leaves an angle which is not filled.

Combined operations, adapted to the particular case, are best. The opening of the sinus should be enlarged by removing 7 or 10 cm. (3 or 4 inches) of the adjacent ribs, and an exploration made. If the cavity leads upward, as is usually the case, an incision is carried upward, the soft parts retracted, and ribs resected so far as is necessary to remove the rigid covering of the cavity. An incision is then made in the upper part of the wound, exposing the lung. The thickened deposit is stripped from the lung 5 or 7 cm. (2 or 3 inches), and the patient allowed to cough. It will then be seen how much the lung is going to expand. The wound should be closed with drainage.

Muscle implantation accomplishes filling the cavity and may be combined with the principles of the operations to induce collapse of part of the chest wall and expansion of the lung. A curved incision which outlines the base of the cavity is made, as in the operation of Schede. It represents only the lower part of the U. To this S. Robinson added a vertical incision, passing in the midaxillary line to its concavity. The vertical incision should extend to the top of the cavity. This inverted T-incision passes down to the ribs.

It is possible to do this operation with the U-incision alone (Fig. 1097). The skin-muscle flap is dissected up, and the underlying ribs resected and removed with their intercostal muscles, unroofing the cavity. The thickened parietal pleura is removed at the same operation or at the next. The cavity is thus freely exposed. The latissimus dorsi muscle is dissected free from the skin flap in the form of two muscular masses, split by a vertical incision. These two flaps of muscle are turned into the cavity and sutured in place, one being imposed upon the other. The skin flap is sewed back in place over the muscle, a large opening for gauze drainage being left at the bottom (see Operations on the Lung, page 453). The muscle implantation operation for old unhealed empyema was devised by S. Robinson.

Fig. 1097.—Incision for Obliterating Cavity of old Empyema.

Bismuth Paste in Empyema.—The injection of bismuth paste not only in the treatment of old empyemic sinuses but also in recent cases of empyema has been employed. Bismuth subnitrate, 5 to 33 per cent., in vaselin is used. From 30 to 120 c.c. of the 33 per cent. preparation may be injected. As much as 250 c.c. are employed. A cavity holding more than this amount should not be treated by this method. When the large amount is used, it should be of the 5 per cent. strength. In treating sinuses, the tube is removed, a bacterial examination of the discharge is made, and an injection of about 100 c.c. thrown into the sinus. The tube is not replaced. A sterile dressing is placed over the opening. This is changed daily. The paste

comes out with the pus. When all of the paste has been discharged, if the sinus is not healed, the injection is repeated.

This method has been practised four days after operation for empyema, during which time tubular drainage had been employed. Treatment by resection of rib, evacuation of pus and injection of 250 c.c. of 5 per cent. bismuth-vaselin paste, has been carried out with success; no drainage tube being used (see Bismuth Paste in Treatment of Sinuses, Vol. I, page 306).

After injecting the bismuth, if the temperature rises above 38°C. (101°F.), if pressure-discomfort is experienced, or toxic symptoms appear, the bismuth should be drained out and the opening allowed to close. Distention of the cavity is not necessary. By injecting warm olive oil into the cavity and allowing it to remain for twelve or twenty-four hours, the bismuth enters into emulsion and may easily be washed out if necessary.

The surgeon should not be too much encouraged in thinking that patients with chronic cavities have been cured by bismuth injections. The injections may have sterilized the cavity, but it still remains, and sooner or later is apt to become infected and the patient overwhelmed with a recurrence.

Tubercular Hydrothorax and Pyothorax.—Most cases of serofibrinous pleurisy in adults are tubercular; and a large proportion of these cases is associated with pulmonary tuberculosis. Their treatment from the beginning should be the general treatment of tuberculosis. By no means should the teaching be promulgated that the treatment should consist in drawing off the fluid. Particularly in unilateral disease, the effusion may be regarded as a salutary and natural manifestation, the tendency of which is to cure the disease of the lung. Pleuritic effusion complicating pulmonary tuberculosis is apt to be to the advantage of the patient, who often has a better chance of recovery with the effusion than without it (see Surgery of Consumption, page 416).

Tuberculous empyema is a cold abscess. There is little toxemia due to it. But when it discharges by an opening through the skin or mucous membrane mixed infection is sure to occur and unless good drainage is then secured, pronounced toxemia results. So long as the pressure of the fluid is not causing serious embarrassment of respiration or of the heart's action and the pus remains purely tubercular it need not be removed. In the meantime the pulmonary disease should be mending. If the pus threatens to break through the skin, it should be evacuated. This is best done by means of an aspirator under rigid asepsis (see Tubercular Abscess, Vol. I, page 281). An antitubercular antiseptic in emulsion may be thrown into the cavity.

For cases with a discharging tubercular sinus, injection of *bismuth paste* is recommended by E. G. Beck. As much as 700 c.c. of bismuth paste may be injected although it is probable that smaller amounts are as effective (see page 412). Bismuth subnitrate varying from 5 to 33 per cent., in vaselin, is used (see Vol. I, page 306).

THE LUNGS

Rupture of the lung, not complicated by penetrating wound of the chest wall, should be treated by rest in bed with the shoulders and head slightly elevated. The appearance of hemorrhage or infection call for special treatment.

Wounds of the lung with penetration of the chest wall require the treatment described for penetrating wounds of the thorax (page 397). *Bleeding* from a wound of the lung usually stops as the lung collapses by reason of the entrance of air into the pleural cavity through the wound of the thoracic

wall. If the lung has not collapsed and bleeding continues, its collapse should be secured by admitting air to the pleural cavity. If the bleeding continues, the lung should be exposed by enlarging or retracting the thoracic wound (a resection of ribs is usually necessary), and the vessels controlled by ligature, suture, or packing of the lung wound. When such an operation

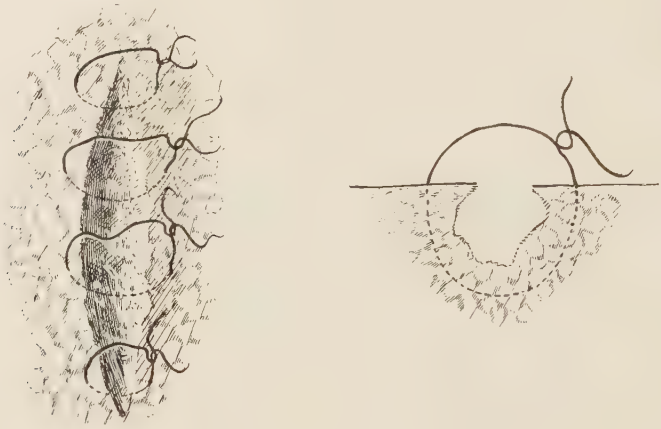

Fig. 1098.—Closing Wound of Lung with Simple Suture.

is done, the clot should be removed from the pleura, and drainage provided. Wounds of the lung of this kind are so commonly followed by *infection of the pleura*, that the surgeon is always on the safe side in providing drainage. This should be through the chest wound; but if there is much effusion, drainage should also be provided at the lower posterior part of the chest, as for empyema.

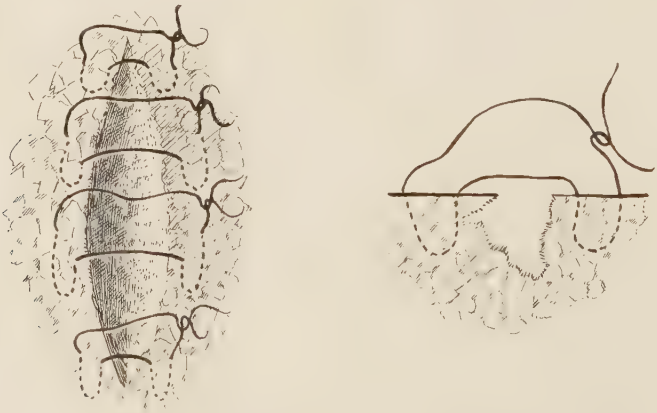

Fig. 1099.—Closing Wound of Lung with Mattress Suture.

The *suturing of wounds of the lung* is best done with chromicized catgut. Ragged edges should be trimmed evenly. Uninfected wounds, even though small, should be sutured. An inverting suture or a through-and-through suture may be used (Figs. 1098 and 1099).

Acute abscess of the lung, which commonly follows operations on the nose and throat, W. D. Tewksbury has shown (Jour. Am. Med. Assoc., Feb.

2, 1918), may best be treated by inducing artificial pneumothorax. The mortality in this condition under nonsurgical treatment is very high. Treatment by pneumothorax has given results superior to those attained by any other method.

Chronic abscess of the lung requires the same treatment as abscess in other parts. Evacuation of the pus and drainage of the cavity should be done. Spontaneous healing by absorption of the pus or by rupture into a bronchus or through the chest wall has occurred but this is rare and delay is dangerous. The cases following pneumonia and operations on the nose and throat offer the best prognosis. Brewer states that under surgical treatment, 60 to 75 per cent. recover.

Two or three ribs should be resected at the point on the chest wall nearest to the abscess. This should preferably be in the axillary line opposite the center of the abscess. The pleura should be incised carefully for but a short distance, in the hope that the incision may fall wholly within a zone of adhesions between the pulmonary and costal pleuræ. Edema of the costal pleura is a sign that adhesions are present. If the costal pleura is found adherent to the lung, the abscess should be opened by a narrow incision followed by blunt scissors or a pair of forceps to dilate the opening. The adhesions between the pleural surfaces should not be broken. A tube should be placed in the abscess and the rest of the wound packed with gauze.

If, as the costal pleura is opened, it is found not adherent to the lung, the opening should be made rather large, a gauze sponge may be rubbed over two pleural surfaces to excite reaction, and the outer wound packed with gauze. After two or three days adhesions of the lung to the chest may be expected. The formation of adhesions may be made sure by removing the soft tissues external to the pleura, and making a short incision at right angles across either end of the pleural incision; this gives two rectangular flaps, which may be turned in so that their raw surfaces lie against the lung. A couple of sutures and some gauze packing hold these flaps in place.

If the condition of the patient demands immediate evacuation of the pus, the wound may be packed all about with gauze, and the pus drawn off through an aspirator. This may have to be of large caliber, but by careful packing the pleural cavity may be spared infection. After a few days the incision may be made. Infection of the general pleural cavity requires drainage as for empyema.

In the case of *abscesses which have ruptured into a bronchus*, the induction of artificial pneumothorax is of value. The collapse of the lung may be hoped to obliterate the cavity. If the lung is adherent to the chest wall, the adhesions may be separated after the resection of two or three ribs. A pleural opening in these cases should be made if, after collapse of the lung, septic absorption continues. If a sinus persists, a plastic operation may have to be done to secure collapse of the chest wall upon the lung (see Thoracoplasty, page 410).

Gangrene of the lung is associated with infection, and for this reason drainage is necessary. Non-surgical treatment has a death-rate of about 80 per cent. Under surgical treatment the mortality is about 30 per cent. The mortality is highest in bilateral cases. The best results are secured in the circumscribed form. The disease should be exposed by the resection of ribs, as in abscess (page 456). Infection of the pleura is quite as dangerous. If adhesions are not present, shutting off the general pleural cavity, an operation in two stages, as advised for pulmonary abscess, is to be recommended. The only exception to this is in the cases which are profoundly septic and

in which relief is urgent. It may properly be held, even in these cases, that if the patient has not vitality to sustain him for two or three days until adhesions can form, he has not vitality to withstand infection of the pleura.

When the pulmonary and costal pleuræ are adherent, the lung should be incised down to the gangrenous area. Loose necrotic tissue should be removed. The central part of adherent slough may be cut out; but the hazard of bleeding is too great to warrant cutting free a still attached slough. The cavity should be packed with gauze, which should be lead out through a good-sized opening in the chest wall.

Tuberculosis of the Lung.—*Resection of the tuberculous lung* has given so high a mortality that the operation has little to recommend it, and *pneumectomy* for tuberculosis has fallen into disuse.

Drainage of tuberculous cavities by external incision has little value except, perhaps, the advantage of the induced pneumothorax which collapses the lung. In certain cases of pulmonary cavities with mixed infection and constant toxemia, drainage by incision may be of service. This should be in two stages in order to insure adhesions between the pleural surfaces (see page 456).

The *induction of artificial pneumothorax* for pulmonary tuberculosis has given sufficiently good results to warrant its recognition in cases which fail to respond to medical treatment.

In pulmonary hemorrhage the operation is of much service in selected cases. This applies to bleeding into the bronchi and also to bleeding into the pleural cavity. The hemorrhage from tubercular cavities may often be checked, and incidentally the tuberculosis checked, by admitting air to the pleural sac. (It often happens that when the thorax is opened to discover and control a bleeding point in the lung, the admission of air causes a collapse of the lung which stops the bleeding. Penetration of the lung by a broken rib may cause a wound of the lung which bleeds until the pleura is opened and air admitted.)

This operation may be done with a trocar and canula or a hollow needle about 1 mm. in diameter. Under strict asepsis, the chest wall is punctured at about the seventh intercostal space in the scapular or axillary line (see Aspiration, page 401). The place of puncture should be as far as possible from the disease in order to avoid adhesions. The patient should lie on the side, with the lung to be collapsed uppermost. The skin and pleura should be anesthetized by free injection. The surgeon should be conscious of the layers of fascia through which the needle passes. Dust-free air may be admitted. The needle should be connected with a tube about 1 meter long, through which all of the air should pass in order to render it sterile. The inside of the tube should be slightly moist and aseptic. If desired the tube may be connected with a wash bottle to demonstrate the movement of the air; or with a meter to measure it and a manometer to control the pressure.

The operation is performed more accurately if the needle is connected with a manometer. When the needle reaches the pleura, even before it is pierced, a slight advance in the indicator will be observed, showing slight negative pressure. When the costal pleura is punctured, if there are no adhesions at the place of puncture, there will be recorded a negative pressure indicated as -4 to -12 cm. of water.

Instead of admitting air, which is quickly absorbed, better results are secured by slowly introducing nitrogen. Usually a desirable dosage is 50 c.c. of the warmed gas. Nitrogen is more slowly absorbed than oxygen or carbon dioxide and it is unirritating and inert. The gas is warmed by passing through a coil in a basin of hot water between the tank and the needle. Then

the manometer is read, and more gas admitted until a slightly negative reading is shown, or a positive pressure of not more than 3 cm. The gas should not be permitted to enter until the manometer shows by negative pressure and free oscillation that the pleural sac has been entered. The cases in which there is serious hemoptysis require that marked positive pressure should be secured. The gas should be stopped if the patient has pain or dyspnea. From 200 to 400 c.c. of gas are introduced. Only after several treatments should the manometer register zero or show positive pressure. The collapse of the lung is best accomplished by injecting the gas every two to five days until a total collapse of the lung is secured. This gradual plan obviates the dangers and discomforts which are sometimes present when the heart and other organs are suddenly subjected to the unnatural pressure. After complete collapse has been secured and determined by the fluoroscope, the next treatment is deferred for ten days or a month.

This operation in selected cases is capable of arresting the disease. A. Larralde (Gaceta Med. de Caracas, Oct. 15, 1917) reported that in 18 of the 68 cases operated upon the patients were free from symptoms in some cases as long as two and a half years after the operation; another group of 18 cases was much improved.

Pleurisy with effusion occurs in a large proportion of cases thus operated upon (30 to 50 per cent.). The fluid should not be removed unless there are strong indications for its removal. If the fluid must be removed nitrogen should be introduced in its place.

Gas embolism is a less common complication. The gas may come through the needle and directly enter a pulmonary vein because of faulty technic. If the needle enters adhesions, this danger is very great.

Pleural shock, with disturbance of the respiratory and circulatory centres, is to be guarded against by care that the needle does not injure the lung, that the collapse of the lung is not rapid, and that the psychology and general physiology of the patient are protected against shock by all means known to that end (see Shock, Vol. I, page 213).

Pleural infection should be prevented by strict asepsis in the operation. Tubercle bacilli near the surface of the lung may be liberated into the pleural sac; this is an accident which can not always be foreseen.

Subcutaneous emphysema calls for discontinuance of treatment until the gas is absorbed.

The *mortality* from the operation is being reduced by experience and attention to details. A report of 2000 punctures made in forty-nine patients by Sangman showed no serious mishap.

The *indications* for the use of artificial pneumothorax are steadily being widened. Many experienced operators now apply it in all progressive cases in which the general treatment is not checking the disease. This is especially in unilateral cases. It would be useless in advanced bilateral tuberculosis, or in cases in which adhesions would prevent collapse of the lung. This leaves but a small percentage of cases as suitable for this treatment. It is not to be used in rapidly acute cases, in patients with dyspnea, in cases with pleural adhesions or superficial cavities, in cases with pronounced tuberculosis in organs outside of the respiratory tract, in badly prostrated patients, or in serious cardiovascular disease. It cannot freely be used on both sides; and is, therefore, not well adapted to bilateral cases. It may be used in chronic disease. Laryngeal tuberculosis need not contraindicate. In incipient infiltration it is especially useful. In cases with small cavities, not associated with pleuritis, it may be used. Its chief value is in hemoptysis; here it is a

positive indication, as nothing offers so much hope in this condition as collapse of the lung.

Recently, beneficial results are being reported in the bilateral treatment. But a partial collapse of the lungs can be allowed. It is suggested that the effect is due to a backing up of lymph in the lungs, producing an autoserotherapy.

The *results* of the operation in the fortunate cases are seen first in lowering of temperature by virtue of the immobilization of the infective focus. Expectoration and cough are checked, and the general condition improves. Hemorrhages are quite invariably stopped. In some cases the benefits do not appear until after several weeks. Often the disease seems to be made worse for a period before benefit is observed.

The *length of treatment* must vary, but it is best to keep the lung collapsed for six months, a year, or even longer. Good results may be seen in six months, but often the treatment must be continued for two years. When the treatment is discontinued the gas is absorbed and the lung again expands, unless the collapse has been maintained for a long time.

Remarks.—This treatment of tuberculosis should be under the guidance of an expert phthisiologist, as tuberculosis of the lung is a disease to be studied by the medical specialist and treated only under his guidance. If adhesions are present it is still possible in some cases to inject salt solution between the layers of the pleura, and separate them.

Interpleural pneumolysia was proposed by F. Torek (Surg., Gyn. and Obst., xix, 1914) for cases in which collapse of the lung is indicated as a therapeutic measure but is prevented by adhesions. The anesthesia should be by insufflation or other method of differential pressure to prevent respiratory accident. An incision fully 15 cm. (6 inches) long is made down to the pleura in the sixth or seventh intercostal space at the posterolateral aspect of the chest. After all bleeding is stopped the pleura is opened. The patient should then be placed with the head very low so that discharges from the bronchi will escape through the mouth and not run into the other lung.

The ribs are separated by retractors and first the finger and then the whole hand are introduced to separate adhesions. This should be done very carefully so that no cavity is opened. Dense adhesions should be divided by scissors. As the lung collapses the cavity is obliterated. If an opening is torn into the lung, inflation should show its location, and it should be closed by sutures.

The pleura is closed without drainage. The ribs are held together with strong sutures. Pain does not follow this operation as occurs from the pulling upon adhesions when gas is introduced. The subsequent treatment is the same as for artificial pneumothorax. The *x*-ray should determine when it is time to inject nitrogen.

Thoracoplasty, such as is done to obliterate old empyemic cavities, is effective in some cases (see page 410). This permits the lung to collapse, puts it at rest, and also adds the nourishment conveyed through the costal circulation. The principle of immobilization of the lung has been worked out by Brauer, Friedrich, Murphy and others, and promises help in cases which fail to yield to medical measures. P. L. Friedrich (Arch. f. Klin. Chir., August, 1914, cv, No. 2) proposed the term *pneumolysis* for the operation. He cut away the ribs, from the second to the tenth inclusive from their cartilage to the spine. The intercostal nerves should be divided or resected. Formerly the intercostal muscles were removed. The smallest possible amount of anesthetic should be used, and the patient should lie on his back to prevent drainage into the sound lung. Such operations are not to be done

when both lungs are affected, or when there is tuberculosis in other organs. The operation is advised in cases in which artificial pneumothorax is otherwise indicated but cannot be done on account of adhesions or some other condition.

Resection of costal cartilages has been applied especially to the first rib. The resection of the cartilages of the first ribs seems to be of some value in early cases of apical tuberculosis, especially in childhood. The mobility of the upper chest aperture is improved by the operation. Still more mobility may be had in some cases by carrying the resection down two or three ribs.

Pulmonary Emphysema.—*Rib resection* has given relief by relaxing the rigid thorax in primary alveolar emphysema. Freund advocated division of the costal cartilages. Friedrich practised removal of 4.5 to 6 cm. (1¾ to 2½ inches) of the cartilage of each rib from the second to the sixth inclusive. This is done at the chondrocostal junction, and the periosteum also is carefully removed in order to secure as much permanent relaxation as possible.

Bronchiectasis (Distention of the Bronchi, either Diffuse, Circumscribed, Cylindrical or Sacculated).—The milder cases should receive medical treatment, and surgery should not be resorted to in any case until medical and topical treatment have done all they can. In this disease the size of the bronchial cavities vary from the size of a pea to that of a hen's egg; the location most commonly affected is the lower lobes; it may affect the young as well as the middle aged or old; and in advanced cases medical treatment can do little more than make a diagnosis and improve the general hygiene. Bronchiectasis is amenable to surgical treatment. Early cases will not submit to operation, but well-developed cases will. Putrefaction of secretions in the cavities makes these patients miserable and offensive, and they are sooner or later willing to accept surgical treatment.

Treatment should be applied progressively. In the *milder cases* non-operative measures should be tried. The *thirst cure* consists in cutting down the amount of fluids allowed the patient until it is reduced to 200 c.c. daily. This reduces the amount of expectoration. On two days a week the patient is allowed more fluids. Sweat baths and oxygen inhalations are added to this treatment.

Other measures are the inhalation of *superheated air;* intravenous injection of *colloidal silver;* local application of *antiseptic drugs* through a catheter or spray, passed through the trachea.

In the more *advanced cases*, which do not yield to other measures operation is indicated. Before operation the patient should be kept in a position which best empties out the cavities—lying on the well side or in the knee-chest position. General anesthesia may be produced with ether, or nitrous oxid. The danger of pneumonia from general anesthesia is so great that local anesthesia is to be preferred (see Local Anesthesia, Vol. I, page 127). A few inhalations of alcohol, ether, or chloroform may occasionally be required. Unless an effective anesthetization of the costal pleural is secured, the patient should be given enough general anesthetic to prevent the cough and straining which is caused by its incision. The operation may be advantageously done in the negative pressure apparatus, or with artificial insufflation of the lung. Insufflation is especially desirable if a general anesthetic is used. Such differential pressure is especially desirable in cases in which pleural adhesions are not present.

The *operation* of *pneumotomy* is employed in cases in which a circumscribed disease has been diagnosed. Two or three ribs are resected near the cavity; the pleura is incised; if adhesions are not present, the lung should be palpated, and then sewed to the wound; if the patient is weak, further proced-

ure may be deferred for a second operation. The region of disease having been identified and walled off, the aspirating needle is inserted until pus is found or air sucked through the needle. The cavity having been tapped, the cautery is passed along beside the needle, or the cautery and knife may be used. If the cavity is deep and near the hilus, a blunt instrument (smaller than the finger) may be pushed in. The cavity may be found as deep as 20 to 26 cm. (8 to 10 inches) from the surface of the chest. Drainage by a large tube is essential. Unless a free opening is maintained recurrence may be expected to follow the later contractions of the drainage tract.

For exposing the middle or lower lobe, an incision in the seventh or eighth intercostal space, extending from the angle of the rib to the anterior axillary line, and the use of a strong retractor, give adequate exposure in most cases. More room may be secured if necessary by dividing the ribs above or below this.

If multiple cavities are present pneumotomy can not meet the situation, and collapse-therapy must be undertaken. The induction of *artificial pneumothorax* fails in advanced cases, and is not to be considered. Compression must be stronger and more durable than can be secured with gas.

The operation of *pneumolysis* is useful if accompanied by artificial filling of the chest cavity with transplanted or foreign material. Subperiosteal resection of 8 or 10 cm. (3 or 4 inches) of one or more ribs is done; the periosteum and fascia are then split down to but not through the pleura; the fingers are then introduced external to the costal pleura which is thus dissected free from the chest wall; the pleura collapses with the lung; and a large extrapleural cavity is created. This cavity should then be filled with fat, omentum, or lipoma, transplanted from the patient or from another, immediately or after having been kept in cold storage. This operation may be done without mortality. Most cases will be improved, but not cured.

Multiple resection of ribs (thoracoplasty) offers help in a large proportion of cases. The operation should be done under regional anesthesia. It can not be expected to cure advanced cases.

Removal of a piece of the phrenic nerve (phrenic neurectomy) is done in the neck on the diseased side. This paralyzes half of the diaphragm, and in some cases, perhaps, is of benefit. *Ligation of the pulmonary artery* improves the condition but does not cure.

The only operation that can be relied upon to effect a cure in the advanced cases of multiple foci is *pneumectomy* (see page 456).

W. Meyer (Annals of Surgery, July, 1914) showed that we have two operative methods: Artificial collapse entails little risk, and may be done in two stages; it causes change in the structure of the lung; it improves: but does not cure the disease. The other operation, removal of the diseased lobe or lobes, is a dangerous procedure but is capable of curing the disease. It is best that patients should select the first method. Pneumectomy remains as a last resort should the first operation fail to give relief.

H. Lilienthal (Annals of Surg., Vol. 64, No. 1, July, 1916) favored excision of the diseased lobe. He usually found adhesions between the lung and the chest wall. The adhesions must be separated and the diseased lobe isolated either by blunt dissection or with scissors. Adhesions between healthy lung and the chest wall should be left unbroken. The diseased lobe being isolated, its pedicle is crushed at the hilum, with a strong clamp, the lobe cut away, and the vessels tied. To prevent flapping of the mediastinum, Lilienthal passes a transfixion ligature from the distal side of the stump out through the costal wound and fastens it outside of the chest. This should not be too tight. A strip of gauze or wicking, surrounded with rubber tissue to prevent

adhesions, is packed against the stump and brought out through the chest wall. The wound is sutured except for the opening where the gauze escapes.

Infection and a complicated convalescence should be expected. Lilienthal wisely calls attention to the value of open-air treatment in these cases, and reports great improvement after a few days and nights in the open.

Extirpation of the diseased lobe or lobes is the radical operation, and may be regarded as the only curative operation. The results of the other procedures are doubtful and rarely curative.

S. Robinson (Surg. Gyn. and Obst., Feb., 1917) concluded that collapse therapy is not curative, and that excision of the diseased portion of the lung is the only curative treatment for advanced cases. The operation should be done in two or three stages. The intercostal operation is to be preferred.

Rigidity of the Chest (A Condition of Fixedness of the Ribs, Giving Rise to Asthma and Emphysema, Observed in the Arteriosclerotic, in which the Chest Becomes Barrel-shaped and Loses its Power of Elastic Contraction).—Medical treatment has been helpless against this disease. Surgery has much to offer.

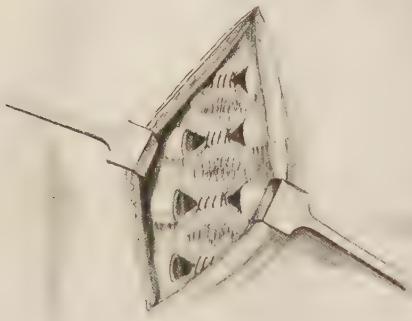

Fig. 1100.—Resection of Costal Cartilages in the Treatment of Rigidity of the Chest.

The cartilages and perichondrium are removed and the muscles sewed across the gap.

To give mobility to a chest wall which has become rigid and in which the costal cartilages have become hardened, removal of the cartilages of the second, third, fourth, and fifth ribs is most effective. By removing these cartilages an interval of 3 or 4 cm. (1½ inch) is provided, in which the ribs not only develop a hinge action but the free ends of the ribs move backward and forward and inward and outward with respiration. The perichondrium must all be removed; if it is not there is a tendency for regeneration of cartilage. A unilateral operation gives great relief; a bilateral gives still more improvement. The resections may be done through short incisions parallel with each cartilage or through a single vertical incision. The cartilages should be wholly removed. Some of the bony end of the rib may be included in the resection.

The operation to be preferred makes an incision, beginning just below the clavicle and passing downward, lying about 2 cm. (¾ inch) from the sternum (Fig. 1100). Through this incision the four costal cartilages are exposed. As each one is cut through close to the sternum, it will be observed that the patient's breathing is at once improved. The cartilage should be lifted up and separated. No perichondrium should be left; the dissection should be down to the pleura and pericardium. The cartilages may be cut with bone-cutting forceps. After the cartilages have been removed, the channels left should be closed by sewing the intercostal structures together, thus obliterating the spaces and lessening the probability of further cartilage growth. The internal mammary artery, which passes down parallel with the border of the sternum and about 1.3 cm. (½ inch) from it, should not be injured. It lies just behind the cartilages. The operation may be done with local anesthesia.

The effect of this operation is most satisfactory. The relief is instantaneous. It is not applicable to all asthmas or emphysemas, but only to the rigid chest. The operation is contraindicated by severe cardiac disease, costovertebral ankylosis, and rigidity due to disease of the respiratory muscles (spasm or paralysis).

The operation is not serious. No mortality should be expected. The first rib is omitted because experience has shown that it participates but little in respiratory movements. The technic may be modified by resecting the cartilage and leaving the perichondrium. The latter is then divided in the middle by a vertical incision, dissected up as two flaps, one of which is sewed over the end of the rib and the other over the sternal defect.

In this operation, if the pleura or pericardium is opened, the wound should at once be closed with a suture. If both sides are operated upon it should be done in two stages.

Bronchial Strictures.—Strictures, following irritation of a foreign body, syphilis or tuberculosis, often require treatment. The only treatment which can be effective is divulsion of the stricture. This is best done by means of divulsors, applied through the bronchoscope. The instruments of Chevalier Jackson are most useful (see Bronchoscopy, page 239).

THE PERICARDIUM

The pericardium occupies the middle mediastinum. In front are the sternum and the costal cartilages of the third, fourth, fifth, sixth and seventh ribs. The pleuræ lie against it laterally. Loose areolar tissue separates it from the sternum. The interpleural anterior pericardial area extends from the lower border of the left fifth chondrosternal articulation to the seventh. It is mostly behind the sternum opposite the sixth intercostal space.

Wounds of the pericardium should receive similar treatment to that described for wounds of the pleura (page 399). Bleeding should be checked and blood clots should be removed from the pericardial sac. If necessary to do this, the wound may be enlarged. A clean wound may be sutured with fine chromicized catgut. Infected wounds should be treated with antiseptics and by applying a large occlusive dressing (see Wounds, Vol. I, page 186).

Serous effusion in the pericardium should be removed when the amount is so great as to embarrass the heart or when the fluid is the seat of a dangerous infection. Spontaneous absorption takes place in most serous effusions.

Pericardiocentesis is performed for curative and diagnostic purposes. It may be done through either the fifth or sixth left intercostal space. The

patient lies supine. Local anesthesia is used. An incision is made in the sternal end of the fifth left intercostal space, from just internal to the left border of the sternum downward and outward for about 2.5 cm. (1 inch). This passes through the pectoralis major and exposes the intercostal fascia. The wound is dried and retracted. An aspirating needle is held between the forefinger and thumb and passed through the fascia close to the border of the sternum and near the upper border of the sixth cartilage. The internal mammary artery lies about 1.3 cm. (½ inch) from the sternum. The needle should pass directly backward about 8 mm. (5/16 inch), the thickness of the sternum. Thence it should pass inward and backward toward the pericardial space behind the sternum for from 1 to 2 cm. (⅜ to ¾ inch). This brings it to the pericardium, which should be punctured in a downward and inward direction. To make the puncture, in the sixth space, the needle should be entered close to the sternum in the middle of the space, and passed backward and inward to the pericardium behind the sternum. The heart should not be permitted to scratch itself upon the point of the needle.

The fifth interspace is wider and is generally preferred for the operation. The pleura is further from the sternal border at the sixth space, and when this space is sufficiently wide it is used. The puncture is made internal to the internal mammary artery. There is less danger of injury to the heart in the sixth space. A bridge of cartilage connects the sixth and seventh costal cartilages. The area between the inner border of this bridge and the sternum may be very small. In some cases such a bridge is present between the fifth and sixth.

All of the fluid should be drawn off. The operation may have to be repeated several times. It may be done without making the skin incision. The advantage of the incision is that it permits a better estimate of the size of the spaces and more accurate distance measurements. The needle and apparatus are the same as employed for aspiration of the pleura (page 401).

Pericardotomy is done for the removal of serous effusions, especially with plastic exudate, requiring irrigation. It is also done for inspection of the pericardium, removal of foreign bodies, and for drainage. An incision, 6 or 7 cm. (2½ inches) long is made from a point just internal to the left border of the sternum and carried outward and downward along the center of the fifth intercostal space. This should pass through the intercostal muscle. After hemostasis and retraction, the internal mammary artery is retracted outward or divided between two ligatures. The fibres of the triangularis sterni are separated or divided. If the pleura appears, it may be retracted outward. The pericardium lies at the bottom of the wound. It may be grasped by toothed forceps, lifted forward and incised in the direction of the intercostal space for a distance of 2.5 cm. (1 inch). If drainage is to be established the edges of the pericardium may be sutured to the deep fascia; or the wound may be closed, the pericardium being sewed with a continuous suture of chromicized catgut.

Empyema of the pericardium should be treated by evacuation of the pus as soon as the diagnosis is made. Rarely is the infection of so mild a nature as to justify simple paracentesis. Most cases should be treated by *pericardotomy*. If the simple intercostal operation does not give sufficient room, excision of costal cartilage should be added to it. The pericardial sac may be washed out with warm saline solution. The traumatism should be as slight as possible in order to prevent the formation of adhesions between the heart and the sac wall. The lips of the wound in the pericardium may be sutured to the intercostal fascia, and the wound left gaping, to be covered with a copious

antiseptic occlusive dressing. The introduction of drainage material into the pericardium is to be deprecated.

Exposure of the pericardium and heart is best done by resection of costal cartilage. This may be done by removal of the cartilage or by temporary resection in a plastic flap. The operation is employed for suturing wounds of the heart, for hemopericardium, for wounds of the pericardium, and for drainage of pus in cases in which the intercostal operation does not give enough room.

For *exposure by excision of the costal cartilage*, an incision about 9 cm. (3½ inches) long, is made from the middle line outward and downward along the fifth costal cartilage and rib. This passes down to the bone and cartilage. The latter is isolated by means of a curved periosteal elevator, divided at its sternal and costal ends with bone-cutting forceps, and removed. The intercostal vessels are identified and ligated at both ends of the wound. The internal mammary artery is exposed, by clearing away the tissues in front of it, ligated in two places, and divided; or it may be retracted outward. The triangularis sterni should be divided near the sternum or its fibers separated and retracted. The pleura will appear overlapping the pericardium from without; it should be freed from its anterior attachments, and carefully retracted outward. At the bottom of the wound when all the parts are retracted lies the pericardium. If it is desired to open the pericardium, it is lifted forward by toothed forceps and incised in the direction of the external wound. Through this opening drainage may be secured or wounds of the heart be sutured.

More room may be had, if necessary, by adding to the above external incision a vertical incision at either end, passing upward or downward, or both, depending upon whether the fourth, sixth, or both costal cartilages are to be removed in addition to the fifth. Kocher carried an incision down the median line from a point opposite the third interspace and thence downward and outward upon the sixth cartilage. This permits excision of the three cartilages.

A *plastic flap* may be made if it is known at the beginning that the removal of one cartilage will not give adequate room. For suture of wounds of the heart, operations for tumor, and wider exposures in general, a U-shaped incision may be made with its base at the sternum, embracing the fourth, fifth and sixth cartilages. These are divided at their costal attachments, the flap elevated, and reflected inward (for wider exposures, see page 426).

Cardiolysis for pericardial adhesions has been practised successfully by Brauer. He performed an osteoplastic resection of the chest wall to release the adherent pericardium (Centralb. f. d. Grenzgebiete der Med. u. Chir., Bd. 9, Nr. 11–14).

THE HEART

The heart lies behind the gladiolus of the sternum. If projects about 6.7 cm. (3 inches) to the left of the median line, and about 4 cm. (1½ inches) to the right of the median line. Its upper margin is on the level of a line drawn from a point at the lower border of the second left costal cartilage 2.5 cm. (1 inch) from the sternum to a point at the upper border of the third right costal cartilage 1.3 cm. (½ inch) from the sternum. The apex is at a point about 2 cm. (¾ inch) internal and 3.8 cm. (1½ inches) below the male nipple; or 9 cm. (3½ inches) to the left of the median line and between the fifth and sixth costal cartilages. It rests upon the diaphragm, and the level of its lower border may be defined by a line from the apex to the seventh right chondrosternal articulation.

A triangular area is not covered by pleura, and is represented by the three lines: (1) a line from the middle of the sternum opposite the fourth costal cartilages downward and outward to the apex of the heart; (2) the median line of the sternum; and (3) a line from the bottom of the sixth right chondrosternal articulation to the top of the seventh left chondrosternal articulation and thence to the apex.

The *right auricle* lies behind the right border of the sternum and the sternal ends of the third, fourth, fifth and sixth right costal cartilages. The *right ventricle* constitutes the large anterior chamber of the beart. It lies between the third and the seventh costal cartilages on the right side of the median line. The *left auricle* is behind the second left interspace and the third left costal cartilage. The *left ventricle* is behind and to the left of the right verticle (Fig. 1101).

Paracentesis of the right auricle of the heart is done to save life in cases in which there is obstruction in the pulmonary circulation. An aspirating needle about 1 mm. in diameter is used, connected with a vacuum bottle. It is directed backward and inserted at the third right intercostal space close to the sternum. It passes through the skin, fascia, pectoralis major, intercostal muscle, intervening deep fascia, a few fibers of the triangularis sterni, con-

FIG. 1101.—THE HEART.

Showing location of the chambers of the heart. The precordial triangle is that area which is not covered by the pleura and through which the heart may be approached for operation.

nective tissue of the anterior mediastinum, pleura, margin of the right lung, and wall of right auricle. The flow of blood announces the entrance of the needle into the heart. When the requisite amount of blood has been withdrawn the needle is quickly removed. The auricle is more easily aspirated than the ventricle because it is not in motion so strongly, its position is more fixed, and its anteroposterior diameter is greater.

Paracentesis of the right ventricle of the heart is done for the same conditions as aspiration of the auricle. Suction is not necessary because of the

greater pressure in the ventricle. The trocar and canula, or needle, is entered in the fourth right intercostal space about 2.5 cm. (1 inch) from the right border of the sternum. It should be directed backward and inward, and passes through the same structures as in auricular aspiration.

Exposure of the heart by a plastic flap, when a wider exposure is desired than has already been described for the pericardium, it is secured as follows: The patient should lie supine with a pillow behind the thorax to throw forward the chest and widen the intercostal spaces. A U-shaped flap lying to the left is outlined with its base inward. The incision begins at the left border of the sternum, passes along the lower border of the third rib, curves downward so that the vertical portion passes just internal to the nipple and thence back to the sternum along the lower border of the fifth rib (Fig. 1102). The flap outlined is intended to expose the lung as well as heart, and is especially adapted to cases in which the pleura has already been injured. It also allows access to the apex, outer and posterior aspects of the heart.

Fig. 1102.—Incision for Osteoplastic Flap for Exposure of Heart.
The heart may be exposed also by a similar flap with its base externally.

The fourth and fifth ribs are exposed by the vertical incision and further outward retraction of the soft tissues. The ribs are divided. The intercostal vessels are ligated and cut. The intercostal incisions are carried down to the pleura and pericardium. The internal mammary artery need not be divided. A retractor is then hooked under the outer end of each inner rib fragment and the flap dissected away from the pleura and pericardium (Fig. 1103). The flap should carry with it the ribs, periosteum, intercostal structures and the superficial tissues. In dissecting between the periosteum of the ribs and the pleura, the latter may be opened, if it has not already been. This contingency should be provided for. As the flap is turned forward and inward upon its sternal base, the cartilages are broken near the sternum.

The pericardium is picked up with forceps and incised from the lower and outer to the upper and inner aspect of the wound. If need be the incision is continued on outward into the pleura. Blood may be removed from the pericardium, and the heart exposed for operative treatment. This operation may wisely be done under differential pressure.

To prevent irritation of the heart through pericardial stimuli, M. Heitler

has suggested applying *cocain to the pericardium* when it is to be much handled (Med. Klinik, Bd. 6, Nr. 25, 1910).

See Operations on the Mediastina, page 458, for other methods of exposing the heart.

Cardiorrhaphy (suture of the heart) is done after exposure of the heart by one of the above-described operations or by the operations described for

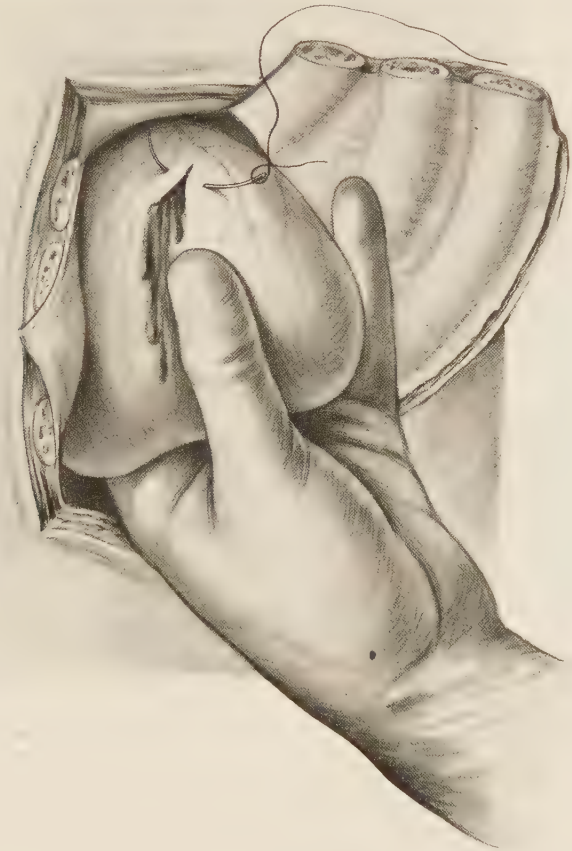

FIG. 1103.—WOUND OF HEART.

Applying first suture. The heart is held in the palm of the hand and steadied by gentle pressure with the thumb. The needle is passed during the diastolic interval between pulsations. The heart has been exposed by an osteoplastic flap with its base outward.

exposure of the mediastina (page 458). The procedure adopted must depend upon the site to be exposed. If necessary to steady the heart a temporary fixation suture of silk may be passed through the musculature of the apex.

For suturing wounds of the heart the wound should be made freely accessible. A full curved needle held in a light needle-holder is used. Fine silk is commonly employed. Fine chromicized catgut is, perhaps, preferable. The needle is quickly inserted only during diastole. The sutures are placed 3 to 4.5 mm. ($\frac{1}{8}$ to $\frac{3}{16}$ inch) from the edge of the wound. The needle should

enter the musculature fairly deeply, but not penetrate the endocardium. Passing the needle, drawing through the thread, and tying the knot should all be done during the diastolic intervals. As soon as the first suture is tied, gentle traction upon it serves to steady the heart for the next suture. Suture of the auricles may be a running or continuous suture. Wounds of the ventricles should be closed by interrupted sutures, or by sutures which are tied once for at least every two completed stitches (Fig. 1104).

Following suture of the heart the blood should be removed from the pericardium with the least possible traumatism to its lining. The pericardial wound may be closed in clean cases. Usually it is best to sew its edges to the intercostal muscle, and carry a drain through the superficial tissues down to it but not within the sac (see Wounds of the Heart, below).

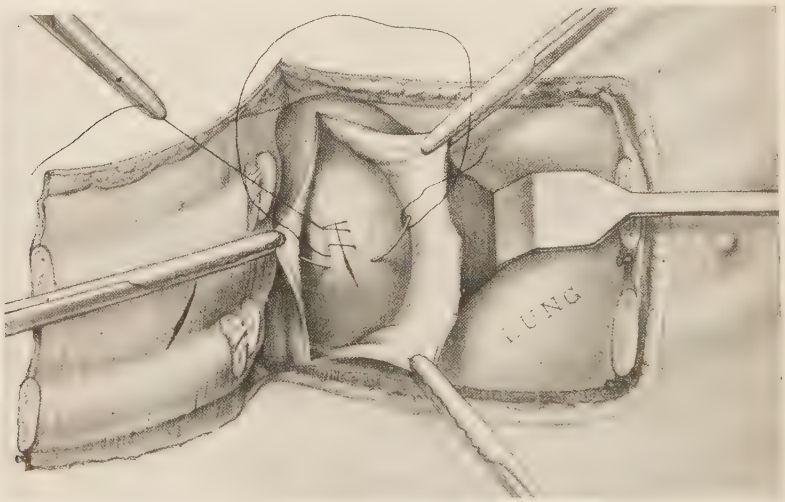

Fig. 1104.—Wound of Heart.
Applying a continuous suture. The heart is exposed by an osteoplastic flap with its base inward. Note clamps on pericardium.

Wounds of the heart should be exposed unless there is no deviation from the normal action of the heart or apparent collection of infected blood in the pericardium. Usually wounds of the heart will require to be exposed, the indications being the position and direction of the wound, and the cardiac embarrassment. The exposure may be made by one of the operations described for exposure of pericardium and heart or mediastina. If there is a wound of the chest wall, usually no typical operation will be done, but the wound will serve as the guide, and sufficient ribs and cartilages will be resected to give the desired exposure. Such wounds should not be probed, as probing can reveal but little and is capable of doing great harm in the opening of sealed wounds, in making new channels, in spreading infection, and in misguiding the surgeon. If the pleura has been opened, much time will be saved by not attempting to spare it.

The operation cannot be begun upon the basis of an accurate diagnosis. Upon opening the pericardium it may be discovered that there is no wound of the heart but only of the pericardium. In such an event, the surgeon should be thankful. He should remove blood clots from the pericardial sac,

partly close it with sutures, and conduct drainage down to but not within the sac (see Wounds of the Pericardium, page 422).

A non-penetrating, small, superficial wound of the heart does not require to be sutured. A wound with gaping of the musculature does, because, unless it is sutured the heart wall is thinned at that place, a patch of scar tissue will develop in the wall, the heart is more apt to become adherent to the pericardium, bloody oozing is more apt to supply serum for bacterial growth in the pericardium, and infection is more apt to occur.

Wounds of the heart which penetrate its chambers should be sutured if the patient can be brought alive to the operating table. After opening the pericardium the relief of pressure, following evacuation of the pericardial blood, may cause overwhelming hemorrhage from the heart wound. This should be controlled by taking the heart in the hand and stopping the wound with a finger while the blood is removed and the first suture introduced. R. Haecker (Archiv für klin. Chirurgie, Bd. 84, Nr. 4, S. 917) has shown that in dogs the afferent vessels can be compressed during operation, keeping the heart practically empty and a bloodless operation done. This was accomplished by displacing the heart forward to angulate the vessels, by digital compression, and by temporary clamping of the venæ cavæ. Some of these expedients can probably be employed in man. After the first suture has been tied it may be used to hold the heart and steady it (see Cardiorrhaphy, page 427).

Of the cases of suture of the heart which have been reported, drainage of the pericardium was employed in most of them. There are, perhaps, 300 or 500 such cases in the literature. Salomoni (Archiv Générales de Chirurgie, vol. iii, Nr. 9, collected reports of 158 cases with recovery in 59. Death occurred in 21 cases before the operation had been finished.

The heart is not the delicate organ it was once supposed to be. It has an enormous capacity to withstand mechanical insult. Its chambers may be tapped and wounded without serious consequence. The location of the injury is the important factor. A wound of an auricle may be fatal, whereas an oblique wound of a ventricle may scarcely give rise to leakage because of the closure effected by each systolic contraction. Wounds near the essential cardiac motor nerve ganglion (bundle of His) are apt to be fatal at once.

Foreign bodies in the heart may remain for a long time without producing serious consequences. A bullet or other blunt object embedded in the heart wall and not producing serious disturbances may be allowed to remain; if the *x*-ray examination shows it to be easily accessible, it may be removed. Pointed objects tend to migrate and provoke trouble; whether they are producing serious symptoms or not their removal is always indicated. When such an operation is attempted, it should be regarded as only an attempt, for if in the course of the procedure it appears that the removal of the foreign body means the sacrifice of the patient the completion of the attempt should be foregone. D. G. Zesas (Fortschritte der Medizin, Bd. 28, Nr. 21, S. 649, 1910) collected records of 118 cases of foreign body in the heart, 96 having reached the heart through the chest wall, 12 from the alimentary canal, 4 by way of the blood-stream from some other part of the body, and 1 from the air passages. The object was a needle in 54 cases and a bullet in 38 cases. Besides these were such objects as a nail, a thorn, an iron peg, a splinter, and a hair pin. Koch found a large nail embedded completely in the heart of a man who had died of an entirely unrelated disease. In the case of a man operated upon by Manteuffel, after the wound of entrance in the anterior surface of the right ventricle had been sewed the bullet was removed

from the cavity of the ventricle through an incision made in its posterior wall. The patient had an uneventful recovery.

Many and marvelous instances of recovery from shrapnel and bullet wounds and other foreign bodies are found in the surgical reports of the war.

Air embolism, occurring through a wound of the vena cava, Schoene has suggested, could be met by temporarily clamping the vena cava or pulmonary artery close to the heart, and at once aspirating the air through a strong suction syringe out of the branches of the pulmonary artery as Trendelenburg did for pulmonary embolism.

Heart massage for cardiac syncope (reanimation of the heart) has been referred to under Anesthesia (Vol. I, page 98). This operation can often be of much service. In *cardiac failure of the newborn*, the ordinary measures of resuscitation often fail. Massage of the heart may be applied by placing the thumb over the precordium and hooking the fingers under the free border of the ribs, thus grasping the heart in the hand, and making rhythmic pressure upon it.

In the adult several methods are in use. They are required chiefly after chloroform syncope, embolism and poisoning. Division of ribs and grasping the heart, while giving the best mechanical control, have not proved of much value. It is not necessary to take hold of the heart, the important thing is to compress the ventricles, and stimulate the nerves of the heart muscle. This can best be done by opening the abdomen above the umbilicus, passing in the hand to the under surface of the diaphragm, and compressing the heart upward and forward against the anterior chest wall. The pressure should aim to squeeze the blood out of the ventricles. It should be rhythmic and applied about 60 times a minute. When spontaneous contractions occur, the pressure should accompany them as much as possible. If the ventricles have not filled at the end of a second, the pressure should be made less frequently. The return of the blood to the heart is important. This may be facilitated by elevating the legs and pelvis. The latter operation also has the effect of relaxing the diaphragm and making massage more effective.

Artificial respiration or tracheal insufflation should be practised at the same time. Adrenalin or pituitrin may be thrown directly into a vein or artery. Intravascular injection of serum or salt solution is also of service. Electric stimulation of the heart is useful. The surface of the body should be kept warm. Centripetal massage of the extremities and lowering of the head should be practised. Subdiaphragmatic massage is most effective when an abdominal opening has already been made, and the delay and depression of opening the abdomen after the syncope is not necessary. The massage should be continued a while after the heart has begun to beat spontaneously. The earlier it is begun the better. It should be started within five minutes. After ten minutes the results are poor. Fifteen minutes of massage may be required before the heart responds.

THE ESOPHAGUS

The esophagus extends from the pharynx at the level of the lower border of the cricoid cartilage between the fifth and sixth cervical vertebræ, and, after passing through the diaphragm at the level of the body of the eighth dorsal vertebra, ends at the stomach 2 or 3 cm. below the diaphragm, opposite the tenth dorsal vertebra. The distance from the incisor teeth to the esophagus is from 14 to 18 cm. (5½ to 7 inches); the length of the esophagus is from 24 to 28 cm. (9½ to 11 inches); the distance from the incisor teeth to the stomach is from 38 to 46 cm. (15 to 18 inches) (Fig. 1105). The narrowest part of the esophagus is at its beginning. It is constricted also at the

fourth dorsal vertebra and at the diaphragm. It follows the anteroposterior curves of the spine. At the root of the neck and at the diaphragm it curves to the left, and is in the middle line at the fifth cervical and fifth dorsal vertebra. *In the neck*, it has in front the trachea, left lobe of thyroid, and left recurrent laryngeal nerve; behind are the spinal column and its muscles; to the right are the common carotid artery and the right recurrent laryngeal nerve; to the left are the carotid artery, left inferior thyroid artery and vein, left subclavian artery, and thoracic duct. *In the thorax*, it has in front the lower end of the trachea, left bronchus, arch of aorta, left common carotid, left subclavian artery, pericardium; behind are the spinal column, thoracic duct, right intercostal arteries and veins, left inferior azygos vein, lower part of thoracic aorta; to the right are the pleura and large azygos vein; to the left is the pleura. The pneumogastric plexus is on either side (Fig. 1106).

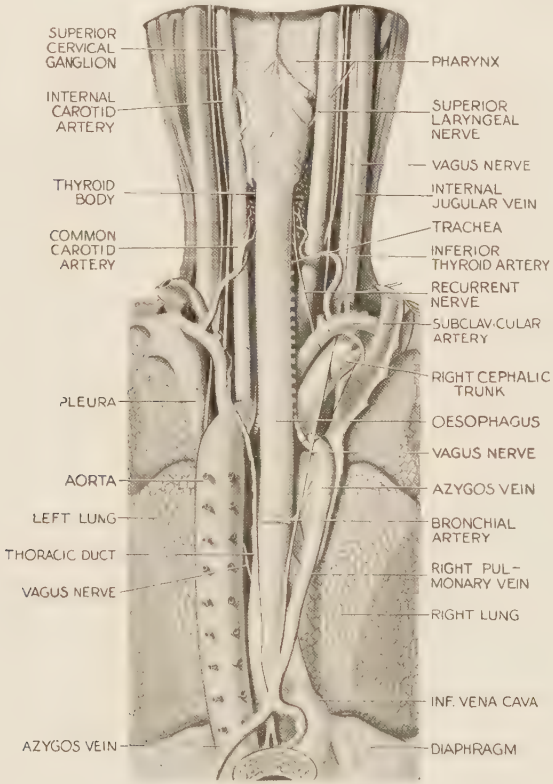

FIG. 1105.—ESOPHAGUS.
Diagrammatic. Seen from behind. (*After Poirier, Charpy and Gray.*)

Wounds of the esophagus are always serious because of the danger of infection extending to the mediastinum. Slight wounds or abrasions of the mucous membrane should be given every consideration to avoid infection. Particles of food should be washed out with clean water. Nourishment should be given per rectum. No food should be taken by the mouth until protective exudate has sealed the wound. At first the diet should be fluid, and this gradually increased to solid diet.

Perforating wounds, if inflicted from within, should be cleansed through the esophagoscope and the wound, if large enough, washed out and packed with gauze once daily. Perforating wounds inflicted from without, such as

stab wounds, are usually complicated by injury of other important structures. In the treatment of the other injured structures, the esophageal wound, if possible, should be exposed and sutured. It is possible in neck wounds for the esophagus alone to be injured. When this is the case, the wound should be enlarged, retracted, cleansed and the esophagus sutured with two layers of chromicized catgut. The wound external to the esophagus should be left open and drained. In wounds of the thorax, penetrating the esophagus, opening of the chest under negative pressure or with lung insufflation may be done. Posterior exposure of the mediastinum may give the best access (see Cervical Esophagotomy, page 442; and Thoracic Exposure of Esophagus, pages 459 and 463).

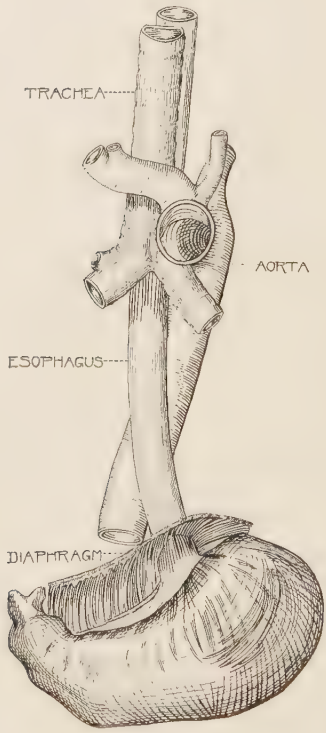

Fig. 1106.—Esophagus, Trachea, Bronchi, Aorta, and Stomach, Relations.

Rupture of the esophagus practically always means preëxisting disease. Its treatment is the same as that of perforating wound, excepting that it is more urgent, because it usually occurs in the act of vomiting or swallowing, and food is projected through the rent. Unless this foreign matter is quickly removed from the periesophageal connective-tissue spaces, death from infection should be expected.

Hemorrhage from the esophagus, not severe enough to prove fatal and too severe to be neglected, may be treated by swallowing bits of ice, by the local use of styptol or adrenalin. The bleeding point may be searched for with the esophagoscope and cauterized or compressed by a gauze packing controlled from above. An inflated rubber bulb or a dilating bougie may be used.

Inflammations and Ulceration.—*Corrosive esophagitis*, caused by swallowing corrosive substances such as acids, caustic alkalies, etc., often end fatally from their effect on the stomach before treatment can be applied. The chemical and physiologic antidotes should be given at once and the poison diluted. A stomach tube should be introduced very carefully and the substance removed from the stomach. Emetics should be avoided because of the danger of mechanical injury to the esophagus. If the corrosion has been so severe as to produce sloughing or occlusive swelling, a *gastrotomy* should be done. This serves for inspection of the stomach, and, if the stomach is found not too badly damaged, for subsequent feeding and for dilatation purposes. If the stomach and pylorus are badly corroded *duodenostomy* is to be preferred. In severe cases if a fistula for feeding is not made nourishment should be given by rectum.

Acute catarrhal esophagitis, caused by milder chemical or mechanical irritation, is treated by rest, rectal feeding and the occasional ingestion of mild astringent solutions.

Abscess of the esophagus, occurring in connection with wounds, esophagitis, or periesophageal infection, should be discovered by the esophagoscope and incised through that instrument. It is possible to reach an abscess in the thorax by performing esophagotomy and dissecting down in the retro-eso-

phageal space to the side of the great vessels. On the right side it is possible to dissect down behind the vessels. These operations are called *cervical mediastinotomy.*

Gangrenous esophagitis is an extremely serious condition if primary and infective in origin. So much septic absorption goes on that, if the disease has not reached the intestine, the best plan of treatment, perhaps, is gastrotomy, with washing of the stomach through the fistula before pouring in the food. I have operated upon such a case too late because the gangrenous process had extended also to the intestine.

Chronic esophagitis, following the acute form or resulting from chronic irritation or infection, should be treated by removal of the cause if it is known. Alcohol and tobacco are often causative factors. Following acute infectious diseases, it subsides with careful feeding and good hygiene. When due to thrush, the application of borax or boracic acid solution is effective.

Ulcers of the esophagus commonly follow chronic inflammation and are best treated by the local application of silver nitrate solution through the esophagoscope. The treatment of pressure ulcers is obvious. **Fissures** should be located by careful examination and treated with silver nitrate. When ulcers or fissures refuse to heal under local applications gentle curettage should be applied and followed by silver solution and rectal nourishment.

Congenital stenosis (atresia) **of the esophagus** may close the esophagus. Such a condition may be determined by passing a catheter or sound from above and one from below and feeling that a diaphragm separates the two. This diaphragm may be punctured by an electrocautery point or by a knife passed through a tube; and a tube left in place.

This operation is rarely the indicated procedure because in most cases each segment of the esophagus ends in a blind pouch, and the upper end of the lower segment communicates with the trachea or a bronchus, forming a free communication between the lungs, the gullet and the stomach. H. M. Richter (Surg., Gyn. and Obst., xvii, 1913) in such cases used intratracheal insufflation ether anesthesia. A preliminary gastrostomy was done; a temporary clamp was placed on the jejunum; a sound was passed up the lower segment of the gullet; an incision was made in the right sixth intercostal space, the inner end carried upward, and the sixth, fifth, and fourth ribs divided at their angles; a ligature was tied about the connection between the gullet and the trachea; the lung was dilated to fill the chest; the chest wall was closed; and a gastrostomy tube left in the stomach for feeding.

The ideal operation would be closure of the tracheal opening, and end-to-end anastomosis of the gullet segments.

Stricture of the Esophagus.—*Cicatricial stenosis*, usually caused by swallowing caustic substances, though it may result from any of the forms of esophagitis, is treated by dilatation. For at least five or six weeks after a corrosive chemical has been swallowed, or if there is fever, or blood in the vomit, dilatation should not be attempted. A sound should not be passed in the presence of serious cardiac or pulmonary disease, aneurism of the aorta, or an extremely excited nervous condition. Esophagoscopy should be done to determine the location and nature of the constriction. If this cannot be carried out the information should be secured by means of sounds (Fig. 1107). For dilating strictures, various forms of instruments are used. Sounds made of fabric, covered with rubber, dilatable rubber bulbs, tents of compressed sea-sponge, silver balls attached to a string, and olive-tipped sounds are most commonly employed (Fig. 1108).

The *introduction of a sound* requires delicacy, some skill, and much judgment. It is best that the patient should sit perfectly erect on a simple chair

with a back. He should be instructed to breathe through the mouth rather rapidly, to make no resistance, and by no means to touch the sound with his hands. He should hold a basin and be instructed to allow the saliva to run out of the mouth. Plates of false teeth should be removed. If preferred, the patient may lie on the right side with a pillow under the head to prevent lateral curvature. An extremely sensitive pharynx may be touched with 7 per cent. cocain solution. In children a gag should be inserted between the teeth. A sound marked with the various distances is advised. The first sound should be a soft stomach tube or catheter. A small piece of gauze placed upon the tongue enables the operator to depress the tongue with his left forefinger, if necessary.

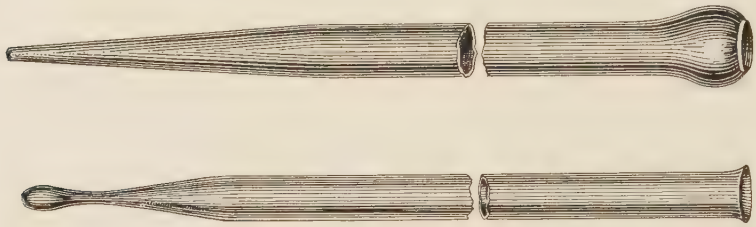

Fig. 1107.—Esophageal Bougies of Flexible Rubber.

The sound should be lubricated by dipping it in warm water or by oiling its surface and bent before introducing it (Fig. 1109). The patient should extend the cervical spine to straighten the canal. As the sound passes from the back of the pharynx to the esophagus, the head should be bent forward, the patient instructed to swallow, and with this the sound passes into the esophagus (Fig. 1110). If an obstruction is met, it is probably spasmodic contraction of the circular fibers of the gullet. This relaxes after a few seconds and the sound passes onward (Fig. 1111). A stricture or obstruction gives a different sensation; it is impassable until a sound is used which is small enough to pass it. No force should be used either in passing a spasmodic contracture or an organic stricture. Local pain should not be caused,

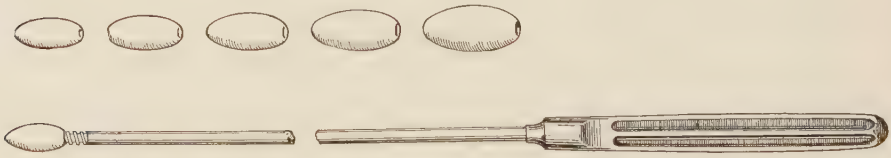

Fig. 1108.—Olive Bougies with Flexible Whalebone Stem.

for it means inflammation, ulcer, or tumor, and a dilating sound is best not used in these conditions. Care should be taken that the wall of a diverticulum is not penetrated.

The preliminary diagnostic examinations should have rendered the patient accustomed to the sounds. A small opening through the stricture may be found by twisting the sound and trying it at different positions. The stricture having been passed, the next larger size should be used, and so on until the ordinary stomach tube can be passed. If progress is being made, the surgeon should be satisfied with a moderate degree of dilatation each day. If bleeding is caused the operation should be discontinued for that day. Swelling of the mucous membrane, caused by the sounds, subsides in a few

days. Cicatricial strictures should be dilated once or twice a week; cancerous strictures daily. The patient soon learns to pass the sound himself.

FIG. 1109.—INTRODUCING ESOPHAGEAL BOUGIE.
The tube has been wet in warm water and bent to a gentle curve.

FIG. 1110.—INTRODUCING ESOPHAGEAL BOUGIE.
The head is extended, the bougie enters the pharynx, and as the patient makes a swallowing motion the tip glides into the esophagus.

The *dilatation of esophageal stricture by mercury* has much to recommend it. It may be combined with retrograde dilatation. The mercury finds its way through the stricture. It does not stick to the wall; and may be re-

covered through the gastrostomy opening. It may be allowed to pass off through the bowel. Valuable x-ray pictures may be made while it is passing the stricture.

When efforts at dilatation by sounds, tents, mercury, collections of filiform bougies and dilators fail, both unguided and by the aid of the esophagoscope, operative relief is called for.

Operative treatment of stricture of the esophagus is indicated when attempts at dilatation have failed, when the patient is suffering from lack of nourishment because of inability to swallow sufficient food, when ulceration or inflammation demands that the esophagus should have rest from manipulation or deglutition, or when an accompanying diverticulum renders the passage of sounds hazardous. *Gastrostomy* is the first step for relief. This permits the patient to be fed and the esophagus to be rested. After a while it may be possible to pass the stricture with a sound from above.

If this does not succeed, the method of *von Hacker* may be tried. The patient swallows a silk thread, one end of which is brought out of the mouth or nose and fastened around the neck. This thread has passed on to it a

Fig. 1111.—Introducing Esophageal Bougie.
As the tip enters the esophagus the head assumes a natural position and the bougie is moved gently downward.

series of steel beads ranging in size up from that of the head of a pin (2 mm.). The lower end of the thread is brought out through the gastrostomy opening. Larger and larger beads are threaded and passed down through the stricture and recovered below. Henle devised an electromagnet for recovering the beads from the stomach. Some surgeons have fastened the beads to the thread 3 or 4 cm. apart and permitted the thread to move downward. This may be followed by a catheter having a silk thread passed through its apex (Fig. 1112). The lower end of the silk thread, whether beads are used or not, may be recovered at the gastrostomy opening by injecting water into the stomach and allowing it to run out rapidly; or forceps, or a blunt hook may be employed.

Sometimes when a tube cannot be made to pass the stricture from above, it may be pulled up from below. *Ochsner* brought a loop of silk thread out through the stomach opening. Through this loop a long, small, soft-rubber drainage tube is passed and doubled back at its middle. This is then pulled

up to the stricture by traction through the mouth. By pulling the string above and the tube below, the latter may be stretched small enough to pass the stricture, and then be relaxed. This gives very effective dilatation, and may be left for both dilating and feeding purposes.



FIG. 1112.—CATHETER WITH SILK THREAD THROUGH THE APEX, USED BY AUTHOR, IN THE ESOPHAGUS.

After beginning dilatation has been secured a drainage tube may be pulled down into the stricture and left there for a few days. The size may be increased from week to week. As soon as dilatation, sufficient to admit an 8 or

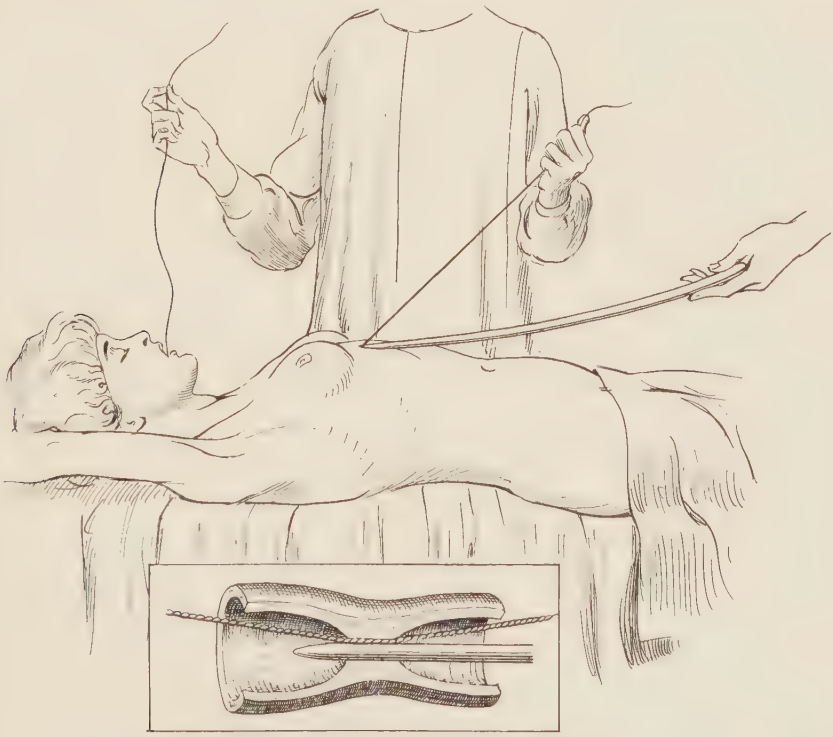

FIG. 1113.—CUTTING STRICTURE OF ESOPHAGUS WITH SILK THREAD.
The bougie is engaged in the stricture through a gastrostomy opening while the thread-saw is operated. (*After Gottstein in Keen's Surgery.*)

10-mm. sound has been secured, dilatation by sounds may be instituted and practised twice daily. To prevent recurrence, the passage of sounds must be kept up faithfully for several months and then the interval gradually increased.

Mechanical contrivances for affecting *rapid dilatation* at one sitting are not as safe or efficacious as the gradual operation. Wounds and fissures easily become infected, more scar tissue is formed or periesophageal infection may occur. *R. Abbé* passed a silk string through the stricture by causing the patient to swallow a shot on its end or by means of an instrument. The lower end is brought out through a gastrostomy opening. The upper end is brought out through the mouth or through an esophagotomy opening above the stricture. The stricture is then made tense by pressing a conical bougie into it. By drawing the string up and down with a rapid sawing motion the stricture is divided (Fig. 1113). After this, sounds are passed regularly to prevent recurrence. If the operation has passed smoothly, and the sound has been easily introduced, the stomach opening may be closed at once.

Resection of the stricture through the neck or mediastinum has been practised. More recently resection and esophagogastro-anastomosis have been done under negative air pressure (for Mediastinal Operations, see pages 459 and 463).

Dilatation by *electrolysis* is sometimes useful. The negative pole is applied to the stricture by an olive-shaped electrode introduced through the mouth, stomach or esophagotomy opening. The positive pole is placed on the skin of the chest. The *electrocautery* has been used with variable results. *Internal esophagotomy* is dangerous unless done through the esophagoscope with the aid of the eye. Because of the closeness of vital organs no deep or uncontrolled incision should be made. When done through the esophagoscope in strictures projecting far into the lumen the results are good. About three incisions should be made. Without the aid of the eye, multiple incisions may be made about the circumference of the stricture. The operation should be followed by systematic dilatation with sounds.

Dilatations of the Esophagus.—*Dilatation* involving the whole circumference of the esophagus, when due to stricture or cardiospasm, are treated by correcting the causative condition.

Chronic dilatation, occurring just above the diaphragm, usually requires relief of the narrowed cardiac orifice. This may usually be secured by making a vertical incision through the cardia and closing it as a transverse incision. But in extreme dilatation of long standing there is often a sagging of the esophagus so that it lies upon the diaphragm as a pouch. If the pouch is very large or the sagging causes an S-shaped bend, it may be necessary to make a second esophageal opening in the diaphragm and perform esophago-gastrostomy.

Usually in chronic dilatation it may be assumed that a more simple operation will suffice. The esophagus may be drawn down through the diaphragm until the relaxation is removed from the thorax and the bulging pouch lies in the abdomen. The cardiac obstruction may then be treated (see Cardiac Stenosis, page 715), and the dilated pouch may be plicated if that step seem necessary (for approach to Cardia, see pages 716 and 756; approach to Esophagus, pages 459 and 470).

Diverticula should be treated, first by the cure of stricture, if any exists. If the diverticulum is of such a sort that it catches and retains food, it should be washed out, and experiments made to find if there is any position in which the patient can place himself in which food will not pass into it. If the entrance of food cannot be prevented, experiment should be made with passing a tube beyond it and feeding through the tube. The most important thing is to keep food from becoming lodged in it and undergoing decay. When this has been accomplished, the sac should be kept washed out and cleansed. Astringent antiseptics may be employed to promote contraction of its walls.

If there is a pouch which cannot be drained, it may be possible under esophagoscopy to divide the spur between the esophagus and the lower part of the pouch, in order to bring its outlet on a level with its floor. This may be done with the electrocautery or the division may be made at the side of a clamp with a cutting instrument. When the diverticulm has been made clean, dilatation of the esophagus at its mouth by means of an inflatable rubber bulb may help throw its cavity into that of the esophagus and obliterate its pouch. This method has been advocated by Lotheissen (Muench. med. Wochenschrift, S. 76, 1906). By these methods the disease may be prevented from destroying the patient.

If treatment is not undertaken, but food continues to enter the diverticulum, a fatal outcome is only a matter of time. The prognosis is bad, and the end wretched. Death results from infection of the mediastinum, from pneumonia caused by regurgitated and aspirated food, abscess or gangrene of the lung, empyema, or inanition. If treatment does not keep the pouch empty and clean, or if curative treatment is not undertaken, gastrostomy should be done and the patient fed through the gastric fistula.

Extirpation of the esophageal diverticulum is the curative operation. It was first done successfully by von Bergmann in 1890 (Archiv für klin. Chir., Bd. 43, 1892). Up to 1918 a large number of cases had been operated upon with about 12 per cent. mortality. Only the disease accessible through the neck is embraced in these statistics. Before operating in the neck, a preliminary gastrostomy should be done two weeks before the operation. A straight sound or esophagoscope is passed into the diverticulum through the mouth. The pouch is then exposed as in cervical esophagotomy (page 442) the operation being done upon the diseased side. The sound makes the pouch project into the wound. The diverticulum is dissected free and isolated down to its mouth or pedicle. The sound is then withdrawn from the pouch and caused to pass a short distance into the esophagus below the pouch opening to serve as a guide. The wound being protected with gauze pads, the diverticulum is cut off, and the wound in the esophagus closed with two layers of sutures. If the neck of the sac is small, it may be ligated, the stump cauterized and sewed over. In the case of a larger sac, some of the sac must be left to close the gap. If the wound cannot be closed it may be packed and drained. The patient should be fed by the stomach fistula until the wound is healed.

Invagination into the esophagus of small diverticula has been successfully practised. It is not as satisfactory as excision.

Diverticula which are too low to be reached by operation in the neck and which are not amenable to other treatment must be attacked through the mediastinum (see page 459).

Fistula.—Fistulæ of the esophagus, following wounds, operations, abscess, or ulceration require that any causative disease shall first be attacked. Stricture in the region of the fistula should be cured. A recent fistula, not yet lined with epithelium, may be treated simply by feeding through the stomach tube to give the esophagus rest. An older fistula, lined with epithelium, requires removal of the epithelial lining after the normal state of the inside of the esophagus itself has been assured. A systematic dissection of the fistula should be made, just as though it were a cyst. No epithelium should be left. The dissection should be carried down to the esophagus, the esophageal opening closed with sutures, and the outer wound drained. Gastrostomy is rarely necessary (see Esophagotomy, page 442; and Fistula, Vol. I, page 304).

Foreign Bodies in the Esophagus.—Foreign bodies of all kinds taken through the mouth become lodged in the esophagus. They may be caught by a stricture or at the naturally narrow places. Usually they are caught at the inferior constrictor of the pharynx, just above the bronchus, and at the diaphragm. Although smooth bodies may remain for a long time, their removal as soon as possible is always desirable because of the danger of ulceration and infection. Sharp and irregular bodies demand much more urgently an early removal because of the additional danger of perforation. Attempts at removal should not be made until the surgeon is satisfied that



Fig. 1114.—Flexible Esophageal Forceps.

a foreign body is present. The patient's sensations are no guide. . Careful history, *x*-ray examination, esophagoscopy, palpation, gentle probing, and the clinical signs should be the surgeon's reliance. Esophagoscopy is the most reliable means for both diagnosis and treatment.

Bodies lodged at the beginning of the esophagus may be dislodged by the finger passed back through the mouth. They may be caught by flexible forceps (Fig. 1114), curved forceps (Fig. 1115), or by the bristle probang (Fig. 1116). Great pressure on the larynx may demand tracheotomy for relief. Bodies above the bronchus should be brought out through the mouth



Fig. 1115.—Curved Esophageal Forceps.

if possible; bodies below the bronchus may be allowed to enter the stomach, although in all cases it is best to fetch up the foreign body.

Fish bones, pins and other small-pointed things should be handled with much gentleness, lest they penetrate and be driven into the great vessels. It is such objects especially that require the esophagoscope. Usually they will be found penetrating horizontally or with the point directed downward. The introduction of an instrument is dangerous unless it passes only to the object or past it.

Angular and irregular bodies may cause tearing of the tissues if not care-

fully handled. Much force should never be used. They may sometimes be rolled upward by taking hold of one side. Often such bodies may be divided by the electrocautery.

Rounded objects such as coins are most easily handled. In the absence of the esophagoscope, they may be removed with other instruments. In the case of a child with an oval locket for ten days engaged at the bronchus, I placed her supine on the *x*-ray table with the light behind her thorax. Under general anesthesia, flexible forceps were passed down the esophagus, and with the fluoroscope I could clearly see the locket approached by the forceps and grasped by the opened jaws. The bristle probang and the coin catcher are effective instruments for these cases.

Soft materials, such as pieces of meat, may sometimes be caused to contract by pouring equal parts of alcohol and water against them. This may be done through a catheter. Or they may be dissolved by means of pepsin and diluted hydrochloric acid.

When edema of the mucous membrane is present from the local irritation it may be treated with adrenalin.

Foreign bodies caught at a stricture should be removed upward and the stricture treated. It may happen that a body has passed through one



Fig. 1116.—Bristle Probang.

stricture and is caught by a stricture below, being inaccessible to the esophagoscope. In such an event the strictures should be dilated to give access.

Rarely is it justifiable to induce vomiting to remove a foreign body as great damage to the esophagus may be done. The gagging caused by introducing the finger into the pharynx often dislodges the object. The method which should take precedence of all others is with the esophagoscope. Mucus should be aspirated or sponged away. If the body cannot be drawn into the tube, it may be grasped and withdrawn with the tube. Whatever method is employed, very commonly the peristalsis which the instrument excites dislodges the body and causes it to pass downward.

Bodies which have become lodged in the esophagus and cannot be moved whole, may be cut in two and thus removed. This operation is best done through the esophagoscope. Thus, a metal pin may be filed; a body of hard rubber, such as a denture, may be burned by the electrocautery; or a softer body may be cut by the rongeur forceps which are used with this instrument.

Operation is indicated when efforts at removal through the natural passages fail, when severe injury has been done to the esophagus, when the pressure upon surrounding important organs by a sharp object is so great as to render manipulation dangerous, and when bleeding obscures the esophagoscopic view. When the body is above the bronchus, cervical esophagotomy is done (page 442). The opening is made on the left side unless the body projects more prominently elsewhere or cellulitis is present on the right side. The opening of the esophagus in the neck gives better access to

the body no matter where it is; if necessary it may be cut with bone forceps or divided by some other means. Curved forceps are used for the extraction.

When the body is below the bronchus, esophagotomy still improves the access to it. By dividing the sternal attachment of the sternomastoid muscle more room is secured. This makes the esophagus easily accessible as far as the bronchus. There is still a distance of 8 or 10 cm. (3 or 4 inches) between the bronchus and the diaphragm. A body may be reached from above, but the constriction caused by the bronchus makes it very difficult.

Better success with the low-lying bodies has been secured through gastrotomy. There are several methods of procedure. (1) The stomach may be drawn out, walled off, incised and the whole hand entered into it. The index-finger is then passed into the esophagus, and the body dislodged and pulled down. (2) An incision 2 cm. long is made down to the mucosa, a purse-string suture is passed around the edges, the mucosa is incised, the index-finger admitted, and the suture tied down upon it. The stomach wall is then invaginated, and the finger passed into the esophagus. (3) A small opening is made in the stomach, the abdomen well walled off, and an instrument passed into the esophagus to grasp the foreign body. (4) A filiform bougie or thin probe is passed from above downward past the obstruction. This carries a thread to which a sponge is attached. The thread is brought out through the stomach opening, and by drawing down the sponge the body may be brought with it. In this operation, a thread controlling the sponge from above should be used in order to draw it back should the operation fail. Other expedients to fit the individual case will occur to the resourceful surgeon. As a last step to be considered is posterior mediastinotomy (page 459).

Esophagismus.—Spasm of the esophagus demands treatment of the cause. Fissure, ulcer, stricture, tumor or contracting scar may be the causative factor to be treated. Constitutional disease, such as hysteria, epilepsy, chorea, and diseases with increased excitability of the cord, should be discovered and treated. Reflex irritation from other parts of the body require correction. In cases in which no cause can be found or removed the spasm may be allayed by rest, simple diet, sedative drugs, and cocain or orthoform locally. Rectal feeding may be required. Dilating sounds are often of help. Gastrostomy should rarely be necessary.

External cervical esophagotomy is done for the removal of foreign bodies which cannot be removed through the mouth. It may be done for tumor or for stricture. For purposes of feeding, gastrostomy is much to be preferred. Esophageal bougies, a stomach tube, bristle probang, esophageal forceps, tracheotomy tube and intubation set should be at hand. The patient lies on the back, the shoulders should be raised and the head dropped back in order to make the front of the neck prominent. If there is no other determining element the incision is best made on the left side; the face should be rotated to the right.

An incision 7.5 or 10 cm. (3 or 4 inches) long is made along the anterior border of the sternomastoid muscle from the upper border of the thyroid cartilage. It should be carried as far toward the clavicle as is necessary. The communicating veins are doubly ligated and cut between. The sternomastoid is exposed and retracted outward; the sternohyoid and sternothyroid are retracted inward; and the omohyoid is retracted outward or divided. The thyroid fascia is exposed. It forms the capsule of the thyroid gland, and thence covers the great vessels. This should be divided, and the thyroid gland with the larynx and trachea retracted inward and forward. The sheath

enclosing the great vessels and pneumogastric nerve should be retracted outward. The inferior thyroid artery will be seen emerging from behind the common carotid and coursing inward and upward in front of the longus colli muscle. It should be ligated in two places and cut between. The superior thyroid vein may also require to be tied and divided. Retraction of the trachea exposes the esophagus, which appears as a red flat tube. The recurrent laryngeal nerve lies in the angle between the esophagus and trachea. It should be spared both wounding and traumatism.

The esophagus may be made to appear more prominently in the wound by passing a bougie into it from the mouth. It may be incised longitudinally through its lateral wall. By catching the lips of the wound with forceps or a silk thread it may be held widely open and the interior of the esophagus exposed for surgical attack (Fig. 1117). After a clean operation, the

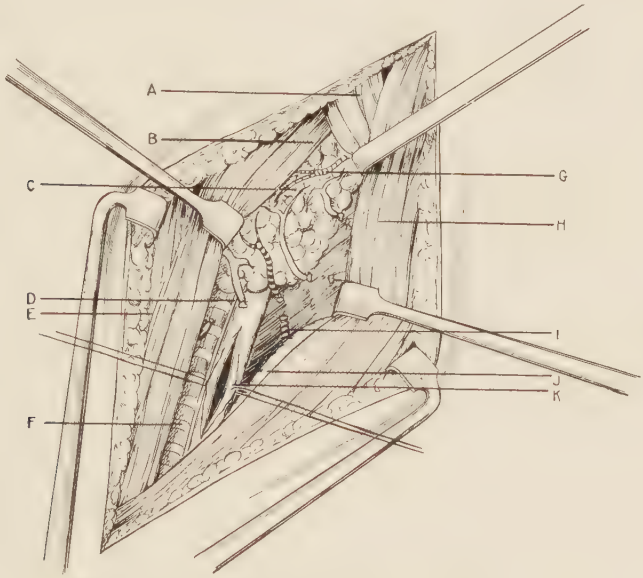

Fig. 1117.—External Cervical Esophagotomy.

A, Omohyoid muscle; *B*, sternohyoid muscle; *C*, thyroid gland; *D*, recurrent laryngeal nerve; *E*, sternothyroid muscle; *F*, trachea; *G*, superior thyroid artery; *H*, sternomastoid muscle; *I*, inferior thyroid artery; *J*, common carotid artery; *K*, esophagus incised and lips of wound retracted with fine sutures.

esophagus is closed by two or three rows of sutures, and the outer wound partly closed and lightly packed with gauze to induce granulation. The patient should be fed by the rectum for about four or five days and for two or three days longer by stomach tube. The packing should be renewed daily.

For purposes of feeding, because of disease above the opening, or for local treatment, the wound in the esophagus may be left open. The operation then becomes an esophagostomy. The edges of the esophageal wound are sewed to the skin, the deep fascia or muscle. Through this opening a tube may be passed and food introduced. When it is desired to close the wound, the esophagus may be dissected free and the opening sutured.

Partial cervical esophagectomy is undertaken for cancer and incurable stricture. The exposure is made as for esophagotomy, excepting that the sternomastoid muscle is detached from the sternum. The esophagus is

dissected free from its attachments as far as necessary or possible. The recurrent laryngeal nerves are most apt to be injured and pains should be taken to leave them attached to the trachea (see Relations of Esophagus, page 430). The isolation being completed, the esophagus is divided above and below the disease. If possible the two ends may be brought together and sewed by an internal mucous membrane suture and an external suture. If the ends are further apart than 4 cm. they can not be approximated and the upper end should be closed to form a pharyngeal cul-de-sac by a mucous membrane suture and an external suture. The lower end should be brought into the wound and sutured. Through this opening the patient is fed by means of a tube. Rectal feeding should be practised for the first few days after the operation.

The mortality in this operation is high. Its only justification is cancer of not more than 3 cm. in extent. The best results have been secured in benign strictures, but in these the mortality (25 per cent. at least) is still too high to make it preferable to other methods. If the stricture can not be cured except by excision, gastrostomy is to be preferred. W. A. Lane (British Med. Jour., Jan. 7, 1911) reported a case of resection for carcinoma involving the upper 5 cm. (2 inches) of the esophagus, in which he replaced the removed segment by a skin-flap, cut transversely from the neck and left attached sufficiently to give it blood-supply. This completely filled the gap, and later it was freed from its pedicle.

The Mediastina

Infections of the mediastinum commonly are the extensions of infections of the neck. For this reason cellulitis of the deep tissues of the neck should be cured before it can spread downward. Cellulitis of the mediastinum should be treated by energetic constitutional measures. Usually the disease involves the anterior portion of the upper mediastinum. *Abscess* should be treated by evacuation. Cervical mediastinotomy will sometimes reach the abscess. Usually it is too low for this and the great vessels shut it off from above. When it is causing pressure or its presence is strongly suspected, the sternum should be trephined in front of the abscess, and careful blunt dissection made. The aspirating needle should not be used. Drainage should be provided. In some cases the abscess points between the ribs at the edge of the sternum. Wherever it appears it should be opened, and if necessary the sternum trephined or cartilage resected to give drainage at its lowest part.

Access to the posterior mediastinum is secured by a vertical incision exposing two or three costovertebral articulations. The transverse processes and the ends of the ribs are excised, and the mediastinum entered (see Posterior Mediastinotomy, page 459).

Tumors of the Thorax.—*Tumors of the chest wall* should be treated according to the principles already laid down (see Tumors, Vol. I, page 323). Tumors of the thoracic viscera are approached by the methods described below for opening the thorax and exposing its parts. The important structures of the chest are so closely associated anatomically and physiologically, that a thorough familiarity with all of them should be possessed by the surgeon before attacking any one. If necessary, the chest wall should be resected. It is possible in some cases to remove ribs and intercostal structures and leave the pleura unwounded. Tumors of the ribs and sternum, growing into the thoracic cavity, should be removed early. Chondromata of the bones

should be widely removed as though malignant because of the tendency to recurrence. Resection of the sternum for sarcoma should be performed with provisions in readiness to do inflation of the lungs by negative or positive pressure. This is necessary because of the possibility of opening the pleural sacs. Sarcoma of ribs is more easily removed. Carcinoma invading the chest wall as a secondary deposit or by extension, especially from the breast, is a well-nigh hopeless condition, because it is usually associated with invasion of the deep lymphatics. Attempts at removal of the disease are justified if the growth does not clearly involve the chest contents.

Tumors may be removed and a flap of soft parts laid directly back upon the lung. Friedrich removed 160 square centimeters of the right side of the diaphragm in extirpating a sarcoma of the thorax and secured satisfactory healing.

Tumors of the pleura usually belong to the endotheliomata and sarcomata, if primary. The tumors have been recognized so late and come to operation when so extensive that little success has been met by their treatment. Secondary sarcoma and carcinoma or extensions from other tissues offer a bad prognosis. Attempts at removal may be made.

Tumors of the lung which require surgical attention are usually cysts and malignant neoplasms. Benign tumors rarely require operation. **Echinococcus cysts** of the lung are not uncommon, and unless recognized and properly treated, the possibilities of death from rupture into a bronchus or from sepsis are serious. Polycythemia is a helpful sign. Aspiration of the cyst is objectionable because of the danger of infecting the pleura and the improbability of such a procedure curing the disease. Aspiration raises the mortality. The best treatment of large cysts consists in exposing the tumor by rib resection, protecting the pleura and the rest of wound by gauze pads, evacuating the cyst contents, if possible peeling out its lining, stitching the edge of the sac to the chest wound, and packing the cavity for drainage. In smaller cysts the tumor may be exposed by pneumotomy, and dissected out without rupturing it. This is the ideal treatment (see Cystomata, Vol. I, page 325).

Malignant tumors of the lung have not been recognized early enough to be removed. If early diagnosis can be made pneumectomy may embrace the disease.

Tumors of the pericardium are similar to those of the pleura. Early removal offers relief.

Tumors of the esophagus amenable to operation are benign and malignant. Benign tumors within the lumen of the gullet are often pedunculated and accessible through the esophagoscope. Polyps may be removed with the snare. Polyps near the pharynx have been caused to be vomited into the pharynx, grasped with forceps and the pedicle cut with a snare. If the growth cannot be reached through the mouth, external esophagotomy is indicated if a benign tumor is causing serious dysphagia and inanition. When a tumor causes great pressure upon the larynx or upper trachea, tracheotomy may be necessary. If removal of the growth is not to be attempted for dysphagia and inanition, gastrostomy is called for.

Operations for the removal of malignant tumors of the esophagus should be undertaken early or not at all. At the best the prognosis is unfavorable. Earlier diagnosis and improved technic are lowering the mortality in this class of diseases. Carcinoma is a common disease of the esophagus, and should be looked for at once in suspicious cases, developing often at the seat of some old inflammatory irritation. The lower segment of the gullet

is usually attacked. When found in the cervical segment, cervical esophagectomy (page 442) may be done. To remove the disease from the thoracic segment requires operation through the chest (see below).

The palliative treatment, if curative operation is not to be done, consists in keeping the patient comfortable and providing nourishment (see Palliative Treatment of Cancer, Vol. I, page 331). If the patient can still take food it should be largely fluid and semifluid. Peptonized milk, scraped beef, gruels, jellies, etc. Mucus and septic material from the esophagus may be washed out of the stomach once or twice a day to the relief of the patient. Gastrostomy is indicated when dysphagia is causing inanition. This should not be confused with the cachexia of the disease.

The treatment by sounds usually precedes gastrostomy. By dilating the constriction the patient may take nourishment throughout the whole course of the disease. Conical rubber bougies are used. The dilatation may be done every day or two, depending on the condition. The local application of methylene blue helps to keep the diseased surface clean. Curettage of the occluding tumor is feasible. Radium has much to offer. The radium treatment is applied directly to the inside of the esophagus. As to the choice between gastrostomy and keeping the passage open with bougies, in most cases the patient will live longer and be more comfortable with the latter treatment. In some cases a rubber tube having a funnel at its upper end, controlled by a string brought out through the mouth may be left in for several days, the funnel resting upon the stricture (see Resection of Thoracic Esophagus, pages 459 and 463). Perforation of the great vessels, perforation of the trachea and extension of the disease to the pleura are to be anticipated.

Tumors of the mediastinum, if malignant, should be removed if a sufficiently early diagnosis has been made. The benign tumors should be removed if pressure causes serious disturbance of the vital organs. The operations are anterior or posterior mediastinotomy (see below).

Intrathoracic goiter requires treatment to relieve the symptoms of pressure and suffocation. Removal of the goiter is necessary when it continues to cause increasing symptoms. The operation may best be done under local anesthesia. These tumors can be removed without dividing the bone (see Thyroid, page 380).

Hypertrophy of thymus gland is a similar condition requiring operative removal (see Thymus, page 394).

Operations through the Mediastina and Pleuræ Which Have Not Been Described Above and Which Are Preferably Done under Positive Intrapulmonary Pressure or Extrapulmonary Rarefaction of the Air.—The collapse of the lung during operation is a serious accident if the other lung is ineffective for any reason. The collapse of both lungs is apt to be a fatal accident. To overcome the disadvantages of throwing the lungs out of use, two distinct plans have been devised: (1) One consists in forcing air in through the trachea to expand the lung; (2) the other consists in lowering the atmospheric pressure upon the surface of the exposed lung. Many combinations of these two principles have been tried.

Increased intrapulmonary pressure (insufflation of the lungs) was worked out by S. J. Meltzer. A rubber catheter is passed through the larynx down as far as the bifurcation, and through this air is pumped to give an intratracheal pressure sufficient to overcome the elastic contraction of the lungs and keep the lungs distended. The escaping air passes out alongside of the catheter, and respiratory motions are no longer necessary because air is

artificially brought into the lungs. The catheter should be much smaller than the lumen of the trachea. For the adult a No. 22 or 24 French soft-rubber or flexible silk woven catheter is used. The air space in the trachea outside of the catheter should be as great as the caliber of the catheter. Through this catheter air enters the lungs and thus they are kept dilated and supplied with a current of air which performs both the function of inspiration and expiration. With this apparatus a person whose respiratory muscles are paralyzed may be kept alive. Air may be admitted to both pleural sacs and still the lungs kept dilated. The dangers of pneumonia are greatly reduced. Inhalation of foreign substances does not take place. The trachea is kept cleared because the current is always upward.

The *apparatus* for insufflation may be of a simple type connected with a foot bellows. For this purpose a glass-blowers' bellows is used. Meltzer (Keen's Surgery, Vol. VI, page 972) described a system of connecting tubes which fulfil all requirements. The air is pumped through a bottle containing ether. Safety valves protect the patient from accident. A manometer

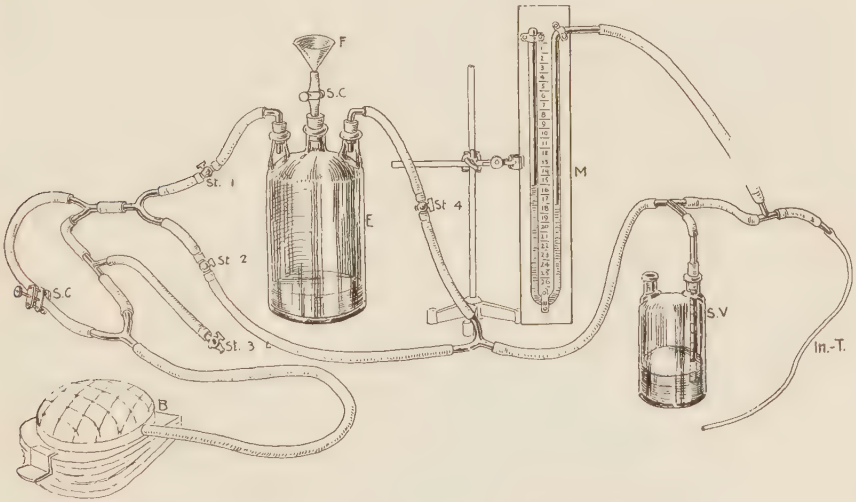

FIG. 1118.—APPARATUS FOR ANESTHESIA BY INTRATRACHEAL INSUFFLATION OF S. J. MELTZER. (*Keen.*)

shows the amount of air pressure in the lungs. By adding a bottle of mercury a tube may be submerged to the depth to which it is desired to limit the pressure. This should not be more than 20 mm. (Fig. 1118).

With the bellows the air is driven through the system of tubes. The tube has a bypass provided with a stopcock (St 3) which may be used for the release of the air at will. When this cock is opened to release air part of the air pumped in may be allowed to circulate through the other arm of the tube. The amount of air passing through the left tube may be regulated by the screw clamp (S.C.). The next branching of the tubes is to control the anesthetic. The ether bottle (E) is introduced in the course of the current, and is bypassed with a tube having a stopcock (St 2). A stopcock (St 1) also controls the air current going to the ether bottle. The air may pass through the ether bottle or around depending upon the opening and closing of these cocks. The air then passes to the tracheal tube (T.T.). Between the ether bottle and the patient the tube is connected to a manometer (M) to show the air pressure in the lungs, and to a bottle of mercury with a blow-off opening (S.V.) which serves as a safety valve. A graduated glass tube is submerged in the mercury to the depth of the maximum mercurial pressure to be allowed. The ether bottle may rest in a warmed chamber or warm water bath (see Warmed Anesthetics, Vol. I, page 130).

The apparatus of C. A. Elsberg (Annals of Surg., February, 1911, vol. 53) is provided with an electric pump as well as a foot bellows (Fig. 1119). It is contained in a box which may be conveniently transported. It is compact and dependable. A one-sixth horsepower electric motor drives the blower (Fig. 1120).



Fig. 1119.—Elsberg's Apparatus for Insufflation of the Lungs.

The rotary electric pump (X) forces air first through the air receiver and oil separator (Z) which removes the oil from the air as it comes from the pump. The air is warmed and moistened by passing through a tank of warm water at G.

An ether regulating valve (R) is designed to shunt the air stream in varying proportions through the ether chamber (M). When the index is over the word "air" on the

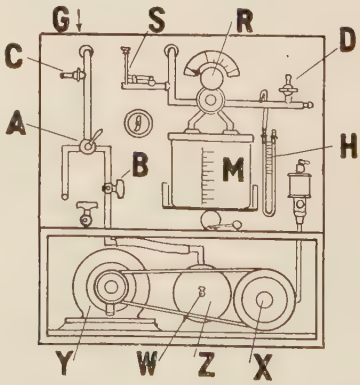

Fig. 1120.—Diagram of Elsberg's Insufflation Apparatus.

scale the ether is completely shut off and the apparatus is delivering pure air. For example, at 50 half of the air is saturated with the anesthetic and at 100 the entire air stream is becoming saturated. The intratracheal tube is connected to the apparatus, by a length of rubber tubing, after it has been introduced the proper distance into the trachea. If the catheter is too small the return current is so rapid that the anesthetic is not absorbed properly, consequently the anesthesia is too light. If the catheter is too large it offers too

much obstruction to the return current, causing the intratracheal pressure to become too high, approaching that registered by the manometer. When the catheter has been properly introduced, the specially designed clamp is slipped over it to hold it in place and prevent its displacement should the patient cough. It also has projections to prevent its being closed at any time by the patient biting on it.

A manometer (H) reads in millimeters of mercury, indicating the pressure at which the apparatus is delivering the etherized air; the intratracheal pressure is usually one-fourth of this amount. An average safe pressure for ordinary use is 20 mm. (manometer reading), it may, however, be necessary to increase the pressure to 30 mm. Pressure much higher than

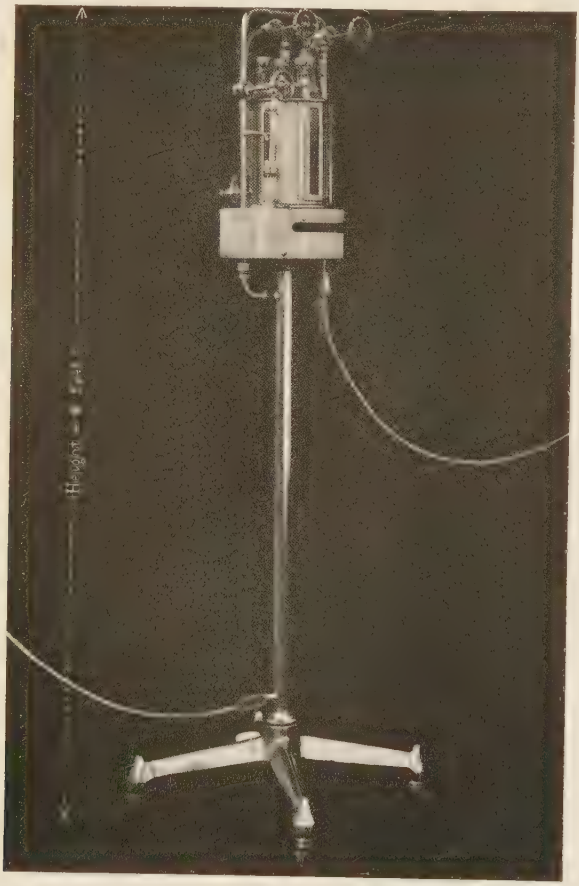

Fig. 1121.—Intratracheal Insufflation Apparatus of Robinson.
The apparatus is supported on a shaft through which the electric wire is conducted. The tube for conducting air and anesthetic vapor to the patient passes off at the right.

this is dangerous. To prevent all danger of rupturing the lung a safety valve (S) is provided, which if properly adjusted prevents accidents due to excessive pressure. The safety valve may be adjusted to blow off slightly in excess of the pressure to be used. The pressure in the entire apparatus is regulated by the stopcock (B) which exhausts the excess.

To cause momentary interruption in the air stream and allow the lungs to partially deflate, the stopcock (D) may be opened and closed; this should be done a number of times a minute. When (D) is opened the pressure falls but is instantly brought back to the original pressure upon closing it. To make the apparatus absolutely safe, the foot bellows should always be connected for immediate use should the electric power fail for

any reason; then by simply throwing over the lever of the valve (A) the operation may proceed without interruption.

If it is desired to use oxygen or nitrous oxid in connection with the apparatus, connection to the cylinder of compressed gas may be made through the stopcock (C) attached for that purpose.

The apparatus of S. Robinson (Surg., Gyn. and Obst., December, 1915) is provided with a supporting shaft upon which it stands (Figs. 1121 and 1122). It is constructed of metal and glass and is compact and effective.



Fig. 1122.—Insufflation Apparatus of Robinson, Showing Details.

With the apparatus of Elsberg or Robinson, the percentage of ether is regulated as the patient requires. Usually the indicator has to be turned until it shows that half or full ether vapor is being used.

The patient is first etherized in the usual manner, placed on the operating table, the head extended on the neck, and the intratracheal tube inserted. This may be done best under the guidance of the eye with the direct laryngoscope. The tip of the catheter should lie about 5 cm. (2 inches) above the bifurcation.

With skill and experience the tube may best be inserted without the aid

of direct vision. A stilet serves to give the necessary curve and act as a guide (Fig. 1123). The tongue of the anesthetized patient is drawn forward with forceps. The mouth gag should give wide exposure. The surgeon lifts the epiglottis with his left forefinger, and passes the tube exactly in the median line over the finger into the larynx. The tube will be stopped by the vocal cords unless the patient is deeply anesthetized. Force should not be used. As the tube slips between the vocal cords respiratory air can be felt issuing from the free end as the stilet is withdrawn. The tube should then be passed downward to the bifurcation and then withdrawn 5 cm. (2 inches).

The catheter should have an opening at or near the end and be at least 30 cm. (12 inches) long. It should have a mark 12 cm. (4¾ inches) from the tip and another 26 cm. (10¼ inches) from the tip. The adult trachea is 12 to 13 cm. (4¾ to 5 inches) long, and the larynx 5 cm. (2 inches). The

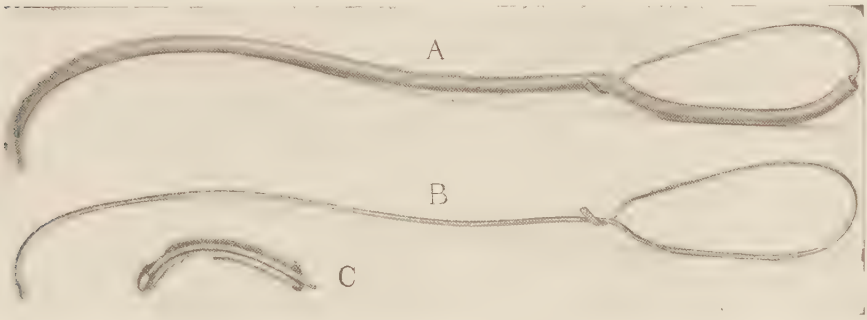

Fig. 1123.—Intratracheal Tube.

This is a modified urethral catheter (*A*). A steel stilet with a bulbous end (*B*) is inserted to guide the catheter. The end of the tube, containing the stilet, is shown in (*C*). This is the tube apparatus devised by S. Robinson.

distance from the incisor teeth to the glottis is 14 cm. (5½ inches). If the tip of the intratracheal tube is 26 cm. from the incisor teeth, it will lie 5 cm. above the bifurcation of the trachea.

The tube is held in place with a special mouth gag. When the pressure is raised to 30 or 40 mm. breathing movements seem to cease, but the patient's color remains good and the action of the heart is not disturbed. If the tube is too close to the bifurcation it causes coughing; if it is too high cyanosis will be observed. The patient's color should be good throughout the operation.

This method is not only applicable for thoracic operations but for general anesthesia in all classes of cases. Post-operative vomiting and the danger of pneumonia seem to be reduced. As a method of anesthesia intratracheal insufflation is now well established.

These devices for insufflation of the lungs have superseded the negative pressure cabinets which served a most useful purpose in the development of thoracic surgery. S. Robinson, for example, who devised an effective differential pressure cabinet, has given it up, as he finds that the work can be done with the intratracheal insufflation apparatus.

The *pneumatic cabinet for securing negative* and *positive atmospheric pressure* in thoracic surgery was perfected by W. Meyer, who improved upon the methods of Sauerbruch and Brauer. Meyer's apparatus consists of an outer negative pressure chamber within which is a positive pressure

chamber. The former is used as the operating room, while the patient's head is in the latter which is the anesthetic room (Fig. 1124). By means of these air-tight chambers it is possible to operate under either negative differential pressure or under positive differential pressure, or a combination of the two. A rubber collar with a guillotine shutter encompasses the patient's neck. The air pressure is regulated by pumps. The chambers are large enough to accommodate operator and assistants.

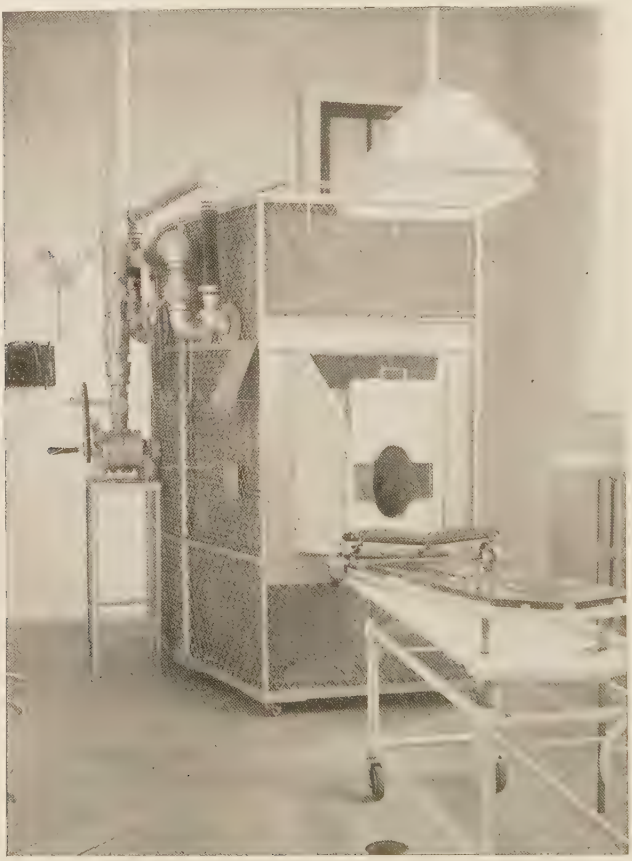

Fig. 1124.—Meyer's Positive Differential Pressure Cabinet used in Operations on the Thorax. (*Keen.*)

By the use of the "universal pressure chamber" of Meyer the patient's pleural cavity may be placed under negative or under positive pressure in the same place and position. This is accomplished by placing the positive pressure cabinet within the negative pressure chamber.

The differential pressures required in thoracic surgery does not often need to be more than 7 or 8 mm. of mercury. This is not so great a deviation from the normal as to cause discomfort to the operator. It is equivalent to an elevation in altitude of 250 to 300 feet. The positive pressure to which the anesthetist is subjected is so slight as to be scarcely noticeable.

OPERATIONS ON THE LUNGS

For Diseases of the Lungs see page 413. The lung may be cut with knife or scissors, but if a large wound is to be made multiple ligatures should have been tied on either side to prevent bleeding. Indurated areas may be incised with less bleeding. Blunt dissection or tearing may be practised for short distances. A bloodless incision may be made by means of the red hot cautery knife. When a lung is incised deeply enough to open large bronchi, the patient should not lie with the sound side down because of the danger of blood running into the sound lung. Cavities are opened by enlarging a narrow incision or puncture by blunt dilatation.

The patient may be placed on the ordinary operating table and the position controlled by sand-bags, or the special table of Friedrich may be used

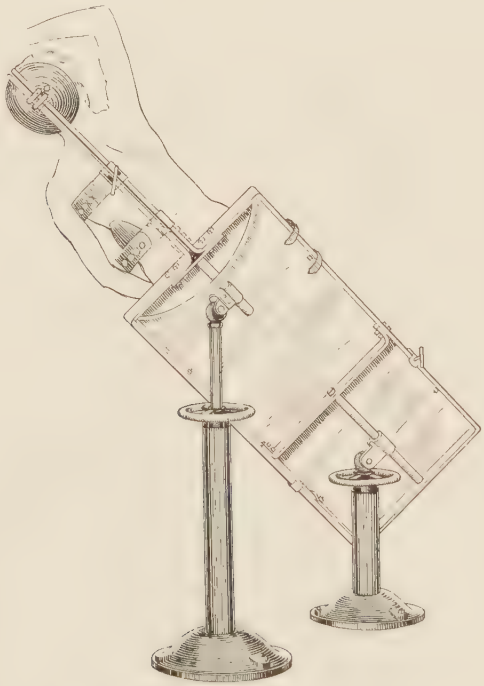

Fig. 1125.—Special Table for Operations on the Thorax

(Fig. 1125). A necessary instrument for thoracic surgery is the rib spreader or retractor which permits wide access with a minimum of assistance and external wound (Fig. 1126).

Exposure of the lungs for pneumotomy, pneumectomy or other operation, may be made by a simple rib resection, as described for empyema, by resecting two ribs through an incision placed between them, or by making a thoracic flap (Fig. 1127). Such a flap may retain the divided rib segments, or they may be sacrificed and the flap consist only of soft tissue (see also Thoracoplasty, page 410). In making these thoracic flaps consideration should be given to the source of blood-supply in order to insure the best nourishment. Lines of incision running parallel with the ribs are to be preferred (Fig. 1128) The division of the ribs in a flap having its base at one intercostal space

should be made a short distance (1 cm.) to one or the other sides of the incision in the skin (Figs. 1129 and 1130).

If a flap of soft parts is turned back it should include everything external to the ribs and external intercostal fascia. The ribs are then divided at the outer edge of the wound, the intercostal vessels tied, and the ribs with the intercostal structures and costal pleura removed throughout the extent of the wound. This operation leaves a raw flap to be replaced against the lung over a ribless area (Fig. 1131).

If it is desired to retain the ribs and pleura in the flap the resected segments and pleura are retained in connection with the superficial soft parts. If before replacing the flap, it is desired to convert it into a boneless flap, the ribs may be removed by incision over each rib on the pleural side. Or if it is desired to secure adhesions to the lung but not collapse of the thorax, the pleura alone may be dissected off or irritated with the curet.



Fig. 1126.—Rib-spreader for Giving Wide Access to the Thorax.

The ribs may be removed, and the pleura left. This is done by turning back the flap of superficial soft tissues, and then removing each rib from its bed of periosteum. With care this can be done without opening the pleura. To expose the lung, an incision may be made through the pleura in any direction. If desired, the intercostal structures may be removed with the ribs, leaving the pleura alone or with the pleural side of the rib periosteum attached to it. When the pleura has been thickened by old empyema, it is easy to separate the ribs with their periosteum from it.

If it is desired to close off the rest of the pleural cavity on account of infection which is to be exposed in the lung, the parietal pleura may not be included in the flap; it is incised, and the lung exposed; the edges of the wound in the parietal pleura are then sewed to an elliptic surface of the lung. This line of suture may be left for a few days to become sealed before incising the lung; or, with the aid of a protective packing, the lung may be incised at once. It is possible to make this suture still tighter by making a superficial incision through the pulmonary pleura, and sewing the edge of this wound to the edge of the wound in the costal pleura.

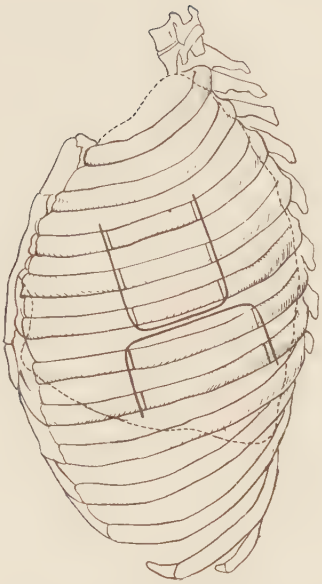

FIG. 1127.

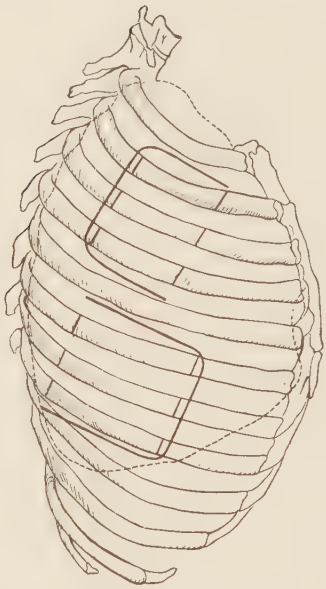

FIG. 1128.

FIG. 1127.—INCISIONS FOR EXPOSING LUNG BY VERTICAL FLAPS.
FIG. 1128.—INCISIONS FOR EXPOSING LUNG BY TRANSVERSE FLAPS.

These incisions are so placed that a better blood supply is provided for the flap than in flaps turned back at right angles to the intercostal spaces.



FIG. 1129.—LUNG EXPOSED BY OSTEOPLASTIC FLAP IN THE DIRECTION OF THE LONG AXES OF THE RIBS.

To turn back this flap, the ribs may be broken. It is better to cut with forceps the two ribs adjacent to the incision and then divide the intervening rib or ribs through a small incision at the base of the flap.

For *exposing the apex of the lung* a U-shaped flap is made having its convexity at the border of the sternum, its base at the anterior axillary line, its upper arm at the first intercostal space, and its lower arm in the third intercostal space. If an *operation in two stages* is done, the flap is placed back. If the second operation is to be carried out after an interval of more than three days, a layer of gauze may be left under the flap in order to facilitate its subsequent separation.

Pneumotomy may be performed through an incision made in the direction of the pleural incision. If drainage is required it may come out at the lower edge of the flap which is left unsutured. Incision is made not only for abscess, gangrene, and tumor, but also for *foreign bodies* in the bronchi,

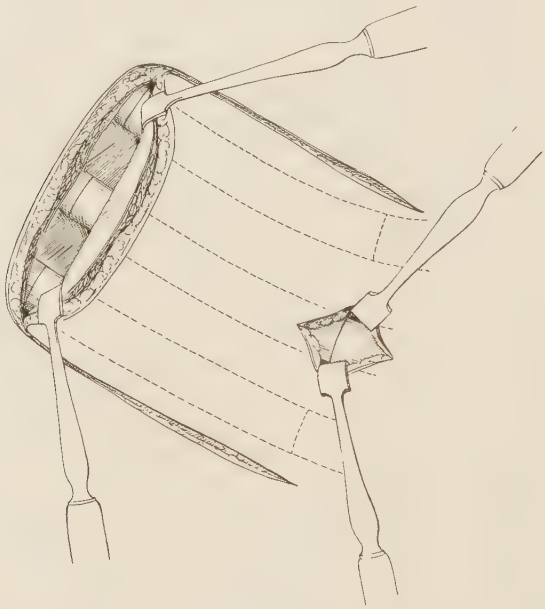

Fig. 1130.—Method of Dividing Ribs to Turn Back Flap.
The two outer ribs adjacent to sides of the flap may be cut through the flap incision; the middle rib is cut through a short special incision at the base of the flap.

which cannot be reached by the bronchoscope. In the latter operations the lung should be exposed and incised at the place nearest to the object with due regard for the important structures and pleural asepsis (Fig. 1131).

Pneumectomy is done for bronchiectasis, tumor, and rarely for tuberculous disease. There must be one sound lung, and the heart must be normal. The operation cannot safely be done on a patient past middle life. Young adults are the patients of choice. The tissue to be removed may consist of one lobe or one lobe and a part of another. The mortality of the operation is very high, and it should be undertaken only when every palliative measure has failed. The operation in stages is to be preferred. Neither differential positive nor negative pressure is necessary. The convexity of the incision is downward. It starts at the fifth rib 5 cm. from the vertebral column, crosses the eighth rib at the scapular line, and ends at the sixth rib in the mammary line. The skin-muscle flap is turned up, and the seventh, eighth, and

ninth ribs subperiosteally resected from their angles to the anterior axillary line. The flap is then replaced. This ends the first operation.

After a week or so, when the patient has quite recovered from the operation and is able to clear the bronchi of sputum, the second stage of the operation is undertaken. The sutures are removed and the skin-muscle flap again turned back. The pleura is freely retracted, and the separation of adhesions attempted. This may prove difficult. Adhesions which can not be separated must be cut. Much force must not be used. If the patient is not doing well the operation should be stopped and deferred to a later day.

For amputating the detached lobe, it is grasped with a long clamp which compresses the root of the lobe. The lobe is cut away about 1 cm. from the clamp. Veins, arteries and bronchi are separately tied with chromic catgut. A ligature carrier is then passed through the pedicle behind the clamp and the pedicle tied in two sections as the clamp is slowly released.

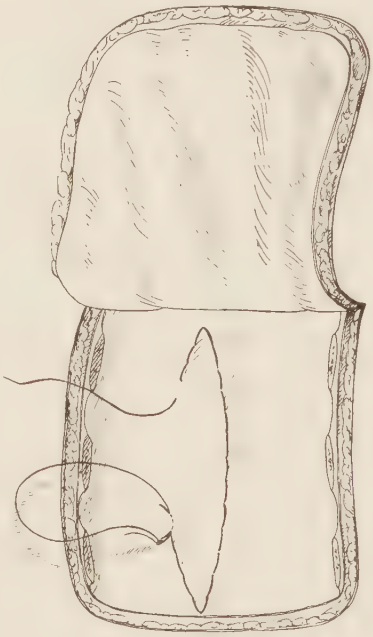

Fig. 1131.—Flap of Skin and Fascia Turned Back to Expose Lung.

The ribs and intercostal structures have been removed. The costal pleura remains, and is in process of being sutured to the pulmonary pleura for the purpose of closing off the pleural sac from infection for later incision.

Pneumectomy may be performed by an exposure secured by simply resecting or dividing the ribs. For the removal of tumors, the pleura may be left unopened, the flap turned back, and the pulmonary and parietal pleuræ sewed together by a running suture carried around the circumference of the wound. The wound is then covered lightly with gauze and the flap replaced. Adhesions are formed, and in two or three days, the lung may be incised through the two adherent pleuræ without causing pneumothorax or hemothorax. For tumor, the one-stage operation is usually done. The lung is brought out through the wound, transfixed behind the part to be removed with a needle carrying chromic catgut and tied off in two or more mass ligatures, massive clamps may be used. The excision is then made, the stump whipped over with a running suture to leave a smooth surface, and dropped back into the chest. In clean cases drainage is not used, and the chest wound is snugly closed.

When performing pneumectomy, if a large bronchus is opened, it should be ligated firmly, its mucous membrane cauterized, and the stump sutured over with adjacent tissue (see Exposure of Lungs, page 453; Diseases of the Lungs, page 413).

Pneumectomy for the removal of a lobe or of the whole lung is a serious operation, and has a mortality of about 50 per cent. There is great danger of vagus shock from irritation of the vagus at the hilus. The exposure of the lung by a chest-wall flap is not difficult or dangerous, but the manipulations at the hilus are. The closing of the bronchus so that it shall be air-tight is one of the difficult problems. This is best secured by destroying the mucous

membrane with the cautery and curet, to which may be added tincture of iodin or phenol. Crushing the bronchial cartilages with heavy clamps is advisable. The stump should then be sutured, and over the bronchus should be sewed the remains of lung tissue. If the stump of the bronchus is not effectively closed leakage of air will take place. There is the danger of pneumothorax developing from this leakage after the costal pleura has been closed. A valve-action of the leaking bronchial stump may fill the cavity with air under pressure, and give rise to a condition which requires prompt tapping of the chest to prevent death from the excessive internal pressure.

Even with the greatest care bronchial fistula may be expected to follow pneumectomy. For this reason free drainage is necessary. This is best secured by a copious packing of the cavity. By using gauze the cavity is kept well drained and no pocketing occurs. A later plastic may be done to cover any remaining fistula.

OPERATIONS ON THE MEDIASTINA

The superior mediastinum is that part of the thoracic cavity lying above the heart and between the two pleuræ. It is bounded in front by the manubrium of the sternum, and behind by the bodies of the first, second, third and fourth dorsal vertebræ. The **anterior mediastinum** is that part of the thoracic cavity between the superior mediastinum and the

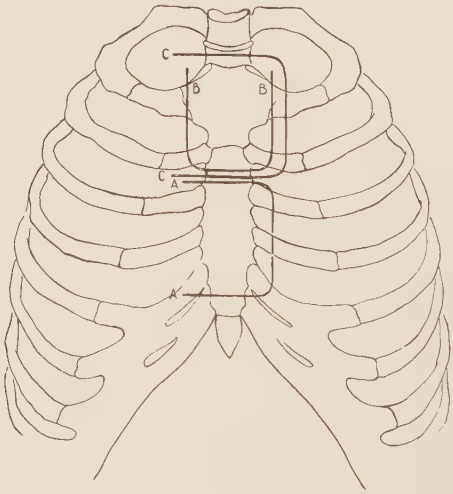

FIG. 1132.—ANTERIOR OSTEOPLASTIC THORACOTOMY, INCISIONS FOR EXPOSING THE MEDIASTINA.

A, Incision for exposure of anterior and middle mediastina; *B*, incision for turning up osteoplastic flap for exposure of superior mediastinum; *C*, incision for turning back laterally a thoracoplastic flap for exposure of superior mediastinum.

diaphragm. It is bounded laterally by the pleuræ, posteriorly by the pericardium, and anteriorly by the gladiolus of the sternum and the sternal ends of the left fourth, fifth, sixth and seventh costal cartilages. The **middle mediastinum** contains the heart, roots of the great vessels, roots of lungs, and bifurcation of trachea. It is between the anterior and posterior mediastina, and laterally is bounded by the pleuræ. The **posterior mediastinum** is bounded anteriorly by the roots of the lungs and pericardium, posteriorly by the bodies of the dorsal vertebræ from the lower border of the fourth dorsal vertebra to the diaphragm, and laterally by the pleuræ.

Anterior exposure of the mediastina is best effected by *anterior osteoplastic thoracotomy*. A flap of sternum is turned back laterally. The hori-

zontal incisions should be placed to include the part of the sternum lying in front of the region which it is desired to uncover. The attachments of two or more costal cartilages may be embraced. As a type of the operation, the following exposes the lower part of the upper mediastinum and the anterior and middle mediastina: The patient is placed supine with a pillow behind the dorsal spine to throw the chest forward. The operation should be done in the presence of appliances for positive or negative differential pressure. The surgeon stands on the left of the patient. Two transverse incisions are made across the sternum and extending not more than 1.2 cm. (2/5 inch) beyond it on either side in order not to wound the internal mammary artery. The upper is on a level with the upper margin of the second costal cartilage, the lower is on a level with the lower part of the fifth cartilage at its sternal articulation.

The two incisions go down to the bone, and their left extremities are connected by a vertical incision between the border of the sternum and the internal mammary artery (Fig. 1132). The second, third, fourth, and fifth costal cartilages are divided with bone forceps. Care should be taken not to wound the pleura or pericardium or to separate the overlying soft parts, from the sternum. The intercostal vessels are tied and the structures are divided. The left margin of the sternum is now lifted slightly forward with a hooked retractor, and the posterior surface of the bone separated from the triangularis sterni and connective tissue by means of blunt dissection. The sternum is divided in the lines of the transverse incisions. This division may be made with bone-cutting forceps or the wire saw. Whatever method is used, the instrument should be kept close to the bone. The posterior surface of the bone is then completely freed from its connections, and the flap turned back to the right side, the right costal cartilages bending or breaking. The pleuræ move in and out laterally with each respiratory movement. They may be protected with a pad and held aside by retractors. If a wider exposure is desired the transverse incisions must be longer, and the internal mammary artery must be ligated and cut.

At the close of the operation the flap is replaced, and held by strong sutures passed through the periosteal tissues. If necessary the bone may be drilled. If the perpendicular incision is made further away from the sternum, and the costal cartilages divided obliquely the flap may be prevented from falling backward when it is replaced. Drainage may be provided at either side through the lowest intercostal space exposed.

Exposure of the mediastina may be secured also by **median division of the sternum** as far as the xiphoid, and lateral retraction of its two halves. This operation gives a separation of 6 or 8 cm. (2½ or 3 inches) but is more hazardous than the flap operations. (For other operations on the anterior and middle mediastina, see Operations on the Heart, page 426.)

Transverse sternothoracotomy, advocated by Friedrich, consists in making a transverse incision across the sternum, connecting two intercostal spaces, dividing the sternum with a wire saw, and retracting the bone fragments. The incision may be carried into the interspaces as far as necessary. The internal mammary arteries may be tied; and, with proper differential pressure, the pleuræ opened. Access is secured to the great vessels by operation on a level with the second interspace.

Posterior exposure of the mediastina is best accomplished by *posterior osteoplastic thoracotomy*. This gives access to the thoracic esophagus, trachea, bronchi, thoracic duct, descending aorta, azygos veins, pneumogastric nerves and posterior mediastinal lymphatics and connective tissue (Fig. 1133). The area to be exposed must depend upon the site of the disease. This exposure is usually employed for the removal of foreign bodies in the trachea, bronchi and

esophagus, for the evacuation of abscesses, resection of esophagus, and for operations on the posterior part of the middle mediastinum. The table of Friedrich is used, or the patient is placed on the sound side with the upper shoulder carried somewhat forward and the upper arm thrown over a sand bag in such a way as to elevate and carry the shoulder outward. The position should carry the scapula as far away from the spine as possible and elevate the ribs.

Three ribs are usually resected, the center one being opposite the object of attack. The esophagus is reached best on the right side below the arch of the aorta. It is in the middle line at the fifth dorsal vertebra. The bifurcation of the trachea is usually opposite the fourth dorsal vertebra or the upper part

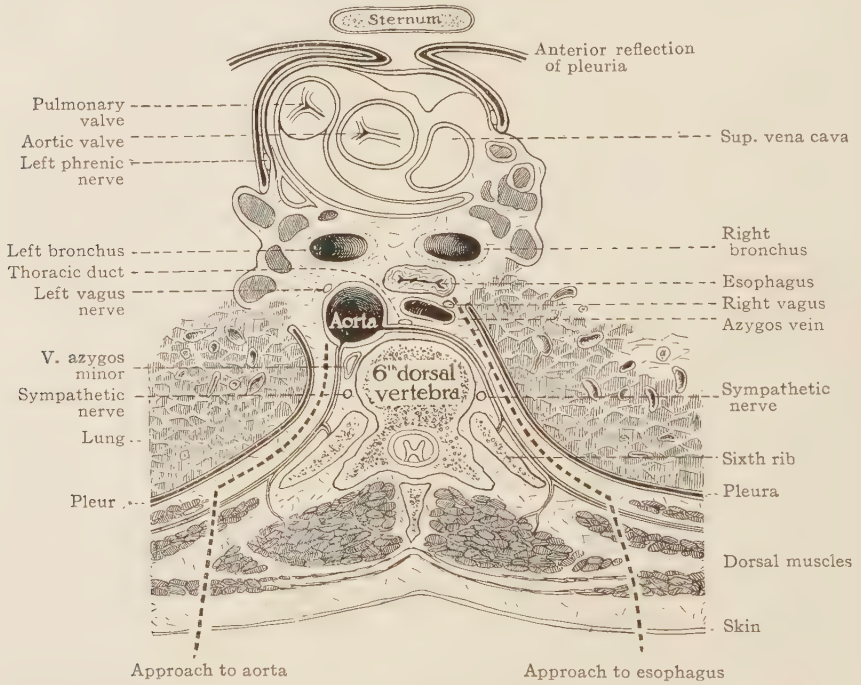

FIG. 1133.—POSTERIOR SURGICAL APPROACH TO THE ESOPHAGUS AND AORTA (POSTERIOR MEDIASTINAL THORACOTOMY).

The dotted lines show approach on right and left sides. The aorta is reached on the left side, the esophagus on the right.

of the fifth. The left bronchus is reached with much greater difficulty than the right. If the object of attack does not call for operation elsewhere, usually the fourth, fifth and sixth ribs are included in the flap. A square opening about 10 cm. (4 inches) on either side is made. Two parallel incisions are made from the spinous processes nearly to the border of the scapula. The upper one is at the interspace between the third and fourth ribs and its outer end is at the level of the inner extremity of the lower border of the spinous process of the scapula. The lower incision is at the interspace between the sixth and seventh ribs. The outer ends of these incisions are connected by a vertical incision running just internal to the scapula. These three incisions should pass down to the ribs and external intercostal fascia (Fig. 1134). The flap of superficial tissues and muscles posterior to the ribs should be dissected up and turned back, and hemostasis secured.

The fifth rib lying across the center of the field is then denuded of periosteum by an incision along its uncovered surface, divided at the extreme outer and inner sides of the wound, and the intervening segment removed. The

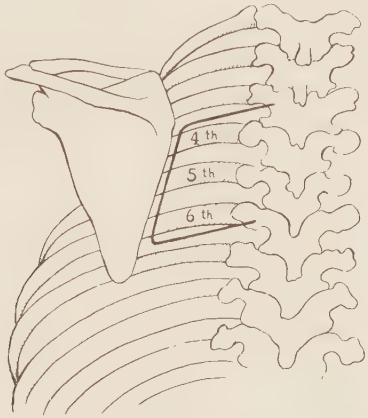

FIG. 1134.—POSTERIOR MEDIASTINAL THORACOTOMY.
Lines of incision.

FIG. 1135.—OPERATION FOR EXPOSURE OF THORACIC ESOPHAGUS.
Schede's method of raising a flap of skin and muscle, including the scapula. With the arm elevated, the scapula may be made to stand out at a right angle to the body.

ribs next above and below this are then divided at the extreme inner and outer edges of the wound but not detached from their beds. The intercostal vessels are ligated and divided. The nerves should be spared. An incision

is then carried across the middle of the wound through the periosteum in the middle of the bed of the resected rib. This incision should go as far as the pleura but should not wound it. The pleura is then separated by blunt dissection from the overlying structure. To the last incision are added two lateral incisions passing in line with the rib divisions, making an H. One flap is reflected upward, the other downward, being separated from the pleura which remains still intact. Each of the flaps contains a resected rib segment. The unopened pleura is carefully pushed outward with the finger and protected from being cut or torn. The trachea, bronchi, esophagus, or thoracic aorta, all of which can be seen and felt, are accessible. This is called *Bryant's operation.*

For the removal of foreign bodies from the trachea, bronchi or esophagus, the structure is incised longitudinally. The opening may be closed with



Fig. 1136.—Thoracic Esophagectomy.

The flap has been lifted up, and the whole length of the sixth intercostal space incised. The rib-spreader gives wide exposure. The thoracic aorta is seen lying next to the esophagus. The esophagus has been resected; the lower stump inserted, and the upper stump tied. The pneumogastric nerves are seen lying along the esophagus, their communicating branches passing from one side to the other.

chromic catgut. The great wound is closed by replacing the two rib flaps, suturing them in place, and then suturing the superficial flap over all. If infection has been caused, drainage should be brought out at one of the lower corners of the wound.

For access to the thoracic esophagus, Franz Torek (Surg., Gyn. and Obst., June, 1913) incised through the whole length of the seventh intercostal space, and carried an incision upward from the posterior end of this, cutting through the angles of the seventh, sixth, fifth and fourth ribs. After ligating some thoracic branches of the aorta, the arch of the aorta may be lifted forward, and the esophagus freely exposed. By dissecting up the esophagus, and bringing it out in front of the sternomastoid muscle, the danger of infection is avoided.

Resection of the Thoracic Esophagus.—This operation is done for cancer. Operation cannot offer hope unless the resection is wide of the disease. This means the removal of so much esophagus that anastomosis to close the gap cannot be hoped for. Therefore the steps must be (1) gastrostomy to feed the patient, (2) esophagectomy and (3) later an external plastic operation to connect the upper segment of the esophagus with the stomach.

To secure access to the esophagus, an advantageous approach is that devised by Schede. An axillary flap is turned up on the left side containing the scapula, and its attached muscles (Fig. 1135). The thorax is entered by intercostal incisions and wide separation of the ribs by means of strong retractors. Entrance may be made through the seventh, eighth or any other

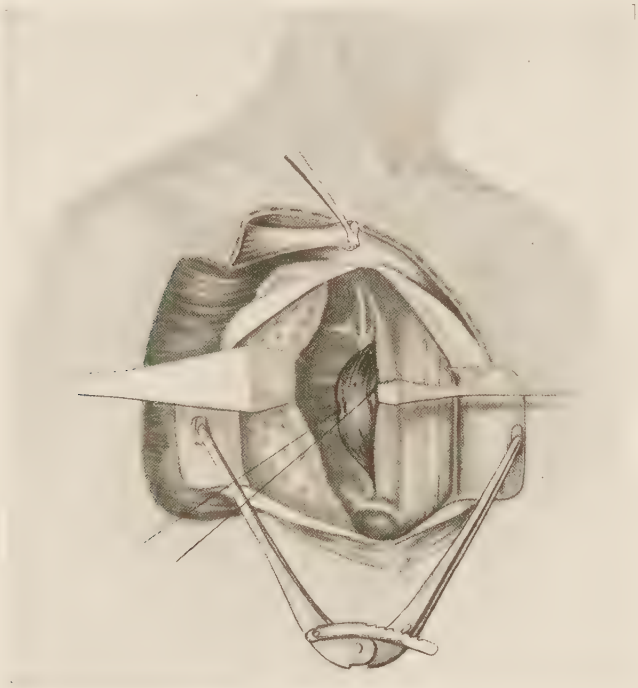

Fig. 1136*a*.—Anterior Exposure of Thoracic Esophagus, Method of Sauerbruch. A traction suture is passed around the esophagus.

intercostal space. The vagi may be discovered throughout their extent from beneath the aortic arch down to the diaphragm. The blocking of one of these nerves by cocain is necessary. They can not be handled roughly.

W. Meyer (Surg., Gyn. and Obst., December, 1912 and February, 1915) advised in cancer of the upper two-thirds of the esophagus to do the operation in two stages. Incision is to be made in the eighth left intercostal space, the esophagus divided below the growth, the ends invaginated and closed, and drainage provided. Seven or ten days later, Schede's incision is made and the chest entered through the sixth and third intercostal spaces. The pneumogastric nerves should be carefully dissected away; one should be cocainized; the esophagus should be brought out from behind the aortic arch, divided above the growth, and the upper stump invaginated and closed (Fig. 1136). The growth is then removed. Drainage should be provided;

or, if the condition of the patient will permit, the upper stump of the esophagus should be brought out in the neck.

The operation of Sauerbruch, for securing access to the esophagus in the upper part of the thorax on the right side, turns back an osteoplastic flap anteriorly (Fig. 1137). It is a more difficult and dangerous procedure than that of Schede.

Esophagoplasty.—Plastic operations for wholly or partially restoring a connection between the mouth and stomach are done after resection of the esophagus for cancer or in cases of obstruction of the esophagus. If a cancer

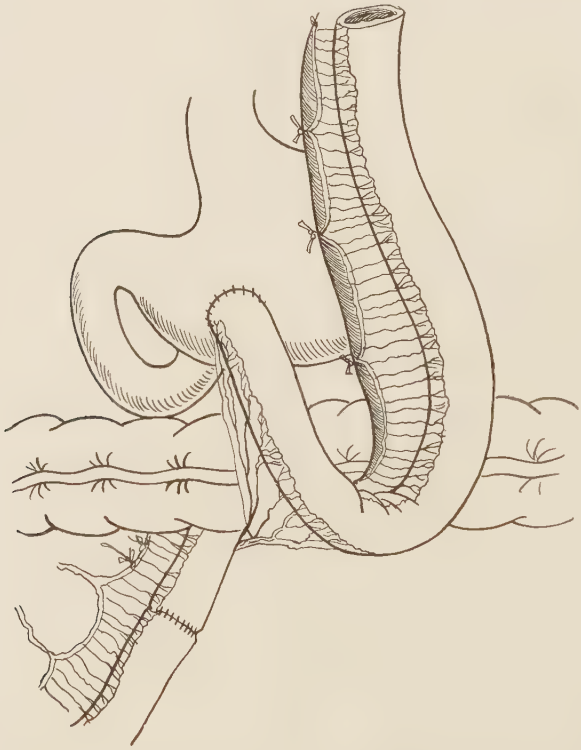

Fig. 1137.—Roux's Esophagogastrojejunostomy.

A segment of jejunum is detached and the continuity of the bowel restored by anastomosis. The distal end of the segment is implanted in the stomach, and the upper end is brought out through the abdominal wall.

of the esophagus is inoperable, simple gastrostomy should be done; but if there is hope of its removal, the preliminary operation on the stomach should plan a partial restoration of the esophagus.

Many methods for accomplishing this are available. Wallstein (Centralb. für Chir., 1904) and Roux (Sem. Med., No. 4, 1907) excluded and transplanted under the skin of the anterior chest wall a loop of jejunum. The upper end was connected with the oral stump of the esophagus, brought out in the neck, and the lower end with the gastric fistula. Roux resected a piece of jejunum; the distal end was fastened to the stomach opening, and the proximal end was brought outside of the abdomen (Fig. 1137). The skin of the anterior chest wall was tunneled and the loop of gut carried under

it was brought out at the upper end of the sternum. The operation is done in several stages. The patient may be fed by a funnel or the oral end of the esophagus may be brought out at the neck later and anastomosed with the upper end of the jejunal loop. Jejunun thus transposed is liable to necrosis especially in older persons. The transverse colon has been used for the same purpose.

A. Jianu (Deutsch. Zeitschr. f. Chir., cxviii, 1912) devised a method whereby the new esophageal tube is constructed from the greater curvature of the stomach. This is the superior operation. It has the merit that when

FIG. 1138.—RESULT AFTER PERFORMING ROUX'S ESOPHAGOJEJUNOSTOMY. The isolated segment of jejunum has been implanted under the skin of the chest. The abdominal wound yet remains to be closed.

the tube is made, one end is already connected with the stomach. A median abdominal section is done above the umbilicus. The great omentum is doubly ligated from the left inferior epiploic artery to and including the right inferior epiploic artery. The left artery is preserved. The ligations are below the gastro-epiploic artery (Fig. 1139). The cardiac end of the stomach is elevated so that the contents shall flow out. A through-and-through suture is then passed about 4 cm. (1½ inches) above the lower border of the stomach and parallel with it. Clamps are then placed on the

stomach to prevent the escape of stomach contents when the incision is made. The division of the stomach should be carried as far up toward the cardia as the entrance of the left epiploic artery will permit, as every gain possible in the length of the tube is of advantage (Fig. 1140).

The stomach wall, through both thicknesses, is divided with scissors just below the line of suture. A piece of cloth is wrapped over the cut edge of the stomach, and the free edge converted into a tube by suturing the two free edges together. This is done by continuing the first suture onto the tube. A second suture, whipping over the free edge is applied to stomach

Fig. 1139.—Gastroesophagoplasty, Method of Jianu. First Stage.
The omentum is tied and cut from the stomach. For the sake of demonstration, the wound is here shown larger than would be made for surgical purposes.

and tube (Fig. 1141). The open end of the tube is temporarily inverted with a couple of sutures. This constructs a tube from 18 to 25 cm. (7 to 10 inches) long (Fig. 1142).

The stomach is then placed so that the base of the tube lies at the upper end of the abdominal wound, where it is made fast by a few sutures and the tube brought out into the open. The rest of the abdominal wound is closed about the tube. The tube is then placed on the skin along the left of the sternum to measure its length, a horizontal cut made, and the skin undermined to receive it. The blood supply of the tube is so good that it may be pulled up on the stretch, and made to reach as high as the third or second rib. After pulling up the tube beneath the skin, by means of forceps, the mucous membrane is sutured to the edges of the upper skin wound (Fig. 1143). A

strip of gauze drain may be placed at each side of the tube in the upper wound, and if necessary in the wound below.

The tube thus constructed has a good blood supply. W. Meyer (Centralbl. für Chir., Feb. 22, 1913, No. 8) has suggested drawing up the tube into the pleural cavity through an opening in the diaphragm to connect it with the upper segment of the esophagus.

The tube tends to leak stomach contents because it has no sphincter. This must be overcome by mechanical pressure or by bringing the tube out through a split between the bundles of the left rectus muscle.

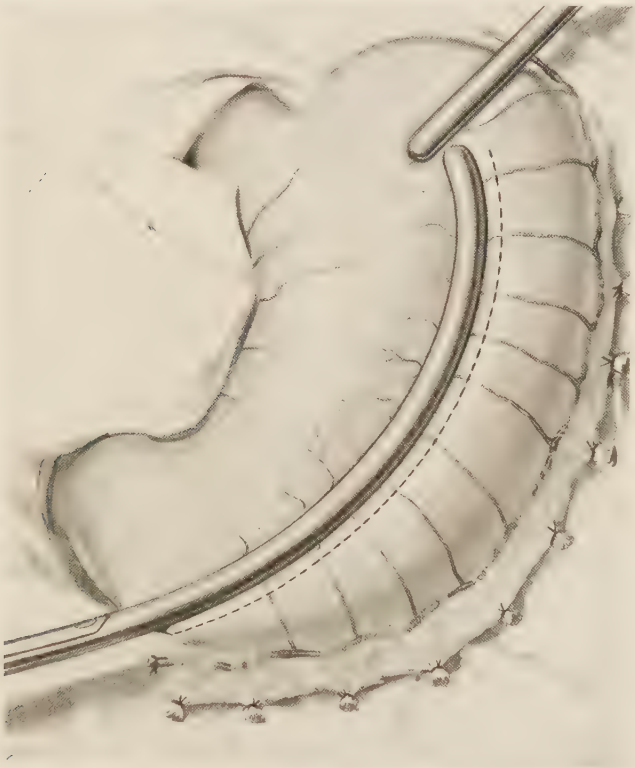

Fig. 1140.—Gastroesophagoplasty. Second Stage.
The omentum has been tied off and cut away from the stomach. The greater curvature of the stomach is to be cut free just below the curved clamp, along the dotted line.

Patients chew their food and blow it through a tube inserted into the upper opening. Later after this operation or after esophagojejunostomy, the upper segment of the esophagus may be brought out at the neck above the clavicle and connected under the skin with the tube which leads to the stomach. Or a plastic continuation of the esophagus may be made (Fig. 1144).

Thoracic exposure of the diaphragm may be made below the pleura, beyond the pleura, through the pleura, or through pleural adhesions. It is done for the evacuation of subdiaphragmatic abscess, for the closure of wounds, for the treatment of hernia, and the removal of tumors. For sub-

phrenic abscess the lateral thoracic route is to be preferred; about 7.5 or 10 cm. (3 or 4 inches) each of the ninth and tenth ribs between the anterior axillary and the scapular lines are resected through an incision placed between

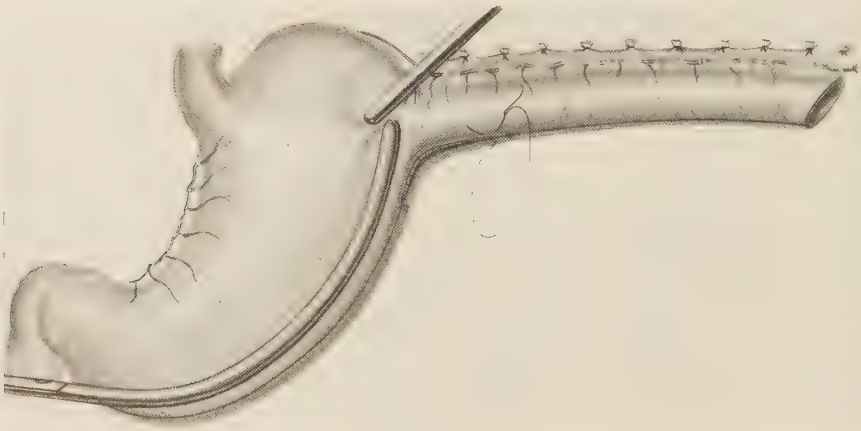

FIG. 1141.—GASTROESOPHAGOPLASTY. THIRD STAGE.
The greater curvature of the stomach has been converted into a tube. Two rows of sutures are used to close the stomach. The clamps should be removed as soon as possible.

them. To reach the diaphragm nearer its center, the transpleural root must be chosen; this is through the excision of costal cartilages in the mammary line.

FIG. 1142.—GASTROESOPHAGOPLASTY. FOURTH STAGE.
Tube completed and ready for transplantation. Note preservation of gastroepiploic artery.

To reach the diaphragm between its center and posterior part, an incision of about 13 cm. (5 inches) is made in the interspace between the ninth and tenth ribs. The center of the incision is midway between the an-

terior axillary and the scapular lines. The wound is retracted to expose the two ribs and about 9 cm. (3½ inches) of each is resected subperiosteally. Care is taken not to injure the pleura. An incision is then made along the middle of the intercostal space down to the pleura. The pleura is not opened but is bluntly dissected back. This may give sufficient access.

If it is desired to expose more of the diaphragm, the pleura may be still further separated from it by blunt dissection, being held up by flat retractors and a gauze pad as the separation proceeds. This is the most satisfactory procedure.

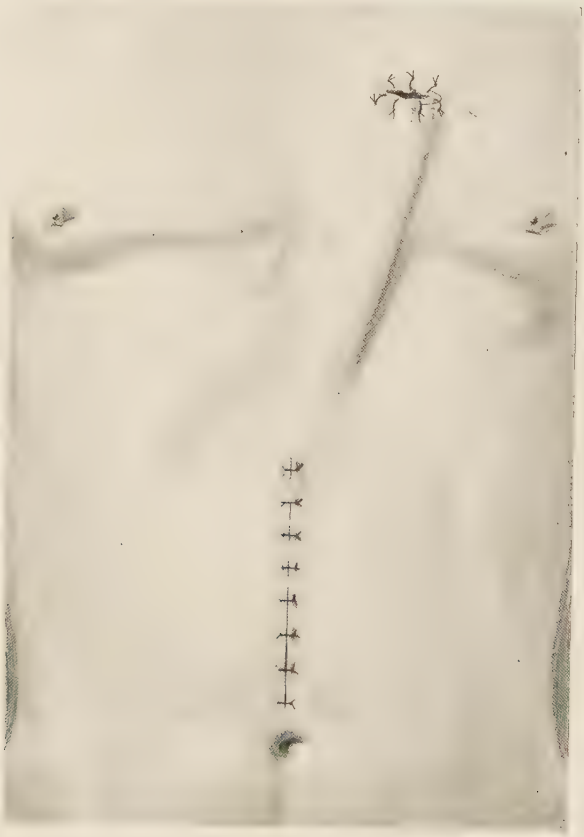

Fig. 1143.—Gastroesophagoplasty. Fifth Stage.
The tube has been drawn under the skin of the thorax and the wounds closed.

If the separation of the pleura from the diaphragm cannot be carried out the two pleural surfaces may be united by suture, the general pleural cavity thus shut off, and the operation carried out through the eliminated pleura. In some cases this may already have been accomplished by adhesions. In other cases it may seem best to pack the wound with gauze, compressing the two pleuræ together and completing the operation after a few days when adhesions have united them.

If none of these expedients can be adopted it may be necessary to open the

pleural cavity, and thence attack the diaphragm through the diaphragmatic pleura.

By this route, *subdiaphragmatic abscess* may be opened and drainage provided; *hernia of the diaphragm* treated according to the general principles laid down for the treatment of hernia; *tumors of the diaphragm* removed; and,

FIG. 1144.—ESOPHAGOPLASTY.

Operation for bringing the upper end of the esophagus out of the neck and implanting it under the skin near the gastroplastic opening. Later an operation may be done to connect the two.

by carrying the resections somewhat farther back on the left side, incision or resection of the lower end of esophagus accomplished (see Subphrenic Abscess, page 553).

Resection of the lower segment of the esophagus may be done for 6 or 8 cm. This requires opening the abdomen through the diaphragm, and bringing up the stomach for anastomosis with the esophagus after resection.

THE BREAST

Anatomy.—The breast in woman lies upon the deep fascia separating it from the pectoralis major, the external oblique muscle of the abdomen, and the serratus magnus. It is not circular in outline but has a prolongation extending upward and outward into the axilla as high as the third rib. Other prolongations also occur into the surrounding fat and pectoral muscles. Gland structure may come up close to the papillary processes of the skin. The main body of the gland extends from the lower border of the second rib to the sixth or seventh rib, and laterally from the margin of the sternum at about the fourth

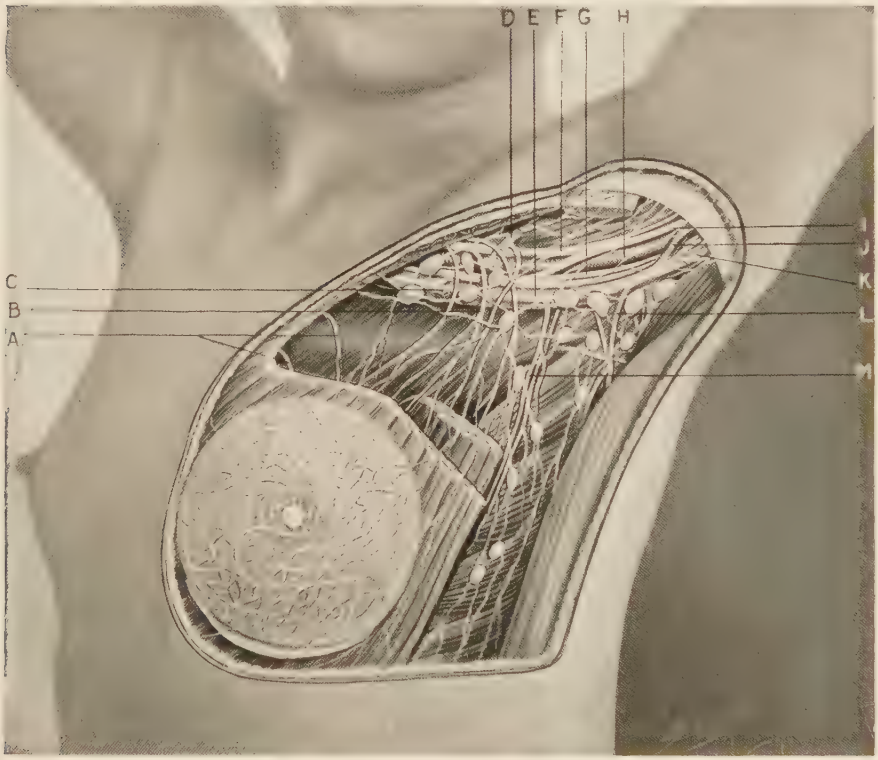

Fig. 1145.—The Female Breast.

Showing blood supply and lymphatics. *A*, Perforating branches of mammary artery; *B*, anterior thoracic nerve; *C*, cephalic vein; *D*, thoraco-acromial artery; *E*, axillary vein; *F*, lateral cord of brachial plexus; *G*, median cord of brachial plexus; *H*, axillary artery; *I*, median nerve; *J*, brachial vein; *K*, basilic vein; *L*, thoraco-epigastric vein; *M*, lateral thoracic vessels.

rib to the anterior axillary line at the fifth rib. The gland in the woman consists of fifteen or twenty lobules each opening at the apex of the nipple through its own separate duct. The whole gland is suspended between two layers of fascia which is continuous with the fascia of the neck (Fig. 1145).

The blood supply is (1) from the anterior intercostal arteries of the second, third, fourth and fifth interspaces, which are branches of the internal mammary; (2) the anterior per-

forating branches of the internal mammary of the same interspaces; (3) anterior branches of the intercostal arteries which are branches of the thoracic aorta; (4) the superior thoracic artery, a branch of the axillary; and (5) the external mammary, a branch of the axillary. The two latter anastomose with the intercostal vessels. The veins form a venous circle around the gland and join to form trunks which follow the arteries.

The **lymphatics of the breast and axilla** are most important. It should be borne in mind that while certain lymphatic chains drain certain areas of the breast, still they all freely anastomose and are capable of currents to and fro which may carry their contents in any direction. Cancer cells liberated from the breast usually first become caught in the meshwork of the lymphatic glands but they may become engaged in the finer lymphatic radicles. The lymphatics of the skin are composed of two networks, one superimposed upon the other. From each network larger trunks lead to the axilla. Other branches communicate with these trunks and lead again to the skin. Lymph channels follow all of the blood-vessels. In the muscles, one set of lymph-vessels runs parallel to the muscle fibres toward the sternum, near the margin of which they perforate the intercostal spaces and empty into the mediastinal lymphatics, which are rich in glands. The lymphatics of the upper part of the pectoralis major at its inner part drain over the clavicle and empty into the supraclavicular glands, and at the clavicular part into the glands lying behind the muscle. The superficial lymphatics freely anastomose across the median line and with the lymphatics of the neck and abdomen. There exists a very intimate connection between the lower and inner quadrants of the breast and the upper abdomen through lymphatic channels which pass downward to the epigastrium and thence back to the peritoneum and through the suspensory ligaments and subperitoneal spaces to the liver.

The lymphatics from the glandular substance of the breast itself pass toward the surface and communicate with the superficial lymphatics. The main vessels run toward the axilla. The deep vessels lie upon the fascia of the pectoralis major, and communicate with the muscular lymphatics. The superficial vessels lie in the layers of the superficial fascia and accompany the lymphatics of the skin. Some lymphatics from the deep parts of the breast accompany the perforating branches of the internal mammary vessels, and lead to the glands of the mediastinum. Others accompany the intercostal vessels into the chest wall and thence to the posterior mediastinum; and others follow the long thoracic vessels to the side of the chest and axilla.

A large lymph-vessel passes from the posterior parts of the breast upward and outward, perforates the pectoralis major muscle to the space between it and the pectoralis minor, runs between the chest wall and the pectoralis major to the second intercostal space, through which it passes into the anterior mediastinum.

The lymphatic glands are especially numerous in the axilla. They lie in close relation to the axillary vein, and follow it over the first rib into the neck and thorax. Four or five glands lie close to the axillary vein, and rarely have any glands intervening between them and the breast. They are connected with the chain of eight to twelve glands lying along the axillary vein, which have other glands intervening between them and the breast. A group lies under the scapular attachment of the pectoralis minor, close to the upper ribs. Another group, traversed by the intercostohumeral nerve, lies in the loose connective tissue in front of the outer border of the scapula, the subscapularis, and the latissimus dorsi muscles. There is also a midaxillary group, scattered more superficially; in the lower axilla they are near the skin; above they lie under the pectoralis major, and communicate with the subclavian glands. The supraclavicular triangle contains glands which receive lymph through vessels passing upward beneath the clavicle. Scattered glands may occur at different places along the lymph channels. Glands are also found along the anterior perforating branches of the internal mammary vessels.

Contusions and Wounds of the Breast. These injuries require the same treatment as when occurring elsewhere. The same may be said of *foreign bodies*.

Congenital Anomalies.—*Polymastia* is treated by excision of the rudimentary supernumerary breast if the patient desires it for cosmetic reasons, or if it is in the way or easily becomes irritated. All of the glandular structure should be removed, but sufficient skin should be left to cover the wound. The same may be said of *polythelia*. *Inverted nipple* may be drawn out by suction with a cup, massage and alcohol and oil applications.

Hypertrophy of the Breasts.—The surgeon has not to do with the congenital or physiologic forms, but *diffuse acquired pathologic hypertrophy* comes within his sphere. In this form, occurring in connection with pregnancy, the hypertrophy is apt to subside after confinement. When occur-

ring in the virgin its tendency is to persist, and operation offers the only assurance of cure. As a palliative measure the breasts may be supported with slings. The curative operation consists in excision of the breasts. Enough skin should be left to cover the wound. The operation may be done upon one breast at a time or both may be removed at one sitting. This should depend upon the patient's condition.

The surgeon should be sure that he is not dealing with pregnancy before suggesting operation for this condition, as pregnancy is the most common cause of hypertrophy of the breasts.

I once, in ignorance, offered operation in the case of a child of fifteen, whose breasts were so heavy that she was physically unable to carry them, and was consequently confined to bed; the hypertrophy subsided after she gave birth to a baby.

Diseases of the Nipple.—*Inflammations* are painful lesions most common during lactation, and are to be prevented by cleanliness. Washing with boracic solution is usually sufficient. Covering the nipple with an artificial nipple permits nursing without interfering with treatment.

Fissures of the nipple which do not yield to this treatment should be treated with 50 per cent. silver nitrate solution. A single large fissure is best treated by being touched with the pure drug.

Retracted nipples may be brought forward by suction. Soft flabby nipples may be massaged forward with boracic acid and alcohol.

Eczema of the nipple requires the ordinary treatment of that disease.

Tumors require the same treatment as elsewhere; the milk ducts should be damaged as little as possible by operation.

Carcinoma of the nipple (Paget's disease) should not be mistaken for eczema alone, with which it is associated, but should be promptly extirpated.

Neuralgia of the Breast.—This affection may be so intractable to hygienic and palliative measures that operation is required. Operative treatment of neuralgia may be applied to the affected nerves. The breast is supplied chiefly by the anterior and lateral cutaneous branches of the second, third, fourth and fifth intercostal nerves, and filaments of the external and internal anterior thoracic nerves and the posterior thoracic. Amputation of the breast need not be done. If the disease is so severe as to suggest such an expedient, an amputation with replacing of the organ is feasible. Through an incision embracing one-half of the circumference of the base of the breast, one-half of the gland is dissected up from its posterior connections, replaced, and the wound closed. After at least three weeks have elapsed the same operation should be done to the other half of the breast. These two operations have accomplished division of all of the nerves supplying the organ. If this does not cure the disease the chances are that complete amputation would not.

Mastitis.—*Acute mastitis* occurs usually in connection with lactation and results in the stoppage of the ducts of one or more lobules. It should be prevented by cleanliness of the nipples. The treatment to which this condition has best yielded is the ice-bag and twice daily massage of the engorged lobules. The massage should be applied with increasing firmness, always toward the nipple, while the rest of the breast is grasped in the other hand. During this process milk should be squeezed out of the breast, and the operation should be continued until the hardened lobule softens. In the meantime the breast should be supported by a sling, and should be nursed from or emptied by a pump. *Caked breast* (stagnation mastitis, lactation mastitis) is this form in which the obstruction of the ducts seems to be the main trouble. They are best emptied by massage and suction.

Chronic mastitis may result from the above form remaining uncured, and having added to it an infection which does not produce acute suppuration or much temperature. The most effective treatment is hot applications, massage toward the nipple, and emptying the breast by the pump.

Suppurative mastitis most commonly follows lactation mastitis, although it may occur independently of lactation. It should be prevented by prompt treatment of the pre-suppurative stage. When cellulitis of the gland has developed, two things are necessary: keep the gland empty of milk by means of the breast pump, and induce hyperemia by hot applications or by a suction cup big enough to embrace the whole breast. As soon as pus has centralized in any place, it should be evacuated by an incision in the direction of radiation from the nipple. This operation should not be deferred; no matter how small the abscess, it should be opened. It is better to make an incision and find no abscess than to leave unevacuated a dram of pus. Large abscesses should be opened at their center, and another opening may be made to advantage at the most dependent part to insure good drainage. Drainage by tubes is best. After opening an abscess, more rapid healing will be secured by the use of the suction cup (see Hyperemia). Careful asepsis, to prevent complicating the infection, should be observed. Submammary abscesses may elude the inexperienced and not receive proper attention until great damage has been done.

Extramammary abscess should be opened outside of the gland structure. It should be borne in mind that an abscess may be located between the gland and the skin or between the gland and the chest wall; and in either case the gland should not be incised.

Chronic fistula of the breast should be treated by cleanliness and suction hyperemia. In *milk fistula*, lactation should be terminated if the ordinary treatment of fistula fails.

Chronic interstitial mastitis is often confused with carcinoma. No treatment except excision is of much avail. On account of the difficulties of differential diagnosis, the indurated area should be exposed by a simple incision; if it presents the appearance of carcinoma, it may be dealt with accordingly; if the disease is inflammatory, the discomfort of the patient and the danger of malignant degeneration will be eliminated by its excision (see Chronic Cystic Mastitis).

Chronic Cystic Mastitis.—The surgeon is always confronted with the question of diagnosis in these cases. If there is no question as to the diagnosis, it would seem that the treatment resolves itself into that of the cystic induration. But the problem is a more complicated one. There usually is some question about the diagnosis; and even though the surgeon were satisfied that the disease is nothing more than chronic cystic mastitis, he can not say how soon malignancy may appear. Indeed, it is possible that in some of these cases cancer has already begun, as the primary disease, and has given rise to the mastitis. A report from the Johns Hopkins Clinic shows that if a simple operation is done for the removal of such an indurated mass and microscopic examination shows that it is carcinoma, the patient may be expected not to live beyond three years, even though a complete secondary operation is done a few days later. Whereas a report from the Mayo Clinic shows that out of 218 cases, conservative operation was done in 211, in none of which was malignancy found. Radical operation was done in the seven doubtful cases.

The course which the surgeon pursues must be regulated by the diagnosis. If there is doubt, the patient should be given the benefit of radical operation as for cancer. In case of conservative operation, an immediate pathologic examination should be made for diagnostic purposes, and if cancer is found,

a radical operation should follow. Patients over thirty-six should usually have a radical operation unless the diagnosis of mastitis is quite obvious. As a guide of action in doubtful cases the following rules may be followed: In women under thirty, partial excision of the breast may be done upon the assumption that the disease is benign; in women between thirty and forty, the whole breast and the underlying fascia of the pectoralis should be removed upon the assumption that early malignancy exists; and in women over forty, the entire gland, the pectoralis muscle, and the lymphatics of the breast and axilla should be removed. This latter operation, of course, is upon the assumption that the disease is not mastitis, but positively advanced cancer. There should be no half-hearted operation for cancer; nor is it possible to do such a thing as a combined operation for benign and malignant growth at the same time, as it would seem from the recommendations of some surgeons in these cases. The operation should be either for one or the other—benign or malignant disease—it cannot be for both.

Hard and fast rules should not be followed. The location and size of the induration and other factors may modify the operation. The *x*-ray, fulguration, and radium may be added to the above treatments.

In young women, the breast may be separated from the underlying muscle by a semicircular incision at its lower border. The gland is turned up as a valve. It may then be dealt with, removing as much as seems necessary from the rear. In the place of the removed tissue a graft of fat from the patient's abdomen or thigh may be introduced for cosmetic purposes if desired. Before beginning such an operation, the surgeon should have the consent of the patient to do a radical operation should the tissues look malignant.

Tuberculosis of the breast should be treated by the general measures already described for tuberculosis. A limited tuberculous area should be excised under aseptic precautions and care that the wound does not become reinfected with tuberculosis. Axillary glands should be removed. A tuberculous breast, penetrated by sinuses and the disease involving much of the gland, should be removed. Between these two are many variations.

The cases, as the surgeon usually sees them, can rarely be said to be limited to a single small area. There is always a strong probability of lymphatic infection even when the primary breast focus is small. For most cases the best treatment consists in removal of the breast, underlying pectoral fascia, and axillary connective tissue and lymphatics. In early cases, with apparently one isolated nodule, the surgeon may be satisfied with elliptic excision of the part of the breast containing the mass, removal of the underlying pectoral fascia, and clearing out the axilla (for removal of breast and axillary lymphatics, see page 480). The prognosis after surgical treatment is better than in most regions.

Benign Tumors.—(See Tumors, Vol. I, page 323.) All benign tumors of the breast should be removed. *Cystadenoma* (senile parenchymatous hypertrophy) is important because of its proneness to undergo carcinomatous degeneration unless extirpated. All of the diseased portion of the breast should be removed, and as the disease is prone to extend to all parts of the gland complete excision is the safest course. *Cystic adenoma*, *adenofibroma*, *fibro-adenoma*, and *intracanalicular myxoma* are encapsulated tumors which should be exposed by a radiating incision or by flap incision, and, having been identified as benign, should be excised, leaving the undiseased gland. The wound should be snugly closed with buried sutures. *Angioma* or *nevus* is best cured by extirpation. *Lipoma* and *mixed tumors* are to be treated as elsewhere.

Cysts.—Cysts of the breast should be treated as benign tumors. *Simple cysts* should be excised. It is not necessary that the excision go beyond the wall of the cyst. Where there are several cysts, and for cosmetic reasons

Fig. 1146.—Incision for Benign Tumor in Posterior Part of Breast.

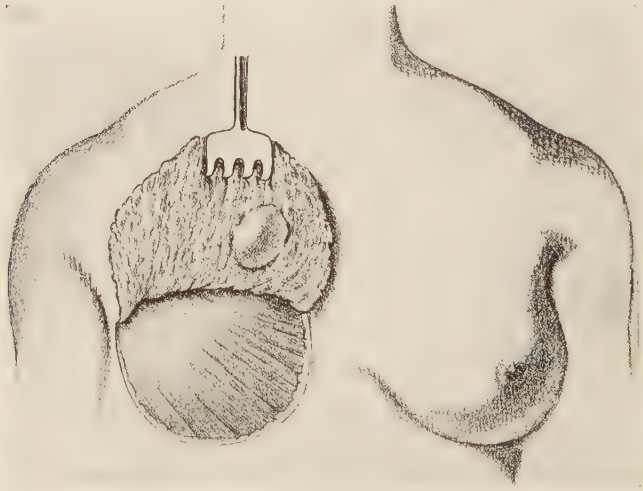

Fig. 1147.—Breast Turned up as a Flap to Remove Benign Tumor.

it is desired to preserve as much of the breast as possible, the gland may be dissected away from the pectoral fascia through a crescentic incision and the cysts removed through its base. A breast containing many scattered

cysts should be removed. Large single cysts over which the gland tissue is stretched are usually best treated by removal with the gland. *Galactocele* is best cured by extirpation of the sac. *Dermoid cysts* and *hydatid cysts* should be treated as elsewhere. *Papillomatous cysts*, or cysts containing papillomatous growths, are so prone to undergo carcinomatous degeneration, that the segment of the breast containing the cyst should be removed; and, if a part of the wall or the adjacent gland tissue is found infiltrated, the disease should be treated as carcinoma and a radical operation performed.

There are some *simple cysts* which are cured simply by aspiration. If there is no possibility of malignancy, there is no reason why aspiration of a simple cyst should not first be tried.

Incisions for the removal of benign tumors should generally be straight incisions in a line radiating from the nipple. A larger tumor requires that an elliptic incision in this direction should be made. Still larger tumors require an ellipse embracing the nipple or a racquet-shaped incision. The milk ducts should only be cut across when necessary. In general it is preferable the incisions should radiate toward the axilla. For tumors of the lower segment a curved incision (Fig. 1146) may be made about the base of the gland, and the gland turned up as a flap, the tumor being removed through the base of the gland (Fig. 1147).

Carcinoma.—*The prevention of carcinoma of the breast* can be promoted by (1) preventing and promptly curing mastitis, (2) by removing indurated areas and benign growths, and (3) by preserving the properties of youth in the individual (see Malignant Tumors, Vol. I, page 327). The removal of benign tumors of the breast or the removal of the whole breast for benign tumor is always justifiable because of the facts, that no benign tumor ever becomes more benign, that all such conditions may become malignant, and that malignancy may already be present though undiagnosticated.

The *cure of carcinoma of the breast* depends upon the removal of all of the carcinoma. When all of the disease has been removed, the patient is cured forever of that particular attack of disease. When but the smallest relic is left, recurrence may be expected. The disease is originally distinctly local, but soon begins to spread into the surrounding tissues and to be carried through the lymphatics; therefore the hope of cure rests upon *early* and *complete extirpation* of the disease while yet it remains localized in one spot. There is no known treatment which has so much to offer as operation. To employ any other treatment in an operable case is unjustifiable. When we realize that, if carcinoma is operated upon as soon as the tumor or induration can be discovered, it is in the great majority of cases absolutely curable, and that with the lapse of time the possibility of cure rapidly declines, until in a few months hope is forever gone, we perceive that to withhold early operation is to condemn the patient to a wretched an unjustifiable death. To await an absolutely accurate diagnosis is a surgical crime. There need be no mortality following the excision of benign tumors of the breast; and the early removal of a hundred such tumors is better than to deny one woman deliverance from cancer of the breast. The question for the surgeon to decide is not, "has this woman cancer?" but, "is there a reasonable possibility that this may be cancer?" Upon the reasonable possibility he should operate. One of the reproaches of medicine is this: the vast majority of the cases operated upon for carcinoma of the breast, are found actually to be suffering with that disease. It would be much to the credit of medicine were it less accurate with diagnosis and more timely with the helping hand. Most cases which come to the surgeon are, alas, too easily diagnosed!

Contraindications to operation should be recognized. There are contra-

indications to the simple operation of extirpation of the breast and adjacent axillary soft tissues; but the contraindications to most other operations are fewer. When the disease has spread to the adjacent lymphatics, it is still possible to remove it all by the simple operation, provided it has not gone beyond the axilla or the structures of the bony chest wall. The cases in which operation is contraindicated, as offering no hope, are those (1) in which there are metastases along the whole length of the subclavian vein or in the supraclavicular triangle of the neck; (2) those with wide skin infiltration; (3) those with involvement of the chest wall, as evidenced by fixedness of the tumor and (4) cases with remote metastases. These are by no means absolute contraindications, and can be regarded as such only when the disease has crossed the median line of the body or involves irremovable structures. It is difficult often to recognize these conditions. Swelling of the arm from venous obstruction points to the first; palpation should reveal the others. Rules cannot be given. Some cases in which the extent of disease was wide and the case apparently hopeless have enjoyed long intervals of immunity after operation; and other cases which seemed hopeful have rapidly perished from recurrence. If it seems possible to remove all of the disease, operation should be attempted. If the operation must be so extensive as to threaten the life of the patient, even though it may seem that all of the disease has been removed, it probably has not. The necessity for extensive operation means the probability of still wider extension of the disease. Inoperable cases may have much done for them by palliative measures (see Extensive and Recurrent Carcinoma, page 494).

Prognosis influences treatment. Death results in nearly 100 per cent. of cases not treated surgically. Usually it occurs within two years. Most patients will be dead inside of three years without operation. Cases operated upon, but in which recurrence takes place within three years after operation, live on an average about two years and a half after the discovery of their original disease. Most recurrences take place within three years after operation. If recurrence has not taken place within three years after operation, 90 per cent. need not expect recurrence at all, and may regard themselves as permanently cured. Later recurrences do take place, sometimes as late as ten years or longer. With modern operative technic, notwithstanding that most cases come to the surgeon weeks and months after the disease could have been recognized, from 40 to 50 per cent. of cases pass the three-year period without recurrence, and from 30 to 40 per cent. pass the five-year period. Local recurrences represent about 10 per cent. of the recurrences in cases in which a modern operation had been done. Regional recurrence is not often seen after the first year. The majority of recurrences are within three months after the operation.

Operations done for recurrence of the disease offer a poor prognosis if a timid and incomplete operation is performed. There is every reason why they should be done if there is any possibility of removal of the secondary growth or of relieving the patient from distressing symptoms. Operations for recurrence have been done repeatedly, and the patients kept alive and in comfort for many years (see Extensive and Recurrent Carcinoma, page 494).

Operations in doubtful cases should be so planned that the tumor is exposed as one of the first steps in the operation. It has been my practice to do this through an incision, which, were the disease carcinoma, would be the part of the incision falling nearest to the growth. The part of the gland, containing the tumor, having been exposed, the surrounding tissues are walled

off with gauze, and the tumor incised. No surgeon is fully competent unless he has had sufficient pathologic training to be able to recognize carcinoma by the gross appearances of the cut surface. If the appearances are those of benign tumor, the surgeon proceeds accordingly; if the appearances are those of carcinoma, the soiled knife is laid aside, the wound in the tumor is packed with gauze soaked with tincture of iodin, the wound is kept covered and the radical operation proceeded with; if there is doubt, the surgeon should proceed as though the appearances were those of carcinoma.

Tissues to be removed and the extent of their removal in cancer of the breast depend upon the location and extent of the growth. The *skin*, it should be remembered, in places lies upon the gland substance, which is rich in its lymphatic communications with the skin. As a rule, all of the skin covering the gland, excepting its outer margin, should be removed with the tumor in the case of central growths. In cases in which the tumor is near the margin of the gland, the skin for from 4 to 8 cm. (1½ to 3 inches) beyond the gland should be removed. In the latter case, skin overlying the gland on the side opposite the growth may be left, provided the growth is not in the lower and inner quadrant. In the case of a deep-lying small tumor, the skin covering much of the breast need not be removed. As a rule, the incision should not approach the tumor nearer than 5 cm. (2 inches); and at the upper and outer quadrant of the breast it should be at least 7.5 cm. (3 inches) remote from the tumor. The skin incision should have as its first aim the circumscribing of all of the disease which may possibly reside in the skin. The *subcutaneous fat* is more apt to be invaded than the skin. The dissection should slant away from the skin incision so that more fat than skin is removed. The fat lying between the gland and the axilla, and the axillary fat should be extirpated.

The *mammary gland* substance should all be removed. Even the parts away from the neoplasm may be invaded through the lymphatics. The *pectoral fascia* upon which the gland rests is apt to be invaded by the disease even before the skin. It may contain deposits of cancer cells before the gland has become adherent to it. All of the fascia underlying the gland and running up to the axilla should be removed. The *muscle* is invaded about as soon as the fascia. I have found, while working with Professor J. Orth in Göttingen, deposits of carcinoma in the pectoralis major in cases in which the primary tumor was not adherent to the pectoral fascia and in which the pectoral fascia was apparently free from disease. Invasions of the fascia and muscle by metastatic deposits are simultaneous. It is for these reasons that removal of the fascia alone has little value. The underlying muscle should go with it.

The *lymph glands* were formerly removed only when large enough to be felt. A high rate of recurrence followed this practice. These glands are involved very early in the disease. All of the lymphatics of the axilla should be removed in every case of carcinoma of the breast operated upon which it is hoped to cure, even though no glands are large enough to be felt. Leaving an impalpable gland with a nest of cancer cells as big as the point of a pin renders the whole operation of no service to the patient. By removing all of the fat contained in the axilla, and all of the connective tissue about the axillary vein, the lymphatics come away with it. The same should be done with the fat and connective tissue lying beneath the scapular attachment of the pectoralis minor, the clavicular attachment of the pectoralis major, and the space between the outer part of the scapula and the serratus magnus. When the upper axillary glands are found carcinomatous the dissection should be carried as far over the first rib as possible and then the supraclavicular

space opened in the neck and its fatty contents removed. If glands can be palpated in this space they should be removed as a routine, though such cases do not promise well.

The *lines of incision* for carcinoma of the breast should depend upon the extent and location of the disease. The incision should be carried further in one direction or another in order to embrace all of the disease and all of the probabilities of lymphatic involvement. The incision usually should begin at the humeral insertion of the pectoralis major, and pass inward well above the axillary border of the muscle, across the tip of the coracoid process, and thence curve downward to embrace the breast. Growths



Fig. 1148.—Carcinoma of the Breast.
Skin incision for disease in upper half of breast.

involving or encroaching upon the upper half of the gland should have a wedge of skin removed between the breast and axilla (Fig. 1148). In tumors confined to the lower half of the breast the incision may make a curve about the upper border of the gland but a wedge of skin should be removed below the breast (Fig. 1149). Tumors involving both the upper and lower halves should have a combination of these two (Fig. 1150). For cases of centrally placed tumor, operated upon early, the breast may be embraced by a circular incision, and a flap taken from above to cover the defect (Fig. 1151). The incision recommended by J. E. Jennings (New York Med. Jour., cii, 1916) is adapted to most cases (Fig. 1152). The special merit of this incision is that it removes the skin of the axilla which is prone to be the seat of cancerous deposits.

Steps of the Operation.—The patient should lie supine with the diseased side close to the edge of the table. The skin preparation should include the front of the chest, neck, upper abdomen, side of the chest, axilla, shoulder



FIG. 1149.—CARCINOMA OF BREAST.
Skin incision for disease of lower half of breast.



FIG. 1150.—CARCINOMA OF BREAST.
Skin incision for disease encroaching upon both upper and lower halves of breast.

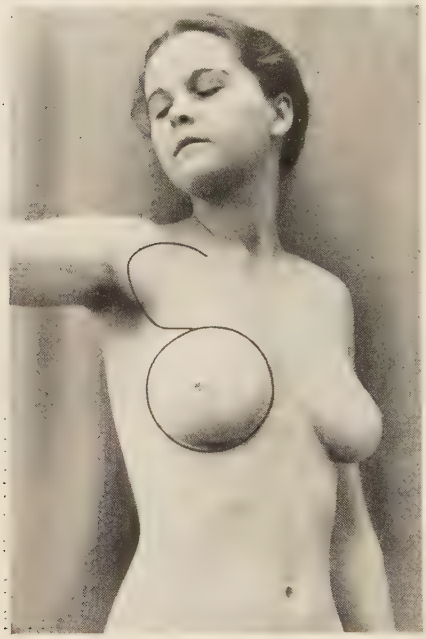

FIG. 1151.—CARCINOMA OF BREAST.
Skin incision with axillary flap for cases of early disease in the center of the breast.



FIG. 1152.—CARCINOMA OF BREAST.
Incision of Jennings, removing axillary skin, for cases with central disease of breast.

and upper arm. The preparation of the skin, and the handling of the tumor before and during the operation should be so gentle that no cancer-cells are forcibly dislodged and sent into the lymph-channels. This is one of the dangers of operation. All manipulations should be governed accordingly. The hand and forearm should be enveloped in towels, and held at a right angle to the body or rested upon a table. It is well to have a protecting screen between the anesthetists apparatus and the field of operation.

If diagnostic exposure of the tumor is to be made the incision should begin at the breast; otherwise it should begin at the arm. In the typical case, the incision should pass from the pectoralis insertion to the inner side of the breast (Fig. 1153). This should be joined above the axilla by the outer arm of the incision, extending from the outer side of the breast. These incisions are carried down to the subcutaneous fat, and obliquely away from

Fig. 1153.—Incision for Cancer of Breast.
The first part of the incision is shown by the solid lines. The incision indicated by the dotted lines is made after the axilla has been dissected.

the wound, down to the fascia lying upon the muscles. The skin and subcutaneous tissues are then undermined and dissected free as far as the outer end of the clavicle and the middle of the sternum; and externally, the axilla and outer thorax should be uncovered as far as the latissimus dorsi muscle. Enough tissue should be left so as not to destroy the nutrition of the skin. In fairly advanced cases the subcutaneous fat in the regions where the lymphatics run, especially between the tumor and the axilla, should be removed.

The insertion of the pectoralis major muscle is then exposed, the finger passed under it, the sternal and costal fibers divided (Fig. 1154), and the stump reflected inward. This division need not always involve the clavicular fibers, which may be separated from the costal part by blunt dissection, and preserved. The removal of the muscle from below the clavicle should

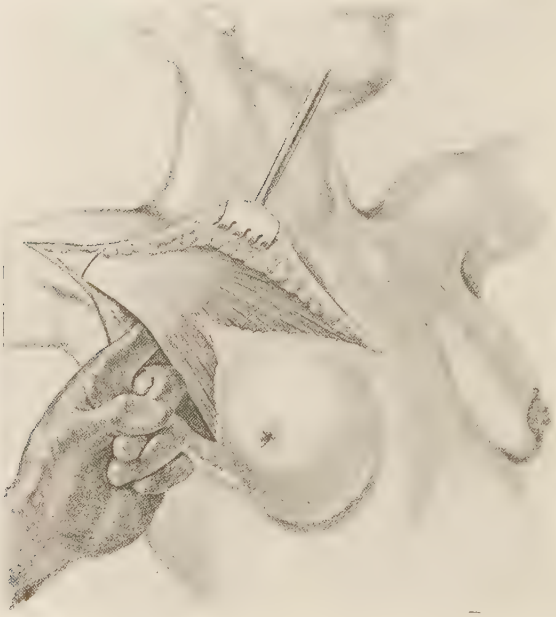

FIG. 1154.—CARCINOMA OF BREAST.
Division of pectoralis major. The incisions have not yet been carried below the breast.

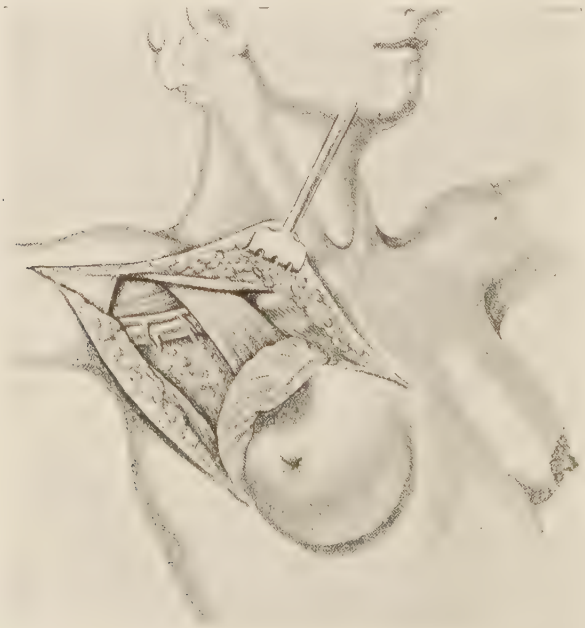

FIG. 1155.—CARCINOMA OF BREAST.
Pectoralis major has been divided. Division of pectoralis minor is the next step.

extend as far inward as the inner third of the clavicle, where the fibers should be divided by a vertical incision, exposing the extreme upper limit of the axilla. The pectoralis minor comes in view and is divided close to its insertion in the coracoid process, and retracted downward and inward (Fig. 1155).

The thin axillary fascia is now exposed. It should be divided at the extreme outer limit of the wound parallel with the vessels, reflected inward and the axillary artery and vein exposed. A clean and complete removal of the connective-tissue contents of the axilla should then be made. There are no structures of much consequence requiring to be spared, excepting the axillary vein and artery and the great nerve trunks. The two superior subscapular nerves may be preserved. The intercostohumeral nerve, passing across the center of the axilla need not be spared. The third subscapular nerve, to the latissimus dorsi, may be saved. None of these nerves should

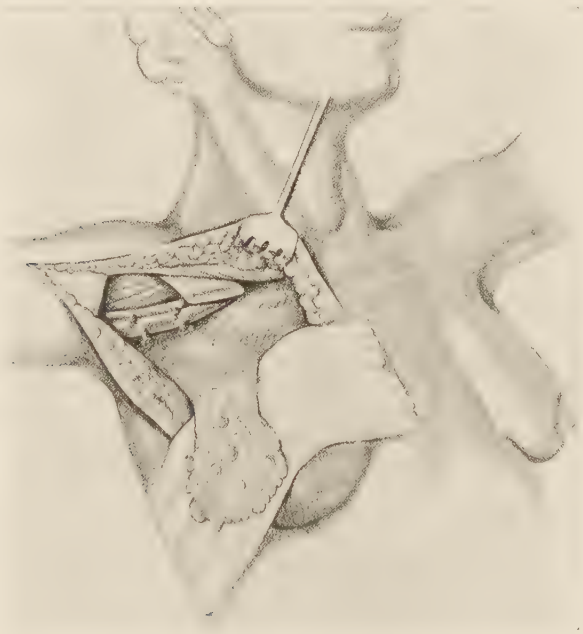

Fig. 1156.—Carcinoma of Breast.

Contents of axilla have been dissected out. As soon as the lymphatics of the axilla have been liberated they should be enveloped in a towel to prevent the escape of cancer cells into the wound.

be preserved if their preservation entails the least amount of risk to the success of the operation. The removal of the axillary contents may begin above at the first rib and follow the vessels downward. The cleaning off of the axillary vein is most important. The vein should be well in view and clearly exposed throughout (Fig. 1156). The numerous small arteries and veins, coming from the main vessels, should be tied in two places and cut between. Free connective tissue should not be embraced by the ligatures. The dissection is best made by anatomic forceps and a small knife. The operation thus clears out the axilla, extending well into the spaces below the clavicle, between coracoid process and first rib, and in front of the outer border of the scapula. The loose tissue is kept attached in one mass. A flat piece of gauze envelops the tissues as they are loosened.

A towel is pressed into the axilla, and the dissection then passes to the thorax. The mass of axillary tissue is carried inward. The pectoralis minor is cut from the ribs, and likewise the upper and outer thoracic attachments of the pectoralis major. The skin incision, which up to this point had not passed below the level of the nipple, is now completed below the breast. The same oblique incision through the superficial fascia is made away from the wound so as to take as much connective tissue from the region of the disease as possible. The pectoralis major is then cut from the chest. This is over an area which is much larger than the area embraced by the skin incision. With the muscle comes the mammary gland, and the axillary tissue hanging to it (Fig. 1157). The periosteum need not be removed from the ribs in ordinary cases, and enough of the pectoralis muscle may be left to afford a hold for the ligatures which the vessels will require (Fig. 1158).

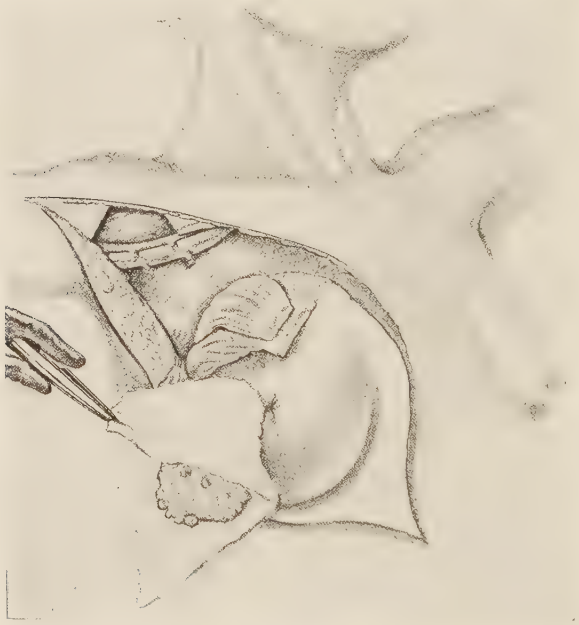

Fig. 1157.—Carcinoma of Breast.

The axilla has been dissected and the removal of the breast and pectoral structures is proceeding. The axillary lymphatics, still attached to the breast, should be enveloped in a towel.

Next to a wide removal of the disease, the saving of blood is the great desideratum in this operation. Most vessels should be clamped before they are cut. Skilled assistants are important. The so-called *shock* following this operation is largely a matter of hemorrhage. No vessel however small should be permitted to bleed. The wound should be kept dry. The pressure of the hemostatic clamp closes most vessels, and not many ligatures are required. A slow operation with a minimum of hemorrhage gives less depression than a bloody rapid operation. From a half to three-quarters of an hour should be consumed up to the completion of the dissection and the beginning of the closure of the wound. Many surgeons take more than an hour for the finished operation.

The *closure of the wound* can not readily be completed without further

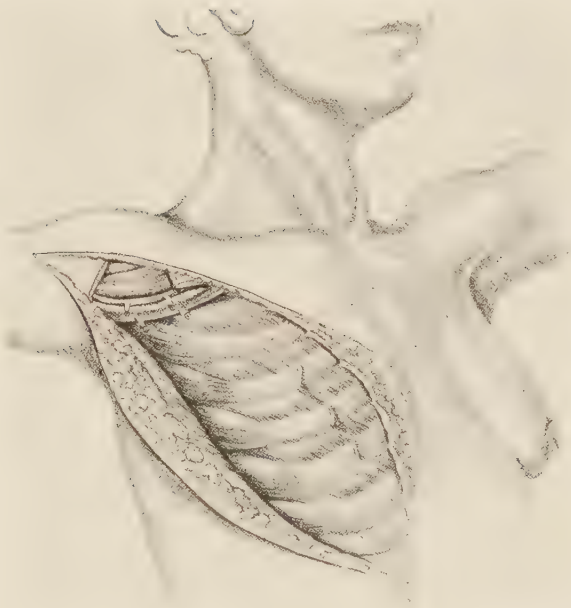

FIG. 1158.—CARCINOMA OF BREAST.
Showing wound after removal of the breast, pectoralis major and minor, and contiguous structures.

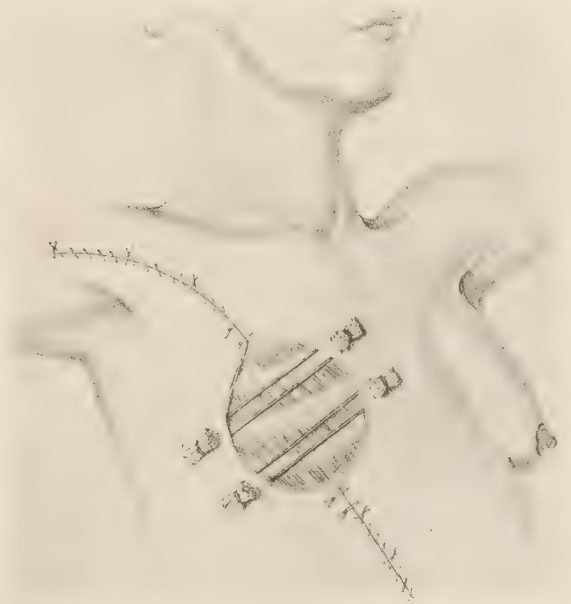

FIG. 1159.—CARCINOMA OF BREAST.
Wound sutured as far as possible. The uncovered area is left to granulate for later skin-grafting. Note two mattress sutures of silkworm gut with gauze bolsters.

plastic work if a large amount of skin has been removed. To make a complete closure, the skin should be dissected free from the chest inward across the sternum and, if necessary, behind the opposite breast. A similar freeing of the skin below and externally may also be made. If this does not permit closure, one or more sliding flaps may be made (see Plastic Operations, Vol. III). These plastic operations should also be made as free from hemorrhage as possible. Apposition is facilitated by bringing the arm to the side and throwing the shoulder forward by a pad placed behind the upper arm. Tension upon the sutures is objectionable; it is better to leave an area uncovered. Such an area may be covered at once with skin grafts or left to granulate (Fig. 1159). A few deep sutures of silkworm-gut, and the closure of the intervening wound with a continuous suture are most suitable.



Fig. 1160.—Carcinoma of Breast.
Dressing completed after operation.

The use of *drainage* must depend upon the possibilities of infection and the amount of exudate expected. As a rule, it is best to make a small drainage opening through the flap at the extreme posterior part of the wound, and pass a rubber tube into the axilla. A separate dressing should be placed over this tube.

A copious gauze *dressing* should be applied to the wound. A pad of gauze should be placed in the axilla. The dressings should be held in place by a breast binder having straps over the shoulders. A separate bandage may hold the dressing on the upper arm. An oblong pad of towels or a pillow should be placed behind the upper arm. It is not necessary to bind it to the side. The patient is more comfortable if it is left free. The forearm may be flexed across the abdomen (Fig. 1160).

The *after-treatment* consists in keeping the patient recumbent for a day or two. She is then gradually elevated in bed, and allowed to sit up on the fourth or fifth day. The drainage tube is removed on the second day by lifting up the back of the dressings, but without removing them. The wound

is dressed on the seventh day, if it was completely closed, and the arm left at liberty. The patient may walk about as soon after this as she feels able. Movements of the arm should be begun after the second or fourth day. The arm should be capable ultimately of making all of the previous motions, excepting that forward adduction is weak.

Other operations than that described are indicated in peculiar cases. A small centrally located tumor in the back of the breast does not require that the elliptic incision for the removal of the breast should include any more skin than will permit of an easy apposition of the wound. A small recent tumor on the extreme inner edge of the breast does not require removal of the pectoralis minor muscle. When the supraclavicular glands contain palpable metastases, if otherwise the case seems hopeful, they may be

Fig. 1161.—Carcinoma of Breast.

Operation with preservation of part of pectoralis major. The inner part of the muscle has been removed with the breast; the outer part, with its nerve-supply intact, is sewed to the thorax.

removed through a supraclavicular incision. It is not worth while in these cases to divide the clavicle, as some surgeons have done. When glands are intimately adherent to the axillary vein, it may be necessary to excise a bit of its wall. The opening may be closed with suture. Or it may be necessary to remove so much of the vessel as to occlude its lumen. A complete segment may have to be cut out. The surgeon should stop at nothing but structures of vital importance. Occlusion of the vein leaves a disagreeable swelling of the arm.

C. E. Ruth (Am. Jour. Obst. and Dis. Wom. and Chil., vol. lxix, No. 1, 1914) preserved the distal part of the pectoralis major muscles. The muscle is divided from the clavicle to the lower and inner part of the axilla. The two stumps of the muscle are retracted and the axilla exposed and operated upon. Then the thoracic portion of the muscle is removed along with the contents of the axilla and the breast. The humeral part of the muscle, at the close

of the operation is turned back and sewed to the chest wall. It is attached to the latissimus dorsi and teres major muscles (Fig. 1161). The muscle thus lies in contact with the axillary vessels and nerves, giving them protection, obliterating the axillary cavity, greatly reducing the amount of scar formation, and providing a better use of the arm than when the muscle is wholly destroyed. As this distal part of the muscle is not prone to be involved in the disease, this step may wisely be introduced as a rule in most operations.

The operation described by Jackson is applicable to small posterior growths or tumors not encroaching upon the upper half of the breast, but it should not be employed in anterior central tumors or tumors of the upper segment, because it does not remove the skin between the gland and the axilla.

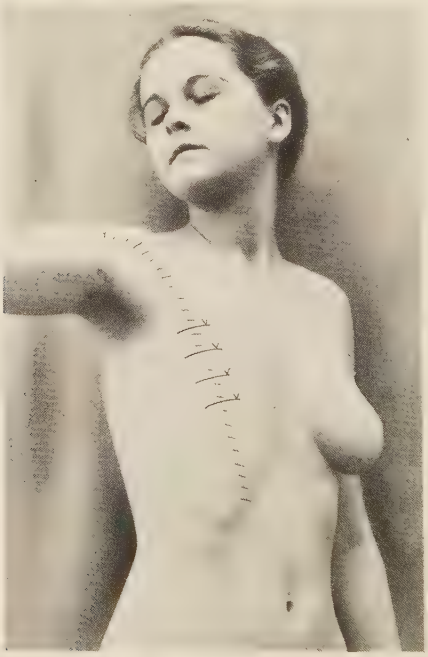

Fig. 1162.—Complete Closure of Wound Possible in Patient Who is not Lean and with Small Central Disease of Breast.

This is not a theoretic objection. Before the days of the radical operation recurrences in just this patch of skin were common.

In tumors of the lower or inner part of the breast, the incision should be carried to the ensiform appendix; the subcutaneous fatty tissue below the breast, together with the superficial layer of the deep fascia lying upon the muscles, should be removed. This operation should remove the fascia lying upon the upper part of the rectus muscle and the costal attachments of the external oblique. The dissection should extend as far inward as the median line, below to the level of the apex of the ensiform, and outward as far as the outer border of the breast.

To prevent planting cancer-cells in the wound, the greatest care should be taken not to squeeze or traumatize the breast. So great is this danger that some surgeons carefully amputate the breast with the pectoral muscle and

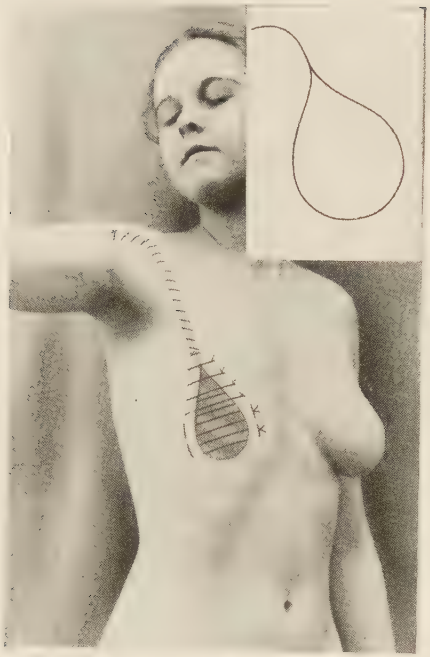

FIG. 1163.—PARTIAL CLOSURE OF HIGH WOUND AFTER EXCISION OF BREAST.

FIG. 1164.—COMPLETE CLOSURE OF HIGH WOUND BY MEANS OF TWO LATERAL PLASTIC FLAPS.

fascia, close the wound; and then two or three weeks later proceed with the operation in the axilla. Others at the first operation remove the part of the breast only which contains the disease; and complete the operation at a second sitting. Others, as has been described above, begin the operation with the dissection of the axilla, and, keeping all the removed tissue in one mass, remove last the breast with its underlying structures.

The *closure of wounds* after these operations is the same as for other wounds. The surgeon should not have this as a matter of primary concern. The wide extirpation of the disease comes first. Closure of the wound is a secondary matter (Figs. 1162, 1163, 1164, 1165, 1166, 1167, 1168 and 1169).

The *radical cautery operation for cancer of the breast* was perfected by J. F. Percy. The cautery knife is used the same as the cold knife. It possesses the

Fig. 1165.—Partial Closure of Low Wound after Excision of Breast.

advantage that it destroys any cancer cells in the line of incision and may be used to check bleeding at the same time. The operation is free from hemorrhage, and the time which is consumed in clamping and tying vessels is saved. The line of incision should be marked out with the cautery knife. The knife should not be too hot. The skin should not be cut from without inward as this causes a necrotic edge. The knife should be caused to puncture the skin, which is lifted up with tenaculum forceps, and then the skin should be cut from within outward as the knife follows along the line marked for the incision. Dissection of all of the structures is done with the red hot knife. Dissection of tissues around blood-vessels can be made quite as close as with a cold knife as the blood-stream maintains a constant temperature in the wall of the vessel and prevents overheating. In dissecting about the axillary vessels and brachial plexus the structures should be held by the fingers of the free hand, encased in a medium-weight rubber glove,

Fig. 1166.—Complete Closure of Low Wound by Plastic Flaps.

Fig. 1167.—Partial Closure of Large Wound after Excision of Breast.

and kept close to the cautery knife. By this means the surgeon may judge the degree of heat which the tissues are sustaining. The heat should be applied until the tissues that were fixed by the disease have become movable. Drainage openings should be made by puncturing the skin from within outward. The sutures should be placed well away from the edges of the wound. Percy reports good results with this method.

Inoperable cancer of the breast is becoming less common as education concerning this disease advances. There are few cases for which nothing can be done. When the disease has progressed so far that the ordinary operation can not circumscribe it, the *x*-ray and radium are capable of checking its progress.

The extent to which surgery may go in removing the invaded parts is only limited by the necessity to leave the organs which are essential to life.

Fig. 1168.—Complete Closure of Large Wound by Aid of Lateral Vertical Incisions and Undercutting of the Skin.

There have been strange recoveries from cancer—strange because the nature of the disease is not yet known. The disappearance of recurrent cancer of the breast has been observed by many surgeons after removal of the ovaries. In some of these cases the disease has returned, but in some permanent cures have been reported.

Extensive and Recurrent Carcinoma of the Breast, Axilla, Neck, and Thorax.—Cases of carcinoma of the breast, which have or have not been operated upon, which show symptoms of extension along the course of the axillary vessels and nerves, giving rise to swelling, pain, and numbness in the arm, have customarily been regarded as inoperable, and condemned to morphin, *x*-rays, serums, bacterins, or quackery until the inevitable end. The suffering of these patients is very great, and death is welcomed as a relief. Has surgery nothing to offer these unfortunates? I think it has. The

mistake made by the older surgeons has been to think of carcinoma of the breast as carcinoma of the breast, when as a matter of fact it soon is carcinoma of the axilla, neck, and thorax, and should be thought of from the beginning, either in fact or potentially, as such.

In these desperate cases the surgeon must put out of his mind the idea that he is considering a disease of the breast, lest the psychology of timidity be stimulated by the observation of the great distance from its origin which the disease has traversed. When we think of disease of the axillary vessels, brachial plexus, scapula, humerus, clavicle, lymphatics of the neck, ribs, pleuræ or lungs we are aware that any of these structures may be removed,

Fig 1169.—Closure of Wound after Operation with Axillary Flap.

I, The breast has been removed, and the circular area behind the breast remains be covered.

II, The axillary flap (*A*) is swung downward and caused to cover breast area. The skin at (*B*) is carried upward, and the wound is closed.

III, Result after suturing wound.

and are every day being attacked with impunity by surgery. Primary cancer of these structures is unhesitatingly extirpated. Why should the surgeon withhold his skill from such disease, if perchance it were preceded by a cancer of the breast?

These patients can be made more comfortable, life in a certain number prolonged, and in some the disease cured by such radical operations. I have no hesitation in saying that such operations have more to offer and will show more cures than the simple amputation of the breast for primary carcinoma which was commonly practised thirty years ago.

The operation begins with amputation of the shoulder, a flap being made from such tissues as are farthest from the disease (see Intrascapulothoracic Amputation, Vol. III). The scapula and clavicle may be removed without hesitation in order to remove disease or to uncover the vessels and

nerves which are involved. The axillary and subclavian vessels should be followed up into the neck and thorax, and the vessels together with all surrounding tissues removed. This dissection and excision may be carried as far as is necessary to reach the limit of the disease. At the same time the cords of the brachial plexus should be followed up and removed with their surrounding tissues. Before cutting the nerve-trunks they should be injected with cocain to block impulses and prevent shock (Figs. 1170 and 1171).

This dissection and excision of vessels and nerves may be carried as far as is necessary. If it is discovered that a rib or ribs are involved in the disease, they may be removed. Ribs are removed for other conditions; why not to

Fig. 1170.—Showing the Possibilities of Surgery in Carcinoma of the Breast, Axilla, Neck and Thorax. Front View.

save a patient from cancer? Involvement of the pleura calls for resection of the disease. Involvement of the lung demands removal at least of the affected lobe. A lobe or the whole lung is excised for other disease; why not for carcinoma?

There is no structure in the side of the neck which may not be sacrificed. Vessels, including the internal jugular and carotids, may be resected. The brachial plexus, vagus, and phrenic nerves may all be removed. In the chest the only structures which must be preserved on one side are the heart, aorta and vena cava. The whole of one lung, the ribs which cover it, clavicle, scapula, arm, all the vessels and nerves of one side of the neck, and the neighboring and involved connective tissues, muscles, and lymphatics may be extirpated. This means everything practically on one or the other side of the spinal column from the base of the skull to the diaphragm.

No operation, of course, would involve all of these structures. Cancer would not involve them all in a single patient. They are enumerated, however, to show the possibilities of radical operation. Such procedures should be carried out with due regard for the possibilities of shock. Blood should be saved; and nerve-trunks should be desensitized. Operations of this sort may be done in several stages, with intervals of several days for recuperation. In the hands of the experienced surgeon, who knows how to save blood and minimize shock, these operations have much to offer. The *x*-rays and radium may be used in conjunction with them.

FIG. 1171.—AMPUTATION OF SHOULDER FOR CARCINOMA OF BREAST AND AXILLA. REAR VIEW.

The experience of surgeons is showing that many patients, otherwise doomed to a painful exodus, may be made comfortable, may have life prolonged, or may be cured by such radical procedures. The literature of surgery is growing rich in the reports of these triumphs. Presumably hopeless cases have been cured. Many cases have been operated upon repeatedly for recurrences and life prolonged, or the disease ultimately cured. No patient should be regarded as beyond the hope of relief unless the general toxemia and inanition indicate an early conclusion.

The Male Breast.—*Chronic mastitis* requires the same treatment as chronic inflammations in other structures. *Tumors* should be treated as in other parts. *Carcinoma*, which is by no means uncommon, should be treated radically as in the female breast.

THE ABDOMEN

GENERAL PRINCIPLES

The peritoneum is the important connecting structure of the abdomen. It is extremely susceptible to infection; and being infected conveys disorder from one organ to another. No surgeon is competent to deal with abdominal diseases unless he has an understanding of its pathology. Nor is a surgeon competent to invade the peritoneum until he has added to his knowledge a large experience as assistant and student under a master of the subject. This is because abdominal surgery can be learned only by experience. To open the abdomen for even the most simple disease may reveal complications, the handling of which would try the most skillful surgeon. Conditions within the abdomen can never fully be revealed by external examinations. Only when the disease is uncovered to the sight or touch can the surgeon be assured of its character. In most cases of abdominal disease it is better that the disease be left to nature than that the peritoneum be invaded by an inexperienced or unskillful surgeon.

The oft-repeated conventionality that the after-care of surgical cases is as important as the immediate treatment is not well founded. In abdominal operations the fate of the patient is usually decided by what the surgeon does before the abdomen is closed.

Every abdominal disease is serious; and invasion of the peritoneum must always be regarded as a major operation. The idea should not be promulgated that certain operations are trivial affairs; it is unfair to the patient, and it encourages boldness in the inexperienced. Operations should not be undertaken to cure conditions which are amenable to less hazardous measures; and when undertaken they should promise the possibility of relief, and the hazard should not be unduly out of proportion to such possibility.

The surgeon should calculate the patient's reserve strength and operate when possible at the propitious time. The emergencies, such as strangulated internal hernia, acute perforation of the intestine or gangrene of the bowel, offer little margin for such calculations. Nor can any of these be diagnosed positively except when exposed to view. On the other hand an infected ovarian cystoma or a bleeding uterine fibroid, which are easily recognized, may require immediate operation, tentative operative relief, or treatment preliminary to a deferred operation. The surgeon must also take into account the relation of the patient's abdominal disease and the operation to disorders of the heart, kidneys and other organs. Arbitrary routine is not desirable; each case should be regarded as peculiar and receive the special consideration which its conditions demand.

Exposure and insult to the peritoneum should be minimized. Operations should be conducted with speed and precision; and for this reason a well-organized operating room with experienced assistants offers the best results.

Discourses to bystanders and audiences are best delivered, not by the operating surgeon but by another surgeon assigned to that special task—preferably an assistant of the operator. If the operator carries on the discourse, an assistant should be performing the operation. For the surgeon to converse and explain to bystanders, thereby delaying his work, is a crime not

forbidden by statute but by a law of higher ethics. Only the competent should be licensed to perform these serious operations; and neither the interest of the surgeon nor that of the bystander should be paramount to that of the unconscious patient.

The **preparation of patients for abdominal operations** is not essentially different from that already described (Vol. I, page 176). Measures to minimize the possibility of vomiting should be taken. The intestine should be well cleaned out by 30 or 60 c.c. (1 or 2 ounces) of castor oil; but the preliminaries should not be so strenuous or extraordinary as to unbalance the patient's physical or mental equipoise (for Preparation for Gastro-intestinal Operations, see page 564). Means for preventing shock should be employed (see Shock, Vol. I, page 213). The legs, arms and thorax should be warmly covered.

Fig. 1172.—Lowered Head, or Elevated Pelvis, Position of Trendelenburg.

The *position for operation* is usually the horizontal dorsal position, but operations should be conducted upon a table which permits either lowering or elevation of the head and chest. The lowered-head position (Trendelenburg) (Fig. 1172) is employed in operations in the lower abdomen and pelvis, in order to permit of easier upward retraction of the intestines to give better exposure of the field of operation. It is much used and greatly facilitates operation. The elevated head position is employed in some cases of operation in the upper abdomen to permit of better downward retraction of the intestines or drainage of the stomach. Either of these positions may be had simply, by elevating one end of the table. The elevated-head position is best secured by the employment of a table capable of producing flexion at the knees. It should be provided with supports to catch the shoulders and prevent slipping of the patient. The legs may or may not be made fast.

The Regions of the Abdomen.—The abdomen is divided arbitrarily by two horizontal and two vertical imaginary lines. The upper horizontal line crosses at the lower part of the tenth costal arch, the lower at the most prominent lateral points of the crests of the ilia. The two vertical lines pass upward from the centre of Poupart's ligament. Antero-posterior planes through these lines divide the abdomen into nine arbitrary regions. The contents of these regions vary greatly, but they will be given as commonly found.

The *right hypochondriac* region: most of the right lobe of the liver, hepatic flexure of colon, and part of right kidney. *Epigastric:* the left lobe of the liver, part of right lobe of

liver, gall-bladder, part of stomach, pyloric and cardiac openings of stomach, first and second parts of duodenum, duodenojejunal junction, most of the pancreas, upper and inner part of the spleen, upper and inner part of both kidneys, suprarenal bodies. *Left hypochondriac:* part of stomach, most of the spleen, tail of the pancreas, splenic flexure of colon, part of left kidney, and sometimes extreme left end of left lobe of liver. *Right lumbar:* ascending colon, part of right kidney, and sometimes part of ileum. *Umbilical:* most of transverse colon, third part of duodenum, parts of coils of jejunum and ileum, part of mesentery, part of great omentum, part of right kidney, and sometimes part of

Fig. 1173.—Regions of the Abdomen According to the Old Nomenclature.

left kidney. *Left lumbar:* descending colon, part of jejunum, and sometimes part of left kidney. *Right iliac:* cecum, vermiform appendix, end of ileum. *Hypogastric:* loop of sigmoid, upper part of rectum, convolutions of ileum, part of bladder in children, and part of distended bladder in adults. *Left iliac:* sigmoid colon, and parts of coils of jejunum and ileum (Fig. 1173).

The B.N.A. commission divided the abdomen into regions according to the natural lines. All of the lines are curved (Fig. 1174).

Structures of Abdominal Wall.—The *anterior wall* is composed of skin, superficial and deep layers of superficial fascia, areolar connective tissue overlying external oblique muscle,

external oblique muscle and its aponeurosis, internal oblique muscle and its aponeurosis, transversalis muscle and its aponeurosis, rectus muscle, pyramidalis muscle, transversalis fascia, extraperitoneal areolar connective tissue, peritoneum (Figs. 1175 and 1176).

The *posterior wall* is composed of five lumbar vertebræ and their intervertebral disks, posterolateral parts of the ilia, and the following soft structures: skin, superficial fascia, posterior layer of the lumbar fascia, erector spinæ muscle, middle layer of lumbar fascia attached to transverse processes, quadratus lumborum muscle, anterior layer of lumbar fascia, psoas muscle, crura of diaphragm, kidneys, areolar connective tissue, colon, extraperitoneal connective tissue, peritoneum (Fig. 1177).

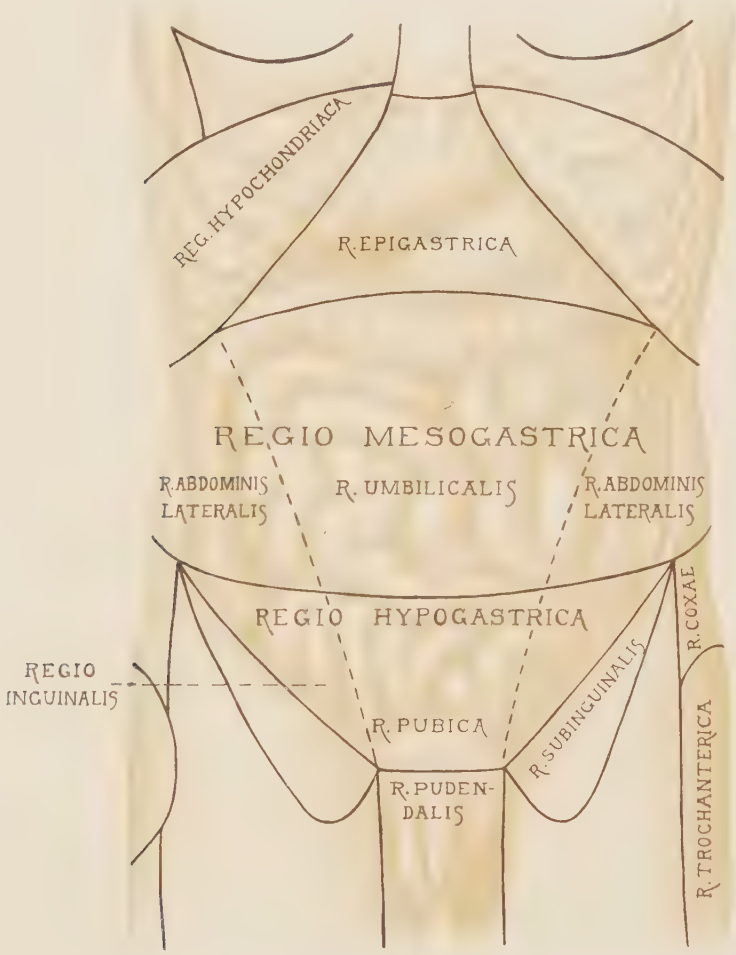

FIG. 1174.—REGIONS OF THE ABDOMEN ACCORDING TO BNA (BASLE NOMINA ANATOMICA).

The *blood-supply* of the abdominal wall is through the superior epigastric and musculophrenic from the internal mammary artery; lowest two intercostals from the thoracic aorta; abdominal branches of lumbar arteries from abdominal aorta; iliolumbar from internal iliac artery; deep circumflex iliac and deep epigastric from external iliac artery; and superficial epigastric, superficial circumflex iliac, and superficial external pudic from the femoral artery. The veins accompany the arteries. There is a plexus of veins in the lower suprapubic region and in front of the inguinal canal.

The *nerve supply* of the anterolateral wall is largely through the lower intercostal nerves. These nerves emerge from the intercostal spaces and pass in a general direction forward and

inward and downward between the internal oblique and transversalis. They penetrate the outer edge of the sheath of the rectus to supply that muscle. Thence they traverse the substance of the muscle, pass through its anterior sheath and supply the skin. The twelfth intercostal nerve passes along the lower border of the twelfth rib in front of the quadratus

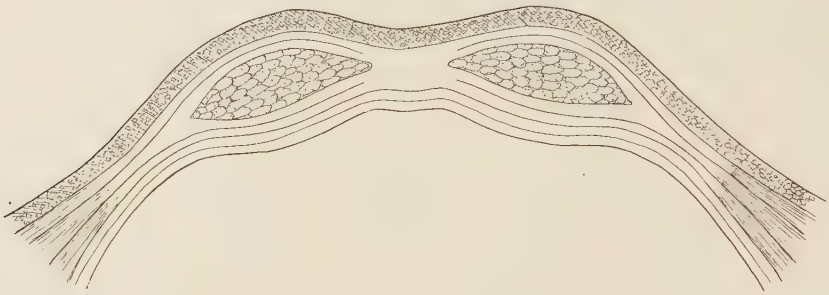

Fig. 1175.—Diagram of Transverse Section of Anterior Abdominal Wall above the Semilunar Fold of Douglas.

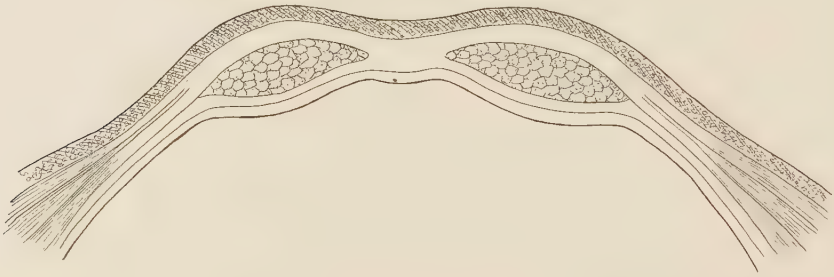

Fig. 1176.—Diagram of Transverse Section of Anterior Abdominal Wall below the Fold of Douglas.

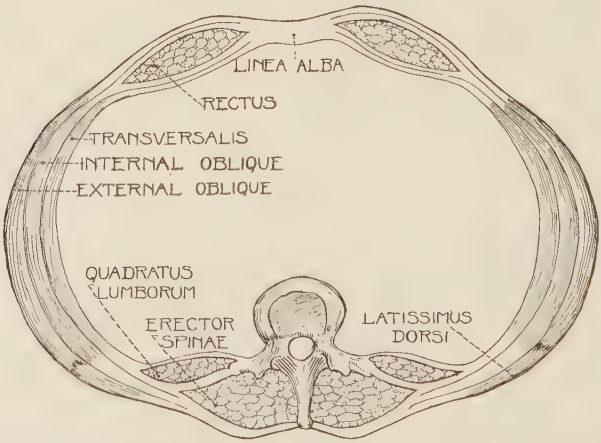

Fig. 1177.—Diagram of Transverse Section of Wall of Abdomen in Midlumbar Region.

lumborum and between the internal oblique and transversalis. Its anterior branch penetrates the rectus and supplies the skin of the suprapubic region.

The iliohypogastric branch of the first lumbar runs along the crest of the ilium, pierces the transversalis, and divides between the transversalis and internal oblique, about 6.5 cm. (2½ inches) posterior to the anterior-superior spine into the hypogastric branch and the

iliac branch. The hypogastric branch passes forward between the internal oblique and transversalis, pierces the internal oblique, then the aponeurosis of the external oblique about 2.5 cm. (1 inch) above the external abdominal ring and just to its outer side, and is distributed to the skin of the hypogastrium and region of the external inguinal ring. Anesthetization of this nerve is easily accomplished for operations in the groin.

The ilio-inguinal branch of the first lumbar nerve passes from the outer border of the psoas and thence just below the iliohypogastric. It penetrates the transversalis near the anterior superior spine of the ilium, passes forward between the transversalis and the internal oblique, and pierces the latter just internal to the anterior superior spine. It passes inward behind the aponeurosis of the external oblique to the spermatic cord, which it accompanies through the inguinal canal. Emerging at the external ring, it supplies the skin of the upper and inner part of the thigh and the scrotum or labium (see Hernia).

Landmarks.—The *sheath of the rectus muscle* is peculiar. Above, the *anterior sheath* is formed by the union of the aponeuroses of the external oblique and anterior layer of that of the internal oblique. Below, the anterior sheath is formed by the union of the aponeuroses of the external oblique, internal oblique, and transversalis.

Above, the *posterior sheath* is formed by the union of the posterior layer of the aponeurosis of the internal oblique and the aponeurosis of the transversalis. Behind these come the transversalis fascia, extraperitoneal connective tissue, and parietal peritoneum. Below the semilunar *fold of Douglas*, the transversalis fascia is the only fascia passing posterior to the muscle. This fold is at the junction of the upper three-fourths and the lower fourth of the recti muscles, about 3 cm. (1¼ inches) below the umbilicus.

The *linea alba* extends from the ensiform cartilage to the symphysis pubis, and is formed by the blending of the aponeuroses of the muscles of the anterior abdominal wall. It is broad above and narrow below. Below the fold of Douglas it is not distinct, and the two recti lie close together. It is most marked just above the umbilicus.

The *umbilicus* is in the median line 2 to 2.5 cm. (¾ to 1 inch) above the highest points of the crests of the ilia. It is about 2 cm. (¾ inch) above the *bifurcation of the aorta*, opposite the tip of the spine of the third lumbar vertebra or the intervertebral disk between the third and fourth lumbar vertebræ. The *celiac axis* is 10 to 12.5 cm. (4 to 5 inches) above the umbilicus. The *renal arteries* arise 7.5 to 10 cm. (3 to 4 inches) above the umbilicus. At the umbilicus only a thin layer of connective tissue separates the peritoneum from the skin. When operating through it or around it, it is well to excise it completely to prevent hernia—excepting in young women to whom it possesses a cosmetic advantage. To avoid the round ligament, the incision should be on the left side.

Fig. 1178.—Diagram of Median Section of the Female Body, Showing Extent and Complexities of the Peritoneum.

The *lineæ semilunares* are formed by the blending of the abdominal aponeuroses, and are bounded internally by the outer borders of the recti muscles. They extend from the seventh costal cartilages to the pubic spines. At the level of the umbilicus they are from 13 to 15 cm. (5 to 6 inches) apart.

The *lineæ transversæ* are tendinous intersections in the substance of the recti muscles. There are usually three. The lowest is at the umbilicus.

The *inguinal landmarks* are especially important for hernia (*q.v.*). The spine of the os pubis is nearly on the same level with the top of the great trochanter. It may be found by following up the adductor longus muscle. The inner pillar of the external ring is attached to it. *Poupart's ligament* represents the lower border of the external oblique muscle and the conjoined fasciæ. It curves slightly downward and connects the anterior-superior spine of the ilium and the pubic spine. The *internal abdominal ring* is situated 1.3 cm. (½ inch) above the centre of Poupart's ligament. The *external abdominal ring* is situated above the extreme inner end of Poupart's ligament. It is just above and external to the crest of the pubic bone.

The *external oblique muscle* becomes aponeurotic anteriorly at a line passing from the anterior limit of the ninth costal cartilage to the anterior superior spine of the ilium. The lower limit of the fleshy part of the muscle is represented by a line drawn transversely between the points on the iliac crests 2.5 or 5 cm. (1 or 2 inches) behind the anterior superior spine. The fibres of the muscle and its aponeurosis run at right angles to a line connecting the anterior superior spine and the umbilicus.

The *internal oblique muscle* runs upward and inward. Above, it becomes aponeurotic at a line passing from the tip of the twelfth rib upward and inward parallel with the costal border; internally, it becomes aponeurotic at a line extending from the middle of Poupart's ligament upward and slightly outward.

The *transversalis muscle* passes to the linea semilunaris further inward above and below than at the midabdomen. It is further described under hernia.

The *peritoneum* is the serous membrane which partly covers the viscera within the abdomen and lines the abdominal walls. It may be thought of as constituting a complicated sac. It communicates with the outer world by the Fallopian tubes. Covering the intestine, it must needs have a large area (Fig. 1178).

ABDOMINAL SECTION

Instruments used in abdominal operations are: scalpels; scissors, straight, curved, pointed, blunt; anatomic forceps; mouse-tooth forceps; hemostats; hooked retractors; smooth retractors; abdominal retractors; sponge holders; ligature carrier; needles, curved and straight; needle holder; long forceps; tenaculum; intestinal clamps; catgut, plain and chromicized; silk; silkworm-gut; gauze pads; gauze sponges; gauze packing; drainage tubes. Besides the ordinary retractors, self-retaining abdominal retractors are useful (see Instruments).

Opening the abdomen for exposure of the abdominal contents, is performed in whatever region required. The nearer the incision is to the middle line, the greater the number of viscera that can be reached. In general, incisions should be made so as to give the best possible access through the smallest opening. For most operations an incision should be from 5 to 9 cm. (2 to 3½ inches) long. Larger openings are often required; smaller, rarely. A 5-cm. (2-inch) incision heals as quickly as a 2.5-cm. (1-inch) incision, and permits better access. When not otherwise undesirable the skin incision should be in the general direction of the nerves and vessels. The incision through fascia should preferably be in the direction of its fibers. Openings through muscle should be made by separating the fibers of the muscle by blunt dissection. This is done with the handle of the scalpel. In many situations it is possible to uncover the muscle to its edge, and then retract it without penetrating its substance. When necessary, muscles may be cut across their fibers; but when this is done, it is most desirable to sew together the rent at the close of the operation. Motor nerves should be spared. They will often be seen traversing the muscle where they may be isolated and retracted.

Hernia is least apt to occur in wounds which are closed in such a way as to restore the structures of the abdominal wall to their natural relations. A wound is strongly protected against hernia if the openings through the several structures are made at different lateral planes, with strong muscle intervening. The muscle and deep fascia are the main protection. Incisions should preferably not be made through the umbilicus but to the left side. An absolutely median incision is rarely made. The so-called median incisions are made slightly to the side of the middle line (Fig. 1179).

Incisions for Opening the Abdomen.—The *median postmuscular incision* has the widest range of usefulness. It has the merit of dividing no motor nerves or muscles; it is in the thinnest part of the abdominal wall; and by making the openings of the deep fascia at one side of the median line and retracting the rectus muscle outward, strong muscular protection is secured (Fig. 1180). The median incision when carried alongside of the ensiform cartilage, should be made with care lest the pleura be opened.

Each structure should be identified and cleanly incised, step-by-step—skin, superficial fascia, deep fascia, muscle, deep layer of deep fascia (trans-

versalis fascia) and peritoneum. A connective-tissue layer with more or less fat lies between the deep connective tissue and the peritoneum. It is quite thick in the upper and lower parts of the median region. Behind the rectus muscle below the level of the umbilicus it is almost absent, and the peritoneum and fascia lie in close contact. When this connective-tissue layer is absent, the peritoneum is divided with the fascia. The transversalis fascia should not be confused with extraperitoneal connective tissue.

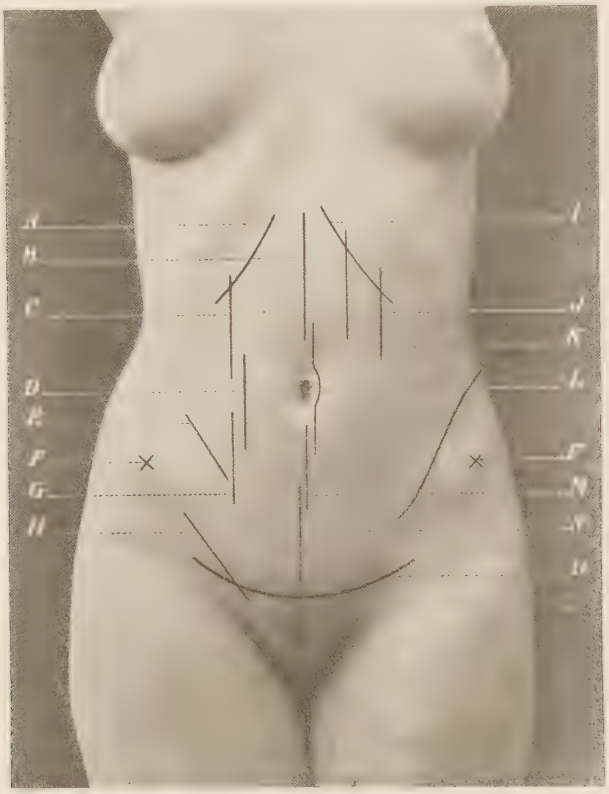

FIG. 1179.—ABDOMINAL INCISIONS.

A, Oblique subcostal for liver and gall-bladder; *B*, median for stomach, and liver; *C*, vertical subcostal for gall-bladder; *D*, right abdominal through rectus; *E*, right oblique for appendix; *F*, anterior superior spine of ilium; *G*, right vertical external to rectus; *H*, oblique inguinal for hernia and exposure of iliac vessels; *I*, left oblique subcostal; *J*, left vertical subcostal for cardiac end of stomach; *K*, left subcostal external to rectus for spleen; *L*, median midabdominal; *M*, infraumbilical midabdominal; *N*, vertical median suprapubic; *O*, suprapubic transverse curved. The costal arch in this picture should be just above the lines *A* and *I* as these incisions are to be placed just below and parallel with the costal border.

The peritoneum should not be mistaken for intestine. If intestine is wounded, it should at once receive the necessary attention (page 628). Extraperitoneal connective tissue should not be confused with omentum. The peritoneum is opened by picking it up with two pairs of forceps, to hold it away from the viscera, and making a small opening between (Fig. 1181). The two edges of the wound are held open by forceps, a finger or other pro-

tector slid beneath the peritoneum, and the opening enlarged with scissors to the desired extent. Before opening the peritoneum all bleeding should have been controlled and clamps removed. There are no vessles of consequence in the anterior abdominal wall.

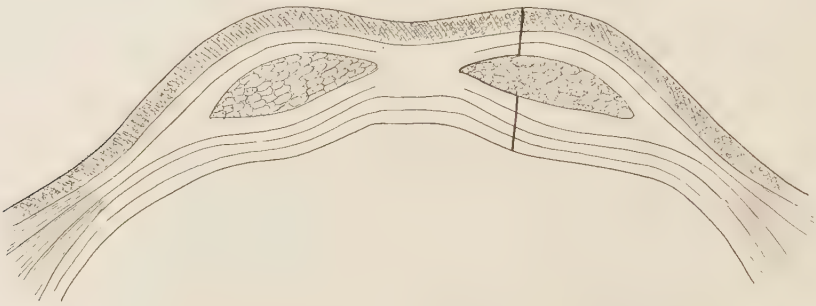

Fig. 1180.—Postmuscular Median Incision.
Showing path of entrance to abdomen. The rectus is retracted outward as soon as it is exposed by the anterior incision.

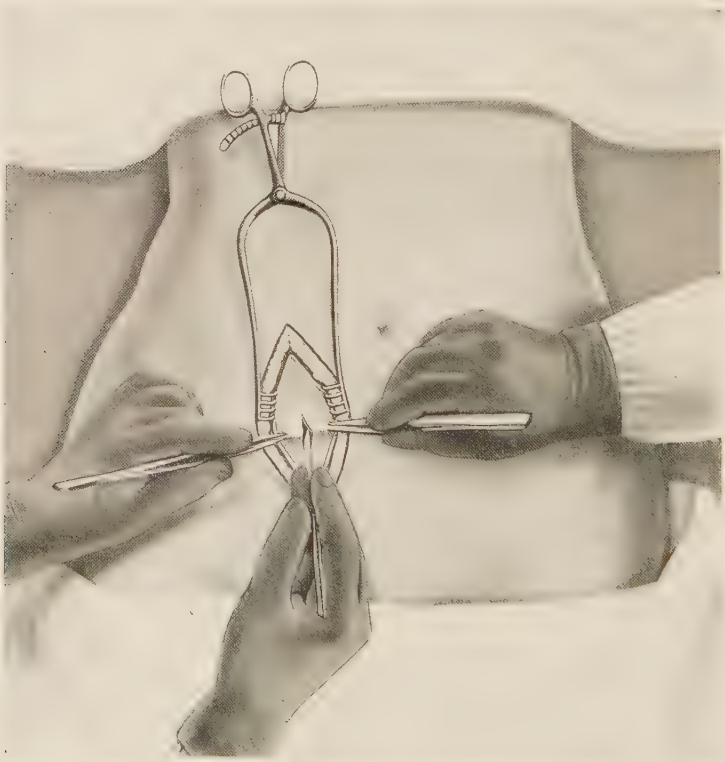

Fig. 1181.—Method of Opening the Peritoneum.
The skin is shown uncovered to demonstrate location of wound.

The *median intramuscular incision*, which passes directly down between the fibers of the rectus muscle, divides the motor nerve and paralyzes a part of the muscle internal to the incision. In dealing with the oblique muscles it

should be noted that the nerves are not parallel with the fibres of the external oblique but run somewhat more transversely. Incisions through the skin may be made as long as desired and in any direction without regard to the nerves. The same may be said of the fascia lying on the muscles.

Median incisions are used for parts most easily available thereby. Above the umbilicus they are used to expose the stomach, liver, pancreas and intestines. They should be made preferably through the fascia external to the inner edge of the rectus.

Lateral vertical incisions along the outer border of the rectus are so apt to damage the motor supply of the rectus as to be decidedly objectionable. They are used for the gall-bladder, bile ducts, liver, duodenum, spleen, kidneys, ascending and descending colon.

Lateral muscle-splitting incisions are made by separating the fibres of muscles, one after another, identifying and protecting the nerves especially between the transversalis and internal oblique, and holding the muscles

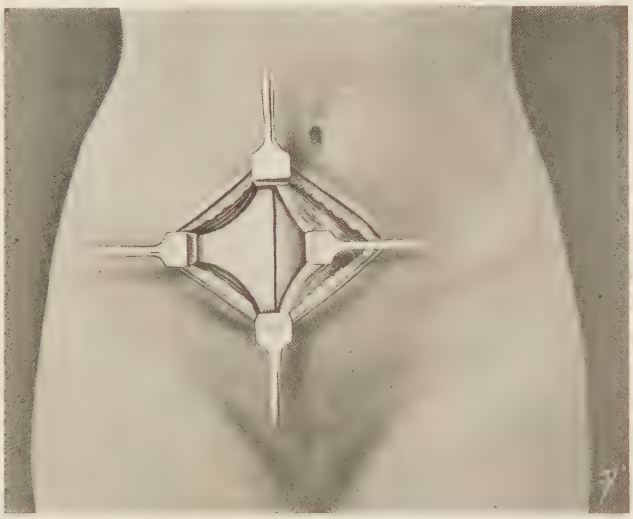

Fig. 1182.—Transverse Superficial and Vertical Deep Incisions.
The rectus muscle is drawn inward, the oblique and transversalis muscles are split and retracted, and the transversalis fascia and peritoneum are incised vertically.

apart while the transversalis fascia and peritoneum are incised and the operation performed. They are used to expose the lateral parts of the abdomen.

Transverse incisions combine the above. Usually they are transverse through the skin and superficial fascia only. Such incisions are used in some instances to obviate the vertical scar. For cosmetic purposes it is possible to place the incision largely within the area of the pubic hair. It may also be placed in the transverse suprapubic crease which is present in the fat abdomen. The incision is carried through the skin and fascia down to the superficial layer of the deep fascia lying upon the muscles. Vertical retraction is then made and the superficial fascia dissected free from the deep fascia as far as is necessary to make room for the vertical incision through the rest of the abdominal wall.

Any modification of this principle may be applied. It simply means that the opening through the deeper abdominal structures need not be made

in the same line as the opening through the skin. Access to all parts of the abdomen may be by this method (Fig. 1182).

Another principle in the application of the transverse incision consists in making the whole opening through the abdominal wall in the transverse direction. For example, for the freest possible access to the stomach, an incision is carried across just above the umbilicus. It may be 15 or 18 cm. (6 or 7 inches) long, or even longer, and passes down to the muscles. A median opening is then made and the finger inserted into the abdomen. At this juncture W. Meyer (Annals of Surg., November, 1915) separated the deep from the superficial fascia for a short distance, and with a curved needle

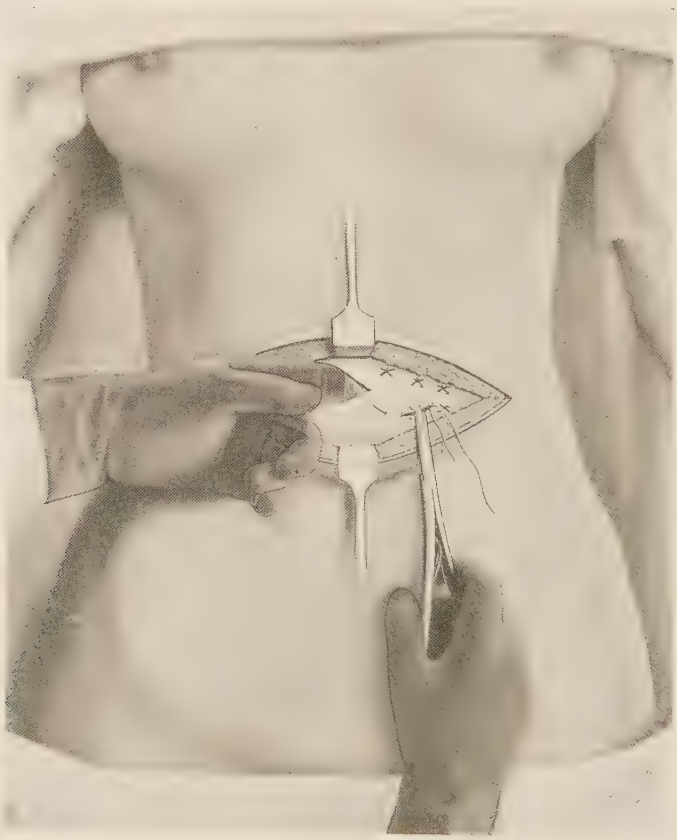

Fig. 1183.—Transverse Abdominal Incision.
Fixing rectus muscle to its sheath after method of W. Meyer.

passed three catgut sutures through each rectus muscle, above and below the proposed place of division, fixing the muscle to its sheath (Fig. 1183). Each of these sutures passes down to but not through the peritoneum. When they have been tied, the incision is carried down transversely through the bellies of the recti and through the peritoneum (Fig. 1184). These sutures prevent retraction of the muscle, and make later suturing easy.

The transverse incision may always be modified to suit other conditions. The above-described division of the recti may be used to involve only one

rectus muscle. It may be modified by continuing another incision upward, downward, or obliquely from either of its extremities.

If the rectus muscle has been divided, it is easily sutured with chromicized catgut. A continuous suture is used to unite the peritoneum and transversalis fascia. A second continuous suture unites the divided muscle and catches the anterior sheath. The skin and superficial fascia are united as usual. Such an incision as this does not damage the nerve supply, it gives remarkably free access, and when the wound is properly closed is capable of restoring a firm abdominal wall.

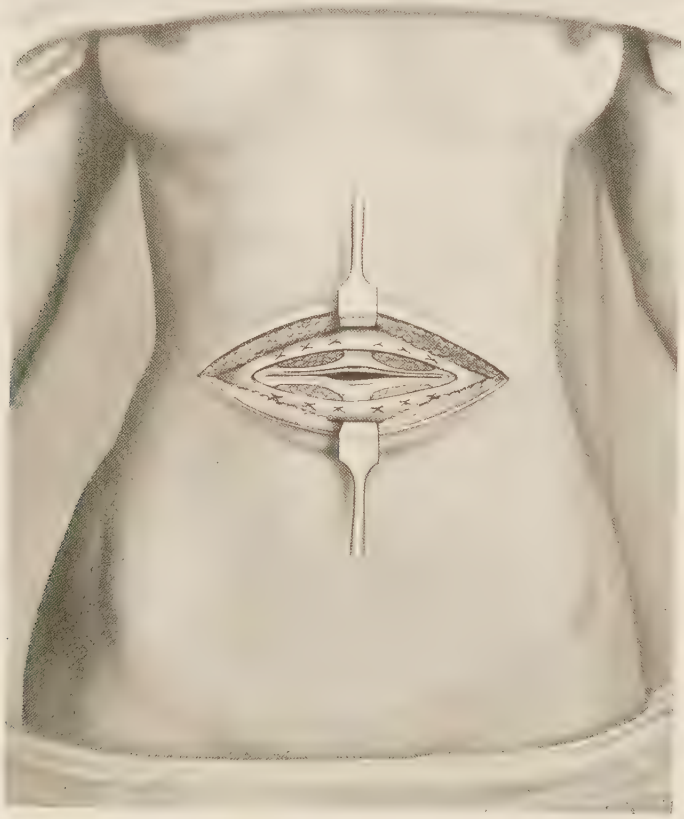

FIG. 1184.—TRANSVERSE ABDOMINAL INCISION.
The rectus, having been fastened to its sheath by two rows of sutures, is divided after method of W. Meyer. The incision passes through the peritoneum.

The neatest incision for hiding the scar is 10 or 13 cm. (4 or 5 inches) long, curved with its convexity downward, all within the pubic hair area. This incision is made in such a way that the edge of the skin flap is very thin, little more than a skin graft for a width of 1 or 2 cm. (½ or ¾ inch). By passing obliquely through the superficial fascia, the anterior sheath of the muscles is exposed 2.5 to 5 cm. (1 or 2 inches) above the pubes. The superficial fascia is dissected upward and retracted. The fascia in front of the recti is divided transversely. From the ends of this latter incision, incisions

are carried upward and outward between the fibers of the external oblique if it is desired to make a lateral opening. The fibers of the internal oblique are similarly separated. If only lateral access is desired, but one of these oblique incisions is made. The recti muscles may be isolated for a distance of 10 or 13 cm. (4 or 5 inches), strongly retracted outward and the peritoneum opened vertically in the median line. For a lateral opening one rectus should be retracted toward the median line.

Transverse postmuscular incisions may be used in connection especially with the rectus muscle. The muscle is exposed by a vertical or oblique incision which passes through its anterior sheath. The muscle is than retracted inward, and the posterior sheath, transversalis fascia, and peritoneum divided transversely. This incision may be used for access to the vermiform appendix. In closing, the structures behind the muscle are sutured; the muscle is then allowed to return to its position; and the anterior structures sewed. This is the most effective entrance to the abdomen for preventing postoperative hernia (see Appendicitis, Vol. III).

Combined incisions may involve any of the above described methods. A very useful incision is the *flap incision.* This consists of a transverse cut and a vertical cut or an oblique and a vertical cut. If the former is made through the external oblique and the latter passes down along the outer border of the rectus muscle a flap is formed which may be turned back and give wide exposure of the lateral regions of the abdomen. When free exposure of the sigmoid or cecum is desired, a transverse incision passing inward and ending at the outer border of the rectus muscle and then continuing downward just external to the rectus permits turning back a triangular flap which gives larger access than can be secured by a single linear incision.

Median Abdominal Section.—The incision may be made anywhere between the ensiform cartilage and the symphysis pubis. If not enough room is secured by the original incision, it may be continued above or below. Within 5 cm. (2 inches) above the pubes, the bladder should always be had in mind. At the umbilicus, the incision should pass preferably to the left to avoid the round ligament of the liver.

In the upper three-fourths of the linea alba, where the recti muscles are somewhat separated, the peritoneum is reached through an incision between the two muscles. If the incision need not be in the middle line, it is best to incise the anterior sheath of the rectus at one or the other sides. The edge of the belly of the muscle is then retracted outward and the aponeurosis, composed of its posterior sheath and transversalis fascia incised. The abdomen is then entered behind the muscle; and when the wound is closed, it is strengthened by the muscle lying over it. If the incision is made in the lower fourth of the abdomen, it may be made between the two recti; but, after passing through the skin and subcutaneous fat, it is preferable to incise the anterior sheath of one or the other recti, about 1.3 or 2.5 cm. (½ or 1 inch) from the border of the muscle. The pyramidalis and rectus are then retracted outward and the abdomen entered behind the muscles. The wound is closed as already described.

Ilio-inguinal Abdominal Section (McBurney's Intramuscular Gridiron Incision).—Incisions in the iliac and inguinal regions for opening the abdomen may best be made to follow the general direction of the fibers of the external oblique muscle. This is the operation best adapted for *exposure of the cecum and vermiform appendix.* A point midway between the anterior superior spine of the ilium and the umbilicus is located. This is the so-called *McBurney's point.* An incision is made about 7.5 cm. (3 inches)

long, from above downward and inward, at an angle of 45 degrees from the perpendicular, having its center a little external to McBurney's point.

Having incised the skin and superficial fascia, the external oblique muscle is exposed and its sheath incised in the line with its fibers. The fibers are then separated bluntly and the separation is continued if necessary below into its aponeurosis by retracting the outer edge of the rectus inward. The opening between the fibers of the external oblique is then retracted at right angles to the incision with curved retractors; and the internal oblique exposed. The sheath of the latter muscle is divided in the line with its fibers which is at about a right angle to that of the external oblique. The fibers are separated similarly by blunt dissection and an occasional incision. This separation is about in the line toward the unbilicus and anterior superior spine, and the opening in the muscle is retracted at right angles to the retraction of the external oblique. The fascia lying in front of the transversalis muscle is exposed. The nerves lying between the internal oblique and the transversalis should be looked for and protected from injury.

The fibers of the transversalis pass more nearly in the direction of the internal oblique. They should be separated in the line of their cleavage. They may be held apart by the retractors which hold the internal oblique. The transversalis fascia is exposed at the bottom of the wound, becoming continuous with the aponeurosis into which the muscle is inserted internally. It is picked up and incised transversely in the line with the muscle fibers, exposing the extraperitoneal connective tissue. The peritoneum is then picked up and incised in the same direction.

In closing this wound, a separate suture of the peritoneum is made with catgut. The transversalis fascia is closed with a continuous suture of chromic catgut tied at frequent intervals. The transversalis muscle need not be sutured. The internal oblique and the external oblique may be sutured with fine running catgut. The subcutaneous fascia, if thick, should be similarly sutured; and a subcuticular suture applied to the skin.

This represents the ideal approach to the abdomen. Hernia does not occur when primary union is secured. If drainage is used the peritoneum is sutured down to the drain, likewise the fascia, muscles, and skin, when the drain is removed, all of these tend to close the wound; and, if muscle or nerve have not been cut, the danger of hernia is slight. The incision may be made longer or shorter; and the operation may be done at a higher or lower plane than here described.

This wound may be enlarged externally by further separation of muscle fibers and retraction. It may be enlarged internally by incising the sheaths of the rectus muscle and retracting the muscle inward.

Oblique Postmuscular Abdominal Section.—This operation may be carried out as a continuation of the above operation by carrying the incision still further inward and downward. This is done when it is desired to make a more internal exposure. The separation of the fibers of the external oblique, its aponeurosis, the internal oblique, and the transversalis is continued as far as the outer border of the rectus. The fascia of the external oblique, already opened with the muscle as far as the rectus, is separated by blunt dissection from the anterior sheath of the rectus and incised as far as necessary. This opening may be carried to the median line if desired, and the split fascia retracted. The anterior sheath of the rectus, thus exposed, is incised in the same direction; although the incision may be made transverse or even more oblique, if desired. The rectus is then retracted inward by a retractor applied to its outer border, while it is bluntly separated from its

posterior sheath which consists in the lower abdomen of transversalis fascia. The deep epigastric artery and vein are exposed, lying upon the posterior sheath of the rectus. They may be ligated in two places and cut between or retracted inwardly with the muscle. The transversalis fascia and peritoneum are then incised in the same line, and the operation proceeded with. The wound is closed after the method above described. After suturing the peritoneum and transversalis fascia the rectus is allowed to spring back into place, and its anterior sheath sutured. This latter suture may include also the fascia of the external oblique. This operation may be done through a small incision, if desired, having its center at the outer border of the rectus.

Vertical Postmuscular Abdominal Section.—This operation is not unlike the modified median section. It may be used in any part of the rectus muscle. A vertical incision is made about 6.5 to 10 cm. (2½ to 4 inches) long and about 2.5 cm. (1 inch) internal to the outer border of the rectus. The anterior sheath of the rectus is exposed and incised vertically in the

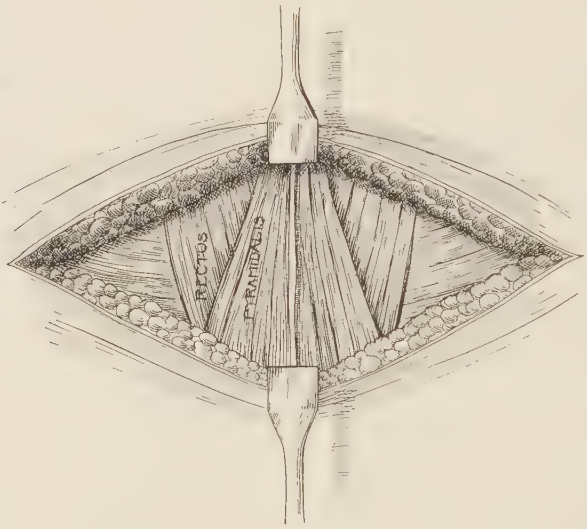

Fig. 1185.—Transverse Incision.
The pyramidalis and recti are exposed.

same line. The outer lip of the rectal sheath is retracted outward until the outer edge of the muscle is exposed. This edge of the muscle is then retracted inward, being bluntly separated from its posterior sheath. This exposes the posterior sheath of the muscle which should be incised vertically. In the lower fourth of the muscle the posterior sheath consists of transversalis fascia, and the deep epigastric vessels lie upon it. These vessels should be ligated or retracted. The peritoneum is then incised, and the operation proceeded with. In closing the wound the peritoneum is sutured separately; the transversalis and posterior sheath of the rectus are firmly sutured with a continuous frequently interrupted suture of chromicized catgut; if the muscle does not readily spring back into place, it should be sutured to the outer part of its sheath; the anterior sheath is closed with a running suture of catgut; and the fascia and skin as above described. The objection to this operation is that some of the nerves to the rectus are destroyed and the muscle weakened at the point where it is important that it should be strong.

For this reason, the oblique operations or the median operations which retract the muscle outward are to be preferred.

Low Median Abdominal Section by the Superficial Transverse Incision.—This incision is of especial value for exposing the lower abdominal structures such as the rectum, bladder, uterus, tubes, ovaries, and broad ligaments. It gives ample exposure because the muscle is easily retracted when the fascia is divided, the obstacle to lateral retraction in vertical operations being the fascia and not the muscle. The scar is largely concealed by the pubic hair. The nourishment of the wound is better than in median sections. A large ellipse of fat may be removed from the obese abdomen. The incision is not to be preferred to the vertical incision in infected cases. The bladder must be looked out for.

The superficial incision is placed transversely, with a downward convexity, and passes just above the pubic bone, and the inner halves of Poupart's ligaments. It traverses the area of the pubic hair, and begins and

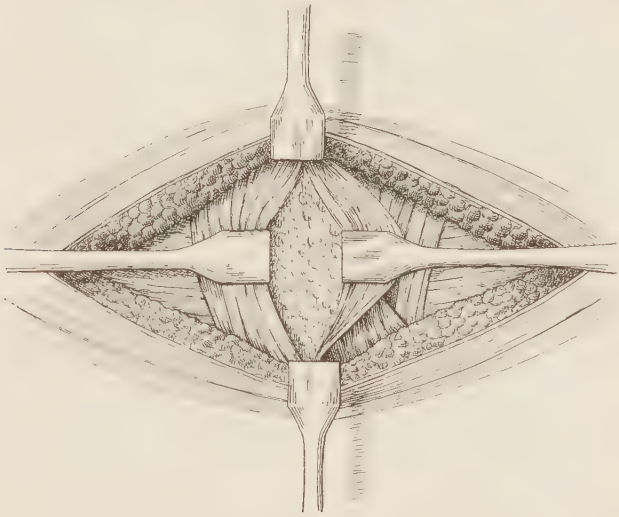

Fig. 1186.—Retraction of Pyramidales and Recti to Make a Median Opening between the Muscles.

ends at the deep epigastric vessels. The transverse incision divides the skin, superficial fascia, and anterior sheath of the two recti muscles. Vessels are ligated. All of these structures are dissected free from the muscle and linea alba and retracted upward (Fig. 1185). The pyramidalis of one side is retracted and a median vertical opening into the abdomen is then made between the two recti just above the symphysis pubis. Upward and lateral retraction then permits of a very satisfactory exposure of the lower abdomen (Fig. 1186). The opening is closed, when the operation is completed, by layer sutures. A continuous suture of chromicized catgut is used for peritoneum and fascia forming the posterior sheath of the rectus muscle. The two recti are approximated with a few sutures of catgut. The transverse openings in the anterior sheaths are sutured with a continuous suture of fine chromicized catgut; and the superficial fascia and skin with buried sutures.

Oblique Subcostal Abdominal Section.—This operation is through an incision parallel to the costochondral margin. It is used *to expose the gall-bladder* and liver on the right side, the left lobe of the liver, cardiac end

of stomach and splenic regions on the left side. The incision is made about 2.5 cm. (1 inch) from the costal arch on one side. The center of the incision should be opposite the object of attack. Its length depends upon the demands of the case. The skin and superficial fascia are incised. The external oblique is exposed and its fibers (aponeurotic above and muscular below) are divided in the line of the skin incision. The wound is retracted, the internal oblique exposed, and its fibers separated by blunt dissection. This may be done external to the rectus, if the operation is not done too high. The transversalis is incised the same as the external oblique. Trans-

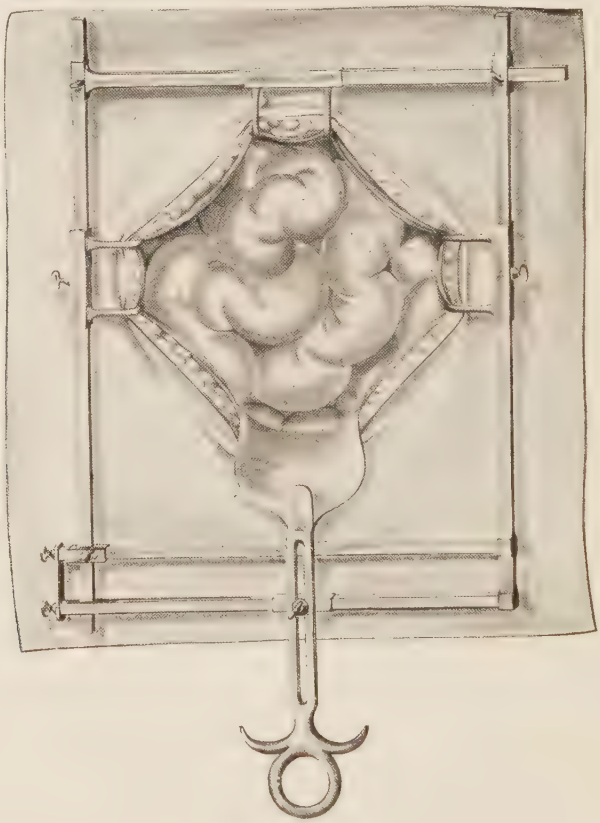

Fig. 1187.—Quadruple Abdominal Retractor.
A sheet of rubber protective is shown covering the skin around the wound.

versalis fascia and peritoneum are incised in the same line. After the completion of the operation, the peritoneum and transversalis fascia are sutured with a running chromicized catgut suture. The divided transversalis and oblique muscles are sutured with interrupted sutures of the same material. The external oblique, fascia and skin may all be included in sutures of silkworm-gut or silk.

If this incision is made so high that the rectus is involved, it is a simple matter to incise its anterior sheath, retract the muscle inward, and continue the incision through its posterior sheath and the peritoneum (for other incisions for exposing the subcostal abdominal structures see Operations on the Bile Tract, Vol. III).

Retraction, after opening the abdomen, is best done by smooth short-bladed retractors (see Retractors). The intestines are kept out of the way by laying flat pads under these. The self-retaining double retractor saves at least two hands, and the quadruple retractor takes the place of four (Fig. 1187). Intestines should not be pinched between retractor and abdominal wall. R. L. Dickinson (Jour. Obst. and Gyn. British Emp., September, 1913) devised a retractor of soft rubber (shield retractor). This consists of rather stiff rubber, held open in a circle by two springs, one of which is within the abdomen the other without (Fig. 1188).

Sponging in abdominal operations should be done only with sponges which are under numerical control. Gauze is the best material. It may be used dry, but is best moistened with salt solution. It should be free from lint and loose threads. Flat sponges (see Vol. I, page 42) are used for keeping coils of intestine out of the way and covered. Such sponges should be used wet and warm. To prevent the irritation which produces adhesions, rubber tissue should be interposed between the gauze and peritoneum (see



Fig. 1188.—Rubber Retractor.
Device of Dickinson shown in position in median abdominal wound.

page 521). Flat sponges may be used for blood. Sponges on clamps are employed where frequent sponging in deep cavities is required.

Protection of peritoneum from every unnecessary insult is imperative. This is accomplished by doing no more than is necessary, by gentle handling of all peritoneum-covered surfaces and by keeping the peritoneum warm. Coils of intestine coming in the field of operation should be pressed back and held covered with warm pads. The flat laparotomy pads or small towels, wrung out in hot water, are best. The experienced surgeon is able soon to wall off the rest of the abdomen and leave exposed only the site of operative attack. Minimized peritoneal irritation is the key to the *prevention of adhesions.*

The **control of bleeding** is best accomplished by clamping and ligating, if necessary, every bleeding vessel. Capillary oozing is checked by pressure with a gauze tampon.

The **toilet of the peritoneum** consists in arranging the viscera in their natural positions and removing foreign material before closing the abdomen. The great omentum should finally be spread in place. The surgeon should be sure that bleeding has been arrested. Blood and other fluid should be removed, especially from pockets such as the prerectal cul-de-sac, and

among the coils of intestines, and in the flanks. If the peritoneum has been much soiled with material which cannot easily be sponged away, a general flushing out with warm salt solution is indicated. Blood clots, bits of gauze, sponges, or instruments should not be left.

The accident of **leaving instruments in the abdomen** is best prevented by careful accounting for all materials used. Before the peritoneum is closed, the nurse should have received back and counted all sponges and instruments that were employed in the wound. A deliberate and systematically carried out operation, rather than a confused procedure, is free from these accidents. Few instruments and no outside distractions characterize good surgery.

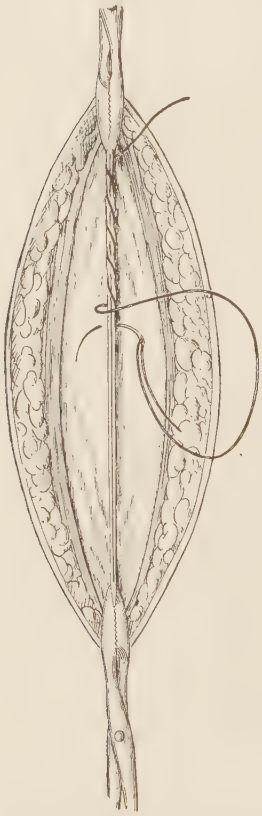

FIG. 1189.—SEWING THE PERITONEUM.

The peritoneum is grasped by two clamps in such a manner that the serous surfaces are opposed, it is lifted forward to make a fold, and the needle is rapidly passed through the two sides of the wound.

Closure of the abdominal wound should preferably be by approximation, layer to layer, of the divided structures, to restore the normal relations. While suturing the peritoneum, a small flat pad should be spread out behind the wound to protect the intestines and prevent them from pressing forward. This is left in place until the closure of the peritoneum is nearly complete when it is withdrawn, and a spatula substituted for it. The suturing of the peritoneum is facilitated by catching its edges with clamps. These may be lifted forward by an assistant while the surgeon applies the suture (Fig. 1189).

For closing the peritoneum the best material is fairly fine chromicized catgut. If it is desired to save the time required for tying the first knot, the thread may be made double, tied together at the end and when introduced, caught in a loop. A fairly good-sized curved needle is used—held in the fingers if the hand is gloved and the wound not deep, otherwise in a holder. In a thin abdomen a straight needle may be used. A continuous suture is employed. The needle is inserted about 6 mm. (1/4 inch) from the edge. Both ends of the suture should be well secured. Care should be taken that threads of the pad are not caught by the needle or it will be difficult to remove it. After removal of the pad, care must be taken not to wound the intestine or include omentum in the suture.

The second tier of sutures is the most important for securing the strength of the wound. It is the closing of the post-muscular fascia. It involves the extraperitoneal connective tissue, transversalis fascia, and posterior aponeurosis of the muscle (rectal sheath in postrectal incisions). It is the suture most concerned with the prevention of hernia. It is best made with fairly fine chromicized catgut, introduced with a curved needle, about 5 mm. (3/16 inch) from the edge and 1 cm. (3/8 inch) apart. An interrupted suture is used, or a continuous one interrupted every second or third suture. If the apposition is good and infection does not occur, hernia need not be feared. The fascia rapidly heals and becomes as strong as ever. When there is danger of hernia or in cases in which it is especially

desirable to strengthen the abdominal wall, this should be made an overlapping suture. The muscle should not be embraced in this suture.

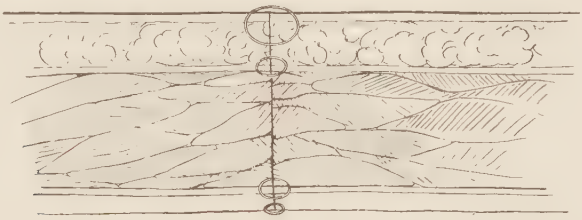

Fig. 1190.—Diagram of Abdominal Wound Completely Sutured in Layers. Peritoneum, transversalis fascia, anterior layer of fascia lata, and skin are each sewed separately.

The third tier of sutures should embrace the anterior sheath of the muscle and the superficial fascia with its areolar tissue and fat. If the fat layer is very thick an extra subcutaneous suture should be used. These are running sutures of fine chromicized catgut, and are intended to close all open spaces.

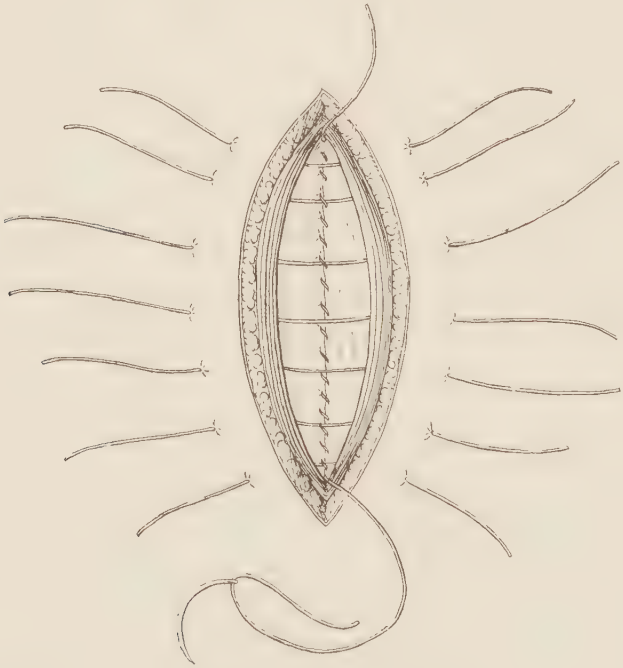

Fig. 1191.—Closure of Abdominal Wound with Continuous and Interrupted Sutures in Muscle-splitting Operation.

The peritoneum has been sewed with a continuous suture, which is brought out at the end of the wound, and deep interrupted sutures of silkworm gut have been introduced through all the structures except the peritoneum. The continuous suture is next to be taken in hand and used to sew the anterior sheath of the muscles. The interrupted sutures are finally to be tied over the skin. For the sake of better apposition a fine running suture of silk may be applied to the skin edges.

The fourth tier of sutures closes the skin. A subcuticular suture of paraffined linen, silk, chromicized catgut, or other material, is used. An ordinary

running stitch, penetrating the skin may be employed. For this purpose, silk or silkworm-gut are acceptable (Fig. 1190).

The above is the most desirable suture for the smaller wounds of the abdomen. For larger wounds the best suture is catgut closure of peritoneum and figure-of-eight silkworm-gut closure of the two fascia layers and skin. Such a suture may be combined with separate catgut suture of the fascia.

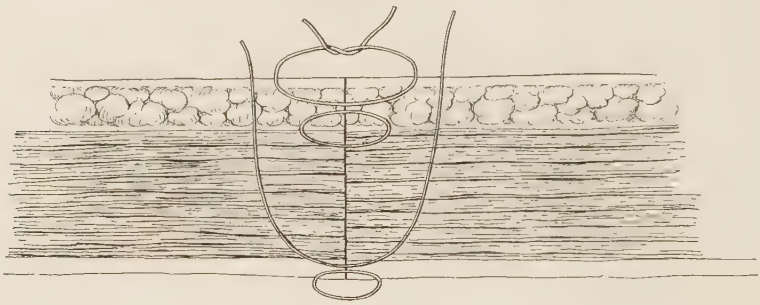

Fig. 1192.—Diagram Showing Continuous and Interrupted Sutures in Closure of Abdominal Wound.

The suture in the peritoneum is continuous and continuous also with that in the anterior sheath of the muscle. The interrupted suture catches all the structures superficial to the peritoneum. The skin suture is superficial.

The silkworm-gut suture is essential to protect the wound from the strain of coughing. When greater haste is demanded, other methods may be employed. Gaping openings through the muscle may require a separate running suture if not capable of being closed by the suture of the overlying fascia. It is often wise to introduce a few deep removable sutures to hold the fascia in connection with the absorbable sutures (Figs. 1191 and 1192). For this purpose figure-of-eight sutures of silkworm-gut are useful. They may

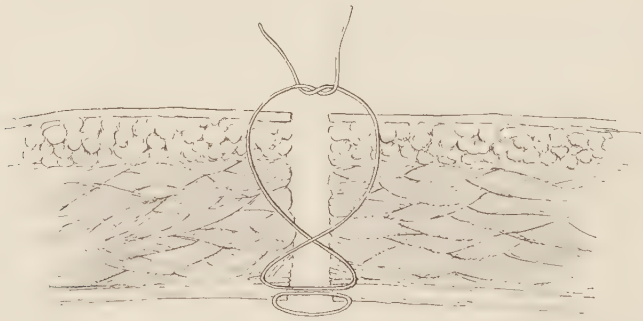

Fig. 1193.—Diagram of Abdominal Wound Closed with Figure-of-eight Sutures. The peritoneum has first been sewed with a continuous suture. The other structures are closed with the figure-of-eight.

be removed after a few days when the danger of vomiting or other special strain has passed and the fascia has become united. Some surgeons sew the peritoneum and transversalis fascia with one running chain-stitch suture, and the structures superficial to this with interrupted or running sutures penetrating the skin. A running suture is desirable for the skin. In situations where the peritoneum is close to the transversalis fascia the two may be

sutured with the same thread. A few deep interrupted sutures of silkworm-gut are always desirable to protect the wound from strain.

The *figure-of-eight suture* may be employed also alone as the permanent suture. Silkworm-gut is the best material. A needle is placed on each end of the thread, and the suture passed from behind forward. One loop embraces the deep fascia; the other embraces the rest of the tissues superficial to it (Fig. 1193). These sutures should be placed about 1 cm. (3/8 inch) apart. When there is much haste, the peritoneum also may be embraced with the transversalis fascia, in the deep loop; and no other suture is required. When such deep sutures alone are used, the skin may require a separate suture applied between each of the deep sutures.

A *triple figure-of-eight suture* was devised by E. H. Richardson (Jour. Am. Med. Assoc., May 7, 1910) (Fig. 1194). To give especial strength the fascia may be overlapped (Fig. 1195).

Fig. 1194.—Triple Figure-of-eight Suture Used in Closing the Abdomen.

Fig. 1195.—Suture for Overlapping the Fascia.

Removable nonabsorbable sutures may be employed for all of the layers if great temporary firmness is required. For this purpose silver or bronze wire or silkworm-gut may be used. Each end is brought out through the skin. By this method a firm and separate suturing of peritoneum, fascia and skin can be made, and all of the sutures removed when union is secure.

Special operations for entering the abdomen and for closing the abdominal wall are described under special operations (see also Closure of Wounds, Vol. I, page 187).

Dressing the wound is a simple matter. The well-apposed skin edges require but little dressing. Its chief value is to act as a splint. A simple flat pad of ten layers of gauze is sufficient. This may be fixed by adhesive straps and an abdominal binder over all. If the wound apposition is not perfect, if infection is feared, or drainage used, some extra absorbent material

may be added. Otherwise, large dressings are not needed (see Vol. I, page 205).

The abdominal binder should be put on tightly and smoothly. It may be provided with thigh pieces to prevent its sliding up (Fig. 1196). Its function is interchangeable with that of the adhesive plaster.

Some surgeons paint the wound with collodion, powder it with antiseptic, apply a wet dressing, or silver foil. All of these have their place, but as a routine none is essential.

Snug adhesive strips, 5 cm. (2 inches) broad, are of decided service in supporting the wound. Two or three of these strips prevent damage from coughing or other strain (Fig. 1197). H. J. Boldt advocated an especially strong dressing of broad adhesive plaster, put on so as to embrace the abdo-

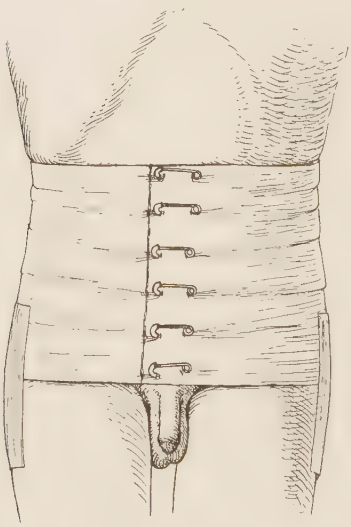

Fig. 1196.

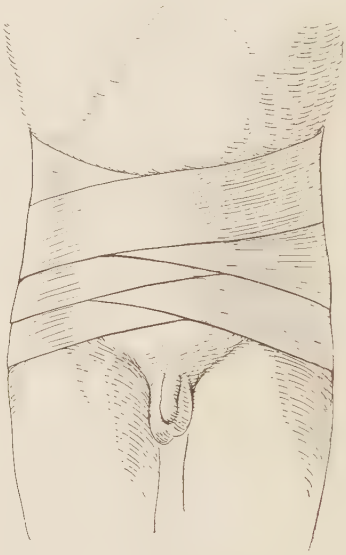

Fig. 1197.

Fig. 1196.—Abdominal Binder Applied over Dressings.

This supplements the adhesive straps in protecting the wound from strain and in retaining the dressings. To prevent upward displacement an adhesive strip may fix the lower border of the binder to the skin of the trochanteric region.

Fig. 1197.—Adhesive Plaster Dressing Capable of Giving Absolute and Immediate Support to the Abdominal Wound.

men for some distance above the scar and to grasp the sides of the abdomen, the pubes, and crests of the ilia. With this dressing over a transmuscular incision; well closed, the patient may walk about on the day following the operation. The dressing is admirable, but the early ambulation of the patient, except in especial cases, is not to be advised.

Nonabsorbable sutures may be removed on the seventh to the tenth day. Snug adhesive straps should be applied again. At the end of two weeks the parts have become strongly agglutinated, and the patient may be allowed up. The adhesive strips, and binder for support should be continued for four weeks after the operation.

Methods of Dealing with Adhesions.—The prevention of adhesions has been referred to in the discussion of protection of the peritoneum (page 515).

Adhesions do not form unless infection or much irritation of the peritoneum has occurred. It is surprising how little prone the healthy peritoneum is to produce adhesions. They do not occur for example between the visceral and parietal peritoneum at the ordinary line of suture. When formed, there is a natural tendency for them to become absorbed; and later examination of an abdomen, once with many adhesions, often shows all adhesions gone. Usually adhesions are salutary, and the surgeon often desires to produce them. This is done by the use of gauze packing, the irritation of which will cause an adhesive plastic exudate to be thrown out in a few minutes, and adhesions of the apposed surfaces in a few hours.

Adhesions may be separated with knife and scissors. Those which can be separated by blunt dissection are the sort which might be expected to dissolve and disappear in the course of time. After dividing adhesions with knife or scissors they will inevitably form again; that is, the raw surfaces left will either adhere to one another or to some other surface unless some of the expedients to prevent adhesions are successfully applied. Wherever possible the wound left by dividing peritoneal adhesions should be sutured. This may be done with fine catgut.

The *prevention of adhesions* should be constantly in the surgeon's mind while operating in the abdomen. While the formation, or absence, of adhesions depends much upon the presence and character of infection, or its absence, and upon the fibrogenetic or fibrolytic action of the patient's fluids, still they may be much influenced by the mechanical and chemical irritations of the peritoneum which the surgeon can control. Chemical irritants, such as bichlorid of mercury solution or alcohol, coming into contact with peritoneum, may be expected to cause adhesions. The surgeon who paints the skin with iodin and then permits the iodin-stained towels or gauze to touch the intestines invites adhesions. Rough handling, sponging, instrumentation, infection, exposure to heat and cold, long exposure to the air, and contact with non-endothelial surfaces are all to be avoided if adhesions would be prevented.

W. B. Brinsmade (Jour. Am. Med. Assoc., vol. lxv, No. 11, Sept. 11, 1915) showed by experiment that for holding and packing off coils of intestines, dry gauze sponges provoke more adhesions than moist sponges, and that smooth rubber dam is the least provocative of adhesions. He accordingly recommended that this latter material be placed against the peritoneum instead of the gauze pads which surgeons are wont to use. Gauze and pads may be employed freely so long as the layer of rubber dam intervenes between them and the peritoneal surfaces. When it is desired to prevent the agglutination of two surfaces which may become adherent, much can be done. Keeping surfaces protected with pads wrung out in warm salt solution is, perhaps, not so effective as wringing the pads in warm petrolatum. Rubber protective is still better than gauze. Any surface which is not covered by endothelium will become adherent to the peritoneum which falls against it. Raw surfaces may be covered with peritoneum slid over it and sutured. This can be done in most parts of the abdomen but is especially facile in the parietal peritoneum and region of the broad ligaments of the pelvis.

The use of sterilized *olive oil* to prevent adhesions has satisfied many surgeons that it has the power to keep the surfaces apart until the endothelium has become healthy. Petrolatum has less value. From 120 to 180 c.c. (4 to 6 ounces) of oil are poured into the peritoneal cavity, and the patient placed in such a position as to encourage its retention between the irritated surfaces.

Camphorated oil is used for the purpose of preventing adhesions. As

much as 200 or 300 c.c. (7 or 10 ounces) of a 1 per cent. solution may be left in the abdomen.

Vogel (Deutsche Zeitschr. für Chirurg., Bd. 63, S. 296) found that 1 part gum arabic in 2 parts of normal salt solution, filtered and sterilized is of value in preventing adhesions. After the abdomen has been nearly closed, a tube is passed down to the area to be treated and the fluid injected. The tube is then removed and the rest of the wound closed.

The method of Cargile, applying thin gold-beater's skin (ox peritoneum), has not been found effective.

The introduction into the peritoneal cavity of the vitreous material from the eyes of animals has a decided influence in the prevention of adhesions. It coats the intestines with a synovial-like unguent which distributes itself throughout the peritoneum.

S. Pope (Annals of Surg., February, 1916) after experimenting with many substances, found that 2 per cent. solution of citrate of soda in 2 per cent chlorid of sodium solution was the most effective agent. All sponges and gauze are moistened with this solution, and 125 to 500 c.c. (4 to 16 ounces), or more, are left in the abdomen. The solution should bathe the whole peritoneum. The solution remains in the peritoneal sac long unabsorbed. It takes up the plastic material poured out by the peritoneum. This solution will not prevent the adhesion of denuded surfaces; probably nothing but peritoneal grafts will. It is well to add 1 or 2 per cent. of citrate of soda to the ordinary operating-room salt solution (for the prevention of adhesions on wounded surfaces, see Wounds of the Peritoneum, page 542; and Wounds of Intestine, page 565).

For the *treatment of adhesions* after they have formed several methods are at the surgeon's command. They require to be divided when their presence hampers the actions of an organ, when they prevent access to some other region, when they attach some structure which is to be removed, or when they strangulate or distort some viscus. Adhesions which are harmless should not be disturbed. Bands or strings should be divided because of the danger of their causing strangulation of the bowel. *Blunt dissection* may be carried out if the adhesions are not firm and especially if a line of cleavage can be found. The soft friable adhesions of recent origin may be separated by the tip of the finger or a blunt instrument. It is surprising how the surfaces left by such an operation will in later years be found covered with apparently normal peritoneum. Older adhesions which are thin and weblike can not be torn through so easily without tearing off the endothelial surface, but they may be cut with scissors, and require no ligatures. Adhesions which have become organized require to have their vessels ligated. If the adhesions are but slightly vascular, they may be divided, and any bleeding vessel ligated. If they are very vascular, multiple mass ligatures may be applied before division of the adhesions (Fig. 1198).

Adhesions of the *omentum*, if not readily separated, are easily treated by ligating the omentum close to the adhesions and cutting it free. As much as is necessary of the omentum may be removed. *Adhesions to the anterior abdominal wall* of viscera which it is not desired to open should be approached with much care if they involve the area of the abdominal section. When such adhesions are suspected, each structure of the abdominal wall should be recognized before it is divided, and after the transversalis fascia has been entered, the peritoneum should be penetrated with caution. It is best, if the interperitoneal line of cleavage is not found, to dissect laterally until the peritoneum is opened and recognized, and then from that standpoint the adhesions may be dealt with. *Interintestinal adhesions* may be separated

by careful dissection. By keeping the same thickness of tissue on each side perforation of the bowel may be avoided. Mucous membrane may be recognized before it is cut. When such adhesions are associated with ulceration of the mucous membrane, perforation of the bowel is very apt to be caused; it is sutured at once, or, if extensive disease demands it, resection of the bowel is done.

Adhesions to the bowel of a part which is removable, such as benign tumor or Fallopian tube, should be divided with the operation leaning away from the bowel. If some part of the structure is left adherent to the intestine no great harm is done.

In the case of *extensive adhesions* which interfere with the functions of viscera, these may often be broken up or divided, the organs placed in normal

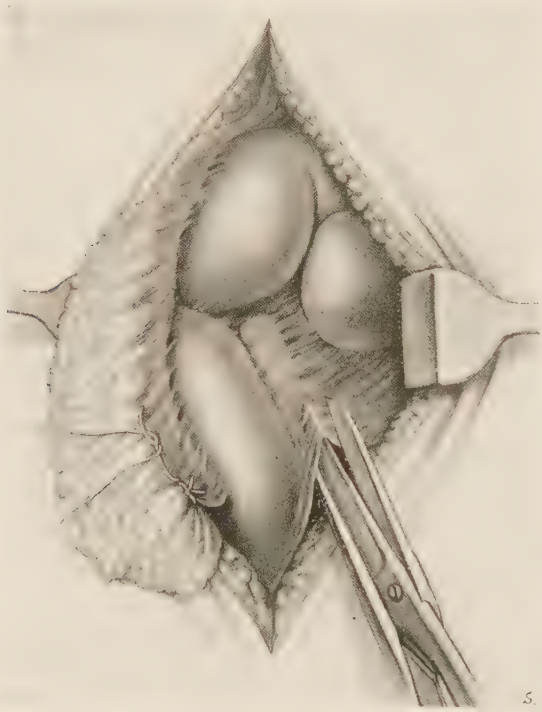

Fig. 1198.—Operation for the Separation of Peritoneal Adhesions and the Removal of Adherent Omentum.

The handle of a scalpel is passed beneath the adhesions and the scissors applied.

position, and the patient much benefited by the procedure (see Intestinal Adhesions, pages 520, 557 and 599).

Methods of Dealing with Hemorrhage.—Bleeding is to be dealt with according to methods already described (Vol I, page 334). It is important that every bleeding point shall be controlled, because, while in other parts of the body hemorrhage stops itself when the clot becomes large enough to create sufficient pressure, the abdomen may easily entertain a fatal amount of hemorrhage without material increase of the intra-abdominal pressure. The control of bleeding is imperative (1) to spare the patient the immediate depressing effects of steadily increasing anemia in the presence of a shocking

operation, and (2) to prevent the occurrence of concealed postoperative bleeding.

Bleeding should be controlled at once as the operation progresses. Vessels of some size, which spurt, should be ligated. It is not well to trust to a clamp and a clot, for after the abdomen has been closed and the patient's blood-pressure rises, the clot may be forced out and intra-abdominal bleeding take place. Oozing surfaces may be treated by packing with gauze or a sponge. It is such packing, which becomes impregnated with clot and takes on the appearance of living tissue, that is sometimes overlooked and left behind when the abdomen is closed.

Fine ligatures carried through the tissues with a needle are useful. The cautery is rarely necessary. Adrenalin sometimes may be used. When deep vessels are caught with long clamps in positions where ligation cannot be done, it may be necessary to leave the clamps in place, surrounded by gauze and rubber protective, and the wound partially closed around them as for drainage. After forty-eight hours the forceps may be removed with care, while the surgeon is ready with the necessary measures if hemorrhage recurs. Gauze packing upon a bleeding area may likewise be brought out through the wound just as a drain. It may be removed a day or two later, and replaced if necessary. When drainage communicates with a source of bleeding the danger of hemorrhage is not great; it is no longer concealed.

Postoperative intra-abdominal hemorrhage demands that the abdomen shall be exposed, preferably by reopening the abdominal wound, and the bleeding point found and secured. This is a rule which should not be neglected. When such hemorrhage is enough to be revealed by its unmistakable signs it is already serious enough to demand radical attention. When the bleeding has increased the pulse-rate from 100 to 120, then is the time to attack it, and not wait until it is 150 or 160. If for any reason it is inexpedient to reopen the abdomen, the palliative measures may be tried. Blood may be confined in the legs and arms by means of a constricting bandage, close to the trunk and light enough to constrict the veins but not the arteries. A tight bandage about *all* of the abdomen to increase the intra-abdominal pressure, and some morphin to insure quiet may be of service.

It seems almost wrong to describe these temporizing measures where in the presence of hemorrhage the one best thing to do is to close the bleeding opening. The thing that is doing the patient greatest harm is the loss of blood, and fifteen minutes of light anesthesia is not so harmful as five minutes of bleeding. It is surprising how the picture changes as soon as the abdomen is opened, the bleeding effectually and finally stopped, the clots removed, the wound closed, and the patient put back in bed; both the patient and the surgeon take on a better color.

To avoid these unpleasant experiences there is one rule: *never close the abdomen when there is even the slightest uncontrolled bleeding.*

Methods for Securing Drainage.—Drainage of the peritoneal cavity is often needed. It is called for when there is infection, the products of which if not given egress will either be retained or spread to other parts. It is used when it is desired to wall off by adhesions an area of peritoneum, for the irritating presence of any drainage material causes an exudation of plastic fibrin not only where it impinges but also for some distance about its periphery, where peritoneum lies apposed to peritoneum. These latter surfaces adhere, and when the drainage is withdrawn it leaves a pocket which is excluded from the general peritoneal cavity. This is the principle of drainage. It is practically constant.

When an infected area is drained, it is desirable that it should all be drained. If some part of the area becomes excluded from the drainage pocket an infection is excluded, and this septic focus may progress away from the drain and invade other tissues.

The objection to drainage is that it covers an area of peritoneum with plastic lymph. If this area is the intestine, the inflammatory infiltration of its wall inhibits peristalsis; and the inhibition of peristalisis by peritonitis is one of the greatest dangers in abdominal diseases. I discussed this many years ago (see Peritonitis, page 546), and the danger is being more and more realized. A small area of drainage is not bad, but to attempt the drainage of large areas may do greater harm than no drainage at all. The peritoneum can take care of a large amount of fluid and infection. If the primary center of infection and reinfection is removed, it is surprising how well the peritoneum can clean up the situation without drainage.

The introduction of drainage in the peritoneal cavity marked a great improvement in treatment. The rule was, to drain when in doubt. Now the

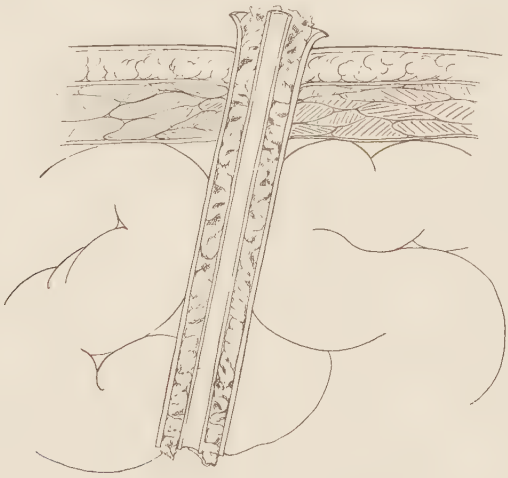

Fig. 1199.—Abdominal Drainage.
Rubber tubing surrounded by gauze enveloped in an outer drainage tube.

dispensing with drainage is marking a still greater improvement. The experienced surgeon is not now using much drainage, provided that the primary source of infection is removed; and he is developing the rule, not to drain when in doubt. The inexperienced surgeon should still drain when in doubt.

Where collections of septic material are focalized it is usually best to evacuate them. Drainage of a septic focus may be lead out through an area of healthy peritoneum with the assurance that it will become walled off.

When a peritoneal abscess is evacuated the focus should be drained. This is best done by a good-sized rubber tube surrounded by gauze or wick drain, and all enclosed in rubber protective. The latter is always desirable as an outer covering because, while it excites plastic adhesions, the peritoneum does not become adherent to it. Gauze, on the other hand, while admirable for all other purposes, has the disadvantage that the plastic fibrin enters its meshes and causes it to adhere to the peritoneum so that it is withdrawn with difficulty, and when pulled out often leaves a bleeding peritoneal surface. In the presence of much pus, however, gauze does not become adherent.

The packing about the tube is desirable, not so much for the sake of its capillary drainage as for the purpose of enlarging the caliber of the drainage canal. Through the rubber tube removable wick may be passed, or the tube may be emptied by aspiration at frequent intervals. Aspiration is done with a small rubber tube, connected with a syringe, and passed down inside of the larger tube. Aspiration may be done once daily or a capillary wicking may be changed once daily (Fig. 1199).

The cigarette drain is useful. Glass drainage tubes are employed in cases in which soft drains would collapse or become disarranged. The glass tube may be placed alone. It may contain wick or be aspirated.

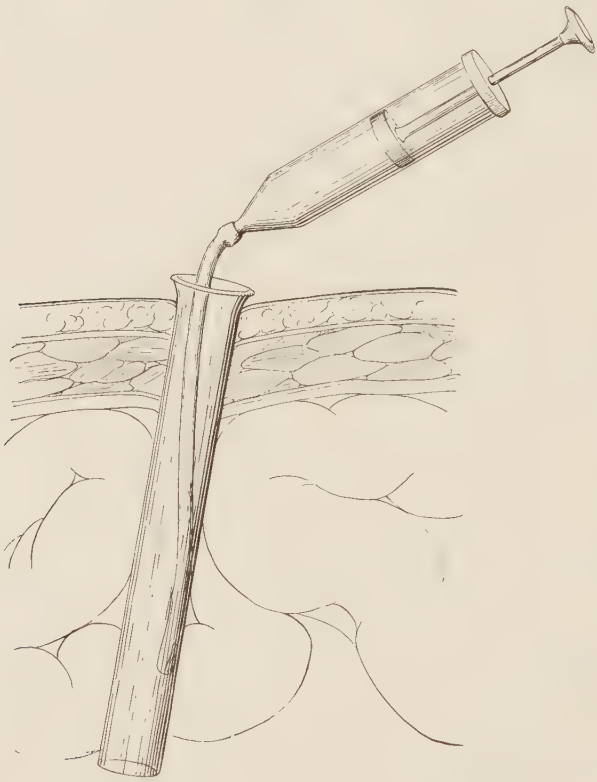

Fig. 1200.—Glass Drainage Tube in Place in Abdomen.
Showing syringe for aspiration of fluid.

It quickly forms a canal and is easily removed. It is especially useful for draining a deep focus out through normal intestinal coils, as is sometimes required in the pelvis or flank (Fig. 1200).

The gauze envelope drain advocated by Mikulicz is often convenient, especially where some pressure packing for bleeding is also desired. The parts are retracted and a square of gauze is pressed into the wound, the edges of the gauze all remaining outside of the body. Packing is pressed into the centre of the square gauze. The packing is all inside of the gauze square; the latter alone comes into contact with the tissues (Fig. 1201). When it is desired to remove the drain, the gauze is easily withdrawn. The packing may be renewed or the square may be taken out. The removal of the latter

is facilitated by having a silk thread fixed to its center before it is introduced. By pulling on the thread the gauze is brought up from the bottom.

In all this work it should be remembered that plastic adhesions are excited by the drain in a few hours, and after that the only area drained is the drainage tract. The exciting of adhesions by such methods is often of advantage when there is no infection, simply for purposes of sealing a peritoneal wound or strengthening a weak place.

After two days the adhesions have become so firm that the drainage may be removed without fear of their giving way. Two mistakes can be obviated only by experience: (1) removing a drain too soon; and (2) leaving a drain in too long. As soon as a drain is withdrawn, the intestines close its path. If it is removed while infection still exists at the bottom of the cavity, the tissues may destroy the germs or they may multiply and reform a septic focus. This septic focus may require to be reached and drained again, or it may rupture into a viscus or be otherwise disposed of. It often happens

Fig. 1201.—Abdominal Drainage.
Mikulicz drain, consisting of a square of gauze with a gauze strip packed within.

in the hands of the inexperienced that a drainage tube is left in while the discharge which it is draining is that produced by its own invitation. It there is no constant source of infection at the bottom of a drainage tract, such as a perforated intestine, gangrenous material, or a foreign body, the tube usually may be withdrawn 1 cm. (¼ to ½ inch) every day after the second day. It is a clinical fact that pus left behind tends to follow the course of the drainage tract and reach the surface.

The longer a drain is left, the longer it is needed. In most instances, the drain may be removed entirely at the end of two days. Often it is better to remove it at the end of twenty-four hours when the peritoneum is less damaged.

Harm may come from drainage not only by the irritative peritonitis which it produces, but by its causing angulation of the bowel which should be eventuating in intestinal obstruction.

When drainage is used, the abdominal wound is closed down to the drain which should usually be at the lower end of the wound. In drained cases it is most convenient to sew the peritoneum separately, and close the transversalis fascia, muscle and skin with a figure-of-eight silkworm-gut suture.

It is well at the time these sutures are introduced to insert also the sutures into the tissues of the drain opening. These may be isolated and covered by the dressings, and when the drain is removed they are ready to be tied. This leaves less probability of hernia than when the wound is left to granulate.

Drainage should be at the lowest part of a cavity to be most effective. This is true in ordinary abscesses, in the drainage of hollow viscera, and in the drainage of the peritoneum. There are two ways of securing such drainage: either by making the exit at the lowest part of the cavity, or by changing the position of the cavity so that the opening is at the lowest point. Posture may be made an important factor in drainage of the abdomen.

So far as the use of drains is concerned, it must be borne in mind that plastic lymph shuts off the average drain in less than a day, and therefore if the drain is to accomplish much it must be soon after it is placed in position. If drains were not used, abscesses would develop deeply among the intestines, and would be reached with difficulty. With the use of drains, the abscess develops at or near the drain and pus more easily finds its way to the surface.

An abscess or a collection of infected fluid being present it should be opened at the lowest place, or if the place at which it can be opened to the best advantage is not the lowest place it should be made so if possible. The pelvic pocket is the lowest part of the peritoneal sac. If it is the seat of infection, it may be drained through the vagina (see Vaginal Drainage, Vol. III); or, by raising the pelvis, its drainage may be successfully secured above the pubes. The peritoneal cisterns on either side of the spine in the lumbar regions are the lowest points in the abdomen with the patient in the supine position. By turning the patient on the diseased side these lateral cisterns may best be drained.

Bode (Centralb. f. Chir., xxvii, 1900, s. 33) and G. R. Fowler (Med. Rec., lvii, 1900, page 617) advocated elevating the upper part of the trunk to facilitate drainage. This position has proved most valuable in many conditions. One of its chief values, however, has not to do with peritoneal drainage at all, but depends upon the better downward movements of the gastrointestinal contents which the semi-sitting posture guarantees.

Rectal drainage has proved most useful in pelvic abscesses, especially of appendical origin. It may be used in either the male or female. The bladder should be emptied by catheter. The exaggerated perineal position with the knees held high is the best position for operation. A posterior retractor and a long-bladed anterior retractor are inserted. The rectum should be irrigated until fecal matter is removed. The bulging place on the anterior wall where the abscess presses should be cleansed with equal parts of alcohol and water. A knife should incise the rectal wall in the anterior median line. This incision should be above the bladder. The pus should be allowed to run out and a soft-rubber tube, having T-wings at the upper end to prevent its escape, should be introduced into the abscess cavity. The sphincter should then be dilated, and the operation is done. Of course, peritonitis should have been treated so that pelvic abscess does not develop, but not all cases are seen early enough by the surgeon to meet this demand.

Drainage by counter opening is to be recommended. In the flanks and in the pelvis, the benefit of gravity may be added to the draining forces. Ordinarily drainage through an anterior abdominal wound, as above described is against gravity. Having dealt with an infective focus which requires drainage, say in the region of the cecum, a stab wound is made outward and slightly backward from the outer side of the mesocolon through the flank. A pair of forceps are passed in through this wound, to dilate it and pull out through it a large drainage tube. The drainage tube has passed

through it a rope of wick. The inner end lies at the site of disease; the outer end emerges through the skin. The anterior abdominal wound may then be closed entirely without drainage; or if it has been infected temporary light drainage may be used in it. This method of counter drainage is much used through the posterior fornix of the vagina for draining the retrouterine cul-de-sac; and above and in front of the kidneys for higher abdominal drainage through the abdominal wall.

Nonadhering gauze for abdominal drainage is desirable because ordinary gauze becomes so fixed to the peritoneum that its removal causes pain and bleeding; and often such strong traction is required to remove it at the first dressing that serious drainage may be done. To meet this need, the rubber and glass tube and the gauze or wick enveloped in rubber or other non-porous material should be used instead of plain gauze in most cases requiring drainage. There are situations in which naked gauze is required. To prevent it becoming penetrated by plastic tissue various expedients may be used. The finer the mesh the less does it adhere. Gauze which has been impregnated with equal parts of paraffin and petrolatum adheres less than plain gauze. A still less adherent gauze is impregnated with a mixture made by melting together 7 parts of paraffin and 3 parts of petrolatum.

French surgeons use *oiled gauze.* This is gauze impregnated with a mixture composed of 2 parts petrolatum, 2 parts castor oil, and 1 part yellow wax. Descour advised the addition of a little balsam-of-Peru which gives it a pleasant odor. This gauze may be used for dressing any kind of a wound and will be found nonadherent (Archiv. de Méd. et de Pharm. Milit., No. 4, Apr., 1917).

The best for this purpose is *paraffined gauze,* impregnated with a sterilized mixture composed of equal parts of paraffin and stearic acid. Gauze which has been soaked in this heated mixture, and stretched out to dry, forms a sieve which is flexible and non-adherent, and may be used most effectively for peritoneal drainage. This is the method devised by H. E. Fisher (see Dressing and Drainage Materials, Vol. I, pages 39 and 45).

Postoperative Treatment of Abdominal Cases.—The less treatment the patient receives after laparotomy the better. The ordinary case with an uncomplicated operation goes from the operating table in good condition. There is a slight degree of depression, scarcely worth being called shock, which requires only that the surface of the body shall not become cold. The patient should be taken to a quiet, not too light room, and laid supine until the anesthetic depression has subsided. Then the head may be elevated. There will be some abdominal pain, some thirst, some nausea, and some insomnia the first night. These usually are of so little consequence as to require no treatment.

As soon as the nausea has subsided, which should be by the day after the operation, the patient may be given fluids by mouth and the elevated head position should be instituted. Fluids mean water, albumin water, broth, glucose solution, whey, orange juice, grape juice, lemonade, or dried proteid powders in water. The head may be elevated so that the trunk inclines at an angle 45 degrees above the horizontal. By the second day milk may be taken if all nausea has subsided. After this the diet may be slowly increased (see Nourishment and Care of the Patient, Vol. I, pages 19 to 27).

The *elevated-head position* may be maintained as much as the patient desires through the day. For sleep he should prefer to lie supine with a pillow for the head. For maintaining the elevated-head position the head of the bed may be raised or an inclined plane placed behind the back. To prevent the patient from sliding down in bed a second inclined plane may be con-

nected with the first. The second plane should accommodate itself to the thighs and legs the apex being at the knees (Figs. 1202 and 1203). An exaggerated position is not called for. The elevation should be about 45 degrees above the horizontal. It need not be more than this. Raising the head of

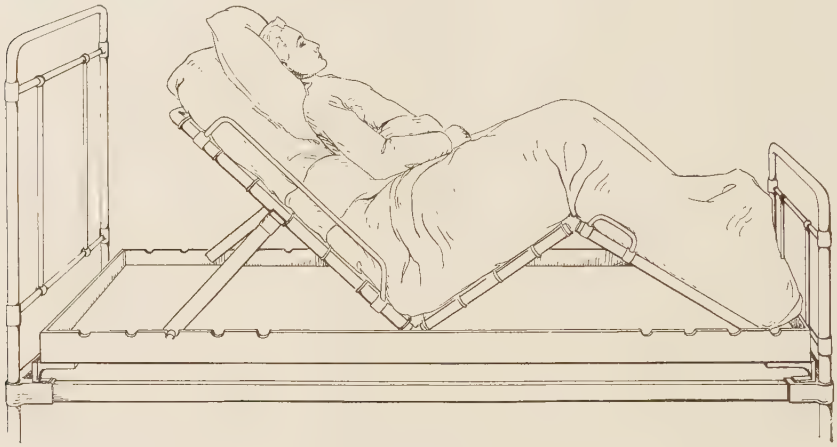

Fig. 1202.—Elevated-head Position after Abdominal Operation.
This position may be secured by means of a special bed frame or by means of props and pillows.

the bed 45 or 50 cm. (18 or 20 inches) on two chairs suffices. A pair of pillows below the buttocks may be fixed with a bandage to prevent the patient sliding downward.

The patient may be allowed out of bed in a chair on the eighth or tenth day; at the end of two weeks he may be allowed to help himself out of bed;

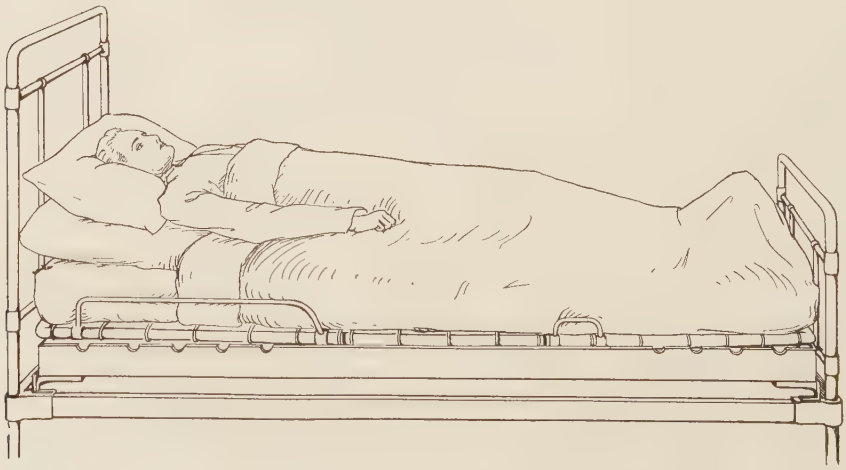

Fig. 1203.—Showing Recumbent Position Secured by the Same Bed that is Used for the Elevated-head Position.

and in twenty-one days he may be permitted to go about his business. In the case of wounds which have been drained, the patient should not be allowed to walk until the wound is entirely healed.

Special treatments are advocated by many surgeons. In some hospitals certain routine measures are followed in all cases. This is necessary only in such institutions as cannot guarantee intelligent supervision over post-operative cases. In the presence of discriminating supervision, each case should receive the treatment indicated for that particular case.

The placing of a *rectal tube* after the patient has been put to bed gives comfort in many cases. It may be left in for two days. If it causes discomfort, some olive oil injected through it will sooth the bowel. The tube permits the escape of gas without muscular effort. It does no harm and may be of great benefit.

J. A. Sampson conceived the idea of *increasing abdominal pressure* by means of sand-bags placed on the abdomen. Sand-bags measuring 15 by 30 cm. and weighing 2 to 3 kilos (5 pounds) are used. These sand-bags are made flat and sewed through to keep their shape. Two bags are placed on the abdomen, one on either side of the median line, and held by the binder. The weight of the bags increases the intra-abdominal pressure. This prevents overfilling of the abdominal blood-vessels, distention of the intestine is counteracted, gas is caused to move onward toward the anus, and the patient has a sense of comfort and security. After the removal of large tumors or large amounts of fluid, this treatment is especially indicated.

The use of *morphin* after abdominal operations requires discrimination. If a patient is not going to have pain or shock it is not necessary. Some surgeons give it as a routine in doses of 0.005 Gm. ($\frac{1}{12}$ grain) every three hours while the patient is awake during the first two days. As a rule the patient is better off without it; but as a rule morphin will do less harm than pain, restlessness, and sleeplessness.

It is not necessary that most patients should have a *bowel movement* on the second or third day, after the operation. Usually if left alone the bowels will move by the fourth day. If the patient is doing well, there is no harm if the bowels do not move till the fifth or sixth day. A dose of paraffin oil may be given if necessary. A particularly effective cathartic at this juncture is a dose of 45 c.c. ($1\frac{1}{2}$ ounces) of castor oil and 4 c.c. (1 dram) of compound tincture of cardamom.

The postoperative administration of *oxygen*, begun immediately, hastens recovery from ether and diminishes the liability to vomiting. The inhalation of the fumes from vinegar relieves the ether nausea.

Postoperative complications, requiring treatment, arise in many cases. They may be mild or so severe as to threaten life. None of the measures, described below are needed in the ordinary uncomplicated case.

Vomiting and *nausea* have already been discussed from the standpoint of the anesthetic (Vol. I, page 104). It is possible to employ anesthesia that will not cause vomiting. Taking fluids too early into the stomach should be guarded against. Vomiting is easily excited after ether anesthesia. Commonly it is due to the reflex or direct mechanical disturbances incident to the operation. Vomiting is least apt to occur if the bowel has been well emptied before operation, and if the minimum of damage has been done to it during the operation. If the vomiting is anticipated in a patient who has had ether, it may be prevented by passing the stomach tube before the patient regains consciousness, and washing out the stomach. This may be repeated if nausea develops.

Nausea due to abnormal peristalsis may be serious. By placing the patient in the elevated-head position downward drainage may be established. An evacuation of the bowels, secured by enema, will often stop the nausea. When vomiting of the contents of the small intestine is troublesome, lavage

of the stomach is essential. This should be repeated as many times daily as necessary.

The surgeon should assure himself that there is no intra-abdominal condition which should be relieved. Gauze or other drainage material may cause irritation to the bowel and reflex vomiting; or it may be responsible for actual mechanical obstruction. A collection of pus may have been overlooked. Very commonly persistent vomiting is due to a spreading peritonitis, and will not subside except by direct treatment of that condition. Vomiting which is intractable is usually due to peritonitis or intestinal obstruction, and the surgeon should address his attentions to these conditions rather than to the stomach (*q.v*).

It is rarely worth while attempting internal medication for nausea. Counterirritation of the skin of the epigastrium by mustard is of help in some nervous cases. Fresh cool air admitted to the lungs, or the inhalation of oxygen, sometimes give relief. Gastric lavage should always be regarded as the main reliance of treatment.

Meteorism, or gaseous inflation of localized segments of bowel, should be prevented by the precautions already described to minimize the damage to the peritoneum and bowel. Hot water by mouth in 4-c.c. (1-dram) doses, as hot as the patient can bear it, will bring up gas. By elevating the upper part of the trunk, placing the patient in the semi-upright position the expulsion of gas is facilitated. The relaxed abdominal muscles may be caused to contract and press out the gas by applying heat. This may be in the form of hot stupes, or dry heat. The latter may be applied by means of the hot-air box.

A distended large intestine requires relief by an enema and the restoration of peristalsis. If the ordinary enema of soap and water does not accomplish it, a more stimulating one should be used. Turpentine, 4 c.c. (1 dram) to 500 c.c. (1 pint) of water, may be added. Powdered alum in the same amount may be used. A combination much employed is made of magnesium sulphate, 30 Gm. (1 ounce); glycerin, 30 c.c. (1 ounce); turpentine, 4 c.c. (1 dram); and water, enough to make 120 c.c. (4 ounces). J. C. Munro recommended a mixture of 500 c.c. (1 pint) of milk, 500 c.c. (1 pint) of molasses, and 15 c.c. (½ ounce) of turpentine. A tube may be passed occasionally to assist the expulsion of gas.

For meteorism, the alum enema is most effective (see Laxative Enemata, page 620). The important thing is that gas shall be expelled. When the measures for the treatment of meteorism and vomiting fail to give relief in twelve hours, the surgeon should realize the strong probability of spreading peritonitis or obstruction being the cause of the trouble (see Peritonitis, page 546).

Eserin salicylate in doses of 0.001 to 0.0015 Gm. (1/60 to 1/40 grain) is useful in some cases. It acts only on the small intestine and an enema should be given four hours later to empty the large bowel. Hormonal in doses of 15 to 20 c.c. (4 to 5 drams) is perhaps still more effective, as it acts on the whole intestine. Neither of these should be given in well-developed peritonitis or obstruction.

Acute dilatation of the stomach may be prevented, diagnosed and cured by the stomach tube.

Pain following operation usually subsides with the meteorism. During the first night it may be so severe as to justify an injection of morphin. The drug is best not to be repeated.

Shock in a slight degree needs only the ordinary postoperative care of the patient. Its degree cannot always be predicted, and it is a wise rule

to be prepared for it in all cases. Its treatment in abdominal cases is not much different from that in other cases (Shock, Vol. I, page 213). *Proctoclysis*, the slow instillation of warm salt solution into the rectum (Vol. III), is of especial service in shock of abdominal origin. Many surgeons institute it at once in cases in which shock is feared.

Some surgeons combat shock by filling the peritoneal cavity with warm saline solution. This is best done by placing a soft catheter behind the omentum, or through it if preferred, so that its tip lies above the transverse mesocolon. The peritoneum and transversalis fascia are snugly closed about the catheter. Saline solution at a temperature of 45°C. (112° to 114°F.), is then allowed to run in from a height of about 1 meter. Five hundred or 1000 c.c. (1 or 2 pints) will fill the abdomen. The tube is then withdrawn and the closure of the wound completed. This treatment gives heat and pressure to the region of the hypogastric and solar plexuses, and vasoconstriction results.

A routine practice of some surgeons is a method advocated by Clark for filling the large bowel with saline solution. At the conclusion of the operation while the abdomen is being closed, the patient is placed in the lowered-head position, 1 to 2 liters (1 or 2 quarts) of warm saline solution are allowed to run into the rectum. This fluid passes through the whole large intestine. Clark employs this method after the treatment of peritoneal adhesions, before closing the abdomen, and is able to see the fluid pass as far as the cecum and sometimes into the ileum, and the colon drop back into its normal position by the weight of the water. If the patient is carefully handled, and the pelvis kept slightly elevated, the fluid is retained and absorbed.

Heat applied to the abdominal wall has the effect to increase salutary hyperemia and peristalsis. A. Strempel (Deutsch. Zeitschrift für Chir., July, 1910, cv, Nos. 5 and 6) advocated heat by means of the hot-air box or the incandescent electric-light box—500 candlepower. It is claimed that it counteracts the tendency to shock, promotes peristalsis, diminishes adhesions, and inhibits peritonitis. A dry air temperature of 130°C. (265°F.) may be used for fifteen or twenty minutes twice daily. A temperature of not more than 55°C. (131°F.) may be used for one or two hours at a time, with intervals of three hours, day and night. Other surgeons use it only once or twice a day. Without any other postoperative treatment it is found that flatus is usually passed during the first twenty-four hours.

Thirst, after laparotomy, is sometimes distressing. If the patient is not nauseated he may drink freely of water that is not cold. If the patient is still nauseated, thirst cannot be slacked with drink. Ice may be taken into the mouth, or the mouth rinsed with a cooling taste of lemon juice. The treatment of thirst consists in supplying fluids to the tissues; and this is done by proctoclysis, hypodermoclysis, infusion, or the other means described for restoring body fluids. It is not wise to give a vomiting patient fluids which do not quench the thirst and which do aggravate the vomiting. It should be remembered that water is not absorbed by the mouth, stomach, or even the upper part of the intestine, but by the small bowel and colon.

Retention of urine should not be confused with scantiness of urine. The treatment of suppression is described elsewhere. After a laparotomy the secretion of urine is diminished. If the patient is kept dry about 360 c.c. (12 ounces) are passed the first twenty-four hours. This should be increased by the use of water by mouth and proctoclysis to at least 500 c.c. (1 pint). If urine is not voided in the first eighteen hours, some artificial encouragement should be given, such as a warm enema or hot applications to the pudendal and pubic regions. If these fail, and the patient feels that urine

could be passed in the sitting or standing position, it may be tried. With a firm adhesive strapping to support the wound the patient can do it no harm by standing up to urinate.

The passage of small quantities frequently, means injury to the bladder, or it indicates the overflow from a full bladder which should be catheterized. Catheterization otherwise should be reserved as a last resort. A record of the amount of urine voided should be kept. The catheter should be passed carefully. For lubricating the catheter a safe mixture is 25 per cent. argyrol in glycerin.

Other complications which may arise require their own treatment. Postoperative hemorrhage, peritonitis, ileus, acute dilatation of the stomach and phlebitis, are discussed in their respective places. Postoperative hiccough is to be combated by removal of the cause (usually peritoneal irritation) and by sedative measures.

Postoperative *pneumonia* should be treated by giving the patient fresh air. The shoulders should be slightly elevated, concentrated nourishment should be given, the surface of the body should be protected from chilling, and nothing should be permitted that depresses the heart. It is possible that some day these cases may be saved from a fatal termination by insufflation of the lungs with fresh air. Pneumonia is to be prevented by sparing the patient from exposure to cold before, during, and after the operation; by careful anesthetization; by cleanliness of the mouth; by having the patient breath deeply as an exercise two or three times a day after the operation; and in the case of old people, by avoidance of the recumbent position.

Remarks.—In general, most abdominal cases require no special treatment. It is best that the patient should not be pestered with attentions. A small dose of morphin the day of the operation and, if at all indicated, the night following the operation should make the patient comfortable. The character of the operation and the amount of traumatism that has been inflicted are the chief determining factors. Fluid by rectum is useful after all serious and depressing operations. The patient should be allowed to change his position as he will. The most comfortable position is the most restful.

The time for getting up after abdominal section must depend upon many conditions. A clean undrained abdominal wound is well united in ten days. The sutures may be removed on from the eighth to the tenth day. Broad adhesive straps should support the wound and hold on the dressing. With such adhesive straps a comfortable patient may be allowed up in a chair any time from the seventh to the tenth day. No harm need be done by sitting up even earlier. Weak patients should remain in bed longer.

An average healthy patient may be permitted to walk two days after he begins to sit up. The adhesive straps which support the abdominal wound and prevent strain upon the union should be worn for a month. Care should be taken that the patient abstains from straining for two or three months.

Postoperative feeding must vary for each patient and the nature of the operation. In operations not involving opening the alimentary canal, water in small doses may be taken after twelve hours. On the day following operation fluid nourishment which is least prone to fermentation and putrefaction may be given. Whey, broth, strained soups, orange juice, peach juice, malted milk, albumin water, and glucose may be given in small doses. At the end of forty-eight hours, if no signs of peritonitis are present, milk may be added. A small glass of milk (120 c.c.) may be given every four hours during the third day after the operation, and this amount may be doubled on the next day. Milk may alternate with the other fluids. Solid

food, such as cereals, dry bread and soft egg may be allowed on the fourth day, and if no complications develop, full diet may be permitted on the fifth day. All food should be in moderate amounts. It should be well chewed. And the patient should preferably eat what tastes good (see Nourishment, Vol. I, page 19).

For *emergency feeding*, when the conditions are not normal, when the patient cannot be given the above diet, and nourishment is necessary, other expedients must be employed. These are intravenous, subcutaneous, and rectal nourishment (for Nutrient Enemata, see page 620; for Nutrient Injections, see Vol. I, page 20).

Contusions and Concussion of the Abdomen.—Any injury which the abdominal wall may suffer is of little consequence compared with the damage which may be sustained by the contents of the abdomen. Two conditions call for treatment: (1) the shock of concussion of the sympathetic plexuses; and (2) visceral injuries.

Sympathetic shock demands the same treatment as described for shock in general (see Vol. I, page 213).

Visceral injuries demand diagnosis first. The surgeon should bear in mind that a slight contusion, confined to a small area, is capable of causing laceration or rupture of viscera, and that this is especially the case with distended hollow viscera and with organs fixed by adhesions. The signs which guide the surgeon are those of peritoneal irritation and hemorrhage. During the first hours these are confusing, as hemorrhage may produce irritation of the peritoneum sufficient to give rigidity, while infection in its early stages gives none. Or the shock of peritoneal invasion by infective matter, before peritonitis has developed, may lower blood-pressure and simulate hemorrhage.

The question to decide is, is there either peritoneal irritation or hemorrhage? If either of these, sufficient to give their classic signs, is present, the abdomen should be opened and the lesion sought. The rule should be added to this; when in doubt explore. Most surgeons are too sure when they explore. It is not wholly to my credit that, in all the doubtful cases of this sort upon which I have operated, I have found a lesion which demanded surgical treatment to save the patient's life. The surgeon who occasionally opens an injured abdomen and finds no injury is much to be respected.

THE ABDOMINAL WALL

Wounds of the Abdominal Wall.—*Rupture of abdominal muscles* from muscular strain or contusion rarely require operation. With rest, the rent heals. If there is an opening through the skin, communicating with the torn muscle, the muscle may be sutured.

Non-penetrating wounds require the same treatment as wounds in other regions. The probe should not be used, except in the hands of an experienced surgeon and then with some very definite object in view.

Penetrating wounds (through the parietal peritoneum) not involving the viscera, require similar treatment to that of non-penetrating wounds, excepting that provision for drainage of the peritoneum should be made. In the case of small wounds, if the opening is large enough, a small drainage tube may be carried down to the presumably infected peritoneum. Larger wounds, which require to be sutured, should be cleansed and closed excepting the most dependent part, through which drainage should be conducted to the peritoneum. *Bullet wounds* which penetrate the parietal peritoneum are not large enough to permit inspection to determine whether viscera are wounded or not. The probability of serious visceral injury is so great that,

if the surgeon is so situated that an aseptic operation can be done immediately, the abdomen should be opened. The operation is done preferably in the median line, employing one of the incisions already described for opening the abdomen. If the wound is external to the anterior axillary line, the incision may be made laterally. In these injuries, the surgeon cannot know before such an exploration what damage has been done. If the bullet is found external to the peritoneum the operation stops there. If penetration is discovered, but no visceral injury, it is worth while making a search in the free peritoneum for the bullet. Too much time and manipulation should not be used in this search. If the bullet is found to have passed out again through a second wound in the parietal peritoneum, it may be left undisturbed unless it is in easy reach. If it is doing damage in its extraperitoneal position, it is best that it should be attacked through some other route rather than across the peritoneal cavity. When asepsis cannot be controlled, as in operations outside of the hospital, in the field, woods, or at sea, the patient has a better chance of recovery if treated by an occlusive antiseptic dressing, abstinence from food for a few days, and rest in the recumbent position.

The treatment of penetrating wounds in which perforation of hollow viscera is possible but not positively diagnosed must depend upon the surgical facilities available. If the surgeon has experience and facilities for performing abdominal operations exploration is advisable. If such surgical help is not at hand the patient should be given morphin or opium and kept as quiet as possible. Shock should be met by keeping the patient comfortably warm and by giving water by hypodermoclysis or proctoclysis. If the patient cannot be operated upon or must be transported before operation can be done, morphin should be supplemented by gentle abdominal compression with a snug binder.

The *treatment of bullet wounds of the abdomen by compression* is advisable when facilities for a proper opening of the abdomen are not at hand. This is especially when the patient has to be transported for some distance. If seen, immediately under these circumstances, a dressing should be applied, and a snug bandage or binder should be placed about the abdomen. This has the effect of immobilizing the abdominal muscles and viscera. The escape and spreading of intestinal contents is lessened; and the localization of the peritonitis is encouraged. It is in every sense a splinting process. Without such abdominal compression, a patient who has to be transported with a perforating wound of the abdomen is subjected to the hazard of having the infection disseminated by the movements of the abdominal contents. This method of artificial compression helps nature do what it is attempting to do by muscular rigidity, pain and distention. Compression is of value only as an early expedient. It is not of value after distention has occurred.

Wounds of the Diaphragm.—These wounds are so commonly associated with wounds of the lung, liver, stomach or other important structures, that their treatment is usually a matter of secondary consideration. A small wound, such as that made by a bullet, so far as the diaphragm is concerned, is of little consequence. Wounds of sufficient size to permit the formation of hernia should be sutured. This is best done from the upper side, either by some of the operations already described (page 467) for exposure of the diaphragm, or by additional resection of the costal margin as described for facilitating approach to the liver. Suturing is best done with chromicized catgut.

Infections of the Abdominal Wall.—Such infections are not peculiar, and should be treated the same as infections elsewhere. The peritoneum need not be feared, as their natural tendency is to progress toward the skin.

The most common infections are those associated with wounds of the abdomen. *Infection in operation wounds* should be treated by taking out the sutures for a sufficient distance to permit of opening the wound down to the infected focus. By doing this promptly, extension of the infection to the rest of the wound may be checked. An infection under the superficial fascia or in some other plane of fascia, extending the whole length of the wound, does not always require opening the wound for its full length. An opening at the upper and lower ends of the wound, through-and-through irrigation and drainage, may suffice to cure it. Unless free drainage is secured, there is always danger that one by one the union of the sutured planes may give way, and the wound gap open. This yielding of a wound may all occur without the skin separating, excepting at one point. One or more of the planes of fascia alone may separate. These infections are a common cause of ventral hernia. The best way to prevent hernia in these wounds is to prevent infection, and when it occurs check its progress by promptly opening the wound and applying asepsis. *Stitch hole abscesses* should be treated by removal of the offending stitch and if necessary enlarging the needle hole to secure more adequate drainage and asepsis.

Infections secondary to disease of abdominal viscera, such as the intestine, require drainage. Incision for this purpose often leaves a fistula communicating with a viscus, the treatment of which is described elsewhere (see Fistulas and Sinuses, Vol. I, page 304; and fistula of various abdominal viscera).

Diseases of the Umbilicus.—*Infections* of the umbilicus are not uncommon. They should be prevented by cleanliness. The treatment consists in opening as widely as possible the skin folds and washing out the pocket with antiseptic fluid. An alcoholic solution of bichlorid of mercury (1 : 3000) is effective. The fluid should be dried out and the pocket filled with mild antiseptic powder, such as calomel, stearate of zinc and boric acid or formidin. Persistent, recurrent and intractable infections of the umbilicus are best treated by alcohol followed by tincture of iodin, by pure phenol followed by alcohol or by silver nitrate solution. A powder should be used after these. If this treatment fails, excision of the umbilicus may be done.

The surgeon should bear in mind that a discharging navel may mean that there is an internal source of infection, and that the navel is the outlet of a fistula. In operating, preparations should have been made to meet such a condition. Granulation tissue protruding from the navel should be cut away and cauterized.

Fistulas and cysts of the umbilicus may be superficial, extend far into the urachus or round ligament of the liver, or communicate with intestine or other hollow viscera. Small superficial pouches, lined with mucous membrane, may be defined by the probe and attacked from the outside. The lining may be dissected out or destroyed with the sharp curet and iodin packing. Deeper disease must be attacked from the peritoneal side. Preliminary to such an operation the umbilicus should have been well cleansed and sterilized with iodin. An incision is then made, preferably at the left side. When the peritoneum is reached it may be possible to remove the fistulous tract or cyst without invading the peritoneal cavity. Usually the peritoneum will require to be opened. The diseased area is then excised from behind forward without opening it; and the wound closed layer by layer. In making this excision, the transversalis fascia should be spared as much as possible in order to have adequate tissue for an effective closure.

Tumors of the umbilicus should be treated as elsewhere. Papilloma, sarcoma, dermoid and carcinoma should be excised.

Diseases of the Urachus.—*Fistulas and cysts* may be connected with the umbilicus or bladder. They should be treated the same as those described above connected with the round ligament of the liver or other umbilical structures. The treatment consists in eradication of the lining mucous membrane or in dissecting out the fistula or cyst. This operation will often lead to the bladder wall. It is not well to leave a pocket communicating with the bladder, but the dissection should be completed down to the bladder mucous membrane. Before operating on such conditions urinary obstruction, such as enlarged prostate, urethral stricture, or stone, should be cured.

Tumors of the Abdominal Wall.—*Nevus*, *fibroma molluscum*, *carcinoma* and *sarcoma* should be treated as elsewhere. *Lipoma* may arise from the fat just outside of the peritoneum, and by growing into the abdomen demand relief for intra-abdominal tumor or by growing outward simulate or cause hernia. Such tumors should be removed early. Lipoma, developing in the other fatty layers of the abdomen, should be excised because of its tendency to enlarge indefinitely; and *lipoma of the epigastrium*, even though small, when close to the peritoneum, should be removed because of the possibility of its producing reflex gastric disturbances. Fibroma, which commonly appears connected with the posterior sheath of the rectus muscle, is best removed; if not excised it may continue to grow and reach a large size, although it usually does not become larger than a hen's egg. *Fibrosarcoma* commonly grows from the posterior layers of fascia but tends to push toward the skin. It should be removed early and completely even though a plastic operation for closure of the opening is required. The fact that sarcoma grows in the abdominal wall is one of the most pressing reasons for subjecting to excision the presumably benign tumors. *Echinococcus cysts* and *actinomycosis* require excision as elsewhere.

Excessive Abdominal Fat.—The treatment of this condition should first have been hygienic living, which would have prevented the disease. The next best thing is dietary and hgyienic treatment. Unfortunately many aggravated cases have not the moral stamina for the latter. Supports by belts and bands, to carry a pendulous abdomen, are employed. The surgical treatment consists in excision of the excessive fat. This may be carried out in one operation or several. The first operation should remove a transverse ellipse from the lower part of the mass. This may extend all the way across the front of the belly. By lifting up in the hands a mass of fat the surgeon may estimate with the eye how much may be removed without making tension on the sutures closing the wound. A lower transverse, slightly curved incision should be made with its convexity just above the pubes. By drawing down the tissues above, it may be estimated where the upper incision is to be made. The excision should be carried down to the fascia covering the muscles (Fig. 1204). The opening in the skin should be somewhat larger than the floor of the wound to give good approximation. Bleeding should be checked by fine ligatures. The wound should be closed by running sutures of catgut in one or more tiers. The skin may be closed with a stronger suture. A drain should be left in the two corners of the wound.

The same operation may be done laterally on each side, the ellipse running vertically or again transversely. Such an excision may be carried also down upon the thighs. In making a median abdominal section in the obese, a vertical ellipse of fat may be removed in the middle line as a part of the operation.

Although these wounds seem poorly supplied with blood, they heal well, and without postoperative discomfort.

FIG. 1204.—EXCISION OF ABDOMINAL FAT IN ADIPOSE AND PENDULOUS ABDOMEN.

A wedge of fat, as indicated by the lines of incision, is removed down to the deep fascia covering the abdominal muscles. The transverse wound is closed by a deep and a superficial layer of sutures.

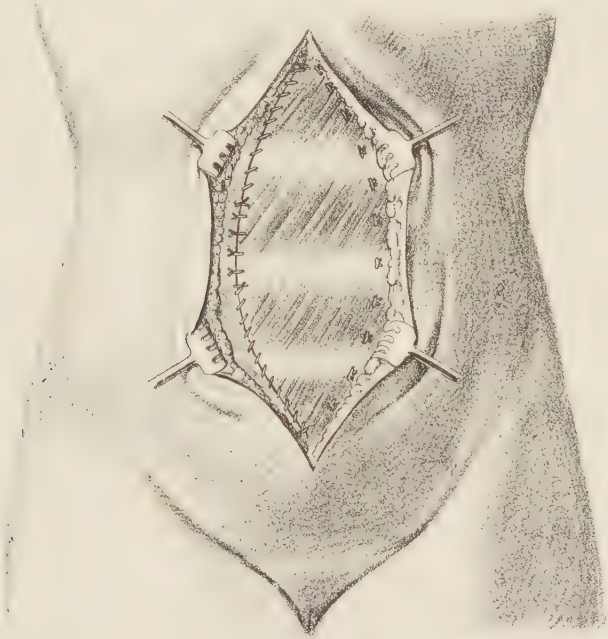

FIG. 1205.—OVERLAPPING OF FASCIA IN TREATMENT OF RELAXED ABDOMEN.

Relaxed and Pendulous Abdomen.—This condition is often associated with excessive fat in the abdominal wall and the operative relief of the two conditions may be combined in one operation. In other cases there is no excess of fat, or, indeed, the abdomen may be quite lean. When hygienic treatment, exercises, electricity and massage have failed, operation should be done.

A median incision is made from a point midway between ensiform and navel down to the pubes. In mild cases, the peritoneum need not be opened. The aponeurosis should be split, overlapped, and sutured, thus drawing the two recti closer together.

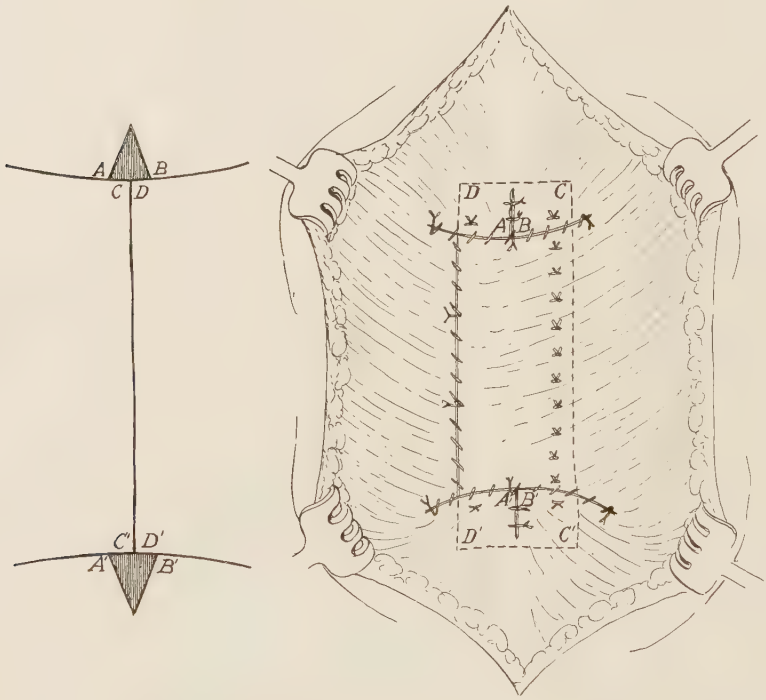

Fig. 1206.—Transverse and Vertical Overlapping of Fascia and Muscle in the Treatment of Relaxed Abdomen.

The two flaps *DD'* and *CC'* are overlapped, thus diminishing the transverse dimension. The vertical dimension is reduced by drawing downward the upper lip of the upper transverse incision and upward the lower lip of the lower transverse incision.

In more pronounced cases, the anterior sheaths of the recti muscles should be incised at their inner borders and separated from the front of the muscles. The anterior sheaths of the muscles should be carried across the median line, and one sewed behind the other. This overlapping shortens the transverse dimension of the abdominal wall, and brings the two recti together (Fig. 1205).

In the more aggravated cases, the median incision should open the abdomen. The superficial fascia should have been dissected free from the deep fascia. A transverse incision, about 10 cm. (4 inches) long, or longer, should be made at either end of the median incision (Fig. 1206). This forms two abdominal flaps, composed of everything but skin and superficial fascia.

These two flaps are overlapped, one in front of the other and held by two vertical rows of sutures. The sutures may come out through the semilunar lines. To take up the vertical slack, the transverse wounds are overlapped in the same way. Mattress sutures combined with continuous sutures of chromicized catgut are used.

Relaxation of the abdominal wall, which is commonly seen in the lower abdomen, and is due to a stretching of the fascia of the external oblique muscle, may be cured by the operation devised by R. C. Coffey (Keen's Surg., Vol. VI, page 441). The fascia of the external oblique is split in the direction of its fibers on either side, the two incisions converging toward the pubes. The fascia is separated from the internal oblique, and the outer lip of the wound is drawn under the muscle and sutured. The inner lip is drawn outward and sutured, overlapping the muscle as a flap. Chromicized catgut sutures are used (Fig. 1207).

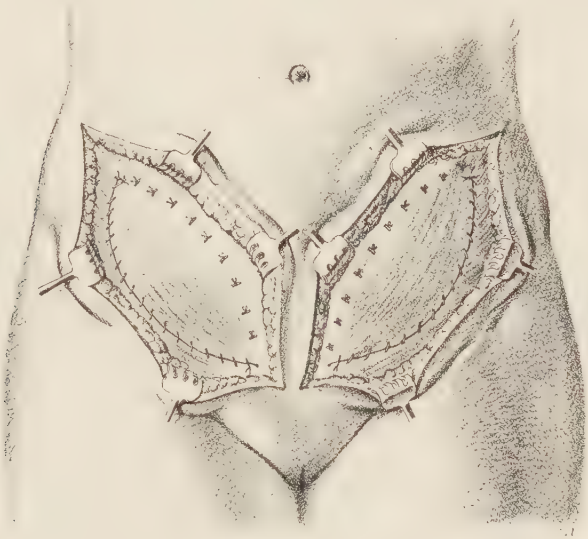

Fig. 1207.—Double Flap Operation for the Cure of Relaxation of the Abdominal Wall.

Before performing these operations the patient's intestinal condition should have been improved by treatment to minimize the amount of gas.

THE PERITONEUM

The peritoneum is a membrane, covered with endothelium on its free surface, which lines the inside of the abdominal cavity and covers the intestines and other abdominal viscera. The total area of the peritoneum is nearly as great as that of the skin. It secretes a lubricating fluid which permits the surfaces to glide over one another. Disease is capable of much altering the amount and character of this fluid. The peritoneum has the power to absorb fluid in large amounts, intoxicating the system with septic fluid or simply removing benign fluid. Absorption takes place chiefly in the upper part of the abdomen, through the peritoneum of the diaphragm and omentum especially. For this reason, when absorption is desired, the lowered-head position is indicated; when the absorption of septic material is to be prevented, the elevated-head position is indicated.

The sensory nerve supply of the peritoneum varies in different parts. The parietal peritoneum is very sensitive. The peritoneum of the stomach, intestines, mesentery, gall-bladder, anterior surface of the liver, the uterus, broad ligaments, tubes, ovaries,

urinary bladder and omentum is practically insensitive to operative attack, although distension of the peritoneum of any of these organs by a distending force operating within the lumen causes the pain known as *colic*.

Injuries of the Peritoneum.—*Traumatism of the peritoneum* is capable of producing a local inflammatory reaction which requires for its treatment, only rest the same as in other endothelial-lined sacs. The traumatism of operation may be sufficient to cause an exudate to be thrown out and adhesions to form. This may be taken advantage of when it is desired to cause adhesions. By leaving any foreign body in contact with the peritoneum for a few hours adhesions will be thrown out around it, and the adjacent peritoneal surfaces will become agglutinated. A sufficient degree of irritation may be produced at once, by vigorously rubbing the peritoneum with a sponge or scraping it with a knife, to cause adhesion to the surface which falls against it. If both surfaces are thus irritated the result is still more assured.

This peculiarity is made use of (1) for the purpose of walling off certain parts of the peritoneum, (2) for the purpose of causing the mechanical fixa-

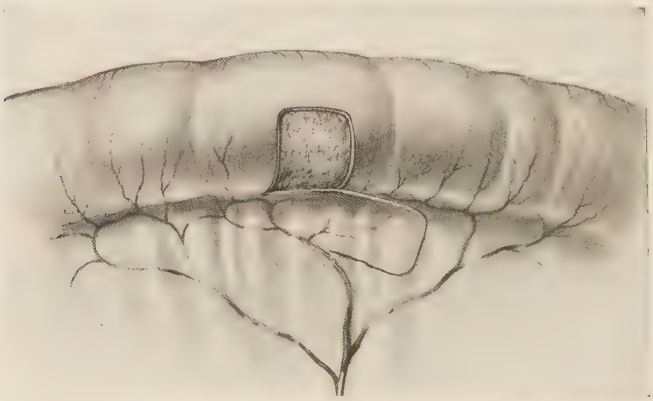

Fig. 1208.—Denuded Surface of Intestine to be Covered.
A flap of peritoneum is marked out on the mesentery.

tion of organs, and (3) for the purpose of securing circulatory communication between two organs or surfaces. Infections are confined and prevented from spreading by this process. In the treatment of prolapses and displacements, and in the suturing of one surface to another, this principle is used. Anastomoses and short-circuiting of the circulation may be secured in this manner, as in cases in which there is portal or hepatic obstruction, the liver and omentum are caused to become adherent to the abdominal wall, vessels develop in the adhesions, enlarge and carry the blood of the abdominal organs directly back to the systemic circulation around the hepatic obstruction.

All suturing of peritoneal surfaces, so important in stomach and intestinal operations, depends upon the irritation caused by the incisions through the peritoneum and upon the irritation of the sutures, to cover the wound and the sutures with plastic fibrin within a few hours, or even minutes, after the close of the operation. Aseptic foreign bodies left in the peritoneum thus become encapsulated (see Adhesions, page 520).

Denuded surfaces of peritoneum, such as occur, on the intestine sometimes in connection with operations for hernia, may be covered by sliding a leaf of

the peritoneum of the mesentery over the denuded surface as a plastic flap and fixing it with sutures (Figs. 1208, 1209 and 1210). This operation should be done with especial attention to the blood-supply of the flap. Such a plastic operation as this is often well worth while in preventing adhesions which will inevitably follow if the operation is not done.

Fig. 1209.—Mesenteric Flap is Turned up and Sewed into Denuded Area.
A second incision is made to secure a secondary plastic peritoneal flap.

Richardson (Bull. Johns Hopkins Hosp., xxii, 283) made an incision through the peritoneum close to the bowel, dissected up the peritoneum and sewed it over the raw surface (Figs. 1211 and 1212). These operations should not injure the blood supply in the mesentery. They are particularly ap-

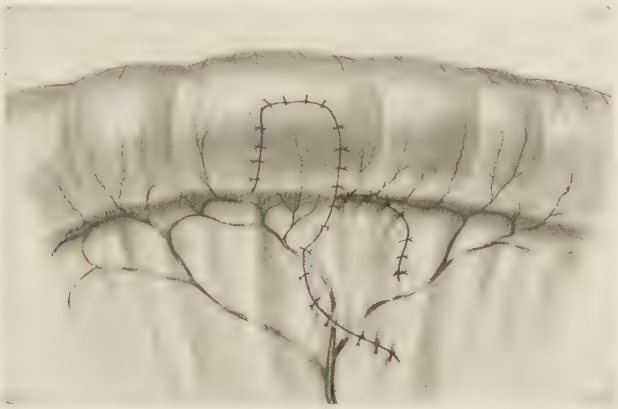

Fig. 1210.—Completed Peritoneal Plastic for Covering Denuded Surface on Intestine.
Showing possibilities of plastic flaps of peritoneum.

plicable to the small intestine and to the mesentery which contains a fair amount of fat.

Another material which may be used for this purpose is omentum; but this leaves the bowel adherent to the omentum unless an omental graft is

used (Fig. 1213), and that is less apt to succeed than an operation with an attached flap.

Peritoneal grafts can be taken from the omentum, broad ligament, mesocolon, hernial sac, hydrocele sac, pelvovesical fold, or any other area where relaxed peritoneum is to be found. The operation of grafting is done by cutting out a piece of peritoneum about one-third larger than the area to be

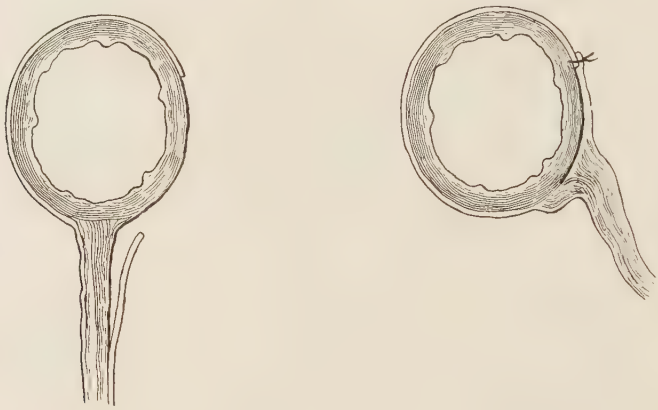

Fig. 1211.—Covering Denuded Bowel with Sliding Flap of Peritoneum.

covered. It is sewed in place and the area from which the graft is taken is closed by sutures.

In structures in which motility will not be hampered an omental graft is best used. Thus in denuded surfaces of the mesentery, stomach, or duodenum the edge of the omentum may be sutured to the surface and a peritoneal covering promptly secured (Fig. 1214).

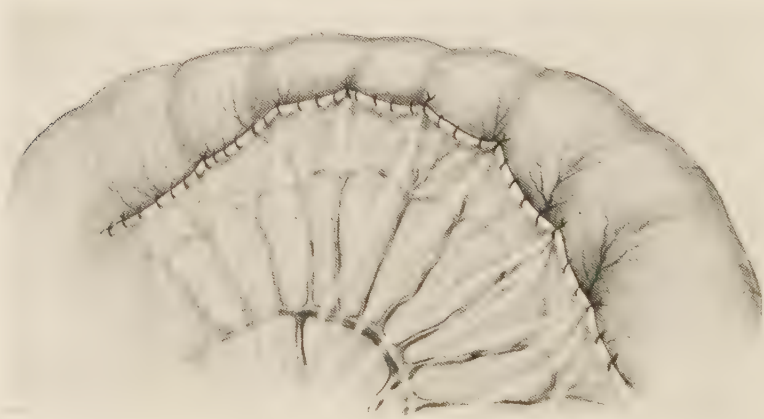

Fig. 1212.—Sliding Flap of Peritoneum Sewed in Place to Cover Denuded Area on the Intestine.

Foreign Bodies in the Peritoneal Sac.—While foreign bodies, such as aseptic sponges and instruments, may remain a long time without producing serious harm, they are apt sooner or later to cause mischief. They tend to work out through the skin or to penetrate into some hollow viscus such as

the intestine or bladder. Death results in many cases from these accidents. Small bodies such as bits of thread, cotton fibers from sponges and bits of metal from instruments cause no appreciable harm, still they undoubtedly are capable of provoking adhesions. For these reasons operations should be

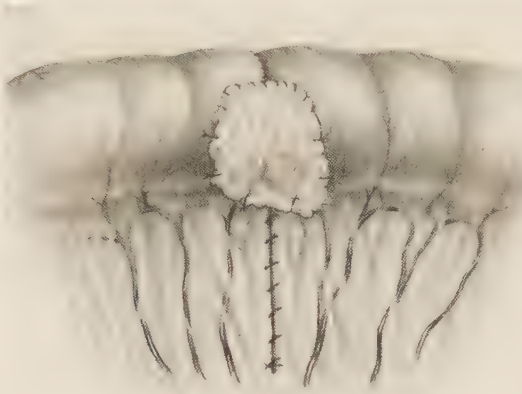

FIG. 1213.—GRAFT OF OMENTUM USED TO COVER A DENUDED SURFACE ON THE INTESTINE.

conducted so as to minimize this danger (see Toilet of the Peritoneum, page 515).

An aseptic foreign body, known, or even suspected to be in the peritoneal sac, should be sought for even though the quest involve the reopening of the



FIG. 1214.—GASTROHEPATIC OMENTUM USED AS A FLAP TO COVER WOUND AFTER EXCISION OF ULCER OF STOMACH.

wound or the making of a new incision. A "body" may be defined as a nonabsorbable object larger than 3 mm. (1/8 inch) in diameter (for Bullet Wounds, see page 535).

Peritonitis.—The treatment of peritonitis cannot be grasped unless one has an understanding of the anatomy of the peritoneum, its relation to the viscera, and the physiology and pathology of inflammations. This should be borne in mind: the danger of peritonitis is not so much from the absorption of toxic materials from the peritoneum as from paralysis of the intestine due to infiltration of its wall with the products of inflammation (J. P. Warbasse, "Acute Peritoneal Infection and its Relation to Acute Intestinal Obstruction," Am. Jour. Med. Sciences, Vol. CXXX, 1905).

Acute peritonitis demands two essentials in its treatment: (1) removal of the source of infection, and (2) prevention of the spread of the disease. The removal of the source of the infection is discussed under the treatment of the diseases of the various abdominal organs. Whether the source be a focus of gangrene or the perforation of an unsterile hollow viscus, the culture-bed or the infective cavity must be eliminated or closed off from communication with the rest of the peritoneum. A collection of pus or other infected fluid must be regarded as a focus of infection so long as it possesses the power of provoking leukocytosis and serous exudate; for so long as it can do this it can increase its bulk and invade new fields of peritoneum. Infected fluid, not walled off by adhesions, must also be regarded as an infective focus to be eliminated. In other words, any collection of infective bacteria, capable of extending the peritonitis, if so situated that it can be removed from the abdominal cavity, should be removed. This means that abscesses and other collections of fluid, containing active organisms should be evacuated.

Adhesions, separating the infected from the uninfected zones, are the salvation of the patient. Were it not for peritonitis, infection of the peritoneum would be fatal in most cases. Operations for the removal of the focus of infection should be done with directness and gentleness. Adhesions should be spared excepting those which prevent access to the focus. The peritoneum should be preserved from traumatism as much as possible. And the operation should be short. Irrigation is not advisable in most cases. If these conditions cannot be complied with, the surgeon may choose one of two preferable courses: (*a*) gently to expose the focus of infection and drain it without disturbance of the surrounding peritoneum; or (*b*) to do no operation at all, but to minimize peristalsis, eliminate toxins, and conserve the resistance of the patient.

To prevent spread of the infection to uninvaded peritoneum, several means are at the service of the surgeon. The first and most important is that already described; removal of the infective focus. When this has been done, or when it seems best not to do it, peristalsis should be inhibited. The most effective way to accomplish this is by keeping the bowel empty. The stomach should be washed out, and the lavage repeated so long as nausea is present. Food by mouth should be withheld, and nourishment given by rectum. Laxatives should not be used.

In connection with the above measures, the patient should be placed in the elevated-head position and proctoclysis should be instituted. These represent the general principles of the treatment of acute peritonitis.

The results of operation performed during the first hours of peritonitis are most satisfactory. This is the time of preference for operation. Operation should be done then. If operation can be done within the first twelve hours of the infection and the cause eliminated—a perforation closed or an appendix removed—recovery should be expected. The results of surgery at this stage are brilliant.

There comes, after the first twenty-four or thirty-six hours of peritonitis the long period of constitutional reaction, in which the contest goes on between bacteria and toxins on one hand and the antitoxins and other resisting forces of the body on the other hand. In this contest there is a balancing of forces. This period of uncertainty continues during the second, third, fourth and fifth days of the disease. Then, as the natural resistance of the body overcomes the invasion of infection, there is a terminal period in which operation may again be done more safely. To operate for peritonitis during the period of acute struggle brutally upsets the balance of the contest and disconcerts the plan which Nature has employed for eons to preserve the race. Operations, after the first thirty-six hours of the disease, on the third, fourth or fifth days, are highly dangerous.

If operation is to be done for the acute disease it should be before the first thirty-six hours. After that the surgeon should work with Nature, and do what Nature is trying to do. The patient must be kept quiet, peristalsis must be inhibited. This means that food must not be given by mouth. Purgation and laxatives are absolutely contraindicated; they are capable of doing most serious harm. If food and purgatives have not been given from the beginning, the patient's chances of recovery are multiplied many fold.

The distressing cases are those in which the fundamental principles have been violated, and a patient has been given food or purgatives. Here the surgeon must decide between a hazardous operation and the ineffective restoration of intestinal quiet in a bowel which has been fed and purged. These are the cases which die in the hands of the surgeon.

Gastric lavage should be used to remove remnants of food, and backed up duodenal secretion. The importance and value of this treatment are very great.

Proctoclysis, to instill fluids into the bowel, restores the bodily fluids, quenches thirst, assuages hunger, dilutes and washes out the toxins from the blood, provides fluid for peritoneal and tissue serum, fills the vessels in the interest of more vigorous circulation, and by reducing temperature contributes to the comfort of the patient. As much as 8 or 9 liters (16 or 18 pints) should be absorbed by an adult in twenty-four hours.

Alonzo Clark reduced the mortality of peritonitis by the use of opium. Later Crile explained the mechanism of its action, and showed that during the period of acute toxic struggle it performs two important functions: (1) It inhibits peristalsis, and (2) it protects the patient from the shock, the nerve depression, and loss of energy, which are caused by the centripetal impulses, flowing inward to the nerve centers from the sites of disease. In severe cases, which can not be subjected to ordinary surgical treatment, the patient may be saved by deep narcotization with opium or morphin. Crile advocated reducing the respirations to 12 or 14 per minute. With the patient thus narcotized and rendered immune to the nervous shocks of the disease, the intestine quiet, and fluid flowing into the bowel from below, a large proportion of the cases once regarded as hopeless may be saved.

After the subsidence of the acute attack any collection of pus which remains should be evacuated. This will be found in the form of an abscess. Its drainage should be accomplished with the least possible traumatism. The elevated-head position is useful. If a collection of pus is diagnosed, and upon opening the abdomen it is found to have free uninfected peritoneum between it and the wound, a drain should be placed in the wound and carried down to the peritoneum, but the abscess should not be opened. Soon the abscess will empty itself through the drainage tract. If it does not, the

drain may be removed after adhesions have formed, and a tube passed down to the abscess.

In *local acute peritonitis*, removal of the infective focus, drying of the peritoneum by gentle sponging if fluid is present, closure of the wound with a small wick drain which is quite as much for the abdominal wall as for the peritoneum, and inhibition of peristalsis are the essentials of treatment.

A. J. Ochsner showed that peristalsis could be best inhibited by washing out the stomach and withholding all mouth feeding. Not even a drop of water is given by mouth. Fluids are supplied by the rectum. No laxative is given. Movements are secured by enema. Nutrient enemata supply food. This method of treatment when applied early and consistently has the power of localizing an infection until it becomes walled off and can be operated upon with safety. This method is of great value to the physician when a surgeon cannot be had. It should be employed after operation in diffuse peritonitis, and in cases of peritonitis in which operation must be deferred.

In *local suppurative peritonitis*, the abscess should be evacuated through the part of the abdominal wall which is nearest the abscess. This should be done without invading the peritoneal field external to the abscess. If the focus of infection can be removed without breaking through the adhesions which confine the abscess, it should be done. A drainage tube should be placed in the opening and the wound closed about it.

In neither of these local conditions is the elevated-head position necessary. Proctoclysis need not be used unless the patient is much depressed. Food by mouth should be withheld for one or two days.

In *diffuse suppurative peritonitis*, there is a pus-producing infection which is more acute than local suppurative peritonitis, as manifested by the fact that limiting adhesions cannot form fast enough or firmly enough to confine the pus. The surgeon has to do with free pus in the peritoneal cavity and a spreading infection. (This is sometimes erroneously called "acute general peritonitis" and "acute septic peritonitis;" the former of which never exists, and the latter of which is fatal before pus develops.) This is the common form of peritonitis, which supervenes upon improper treatment of the local form, which might have been checked while still localized, but which in most cases showed a disposition to spread from the beginning.

The disease should be recognized and treated early. Treatment, to be successful, should be inaugurated in the first twenty-four hours; in the first twelve hours, if possible. Operation should be done at once. Tenderness, muscular rigidity, pain—these are the signs upon which the surgeon should act. His experience with the disease should enable him to make the diagnosis upon these and the general appearance of the patient. He should operate upon the signs of the disease and not demand that the signs of dissolution be present before proceeding. Most cases are due to appendicitis or perforation of the intestine or stomach.

There is already a beginning intestinal paresis. This means absorption of toxins which in turn causes vasomotor collapse. When these patients die, it is from vasomotor paresis. If there is much vasomotor depression, the patient should be fortified for operation by measures for overcoming shock. A venous infusion should be given, and this followed by adrenalin (see Shock, Vol. I, page 213). Preparations for postoperative transfusion of blood should be made. The anesthetic should be given so as to depress the patient as little as possible. When shock is present, as it usually is, much of the patient's blood is in the relaxed vessels of the splanchnic system. When the abdomen is opened, these vessels relax still more and

suck in from the rest of the circulation the blood that is necessary to keep the patient alive. This is the "peritoneal collapse" so familiar to surgeons.

The abdomen should be opened at the site of the disease. Blood should be saved. If the focus is an inflamed appendix, it should be tied off and removed (see Appendicitis, Vol. III). If the appendix is not gangrenous, and is buried in adhesions, it need not be removed if liberating it from its bed will expose to infection uninfected areas of peritoneum. If the focus is a perforation of the bowel or stomach, the perforation should be closed (see Perforation of Intestine, page 566).

Free pus or infective serum in the abdomen should be removed. This is usually best done by gentle suction. Suction may be secured by means of a glass tube on the end of a rubber tube which is connected with an air pump. For this purpose the pump may be connected with a tap of running water or a vacuum bottle exhausted by an electric pump. The suction device used by dentists is most effective. In the absence of suction apparatus gentle sponging may be employed. In most cases the flat sponges used to retract the intestines take up what remains after the first exposure of the focus of infection. In diseases of the lower abdomen the pelvic cul-de-sac should be exposed by gentle retraction of the intestines and sucked dry. For sponging a tubular speculum or proctoscope is useful; it permits sponges to be passed down into the pelvis without scraping over the intestines. Irrigation should be avoided except in rare instances.

If there is much pus, fibroplastic detritus, or products of perforation widely distributed, irrigation with warm normal saline solution is more effective than sponging and does less damage to the peritoneum. If irrigation must be employed, it should be free and copious; for, inasmuch as it may disseminate infected matter, it should wash it all out. Fluid should be used until it returns clear and clean, even though several gallons are required. While the irrigation progresses the wound is being sutured.

Drainage should be provided. A cigaret drain or tube containing loose wick should be carried down to the site of the primary disease. A similar drain or a glass tube should be placed in the pelvis if pus were found there. The abdominal wound should be closed about these. Packing the abdomen with gauze is to be deprecated. A copious moist gauze dressing should be applied. This should be changed twice daily while the discharge is profuse. The wick in the tubes should be renewed as often as necessary or the tubes aspirated (see Methods of Securing Peritoneal Drainage, page 524).

Most of these cases do best in the elevated-head position (Elevated-head Position, page 529). But if it cause dizziness or disturbed heart action it should not be used.

The vasomotor disturbance, from which these patients suffer and which always threatens their lives, fills the great abdominal vessels with blood and depletes the peripheral vessels. This gives the pinched facies, the small pulse and the rapid heart. The best means for filling the peripheral vessels is by adding fluids. This is best accomplished by proctoclysis (Vol. III). If the emergency is great, fluids may be given by any of the methods used in shock.

If the emergency is not great, some patients prefer single rectal injections. A small injection of warm solution by rectum every two to four hours is of great value. This should begin with 180 or 240 c.c. (6 or 8 ounces). The patient should be instructed not to expel it unless there is a desire to pass flatus or feces. If it is expelled, a similar amount should be injected within an hour. As the patient becomes accustomed to retaining the fluid

the amount may be increased gradually until 500 c.c. (1 pint) at a time are given. Reversed peristalsis carries this fluid up into the colon where it is absorbed. This method does not entail watching, as does proctoclysis, which is not always comfortable, and for which especial apparatus is necessary.

These patients absorb fluid rapidly. The pulse should be watched and when it approaches the normal in fulness the injections should be stopped. It is possible to overfill the vessels and produce edema of the lungs.

Hypodermoclysis may also be employed; and, if the patient is still struggling against unfilled peripheral vessels, saline infusion in the veins is to be used. Enough fluid should be used to give the heart something to contract upon. The treatment fails unless the surgeon succeeds in filling the vessels outside of the splanchnic system.

This use of fluids is aimed to overcome shock by filling the vessels, to dissolve toxins and carry them off through the emunctories, and to satisfy the thirst of the tissues. It is one of the most important postoperative measures, and undoubtedly aids in the body's struggle against the infection and the effects of the peritonitis.

The stomach should be washed out if there is nausea and vomiting. So long as the contents of the duodenum are running back into the stomach and producing nausea, lavage should be practised. It may be done twice or thrice daily or oftener. It makes the patient more comfortable, eliminates toxic matter, and prevents acute postoperative dilatation of the stomach. As soon as the nausea or vomiting cease, or if they have not been present, lavage may be omitted, and water may be given by mouth. This should be in small amounts at first, and gradually increased from doses of 4 c.c. (1 dram) up. When water by mouth is taken without nausea and vomiting, the saline enemata may be omitted.

As long as nausea is present, food should not be given by mouth. When water is taken without nausea or vomiting after the first twenty-four hours following the operation, diluted milk or other proteid fluid food may be given. Thirty c.c. (1 ounce) may be given every hour, and this gradually increased.

At the end of twenty-four hours, if the patient still vomits, nutrient enemata should be employed. If proctoclysis is still needed, these may be given alternately with it. Once daily the rectum should be washed out with a cleansing enema.

There are cases which are in extremis when seen by the surgeon. If the patient is moribund operation should not be done. If there is some hope, an incision may be made under local anesthesia, and drainage secured with or without suction. Some of these bad cases with intestinal paresis may be saved by adding to the suction and drainage, opening of the intestine and washing out its retained contents (see Ileus below).

In the far advanced cases of peritonitis, in which the skin is cold and moist, the lips dark, the pulse rapid and weak, the temperature below normal, the leukocyte count low, the abdomen distended, respiration exclusively costal, and the mental state apathetic, operation is not to be considered.

Cases of diffuse peritonitis in which the infective focus is eliminated by operation, and in which free pus or detritus has been removed, need not invariably be drained. The abdomen may be closed with only a small drain in the wound down to the peritoneum for drainage of the wound of the abdominal wall.

Iodin in the treatment of peritonitis has found favor in some hands. J. A. Crisler (Trans. Southern Surg. and Gyn. Assoc., 1915) used a 2.5 per cent. solution of pure iodin in alcohol. Theoretically this should produce adhe-

sions and cause decided irritation. Surgeons who use it claim that it does not.

Dichloramin in the treatment of peritonitis is used in 5 per cent. solution.

Hypochlorites of calcium and *soda, chlorinated oil*, and others of the chlorin antiseptics have all been used with more or less success in the treatment of peritonitis.

Sulphuric ether in the treatment of peritonitis has been proved by the French surgeons to be a valuable agent. It is antiseptic; it induces salutary hyperemia; and it minimizes postoperative pain and restlessness. When operation reveals an infected peritoneum ether may be applied after removing the pus or serum. Most encouraging results have been secured by washing out the peritoneal cavity in diffuse peritonitis with a liter (1 quart) or more of ether. In local infected areas and abscesses, as much as 30 c.c. (1 ounce) may be left in the abdomen in the case of children from 5 to 15; and 60 to 120 c.c. (2 to 4 ounces) in the case of adults. The abdomen may be closed, and the ether confined. If a drainage tube is used, the tube may be clamped for a few hours to prevent the escape of the ether. As the boiling point of ether is 20°C. lower than the body temperature, it promptly boils, evaporates and is absorbed by the tissues. It does not, however, materially deepen the general anesthesia although it prolongs the post-anesthetic quiet.

This treatment is not recommended as a part of the routine handling of peritonitis, but as an expedient which some surgeons have found useful.

Camphorated oil has been much used by some surgeons in the peritoneum to provoke a reacti on against infection in cases in which the peritoneum had to be exposed in the.presence of infection. About 30 to 60 c.c. (1 to 2 ounces) of a 10 per cent. solution are used, or 200 to 300 c.c. (7 to 10 ounces) of a 1 per cent. solutioni It seems to inhibit infection, prevent adhesions, and act as a general stmulant.

Recapitulation.—The first essential to save life in peritonitis is early operation by skilled hands. A certain number of cases will subside without operation if the infective origin is self-limiting; but the peritonitis associated with necrosis of tissue or perforation of a non-sterile hollow viscus urgently demands operation for the elimination of a constantly acting source of infection. Since the nature of the infection cannot be known except by operation, this must be regarded as the essential procedure.

In acute peritonitis, death is caused by (1) absorption of toxic products; (2) poisonous effects of acid products; (3) fatigue of the nervous system, and (4) insufficient nourishment.

(1) Toxemia is to be combatted by drainage, increasing the bodily fluids, and by all of the measures which antagonize infection. (2) Acid by-products are to be eliminated by excessive intake of water by all channels except the stomach. As much as 2000 c.c. of solution may be given daily by hypodermoclysis. The acidosis may be neutralized and nourishment supplied by proctoclysis with 5 per cent. solution of sodium bicarbonate and glucose. (3) For the nervous fatigue the patient must have sleep. Morphin at night may be given freely enough to insure rest.

For the case seen early by the surgeon, the steps should be prompt and rapid operation, minimization of shock, removal or elimination of the source of infection, and the institution of proctoclysis.

The treatment formulated by Ochsner is advisable in the cases which have passed the period for early operation, provided the cases are of localized infection such as occur with infections of the appendix and gall-bladder; but in peritonitis with strangulation, gangrene of the bowel, perforation, or with diffused seropus, operation should precede the rest treatment.

The later cases which are treated by the method of Ochsner, should have an half hourly or hourly pulse record kept. If the pulse-rate shows a steady tendency to decline during the course of two or three hours, operation may safely be postponed, but if the pulse-rate shows a steady increase, immediate operation is indicated. Cases which are clearly moribund should not be operated upon.

An autogenous vaccine may be made from the exudate and administered as soon as possible. Its value is still problematical.

The stomach should be kept washed out so long as nausea is present.

Isolated abscess should be opened. Diffused pus should be liberated.

Through-and-through irrigation of paralyzed intestine should be practised.

Paralytic ileus, caused by peritonitis, or traumatism is one of the most distressing conditions the surgeon is called upon to treat. It is due (1) to infiltration of the wall of the intestine with leukocytes, serum and the other products of inflammation; (2) to the effect of extraintestinal and intraintestinal toxins upon the motor nerves; and (3) to traumatism to the intestine, peritoneum and abdominal nerves. Dilatation of the bowel aggravates the paresis. The treatment described above is directed to prevent this ileus. When there is a degree of distention which looks incapable of recovery unless given mechanical relief, the bowel should be opened and emptied. The experienced surgeon will recognize this at the first operation. In other cases it will be apparent after operation that the patient has a dangerous degree of ileus which is not yielding to enemata or other measures. Recovery may be secured for some of these desperate cases by the following treatment:

The intestine is exposed at the lower and upper limits of the ileus. A purse-string suture of silk is introduced in a circle on the wall of the bowel. Through the middle of this circle, a large trocar and canula are thrust, and the contents of the bowel evacuated. At the same time the purse-string is tied down to prevent leakage. The canula should be connected with a rubber tube as soon as the trocar can be withdrawn. In lieu of such an arrangement, an opening may be made in the circle with a slender knife, a large catheter or stomach tube inserted into the bowel and the suture tied down upon it. This operation should be repeated at the other end of the paralyzed segment of bowel. The intestine should be washed out through these two tubes, fluid passing in at the upper and out at the lower. If the interval between the two is too great for such irrigation, one or two similar drains may be introduced between them.

These tubes should be left in place and fixed so that they will remain. Irrigation with sterile water or saline solution should be practised once or twice daily, or oftener if indicated. In the mean time the tubes may be closed. Castor oil may be introduced through one of the tubes. Twenty-four hours of this treatment may make a striking change for the better. Thirty-six hours should determine whether it succeeds or fails. At the end of two days the patient may be quite convalescent. This is the rational treatment of this condition, and it should not be denied any patient who has a grain of hope. I have seen patients recover under it who otherwise, it seemed, would surely nave perished.

This method has been modified by Stewart, who fixed the half of a Murphy button into the bowel and connected a rubber tube with it by means of the other half. Kocher made one opening in the upper part of the jejunum and another in the lower part of the ileum: he washed the bowel through and then closed the openings. It is always desirable to have such a tube in the colon. This may often be introduced through the stump of the appendix.

The patient may later be given predigested food through the tube. Such a tube introduced into the colon lends itself especially for washing out the bowel, administering fluids, and giving predigested food. There is no limit to the time the tube may be left in place. It causes no especial harm and, if fixed by a suture, will not be extruded by peristaltic contractions.

The *medical treatment* of the inhibition of peristalsis from peritonitis has much to offer. In the cases in which operation is not positively called for, such drugs as *pituitrin* are used with good effect. A fresh solution of pituitrin should be used. It is given hypodermatically in the muscles. The dose is 1 c.c. repeated every one or two hours up to three or five doses. Not more than five doses in twenty-four hours need be given. In mild cases of obstruction the passage of gas occurs often after the second dose.

There are *other sequelæ of acute diffuse suppurative peritonitis* besides paralytic ileus, which require treatment and which may tax the surgeon even more than the original disease. *Localized peritoneal abscess* should be opened as soon as the disease has become quiescent and the abscess can be evacuated without invading the general cavity. *Secondary abscess* in other organs should be opened at once. *Infections of the retroperitoneal lymphatics* do not require local treatment unless they give rise to abscess. *Empyema, abscess of the lung* and *phlebitis* should receive the treatment already described. *Intestinal obstruction,* developing as the result of adhesions, angulation, or bands, should be treated at once by exposure of the site of trouble and relief of the occluded bowel. *Intestinal fistula* is described below.

Subphrenic (subdiaphragmatic) *abscess* may be opened (1) through the abdomen below the costal arch; (2) through the pleura; (3) through the chest by pushing up the pleura, and incising through the diaphragm, without opening the pleura; and (4) by incision in the lumbar region.

The abscesses which are usually due to perforation of the stomach, which bulge forward in the epigastrium, may be opened through the anterior abdominal wall. This should be by a systematic operation, as described for entering the abdomen, and not by a simple incision, as described for opening an abscess. The general peritoneal cavity should not be invaded. The wound should be retracted and the pus sponged out. The cavity will usually be found to extend far posteriorly, and a drain may be introduced through a counter-opening in the flank, crossing in front of the kidney. The cavity may be washed out with warm saline solution. A drain should be left in the anterior opening.

An incision along the costal margin is indicated for abscesses which appear to be located laterally.

In most cases the abscess lies up so close beneath the diaphragm that it is best reached by incision through that structure. An incision 15 cm. (6 inches) long is made between the ninth and tenth ribs on the right side, or between the seventh and eighth ribs on the left side. The middle of the incision should be in the midaxillary line, or at the point where the aspirating needle found pus. About 10 cm. (4 inches) of each rib is excised. The pleura if uninfected should be protected, and the diaphragm exposed (see Exposure of the Diaphragm, page 467). The diaphragm should then be incised at the place where the abscess bulges upward, the abscess washed out and drained. The abdominal incision may be combined with this in some cases.

Opening between the ribs gives adequate room only when the abscess has advanced through the diaphragm. If there is no cellulitis of the lower thorax, resection of a rib is necessary to secure adequate access. The pleura comes down to the tenth rib in most cases in the posterior axillary and midaxillary

lines. Still the tenth rib may be resected, and the pleura pushed upward. The ninth rib may be resected between the anterior and middle axillary lines, and the exposed pleura pushed up. In operating upon these ribs the periosteum should be left attached to the pleura (Figs. 1215 and 1216). After elevating the pleura the diaphragm may be incised, and drainage provided. Resections of both ninth and tenth ribs may be done.

In cases in which it is necessary to pass through the pleura, if the two pleural surfaces are not united by adhesions, they should be sewed together so that a space is left through which the diaphragm may be approached without infecting the pleural sac (Fig. 1217). Or the diaphragm may be sutured to the chest wall.

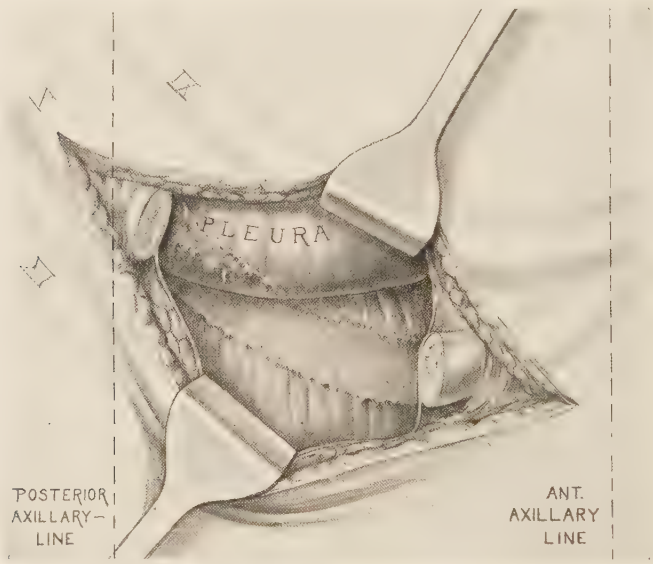

Fig. 1215.—Operation for Exposure of Subphrenic Abscess.

The retractors are in the right midaxillary line. A section of the *X* rib has been removed. The periosteum has been left. The lower reflection of the pleura is seen presenting in the wound. The diaphragm forms the floor of the wound.

Acute nonsuppurative peritonitis is best treated by the methods used in acute peritonitis, and especially the method of A. J. Ochsner (page 548).

Chronic peritoneal abscess is usually a relic of acute peritonitis or some slowly acting infection. It should be evacuated.

Tuberculous peritonitis should be treated by measures directed to the patient's general condition (see Tuberculosis, Vol. I, page 276). The *acute miliary* and the *dry* forms are medical, rather than surgical diseases. The *exudative form with serum* in the abdomen (ascites) is surgical (1) when hygienic and medical treatment fail and (2) when the amount of fluid is so great as to cause discomfort or interference with function.

The same hygienic treatment as is given to a case of pulmonary tuberculosis should be employed. Operation should not be done until this is given a full trial (three to six months), unless the ascites is distressing or steadily progressing. Often the fluid will disappear as the patient's resistance improves. Operation is by no means essential for a cure.

The treatment of cases, not cured by hygienic and medical measures,

demands that an examination and inquiry into the history shall be made to determine, if possible, the location of any primary focus of the disease. The abdomen should be opened in the region of such primary focus, or, if none is found, a median operation between the pubes and umbilicus should be done. After the ascitic fluid has been removed by sponges, tuberculous foci should be sought. If any organ or region is preponderatingly affected with tuberculosis and its removal is easily accomplished it should be removed. This rule does not apply to any procedure so serious as resection of the intestine unless by the operation all foci can be removed. It applies to such structures as the Fallopian tubes, appendix vermiformis, or ovarian peritoneum.

The most effective operation is the simplest. It consists in removal of the ascitic fluid. The presence of the fluid in the peritoneum is a natural reaction against the disease. As the fluid becomes old, it probably loses its bactericidal power. Withdrawal of the old fluid is followed by the formation of

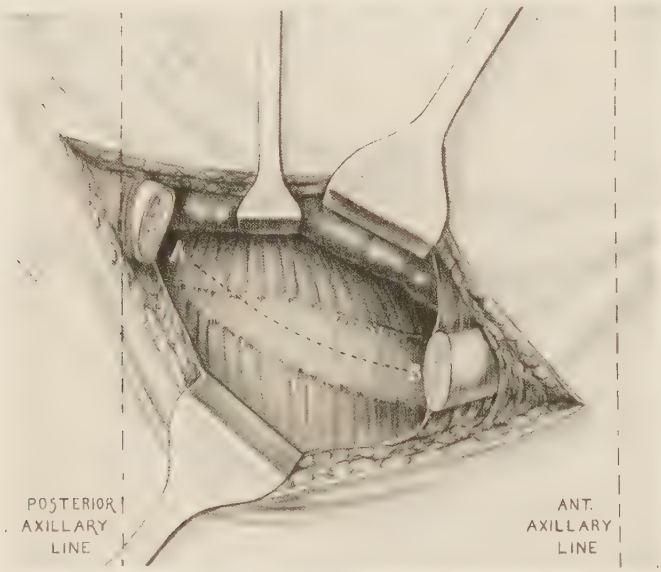

FIG. 1216.—SUBPLEURAL DIAPHRAGMOTOMY.
AB, Incision in diaphragm for exposure of subphrenic abscess.

new fluid which has greater antitubercular properties. The abdomen should be closed without drainage.

Operation is done only when there is ascites, and ascites is usually present only with disseminated disease. An opportunity to perform a resection of any tuberculous area is rarely offered. There are two exceptions: When the Fallopian tubes or vermiform appendix are involved, they should be removed, and the opening cauterized and occluded. This is recommended because there is apt to be a tuberculosis of their mucous membrane which may continue to reinfect the peritoneum. After exposing all of the diseased peritoneum to the air, the abdomen is closed without drainage. Operation is best done after the primary febrile stage has passed, but before the patient becomes debilitated and other organs involved.

It is entirely adequate to open the abdomen, evacuate the fluid, and close the wound. Nothing more need be done in a surgical way. Systematic

treatment with tuberculin should be begun a week or two after the operation, and continued after the patient leaves the hospital. Under this treatment, combined with hygiene, 50 per cent. of cases may be cured, and most all patients benefited.

A. Florio (Gazzetta degli Ospedalie delle Cliniche, Jan. 2, 1910) aspirated the ascitic fluid and then injected air into the peritoneal cavity in amount about equal to the fluid withdrawn. The air is absorbed in from six to twenty-three days. The benefits of the operation seem to be as great as by laparotomy. For this operation the same apparatus may be used as is employed in the similar treatment of pleurisy with effusion (page 401).

In the *suppurative form* there is either a breaking down of tissues or a mixed infection. It is best not operated upon unless a distinct well-circumscribed wall is present, and then the treatment should be that described for tuberculous abscess (Vol. I, page 281).

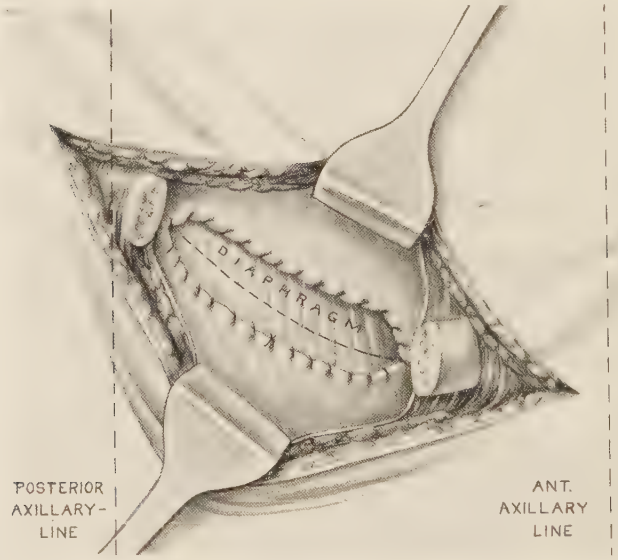

FIG. 1217.—TRANSPLEURAL DIAPHRAGMOTOMY.

Operation for transpleural incision of subphrenic abscess. Showing line of incision in diaphragm, after pleura has been incised and the parietal and diaphragmatic layers of the pleura have been sewed together.

The local application of tincture of iodin (10 per cent.) has proved effective in the hands of some surgeons. The abdomen is opened, and emptied of fluid. As much of the tuberculous area as is easily accessible is painted with the iodin, which is then wiped off with gauze. The abdomen is then closed. Following the treatment the abdomen becomes distended with fluid, which in the course of two weeks may be expected to disappear. The tenderness subsides. The patients may be allowed up three weeks after the operation to resume hygienic treatment. Distinctly tubercular organs, such as the Fallopian tubes, should be removed.

The internal use of lime is advocated by French surgeons in connection with other treatment:

Calcium carbonate	0.65 Gm.
Tribasic calcium phosphate	0.2 Gm.
Sodium chlorid	0.15 Gm.

This is given in capsule three times daily after meals. It seems especially effective when anorexia, vomiting, diarrhea, and pulmonary complications are present.

Peritonitis of the duodenal region (region of the pylorus, gall-bladder, head of pancreas, and gastrohepatic area) is usually due, if *acute*, to perforation of the duodenum or stomach or to acute cholecystitis, and requires the treatment of these conditions. The *chronic* form, giving rise to *adhesions of the duodenal region*, may have its origin in disease of the duodenum, gall-tract, pancreatic ducts, or stomach. These adhesions bind together the adjacent structures and cause symptoms usually referable to the stomach. In 1903 I called attention to this condition, and reported cases upon which I had operated (Vicious Peritoneal Adhesions of the Duodenohepatic Region, Brooklyn Medical Jour., January, 1903).

Often the causative disease has healed or disappeared, and there remain only the adhesions. These may be separated by blunt dissection or with knife and scissors, and the duodenum, stomach, hepatic flexure, and gall-bladder, which may all have been drawn into a mass, dropped back into their normal positions. If no evidence of stone, duodenal or gastric ulcer, or stricture is present, the abdomen is closed, and the patient kept supine for two weeks. Great benefit results from the operation. Undoubtedly adhesions form again, but, by keeping the patient supine, they form with the organs in a better position. This is particularly the case when there is an angulation at the upper end of the duodenum, as is sometimes caused by the pyloric end of the stomach becoming displaced to the right and fixed to the structures in the region of the gall-bladder. If the organs tend to fall back into vicious position after the adhesions have been divided they may be fixed with a suture wherever necessary.

Tumors of the Peritoneum.—The primary tumors are rare; most are extraperitoneal; they should be treated according to the rules already given (Tumors, Vol. I, page 223). Metastatic tumors are not uncommon; usually they are secondary to carcinoma of the stomach; their treatment is palliative.

Ascites.—Collections of serum in the peritoneal sac should be treated by dealing with the causative disease, and by measures to promote absorption and elimination of body fluids. If this does not relieve the ascites, the simplest way to remove the fluid is by *aspiration* or "*tapping*." This operation is done when the amount of fluid is so great as to cause discomfort, disability, and interference with respiration and circulation. The operation is done as follows: The diagnosis of fluid-distention having been assured, the patient is placed in the upright sitting position, and by percussion the height of the fluid in that position is determined. With a sharp-pointed knife a small puncture is made through the skin in the median line of the anterior abdominal wall about 5 cm. (2 inches) above the pubes. Through this a trocar and canula are thrust, through the abdominal wall into the peritoneal fluid. The surgeon should have estimated the thickness of the wall and marked by his finger the depth which he proposes to allow the instrument to pass. As it penetrates the peritoneum there is a sense of non-resistance. The trocar is removed, the fluid runs out through the canula. When it ceases to flow the canula is removed, and a small sterile dressing is held over the wound with an adhesive strip.

The operation should be done with aseptic precautions. The bladder and bowel should be emptied. Usually the intestines float up on top of the fluid and there is no danger of injuring them. If they should be held against the lower anterior abdominal wall by adhesions, the percussion note would give the warning of this unusual condition, and the tapping should be done

at one side. The canula should not be so large as to permit too rapid an escape of fluid nor so small as to become clogged by bits of fibrin. About 6 mm. (¼ inch) in outside diameter is a good size. It should pass only just through the abdominal wall. The fluid as it spurts out may be caught in a vessel. Its flow should be stopped at short intervals to permit the abdominal structures gradually to accommodate themselves to the diminishing pressure. If the fluid runs out too fast engorgement of the splanchnic vessels may take place, producing shock, or syncope, or even abdominal hemorrhage. The patient's circulation should be watched, and the head lowered if the heart becomes weak and rapid.

The *artificial formation of intra-abdominal adhesions for ascites*, due to cirrhosis of the liver, first was advocated by Talma (Berlin Klin. Woch., Sept. 19, 1898). The abdomen is opened by an incision in the median line between the ensiform and umbilicus. The fluid is evacuated and sponged away. The upper surface of the liver which can be reached is rubbed with gauze for the purpose of irritating its peritoneal covering and causing it to become adherent to the diaphragm. The relaxed abdominal wall is then everted, the peritoneum in the neighborhood of the wound rubbed, and the great omentum sewed to it, first on one side of the wound, then on the other. As broad an attachment of omentum to the peritoneum of the abdominal wall as possible is made. The abdomen is then closed. The adhesions which form as a result of this operation cause anastomoses between the veins of the mesenteric system and those of the anterior abdominal wall; and blood from the veins of the abdomen is carried to the vena cava without passing through the portal veins and the liver. Care should be taken not to injure the circulation in the round ligament.

The results of this operation are very satisfactory in a large proportion of cases of cirrhosis of the liver which are not too far gone with other complications. A. Blad (Ugeskrift for Laeger, July 15, 1915) found that about 40 per cent. of the cases operated upon by this method have been cured of the ascites. The reason for the 60 per cent. of failures is that the operation has been improperly used.

The operation usually fails in cases of chronic congestion of the liver—"nutmeg liver." In these cases there is general venous stasis, associated with heart disease. Drainage of the ascitic fluid is about the only sure surgical relief. The operation succeeds in cases of stasis of the portal system. Success depends largely on the functional potency of the liver. This factor cannot always be determined before operation. The operation is found to give relief in some cases of ascites not due to portal defect. This is possibly because it relieves a secondary portal stasis. If adhesions already exist or if the omentum is small and shriveled the operation will do no good. If the operation is done before the general health of the patient has become seriously impaired, improvement should be secured in 90 per cent. of cases operated upon.

The operation need not be carried out just according to the method of Talma. The best results are being secured by bringing an edge of omentum outside of the abdomen, and fixing it in the abdominal wall. Most surgeons use local anesthesia. E. A. Babler (Jour. Am. Med. Assoc., Vol. 58, No. 15, April 13, 1912) improved the operation by making a transverse opening into the abdomen. A vertical incision is made down to the deep fascia; the sheaths of the recti are opened at their inner borders; the muscles are retracted outward; a transverse incision is made through the transversalis fascia and peritoneum; the omentum is drawn smoothly through this opening (Fig. 1218), spread out below it, and fastened with a few sutures behind

the muscles. If necessary to strengthen the opening the muscles or fascia may be united in front of the omentum in the middle line.

Subcutaneous drainage for ascites has been attempted by many methods. Glass tubes, silver wire, tubes of fascia, skin, serous membrane, and other substances have been used. The first of these operations was that of Lambotte (Semaine Medicale, 1905, page 19) who used silk thread. The abdomen is opened in the left semilunar line, and a big needle carries heavy silk in an out through the peritoneum. The ends of the threads are then carried beneath the skin, converging at a point on the thigh below Poupart's ligament. The wounds are then closed.

P. Peterson (Lancet, Oct. 29, 1910) made an incision about 7.5 cm. (3 inches) long in the middle line below the umbilicus, opened the abdomen,

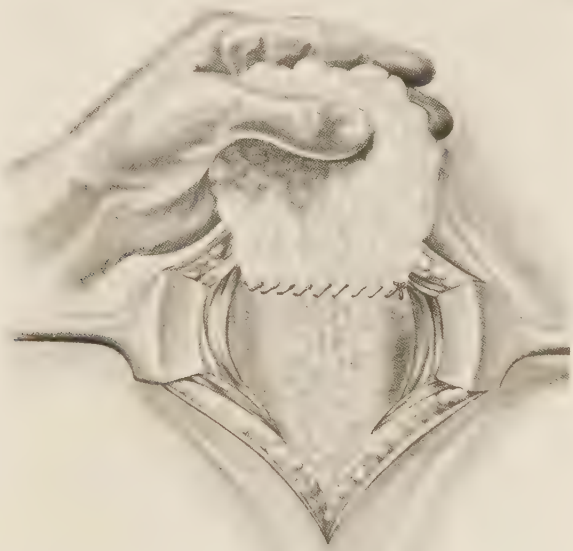

Fig. 1218.—Operation for Ascites.
Omentum sutured in transverse opening in fascia between recti muscles.

and evacuated the most of the ascitic fluid. The omentum was then drawn down, tied off and removed at a level well above the wound. The subcutaneous tissues were then dissected outward on one side of the wound as far as the semilunar line. Through this an opening is made into the peritoneal cavity just large enough to admit a flanged spool. This is a cylinder of glass flanged at each end. Several sizes of these spools are had on hand to fit abdomens of different thickness. The spools are 2.5 cm. (1 inch) across the flanges, and the canal is 2 mm. (1/12 inch) in diameter. The subcutaneous opening should be just large enough to admit the spool, which should be inserted from the peritoneal side in order to be sure that the peritoneum is not stripped up. The subcutaneous tissues are then tightly sewed to the

sheath of the rectus about 2.5 cm. (1 inch) from the margin of the median wound, to prevent the escaping fluid throwing too much strain on the wound. The primary wound is then snugly sutured in the usual manner. Swelling and edema in the neighborhood of the tube characterize the draining off of the fluid into the subcutaneous tissues.

This operation may be made much less formidable. The glass spool need have a lumen of not more than 1 cm. (3/8 inch). It may be introduced under local anesthesia through a small wound made between the pubes and navel. The omentum need not be tied off at the first operation.

Franke contrived a system of drainage, using a simple silver wire. It is loosely twisted double and the ends are bent so as to have somewhat the shape of the letter H. One of the sides is 10 cm. (4 inches) and the other 2 cm. (3/4 inch) long. The short side is twisted like a figure 8, and introduced in the abdomen. The long side lies in the subcutaneous tissue. The distribution of the fluid which passes out along the twisted wire is facilitated

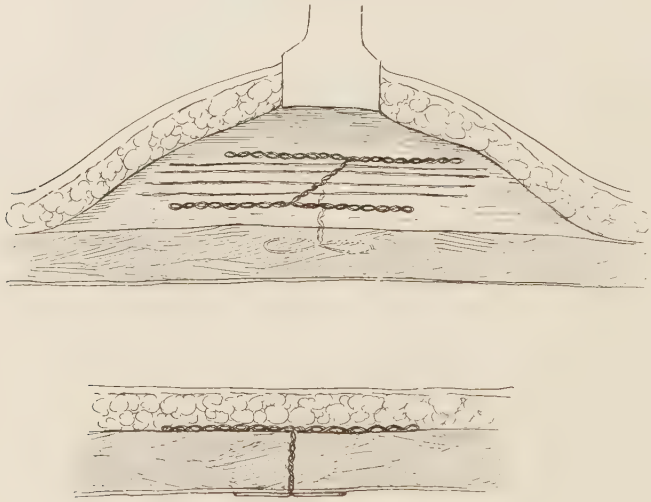

Fig. 1219.—Arrangement of Silver Wire and Strands of Silk Thread for the Drainage of Ascitic Fluid into the Abdominal Wall.

by three or four strands of silk, caught in the wire and spread out under the skin as six or eight drains (Fig. 1219).

Blad has used successfully a square of fascia, taken from the thigh, rolled into a tube, and inserted into the peritoneal cavity in the right lumbar region. The tube should be about 3 cm. (1 1/4 inches) long and 1.5 cm. (5/8 inch) in diameter, and terminate in the lumbar muscles.

A piece of vein (saphenous), resected from the patient would serve better than any of these substances, all of which are doomed to become encysted in connective tissue. Thus far, the implantation of foreign materials as above described have given about an equal proportion of failures and successes.

Anastomosis of the saphenous vein with the peritoneum was devised by Routte for carrying off the ascitic fluid directly into the centripetal circulation. An incision is begun about 2.5 cm. (1 inch) above the middle of Poupart's ligament and curved inward and downward over the femoral ring and along the course of the long saphenous vein to a point about 10 cm. (4 inches) below its entrance into the femoral vein. The fibers of the muscles and fascia

are separated and retracted and the peritoneum exposed about 1.3 cm. (½ inch) above the ligament through a short wound. The incision below this wound is then deepened and the saphenous vein is exposed and isolated for a distance of 9 cm. (3½ inches) from its mouth. The peritoneum is then picked up and incised so as to make an opening the size of the lumen of the vein. When the ascitic fluid has drained off, the vein is ligated and divided above the ligature at a point about 8 cm. (3 inches) from its mouth. This proximal arm of the vein is then turned upward and sutured in the peritoneal opening, endothelium to endothelium, with fine chromic catgut, and the overlying tissues closed. The vein should be cut longer or shorter as is necessary to reach the opening without too much stretching or relaxation. If necessary the abdominal wound through the fascia may be slightly relaxed by a short transverse nick in the conjoined fascia. The reports from the few cases subjected to this operation show good results if the vein was not smaller than normal. Whether the operation has permanent value has not yet been determined.

Drainage of ascitic fluid into the bladder was accomplished by P. Rosenstein (Zentralb. f. chir., xli, No. 9, Feb. 28, 1914) who made a valved communication between the interior of the bladder and the peritoneal cavity.

Anastomosis between the vena cava and the portal vein was first described by N. V. Eck (Militar-med. Jour., 1877, cxxx, Jahrg., 55). The first operation on man was done by Vidal (La Semaine Med., 1903) upon a man with cirrhosis of the liver who died four months later of cardiac disease. The second operation was done by P. Rosenstein (Zentralb. für Chir., No. 9, Feb. 28, 1914) in a man with cirrhosis of the liver in whom omentopexy had not given relief. The *Eck fistula* in this case gave only temporary relief; and the patient was finally relieved by the operation described above for drainage of the ascitic fluid into the urinary bladder. The operation has been done repeatedly and successfully in animals. A bibliography is found in an admirable paper on the subject by M. M. Peet (Annals of Surg., vol. 60, 1914).

The object of the operation is to permit the return of venous blood from the abdomen to the heart without passing through the liver. It is naturally most applicable to cases of cirrhosis of the liver, with ascites, in which the other organs are fairly healthy. Such cases are found in alcoholic cirrhosis. These patients show the dilated subcutaneous vessels about the costal arch, dilated hemorrhoidal vessels, and enlargement of the esophageal veins.

The operation cannot be expected to help the cases of chronic congestion of the liver, giving rise to "nutmeg cirrhosis." These are cases of increased pressure in the vena cava itself, commonly associated with valvular disease of the heart with general venous stasis. In these cases, as well as those due to nephritis, drainage of the ascitic fluid or tapping are the only forms of surgical relief to be considered.

Peet is of the opinion that the operation should give relief also in the cirrhosis which is secondary to the splenomegaly of *splenic anemia*, and in the cases of thrombophlebitis of the portal vein. In this latter class of cases it would be necessary to make the anastomosis between the vena cava or common iliac vein and some large adjacent mesenteric vein.

The portal vein lies at the right side and in front of the vena cava. The vena cava is between the portal vein and the aorta. The common bile duct is to the right of the portal vein and in front of it. From within outward are the aorta, vena cava, portal vein, common bile duct and descending duodenum. In the same order the structures may be enumerated from behind forward. The hepatic artery lies in front of the portal vein (Fig. 1220). The

common bile duct is the guide. If the peritoneum is divided longitudinally about midway between the duct and the aorta, and gently retracted the portal vein and the inferior cava will be exposed. The operation is done in the space bounded by the hepatic artery above and the splenic vein below. Some small vessels may need to be tied and divided.

Carrel and Guthrie isolated the veins and closed the veins above and below with soft clamps. An incision was made in each vessel and all blood washed out with liquid vaselin. A stay suture unites the ends of each opening. These are tied externally. A running through-and-through suture then unites the posterior lips of the gap. This is done with one end of the stay suture. The anterior lips are united in the same way. Fine straight needles with ooo silk are used. The stitches should be about 1 mm. apart.

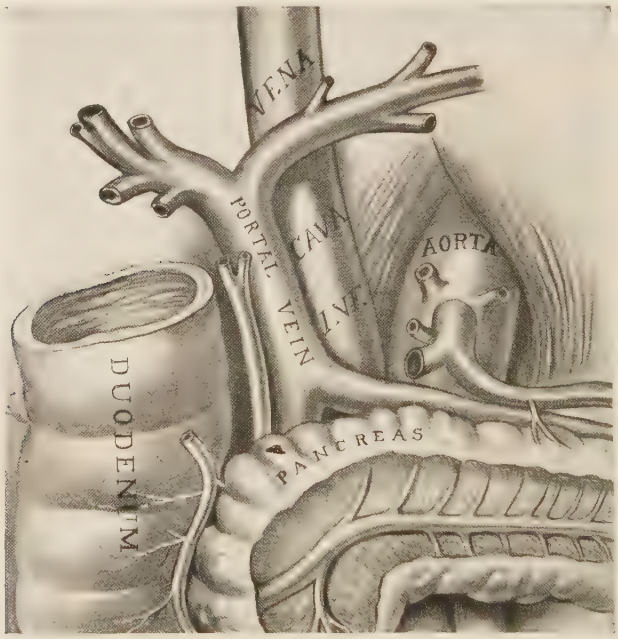

Fig. 1220.—Relations of Portal Vein.
Showing location for making anastomosis between portal vein and vena cava.

A simpler method is with the use of curved anastomosis clamps (see Arteriovenous Anastomosis). This permits closure of the vessels and lateral apposition with the assistance of the same apparatus. By the use of these clamps the vessels are not entirely occluded, which in man is an important advantage. Less isolation of the vessels is required by this method. Two two-bladed clamps permit more facile adjustment of the vessels but take more room than one three-bladed clamp. Peet, who has done the operation on dogs with the three-bladed clamp, advises a curved needle. He advises that when adhesions or thrombosis prevent use of those two veins a mesenteric vein may be anastomosed with the common iliac vein; or if this is not long enough the mesenteric vein may be tied near its mouth, cut and turned downward. It may be anastomosed with the vena cava.

Bier failed in two attempts to complete the operation on account of bleeding adhesions. Kocher designated it as an unthinkable procedure.

Because of the difficulties, added by the presence of the enlarged liver the operation is rarely applicable. The surgeon should not attempt the operation until he has practiced it on the cadaver.

Anastomosis between superior mesenteric vein and vena cava is a more practical operation than the above. A transverse abdominal incision is made at the umbilicus. Both recti are divided. The transverse colon is retracted upward and the small intestine to the left. The horizontal portion of the duodenum is exposed and passing in front of it is seen through the peritoneum the superior mesenteric artery and vein. To expose the vena cava, the peritoneum is incised below the duodenum and the bowel retracted upward. The mesenteric vein is freed, and can easily be brought into contact with the vena cava for a distance of 4 or 5 cm. A lateral anastomosis is made after first ligating the small lateral branches of the cava, and temporarily occluding the vessels. The soft curved clamp serves best for partial lateral occlusion of the vena cava (see Anastomosis of Vessels, Vol. I, page 378).

Anastomosis between the superior mesenteric and ovarian veins may be done in the above manner for the same type of cases. A branch of the superior mesenteric vein is used.

Retroperitoneal Disease.—There are three main groups of lymphatics behind the peritoneum coming from the pelvis and located along the iliac vessels. The aortic glands number twenty or thirty, grouped around the abdominal aorta. The latter are a continuation of the pelvic chain. There are also glands scattered along the great visceral branches of the aorta. The mesenteric glands are scattered through the mesentery. The pelvic glands not only receive lymph from the pelvic organs but communicate also with the external genitals and the groins; and the aortic glands are supplied not only by the abdominal organs but also from the abdominal wall.

Retroperitoneal infection and abscess may come from infection of pelvic or abdominal viscera, from infection in the pelvic or abdominal wall, from infection in the thorax, from the lower extremities, or from the spine, retroperitoneal region, or by metastasis from some distant part. The vermiform appendix is a common source of infection. If the primary focus is still present, it should be eliminated as a factor in future infection. A lymphatic infection without abscess may be very persistent and yield only to treatment with bacterial products. Abscesses tend to work downward and outward; and, coming near the surface in the groin, flank or lumbar region, they should be opened.

Retroperitoneal and mesenteric tumors are of great variety. Next to the lymphatic enlargements and secondary growths, *lipoma* is the most common. It should be enucleated. This may be done without opening the peritoneum, through an incision in the flank entering the retroperitoneal space. Other tumors presenting in the groin may be reached beneath the peritoneum through an incision just above Poupart's ligament. Commonly these growths have had to be reached by the transperitoneal route. With due regard for the surrounding structures the peritoneum is incised, the opening enlarged, and the tumor enucleated.

Pedunculated tumors are more easily dealt with, the pedicle being ligated and the mass removed. After an enucleation, leaving a retroperitoneal excavation, drainage for a few days should be provided through the flank by means of a good-sized tube. After such an operation the surgeon should be prepared to treat paralysis or gangrene of the intestine or disturbance in any of the abdominal organs whose nerve or blood supply has been harmed. These operations are as difficult as the preoperative diagnosis of the disease.

Other benign tumors, such as *fibroma*, should be treated in the same way.

Primary *sarcoma* is sufficiently frequent to justify the removal of any suspicious retroperitoneal tumor. When sarcoma reaches a size so great as to demand surgical relief, surgery cannot give relief. The hopeful cases are those in which an unexpected discovery of the tumor is made. Even then the successful treatment may demand resection of bowel, kidney or other important structure. Malignant tumors are best operated upon from in front, to insure wide exposure.

The *retroperitoneal cysts* are of great variety, and may be extirpated through the peritoneal cavity without rupture. In the case of large cysts it may be best to cause the peritoneum covering the cyst to become adherent to the abdominal wound, and then after a few days evacuate it and take measures to effect the destruction of its lining (see Cystomata, Vol. I, page 325). If the surgeon is sure that such a cyst is not infected, its contents may be evacuated at once and the cavity drained after the sac is sewed to the abdominal wound. This is the best way to deal with *mesenteric blood-cysts*. These measures, which take the place of enucleation of the cyst, are advisable even when enucleation could be done but would endanger the blood supply of the intestine, or when the condition of the patient does not warrant the operation. As a rule, so far as the mechanical possibilities go, a tumor which has not caused gangrene of the bowel can be removed without causing gangrene, provided the opening in the peritoneum is made in such a way as to spare the vessels and nerves of the mesentery.

Mesenteric tumors and *cysts* require only the special consideration as to resection of the bowel. In order to remove the tumor, it often means that the blood supply of the intestine will be so interfered with that bowel must be resected. This should be done without hesitation if the tumor is growing. Several feet of bowel may require to be removed. The hazard which resection of the bowel adds should prompt the surgeon to remove the tumor, sparing the blood-vessels in such a way as to obviate the necessity for resection (see Mesentery, page 568).

PREPARATION OF PATIENTS FOR OPERATIONS ON THE ALIMENTARY CANAL

In operations upon the alimentary canal the lumen of the canal may be opened and its contents and mucous membrane become involved in the field of operation. The surgeon attempts to control the asepticity of the field of operation down to the mucous membrane; he should also attempt some control of the *bacteria of the alimentary canal.*

The *Bacillus coli* is a natural inhabitant of the intestine. Besides it there are many other adventitious organisms in large number and variety. Bacteria are, perhaps, not essential to life. Many animals live without them. Most of the adventitious bacteria tend to disappear, but are renewed with the food. It has been shown that at the end of nine hours after a digestible meal, the stomach contains no bacteria. After the stomach has emptied itself of food, bacteria cannot be found in its mucous membrane. Fluids are passed quickly out of the stomach; only solids are retained. Cushing showed in a case of jejunal fistula that a glass of milk taken by the mouth could all be recovered at the fistula within a few minutes after its ingestion. While solid food remains in the stomach the number of its bacteria is being constantly reduced; the longer it remains, the fewer bacteria live to enter the duodenum.

Gastric digestion destroys even the anthrax bacillus. When ingested after a solid meal, it cannot be found in the intestine; but when ingested with a large quantity of fluid in an empty stomach it is easily found in the lower bowel.

The duodenum contains but few bacteria. It is often sterile. From the duodenum downward, the number and virulence of the bacteria increase. The maximum of numbers and virulence is reached at the ileocecal valve. The stomach and upper jejunum may be kept sterile by feeding only sterile foods, permitting no infected material or object to enter the mouth, and by proper attention to the cleansing of the buccal cavity. Obstruction or stagnation anywhere in the gastro-intestinal tract results in a damming back of material in which the number and virulence of the bacteria are much increased.

When perforation or opening of the intestine takes place, the dangers of peritoneal infection are greatly modified by the above conditions. Food means infection. The empty canal may be free from infection. The higher up the perforation, the more apt is the infection to be due to some adventitious organism, such as the streptococcus; lower in the intestine, the Bacillus coli is most apt to be the chief or only infecting agent.

Drugs, such as salol, borax, salicylic acid, betanaphthol and iodoform, given for their antiseptic effect, have little or no effect upon reducing the intestinal flora. It has been shown by Adolph Hofmann (Moynihan: Abdominal Operations, Sec. Edit., 1906, page 22) that isoform, given in 0.5-Gm. doses in amounts up to 3 Gm. in twenty-four hours, diminishes the number of intestinal bacteria. As much as 8 Gm. have been given without harm. The antiseptic effect in the stomach is rapid; in the intestine the effect is secured in about thirty hours. It has but little practical value in surgery.

It often happens that emergency operations must be done, in which the gastrointestinal tract is opened; but when a few days' preparation can be had, the dangers of infection can be much reduced. The following is the preliminary preparation: An attempt is made to render all ingesta sterile. The patient is caused to rinse his mouth with an antiseptic solution at frequent intervals (see Cleansing of the Mouth, page 244). The teeth are brushed at frequent intervals with a sterilized tooth brush and especially before and after taking food. A test meal is given, and if any gastric catarrh with microörganisms is found, the stomach is washed out twice daily. Only fluids are given. The food and utensils are all sterilized. Food consists of boiled water, milk, albumin water, broths, soups and fruit juices. This treatment may be continued for two or three days; or longer, if the condition of the mouth is bad. The bowels should be thoroughly emptied by castor oil, calomel or saline aperient, forty-eight hours before operation; and an enema should be given the night before operation. All of the cleansing of the bowels should end on the day previous to operation. The operation should be done in the morning. No food should be taken by mouth for six or ten hours prior to operation. If nourishment is demanded, nutrient enemata may be given (see Preparation of Patient, Vol. I, page 176).

This rigorous sterilization of the food and mouth need not be followed as a routine, but in cases in which the dangers of infection are contemplated it may be applied. The bacteria ordinarily found in the intestine are not inimical to wound healing. This is particularly the case if the contents of the intestine are not fluid. Dry or soft solid fecal contents are not to be feared. Fluid feces are apt to contain virulent bacteria. This is the reason a purge should preferably not be given within twenty-four hours of the operation.

THE INTESTINES

Contusions.—Contusions of the intestine, without rupture, may produce ecchymoses, local paralysis of the bowel, or be associated with the shock due to contusion of the sympathetic nerves of the abdomen. If gangrene does

not take place, the intestine recovers and operation is not required. Both this condition and local paralysis require that the patient should be watched for signs of peritonitis. He should be kept quietly in bed, the bowels should be moved by enema only, and no food except fluids should be given (see Contusions of Abdomen, page 535).

Rupture of the Intestine.—Operation should be done at once for acute rupture of the intestine with soiling of the peritoneum. The shock present may be due to peritoneal irritation, abdominal trauma, or it may be confused with hemorrhage. If shock is pronounced, the first step in the operation should consist in exposing a vein for saline infusion. As soon as the abdomen is opened, if hemorrhage is not found as a cause of the depression, an assistant should proceed with the infusion. Shock is the important factor, and should be combated by every means (see Vol. I, page 213). The abdomen should be opened near the injury if there are localizing signs; otherwise the opening should be made in the median line as it gives access to the largest extent of intestine. The opening should be large enough for free examination. The injury should be sought in the direction from which fluid comes or where redness is present. As soon as it is discovered, the surrounding peritoneum should be sucked or sponged dry, the rest of the peritoneum walled off with sponges, and the injured bowel brought into the wound. The opening should be sewed (see Intestinal Suture, page 626). If possible, rents should be sewed transversely rather than longitudinally in order not to narrow the lumen of the bowel. Further search should then be made for other injuries which might demand surgical treatment.

If the condition of the patient is bad, it may rarely be best not to take the time to suture the rupture but to bring the intestine into the abdominal wound and suture it there with the view of establishing a fecal fistula. The lower in the intestine the opening is the more feasible such a course becomes (see Intestinal Fistulæ, page 683).

It sometimes happens that the surgeon finds the intestinal wound closed by agglutination to adjacent intestine or to some other part of the peritoneum. Judgment is required to decide whether the adhesions shall be broken apart and the rent sewed or whether they shall be left undisturbed. A living patient is always to be preferred to a perfect piece of work in a dead patient. If the occlusion by adhesions is complete, and the surrounding peritonitis has subsided or is subsiding, it will often be good surgery to leave the condition as it is. A later operation may be done if necessary to separate the adhesions. If the occlusion, on the other hand is not complete, or if it is soft and surrounded by an area of active peritonitis, no chances should be taken with it; it should be separated and sewed.

The cases requiring most skill and judgment are those with injury about the wound or injury of the mesentery which threatens gangrene (see Wounds of Mesentery, page 568). Here the well-equipped surgeon is always on the safe side in doing a resection of the bowel and anastomosis. If the condition of the patient will not permit this, then the damaged bowel should be brought in the wound for the formation of a fistula.

Irrigation is called for in these cases only when intestinal contents have been spread rather widely away from the wound. Usually suction or sponging should be relied upon to take up infective matter. The abdomen should be searched wherever peritonitis or fluid leads in order to discover other injuries.

The use of drainage and the subsequent treatment should be governed by the rules already laid down for the treatment of peritonitis (page 546). Drainage in most cases is not necessary (see Ulcers of Intestines, page 576).

Perforating Wounds of the Intestines.—The treatment of these wounds is the same as that of rupture of the intestine. Penetrating wounds of the abdomen have been described (page 535). *Perforating bullet wounds* should be exposed if the surgeon can control the asepticity of the operation. With the modern small-caliber bullet these wounds are by no means always fatal, and if aseptic and skillful surgery is not available the patient has a better chance for his life by the application of an occlusive dressing, and the treatment for peritonitis (see Peritonitis, page 546). This treatment should be applied from the first, and peritonitis not awaited. The essentials are rest and the inhibition of peristalsis.

Ordinarily the treatment of these wounds, as for incised, punctured, and lacerated wounds of the intestine, is immediate exposure and suture. Usually a median abdominal incision is best. Bullet wounds should be closed by a single very fine purse-string suture. Small incised wounds require a single suture. Larger wounds, involving a distance equal to more than

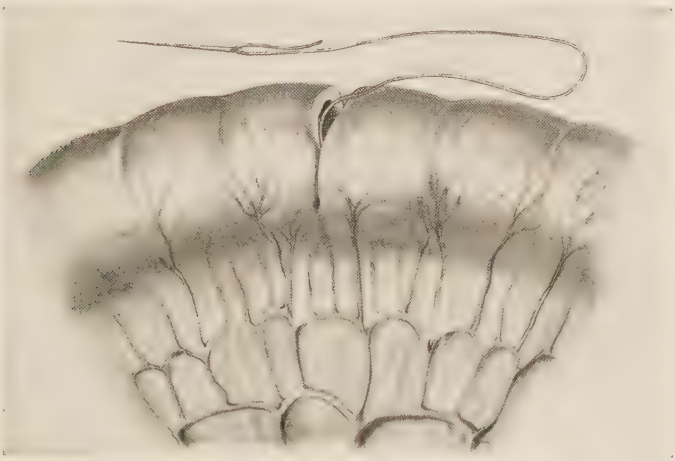

Fig. 1221.—Suturing Wound of Intestine Transversely.
This gives the least narrowing of the lumen.

one-third of the circumference of the bowel, may be closed by two layers of suture. If the suturing of a wound reduces the caliber of the bowel more than one-half, resection is to be preferred. Transverse wounds threaten the vitality of the bowel less than longitudinal wounds. Wounds should be sutured in such a manner that the caliber of the bowel is not reduced (Figs. 1221 and 1222). This is best accomplished by sewing wounds transversely to the long axis of the bowel whenever possible.

If the wound is not found at once, the direction from which fluid or blood comes is the guide. If it is still not found, or after a single wound has been found and the injury was inflicted in such a way as to warrant the suspicion that other coils were wounded, a systematic examination of the whole length of the intestine should be made. This should begin with the stomach and follow the duodenum, jejunum, ileum, and colon. As each wound is found it should be sutured. At the same time, wounds of the mesentery and other structures should be given attention.

Ragged edges of a wound may require to be trimmed, and bleeding vessels ligated. The important feature of the suture is that it shall oppose peritoneal

surfaces and that no mucous membrane shall come into contact with peritoneum. In multiple wounds if intestinal contents run forth from each, it is best to find all of the wounds and include each with a clamp before suturing them. If extensive destruction of the intestinal wall is present, and there is doubt as to its future vitality, or if suture will leave pronounced angulation or narrowing of the intestinal canal, resection of the damaged segment is to be preferred. Complete division of the intestinal canal requires end-to-end or lateral anastomosis. Badly damaged areas, which are not perforated but which may slough, should be turned in by suturing healthy peritoneum over them.

FIG. 1222.—LONGITUDINAL SUTURING OF WOUND OF INTESTINE.

This method gives dangerous narrowing of the lumen and should be avoided whenever possible.

Wounds of the mesentery not involving its main vessels may be sutured, but any damage to the nutrient vessels of the intestine occluding the vessel should cause the surgeon to consider the advisability of resection (see Wounds of the Mesentery below). Wounds with loss of substance, or extensive lacerated wounds requiring trimming, located opposite or nearly opposite the mesentery, may be closed by *angulation*, if the simple suturing of the wound would cause great narrowing of the intestinal tube. Angulation consists in bending the bowel, so as to double the wound upon itself, and sewing its edges together (Fig. 1223). A second row of sutures is added for purposes of security. If necessary the wound may be enlarged opposite the mesentery in order to secure an entero-anastomosis. When such a wound is closed transversely, an angulation is produced but it is not of such a character as to narrow the lumen of the bowel (Fig. 1224).

(For methods of suturing intestine, see Enterorrhaphy, page 621.)

Wounds of the Mesentery.—Punctured wounds need not be sutured, if small. Larger wounds, parallel to the vessels, should be sutured, care being taken not to include any large vessel in the suture. Wounds parallel to the bowel, if they cross one or two large vessels, require resection of the bowel. Even though a wound be small, the contusion associated with it may cause occlusion of adjacent vessels, and demand resection of the bowel. No rules can be laid down for determining the necessity for resection. Only experience can teach. Generally, if the peritoneum of the bowel has lost its luster, if it looks dark and injected, and otherwise shows signs of lack of circulation resection should be done. When there is doubt the surgeon is on the safer side to resect. From the above it will be seen that the simple suture of wounds of the mesentery is not much called for because wounds large enough to require suturing are apt to have done so much damage to the vessels as to demand more radical treatment (see Gangrene of Intestines, page 609).

Nonperforating Wounds of the Intestine with Wounds of the Mesentery.—If the wounds of the mesentery do not destroy important vessels and interfere with the nourishment of the bowel, they may be sutured; and at the same time the wounds of the bowel are closed. If the wounds are extensive and the denudation does not permit peritoneal suture, omentum should be

sewed over the raw surface. The use of omentum for this purpose plays two important parts: it covers the wound with peritoneum, and thus guarantees healing and obviates vicious adhesions, and it supplies nourishment to a

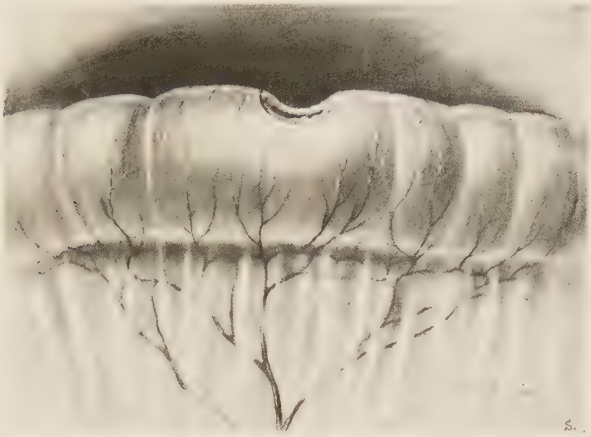

Fig. 1223.—Wound of Intestine to be Closed Transversely by Suture.

segment of the bowel which might later fall into a state of gangrene when traumatic reaction further occludes the mesenteric vessels.

Infections of the Intestinal Canal.—Most of the enteritides are medical diseases. In general, the treatment consists in emptying the bowel by a

Fig. 1224.—Closure of Wound by Transverse Suture and Angulation. Note that this method of closure does not cause narrowing of the lumen of the bowel.

laxative, such as castor oil, and withholding food which is not wholly digestible and assimilable. If the condition of the patient will permit, the best results will be secured by allowing no food but water. Albumin water,

fruit juice, whey, glucose, and clear broth leave little residue and offer all the necessary food elements. These may be used if food is necessary.

Colitis should yield to the ordinary treatment for enteritis. If it does not, *irrigation of the colon* through the rectum should be used. This is accomplished by placing the patient in the knee-chest position, or on the side with the foot of the bed raised, and allowing ½ to 2 liters (1 to 4 pints) of warm fluid to run in the rectum slowly from a height of about 60 cm. (2 feet). The amount should be small at first and increased with tolerance. The fluid passes into the colon as far as the ileocecal valve, or farther, by reversed peristalsis. Some of it is absorbed. It should be retained for ten or fifteen minutes and then allowed to escape. If the rectum is irritable it may be made tolerant by a preliminary injection of cocain, morphin or hyoscyamus.

First, saline solution should be used. If this does not effect a cure, a mild antiseptic astringent solution may be employed. Borax or boric acid, 2 per cent. solution, to which is added 1 per cent. of the fluidextract of hydrastis, is effective. Instead of the latter, tannic acid (1 per cent.), zinc sulphate (1/10 of 1 per cent.), lead acetate (1/5 of 1 per cent.) or aluminum acetotartrate (1 per cent.) may be used. A hot solution of alum, 4 c.c. (1 dram) in water 1000 c.c. (1 quart), is useful in hemorrhage of the bowel. Silver nitrate (1 : 2000) has been recommended. These treatments may be given once or twice daily. When chronic colitis or colonic diarrhea does not yield to internal treatment or irrigations, operative treatment has much to offer. This consists in making a fistula for irrigation at the beginning of the colon (see Enterostomy for Irrigation, page 572; and Appendicostomy, page 571).

In *amebic colitis* (tropical dysentery due to the entameba), the general strength of the patient should be preserved by careful diet and rest.

Milk diet or a strictly fluid diet should be given. Castor oil, magnesium sulphate and other laxatives are useful. Bismuth subnitrate or subcarbonate in large doses may be given by mouth. About 12 to 24 Gm. (180 to 360 grains) in a glass of water are administered every three to six hours night and day. The number of doses is diminished as the patient improves.

The specific treatment consists in the administration of *emetin* or *ipecac*. Ipecac is given in salol-coated pills, 2 Gm. (30 grains) daily at a dose, diminishing 0.3 Gm. (5 grains) daily till by the sixth day only 0.3 Gm. is given at a dose. More effective than ipecac is its resinoid emetin. Injections of 0.3 Gm. (5 grains) are given once daily for a week or ten days. If improvement is not established in three days of this treatment, it is doubtful if the disease is due to the endameba. In conjunction with the medical treatment local irrigation is of value.

Treatment with *oil of chenopodium* was recommended by W. Emrich (Jour. Am. Med. Assoc., May 19, 1917). The following sequence is used: 15 to 30 Gm. (½ to 1 ounce) of magnesium sulphate at 6 a.m.; 1 c.c. (16 minims) oil of chenopodium in gelatin capsules at 8 a.m., 10 a.m. and 12 m.; 30 c.c. (1 ounce) of castor oil, containing 3 c.c. (50 minims) of chloroform, at 2 p.m. This is the dosage for adults; for children it should be reduced according to age.

The amebæ can be destroyed by local applications. They may be reached by irrigation through the rectum. Irrigation is given as above described. It should be given in the presence of the surgeon. The most effective solution is sulphate of quinin 1 : 3000 up to 1 : 500. The solution is best given in the knee-chest position. It should be retained for the greater part of an hour after the patient has gradually become used to it. Silver nitrate in 1 : 1000 solution is also used in chronic cases. Irrigation through the

rectum is uncomfortable and often painful. To be effective a large amount of fluid must be used. When the lesions are high it is difficult to reach them. For these reasons a direct opening into the cecum gives much better results and greatly shortens the period of treatment. Often without this the disease is incurable. Surgeons who have to treat many cases of this disease in the Philippine Islands, are performing the operation earlier and earlier instead of deferring it for the apparently hopeless cases. The results are most satisfactory. An operation which gives much satisfaction is *appendicostomy* (see below). When the appendix is not available, *cecostomy* (see below) should be done. Surgeons are agreed that amebic dysentery with lesions above the sigmoid which has existed for more than a year and has not yielded to irrigations through the rectum should be treated through the cecum. The general tendency is for the operation to be done still earlier than this.

Continuous irrigation of the bowel may best be carried out by a double rectal tube; that is, a tube within a tube, one connected for inflow and the other for outflow. If this is not at hand it may be made with two catheters. The catheters are passed through a piece of rubber tubing, 8 cm. (3 inches) long. The distal end of the outer tube should be beveled so that it will enter the rectum smoothly. The tube may be sealed by filling the interstices around the catheters with paraffin, wax or rubber cement. The two ends should be 5 cm. (2 inches) apart. The outlet tube should have at least two eyes (Fig. 1225). By applying clamps to the two tubes the rapidity of flow may be regulated. The two tubes may be clamped alternately and the inflow and outflow thus made to alternate.



Fig. 1225.—Double Tube for Continuous Irrigation of Bowel.
Tube held by sphincter.

The *indications* for intestinal irrigation are not only colitis, but it is useful in a great variety of conditions. In shock and hemorrhage it is discussed elsewhere (see Vol. III). In sthenic cases, in prolonged diarrhea and other diseases which exhaust the fluids of the body it is most useful. In gynecologic conditions in which the warm vaginal douch is useful, rectal heat may have the same effect. Inflammations of the prostate, seminal vesicles and bladder, spasms of the urethra are often helped by it.

Appendicostomy consists in fixing the vermiform appendix in the abdominal wall, and using it as a fistula for irrigation of the colon. The operation

was suggested by C. B. Keetley and first performed by R. F. Weir. It is of service for the treatment of diseases of the colon such as mucomembranous colitis, amebic colitis, some forms of chronic constipation, ileocecal intussusception, ulcerative disease of the colon, as a substitute for typhlotomy in acute obstruction in the large intestine, for medication of the lower ileum, and as a means for administering nourishment in cases of combined gastric and rectal or colonic disorder.

The *operation* is begun as the ordinary procedure for removal of the appendix. A small opening, not larger than 5 cm. (2 inches), is made over the appendix by the McBurney method of muscle splitting (see Vol. III). The appendix is brought up through the wound. The meso-appendix is secured to the peritoneum of the wound, and a similar stitch is placed in the appendix opposite the mesoappendix. The retracted muscles are allowed to drop together, and a stitch through the skin catches the appendix on either side. The wound is then closed with the appendix projecting through it. If the operation is done for acute obstruction, the appendix may be amputated at once. Otherwise it is best to leave it for two days until adhesions have formed. The amputation is done flush with the skin. If the appendix is amputated at once a purse-string suture or a ligature should be thrown about it after the catheter is introduced to prevent leakage (Fig. 1226).

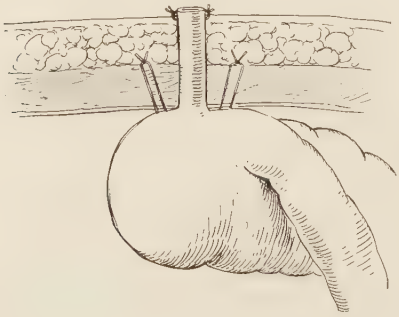

Fig. 1226.—Appendicostomy.
Showing appendix brought out through abdominal wound and cecum sutured to abdominal wall.

After amputating the appendix, the artery may have to be ligated. The mucous membrane may be caught with fine forceps and fixed to the skin with four sutures. The lumen may be dilated so that it will admit a No. 10 or 12 English catheter. It is well to leave the catheter in constantly for the first week to prevent contractions; after that it may be inserted daily for treatments.

In bringing up the appendix it may be found involved in adhesions; these should be divided. The surgeon should see that the appendix is straight, so that angulation shall not prevent the introduction of the catheter. The appendix need not be drawn out until the cecum strikes the wound; enough should be left in the abdomen so that the cecum lies in an easy position. If adhesions are too dense or if the appendix has been destroyed by inflammation, the operation of cecostomy may be done instead. When the appendicostomy has performed its service, the opening may close spontaneously. If it does not close, the wound may be opened as before, and the appendix amputated at its base as in appendectomy.

Cecostomy is done for the same conditions as appendicostomy. Of the two operations cecostomy is to be preferred. The approach is the same. The cecum is brought into the wound and a point in the anterior longitudinal band selected for the opening. A valvular opening is made after the method of gastrostomy (page 731). A purse-string suture is cast about the point selected; and another similar suture placed around the first. A very small opening is made into the cecum, and a catheter inserted through it into the bowel. First the inner purse-string is tied, and then the outer, in such a way that the wall of the cecum is pressed inward making a teat inside of the bowel with the catheter emerging at its apex (Fig. 1227). The ends of the two

sutures are secured to the abdominal wall and the rest of the wound closed about the catheter. Irrigation may be begun forthwith. Adhesions are quite firm in two days.

C. L. Gibson, who described this operation in 1902 (Boston Med. and Surg. Jour., Sept. 25), and whose idea preceded that of Weir for making a cecal fistula for colitis, made a simple fold in the wall of the bowel by applying two sutures and then a row of four sutures folding under the first two. A soft No. 30 F. catheter is used.

The irrigations and dressings can soon be managed by the patient. The catheter is introduced and the medicated fluid is thrown into the cecum and expelled by the rectum. Some of the fluid enters the small intestine. Irri-

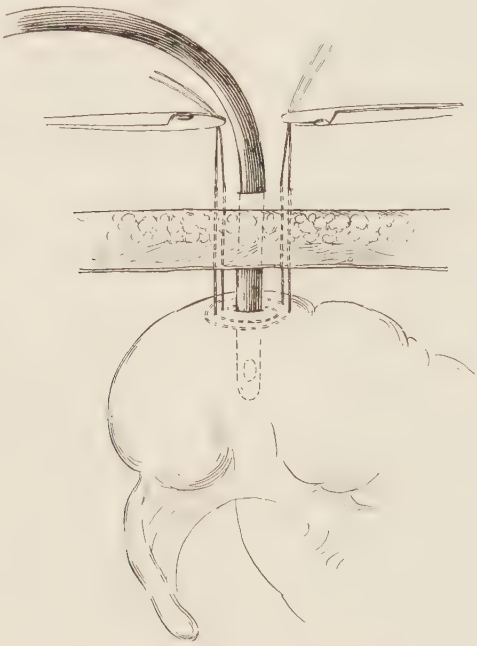

Fig. 1227.—Cecostomy.

Three purse-string sutures have been placed on the wall of the cecum. A catheter is passed through a puncture in the abdominal wall and through a puncture in the purse-string circle. The innermost suture is tied tightly around the catheter. The ends of the other two sutures are passed through the abdominal wall on opposite sides of the puncture and tied externally.

gation may be practised once daily, or more or less frequently as the case may require. With such a fistula the cleansing of the colon is entirely in control. Irrigation through the entire length of the colon may be continuous if desired. By inserting a tube in the rectum the patient may be spared the effort of expelling the rectal contents.

Colostomy and *enterostomy* for securing rest for the colon in the treatment of diseases of that viscus are a useful combination. An artificial anus is made at the lower end of the ileum and a cecostomy is done for purposes of irrigating the colon. This operation is of value in chronic colitis, amebic colitis, ulcerative colitis, tuberculosis, obstructive disease in which radical operation cannot be done, and in chronic intestinal stasis.

The abdomen is opened through the lower part of the right rectus muscle. An appendicostomy or a cecostomy is made through a stab wound external to the rectus opening, and a tube fixed in the cecum (see Appendicostomy, page 571; Cecostomy, page 572). The lower end of the ileum is brought into the abdominal opening in the right rectus muscle, and an artificial anus made with a spur (see page 683). A large rubber tube is fixed in the ileum to carry discharges away from the wound. Later the tube is dispensed with. If the opening of the bowel is deferred for a few days no tube need be used.

After a few days, irrigation of the colon may be practised as described under appendicostomy and cecostomy. With a tube in the rectum irrigation through the colon may be carried on daily without discomfort or effort on the part of the patient. The artificial anus in the lower end of the ileum provides rest for the colon. By this treatment much better results are secured than when the fecal current is allowed to continue through the colon.

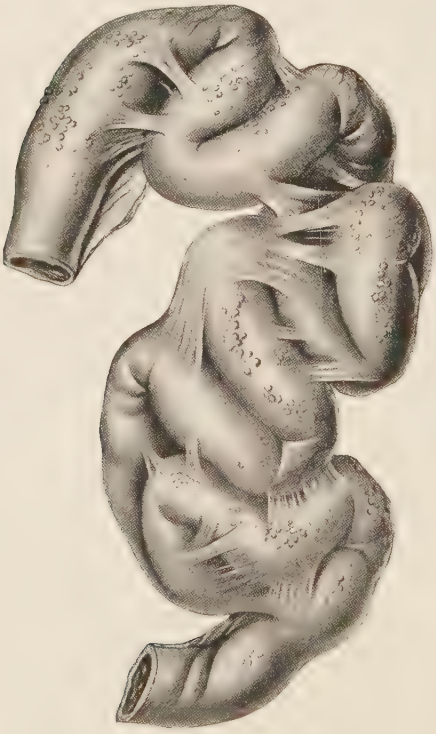

Fig. 1228.—Resected Tuberculous Coils of Intestine.

This operation will do everything for *chronic intestinal stasis* that can be expected from the more formidable procedures. The discharge from the ileum is much less offensive than that from the colon. When the disease is cured, the openings may be closed (see Closure of Fecal Fistula, page 616). J. Y. Brown (Surg., Gyn. and Obst., vol. xvi, 1913) divided the ileum at the cecum, and fixed the end of the bowel in the wound, after closing the distal opening, and placing a cecostomy tube in the front wall of the cecum.

Through-and-through washing of the bowel with sterile water or saline solution may be done twice daily or oftener. If any medicated substances are used, the bowel should first be washed out. Such agents as quinin, hydrastin, boric acid, silver nitrate in 0.03-Gm. (½-grain) dosage, methylene blue, ichthyol, and iodoform are used. It should be remembered that the large intestine absorbs these drugs and the dosage should be regulated accordingly.

Acute phlegmonous inflammation of the intestine, if presenting abscess foci, should be treated by free longitudinal incision of the abscess areas, and drainage. A case of interstitial infection of the descending colon was treated by C. N. Dowd (Annals of Surg., vol. 56, 1912) by resection, with recovery.

Tuberculosis of the intestine requires the general treatment described for tuberculosis (Vol. I, page 276). It usually demands operative treatment when the above measures fail, or when symptoms of stricture, ulceration and adhesions, or ulceration and diarrhea, call for relief. The best results are secured by resection of the tuberculous bowel. This usually means resection of the segments containing stricture. If a series of strictures are close to-

gether, the whole may be resected; if they are some distance apart each segment separately should be removed. In case of a coil of intestines, matted together by adhesions the whole coil may be resected (Fig. 1228). If such a coil cannot well be removed the bowel may be divided immediately above and below the disease and the two healthy ends united. The two ends of the irremovable coil may be brought out through the wound and fastened, for purposes of drainage and subsequent irrigation and medication. The later removal of the disease should be planned.

It is possible that, if tuberculosis of the bowel were recognized before stricture and adhesions had formed, local treatment may be of some service. A valve fistula, such as described above for cecostomy might be made above and below the disease, and irrigation and medication instituted, the fluid being injected at the upper opening and allowed to escape through the catheter in the lower opening.

Tuberculosis of the cecum is the most common form of intestinal tuberculosis and should always be had in mind. Early cases should not be operated upon as for appendicitis alone, and late cases should not be confused with carcinoma. Whatever is done the appendix should be removed. The extent of the disease and the condition of the patient must control the operative procedure. As the disease is usually primary, early cases may be cured.

Excision of the ileocecal segment of the bowel is the operation of choice. It can be done in early cases in which the cecum is freely movable. It is called for if the disease has not widely extended, if adhesions have not yet made it impossible, and if the condition of the patient is good. The cecum is lifted up, the mesentery of the ileum and colon are tied and divided, and the diseased segment resected. The intestinal anastomosis may be a lateral or end-to-end union. The lowest mortality is associated with resection in two stages as for cancer of the intestine. Some surgeons prefer to do a lateral anastomosis at the first operation, and then at a second operation to do the resection. These latter operations are to be preferred to primary resection.

Ileocolostomy will relieve most cases and cure many. The ileum is anastomosed to the colon not nearer than 6 cm. (2½ inches) on either side of the disease. A simple lateral anastomosis is made. This is of especial value in cases with adhesions and obstruction. The symptoms are relieved, the patient improves in strength, and may go on to recovery. Later the diseased segment may be resected. For this reason the anastomosis should be done far enough away from the disease to permit resection.

Intestinal exclusion may be combined with the above operation. If the disease is extensive ileosigmoidostomy may be done, combined with exclusion of the diseased bowel.

Artificial anus, just above the disease, in the lower end of the ileum, may be done in desperate cases with obstruction. It should be followed by ileocolostomy or resection.

After performing ileocolostomy and exclusion, if ulceration is present, direct medication may be applied by doing a secondary colostomy. Through such an opening the disease may be directly cleansed and medicated. This is rarely indicated, as healing rapidly takes place as soon as the fecal current no longer passes through the diseased segment.

The same treatment as is described above for tuberculosis of the intestine may be employed. The general hygienic treatment is most important (see Tuberculosis, Vol. I, page 276).

Actinomycosis of the intestine usually appears in the colon; the appendix

and cecum are the common seats. By the time a diagnosis has been made it usually has extended too wide for extirpation. The tissues break down and an abscess or fistula forms. This should be incised and curetted out, removing in this way all that can safely be removed. Free drainage should be secured. Local treatment is by peroxid of hydrogen, iodin or some other antiseptic. The general treatment of actinomycosis is called for (see Vol. I, page 272).

Typhlitis and *perityphlitis* are terms which once were applied to appendicitis. They still have a place in surgery, as inflammation of the cecum, without appendicitis, sometimes requires treatment. Most cases belong to the inflammations of the lining of the colon, the treatment of which is described under colitis. I have seen these cases, often simulating appendicitis, recover under a restricted regimen. The infection may invade the whole thickness of the wall of the cecum and provoke peritonitis, precisely as occurs in appendicitis, the appendix being involved but secondarily in the disease, or abscess may develop beneath the peritoneum. I have operated upon such cases, removing the appendix and otherwise conducting the operation as for appendicitis. Gangrene of the wall of the cecum is sometimes found, either as a primary disease or associated with gangrene of the appendix. The gangrenous area should be excised and the wound closed with drainage. Small gangrenous areas, which seem to have reached their limit, may be inverted by sutures in the healthy bowel; this is not to be preferred to excision.

Pericolitis may occur where infection traverses the wall of the colon; and require either the treatment described for peritonitis or for retroperitoneal infection.

Ulcers and Perforations of the Intestine.—*Ulcer of the duodenum* should at first receive internal treatment. This consists in improving the general hygiene of the patient, abstinence from hearty meals, spices, and acids, and the administration of certain substances to act directly upon the ulcer. It is important that the stomach should not become dilated. Meals should be small and dry. Water should be taken warm, and preferably when the stomach is empty; it then passes into the duodenum and cleanses the ulcer. Calcined magnesia 0.5 Gm. (8 grains) and subnitrate of bismuth 2.0 Gm. (30 grains) are given 3 times a day, half an hour before meals. Adrenalin, given by stomach, will relieve pyloric and cardiac spasm in most cases. Olive oil, 30 c.c. (1 ounce) morning and evening has been of service in some cases. Rest in bed is demanded for cases with severe pain, gastric disturbance or hemorrhage. It has been suggested that a highly proteid diet is of value to take up the pepsin and trypsin which otherwise would attack the ulcer.

Hort (British Med. Jour., Jan. 8, 1910) accomplished this by feeding small dry meals, mainly of meat, and the use of an antilytic serum. He also gave normal horse serum subcutaneously. Herschell (Clinical Journal, Aug. 10, 1910) insisted that a band should be worn to support the abdomen. He neutralized the digestive ferments by a daily dose of horse serum, given by mouth. All vegetables should be put through a sieve. Internal treatment failing to give relief, or if perforation takes place, or serious narrowing of the duodenum develops, or hemorrhage is intractable, operation should be done.

B. W. Sippy (Musser and Kelly: Handbook of Practical Treatment, Vol. III, 1911) treated peptic ulcers of the stomach and duodenum by neutralizing the gastric juice. This is done by giving food at such times as are necessary to keep the digestive juices absorbed by food, administering alkalies between feedings, and emptying the stomach of juices during the

night. At first in most cases a restricted diet is given hourly from 7 a.m. till 7 p.m. A powder containing 0.6 Gm. (10 grains) each of heavy calcined magnesia and bicarbonate of soda is given between feedings, alternating with a powder containing 0.6 Gm. (10 grains) of bismuth subcarbonate and 2 Gm. (30 grains) of sodium bicarbonate. Larger quantities are given if necessary. All this should be regulated by tests for acidity (Jour. Am. Med. Assoc., May 15, 1915). These are some of the medical conceptions of the treatment of the disease. Their value is doubtful.

When I was treating these cases medically I found most gratifying results from the administration of large quantities of water. The object of this was to dilute the gastric juice, so that the acid solution which entered the duodenum was a very weak one, and to irrigate the ulcer with a mild acidulated fluid. I satisfied myself at least that cures were effected by this expedient alone. No nonoperative treatment guarantees against recurrence.

Jejunal feeding has been practised with some success, using food which has been subjected to artificial ptyalin, pepsin and acid digestion. Food is introduced directly into the bowel through a tube passed through a jejunostomy opening. This method is of value in ulcer of the stomach and in ulcer of the duodenum.

Direct duodenal medication is applied by the duodenal tube, which the skilled gastrologist is able to pass into the duodenum by way of the mouth and stomach. With such a tube in the duodenum, the bowel may be washed out, medication applied to the ulcer, and food injected into the jejunum. These methods have not been generally adopted as routine measures.

E. C. Rosenow (Jour. Am. Med. Assoc., Nov. 23, 1915) has showed that infections in the mouth, especially at the roots of the teeth are commonly due to streptococci which are capable of provoking and perpetuating ulcers of the pyloric region. Therefore these lesions in the mouth should be looked for with the *x*-ray, and treated, as one of the first steps in the therapy of peptic ulcers. So also should infections of the gall-bladder and appendix.

Indications for operation must vary with the condition of the patient and the availability of skillful surgery. In general it may be said that operation is indicated: (1) in cases of perforation; (2) in repeated, uncontrollable, or constant loss of blood, either by vomiting or in the stools, or expressed by subnormal hemoglobin in the circulation; (3) in uncontrollable pain; (4) when contracture of the duodenum or pyloric spasm causes obstruction to the exit of gastric contents; (5) when defective nutrition is interfering with the health of the patient; and (6) in failure of medical treatment to cure the disease after thorough trial. A characteristic of the symptoms of duodenal ulcer is their intermittency. These periods of freedom from symptoms are often interpreted as a cure. The permanence of medical cures cannot be assured, and are always doubtful. Inasmuch as operation is capable of giving positive results, it must be regarded as the treatment of choice in unhealed chronic ulcers. Operation will cure most cases. Failures and recurrences after operation are usually due to faulty technic.

Operative treatment of duodenal ulcer is the only guarantee of cure. The operation of choice is excision of the ulcer and gastroduodenostomy or pyloroplasty to provide free drainage of the stomach. The ulcer should be removed by an elliptic or circular excision of the whole thickness of the ulcerated area of duodenal wall. The cases in which excision cannot be done are those with much thickening, induration and adhesions. In these gastrojejunostomy is easier; but the surgeon may often excise the ulcer in these cases after the gastrojejunostomy has been done.

Excision is called for especially if hemorrhage has been a serious feature

or if the ulcer is near to perforation. All of this can be done without excluding the remaining healthy duodenal mucous membrane from the energizing contact of the gastric juice. Excision of the ulcer is usually a simple matter, because the ulcer is usually single and situated in the upper and anterior aspect of the gut.

Ulcers of the anterior wall, if small and without much induration, may be treated by excision without doing pyloroplasty or gastro-enterostomy. But in doing this operation the surgeon should be sure that there is not a contact ulcer on the opposite side of the duodenum; and the wound should be closed in such a manner as not to narrow the bowel caliber.

Pyloroplasty has been advocated especially by J. M. T. Finney as the operation of choice. It possesses the merit of exposing the ulcer and permitting excision at the same time if on the anterior wall. This operation surely provides adequate drainage. Finney claims that it gives every advantage that gastrojejunostomy gives, and does not create the abnormal conditions which characterize gastrojejunostomy. Moreover, it is a more simple operation. It is highly possible that this operation is destined to become the procedure of preference (see Pyloroplasty, page 740). The essential surgical treatment is free drainage of the stomach and relief of an ulcerated area from the irritation of gastric juice. There is a growing feeling among surgeons that excision is the rational treatment of ulcers. If excision is not done, gastro-enterostomy or pyloroplasty is urgently called for. These operations are probably the only curative treatment. Nonoperative treatment produces only doubtful cures.

For certain cases, jejunostomy may be done. This operation is capable of giving rest to the diseased bowel. By feeding the patient through a tube in the jejunum, nothing but stomach and duodenal juices come into contact with the ulcer. These juices may be greatly diluted by having the patient take an abundance of water by the mouth.

Gastrojejunostomy continues to be the operation of choice with many surgeons. Closure of the duodenum after gastrojejunostomy, in order to exclude it entirely from the irritation of food and gastric juice, is of doubtful value. The gastrojejunostomy alone is capable of curing most ulcers. At the same time, the gall-bladder and appendix should be examined and operated upon if found infected.

It is wise in some cases to infold the ulcer-bearing area in these cases with stout thread in order to occlude the duodenum and cover the base of the ulcer. The suture may be placed for the special purpose of causing obstruction. It produces a plication of the duodenum. Obstruction produced by this external suturing is not permanent, but it lasts long enough to allow the ulcer to heal.

If the ulcer recurs after gastrojejunostomy, it is easy enough to do an operation for *permanent occlusion of the pylorus*. This may be done by dividing the pyloric end of the stomach and closing the two ends. Or a band of fascia cut from the sheath of the rectus may be passed about the pyloric end of the stomach, woven under the peritoneum, and drawn down tightly enough to close the lumen.

The effectiveness or necessity of permanent occlusion is doubtful. It surely has some positive disadvantages. This expression is prompted by the finding that intestinal digestion and assimilation are much dependent upon the secretion of the duodenal mucous membrane, and that this secretion is poured out in response to the stimulus of gastric juice. Occlusion of the duodenum, of course, must be done in cases in which perforation is threatening, and excision of the ulcer is not done. It is also well in such cases to

cover the ulcer base with omentum. If excision of the ulcer is not done, gastroenterostomy may be regarded as the operation of choice. Excision of the ulcer and simple closure of the wound are rational additions to it, but by no means essential for a cure.

W. J. Mayo has called attention to the "curative effect of perforation," showing that after perforation and recovery of the patient from the peritonitis, the ulcer heals. He has duplicated nature's method in some cases, cut out the center of the ulcer, closed the wound, and secured healing.

Operation for perforating duodenal ulcer is quite a different matter. This is not an uncommon disease, and, because of the tendency of the infection to travel down the outer side of the ascending mesocolon, is sometimes treated as appendicitis. As about 90 per cent. of duodenal ulcers occur on the anterior surface of the first portion, access to the lesion is not difficult.

(*a*) In acute perforation through the peritoneum, with rapid escape of much duodenal contents into the general peritoneal cavity, the patient rapidly goes into a state of shock, and any treatment to save life must be quickly applied. The fate of the patient depends much upon the promptness of operation. After twenty-four hours, operation offers little hope; within the first eight hours operation can save the patient without question. Operation should be done as soon as possible; shock is no contraindication.

Measures to combat shock should be employed at once with the preparation for operation. No single treatment has greater value than an intravenous infusion (see Shock, Vol. I, page 213; Shock in Peritonitis, pages 546, 551; Rupture and Wounds of Intestines, page 566). The duodenal region should be exposed as soon as possible. All of the foreign matter should be aspirated or sponged out. Even though widespread, irrigation is undesirable. The opening in the bowel should be closed with a purse-string suture of linen or an infolding suture may be applied. It is well also to place an edge of omentum over the place of suture, and hold it there by a few stitches. Drainage may or may not be used. If there has been pus and plastic lymph, drainage should be employed; a pelvic drain is essential. The operation should be rapidly completed.

If the perforation is in such a position that it cannot easily be sutured, a drain should be carried down to it, and gauze packing should hold back the intestines from the drainage tract.

These acute perforations are the common cases. J. B. Deaver and many other surgeons treat them by adding posterior gastrojejunostomy to the plication of the perforated duodenum. The surgeon must be guided by the ability of the patient to bear further operation, and his own ability to perform gastro-enterostomy quickly. Gastro-enterostomy is desirable in most cases because the plication or suture of the ulcerated area narrows the lumen of the duodenum and produces more or less duodenal obstruction. Some surgeons are not deterred even by suppurative peritonitis.

(*b*) In acute perforation through the peritoneum, in which the amount of duodenal contents to escape is small, the infection may remain localized to a limited area and become walled off by adhesions. This abscess should be opened and sponged out, and the perforation closed with a suture. The area should be drained for a few days. It may occur in these cases, if they are not promptly operated upon, that additional leakage causes the limiting adhesions to give way and the infection to become a diffuse suppurative or septic peritonitis.

(*c*) In chronic perforation through the peritoneum, in which plastic exudate and adhesions cause a thickening over the inflamed area, representing the floor of the ulcer, perforation may be so gradual that it amounts

simply to the infection of a small surface of plastic fibrin. These cases may not come to operation until the extra-intestinal adhesions cause disturbance of function, long after the ulcer has healed. Adhesions about the duodenum are so common that this condition is perhaps more frequent than is supposed. In some of these cases, actual perforation does not take place, the ulceration stopping short of the peritoneum, but the inflammation penetrating it.

(*d*) In chronic perforation into the retroperitoneal space an abscess behind the peritoneum may result. This is the rarest condition. The abscess migrates externally, heals spontaneously, or it may rupture into another viscus (see Retroperitoneal Abscess, page 563). It requires the treatment of retroperitoneal infection.

In any form of perforation with peritonitis other openings may have to be made for drainage of regions remote from the duodenum. This applies especially to the right flank. Gastro-enterostomy may be done in the chronic and less acute cases. Usually the conservative policy consists in attention to the perforation alone, and later, if pyloroplasty or gastro-enterostomy is indicated, it may be done. If hemorrhage is a feature of the case, excision of the ulcer and ligation of the bleeding vessel is demanded.

The results in perforated ulcer depend much upon the promptness of operation. Cases operated upon within five hours of the perforation may be expected to recover, after removal of foreign matter, and closure of the perforation. After ten hours, the prognosis grows more serious, but recovery may be expected in the majority of cases. After fifteen or twenty hours the the prognosis becomes grave, except in the limited and chronic cases.

Pyloroplasty or gastro-enterostomy may properly be added to the primary operation, if the operation is done within ten hours after the perforation, if the general condition of the patient is good, if the surgeon has skill in this procedure, and if it can be done under the best of operative conditions. Otherwise the primary operation upon the perforation should suffice.

Jejunal ulcer and *gastrojejunal ulcer* are commonly results of gastrojejunostomy and must be prevented by a proper technic. Usually these ulcers have been found to be due to linen or silk thread used in the gastrojejunostomy, the unabsorbed thread causing the irritation which produces the ulcer. This is obviated by using chromicized or other slowly absorbable catgut in the mucous membrane. The treatment of the condition calls for separation of the jejunum from the stomach, closure of the two openings, and the performance of pyloroplasty to provide free drainage of the stomach. If the adhesions prevent this operation then the ulcer should be exposed by incision through the wall of the stomach or duodenum. The ulcer and sutures should be removed, and the wounds closed. If there is much induration and contracture, precluding pyloroplasty, the anastomosis must be separated and a new gastro-enterostomy done in sound tissue.

Perforating typhoid ulcer does not yet receive adequate treatment. Comparatively few cases are saved. It is estimated that about one-third of the deaths from typhoid fever are due to perforation. In the U. S. Army in 1899 I saw many cases of typhoid; in which, death was due to perforation in 90 per cent. of those coming to autopsy. Perforation occurs usually between the fourteenth and twenty-first day of the disease, most commonly in the lower ileum. Most perforations occur in the last 30 cm. (12 inches) of the ilium. The ileum higher up, the cecum, or vermiform appendix may be the seat of the perforation. The opening in the gut varies from the size of a a pin to that of a lead pencil (1 to 7 mm.).

The operation should be done as soon as the disease can be recognized,

sudden pain, tenderness, and rigidity being the chief signs. The patient should be fortified against further shock (see Shock, Vol. I, page 213; Prevention of Shock, page 532; Peritonitis, page 546; Rupture of Intestines, page 566). Ether and nitrous oxid anesthesia is borne well by these patients. The lesion is best exposed at the site of greatest tenderness. This is usually to the right of the median line just below the level of the umbilicus. The opening in the abdomen is best made at the outer border of the rectus. If the lesion does not come at once into view, the ileum should be found by first identifying the cecum. Intestinal contents, serum, and plastic lymph should be aspirated or sponged away. The perforation, if small may be closed with a purse-string, or in-folding suture of fine chromic catgut. Usually the intestinal wall will be found thin about the perforation, and the suture should embrace all coats. A second suture may then be applied transversely to the gut, not penetrating the whole wall of the bowel, and covering in the first suture. Drainage is probably best dispensed with excepting in late cases in which the patient has survived long enough to produce an abscess.

More than one perforation may sometimes be found. Subsequent perforation should be similarly operated upon. In the region of the perforation, thin, necrotic-looking places will often be found at the first operation. These mark the site of other ulcers, and if the condition of the patient will permit, it is wise to infold these thin areas by a row of transverse sutures, passing through serosa and muscularis. Where necrotic gut or multiple perforations with necrosis are found, the making of a resection or fecal fistula must be decided by the exigencies of the case.

Typhoid ulcers perforating the appendix should be treated by removal of that organ. Perforation of the colon or other viscera is to be treated by the methods already described.

The mortality from typhoid perforations should be lowered. Consent to operate should be secured in all cases of typhoid before perforation is even threatened, and a surgeon should be in touch with the medical attendant from the beginning. It should be well understood that a perforation not recognized early and operated upon early, reflects seriously upon the competency of those responsible in the management of the case. The modern treatment of typhoid is rapidly eliminating this disease.

Tubercular perforation of the intestine is usually a chronic perforation, preceded by adhesions which prevent diffuse peritonitis. The area of local peritonitis should be exposed and drained. An intestinal fistula results. the resection of the diseased bowel may be performed at the first operation or undertaken later. The perforation is usually an incident of lesser importance in a more serious disease (see Tuberculosis, Vol. I, page 276; Tuberculosis of the Intestine, Vol. II, page 574).

Malignant perforation of the intestine is that of cancer of the bowel. It perforates somewhat like tuberculosis, the perforation being preceded usually by adhesions which confine the infection. The treatment becomes that of the original disease, fecal fistula, and intestinal obstruction.

Perforation of gaseous cysts is very rare and requires infolding or excision of the cyst wall with suture of the opening.

Suppurative perforation occurs from without inward. A walled-off peritoneal abscess or an extraperitoneal abscess becomes adherent to the bowel, and perforates through its wall, discharging pus into the intestinal canal. Such abscesses often heal spontaneously, or they may become reinfected and repeatedly discharge. Usually it is well to give such an abscess an opportunity to heal without interference. If it continues to fill and empty, it

should be exposed and treated externally. The intestinal fistula which remains may require subsequent treatment.

Duodenal fistula is one of the most serious results of duodenal perforation. In operating, every effort should be made to prevent it, as a duodenal fistula tends not to contract but to enlarge; the combined secretions of the stomach, liver, duodenum and pancreas are poured out in enormous amount; the skin and surrounding tissues are prone to become ulcerated and necrotic; the patient rapidly loses strength; and death has been the result in most cases. This condition can in no sense be thought of lightly as an ordinary intestinal fistula. As soon as the fistula is discovered, and before the patient has become greatly reduced, feeding by mouth should be stopped. The patient should be given nourishment and fluids by rectum. Glucose and bicarbonate of soda should be given. To prevent digestion of the skin the sinus should be kept filled with petrolatum. Atropin and adrenalin inhibit gastric secretion. An alkaline solution, allowed to flow into the fistula, by the drip method, is often curative.

By giving the patient large quantities of liquid paraffin by mouth the fistula may be kept bathed with this fluid. The bowels should be kept open with castor oil. Gradually foods which do not excite much gastric secretion may be given.

If the surgeon desires to undertake operative treatment, it should be instituted before the patient becomes hopelessly weak. Gastrojejunostomy is capable of draining the stomach; and, by combining the operation with pyloric occlusion, the duodenum is relieved of the presence of gastric contents. Dissecting out the fistula and closing the opening in the bowel, as can be done lower in the intestine, is possible with skilled hands.

Perforation of the colon may result from any of the ulcerative conditions, and requires treatment not essentially different from that of the small intestine. Diffuse soiling of the peritoneum is not so apt to be present. If there is any question as to the expediency of suturing the opening, it is always wise to make an artificial anus.

Tumors of the Intestines.—The intestines being composed of epithelium, glands, muscle, connective tissue, fat, blood-vessels, lymphatics and endothelium, may be the seat of a great variety of new growths. The treatment of these does not differ from that of tumors elsewhere, excepting that they produce or threaten intestinal obstruction or stasis, and then the treatment must be aimed to meet those conditions.

Benign tumors should be removed if they cause symptoms (see Tumors, Vol. I, page 323). If discovered unexpectedly the judgment of the surgeon must determine whether the tumor is growing or is apt to make future trouble. The possibility of even a small tumor causing intussusception, polypus or other obstructing condition is so great that the removal of any tumor of the bowel wall should be regarded as conservative surgery, provided the condition of the patient does not contraindicate the operation. Resection of the bowel should be done if the closure of the wound after removal of the tumor is going to narrow the lumen more than 33 per cent. In some cases closure by angulation can be done (see page 569). *Polypoid adenomata* should be removed wherever discovered because of their tendency to produce intussusception, hemorrhage and to undergo malignant degeneration.

Cysts of the intestinal wall should be removed. If possible this should be accomplished without incision of the mucous membrane (see Cystomata, Vol. I, page 325). *Gaseous cysts*, if uninfected, may be incised, the interior irritated with iodin and the wound closed. Infected cysts should be treated

as abscess of the wall of the bowel, the infected fluid evacuated and drainage established.

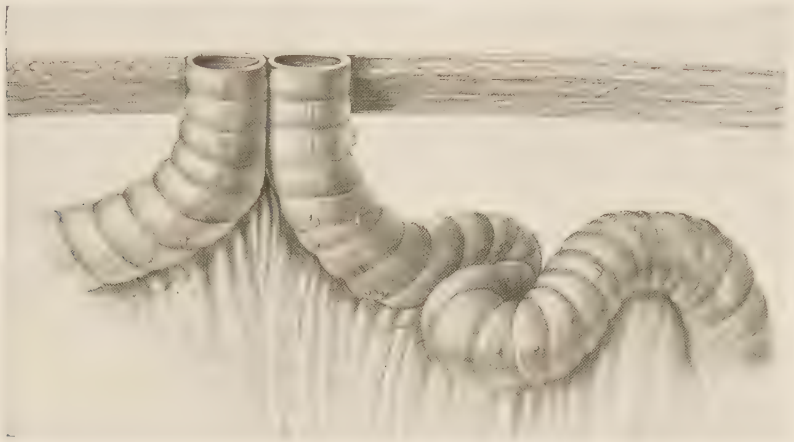

FIG. 1229.—OPERATION FOR CANCER OF THE COLON WITH SERIOUS SYMPTOMS OF INTESTINAL OBSTRUCTION.

First operation. An artificial anus is made above the tumor. This saves the patient from obstruction. Note disease of bowel some distance below the opening.

Malignant tumors may occur in any part of the alimentary canal. *Sarcoma* of the intestine is usually fatal inside of a year. Treatment inaugurated

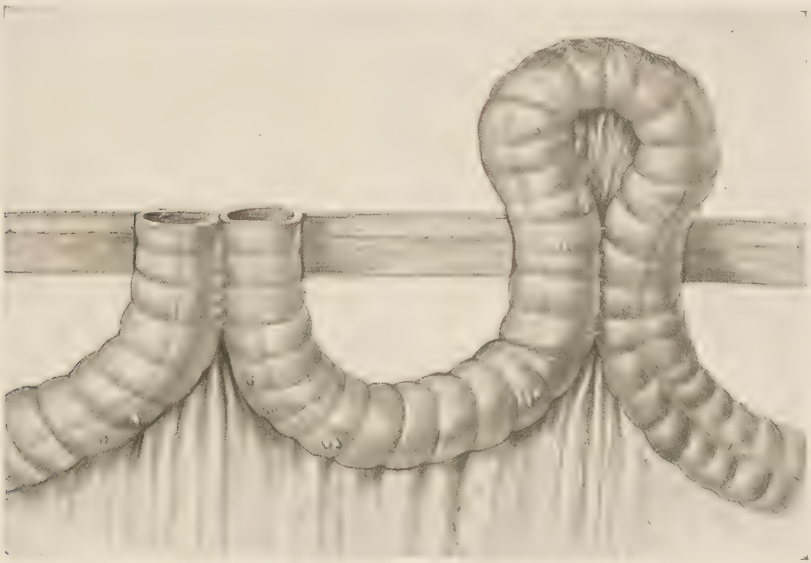

FIG. 1230.—OPERATION FOR CANCER OF COLON.

Second operation. The loop of bowel with the tumor is fastened outside of the abdomen through a lower wound if the mesocolon is long enough to permit.

after symptoms begin usually is too late to save the patient. The cases that will be saved by operation are those in which the tumor is accidentally

discovered in an early stage. The small intestine is commonly the seat of the disease.

Carcinoma occurs usually in the colon. The sigmoid flexure, the cecum, the splenic flexure, the hepatic flexure, the transverse and the ascending

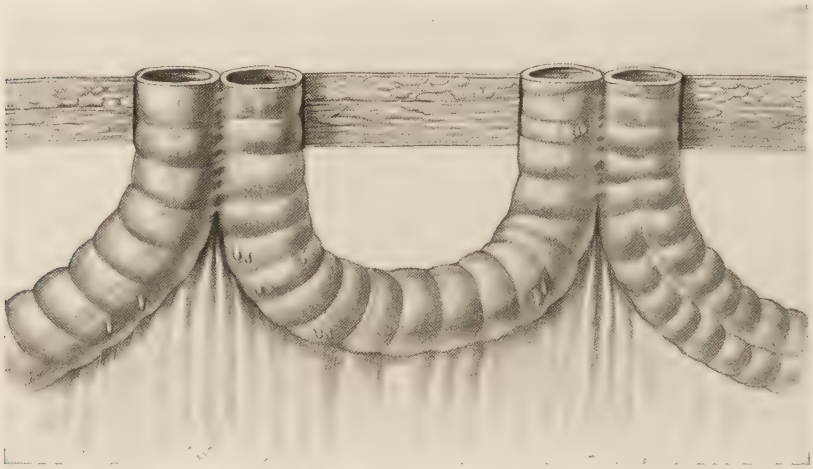

FIG. 1231.—OPERATION FOR CANCER OF COLON.
Third operation. The tumor with the adjacent bowel is removed. This leaves two colostomy openings.

colon are the common sites. Surgical treatment offers much in this disease if applied early. Ulceration of the mucous membrane is usually present when these cases come to treatment, and the region of the disease is in

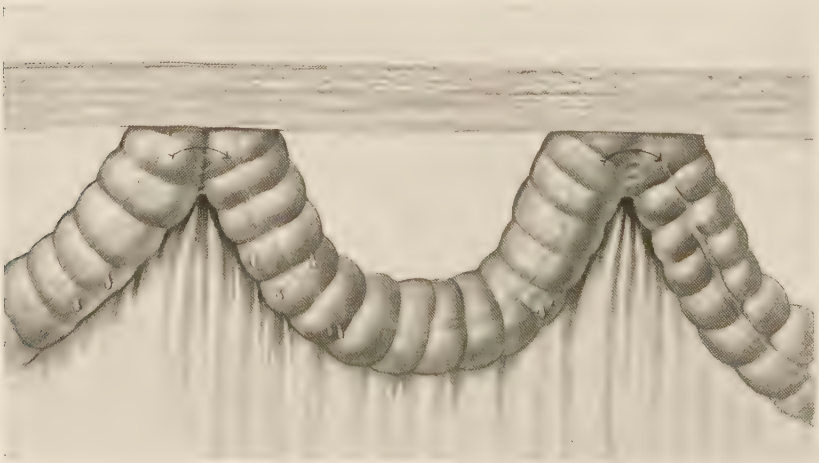

FIG. 1232.—OPERATION FOR CANCER OF COLON.
Fourth operation. The spurs in the colostomy openings have been divided and the openings in the bowel and abdominal wall closed. The bowel is left attached to the abdominal wall.

an infective state. In addition to this there is often stasis above the tumor, and the patient is not only suffering with cancer but intestinal obstruction

also. This may be chronic or acute. For these reasons a completed curative operation in one stage cannot often be done.

The best results have been secured by operating for carcinoma in two or more stages. Each case is peculiar. Many are best treated by doing first a colostomy well above the disease, making an opening where it will not conflict with the later operation (Fig. 1229). This relieves the obstruction and drains the bowel. After a week or two of recuperation, the tumor is exposed and a curative operation accomplished if possible by wide resection of the growth. The two ends of the bowel are brought into the wound and fastened there. Then at the convenience of the surgeon and patient the fistulæ may be closed. This series of operations can be done without operative mortality.

In some cases all of these operations can be done without exposing the peritoneum to infection from the bowel at any time. Thus, if there is not acute obstruction, the colostomy may be done by fixing the gut in the wound

Fig. 1233.—Operation for Cancer of Colon.

Fifth operation. The two loops of intestine which are adherent to the abdominal wall are detached and the raw surfaces covered with peritoneum. The bowel is freed, its continuity is reëstablished, and the tumor has been removed with the minimum of exposure of the peritoneum to infection.

and opening it thirty-six hours later when adhesions are present; if the tumor is sufficiently movable, the segment of intestine bearing it may be brought entirely through the second wound and sutured (Fig. 1230), and the resection done with the cautery as an extra-abdominal operation when adhesions have formed (Fig. 1231); and next the two intestinal fistulas may be closed by dividing the spurs between the distal and proximal arms, and then freshening and suturing the external wounds (Fig. 1232). A still later operation may be done to liberate the bowel from its attachment to the two places in the abdominal wall (Fig. 1233). In cases of cancer of the sigmoid, for example, one operation may be done on the right side and the other on the left side.

Cases, in which the obstruction is not a pronounced feature, need not have the preliminary colostomy. The growth may be brought out of the wound and the resection done later. In this operation, the bowel should

have been well cleaned out, and, it may be best in the interim between the two operations, that nourishment should be by some other route than the stomach. The object of this is to prevent the ileus which might supervene on account of the evisceration.

In the colon the loop of intestine, having the tumor at its apex, is united for a distance of 10 cm. (4 inches) by a continuous suture in two lines (most

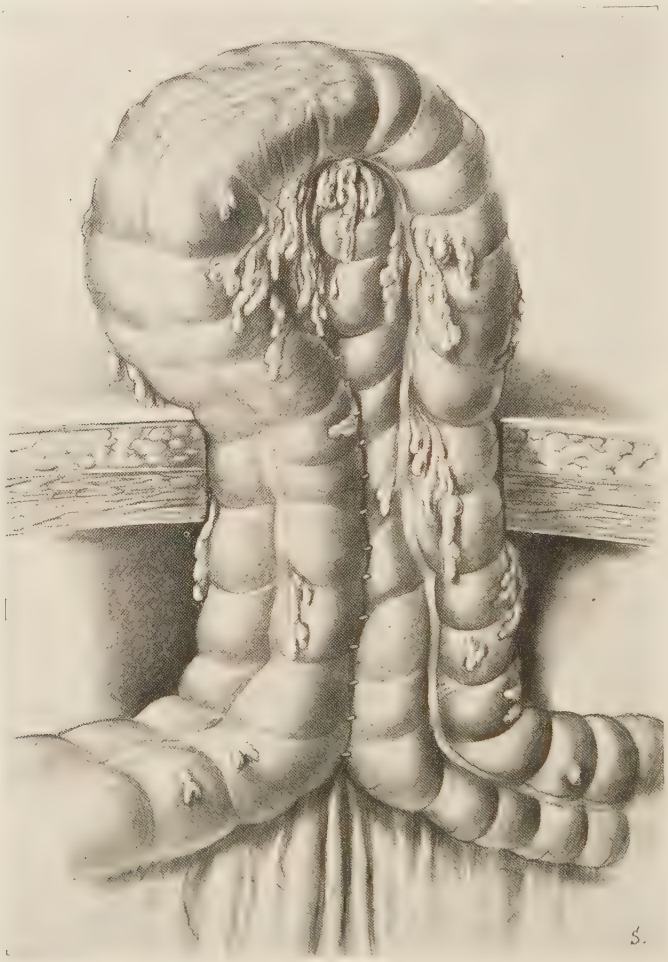

Fig. 1234.—Loop of Intestine with Cancer Fixed Outside of Abdomen. Showing bowel united to bowel to form a spur. This is the operation of choice in cases in which intestinal obstruction has not developed.

surgeons make but one line of sutures). The tumor is brought out through the abdominal wound and the bowel sutured to the wound-edges (Fig. 1234). At the end of three or four or five days, more or less, the loop of bowel, carrying the tumor, is amputated. No anesthetic is required. A few minute vessels may need to be tied. The wound surfaces are covered with a thick layer of petroleum jelly, and a dry gauze dressing applied. If there is much obstruction or question as to the vitality of the bowel, the resection may be

done at once, and a large-sized tube fastened in the upper segment to carry the discharges into a receptacle. Preferably the resection is deferred. Ten days or more after the resection a long pair of straight forceps is made to grasp the septum between the two limbs of the bowel, one blade being passed into each opening. It should be tightened a little every day (Fig. 1235). In a few days the pressure of the clamp has caused necrosis of the septum between the suture lines and a wide communication is established (Fig. 1236). This usually takes about five days. The later treatment is for closure of the

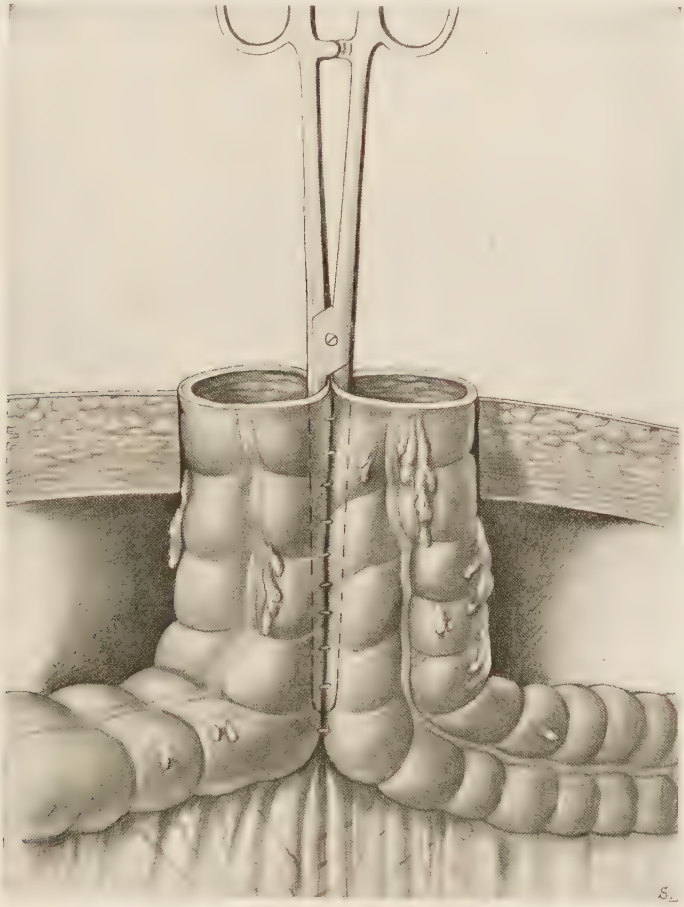

Fig. 1235.—Treatment of Cancer of Bowel.
The loop of intestine, bearing the tumor, has been amputated and the spur clamped.

fistula (page 616). This is the most satisfactory and least dangerous operation for cancer of the colon.

In many cases the shortness of the mesocolon will not permit sufficient evisceration to make this operation possible. In that event the mesocolon and any enlarged glands are dissected free from the back of the abdomen, and the gut bearing the tumor brought forward through the wound. This may mean that the mesocolon is divided completely through both layers. In from thirty-six hours to four or more days, the segment bearing the tumor

is resected. Or the resection may be done at once after the bowel has been sewed to the wound edges. In the small intestine the upper end may be cut off 5 to 7.5 cm. (2 to 3 inches) from the skin; and the two ends united by anastomosis suture or connected by a large tube. If the tumor is low down, a tube may be placed in each opening separately (Fig. 1237).

As a means of treating the distended loop of bowel above the tumor the glass tube is most useful. It permits keeping the parts clean while the patient is recovering from the obstruction (Fig. 1238).

Carcinoma of the intestine, if removable, may, of course, be treated by one complete operation; resection, enteroanastomosis and closure of the wound. In many cases this treatment may be employed. They are the cases in which the disease is discovered early before acute obstruction has developed, and the resistance of the patient is good.

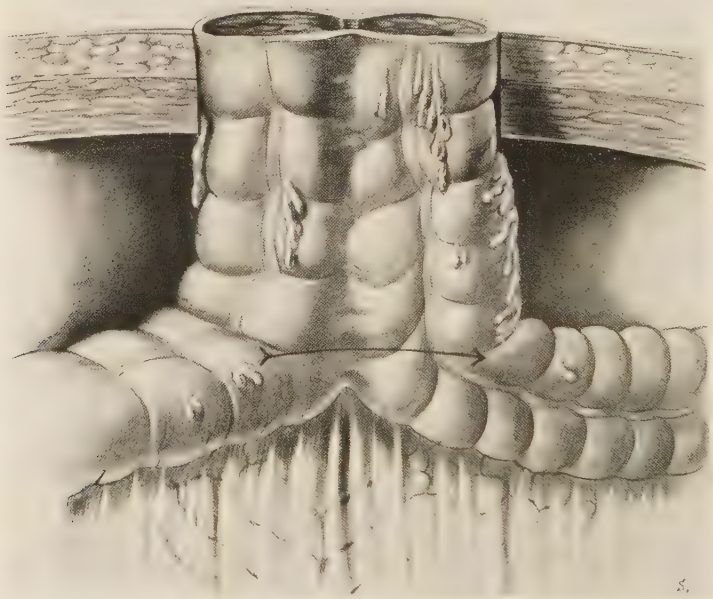

Fig. 1236.—Closure of Artificial Anus.
The pressure of the clamp has caused necrosis of the spur between the two loops and a wide communication is established.

In some of these cases the method of entero-enterostomy with the elastic ligature may be employed. The loop with the growth is brought out through the wound and a lateral short-circuiting anastomosis made with the elastic ligature (page 675) about 7.5 cm. (3 inches) from the tumor. The anastomosis is returned to the abdomen. The bowel is then clamped for resection of the tumor. A purse-string suture is placed around each arm of the bowel between the growth and the anastomosis. The distal limb is divided, its end closed and dropped back into the abdomen. The tumor is then removed by amputating through the proximal limb and a glass tube is fixed in the bowel. When the elastic ligature cuts through, the discharge from the tube stops and the bowel and abdominal opening may be closed.

An unfortunately large class of cases is not amenable to any of the above methods. These are the cases in which there are metastatic deposits or involvement of irremovable structures. Palliative measures are to be employed here. An artificial anus may be made in the bowel above the growth, an anastomosis may be made between the intestine above and below the tumor, or some of the other palliative measures employed (see Inoperable Carcinoma, Vol. I, page 327).

Carcinoma of the sigmoid is most successfully treated. Metastases are late, and often a wide resection may be successfully made in advanced cases. In the cecum, if the growth is one capable of being removed, it is usually best to excise the tumor and do an ileocolostomy at once. If the

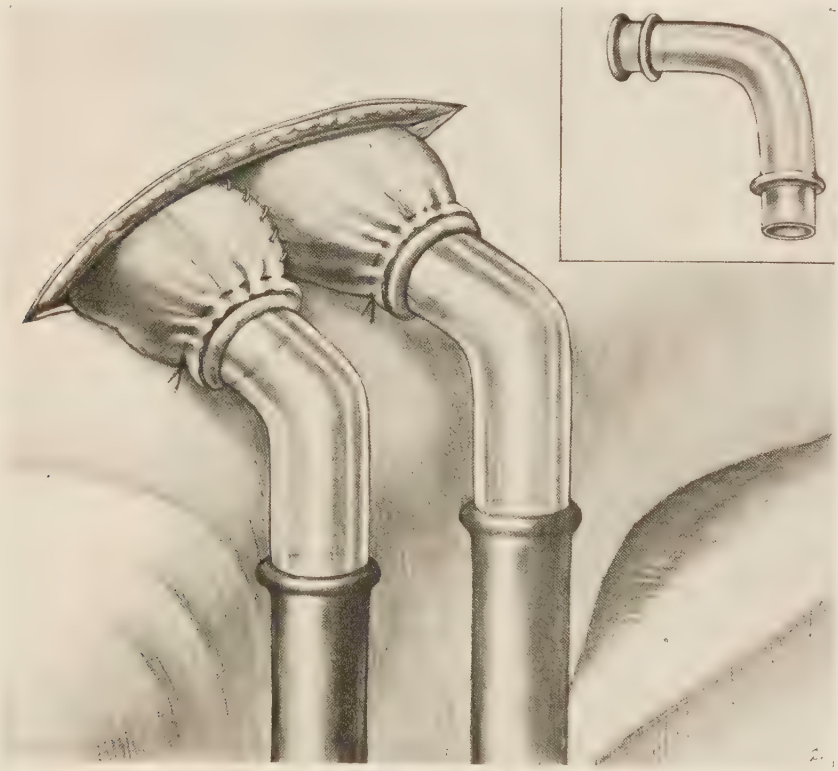

Fig. 1237.—Glass Tubes for Drainage of Bowel.
The two limbs of the colon are sewed together and a tube fixed in each.

growth cannot be removed, the best operation is still ileocolostomy, connecting the lower end of the ileum with the ascending colon well beyond the tumor.

The *lymphatics of the colon* follow the course of the blood-vessels. For this reason, to make resection of the bowel for cancer complete the mesocolon and the mesocolic vessels should be removed. J. K. Jamieson and J. F. Dobson (Annals of Surg., 50, 1909) showed that for *cancer of the cecum* or ileocolic region a radical resection demands removal of the lower 15 cm. (6 inches) of the ileum and the colon beyond the hepatic flexure. The lower border of the third part of the duodenum should be exposed, the peritoneum

divided and the ileocolic vessel found. The fatty tissue around the vessels should be stripped downward with gauze, and the artery and vein tied close to the superior mesenteric artery. Then the corresponding wedge of mesocolon and intestine should be removed (Fig. 1239).

For the radical removal of *cancer at the hepatic flexure*, greater difficulty is encountered because of the early involvement of the pancreas, duodenum and other neighboring organs. For removal of the lymphatic area, the middle colic artery should be divided at its roots close to the superior mesenteric. This removes the blood-supply of so much of the colon that it must be followed by removal of the lower 15 cm. of the ileum, all of the ascending colon, and half of the transverse colon (Fig. 1240).

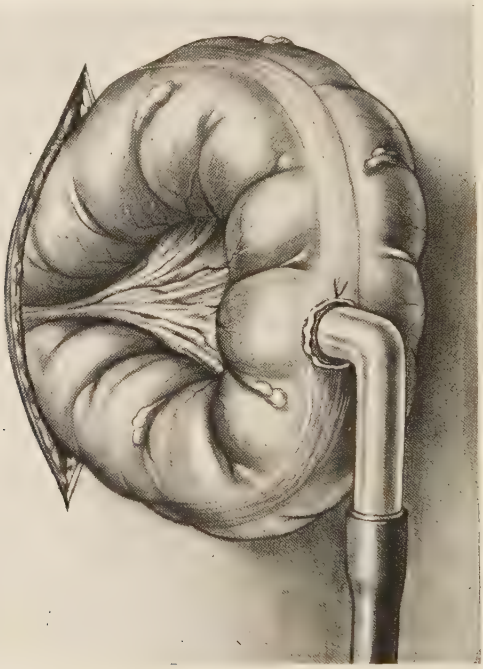

Fig. 1238.—Drainage of Loop of Intestine.
The single large glass tube provides drainage of the obstructed bowel and permits keeping the skin and wound clean.

For removal of *cancer in the middle of the transverse colon*, the lymphatics lie close to the bowel, and it is only necessary to remove 8 or 10 cm. (3 or 4 inches) of bowel on either side of the growth together with the attached wedge of mesocolon.

For *cancer near the splenic flexure*, the left colic artery should be exposed as it leaves the inferior mesenteric vein and tied with its vein. The bowel supplied by these vessels must then be excised. This usually means the last third of the transverse colon and the upper half of the descending colon (Fig. 1241).

For *cancer of the descending colon*, the left colic artery must be tied at the point where it leaves the inferior mesenteric vein and also the upper sigmoid artery near its origin. The bowel to be removed is the left third of the

transverse colon, the descending colon, and the upper part of the sigmoid flexure (Fig. 1242).

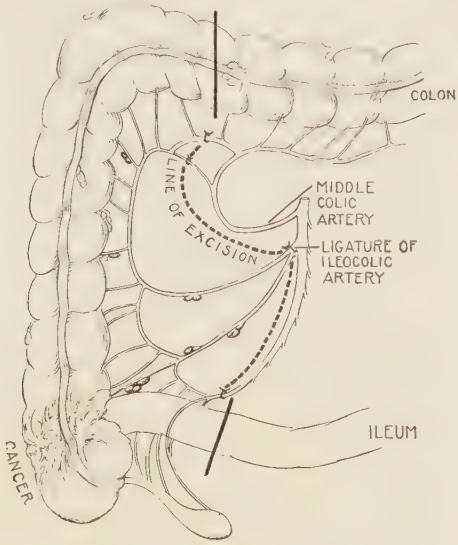

FIG. 1239.—CANCER OF CECUM.
Showing extent of bowel and mesentery to be removed.

For *cancer of the lower part of the sigmoid* and *upper part of the rectum*, the glands which require removal lie along the inferior mesenteric artery

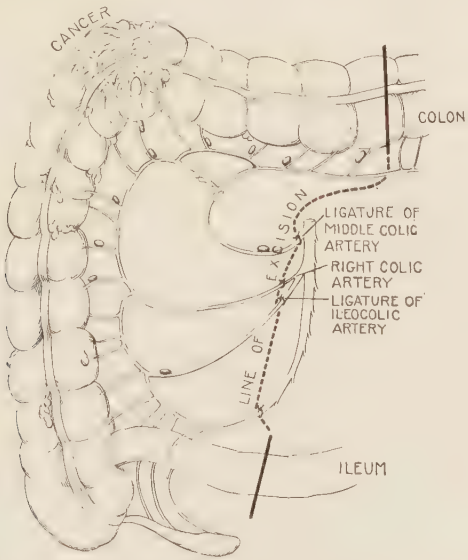

FIG. 1240.—CANCER OF HEPATIC FLEXURE OF COLON.
Showing extent of bowel and mesentery to be removed.

and the superior hemorrhoidal artery from the origin of the left colic downward. The operation consists in exposing the inferior mesenteric artery

and tying it and the vein just below the place of origin of the left colic artery. The mesosigmoid is then divided downward from the point of ligation to the middle of the sigmoid flexure. The secondary arches of the sigmoid artery should not be damaged. The peritoneum is then divided along the inner side of the artery to the inner side of the mesorectum. The lymphatic and mesocolic tissue is then stripped forward from the hollow of the sacrum and the middle sacral artery is tied. The peritoneal reflection between the bladder and rectum is then divided (Fig. 1243) (see Cancer of Rectum, Vol. III).

For *cancer of the middle* and *upper part of the sigmoid*, the same procedure as described above is followed. A larger amount of mesocolon is removed. The bowel is divided above at the end of the descending colon, and below it should be divided about 15 cm. (6 inches) beyond the growth (Fig. 1244).

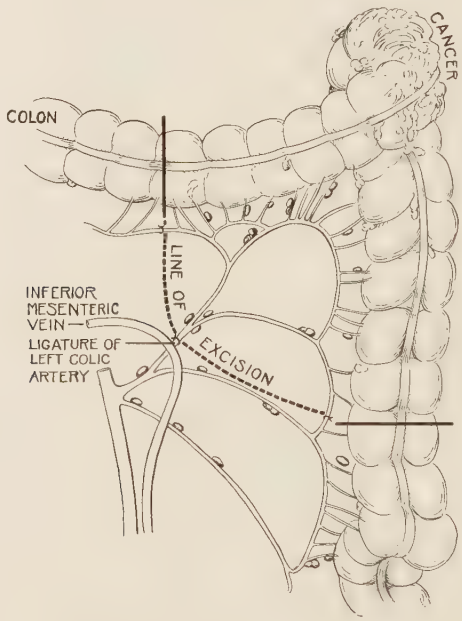

Fig. 1241.—Cancer of Splenic Flexure of Colon.
Showing extent of colon and mesocolon to be removed.

If the surgeon would take into account the lymphatics and eliminate every possibility of recurrence, the operation must be carried out in compliance with these requirements. This is not possible in some cases, and not necessary in others.

Remarks on Cancer of the Colon.—Before operating everything should have been done to put the patient in the best possible state of physical resistance. A laxative should not be given within twenty-four hours of the operation; if one is required it is best that it should be administered not nearer than forty-eight hours to the operation. The reason for this is that if resection is done, it is better performed in the presence of a dry intestine with solid contents than in the presence of watery feces.

A free incision should be made so that a thorough exploration may be conducted. The liver should be examined. Enlarged lymphatics do not

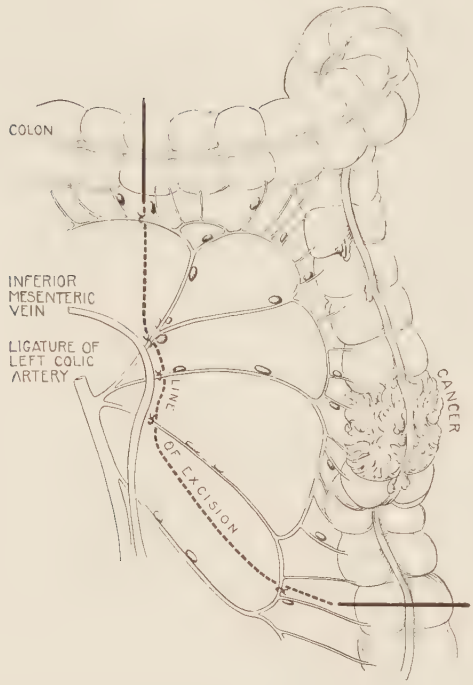

FIG. 1242.—CANCER OF DESCENDING COLON.
Showing extent of colon and mesocolon to be removed.

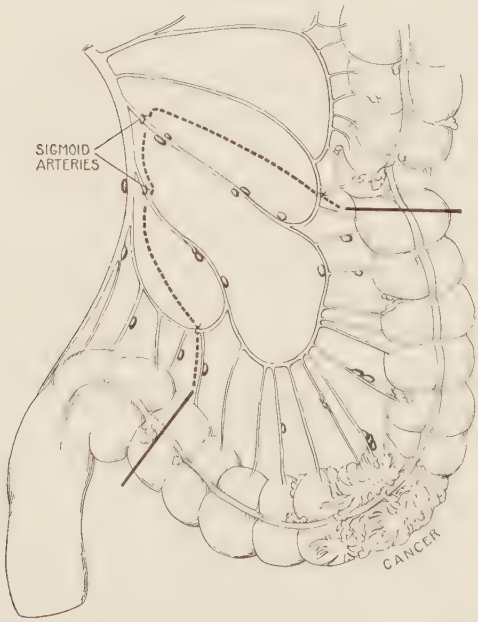

FIG. 1243.—CANCER OF MIDDLE OF SIGMOID FLEXURE.
Showing extent of bowel and mesocolon to be removed.

necessarily mean cancer. Masses of enlarged glands may sometimes be removed and found entirely free from cancer.

If the cancer is adherent posteriorly it may be necessary to remove the ureter or the kidney also. Extension of the growth to the abdominal wall calls for resection of as much of the latter as is necessary.

In some cases one or more loops of small intestine may be adherent and involved in the growth. There resection and end-to-end or lateral anastomosis is not difficult; the same of involvement of the ovaries, tubes or uterus.

The growth will sometimes be found attached to the bladder. Resection of this viscus should be done without hesitation. The organ may be sutured and a good result hoped for.

Operation in one stage, with resection of the cancer and anastomosis of the bowel, is rarely justifiable in cases which have even moderate obstruction.

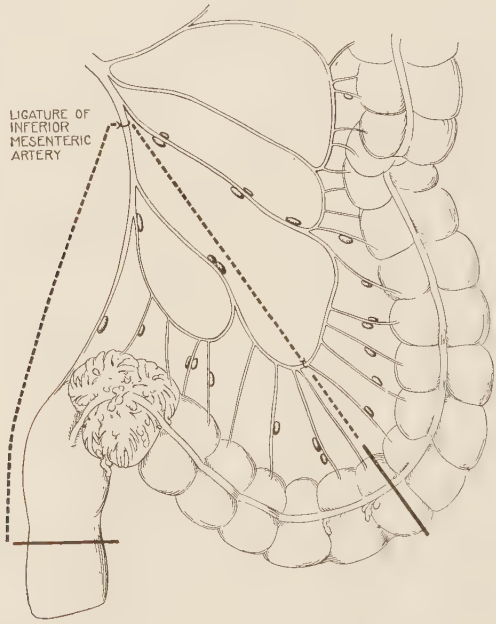

Fig. 1244.—Cancer of Sigmoid and Rectum.
Showing extent of bowel and mesocolon to be removed.

The vitality of the bowel is damaged, and sutures may not hold. This is the condition in the majority of cases; and the surgeon should not be tempted to do a completed operation. It is much wiser to do cecostomy if the obstruction is urgent. If the obstruction is not a pressing factor, the operation in which the diseased loop is fastened outside of the body, and later resected, is by all means the safest operation. This operation is especially applicable to the second half of the colon. Colostomy just above the disease, which may be resected with the tumor at a later operation, is to be considered for some cases.

If the surgeon plans a wide resection with removal of mesocolon and vessels, an end-to-end anastomosis may be made or the bowel ends may be sewed in the abdominal wall. In the latter case the upper opening serves as an artificial anus and the lower for irrigation of the distal bowel. The wide resection, with the view of removing the lymphatics, is the ideal opera-

tion, and should be done if the condition of the patient will permit and the hopefulness of the case seems to warrant. It is often wise to proceed with this extensive resection after a simple loop operation has been done, the tumor removed, and the patient brought to a good state of resistance.

In resections of the sigmoid or descending colon, a good-sized rubber tube with several openings at the upper end may be passed through the anus and up above the anastomosis, and contribute materially to lessening the strain on the sutures, as advised by D. C. Balfour.

Intestinal Obstruction.—**Acute intestinal obstruction** demands not only judgment and technical skill but also experience for its best treatment. Time must not be lost. Operation should not be reserved as a last resort. It is the conservative treatment, and should be applied at once. The mortality increases with each hour that operation is deferred. Mistakes of diagnosis are not so serious as delay of operation. The conditions which may be mistaken for acute obstruction are also conditions requiring operative treatment.

If the patient is suffering intensely from prostrating pain, and the condition is recognized as one of acute obstruction, a single injection of morphin should be given. But it should be understood that this is a preliminary to operation; and the relief that follows it should not benumb into inactivity the surgeon also. Morphin should not be given repeatedly nor should it be ordered excepting by the surgeon who has determined that operation should at once be done. This does not refer to diaphragmatic pleurisy or to renal calculus, but to acute intestinal obstruction.

Measures for meeting and preventing further shock should go on with the preparation for the operation (see Shock, Vol. I, page 213; Prevention of Shock, page 574). The stomach should be washed out, the lavage continuing until the fluid returns clear. Unless this is done, vomitus flows forth as soon as the anesthetic is begun, gushing from mouth and nostrils, and more or less finds its way into the larynx. These patients are actually often drowned in their own vomit.

The least amount of anesthetic possible should be given. Many of these patients are so low that local anesthesia only should be used. Time should not be wasted upon predetermining just the character of the lesion. The main fact in the diagnosis is obstruction. Unless some other region such as the colon is strongly pointed to, the abdomen should be opened in the middle line between the pubes and umbilicus. The incision should be large enough to admit the hand 7.5 or 10 cm. (3 or 4 inches) long. Distended bowel will be found pressed against the anterior abdominal wall, and care must be taken lest it be injured in cutting through the peritoneum.

The index- and middle fingers introduced in the abdomen usually suffice to find the obstruction. If it is not come upon at once, the cecum is sought. If it is distended, the obstruction is in the large intestine; if it is collapsed the obstruction is in the small intestine. In the first event, the fingers then follow along the course of the distended colon until the obstruction is reached. In the event of the disease being in the small bowel, there are certain places most prone to harbor obstruction. Moynihan called attention to the tendency of the blocked coil of intestine to sink into the pelvis. Search should be made there. Then the sites of hernia should be explored, especially the groins and umbilicus. All of this exploration takes but a minute, and may usually be done with two or three fingers.

If the obstruction is not found in this way, a visual inspection should be made. Warm cloths, already at hand should be spread on either side of the wound, and the distended bowels allowed to escape from the abdomen and

be enveloped by the towels. The surgeon should seek below, not above, as the intestines are rolled out. As soon as the obstruction is come upon, the rest of the intestines should be returned to the abdomen; and the operation for its relief performed.

In acute intestinal obstruction the fatal conditions reside in the distended bowel, its contractile forces inhibited, its contents intensely septic and thrown back constantly into the more healthy bowel, its nerves and other structures traumatized by tension, and a transudative peritoneal irritation developing. The greatest urgency is to meet these conditions rather than to relieve the obstruction. In cases not too far advanced, relieving the obstruction is all that is required. But in an unfortunately large percentage of cases, so much time has elapsed between the incidence of obstruction and the operation

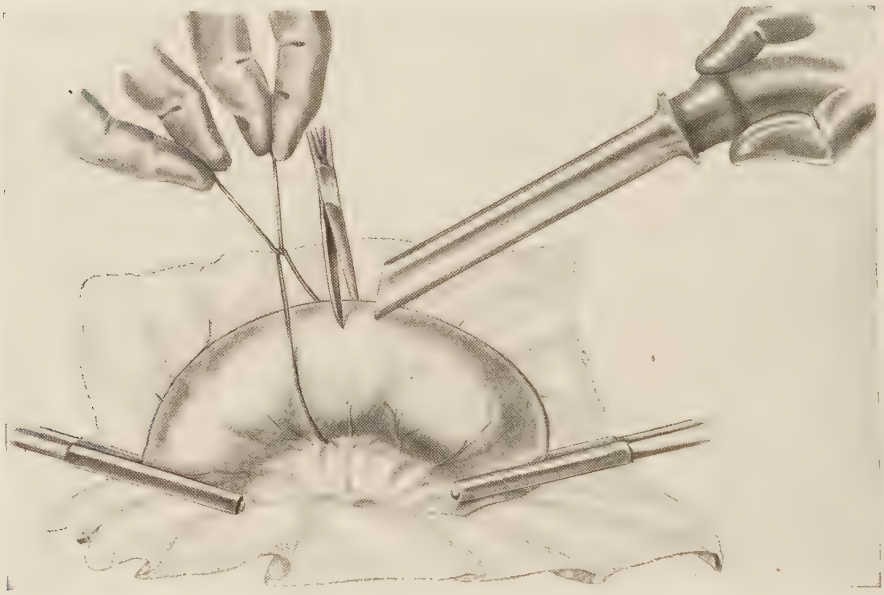

Fig. 1245.—Preparation for Emptying Bowel in Acute Intestinal Obstruction. The distended loop has been brought out of the abdomen, a rubber ligature has been passed through the mesentery, the intestine is about to be opened, and the glass tube inserted.

for its relief, that conditions have developed which require something more than removal of the obstruction. At least one thing is certain: acute intestinal obstruction in the large intestine should not always be treated by immediate resection and anastomosis.

Only in the mild cases with little distention and with little depression of vitality can the surgeon simply relieve the obstruction and do nothing more. This policy may be pursued in the cases which are seen early.

In cases which have been delayed, in which there are serious distention, toxemia, and shock, the distended bowel must be emptied of its putrid contents. It should be drawn out of the abdomen and the rest of the intestine carefully protected. A thin elastic ligature is passed through the mesentery of the distended bowel, and the bowel grasped by forceps and opened by a transverse incision about 1.3 cm. (½ inch) in length just below the ligature above the obstruction (Fig. 1245). Into this opening a glass tube of a similar diameter

is quickly passed before leakage of fluid matter has taken place. This glass tube should fit tightly into the opening and pass upward. The ligature is then caught with a clamp and leakage prevented. The tube should be connected with a rubber tube to conduct the intestinal contents into a receptacle on the floor (Fig. 1246).

If the obstruction has been relieved without injury to the bowel, the opening may be made in the sound gut below the place of obstruction. If an opening of the bowel has been necessary to relieve the obstruction, the tube may be introduced and the bowel emptied through the wound of operation. The distended bowel above the block may be made to empty itself by gentle pressure. After emptying the intestine of gas and fecal matter, the next step in the operation should consist in removal of the obstruction. The wound in the bowel should be closed by a double row of sutures after

Fig. 1246. Emptying Bowel in Acute Intestinal Obstruction.
The tube has been passed into the bowel, the ligature has been tightened and caught with a clamp to prevent leakage, and the bowel has been moved along over the tube.

the tube is withdrawn, and the loop washed, dried, and returned to the abdomen. The whole operation should be carried out rapidly. Drainage in most cases is not necessary (see Rupture of Intestine, page 566).

In more desperate cases the procedure must differ somewhat from the above. Patients in an advanced state of shock and toxemia can have but one thing done, and that is relief of the distended bowel above the obstruction. The stomach should be washed out. If the depression from this is feared, the back of the throat may be touched with cocain solution. The treatment of shock should precede or accompany the operation. Intravenous infusion and adrenalin are of much service. The skin should be made warm.

Under local anesthesia the abdomen should be opened rapidly by a small incision. A distended coil of intestine presents itself in the wound. If the distention is great and the bowel congested the surgeon may know that it is a part of the gut which is suffering above the obstruction. The coil which

presses anteriorly is usually the most distended and is not far above the obstruction. This distended coil which pressed forward should be sewed to the edges of the parietal peritoneum, leaving an ellipse of the intestine in the wound. The suture should be a continuous suture of silk, and made tight enough to prevent leakage before adhesions have formed. As the bowel is thinned by distention, care must be taken not to penetrate the mucous membrane. A thin curved needle should be used. In the center of the ellipse a purse-string suture should be applied, making a circle about 1.5 cm. (⅝ inch) in diameter. An incision into the bowel should be made inside of this circle, and a tube of glass or rubber about 1.3 cm. (½ inch) in diameter introduced through the opening, and the purse-string tied down upon it. A tube should carry the discharge from the intestine into a receptacle. Care should be taken that the tube does not tear out the sutures.

After this operation the condition of the patient may improve. With a fecal fistula in the small intestine, improvement may not continue long. If the obstruction still exists, inanition soon supervenes. Or life may only have been prolonged while a gangrenous loop of strangulated bowel goes on and produces fatal peritonitis.

If fecal matter cannot be recovered at the rectum, it may be judged that obstruction still exists. If peritonitis does not cause death and the bowel remains blocked, a curative operation must be attempted. There are two ways of going about this: (1) The intestinal fecal fistula may be tightly sutured as a temporary procedure, the outside of the wound cleaned, the gut dissected free from its attachment to the abdominal wall, wrapped in cloth, and the obstruction lower down attacked. This may mean resection, or making a fecal fistula, or intestinal anastomosis. The original temporarily closed fistula may then be reëstablished, or the temporary closure may be converted into a permanent closure. Whatever is done with this first intestinal wound, it should be left in close contact with the median abdominal wound or reached by a drain because of the danger of infection in connection with it. (2) Or the skin may be cleansed, a gauze plug placed in the fecal fistula and another opening made in the abdominal wall, through which the obstruction may receive treatment. The second operation in these cases requires more skill and judgment than the first. Many of these patients succumb before a second operation can be done. Many of the desperate cases which recover had not been suffering from actual mechanical obstruction, but from peritonitis or some other curable condition.

Cases in which the obstruction has disappeared offer less of a problem. Here the intestinal fistula may close spontaneously. If it does not, it is easily closed by operation (see Intestinal Fistula, page 616).

The after-treatment should be similar to that of peritonitis. The stomach should be washed out freely. Food should not be given at first by mouth. Saline solution should be given by rectum. Nutrient enemata are indicated. It should be borne in mind that the bowel below an artificial anus collapses and degenerates; adhesions often form; and it becomes difficult to reëstablish its function. For this reason, it should be compelled to exercise by injecting fluids into it from above or below; and reëstablishment of the natural fecal current should be brought about at as early a time as possible. In the treatment of palsied bowels, strychnia, electricity and similar measures are of little service.

Acute obstruction of the colon when due to a cause, such as cancer, which cannot be removed at once, or which it is not advisable to remove at once, may be treated by anastomosis of the cecum to the rectum. This operation may be easily and quickly done with a button without suture. The

small intestine, cecum, colon or sigmoid may be used. The convenient segment above the obstruction is evacuated by a trocar puncture surrounded by a purse-string. After the bowel has been emptied, the upper half of a large colonic button is substituted for the tube and held by the purse-string suture, the lower half of the button is then passed up through the rectum by means of forceps (J. S. McArdle had special forceps made for this purpose). The button is pressed against the upper rectal wall, which is incised from the peritoneal side enough to allow the stem of the button to squeeze through the opening. Then without further suture the two halves are pressed together and the anastomosis completed. A still safer procedure consists in drawing out a loop of bowel above the obstruction and rapidly making an artificial anus.

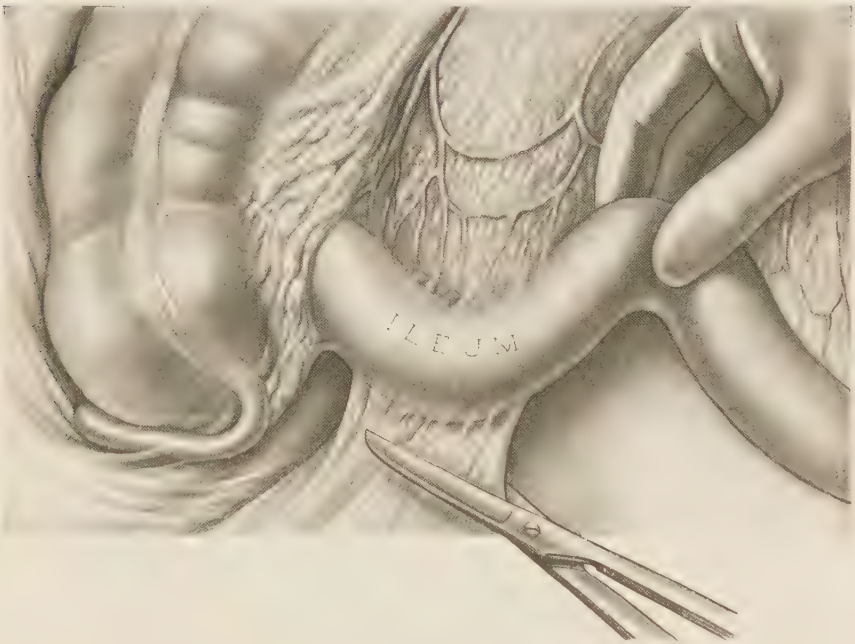

Fig. 1247.—Adhesions Causing Mild Obstruction Cured by Division of the Adhesions.

Special Forms of Intestinal Obstruction.—Intestinal obstructions due to the paralysis of peritonitis and to tumor have been discussed. Hernia is discussed in a separate chapter (Vol. III, page 17). Whatever may be the cause of obstruction the first consideration should not be its removal, but to do the thing necessary to save the patient's life; the treatment of the causative condition may then follow in due time.

Strangulation by bands should be treated by dividing the band. This may be a fibrous cord, formed by stretched-out adhesions, which is friable and requires no ligature, or it may be some vascular structure such as a tab of omentum or tip of Fallopian tube, and require to be ligated on either side. It often happens that the examining finger breaks the band and relieves the obstruction. The bowel which is angulated across the band, may have sustained so much damage at the line of pressure, that when the constriction is relieved and intestinal contents dilate this injured place, rupture of the gut

may occur. This should be guarded against by compressing the bowel above the stricture to control its contents while the degree of injury is determined. A narrow line of weakness may be reinforced by a transverse suture of the outer coats over the damaged strip. When a band is divided it should be cut away entirely at both extremities, as the free ends will form other attachments and may again cause trouble.

Obstruction from adhesions may be the sort which occurs as a result of peritonitis matting together coils of bowel and inhibiting peristalsis. It may be necessary in these cases to resect the adherent mass or to exclude it by anastomosis above and below, as is done for tuberculosis of the intestines

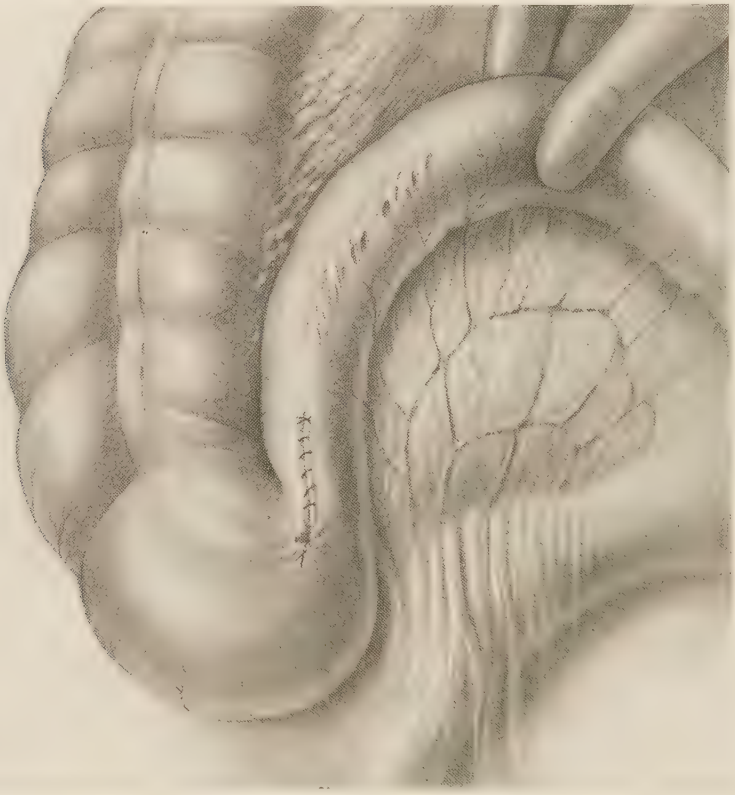

Fig. 1248.—Result after Dividing Adhesions and Removing Appendix.

(page 574). In some cases the adhesions may be divided and the bowels placed in corrected position by being caught here and there with a suture. Or the simple treatment of adhesions may suffice (see Adhesions, page 520). After dividing adhesions, the raw surface left should be covered by suturing the peritoneum over it.

The offending adhesions may have caused *angulation* either by traction, pressure, or adhesion, involving only a small area (Figs. 1247 and 1248). The adhesions should be divided. Both mild and complete obstruction may be remedied by this simple operation (Fig. 1249). After division of the adhesions a compressing pad held on the outside of the abdomen may be applied so as to prevent the bowel falling back into its old position. Such a pad may

FIG. 1249.—PRONOUNCED ANGULATION, CAUSING OBSTRUCTION.

This condition is to be remedied by division of the angulating bands. It is obvious that the treatment of such angulation as this is division of the adhesions in the lines indicated, to be followed by straightening out of the kinks. Removal of the appendix is also called for.

FIG. 1250.—PERICOLIC ADHESIONS, WHICH MAY BE CURED BY DIVISION, REMOVAL AND COVERING RAW SURFACES.

be adjusted immediately after the operation. If the gut does not fall into better position, its position may be corrected by a few sutures converting a concavity into a convexity by sewing it to some neighboring peritoneal surface. An angulation which is intractable must be treated by making a longitudinal incision on its concave side, the middle of the incision being at the apex of the angle, and closing the wound as an enteroanastomosis, producing a transverse wound.

Pericolic adhesions (membranous pericolitis, pericolic veils) have been best described by J. N. Jackson, W. A. Lane, and L. S. Pilcher (Annals of Surg., vol. 55, 1912). Usually in treating the thin veil of adhesions found about the

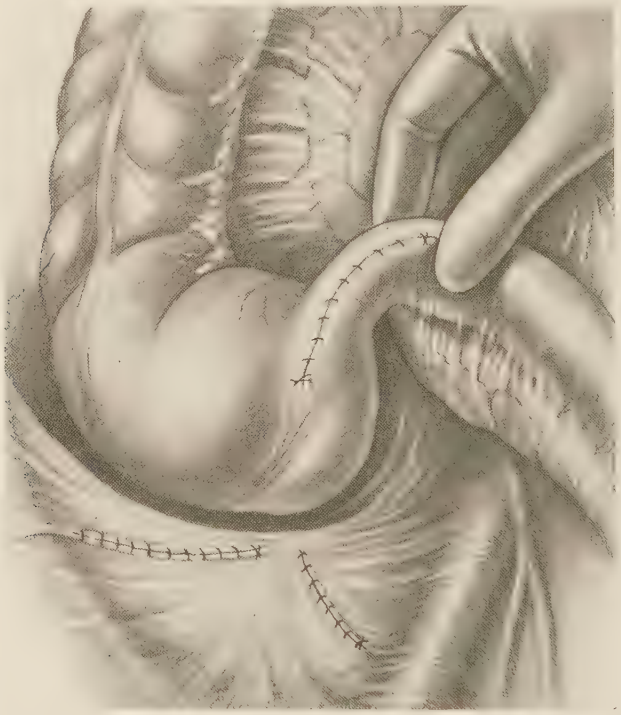

Fig. 1251.—Pericolic Adhesions Removed and Bowel Liberated.
The adhesions have been divided and removed. The raw surfaces have been sewed over and the appendix amputated.

ileocecal angle, removal of the chronically inflamed vermiform appendix is also required. This region is best approached by an incision through the outer part of the sheath of the right rectus muscle. All of the hands and sheets of adhesions which confine the free motion of the bowel should be cut. The raw surfaces remaining should be covered by sewing the peritoneum over them (Figs. 1250 and 1251). Adhesions of other regions are amenable to the same treatment. In the sigmoid region the adhesions may cause fixation of the sigmoid and give rise to obstinate constipation, which is relieved only by dividing the adhesions and restoring the mobility of the bowel (Figs. 1252 and 1253) (see Peritoneal Adhesions, page 520; and Chronic Intestinal Stasis, page 610).

Ileocecal valve obstruction is not uncommonly seen as an abnormal tight-

ness of the valve, giving rise to dilatation of the ileum, ileal stasis, and often symptoms similar to appendicitis. Many of these cases have been operated upon for appendicitis, and the appendix found to be normal. The treatment is highly satisfactory. An incision should be made 5 to 7 cm. (2 to 2¾ inches) long in the direction of the long axis of the ileum. Its middle should be at the ileocecal valve. It should involve the whole thickness of the bowel wall. The two ends of the incision should then be brought together, and the wound closed at right angles to the incision which made it. This operation enlarges the orifice and cures the disease.

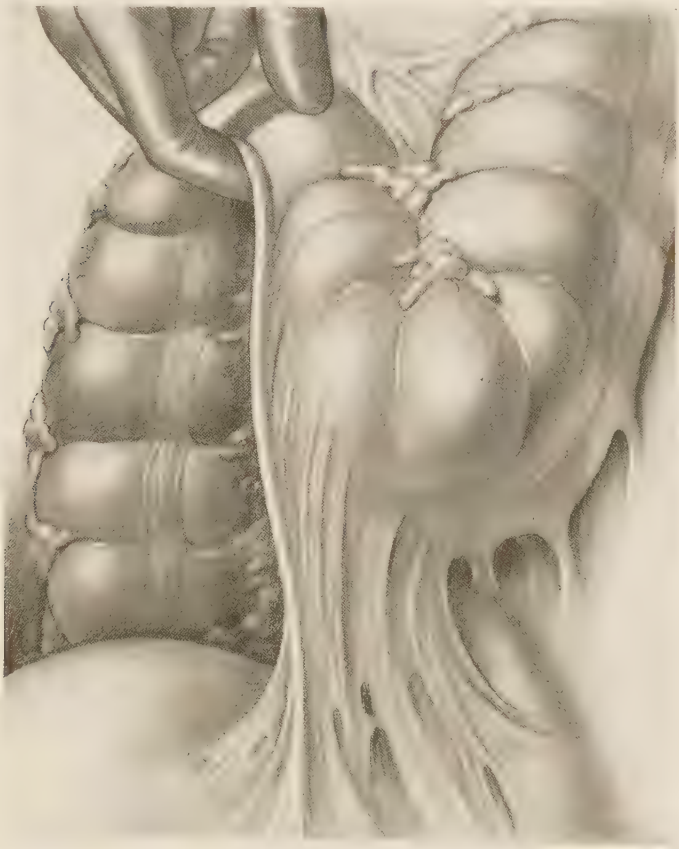

Fig. 1252.—Sigmoid Adhesions, Causing Constipation, Which can be Cured only by Division of the Adhesions.

Diverticula cause obstruction in several ways. (1) The extremity of the diverticulum may have become attached at the umbilicus or have become adherent in any part of the peritoneum, forming a *band* under which bowel becomes strangulated. The diverticulum may be so large that confusion is caused by mistaking it for intestine. The extremity should be freed from its attachment and the diverticulum amputated after the manner of removing the vermiform appendix. It is ligated at its base a short distance from the bowel, cut off, the mucous membrane distal to the ligature sterilized by cauterization, and the stump buried by a seromuscular suture of the intestinal wall. Usually this should make a transverse line. In the case of a small

diverticulum, a purse-string suture may be used. The treatment of the obstructed bowel is the same as that for strangulation by bands. (1) The diverticulum, as a floating cord, may form a loop or knot about the intestine, or it may cause rotation of the loop to which it is attached. In any of these events, it should be removed. (2) Becoming inverted into the lumen of the bowel, it may produce obstruction by causing intussusception. Its treatment here also is by removal. (3) Inflammation in the interior of a diverticulum may cause peritonitis, adhesions, or any of the obstructing lesions similar to appendicitis. Its treatment is the same as that of appendicitis.

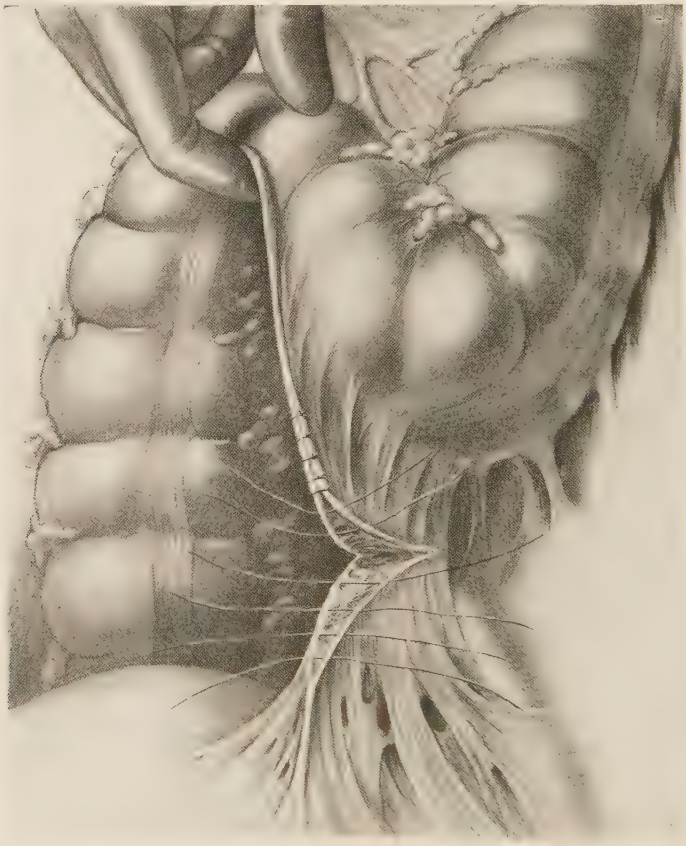

Fig. 1253.—Liberation of Sigmoid by Division of Adhesions and Closure of Wound. Operation in progress.

The removal of a small diverticulum is the same as the appendix. The removal of the ordinary sized diverticulum should be by amputation near the base and closure of the opening the same as a wound of the intestine. The wound should be sutured preferably transversely, with two layers of suture.

Intussusception usually occurs in infants. Early diagnosis is the most important prerequisite to treatment. Treatment must promptly follow upon the appearance of certain characteristic phenomena. The onset is sudden. A previously well baby screams, turns pale, and vomits. The

abdomen is tender. The first pain subsides, and is then followed at intervals by waves of colic in which the child cries with pain. A normal movement often follows the first attack of pain. During the first nine hours after this, blood will usually be passed by rectum. The child does not seem ill except from pain. A mass can be made out under general anesthesia.

In *reducible intussusception* a cure should be expected. If the case is seen during the first few hours reduction may be accomplished by the injection of fluid into the bowel. The pelvis is elevated and warm sterilized saline solution is permitted to flow into the rectum. Five hundred or 1000 c.c. (1 or 2 pints) may be used. The child may be inverted to facilitate retention of the fluid and reversed peristalsis. After four hours, or before this if blood has appeared, swelling and adhesions have developed which make reduction by this method both improbable and dangerous.

In all cases the child should be protected against shock (Vol. I, page 213), and in all cases the abdomen should be opened. This should be done also when injections are supposed to have reduced the invagination, because of (1) the possibility of reduction not having been accomplished, and because of (2) the possibility of injury to the intestine which may require further treatment. An exception to this rule may be made in the case which is seen very early, in which a mass is distinctly felt to disappear under general anesthesia and colonic injections, and in which the child seems well after this. Even in these cases the reduction may have been only partial, reducing the invagination in size but not in fact. Abdominal section in a cured case does no harm; in an uncured case it may save life.

Having opened the abdomen at the side of the rectus if the mass is felt there, or in the middle line, by a 5-cm. (2-inch) incision, reduction may be accomplished by gentle manipulation. After an intussusception has existed for forty-eight hours, reduction is difficult; after it has existed for three days, reduction is difficult or impossible. Reduction by operation is possible in the majority of cases up to the fourth day. Reduction should not be attempted in late cases by traction alone. The lower limit of the intussusceptum should be sought, the gut grasped between the thumb and forefinger, and the apex of the invaginated portion gently pressed upward. This manipulation also pulls downward the outer bowel. The apex of the intussusceptum is usually edematous, and when it reaches the place of entrance its further reduction may be impossible. The edema may be reduced by gentle and steady pressure, embracing, if necessary, the whole circumference of the gut in the hand. Having completed the reduction, the bowel should be inspected for wounds, any of which should be sutured. The cause of the intussusception should be sought. If a diverticulum, polyp or tumor is discovered, it should be removed. Shock will be minimized if all manipulations are conducted within the abdomen.

If the colon involved has undue mobility, it should be fixed to the lateral and posterior abdominal wall by a few sutures, and the invaginated small intestine should be similarly fixed. If the mesentery of the intussusceptum is unduly long it should be shortened by peritoneal sutures. Time should not be taken for this if the child's condition is bad.

In *irreducible intussusception*, the conditions are more serious. The bowel below may be injected with fluid as an aid to the operation and as a preventive of shock. In adults immediate resection is the operation of choice. In children resection gives a high mortality.

If the invagination is *irreducible but not gangrenous*, the procedure should depend upon the general condition of the patient. If urgency is demanded, an intestinal fistula should be made. In the event of a small invagination,

it may be brought outside of the abdomen, fixed in the wound, and the bowel opened at once and drained, as for malignant tumors (see Intestinal Obstruction, page 595; Malignant Tumors, page 582). For this, intussusception

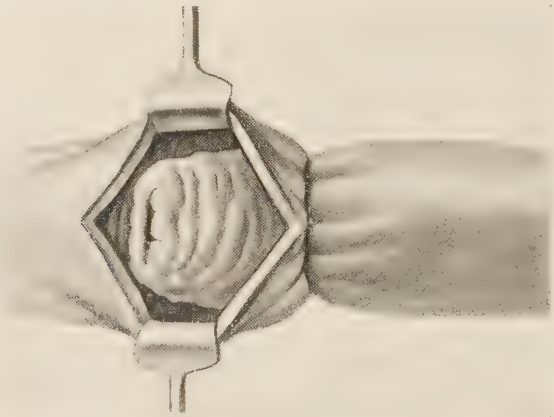

Fig. 1254.—Operation for Intussusception.
The intestine is opened to expose the intussuscepted segment.

may be incised or resected. In the less urgent cases resection and anastomosis is indicated in adults; in children, an intestinal fistula may be made, either with or without immediate resection.

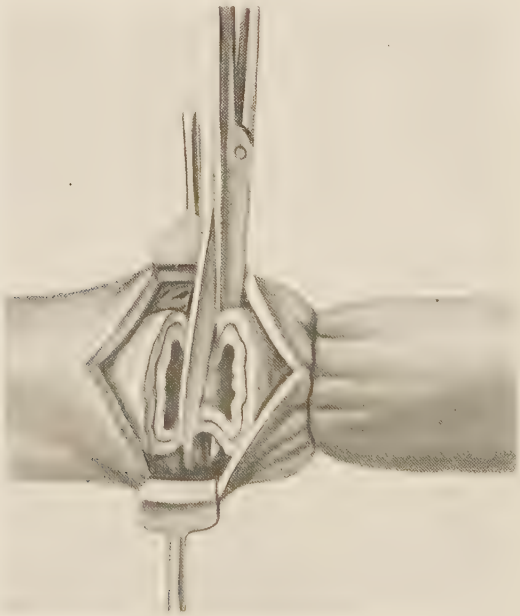

Fig. 1255.—Amputation of the Intussuscepted Segment.

It is possible in some cases in children to bring the disease out through the wound, and suture the bowel to the peritoneum above and below the tumor.

This is the method of *eventration*. The bowel is placed in such a position that its parts farthest from the mesentery lie in contact. A purse-string suture is placed on the upper limb, the bowel incised in the circle, a tube introduced and the suture tied down upon it (see pages 596 and 597). This empties the bowel and fixes it for the formation of adhesions. One or two days later, the intussusception is resected and a clamp introduced to cause sloughing through of the spur (see Fecal Fistula, page 587).

In some cases it is possible to make a longitudinal incision through the intussuscipiens at the place of invagination, and thus relieve the stricture which prevents reduction.

In the cases in which a great length of gut is invaginated, resection is still more urgently demanded.

If the intussusception is *irreducible* and *gangrenous*, it is best treated by the above method of *eventration*. In adults the mass may be excised and the bowel united end-to-end or laterally. Resection and the formation of an intestinal fistula may be done.

In some cases *resection of the intussusceptum* may be done by the method similar to that of Maunsell for intestinal anastomosis. The operation was

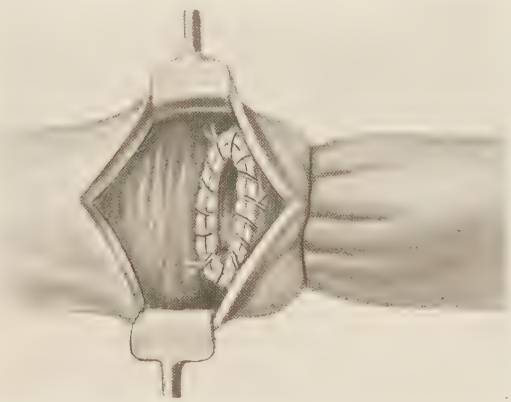

Fig. 1256.—Stump of Amputated Intussusceptum Sutured.

first applied by Jessett to intussusception. A continuous seromuscular suture is caused to unite the bowel at the line where the intussusceptum enters the intussuscipiens. A longitudinal incision about 5 cm. (2 inches) long is then made through the invaginating part opposite the mesentery (Fig. 1254). This exposes the invaginated bowel. The incision is carried to within 1.3 cm. (½ inch) of the circular suture. The invaginated bowel is then amputated (Fig. 1255), leaving a proximal stump. This stump represents two coats of bowel. These are sewed together by a continuous suture (Fig. 1256). The wound is then closed by suture (Fig. 1257). When done for gangrene, at least all of the gangrenous bowel should be removed. This method is becoming more and more employed for nongangrenous irreducible cases, and is to be recommended.

In infants the mortality following resection is very high; but it is possible that if resection is done at once, and time and traumatism not bestowed upon the lesion, better results may be secured.

C. P. B. Clubbe reported 173 cases of intussusception under his care. In 16, reduction was accomplished by injections. Laparotomy was done in

157 cases. He had 25 deaths in the first 50 cases operated on, 12 deaths in the second 50, and 4 deaths in the third 50. In his last 7 cases, which were operated upon, there were no deaths. The reason for the better results in the latter cases is that the patients were operated upon earlier. He insists that all cases should be treated by operation.

Volvulus may be alone or associated with adhesions or angulation. Here distinct volvulus will be discussed. It is commonly found in the sigmoid flexure, but other parts may be involved. An anatomic peculiarity usually is a determining cause, and if the volvulus is simply untwisted the tendency to recur is greater than it was before. The volvulus having been discovered, it should be untwisted if this can be done without damage to the gut. In some cases the distention of the gut may be so great that manipulations can not be made until it is brought outside of the abdomen. In extreme cases it becomes necessary to incise and empty the gut before anything else can be done.

After untwisting a volvulus and permitting the obstructed intestinal contents to pass onward, it may seem as though the loop would remain in good position; but this hope should not be entertained, because when it again



Fig. 1257.—Wounds Closed after Operation for Intussusception.

becomes distended or the same conditions are present which produced the first volvulus, recurrence is to be expected. In order to prevent this, the offending loop should be fixed by sutures. If there is an abnormally long mesentery it may be shortened by making a fold parallel to the gut; the sutures should not catch the blood-vessels. Such a fold need not damage the circulation of the bowel. If this is not necessary, the bowel may be prevented from rotating by suturing it to the posterior, lateral or anterior abdominal wall. In *ptosis of the sigmoid*, it may be fastened to the peritoneum of the pelvic brim by sutures catching its mesentery close to the bowel. In doing these operations the bowel should be placed in a natural position, so that no strain shall fall upon the sutures or danger of angulation be incurred.

Foreign bodies causing intestinal obstruction may have been swallowed or formed in the body. Usually such a body which can traverse the gullet can traverse the rest of the gastro-intestinal canal. But a slight narrowing, the result of old ulcer or adhesions, may stop it, and obstruction supervene. The ileocecal valve is the narrowest part of the bowel, and here the body may become engaged. A foreign body may by its irritation cause spasm of the bowel which grips the body and causes ileus.

The most common causes of foreign body obstruction are *gall-stones*. The occlusion is usually at or above the ileocecal valve. The circulation of the bowel is not damaged by this form of obstruction. Operative mortality

should be very low. It is high because in some of these cases after obstruction was apparently established, the body has been passed, and the patient has recovered; the hope that this may occur prompts delay, and operation is sought as a last resort, often for a moribund patient.

The foreign body is located by the methods already described (page 595). If the bowel is not much damaged a longitudinal incision is made opposite the mesentery and the foreign body removed. The opening should be closed with two rows of sutures. If the body has been present long enough to produce ulceration or the bowel looks badly the body should be moved upward and removed through better intestine.

Intestinal obstruction due to impacted gall-stone in the intestine is especially serious because the retained fluid above the obstruction, if absorbed in large amount, is distinctly poisonous. If the gall-stone is removed and the obstructed fluid permitted to flow down into the lower bowel, whence it will be absorbed, serious consequences may follow. It is best to introduce a tube through the wall of the bowel at least 10 cm. above the obstruction and wash out with warm saline solution all of the septic fluid. Then the impacted stone may be pushed up to the opening in the bowel and removed with safety. By making this opening high enough to be in healthy bowel the danger is greatly reduced.

Stricture usually requires treatment for chronic obstruction. In some cases it may contract rapidly, or be associated with other conditions, and cause acute obstruction. The treatment should be conducted on the principles already laid down (page 595). A single stricture or a loop of intestine beset with strictures is radically cured by resection and anastomosis. Stricture causing partial closure of the lumen of the bowel may be treated by a longitudinal incision, crossing the stricture, and closure of the wound transversely (Figs. 997 and 998).

The dilating of intestinal strictures, which give symptoms of obstruction, is to be considered only if the stricture can be reached through the anus.

Gangrene of the Intestine.—This condition may follow traumatism, infection, strangulation, or thrombosis or embolism of the mesenteric vessels. Its treatment must often be combined with the treatment of other conditions. For limited areas of gangrene—up to 9 cm. (3½ inches)—*invagination* has been done with success. The bowel is invaginated, as in intussusception, and secured by a continuous suture.

If a greater length than 5 cm. (2 inches) is to be invaginated the mesentery may have to be removed. In *stoppage of the mesenteric vessels*, gangrene occurs independently and unexpectedly. A few centimeters or one or more meters of bowel may be found gangrenous. If the diseased segment is not soon removed from the abdomen, perforation of the slough and fatal peritonitis supervene. In all cases of gangrene, involving the whole circumference of the bowel, it is essential that the gangrenous tissue be removed from the abdomen. If the condition of the patient will permit, resection of the diseased segment and anastomosis may be done. In resecting for gangrene care should be taken that enough bowel is removed to insure good vitality in the remaining ends. The hazard in the removal of 5 cm. (2 inches) of gut is not materiallly less than that in the removal of 50 cm. (20 inches). It is always best to lean toward the safe side.

In cases in which the condition of the patient is bad, *eventration* may be done. The gangrenous loop is brought out through the abdominal wound, and sewed to the peritoneum above and below the lesion. The bowel may be emptied at once or later, as the degree of ileus demands (see Obstruction, page 595; Eventration, page 586). If perforation has already taken place,

the gangrenous segment should be cut away. A tube may be fixed in the upper limb to conduct intestinal contents away. Later an operation for fecal fistula should be done.

The mortality in spontaneous mesenteric gangrene is high. A few cases have been saved by resection and anastomosis. The best hope for all desperate cases of intestinal obstruction and palsy is the two-stage procedure—intestinal fistula and its cure.

Chronic Intestinal Obstruction.—Many of the conditions described as causing acute obstruction, are capable of causing chronic obstruction and should have been treated radically before the acute condition supervened.

Such conditions as *tumors, strictures, adhesions, angulation,* and abnormally *long mesentery,* should be remedied (see treatment of each of these conditions; for treatment of long mesentery, see Volvulus). Adhesions are often found about the cecum and appendix which need treatment. Tumors causing obstruction *to the portal system* may require removal. *Hemorrhoids, fissure,* or *anal ulcer* may require attention to relieve pain which prompts voluntary abstinence from stool. *Mucous colitis* may be treated by appendicostomy.

When *coprostasis* occurs, the accumulation of fecal matter in the bowel may be only relieved by mechanical measures. Warm soap enemas, given slowly and allowed to remain a long time help dissolve and bring down the masses. Abdominal massage may be added, but should never be used if painful. Hardened *impacted feces* should be removed from the rectum by means of the finger and a spoon. As the material is removed below more may come down. A volvulus or sagging of the sigmoid may hold a mass and require colotomy for its relief. Accumulations of hard feces at the cecum may refuse to move onward, and colotomy may be necessary.

The treatment of *dilatation of the colon* is largely medical. When these measures fail, as in congenital dilatation (Hirschsprung), operation is required. By anastomosing the lower end of the ileum with the large intestine below the disease, relief may be secured. Resection of the diseased bowel is also practised.

In the treatment of *acute flexures* or *angulations of the sigmoid* and *colon,* either palliative or radical measures may be employed. Relief may be given by inflation of the colon with air, and by passing long rectal bougies through the flexure by means of the sigmoidoscope and leaving them in place for fifteen minutes. These measures fail when the condition is due to firm adhesions or congenital malformation. Then operation should be done. The operation should straighten out the angulation and suture the bowel in such position that angulation cannot recur. Raw surfaces should be covered. In some cases operation by angulation is indicated (pages 568, 600).

Chronic intestinal stasis (chronic intestinal toxemia) is largely a medical problem, to be met by better hygiene and internal treatment. No case should be operated upon until these measures have been faithfully and intelligently applied; I am tempted to say that no case will be operated upon if they are. Perhaps no method of treatment has given better results than that employed by J. H. Kellogg at Battle Creek. This consists in a low proteid diet of bulky foods, consisting largely of whole grain products, fruits and fresh vegetables. Bran or agar-agar at each meal is desirable; from 15 to 30 Gm. (½ to 1 ounce) of cellulose daily in this form seems useful as a stimulant of peristalsis. At every meal 15 to 45 c.c. (½ to 1½ ounces) of liquid petrolatum is advised. This may be given plain, in emulsion, or the petroleum jelly may be used. In obstinate cases the patient should take 30 Gm. (1 ounce) of bran three or four times daily. Fresh fruit should be

eaten at the same time. Bran furnishes bulk and petrolatum supplies lubrication; these are prime essentials in most cases.

The abdominal muscles should be strengthened and the abdominal circulation improved by exercises. If these do not suffice, abdominal massage should be added. The vegetables which are of especial value are tomatoes, lettuce, celery and spinach. If hyperacidity is present the non-acid fruits are recommended: bananas, melons and pears. There is often advantage in making the diet exclusively for a few days of cooked and raw green vegetables and agar-agar or bran. Bran may be baked into cakes. A useful formula for the employment of agar consists in mixing 30 Gm. with 1 liter of water and the juice of a lemon. This should be kept hot and taken in small doses between meals during the day.

The patient should cultivate a regular habit of going to stool, preferably immediately after rising in the morning and after each meal. If satisfactory bowel action is not secured, an enema of warm water should be used once daily. This will rarely need to be continued with the above regimen. Kellogg advised in cases of colitis with spastic condition of the descending colon, warm saline enemas, after which 50 or 100 c.c. or more of liquid culture of *Bacillus bulgaricus* and *B. bifidus* is introduced into the colon with the patient in the knee-chest position. To this should be added a small amount of malt sugar and boiled starch as a culture medium.

If the lower colon is weak in peristaltic power it may be stimulated with electricity. A bipolar electrode is used in the upper part of the rectum. A solution of citric acid (0.25 to 0.5 per cent.) is useful; also a mixture of equal parts of carbon dioxid and pure oxygen gases. If the chronic proctitis has caused atrophy of the mucous membrane, 100 or 125 Gm. of petroleum jelly may be introduced into the lower colon at night.

The above measures will cure most cases. Kinks, ptosis, and "veils" are results of stasis. When the bowels are given the work which they are physiologically adapted to do, the symptoms may be expected to abate.

Treatment with autogenous vaccines of colon bacillus is of help in some cases. Stock vaccines are of little value. The beginning dose is from 10 to 25 million dead bacilli, injected subcutaneously. The dose is repeated every five or seven days, and gradually increased by 25 million at each injection until 150 or 300 million are given. If a colon bacillus toxemia is present, there will be a local reaction—redness, pain and swelling, at the point of injection, and a general reaction—malaise, headache and soreness. Relief follows after three to six weeks of treatment.

The conditions, described above, requiring operation, are the exceptional causes of this condition. These cases should come to the surgeon from the physician who has discovered the surgical character of the case by the failure of nonsurgical measures. As the disease concerns especially the neurotic and persons with visceroptosis, prolonged treatment is necessary before surgery should be considered. When these patients finally are sent to the surgeon, it is best that no operation be done which irretrievably destroys important bowel-function. Some of the radical operations which have been done for these conditions have been temporary fads which have not withstood the tests of time. Partial colectomy and even complete colectomy have never attained a position in surgery in the routine treatment of chronic stasis. The fad of short-circuiting should not mislead the surgeon; none of these operations have been placed upon a secure basis as measures to be applied with assurance.

If any operation can be of value it must meet some definite pathologic condition which the surgeon finds. The surgeon should bear in mind that the

colon has a function and should not be sacrificed as freely as a useless organ. If the surgeon can remove a chronically inflamed or adherent appendix, relieve abnormal intra-abdominal pressure, remedy some angulation or other condition which actually is causing obstruction, or secure some means for treating infection of the colonic mucous membrane, he is justified in operating, for he is applying rational measures to this disease. But he should beware of operating upon the bowels for lesions which reside in the nervous system or the glandular mechanism. Such surgery is not rational. Any condition which justifies opening the intestinal canal in this disease is rare.

Most of these cases which have passed through medical hands and been referred at last to the surgeon, will best be served by referring them again to

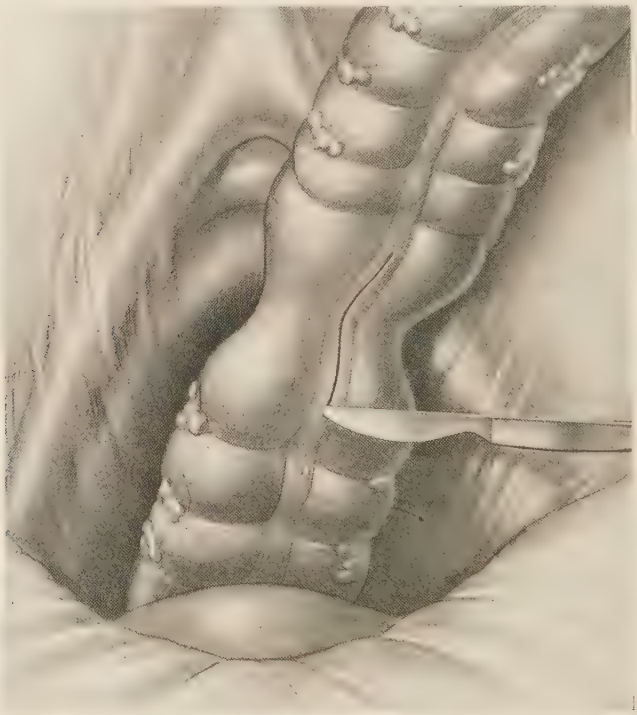

Fig. 1258.—Stricture of Colon, Causing Chronic Constipation, which can be Cured only by Operation.

Longitudinal colotomy at site of stricture.

more competent medical hands. The treatment requires special understanding. Many cases improve under hygienic treatment and the administration of vaccines, liquid albolene, petrolatum or paraffin oil.

Most surgeons have had experiences with cases with adhesions, angulations, abnormally elongated mesocolon, or enteroptosis in which removal of the upper half of the colon, or more, has been followed by improvement. The number of patients in whom this extirpation of cecum, ascending, and part of transverse colon will be justified for the treatment of chronic stasis, without any distinct obstruction being discernible, is exceedingly small.

Another condition in this category is the so-called *redundant sigmoid.* It is said to come within this definition if it is longer than 25 cm. (10 inches)

and "is the seat of symptoms of redundancy." Chronic constipation is the chief symptom calling for treament. If hygiene, massage, hydrotherapy, laxatives, restricted diet, and modified external pressure do not give relief, operation is indicated. Sigmoidopexy, ileosigmoidostomy, cecosigmoidostomy, sigmoidectomy, and colectomy are the measures resorted to. In this condition also the number of cases in which operation is indicated as the rational procedure is very small.

These operations have been advocated by some for *arthritis deformans* upon the ground that the disease is due to *Streptococcus viridans* the common habitat of which is the lower ileum. Ileosigmoidostomy seems to have improved a certain proportion of these cases. If there is any obstruction in the colon above the contemplated point of anastomosis, removal of the colon

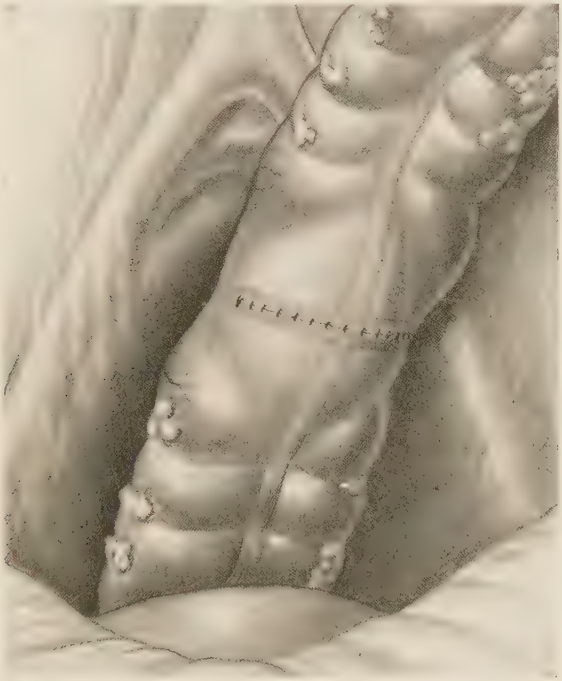

FIG. 1259.—CURE OF STRICTURE OF COLON.
Longitudinal incision of stricture and suture of wound transversely.

seems necessary. The object of the operation is to give better drainage to the lower ileum.

Upon the hypothesis of Metchnikoff, that the upper part of the large intestine is "the cesspool of the system," ileocolostomy has been advocated and practised by many surgeons and advocated as the "highway of hope" not only in obstinate constipation and arthritis, but in melancholia, arteriosclerosis, nephritis, and all of the ills to which the theory of *autointoxication* can be connected.

W. A. Lane claimed that in a large proportion of advanced cases, division of the adhesions gives relief only in so far as the patient is benefited by the rest in bed which the operation entails, and that as soon as the patient resumes active life the old symptoms return. When *x*-ray tests show a marked

degree of stasis in the colon in advanced chronic cases, treatment of the iliac kink or division of adhesions may be omitted, and instead an anastomosis between the ileum above the disease and the sigmoid below the disease may be done. Lane and his school divide the ileum and implant the proximal end into the sigmoid. If the large bowel is very static, and especially if the abdomen is relaxed, these surgeons remove the large bowel and report highly satisfactory results. If the removal of the bowel entails any great risk to the patient, the practice is to make a short-circuit, and do the resection later when the patient has been relieved of autointoxication and complains of the distention of the colon. Distention of the excluded colon may be expected to follow these operations unless it is kept clean by irrigation.

The operation of choice is (1) lateral ileosigmoidostomy, (2) sewing the opened cecum and the opened sigmoid into an abdominal wound, (3) irrigating the colon through-and-through until it atrophies. Later the atrophied colon may be removed, if desired, without hazard.

Incompetent ileocecal valve, when a cause of iliac stasis, has been successfully treated by J. H. Kellogg (Annals of Surg., Jan., 1918) by a simple operation. Sutures are passed in such a way as to invaginate the ileum into the cecum and thus form a valve. This is done by catching the wall of the bowel with one or more mattress sutures in such a way as to turn in about 3 cm. of the ileum. Kellogg carefully dissected free the peritoneum before applying the sutures. The patency and competency of the valve are tested by squeezing the intestinal gas along the bowel before tying the second knots in the sutures.

Megacolon (congenital or acquired dilatation of the colon) may be relieved by hygienic and medical treatment. It should not be treated by the surgeon until such measures have been well applied. The presence of coproliths may demand colotomy for their removal. Colopexy and coloplasty for this condition have proved to be of but little value. Coloplasty for enlarging the outlet of the dilated segment has not seemed of service. Coloplasty, by making longitudinal folds in the bowel, seems to have given relief in some cases. Colostomy, to make an artificial anus, gives relief, but is a poor substitute for the disease. Some surgeons have followed it with resection. Ileosigmoidostomy and colostomy have cured some cases; in others the dilated segment has become filled with fecal material, and resection has been necessary. The operation which gives the most certain results is resection. It may be done as a primary operation, or it may follow anastomosis, if the anastomosis operation fails to give relief.

Acute Intestinal Stasis.—This condition, usually due to acute obstruction or to peritonitis, requires treatment of the causative condition. When due to the traumatism of operation, or reduction of hernia, defective nerve supply, partial paralysis, gas distention, toxemia, etc., relief may be secured by means of laxatives and enemata. In some cases gas distention prevents the action of laxatives. Those drugs which act on the spinal cord and sympathetic centres may be used. *Hormonal* is given by intravenous injection in doses of 15 or 20 c.c. (4 or 5 drams). It may be given subcutaneously. *Eserin* (physostigmin) is also used hypodermically in doses of 0.0005 to 0.002 Gm. ($\frac{1}{120}$ to $\frac{1}{30}$ grain) for the same purpose. These drugs should not be expected to help in the paresis of acute peritonitis.

Another drug having a marked effect on the musculature of the bowel, and capable of causing contractions to overcome the temporary paralysis which follows the traumatism of operation, is *pituitrin* or *pituitary extract.* From 0.5 to 1 c.c. ($7\frac{1}{2}$ to 15 minims) of the extract may be hypodermically given every four hours after operation. The injection should be made into

muscle. Some surgeons use it as a routine during the first day after abdominal operations, with the result that the patients suffer less from gas pains.

There is a form of **duodenal occlusion,** which commonly occurs after abdominal operations but which may appear spontaneously, due to dragging downward of the mesentery of the small intestine and compression of the duodenum as it passes under it, the superior mesenteric artery acting as a band pressing upon the duodenum. This condition may be prevented by keeping the small intestine from falling into the pelvis, and by preventing adhesions. When it occurs, it is promptly relieved by washing out the dilated stomach and turning the patient so that he lies face downward. This is probably the condition which has to do with *postoperative dilatation of the stomach,* the postural treatment of which should be borne in mind. It may become necessary in this condition to open the abdomen, and release the root of the mesentery. B. Rosenthal (Archiv für Gyn., vol. 86, No. 1) suggests placing the patient in the knee-chest position and manipulating the intestine upward.

Acute dilatation of the stomach, occurring after operations, may be prevented by proper preparation of the patient for operation. The intestine should have been well cleansed of food and gas. Anesthesia should not be too profound. The stomach, bowel and splanchnic area should be traumatized but little. Exposure of the peritoneum to air, gauze sponging and other irritations which cause adhesions should be avoided as much as possible. After operation food should not be taken into the stomach for several days if there is ether nausea. The surgeon should daily palpate the epigastrium of abdominal cases to discover fulness. If it is present, the stomach tube should be passed at once. Nausea should call for lavage. Upon the first appearance of distention of the stomach with fluid or gas, of vomiting, or of nausea, the stomach should be emptied and washed until the fluid returns clear.

If the stomach is found distended after operation, and not normally emptying itself, lavage should be practised often enough during the day to keep it empty. The fact that the patient has become comfortable after having presented the first symptoms of dilatation, should not deceive the surgeon that danger has passed. Lavage should be continued. If there are any drains in the abdomen, they should be removed. The patient should lie on the right side with the head of the bed raised.

It is doubtful if the disease is due alone to obstruction by the mesentery, as it occurs after gastro-enterostomy; therefore operations to relieve obstruction are not indicated. The disease seems to be a paresis of the stomach wall, to be treated by sparing it from dilatation.

If the patient suffers from loss of body fluids they should be restored by proctoclysis or infusion. The patient should be placed in the elevated-head position, even to sitting upright if it gives the most comfort. Usually it will be found that the stomach empties itself best if the head of the bed is raised and the patient lies on the right side.

Postoperative vomiting, which is relieved by lavage, may in some cases be treated by passing a rubber tube, about 7 mm. (¼ inch) in diameter, through the nose into the stomach. It should pass down about 45 cm. (18 inches). The tube should have two or three openings in the end. Connected with this tube should be a long tube reaching to a vessel on the floor. The tube is made fast by a tape tied around the head. Fluid siphons out and the patient is kept comfortable. He may drink as much water as he can (see Postanesthetic Vomiting, Vol. I, page 104; and Vomiting after Abdominal Operations, page 531).

Enteroptosis is a most common condition, though in most cases it causes no symptoms which demand relief. It may often be discovered in the search for causes, but the surgeon should not attempt to change the arrangements of the abdominal viscera unless he is quite sure that he is correcting the defect which causes the symptoms. It is natural for the viscera to be movable. Hygienic and medical treatment should precede surgery. Actual enteroptoses may be cured by proper eating, exercise and sleep. Reflex irritations, as found in the eyes, vermiform appendix, and genital organs, should be corrected. Ochsner has children with enteroptosis sleep with the foot of the bed elevated 15 to 30 degrees, to cause the abdominal viscera to move upward, and relieve the supporting structures from strain.

An *elongated mesocolon* may permit prolapse or actual torsion of the cecum simulating appendicitis. This can be corrected by making a fold in it with sutures to the posterior and lateral abdominal walls (see Volvulus, page

Fig. 1260.—Ptosis of the Transverse Colon to be Remedied by Operation.

608). *Ptosis of the transverse colon* may be so extreme as to lodge that organ in the pelvis. This may be corrected by shortening its mesenteric attachment, by shortening the gastrocolic omentum, or by fixing the omentum just below the colon to the anterior abdominal wall (Figs. 1260 and 1261). The *hepatic* and *splenic flexures* may be fixed in place by sutures anchoring their mesenteries to the posterior abdominal wall. *Ptosis of the sigmoid* has been discussed under volvulus (page 608).

In extreme cases of elongation and ptosis of the transverse colon, giving rise to constipation and other disturbances, resection of bowel may be done (see Gastroptosis, page 710).

Closure of Intestinal Fistula (Fecal Fistula, Artificial Anus).—A small *intestinal sinus* should be easily closed (see Fistulas and Sinuses, Vol. I,

page 304). In addition to the ordinary local treatment, the patient may be caused to fast for a few days or subsist on nutrient enemata. If these methods fail, the sinus may be dissected out, and the intestinal opening sutured. Before such an operation, the skin should be gotten into healthy condition by keeping it dry, by applying boric acid powder, ointment, or other medication. The operation is done by packing the sinus with dry gauze; sewing its mouth tightly together with silk; sterilizing the wound area with iodin or chlorin solution; isolating the sinus, without opening it, by an elliptic incision; liberating the bowel with tissue containing the sinus attached to it; amputating the sinus at its entrance to the bowel, closing the bowel opening with two layers of sutures; and closing the abdominal wound.

Fig. 1261.—Omentum Sewed to Abdominal Wall, Holding Colon in Place.

The great omentum, immediately below the transverse colon, is caught to the anterior abdominal wall with three or four sutures. The bowel is here shown lifted up. When it is released and the wound closed it drops below the level of the wound.

Later, if necessary, the intestine may be liberated from its adhesion to the abdominal wall.

A *fecal fistula*, having a larger opening, without a spur or without obstruction in the distal arm tends to close spontaneously. If it does not close, it may be treated as above (Fig. 1262). If it is not desired to expose the peritoneum, the elliptical dissection may be carried down to the peritoneum but not through it, and the opening in the bowel sutured. This leaves the bowel still attached to the abdominal wall, where it may be left, or liberated at a subsequent operation.

In most cases it is best to carry the incision through the peritoneum (Fig. 1263). The finger then can determine the position of the adhesions. All of the inflammatory mass containing the fistula is excised, together with a

small ellipse of bowel having the fistula in its center (Fig. 1264). The longitudinal opening in the bowel is closed transversely with two rows of sutures (Fig. 1265). The transverse closure of a longitudinal wound is to prevent narrowing of the bowel at this point. In the case of *fecal fistula with obstruction* beyond the fistula, closure should not be attempted until the obstruction

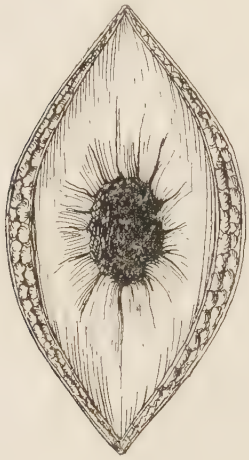

Fig. 1262.—Excision of Intestinal Fistula.

Incision made in skin about fistula.

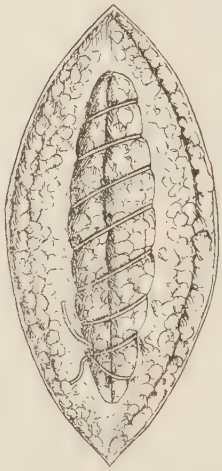

Fig. 1263.—Excision of Intestinal Fistula.

The mouth of the fistula has been closed by suture passed through the dissected-up skin.

is removed. In some cases this may be done as a separate operation through a separate wound; in other cases the obstruction and fistula may lie so near together that they both may be attacked through the elliptical wound made about the fistula.

The treatment of *fistula with a spur* (Fig. 1265) consists in division of the spur. As a preliminary, when a fecal fistula is made, if time will permit, it is

Fig. 1264.—Fistula Dissected out with Small Segment of Intestinal Wall.

wise to sew two arms together on either side so that the spur shall consist of two adherent bowel walls (see Artificial Anus, page 587). When this has been done, the division of the spur by means of a clamp can be accomplished without danger to other structures. One blade of a clamp is introduced on either

side of the spur, and the spur grasped. The pressure of the clamp in a few days causes necrosis through the spur, and a free passage for the intestinal contents is provided. An adhesive peritoneal inflammation is caused by the pressure. This extends for some distance beyond the line of necrosis. The clamp should be tight enough to occlude all vessels. A screw clamp requires to be tightened frequently. It may be left on for two days, and reapplied if perforation does not occur within ten days. I have found the best satisfaction in using long, straight, stomach or intestinal clamps and regulating the bite by placing elastic bands on the handles.

Some surgeons prefer to leave the clamp on until it has cut through the spur. Two light clamps may be applied side by side, or the ordinary pedicle clamp may be used. Unless a preliminary suturing of the bowel surfaces has been done, it is possible that the adhesions which form as a result of the clamp pressure may be so delicate that they fail to hold. In this event intestinal contents escape into the peritoneal cavity, and the operation ends in disaster. While this is a possibility, it rarely occurs, and surgeons usually are satisfied to do the operation without sewing the loop together.

Fig. 1265. Diagram of Several Forms of Fecal Fistula which may be Cured by Operation.

In order to obviate the above danger the following procedure may be adopted: The bowels are thoroughly cleared out. A circular incision is made through the skin about 5 mm. (3/16 inch) from the fistula. A good-sized, stiff, rubber tube is introduced in the upper limb of the fistula, and the skin closed tightly around the tube by a purse-string suture of silk. The wound region is then sterilized with iodin. The peritoneum is then opened and the bowel liberated by an elliptic incision, as above described. In opening the peritoneum in these operations care must be taken lest adherent bowel be wounded. The afferent and efferent segments of bowel are then sewed together by a continuous suture passing down one side and up the other in the form of a U. This suture embraces the spur. The loop of bowel is again sewed in the wound as before. After two days, adhesions have developed, the tube may be removed, and a clamp put on the spur. This is a safer operation than making an anastomosis or doing a resection.

Another expedient consists in temporarily closing the fistulous opening; dissecting free the loop of bowel by an elliptic incision; applying the U-shaped musculoserous suture to the two limbs; drawing out the bowel and protecting it; removing the temporary suture; enlarging the opening longitudinally; dividing the spur with scissors between the two arms of the U-suture; applying a continuous through-and-through suture to the divided edges of the spur, running parallel with the U-shaped peritoneal suture; closing the opening in the bowel; and then closing the abdominal wound. If there are raw surfaces left on the bowel, they may be covered with a peritoneal flap, taken from the adjacent abdominal wall or by omentum. To make the

operation still more safe, the fistula may be left open in the abdominal wound, and closed at a later operation.

The Omentum.—*Inflammations of the omentum* are a part of peritonitis and are treated the same. When found inflamed and gathered into a solid mass, the omentum is best removed.

Ligation of the omentum is done in sections, each ligature embracing enough tissue to make a pedicle about 3 mm. (⅛ inch) in diameter. A torn string of omentum should be ligated and removed.

Strangulation of the omentum found with hernia and bands requires removal of the strangulated part.

Torsion of the omentum may be of such a degree as to shut off the circulation. Removal of the strangulated part is called for.

Tumors of the omentum should be treated as tumors elsewhere (Vol. I, page 323).

Cysts of the omentum should be extirpated or incised and drained (see Cysts, Vol. I, page 325).

Enemata.—*Laxative enemata* are best given with a fountain syringe. This consists of a bag or vessel, holding 1 or 2 liters (1 or 2 quarts), with a rubber tube about 2 meters (6 feet) long, and a tip for introduction in the rectum. The tube should have a stop for closing it, and have a piece of glass tubing introduced somewhere in its course so that the flow can be seen. The receptacle should be elevated from 60 to 120 cm. (2 to 4 feet) above the level of the rectum. The patient should lie on the back or right side with the pelvis elevated. In some cases better results will be secured by the knee-chest position. The temperature of the injection should be about 105°F. (41°C.) in the receptacle. The fluid should run in slowly, the patient having been instructed to relax himself, breathe deeply with the mouth open, and not to resist. The sphincter should control any tendency of the fluid to escape (see Intestinal Irrigation, page 570). The patient should retain the enema about ten minutes, and then pass it with the defecation.

A *soap enema* consists of about 30 Gm. (1 ounce) of nonirritating soap mixed into a suds with 1 liter (1 quart) of water.

A *turpentine enema* adds 4 c.c. (1 dram) of oleum terebinthinæ rectificatum to the above. The turpentine may be increased up to 30 c.c. (1 ounce) if necessary.

The *glycerin enema* consists of 30c.c. (1 ounce) of glycerin in 125 to 500 c.c. (4 to 16 ounces) of water.

The *alum enema* is made by adding 4 Gm. (1 dram) of powdered alum to 500 or 1000 c.c. (1 or 2 pints) of water.

The *milk* and *molasses enema* is composed of 500 c.c. (1 pint) of each of these ingredients. Munro adds 15 c.c. (½ ounce) of turpentine.

A *mixed enema* is made of 60 Gm. (2 ounces) each of magnesium sulphate and glycerin, with water enough to make 180 c.c. (6 ounces).

The *oil enema* is composed of as much warmed olive oil as the patient will take, usually about a pint.

Nutrient enemata should be preceded by a washing out of the bowel with simple warm saline solution. If there is irritability of the rectum it may be allayed by the injection of a mixture of 0.03 Gm. (½ grain) of cocain, 0.015 Gm. (¼ grain) of morphin, 0.06 Gm. (1 grain) of extract of hyoscyamus and 0.6 Gm. (10 grains) of bromide of soda, dissolved in 60 c.c. (2 ounces) of water. If either the morphin or cocain are contraindicated they may be omitted. If it is desired to make the injection smaller, the bromide and half of the water may be omitted.

Nutrient enemata may be given every four or six hours. The material is

injected into the rectum, with the patient's pelvis elevated. Reversed peristalsis sometimes carries it up into the colon where it is absorbed. It should not be too large or it will excite progressive peristalsis and be expelled. The maximum amount should be 250 c.c. (8 ounces). It should be given at a temperature of about 39°C. (102°F.).. It should be given through a soft-rubber rectal tube 10 or 12 mm. (⅜ to ½ inch) in diameter. The tube should be lubricated with vaselin and introduced 15 or 20 cm. (6 or 8 inches) into the rectum. The enema should flow in slowly by gravity, being poured into a funnel.

Nutrient enemata fail to be of use unless the predigestion has been carried to an advanced stage. It must go beyond the peptone stage. The latest studies have shown that the amino-acids produced from meat and milk which have been digested for twenty-four hours with pancreatic enzymes are well absorbed. Dextrose is absorbed well. The dextrose should not be used stronger than 10 per cent. Milk which has been subjected to vigorous pancreatic predigestion, and the subsequent addition of 5 per cent. dextrose makes the best nutrient enema. The milk should be treated for twenty-four hours with an active pancreatic extract. Eggs and poorly digested milk are probably useless. Fats and oils are not absorbed.

Defibrinated blood is absorbed from the rectum. As much as 90 to 120 c.c. (3 to 4 ounces) of blood plasma can be absorbed in eight or ten hours.

The drip method is useful. Either a glucose solution or glucose and peptonized milk may be used. With a 1 or 2 per cent. dextrose solution 30 to 60 drops a minute may be given. An enema of 125 to 250 c.c. (4 to 8 ounces) of peptonized milk and 500 c.c. (1 pint) of a 4 per cent. glucose solution may be given by the drop method 3 or 4 times daily. The glucose solution may be used as strong as 50 Gm. to 500 c.c. of water, given every six hours (see Proctoclysis, Vol. III). Not more than 25 Gm. of glucose should be given at one injection.

Often the drip method is not well tolerated. Single injections of meat or milk amino-acids with glucose may be given. About 10 Gm. of nitrogen with 50 or 75 Gm. of glucose in twenty-four hours may be divided into three or four enemas. A single enema of 225 to 275 c.c. is best absorbed.

By this method it is possible to supply the body with 400 to 600 calories daily. This diet is deficient in fats, but supplies nitrogen and carbohydrates. The patient consumes his own fats. It is possible to maintain a fair degree of nutrition for two or three weeks by this method.

Operations on the Intestines

Anatomy.—The stomach and intestines are composed of four coats, the serous (peritoneum), the muscular, the submucous, and the mucous. A thin but tough layer of muscle fibers (muscularis mucosæ) lies between the mucous and submucous coats (Fig. 1266).

The upper limit of the root of the mesentery of the small intestine, the duodenojejunal angle, is usually 8 or 10 cm. (3 or 4 inches) above the level of the umbilicus. The root of the mesentery extends from the left side of the body of the second lumbar vertebra downward to the right sacro-iliac synchondrosis (Fig. 1267).

As the mesentery approaches the intestine its two serous surfaces separate and leave a space on the bowel which is free from peritoneum. This mesenteric triangle must receive especial attention in making intestinal anastomosis lest leakage occur. G. H. Monks showed that the situation of the loop of small intestine exposed may be determined by the character of the mesenteric blood-vessels (Figs. 1268, 1269, 1270 and 1271).

The *duodenum* is 25 to 30 cm. (10 to 12 inches) long. It lies posterior to the peritoneum and may be said to have no mesentery. Its first or hepatic portion passes from the pylorus of the stomach upward, backward, and outward to the neck of the gall-bladder. The second, vertical or descending, portion passes down along the right side of the spine behind

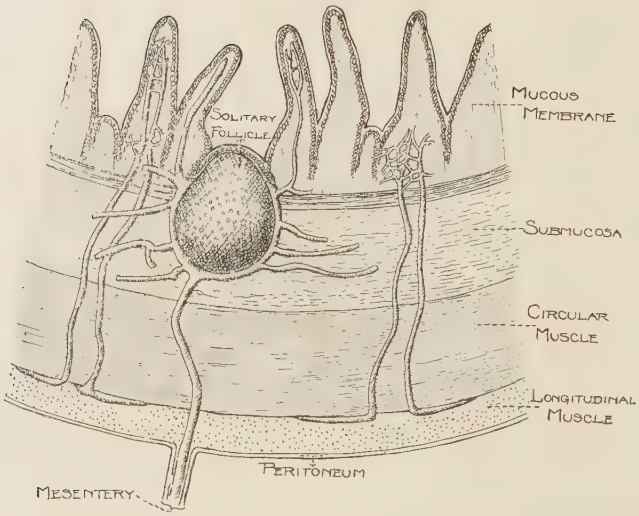

Fig. 1266.—Magnified Cross-section of Small Intestine. Showing the various coats with which the surgeon has to deal.

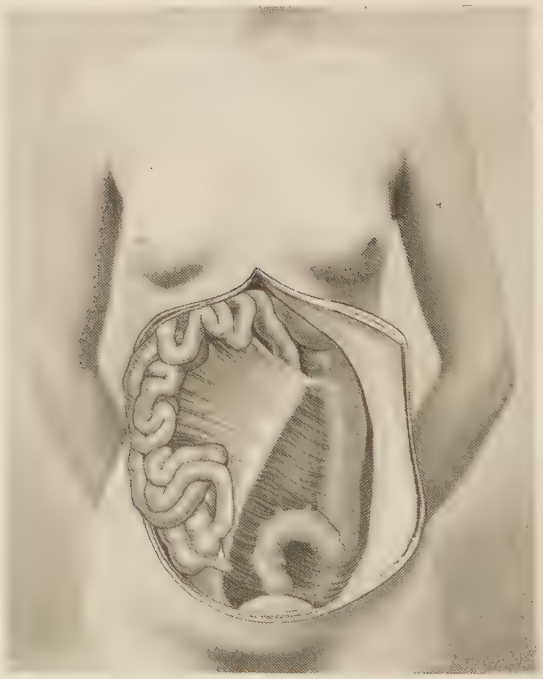

Fig. 1267.—The Mesentery.
The small intestine is lifted upward and to the side. The oblique attachment of the root of the mesentery is shown.

FIG. 1268.—SMALL INTESTINE ONE METER BELOW THE DUODENUM.
The primary mesenteric loops give off the vasa recta. Note translucent space between the vessels.

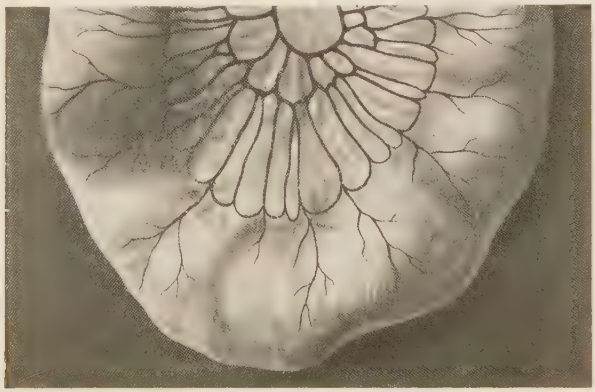

FIG. 1269.—SMALL INTESTINE TWO METERS BELOW DUODENUM.
The secondary vascular loops are well developed. The translucent area is less than above

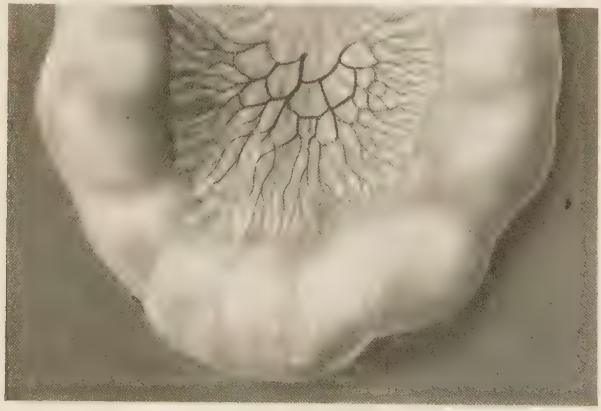

FIG. 1270.—SMALL INTESTINE FIVE AND A HALF METERS BELOW DUODENUM.
The mesentery is opaque and the vessels have become a complicated network.

the transverse colon, and receives the bile and pancreatic ducts posteriorly. The third, the transverse or preaortic, portion passes behind the mesentery from right to left to emerge just below the transverse mesocolon. The fourth or ascending portion passes upward along the left side of the spine. The fifth portion, or duodenojejunal angle curves sharply to continue downward into the jejunum (Fig. 1272).

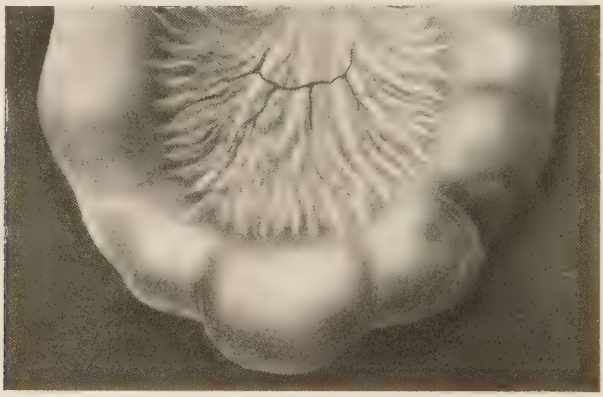

FIG. 1271.—SMALL INTESTINE SEVEN METERS BELOW DUODENUM.
The mesentery is fatty and more closely resembles that of the large intestine. The arrangement of the vessels is complicated and obscured by the opacity of the mesentery.

The *jejunum* is about 3 meters (10 feet) long. Its coils are generally on the left side of the abdomen, in the lumbar, inguinal, and left half of the umbilical regions.

The *ileum* is about 4 or 5 meters (14 feet) long. Its coils are generally on the right side of the abdomen and pelvis, in the lumbar, inguinal, and right halves of the umbilical and hypogastric regions.

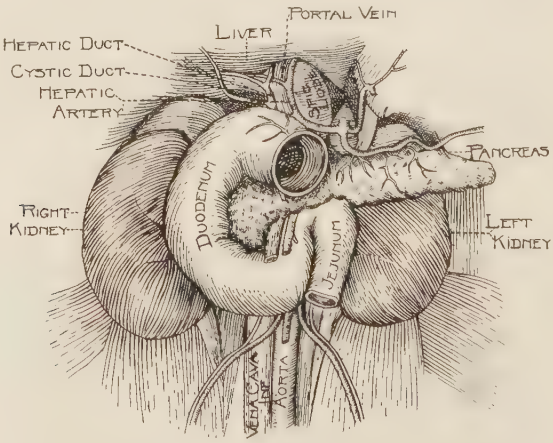

FIG. 1272.—DUODENUM.
Showing its anatomic relations.

The *large intestine* differs from the small intestine in that, it is larger; it is more fixed; it has sacculations, separated by transverse ridges; it has longitudinal bands, and appendices epiploicæ (Fig. 1273).

The *cecum* lies in the right iliac fossa on the psoas-iliacus muscle. It is entirely covered by peritoneum, being free, and usually without a mesentery. It is just above the outer half of Poupart's ligament. The *appendix vermiformis* generally is attached about 1.7 cm. ($1\frac{1}{16}$ inch) below the ileocecal valve, to the inner and posterior aspect of the cecum.

The *ileocecal valve*, at the junction of ileum and cecum, is on the posterio-internal aspect of the upper part of the cecum.

The *ascending colon* is about 20 cm. (8 inches) long. It ends at the lower surface of the right lobe of the liver at the right of the gall-bladder. It is usually behind the peritoneum, having no mesentery in about three-fourths of cases. The *transverse colon* is about 50 cm. (20 inches) long. Its mesocolon is long. The *descending colon* is about 22

FIG. 1273.—CROSS-SECTION OF ASCENDING COLON.

cm. (8½ inches) long. Its peritoneal covering is similar to that of the ascending colon. A mesocolon is present in about a third of the cases. The *sigmoid colon* is about 31 cm. (13 inches) long, and lies in the left iliac fossa. It ends opposite the brim of the pelvis opposite the left sacro-iliac synchondrosis. It has a freely movable mesentery.

The *mesenteric triangle* is that part of intestine having a mesentery where the two peritoneal layers of the mesentery separate to pass around the bowel. The two layers begin

FIG. 1274.—MESENTERIC TRIANGLE, WHICH REQUIRES ESPECIAL ATTENTION IN MAKING INTESTINAL ANASTOMOSIS.

to separate about 1.5 to 2 cm. (⅔ to ¾ inch) from the bowel, and leave about 8 mm. (5/16 inch) of the bowel wall without a serous coat (Fig. 1274).

The *surface topography* of the large intestine is less variable than that of the small intestine, but still quite variable. In general, the lower border of the cecum corresponds to a line drawn from the anterior superior spine of the ilium to the symphysis pubis. The

ascending colon traverses the right lumbar and hypochondriac regions to the hepatic flexure just below and to the outer side of the gall-bladder. The transverse colon commonly passes across the abdomen at the junction of the epigastric and umbilical regions. It lies between the greater curvature of the stomach and the umbilicus. The splenic flexure

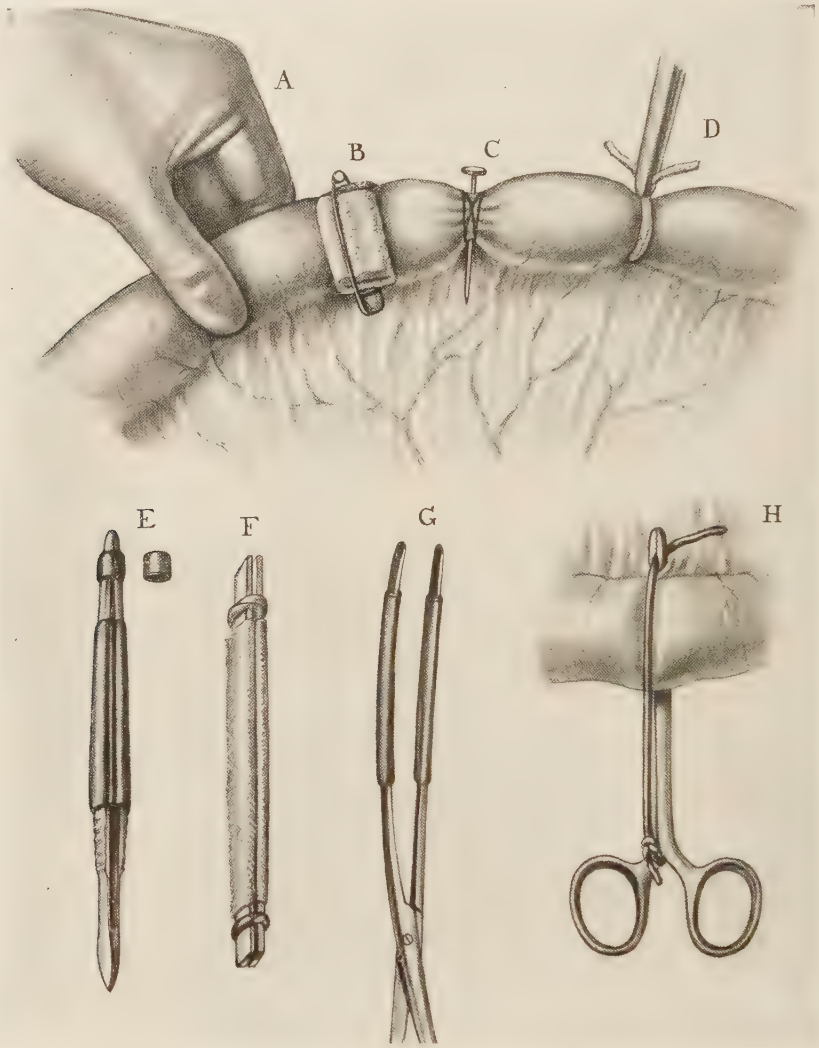

FIG. 1275.—METHODS OF TEMPORARY CLOSURE OF INTESTINE DURING OPERATION.

A, Digital compression; *B*, safety pin and sponges (*Maunsell*); *C*, pin of metal or wood (probe, nail or skewer) with rubber band; *D*, fillet of gauze held about bowel with hemostatic clamp; *E*, forceps protected with rubber tubing and held together by a small ring of tubing; *F*, wooden strips covered with gauze and held together with rubber elastics; *G*, special intestinal clamps covered with rubber tubing; *H*, rubber cord combined with hemostatic clamp.

is posterior to the cardia of the stomach in the left hypochondrium. The descending colon passes downward through the left hypochondriac and lumbar regions to the sigmoid.

Instruments for Intestinal Operations.—Intestinal clamps for temporary closure of intestine are used. In lieu of these a hemostat and a rubber elastic

band may be employed, or any other device giving gentle and even pressure (Fig. 1275).

Needles should be both straight and curved. A round, straight needle, such as used by milliners, may be held in the fingers, and is very satisfactory for intestinal work (Fig. 1276). Nos. 6 to 8 are used. Many surgeons prefer a curved needle to be used either with or without a holder (Fig. 1277). The straight needle is usually best where there is room; the curved needle is best for work which must be done inside of the abdomen. Round needles are to be preferred to needles which cut the tissues. For interrupted sutures,

Fig. 1276.—Milliner's Needle Used in Intestinal Suturing.

many needles may be ready threaded, or a long thread may be used and cut at each suture. It is usually best not to tie interrupted sutures until all have been introduced. No. 0 chromic catgut has the largest range of usefulness. No. 1 silk or linen thread is also used. For special purposes still larger and smaller sizes of thread are employed. The needle may be held and passed toward or away from the operator or laterally.

Knives, ligature carrier, hemostatic clamps (short and long), anatomic and toothed forceps, scissors, probe, tenaculum, needle holder, sponge holders, rubber and glass drainage tubing, laparotomy pads, sponges, gauze or wick drains, ligatures, and the instruments for opening and retracting the abdominal wall are used (see Instruments and Materials, Vol. I). Special instruments and appliances are used for special operations.

Fig. 1277.—Curved Needle Used in Intestinal Suturing.

General Principles.—Successful intestinal suturing requires experience and skill to begin with. They are best secured by operations on animals and by assisting an experienced and skilled surgeon. The basic principle in the suturing of intestinal wounds is the even apposition of serous surfaces, which are to be held by the sutures, without leakage to infect them, until they become adherent and the adhesions organized. The broader the surfaces, the less the danger of leakage. The scar tissue that unites the surfaces contracts, and allowance should be made whenever possible for this contracture by making artificial openings from 2 to 4 times as large as they need ultimately to be.

The closure should be water-tight. If two tiers of suture are employed, it is generally best that a suture penetrating the mucosa should not penetrate the serosa; and a suture penetrating the serosa should not penetrate the mucosa. The serosa suture should pass as far as the mucosa, embracing, if possible, the muscularis mucosæ. Sutures embracing the mucous mem-

brane should preferably be of silk or linen, except in the stomach. For sutures which pass through all the coats, silk or linen is the best material.

To prevent leakage of intestinal contents during operations, clamps are used. These should be so protected that they cannot do injury to the bowel. If lock clamps are employed the jaws should each be covered with rubber tubing. In the absence of any clamping device a bit of gauze drain may be pulled through a small opening in the mesentery and tied or caught by a clamp.

The submucous vessels may bleed after the operation. They should be controlled by the suture. The suture which embraces the mucous membrane should be tight, and, if continuous, it should be tied or interrupted frequently.

The relation of the supplying vessels in the mesentery to the bowel to be resected should be observed. No chances should be taken to leave any segment of bowel to be supplied by damaged mesenteric vessels. Resections should be made larger, if necessary, to insure a safe blood supply.

Two *forms of suture* are used: the *interrupted* and the *continuous*. The interrupted suture more evenly distributes the strain; if one becomes weak or loose, it does not affect the others; the blood-vessels are compressed only at each suture; and expansion of the wound is not hindered. The continuous suture is more quickly applied, but the whole suture is as weak as its weakest part. The disadvantages of the continuous suture may be prevented somewhat by tying the thread at frequent intervals. This interrupts the suture. Certain interlocking sutures, such as taking two turns about each suture before pulling it taut, also give it the character of an interrupted suture.

It is best to use two tiers of sutures. In doing this, at least one tier may be a continuous suture. To tighten a suture, after it has been introduced, it should be pulled in a direction nearly parallel with the direction in which it was introduced. Traction at a right angle to the direction of introduction will cause the suture to tear out.

The bowel at the place of operation should be emptied by placing a clamp above and then gently stripping its contents downward and placing a clamp below to prevent regurgitation. The clamps should be far enough apart to give ample room for work. Bowel to be opened should be placed upon a separate towel or pad which may easily be removed and renewed without interference with the rest of the field of operation. With care, it is possible to soil only the sponges which touch the mucous membrane. Soiled instruments are laid aside or rinsed off. There should be but few instruments in the field. The only instruments to become soiled should be a needle and forceps. The field of operation should be dry. Soiled instruments and sponges should not lie about. Skillful surgery is simple and orderly. Mussy surgery means bad results.

Hemorrhage should be minimized by making incisions through areas having the smallest vessels. Cut vessels should be caught quickly and tied with fine catgut. The peritoneum should be left dry. Drainage is usually not to be employed.

Intestinal Suture (Enterorrhaphy).—There are many methods of applying intestinal sutures. The most important will be described. They are applied in such a way that as the suture is tightened, the wound edges are invaginated. The width of tissue embraced in the suture is about 3 mm. (1/8 inch) the sutures should emerge about 2.5 to 3 mm. (1/10 to 1/8 inch) from the edge of the wound; and they should be about 3 mm. (1/8 inch) apart. Moynihan estimates the tightness to which a continuous suture should be drawn as follows: the last suture should be pulled to raise up into prominence the part of the wall into which the next suture is to be passed. Suturing the intestine

should be done with the loop to be operated upon outside of the abdomen. All the rest of the bowel should be in the abdomen, and the field of operation thoroughly protected. An extra protective pad should be placed under the place where the bowel is to be opened. As soon as soiling has ceased, this should be changed. After completing a suture in which the lumen of the bowel has been exposed, the bowel should be washed off with warm salt solution before being returned to the abdomen.

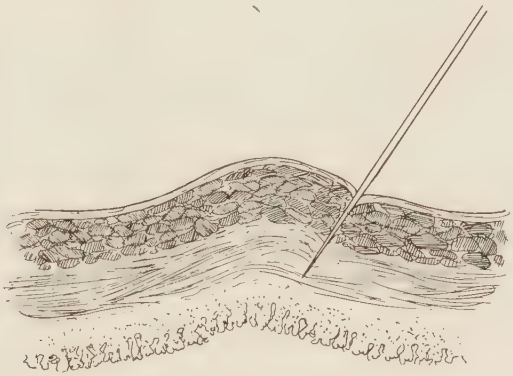

FIG. 1278.—SEROMUSCULAR SUTURE.
The needle passes as far as the submucosa.

For applying the *seromuscular suture* with a straight needle, the needle is passed as far as the submucosa and then caused to lift up the wall of the bowel as a fold and push the needle on so that it passes out through muscularis and serosa without penetrating the mucous membrane (Figs. 1278 and 1279).

The use of *omental grafts* is indicated in some cases where the line of suture may be weak. The best omental graft consists in a surface of omentum



FIG. 1279.—SEROMUSCULAR SUTURE.
The wall of the bowel is lifted up to make a fold and the needle is passed on through muscularis and serosa without penetrating mucous membrane.

sewed about the line of sutures so as to cover it. This imitates what nature does in just such cases. A detached piece of omentum may also be used for this purpose.

The *sterilization of mucous membrane* which is exposed in the course of operations is usually not necessary. It is infected, of course, but the bacteria

of the intestine when carried by sutures seem not to grow in the tissues. Still, so far as the surgeon's hands, instruments, and sponges are concerned, it should be assumed that dangerous infection is present in the mucous mem-

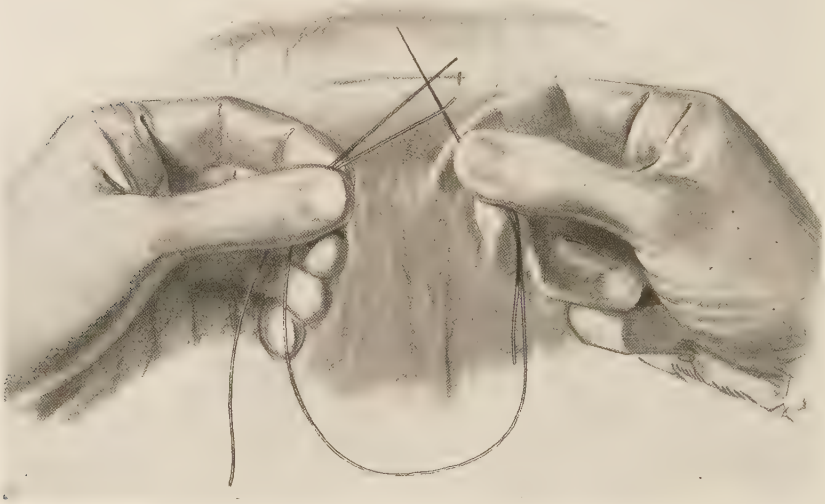

Fig. 1280.—Beginning Stitch for Suture of the Intestine.

brane, and material from the mucous membrane should not be conveyed to uninfected tissues. This means that when the surgeon's hand touches the mucous membrane, the hand should be washed off before it touches sterile parts such as peritoneum or wound surface.

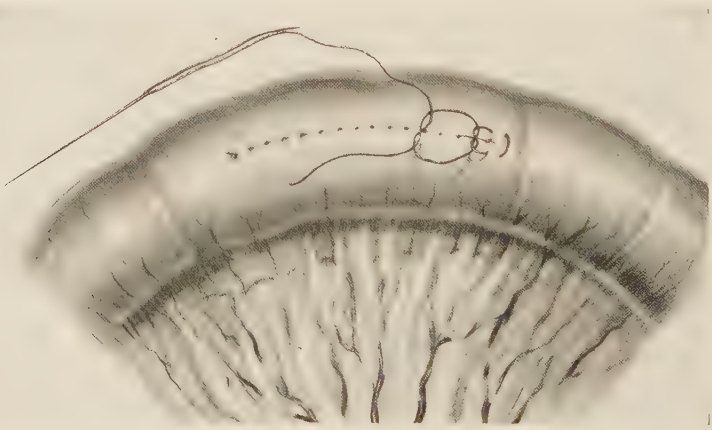

Fig. 1281.—Tying the First Knot for the Continuous Parallel Suture.
The first layer of through-and-through sutures has been introduced.

If the intestinal contents are in a fluid state, the danger of infection is much greater. Fluid feces are much richer in virulent organisms than are dry or soft feces. This should be borne in mind, and before operations for

opening the intestine a purge should not be given within twenty-four hours. It is best in these cases that the laxative be given forty-eight hours before the operation, after which only such foods as leave the minimum of fecal residue should be taken.

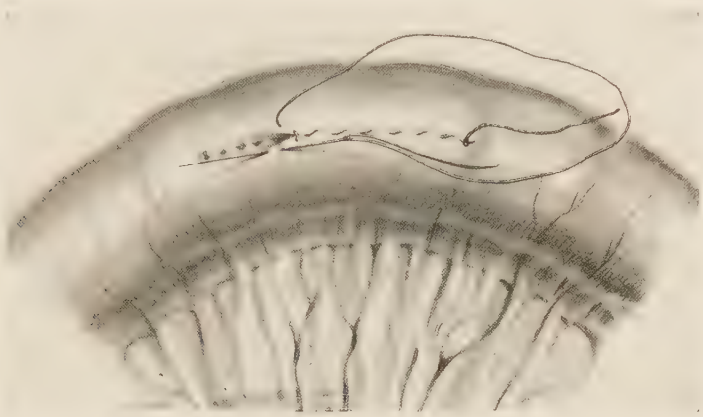

FIG. 1282.—THE PARALLEL CONTINUOUS STITCH.
The first layer of sutures has been introduced. The second layer is in process of application.

When the surgeon desires to sterilize the mucous membrane which appears in the wound at the time of operation, it may be done by applying 5 per cent. alcoholic solution of thymol. Tincture of iodin serves the same purpose, but not so effectively as the thymol.

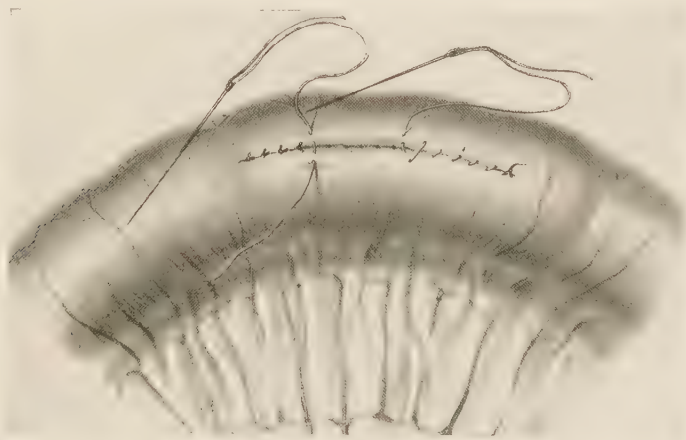

FIG. 1283.—SIMPLE RIGHT-ANGLE STITCH OF LEMBERT.
Showing interrupted suture (at left) and continuous suture (at right). The primary suture has been placed.

The *parallel continuous stitch* (Cushing) is applied with the needle always passing parallel to the wound, first on one side and then on the other. At the extreme ends the suture may be caused to double back upon itself in order to cover the knot (Figs. 1280, 1281, and 1282).

The *simple right-angle stitch* (Lembert) (Figs. 1283 and 1284) passes

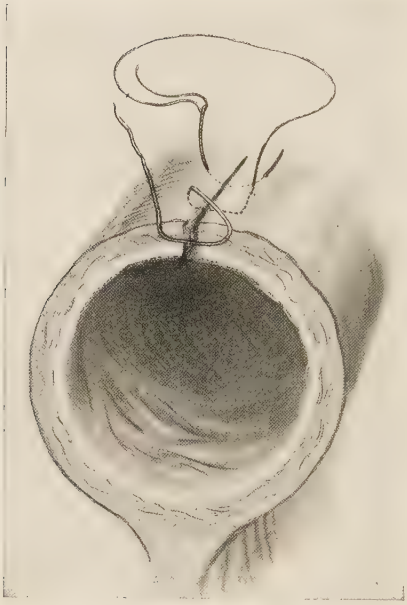

Fig. 1284.—Simple Right-angle Suture of Lembert.
Suture shown in cross-section of bowel.

Fig. 1285.—Simple Right-angle Infolding Suture of Lembert.
Transverse section.

transversely from one side of the wound to the other. It may be interrupted or continuous. It may be used as a simple infolding suture (Fig. 1285) or combined with an underlying penetrating stitch (Fig. 1286).

Fig. 1286.—Simple Right-angle Infolding Suture of Lembert, Combined with Underlying Penetrating Suture. Diagrammatic.

The *seromuscular mattress stitch* represents two stitches with one tie (Fig. 1287).

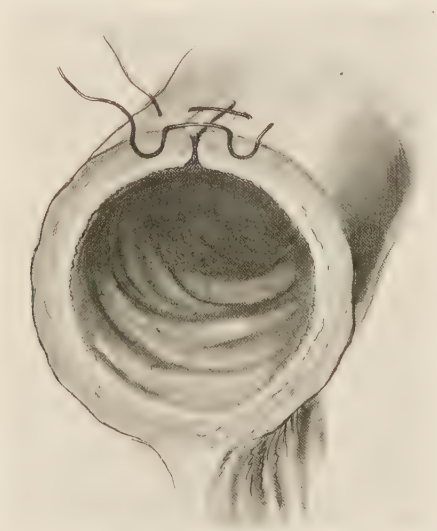

Fig. 1287.—Seromuscular Mattress Stitch.

The right-angle mattress stitch (Halsted) (Fig. 1288) represents one tie for every two simple right-angle stitches (Lembert). This is modified (Gould) by reversing the direction of introduction on one side (Fig. 1289).

Fig. 1288.—Right-angle Mattress Stitch of Halsted.
The primary suture has been applied.

Fig. 1289.—Infolding Right-angle Mattress Suture of Gould.
The primary suture has been applied.

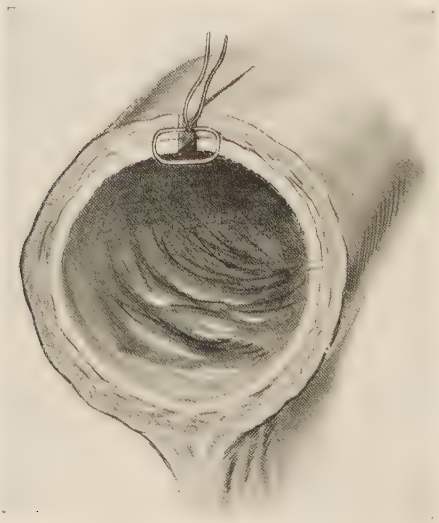

Fig. 1290.—Mucosa Suture of Czerny.
This suture is usually applied as a first layer to the mucous membrane and muscularis.

The *mucosa suture* (Czerny) (Fig. 1290) is applied to the mucous membrane and submucosa. It is usually interrupted, but may be applied as a continuous suture with occasional interruptions.

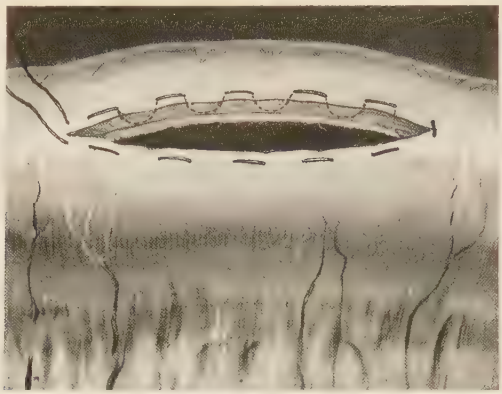

Fig. 1291.—Purse-string Suture Applied to Lateral Opening of Bowel.

The *purse-string suture* (Figs. 1291, 1292, and 1293) is used for fixing a tube or other device in the side of the bowel or in the cut end. The mucous membrane is not included except in using such devices as the Murphy button.

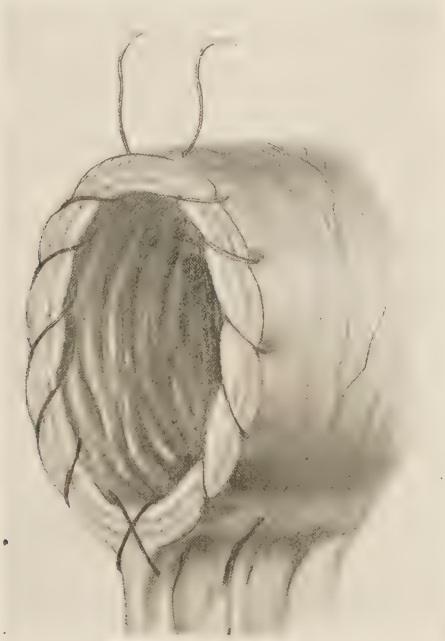

Fig. 1292.—Purse-string Suture Applied to End of Bowel.
Suture used to hold Murphy button.

For *suturing wounds of the intestines*, large enough to require two rows of sutures, a deep interrupted row of simple right-angle sutures (Lembert),

covered in by the continuous parallel stitch (Cushing) is to be preferred. A mucosa suture may be used if there is bleeding from the mucous membrane edges which is not controlled by ligatures.

The *perforating stitch* (Figs. 1294 and 1295) involves all of the coats of the bowel. It may be continuous or interrupted. It is used in some forms



Fig. 1293.—Purse-string Suture for Closing End of Bowel.

of enteroanastomosis (Connell). It may be a simple running suture or some form of button-hole or glover's stitch may be used. It was once thought that such a suture would convey infection to the peritoneum; but experience has shown that it sinks into the peritoneum, becomes sealed with plastic exudate, and is virtually a buried suture.

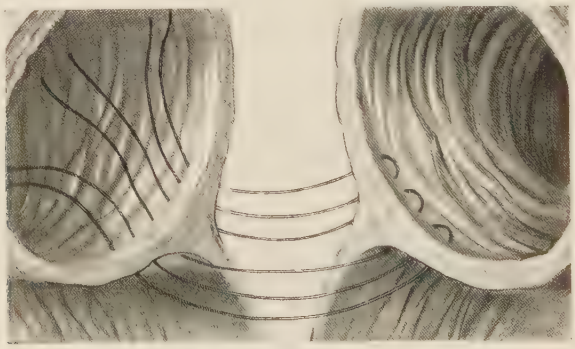

Fig. 1294.—Perforating Stitch of Connell.
The first three sutures have been applied.

The *mattress interlocking stitch* (Türck) (Figs. 1296 and 1297) obviates the danger of the open space between interrupted sutures, and combines many of the advantages of the interrupted and continuous stitch.

Intestinal Resection (Partial Enterectomy).—In man removal of 80 per cent. of the small intestine is compatible with life. As much as 540 cm.

(18 feet), have been successfully removed. The whole of the large intestine may be taken out without causing serious disturbance. While all of the colon can be removed without serious impairment of health, the removal of more than one-half of the small intestine is a serious undertaking. Removal of a segment of the intestinal canal is done for injury and disease. It is followed by intestinal anastomosis or the formation of an intestinal fistula. The abdomen is opened, and the segment to be removed is identified and brought out through the abdominal wound. The surgeon should mark with his eye a triangle on the mesentery, having its base at the segment of bowel to be removed and its apex about one-half of the distance toward the root of the mesentery. The vessels running into this triangle should be tied with

Fig. 1295.—Perforating Stitch of Connell.
The first third of the through-and-through suture has been applied.

the aid of the ligature carrier. The base of the mesenteric triangle to be removed should be slightly shorter than the bowel to be removed, in order that the nourishment of the cut edges of the intestine shall be adequate. The bowel is then emptied and clamped or its lumen obstructed by the fingers of an assistant about 6 or 8 cm. (3 inches) from the place to be cut. Protective towels and pads are placed in position, clamps are also placed on the segment to be removed in order to retain its contents.

The clamps placed on the bowel ends to be joined should not be at right angles to the gut but their tips should incline toward one another. The bowel should not be divided at right angles to its long axis, but about 25 or 45 degrees away from that. This means that as the cut surface is farther from the mesentery, the more bowel is removed (Fig. 1298). This oblique

division of the bowel makes a larger lumen, and guarantees better nourishment to the distal side. If 45 degrees are removed from each side this means that an angulation of 90 degrees is produced by the union. There is no disadvantage in this.

The mesenteric triangle is then cut on two sides up to the intestine. When the intestine is divided, its ends are cleansed and covered, and the segment of bowel and mesentery removed (Figs. 1299 and 1300). Soiled pads and cloths are removed, the hands are rinsed off, and a general cleaning up instituted.



Fig. 1296.—Mattress-interlocking Stitch of Türck.
Manner of cutting one-half of the double stitch.

Some surgeons prefer not to remove the mesentery, but to place the ligatures close to the bowel and parallel with it, and then cut the mesentery between the ligatures and the bowel. After removal of the intestine and anastomosis, the redundant mesentery is folded over and stitched to the adjacent mesentery (Fig. 1301). Another method of dealing with the unremoved mesentery, which I have used with satisfaction, consists in splitting it down midway between the two bowel ends, and leaving it in the form of

two triangular flaps, one connected with each segment. After the anastomosis, one mesenteric flap is placed on one side and the other on the other side, and each is sutured to the flat surface of the mesentery as close to the bowel as possible (Fig. 1302).

Whatever method of dealing with the mesentery is followed, it is always important that for anastomosis a firm suture to relieve tension on the stitches should be placed on either side at the enteromesenteric junction. This should not be placed so deeply as to interfere with the nutrient vessels.

Intestinal resection is done for obstruction caused by tumors, adhesions, or stricture; for gangrene of the bowel; for wounds and perforations of the bowel too extensive or complicated for satisfactory suture; for cases of intestinal fistula not capable of closure by simpler measures; for bowel which

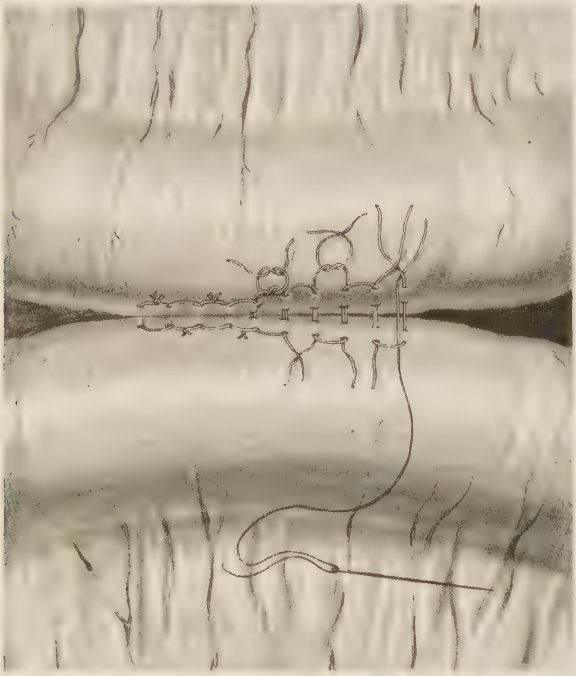

Fig. 1297.—Mattress-interlocking Stitch of Türck.
Showing manner of tying sutures.

has been excluded and no longer functionates; and for injuries, vascular diseases, or tumors of the mesentery, in which the blood supply of the intestine is so compromised or threatened as to cause or threaten gangrene of the bowel.

In resections where there is gangrenous or distended bowel, the mesentery should be freed from the bowel to the full extent; the distal division of the intestine is then made; and the segment which is to be removed used as a tube to convey away from the field of operation the contents of the bowel above. After the intestine has thus been emptied, the upper clamps are applied, and the resection proceeded with (the methods of anastomosis are given below).

Anastomosis may be difficult in some situations because of adhesions or

FIG. 1298.—RESECTION OF INTESTINE FOR END-TO-END ANASTOMOSIS.
The lines of incision having been determined, the mesenteric vessels are first tied and the mesentery is divided. No clamps are applied to the bowel until after this has been done.

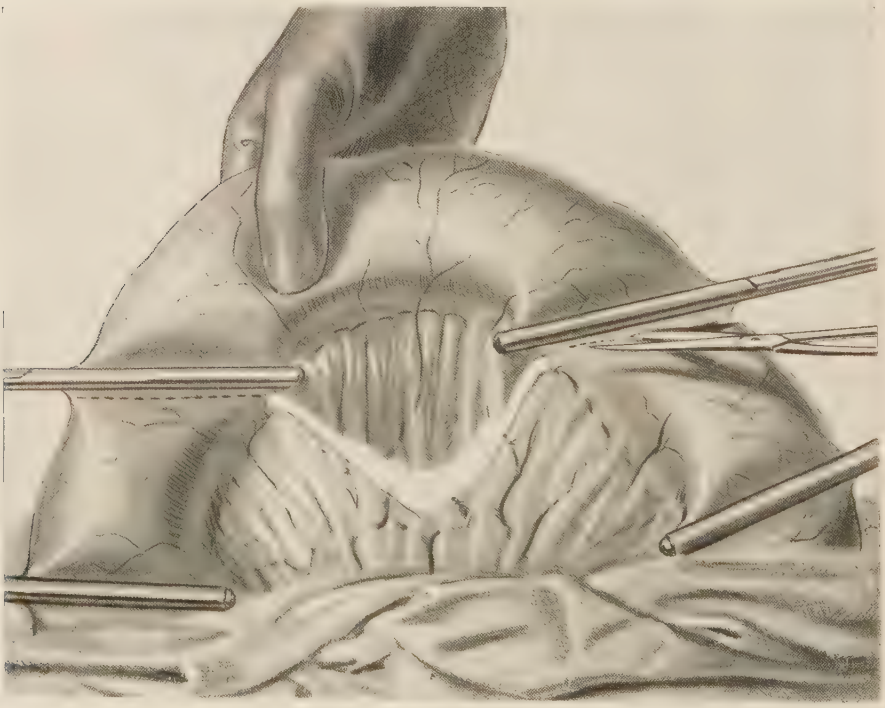

FIG. 1299.—RESECTION OF INTESTINE FOR END-TO-END ANASTOMOSIS
Note oblique division of the bowel. Such oblique division provides for better nourishment to the distal side of the gut and insures against stricture better than does transverse division.

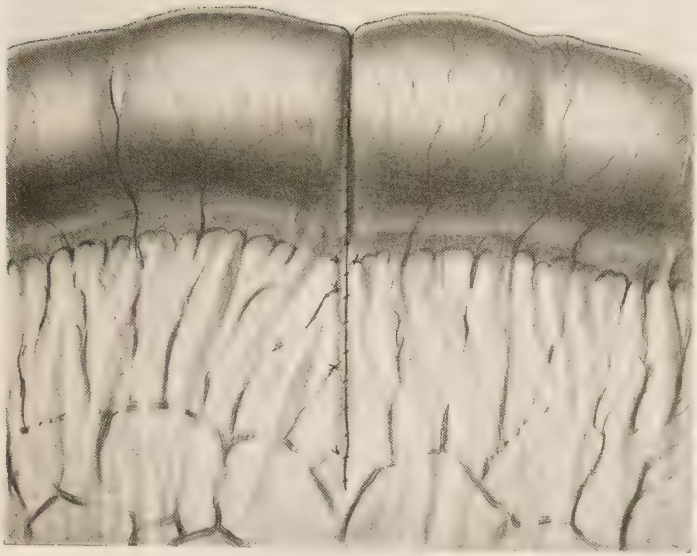

FIG. 1300.—RESULT OF ANASTOMOSIS AFTER OBLIQUE DIVISION OF BOWEL.

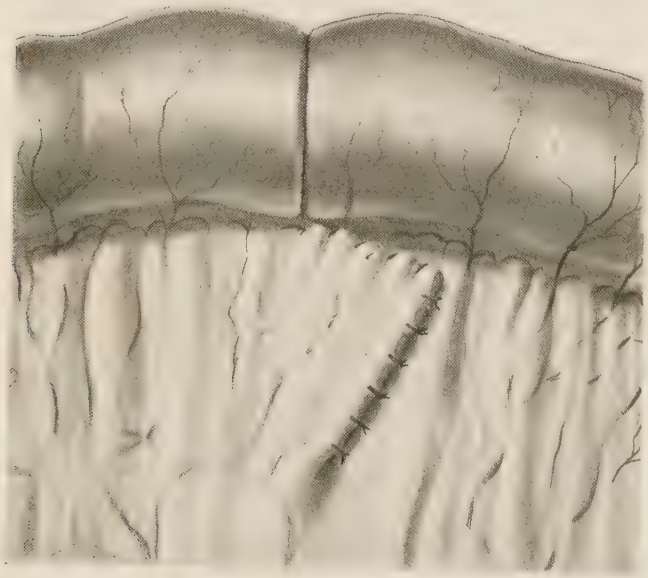

FIG. 1301.—METHOD OF TREATING REDUNDANT MESENTERY WHICH HAS NOT BEEN REMOVED WITH THE RESECTION OF INTESTINE.

The mesenteric fold is stitched over at its raw border and sewed to the adjacent mesentery.

anatomic peculiarities. In resection of the lower part of the sigmoid and upper end of the rectum, it may be difficult to manipulate the distal stump. To meet this, W. J. Mayo passed a large soft-rubber tube out through the rectum, and fixed its upper end inside of the upper stump by a catgut suture. The tube is then pulled down, and the proximal gut drawn inside the distal gut, after which the edges may be united by a suture. Further traction draws the gut down farther, invaginates the suture line, and a second row of sutures may be applied on the peritoneal side (Fig. 1303).

Removal of the *cecum* and *ascending colon* is often indicated for cancer, ulceration, stenosis and chronic stasis. In all such resections the operation should be done through a good-sized opening through the sheath of the rectus muscle. The resection should be preceded by a thorough investigation of the abdomen to determine the extent of the disease or the presence of other lesions. For resection of the right colon, after placing the protective gauze

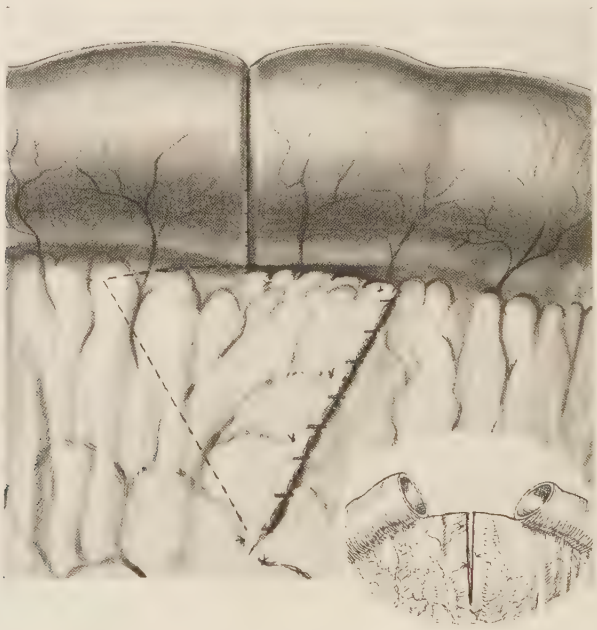

Fig. 1302.—Method of Treating Unremoved Mesentery by Dividing it into Two Equal Triangular Flaps and Sewing Each on Opposite Sides of the Mesentery.

or rubber sheeting along the inner side of the bowel, an incision is made at the "white fold" of parietal peritoneum where it passes to the outer side of the bowel. The bowel may then be lifted forward, and the subperitoneal wound packed with gauze. The ileum should then be ligated with catgut about 7 cm. (3 inches) from the colon, clamped 1 cm. distal to the ligature, and divided about 5 cm. distal to the ligature. The two cut ends of bowel should be sterilized with 5 per cent. thymol alcoholic solution, tincture of iodin, or phenol. The proximal stump is covered with a warm towel. Then from below upward the mesocolon is tied at intervals, clamped on the bowel side and divided. This proceeds rapidly to the hepatic flexure or as far as necessary. In the case of chronic stasis resection is carried to the junction of the right and middle thirds of the transverse colon.

In malignant cases, the division of the mesocolon is made far from the bowel; in non-malignant cases it is made close to the bowel. Care should be taken not to injure the duodenum as it passes under the mesocolon. Ureter and kidney must also be considered.

In removing the omentum, it should be ligated and cut from the right third of the colon. (For preserving the omentum, see below.) The colon is then tightly ligated with catgut, clamped proximal to the ligature and cut about 7 mm. proximal to the ligature, and the liberated bowel removed. The puckered mucous membrane of the stump is sterilized with the actual cautery, and buried with a purse-string suture of catgut. The stump of

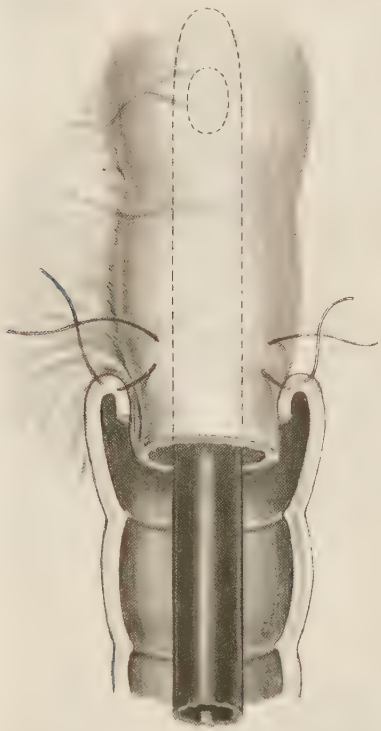

Fig. 1303.—Method of Resection and Anastomosis with Invagination. When anastomosis is made between sigmoid and rectum a tube is left in the bowel to prevent distention.

the ileum is buried with a purse-string suture, and the ileum is brought up and united to the colon by a lateral anastomosis 5 or 6 cm. (2 or 2½ inches) from the end of the stump of the colon.

Instead of ligating the bowels, they may be clamped in two places and cut between the clamps. The male half of an anastomosis button may be fixed in the end of the ileum, and the female half inserted into the lumen of the colon. The end of the colon may then be closed by two rows of sutures, and the button manipulated into position and an opening cut for it in one of the longitudinal bands of the bowel about 5 or 6 cm. from the end. This

may then be united with the ileum, making an end-to-side anastomosis (see Anastomosis with Button, page 667). Or an end-to-end anastomosis may be done. The peritoneum should be sewed over the raw surface in the back of the abdomen.

To prevent obstruction to the passage of gas is a most important consideration in connection with these operations on the colon. The great danger is peritonitis from yielding of the sutures because of gas distention of the bowel, which is apt to be pronounced between the fourth and sixth days. To obviate this, after resection such as is described above, the stump of the colon is brought up to the anterior abdominal wound by a couple of silkworm-gut sutures which hold the wound at the closed end of the bowel, against the rectus muscle. The parietal peritoneum is not permitted to intervene. The ends of the purse-string suture should be left long and lie free in the wound

Fig. 1304.—Safety Operation to Insure against Obstruction after Resection of Colon.

The end of the bowel has been closed with a purse-string suture. Two sutures are passed on either side of this and through the abdominal wall to hold the place of closure against the abdominal wound. The ends of the purse-string suture are brought out through the wound to guarantee drainage, as suggested by Mayo.

as a guide. A strip of gauze is passed down to the puckered bowel wound (Fig. 1304). This gives a communication to the bowel through the abdominal wall. The ends of the purse-string suture lie beside the gauze and project beyond the skin. The two sutures which hold the bowel against the abdominal wall are left long and are removed at the end of seven days. If the colon becomes distended with gas, it is a simple matter to withdraw the gauze, and pass a trocar and canula or a grooved director down into the colon along the purse-string sutures, and relieve the distention. Mayo has emphasized the importance of this procedure.

Another method of accomplishing the same result is to make a lateral anastomosis about 10 cm. (4 inches) from the end of the ileum. The stump of the ileum is then brought up to the abdominal wound and fixed with a tube in it. After the enterostomy opening has proved its patency and gas distention has

subsided, the fistula may be allowed to close. If the above anastomosis can not be made without great tension, the ileum may be connected with the sigmoid, and a tube passed through the rectum and fixed in such a position that its upper end is above the anastomosis (Fig. 1305).

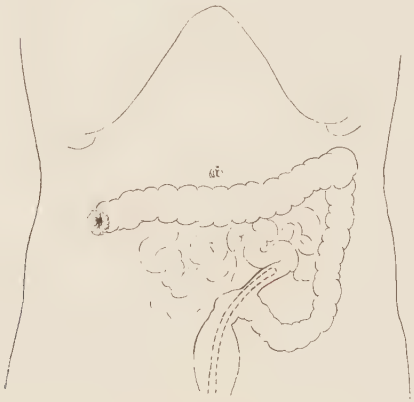

Fig. 1305.—Anastomosis between Ileum and Sigmoid.

Note rectal drainage tube extending into ileum. This prevents gas retention and dilatation of the bowel. The cecum and ascending colon have been resected. The stump of the colon at the hepatic flexure is brought out through a small opening in the abdominal wall.

If the colon is not removed, but only an ileosigmoidostomy done, the distal stump of the ileum may also be brought out through a right iliac opening and used for irrigation purposes as in appendicostomy. It is possible in this short-

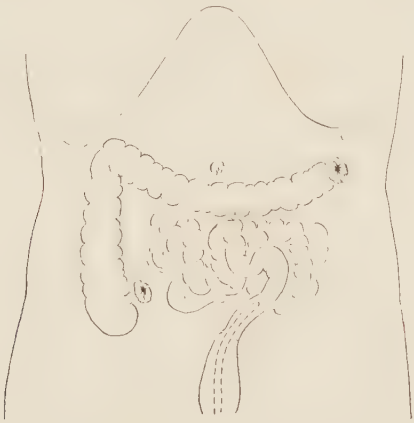

Fig. 1306.—Anastomosis between Ileum and Sigmoid with Rectal Drainage Tube Passing above Anastomosis.

The stump of the ileum is brought out through a wound in the lower right abdomen; the stump of the colon is brought out at a small wound in the upper left abdomen; the descending colon is resected.

circuiting operation to divide the sigmoid or upper rectum and do an end-to-end anastomosis with the ileum. The two ends of the excluded bowel are then brought out at the abdominal wall, permitting preservation of the

omentum, and providing means for through-and-through cleansing of the colon (see Intestinal Exclusion, page 677).

After excision of descending colon, the ileum may be united with the distal stump, and the two ends of the colon connected with the surface by two openings through the abdominal wall (Fig. 1306).

The transverse colon should not be sacrificed unless absolutely imperative, because by so doing the omentum is often either damaged or lost. Removal of the omentum is highly undesirable, as it serves an important function in distributing heat to the bowels, in equalizing the circulation, in preventing the spread of peritonitis, and in safeguarding the viscera from mechanical injury. When it is removed, the bowels tend to become matted together by adhesions.

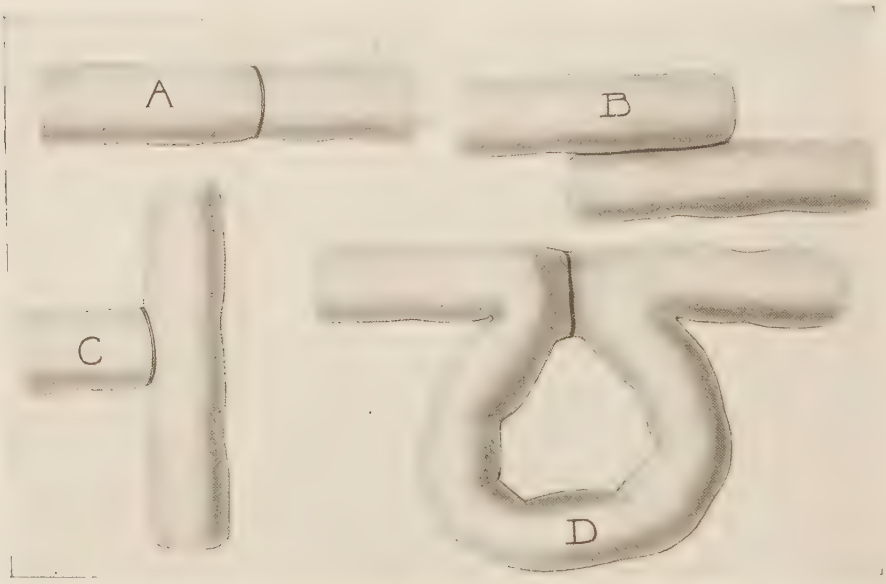

FIG. 1307.—DIAGRAMS OF INTESTINAL ANASTOMOSIS.

A, End-to-end anastomosis; *B*, lateral anastomosis; *C*, lateral implantation by end-to-side anastomosis; *D*, lateral loop anastomosis for intestinal exclusion or short circuiting.

For *resecting the transverse colon with preservation of the omentum*, J. E. Summers (Annals of Surg., September, 1917) proceeded as follows: The bowel is held taut. The omentum is lifted up, and with a straight narrow knife the peritoneum is nicked along the line of junction of the under surface of the omentum and the upper surface of the colon. With a sponge the omentum is forced upward from the transverse mesocolon to the lower border of the stomach, exposing but not injuring the mesenteric blood-vessels. The colon is then resected in the usual manner by view from above of the mesenteric vessels. After the anastomosis is made the omentum is sewed over the place of bowel union. This operation serves the two purposes of preserving the omentum and protecting the line of anastomosis.

Intestinal Anastomosis (Entero-enterostomy).—There are many forms of intestinal anastomosis. In general they fall under the following methods: end-to-end anastomosis, lateral anastomosis, intestinal exclusion or short-circuiting, and intestinal implantation or end-to-side anastomosis (Fig. 1307).

When end-to-end anastomosis is to be done between two tubes of unequal size, the larger may be made smaller by cutting out a V-shaped piece opposite the mesentery and sewing the notch together; or the smaller may be made larger by cutting it obliquely instead of at right angles, or by making a longitudinal cut in its margin (Fig. 1308). Instead of end-to-end anastomosis in such cases, the end of each may be closed and a lateral anastomosis done. Anastomosis should not be done with an upper bowel segment that is much distended. The bowel must not have lost its power to contract. If it has, a higher operation or some other procedure should be undertaken.

It is always desirable that in preparing the bowel for end-to-end suture the bowel be cut obliquely and not at right angles, so that the mesenteric side is longer than the side opposite the mesentery. This is to insure better blood supply to the distal side and to make the lumen larger at the anasto-

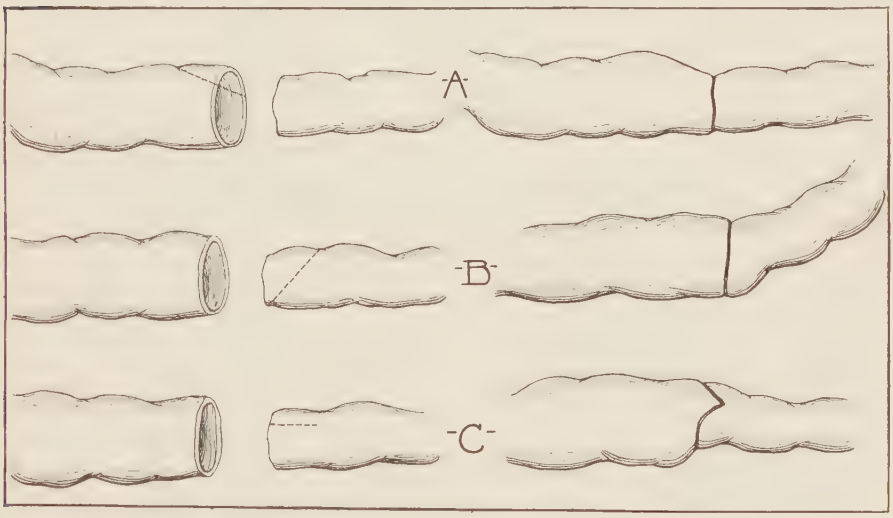

FIG. 1308.—METHODS OF END-TO-END ANASTOMOSIS IN CASES IN WHICH ONE SEGMENT OF BOWEL IS LARGER THAN THE OTHER.

A, The larger segment is made smaller by removing a wedge of bowel wall.
B, The smaller segment is cut obliquely thus increasing the size of the end opening.
C, The smaller segment is cut into longitudinally to increase its calibre.

mosis. If the obliquity is 45 degrees, an angulation of 90 degrees, or a right angle is formed, after the anastomosis is made. Experience has showed that there is no objection to this, although it will rarely be necessary to make so great an obliquity in the section of the bowel. Half of this obliquity usually suffices (see page 640).

Simple end-to-end anastomosis begins with the closure of the mesenteric angle. This is done as follows: A suture 30 cm. (12 inches) long, with a straight needle is taken in hand. The needle is passed from within the bowel, being entered in the mucous membrane a little more than 3 mm. ($\frac{1}{8}$ inch) from the edge, and passed into the connective tissue of the mesenteric angle, and thence out through the peritoneum, emerging about 1.5 mm. ($\frac{1}{16}$ inch) from the edge, in the line where the peritoneum is reflected from the mesentery to the bowel. It then enters the peritoneum and mucous membrane of the opposite segment in just the reverse line, passing into the mucous membrane again and repeating its course on the other side of the mesentery, to enter the

lumen of the bowel whence it started. The two ends are then tied and cut. The transverse suture loop inside of each bowel end is about 4.5 mm. (3/16 inch) long (Fig. 1309).

The two bowel ends are folded back upon the mesentery, and a suture introduced at one side of the mesenteric angle, apposing serosa to serosa. It is tied on the serosa side, and its end left long to serve as the first traction guide. Another suture is then introduced through all the coats, the same distance from the mesenteric angle as the previous suture, apposing serosa to serosa. It is not tied, but the ends are left long, to be used as a second traction guide. The distance between the first and second guides should be about one-third of the circumference of the bowel.

The two guides are then used for gentle traction in the hands of an assistant, bringing the wound edges in a line. The needle end of the first guide is employed to make a continuous suture between the two (Fig. 1310). When the second traction guide is reached, a third traction guide is introduced, in a manner similar to the second, midway between the two first guides.

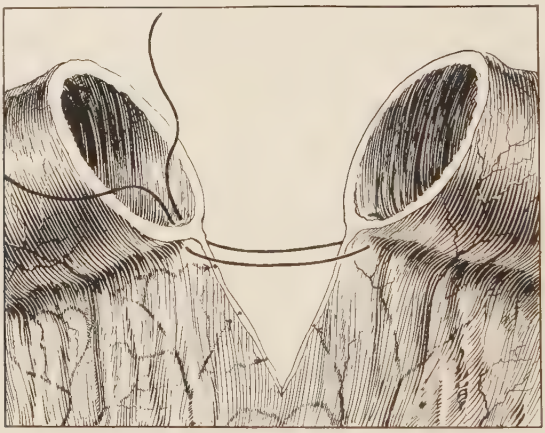

Fig. 1309.—First Stitch in End-to-end Anastomosis.
This is the mattress mesenteric stitch.

The stitch is then continued between the second and third guides. The second guide is then removed, and the last third of the suture completed by using the first and second guides for traction alignment. The last part of this suture, of course, cannot be drawn tightly until all of the stitches have been introduced (Fig. 1311). The last stitch ends on the outside, and the suture is tied to the end left as the first traction guide. The third guide is removed and the ends of the last knot cut. Some surgeons prefer to tie the first traction suture on the inside, and end the suture by a knot which sinks into the lumen of the bowel as the last suture is tied.

In applying such a continuous suture, it should be interrupted at short intervals or several separate sutures used. This is in order to prevent unequal tightening or relaxation of the suture. This inner stitch controls bleeding and prevents leakage.

The more important stitch is the second or outer tier. This is aimed to give broad serous apposition and still further strengthen the union. It should not take in too much tissue lest the circle of inverted bowel encroach too much upon the lumen and cause some obstruction or conduce to intus-

susception. It should embrace all of the coats except the mucous membrane. Some surgeons employ parallel continuous stitch (Cushing) for this, others the simple right-angle stitch (Lembert), and others the right-angle mattress

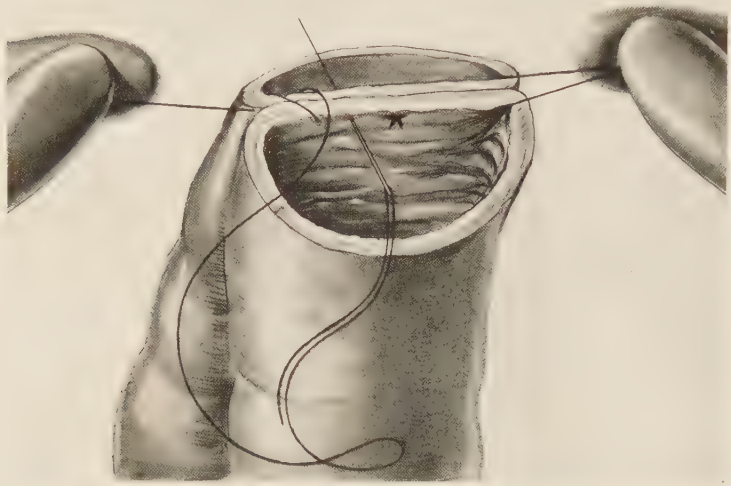

Fig. 1310.—Suturing First Third in End-to-end Anastomosis.

The mattress mesenteric stitch has been tied. The guide sutures are held by an assistant. One guide is the tied end of the first continuous suture; the other will become the second continuous suture.

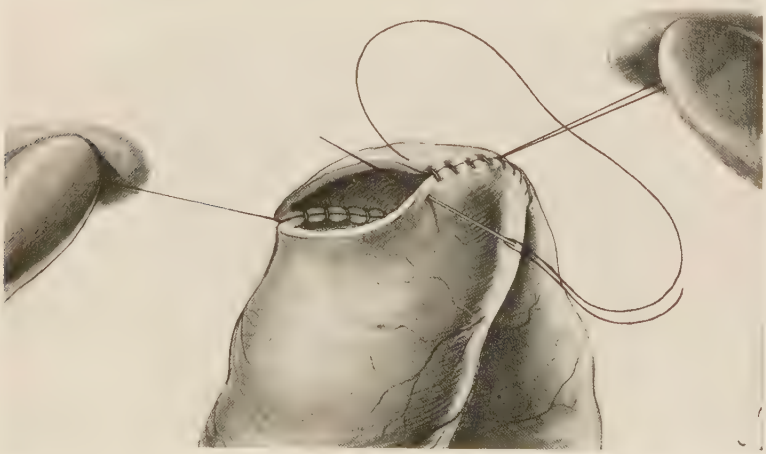

Fig. 1311.—Suturing Last Third of Circumference in End-to-end Anastomosis.

The right hand guide is opposite the mesentery; the left hand guide is midway between it and the mesentery and is the end of the first continuous suture.

stitch (Halsted). The continuous suture is used when haste is necessary, otherwise the interrupted or interrupted continuous stitch is to be preferred.

The first serosa interrupted stitch is placed directly opposite the mesen-

teric attachment. One is placed on either side midway between this and the mesentery. The ends of these are left long to serve as guides. The intervals between these guides are sutured as for ordinary enterorrhaphy (Fig. 1312).

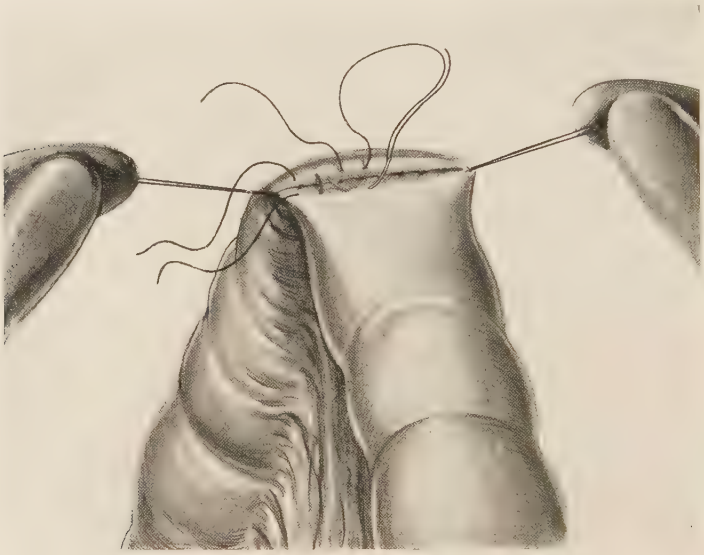

Fig. 1312.—Placing the Serosa Layer of Sutures.
The first layer of sutures has been placed; guides have been inserted; and the interrupted parallel mattress sutures are being applied.

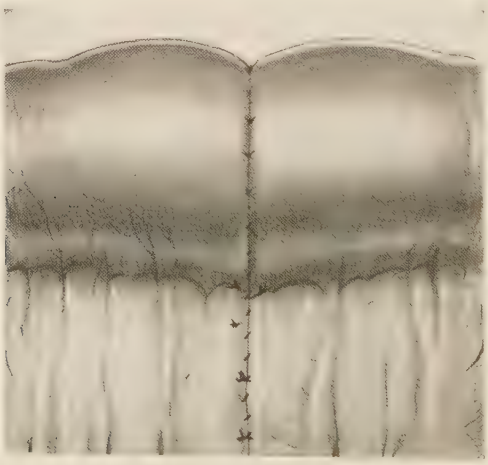

Fig. 1313.—End-to-end Anastomosis Completed.
The caliber of the bowel is increased at the place of anastomosis by the obliquity of its division.

After completing the second row, instruments are removed, the mesenteric wound is closed with a few interrupted sutures (Fig. 1313), the bowel replaced, the omentum drawn down, and the abdomen closed.

There are many modifications of this method of suture. If time must be

economized, the serosa layer of sutures may be omitted entirely. The inner suture may be interrupted and the outer suture continuous.

End-to-end anastomosis with mattress sutures (Connell) uses but one row of sutures and all knots are tied inside of the bowel. It is done as follows: The mesenteric stitch is introduced as in the above-described operation. A similar stitch is placed on either side of the first one, the inner punctures of these two stitches being placed so close to the first that they pass into the mesenteric angle (Figs. 1309 and 1310). These are tied. The ends of the outer ones are left long to be used as guides. A similar mattress suture is placed at a point represented by one-third of the distance on the circum-

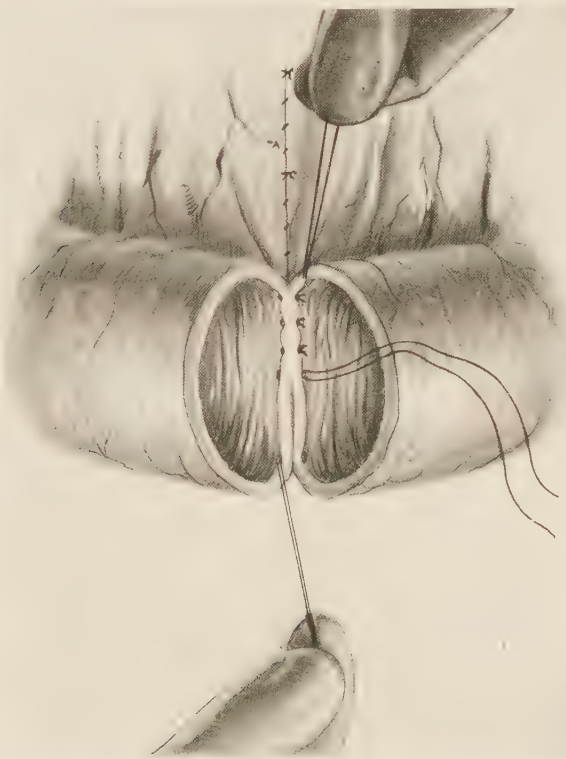

FIG. 1314.—END-TO-END MATTRESS SUTURE CONTINUED.

The suturing is progressing between the two guides. The lower guide is one of the first three mesenteric sutures. The upper guide is a mattress suture, with the ends left long, placed one-third of the distance from the mesentery.

ference of the bowel measured from the mesentery. This is tied and the ends left long to be used as the second guide. The first guide should be on the side opposite the mesentery from the second guide. Gentle traction on these two guides brings into alignment the edges to be joined, and perforating mattress sutures are applied and tied (Fig. 1314).

The sutures are about 3 mm. (⅛ inch) from the cut edge of the bowel, a little less than this distance apart, and each suture makes a span a little greater than this. If bleeding is observed between any sutures after they have been tied another mattress should be placed to control it.

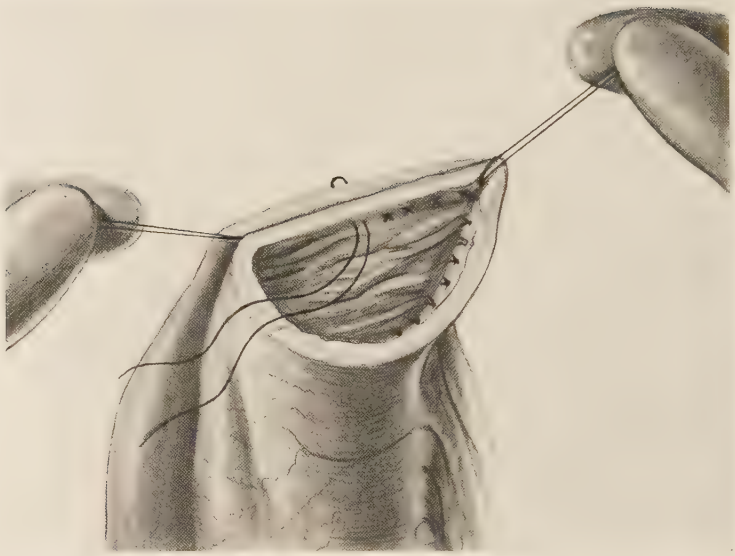

FIG. 1315.—END-TO-END MATTRESS SUTURE CONTINUED.

Sutures are being applied to the second third of the circumference. Two mattress sutures, with the ends left long, serve as guides. The knots are all tied on the mucous membrane surface.



FIG. 1316.—END-TO-END MATTRESS SUTURE.

Placing last sutures. The bowel has been inverted. The last stitches are applied in inverted form from the serosa side. When the knot is tied on the mucous membrane side it continues the inversion. The last two sutures remain yet to be inserted.

When the first third of the circumference has been sutured the ends of the first mattress guide are cut off. Another mattress guide is introduced and tied midway between the two first guides on the ununited border. The ends of the second guide are brought forward under this last one, and by pulling these two taut the bowel edges are made prominent for suturing

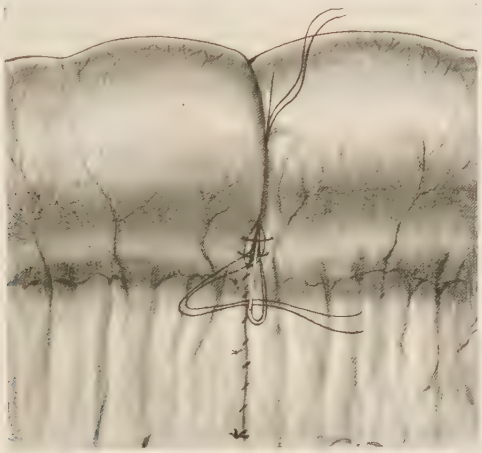

FIG. 1317.—END-TO-END MATTRESS SUTURE.
Method of inserting needle for tying last knot. After the knot is tied the ends of the thread are caught in the loop of the threaded needle and drawn inside of the bowel.

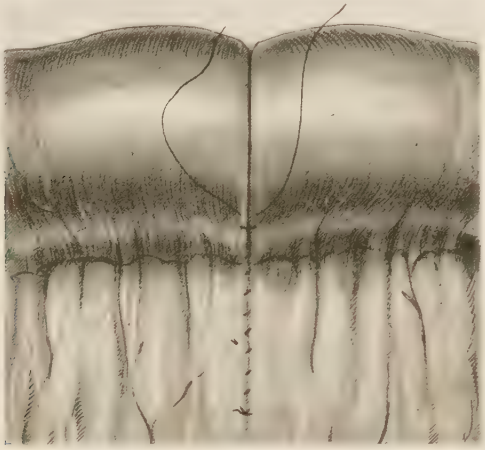

FIG. 1318.—END-TO-END ANASTOMOSIS.
Inserting parallel mattress serosa stitch instead of last through-and-through suture.

(Fig. 1315). When the suture has been completed between the second and third guides, the ends of the second one are cut off, and the gut inverted into position.

The last third of the circumference now remains to be sewed. This is between the mesentery and third traction suture. This part of the operation is less easy than the first two-thirds. The needle is passed in and out through

each wall separately making four transfixions for each suture, beginning and ending in the mucous membrane. The ends are left untied until all have been passed (Fig. 1316). Then all are tied excepting the last one. Gould has an assistant hold the bowel across an index-finger. The long ends of each tied suture are used for traction while the next stitch is being introduced.

The tying of the last suture is not a simple matter. Connell introduces into the space between two sutures at an opposite point, a straight needle, shank first, threaded with silk. The needle is made to emerge at the unclosed space. The ends of the suture are threaded into the loop between the silk thread and the needle and drawn out through the space into which the needle was introduced. They are tied, cut off, and allowed to retract into the lumen of the bowel (Fig. 1317). Instead of this, the last mattress suture may be omitted, and the opening closed with a serosa parallel mattress stitch (Cushing) (Fig. 1318).

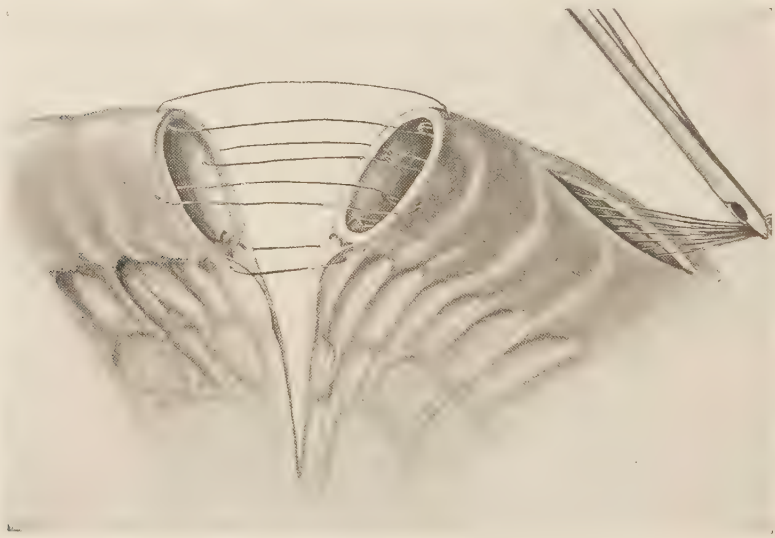

Fig. 1319.—Maunsell's Invagination Method of End-to-end Anastomosis. Traction sutures have been applied and the ends brought out through an antimesenteric incision.

End-to-end anastomosis by the invagination method (Maunsell) is characterized by a temporary opening made through the wall of the gut. After performing a resection of the bowel, without removing a segment of mesentery, two traction sutures are introduced. One is placed at the mesenteric side and the other directly opposite it. The mesenteric suture should be passed in the same manner as that described in the previous operations. The opposite suture is passed so that its knot falls within the lumen of the bowel, penetrates all coats of the bowel, is loosely knotted, and the ends left long. An opening is now made in the larger bowel segment, in its long axis, opposite the mesenteric attachment. This opening should be about 2.5 cm. (1 inch) from the end. Its size should depend upon the size of the gut to be invaginated through it. For the small intestine it will be about 4 cm. (1½ inches) long (Fig. 1319).

A pair of forceps are passed into the bowel through this opening and caused to grasp the two traction sutures. They are pulled out through the

opening, bringing with them the two bowel ends. The hand assists this invagination process. The opening should be sufficiently large to accommodate it without undue strain upon the traction sutures. The ends are brought out far enough to allow of easy suturing. The peritoneal surfaces of the ends of the two segments are made to lie in contact by this means. The two bowel ends are adjusted early, and a long straight needle, threaded with silk or chromicized catgut (Maunsell used horsehair), is caused to transfix all the coats of the apposed bowel ends midway between the traction sutures, about 5 mm. ($^3/_{16}$ inch) from the free edges. The needle is drawn through four thicknesses of bowel, and the thread caught up in the middle and cut. Each half is then tied over the two bowel thicknesses through which it passes. Twenty sutures may thus be introduced with ten thrusts of the needle (Fig. 1320).

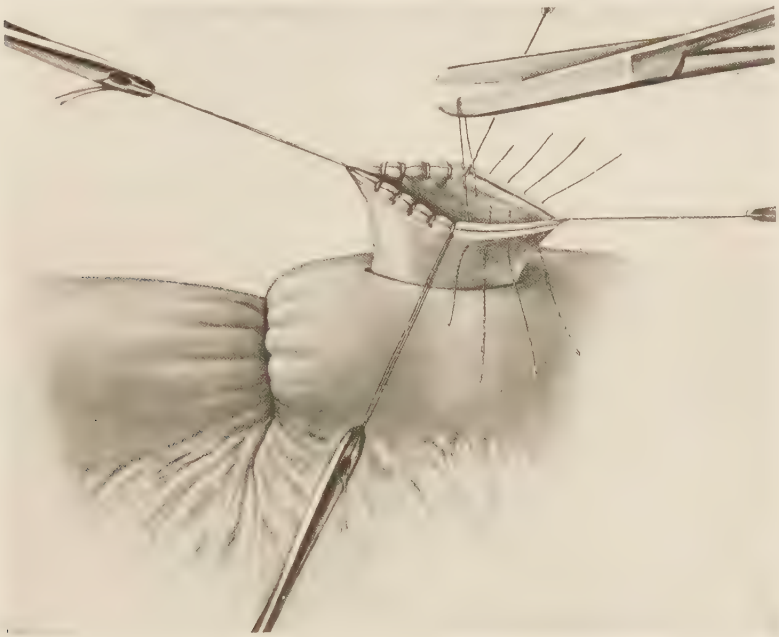

FIG. 1320.—INVAGINATION METHOD OF END-TO-END ANASTOMOSIS.
The ends of the bowel have been drawn through the antimesenteric opening by the traction sutures. Sutures have been passed and are in process of being tied.

The traction guide sutures may then be tied down or removed. The invagination is reduced by careful traction and manipulation. The mesentery is sutured. The longitudinal opening is then closed by continuous or interrupted sutures. The parallel continuous stitch (Cushing) is well adapted to this (see Wounds of Intestine, page 566; Enterorrhaphy, page 628). Care should be taken in reducing the invagination not to put any strain on the suture line. As soon as possible the mesentery should be sutured. It is done with care that all slack is taken up at the enteromesenteric junction so that traction strain shall fall on the mesentery rather than the bowel.

In this operation the sutures may be tied as each is inserted or they may all be inserted before tying. Some surgeons after reducing the invagination,

place a parallel continuous stitch (Cushing) through the musculoserous coats (Fig. 1321).

End-to-end anastomosis of segments of unequal size by the invagination method differs from the above operation first in reducing the size of the larger end. Bickham (Operative Surgery) proceeded as follows: The mesenteric

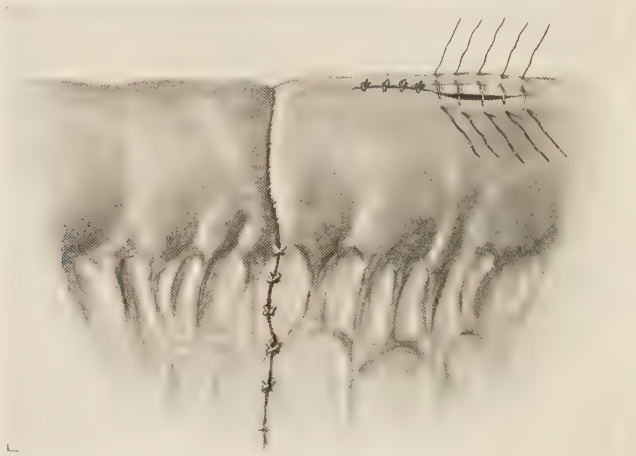

Fig. 1321.—Invagination Method of End-to-end Anastomosis.
The invagination has been reduced, the mesentery sewed, and the bowel opening is being closed.

traction suture is introduced as above described. The second traction suture is introduced also as that in the above operation, excepting that while it is passed opposite to the mesentery in the small segment, in the larger segment it is passed at a distance from the mesenteric attachment



Fig. 1322.—Invagination Method of End-to-end Anastomosis with Aid of Ring.
The bowel has been tied to the ring or hollow bobbin by means of two strong ligatures and an elastic band.

equal to the diameter of the smaller segment. A third traction suture is introduced through the larger segment alone at a point opposite the mesentery. The opening is then made in the larger bowel segment as above described, and the three traction sutures drawn through it.

The ends are then invaginated, the smaller being surrounded by the larger, and the sutures introduced and tied, beginning at the mesenteric side. This should proceed evenly on either side. As the side opposite the mesentery

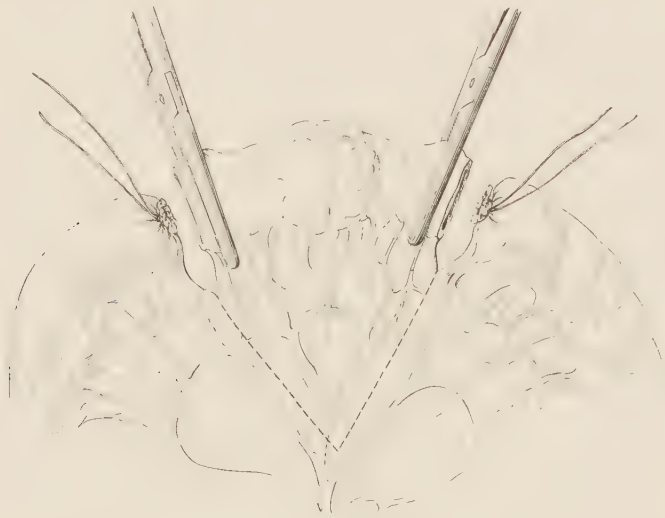

FIG. 1323.—ANASTOMOSIS BY THE CIRCULAR OCCLUSION METHOD.
The bowel is to be tied tightly on either side of the disease with strong ligatures and the ends left long. Clamps are applied on the segment to be removed between the two ligatures. The bowel is cut between the ligature and the clamp.

is reached, it will be apparent how much excess of the larger segment is to be disposed of. This should be removed as a triangle. The V-shaped gap should be sutured serosa-to-serosa by a continuous over-and-over stitch.

FIG. 1324.—ANASTOMOSIS BY THE CIRCULAR OCCLUSION METHOD.
The two tied ends are brought together and anastomosed by suture.

Care should be taken that the triangle removed is not so great as to give inadequate coaptation in closing the space; and in closing the space care

should be taken that the closure is brought snugly down to the caliber of the smaller segment. The suture is then completed, the invagination reduced, and the longitudinal wound closed.

Invagination method with aid of a ring or bobbin was devised by Ullmann as a modification of the method of Maunsell. The ring or bobbin may be of absorbable material (decalcified bone, carrot or magnesium) or of slowly absorbable or non-absorbable metal. The ring is inserted into the opening of the two bowel ends after they have been brought out through the anti-mesenteric wound. A heavy silk thread is tied around the bowel ends, sinking into a groove in the ring. A rubber elastic band may be added to this, and the bowel is then disinvaginated. No anastomosis sutures are required. The bowel ends beyond the ligature necrose and the ring if insoluble, is passed by the rectum in about a week (Fig. 1322).

Anastomosis by the circular occlusion method has never met with general acceptance. In 1893, I tried it repeatedly upon the cadaver and then in the living. It has a field of usefulness in the small intestine. The bowel is

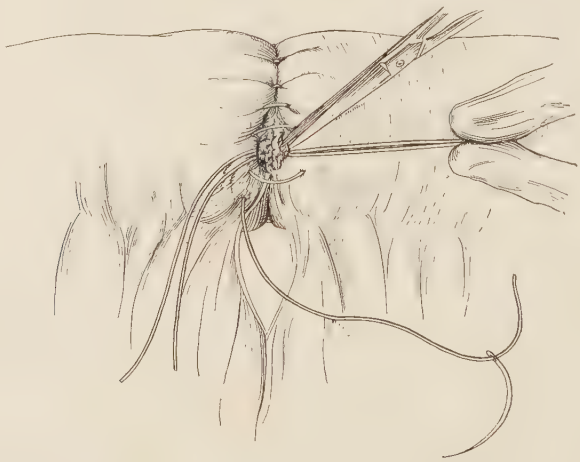

Fig. 1325.—Anastomosis by the Circular Occlusion Method.
The tied ends of bowel are anastomosed. Before the last suture is tied the circular tie-strings are cut and removed.

ligated on either side of the disease by a temporary ligature of strong silk. This is passed through the mesentery close to the bowel. It is tied very tightly with a firm square knot, the ends left long, and knotted for identification. The diseased segment is then clamped and cut out with the mesentery (Fig. 1323). The division of the bowel is made about 1.5 mm. (1/16 inch) from the ligature. The mucous membrane is cauterized with the actual cautery or with phenol followed by alcohol (Fig. 1324).

The two stumps are then brought together, and a musculo-serous suture applied to unite them. The first suture should be a mattress suture closing the mesenteric angle. This is the most important and weakest place in the anastomosis. Three other stay sutures should be placed at equal distances connecting the two segments. The suture for completing the anastomosis should be a mattress interlocking stitch best introduced with a curved needle (Fig. 1325).

Before tying the last two sutures, which should close the space through which the ends of the occlusion ligatures emerge, each of these ligatures is

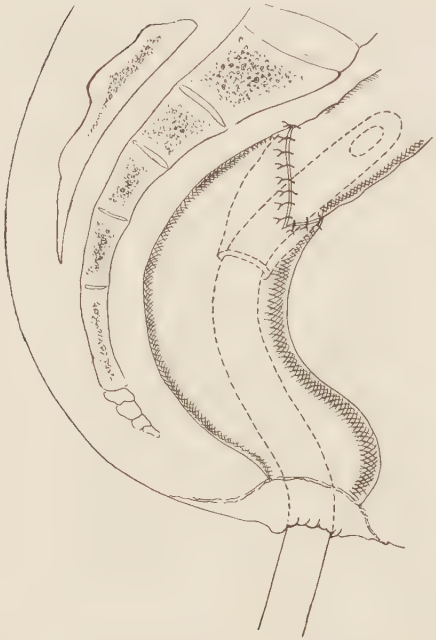

FIG. 1326.—ANASTOMOSIS BY SIMPLE INVAGINATION.

The stump of the colon has been invaginated into the rectum. To increase the size of the latter a longitudinal incision has been made. Sutures are applied on the serosa side. A large tube is passed above the anastomosis and fixed in the rectum.

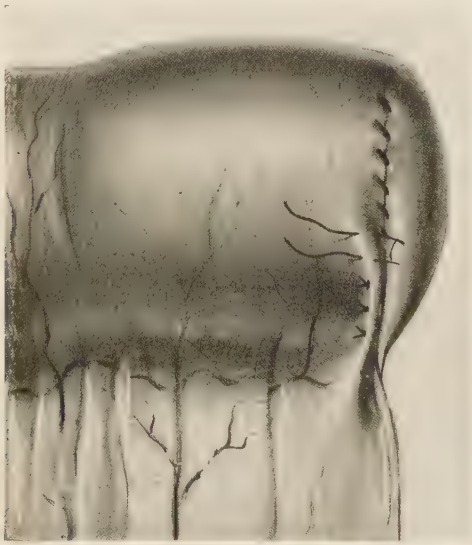

FIG. 1327.—CLOSING END OF INTESTINE.

A continuous through-and-through suture has been applied. The overlying seromuscular suture is in process of application.

drawn up and cut. This is done with narrow pointed scissors, or with a cataract knife or tenotome. If necessary, the ligature may be caught up with a tenaculum. The distal ligature should be cut first and then the proximal one. Each should be pulled out, demonstrating that the constriction has



Fig. 1328.—Purse-string Closure of End of Bowel.

been relieved. The remaining sutures are then tied, and the mesentery sutured.

This operation, as done by F. B. Walker (Jour. Am. Med. Assoc., Aug. 15, 1908, vol. 51, No. 7, page 546), was performed with a purse-string

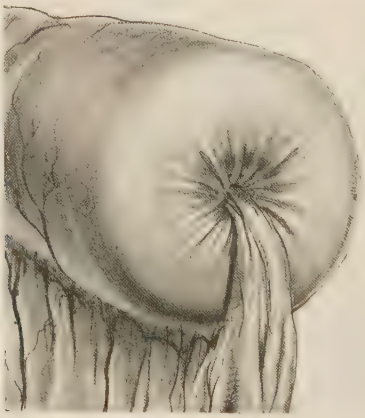

Fig. 1329.—Closure of End of Bowel by Simple Ligature and Purse-string Suture. The bowel end has been tied, the mucosa of the stump sterilized and buried as in appendectomy.

ligature, tied in a bow-knot. The ends emerge, and by pulling, the knot is untied and the ligature pulled out, after applying the apposition suture. The parallel continuous stitch (Cushing) is used. The same principle is applied by Walker in making lateral anastomosis. A purse-string suture

is inserted and the opening in the bowel or stomach is made inside of it. The anastomosis is then made, and the purse-string is pulled out. The first half of the anastomosis suture is inserted before the openings are cut.

These methods have the disadvantage that a redundant free edge of bowel is left on each stump. These free ends hang as a constricting flap in the lumen of the bowel and increase the amount of scar tissue.

Anastomosis by simple invagination, with mucosa to peritoneum may be done with the rectum and in rectosigmoid anastomosis. The upper segment is simply invaginated into the lower segment for a distance of 2.5 to 5 cm. (1 or 2 inches). A large rubber tube is placed in the bowel, one end above the anastomosis and the other end in the rectum or projecting through the anus (Fig. 1326). The upper end of the rectum is sewed to the outer layers of the sigmoid. Ultimately the mucous and serous coats become

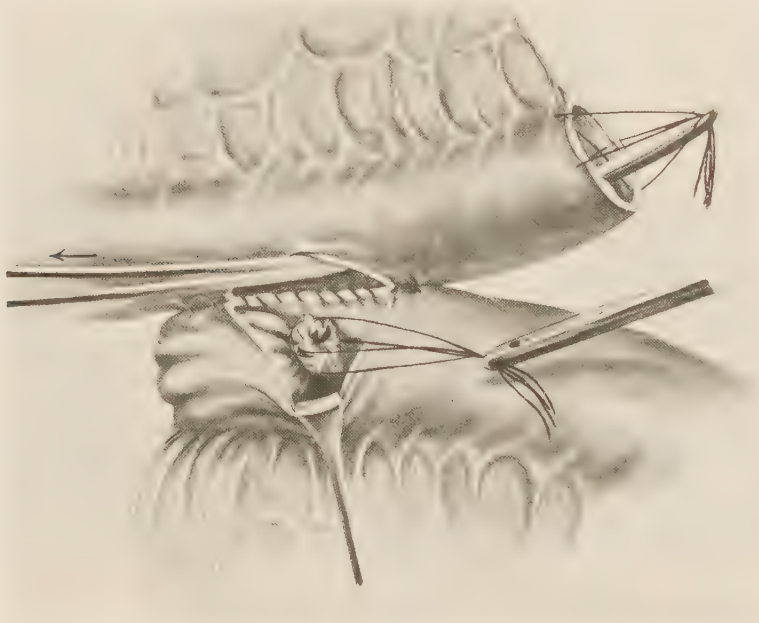

Fig. 1329*a*.—Closure of Bowel Ends by Ligation Inside of the Bowel (Method of Maunsell.)

The first half of the lateral anastomosis has been done, and the lateral bowel openings made. One stump has been inverted and tied; the other is about to be inverted by drawing through the guide ligatures with a long clamp.

adherent. If the sigmoid end has not been incised longitudinally, it may require to be cut later with scissors through the proctoscope to relieve circular contraction.

Lateral anastomosis may be employed in the stead of end-to-end anastomosis or it may be done to accomplish short-circuiting or intestinal occlusion. As a substitute for the end-to-end operation, it possesses the advantages that (1) it has simplicity of application in some respects; (2) the hazardous mesenteric triangle is not involved; (3) the opening can be made sufficiently large to allow for contraction, in contrast to the end-to-end method in which the bowel is often narrowed by the operation; and (4) a considerable part of the anastomosing suture can be introduced before the bowel is opened.

When done in the stead of end-to-end union, the closure of the ends of the bowel must first be done. *The formation of a blind end* may be accomplished by any one of several different methods. The most useful are the following:

1. The bowel is divided between two clamps. The end to be closed is then sutured with an over-and-over suture through all of its coats bringing the wound edges together or serosa to serosa. This suture begins opposite the mesenteric attachment and ends at the mesentery. Its object is to compress the blood-vessels. A second suture begins opposite the mesentery and buries the first line of sutures. This should be the parallel continuous stitch (Cushing), embracing all but the mucosa (Fig. 1327).

2. An angiotribe is used as the clamp on the end to be closed. This occludes the vessels. The clamp is removed, the bowel is divided along the crushed strip, and the crushed edge buried by a musculoserosa suture as above.

3. Instead of using the angiotribe, hemostasis may be secured by passing the thermocautery along the cut edge. This insures asepticity.

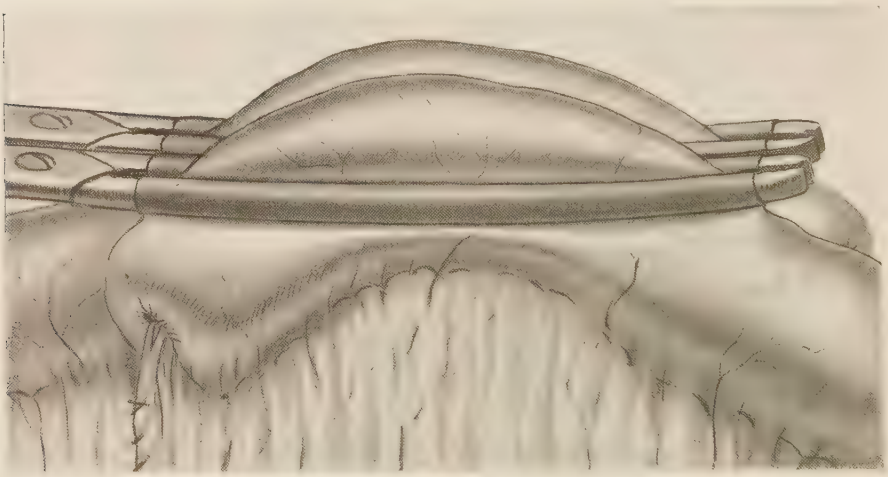

Fig. 1330.—Lateral Intestinal Anastomosis.

The ends of the bowel have been closed. The protected clamps grasp the bowel segments and place them side-by-side. The edges of the mesentery are sewed to the mesenteric surface.

4. The purse-string method is particularly useful in the small intestine. A purse-string suture is passed around the bowel, penetrating only the outer coats. A clamp then grasps the bowel at a right angle, and the intestine is cut across about 6 mm. (¼ inch) from the clamp. To control hemorrhage the free end is sewed over-and-over with a running stitch passing through all the coats. The clamp is then taken off, the sewed end inverted, and the purse-string suture tightened and tied (Fig. 1328).

5. Ligation of the bowel was recommended by H. Lilienthal (Am. Jour. of Surgery, March, 1909). He applied it to both the small and large intestine. He insists that the ligature should be tied tightly enough to crush the mucosa, and that the mucous membrane remaining in the stump be sterilized with pure phenol. A catgut ligature, a short stump, and the addition of a purse-string suture to bury it, as in the treatment of the stump of the vermiform appendix, should make this a highly satisfactory operation (Fig. 1329). Pleth (Am. Jour. Surg., July, 1909) applied the angiotribe

to the bowel and then tied the bowel in this line with a linen thread. It is not inverted. Moynihan crushed a line with the angiotribe, ligated with catgut in this line and cut beyond. He then buries the stump with a purse-string suture. This is the most effective method.

6. Ligation inside of the bowel is done by the method of Maunsell. The first half of the lateral anastomosis is done, the bowel opened, and then the bowel ends are inverted, pulled into the opening, ligated and replaced. This leaves the ligature inside of the bowel, and apposes serosa to serosa (Fig. 1329*a*).

The *technic of lateral anastomosis* is simple. The bowel is occluded above and below the place of anastomosis. Each bowel end is grasped by a clamp in such a way as to include a lateral segment, about 9 cm. (3½ inches) long and representing about half of the circumference of the gut. The

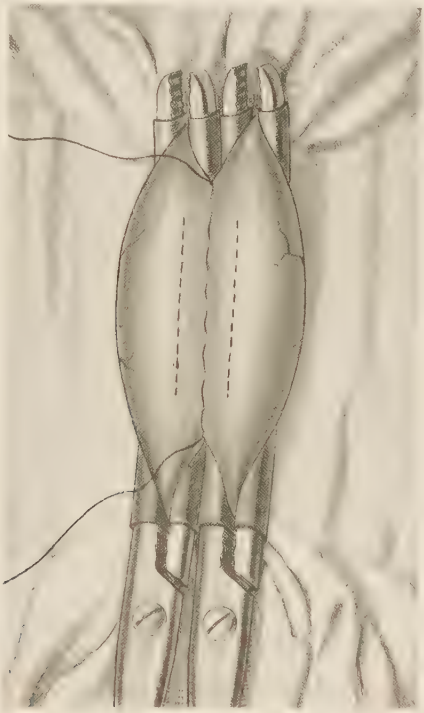

FIG. 1331.—LATERAL ANASTOMOSIS.
The serosa-muscularis suture has been applied. Dotted lines show place of bowel incisions

infolded end should not be grasped. These two segments are laid side-by-side, the stumps in opposite directions (Fig. 1330). The clamps should not cause undue contusion. The jaws should be covered with rubber or cloth and should lie evenly together. Two layers of sutures are to be applied. A curved needle that can be held in the fingers is used.

It is best to introduce the first half of the outer suture before opening the bowel. This is a continuous simple right-angle stitch of chromicized No. 0 catgut, penetrating serosa, muscularis and submucosa. Rather than miss the latter, the surgeon need not fear if the mucosa also is penetrated. It is placed longitudinally, about 6 mm. (¼ inch) from the antimesenteric aspect

of the bowel, and after tying, the ends are left long at each end of the suture (Fig. 1331). A needle is left on each of these ends, and they are covered with a towel for future use.

Each bowel is then incised longitudinally at its antimesenteric aspect: that is, 6 mm. (¼ inch) from the suture line and directly opposite the mesenteric attachment. The incisions should be about 6 mm. (¼ inch) shorter than the stitch which they parallel. Bleeding is prevented by the clamps. The inner suture is then inserted. It is a continuous simple right-angle stitch, uniting the cut borders throughout the whole circumference of the opening (Fig. 1332). The needle passes through all the walls of the gut. It passes from mucosa to serosa and from serosa to mucosa, and is tied inside of the bowel on the mucous membrane. No. 0 chromicized catgut is used

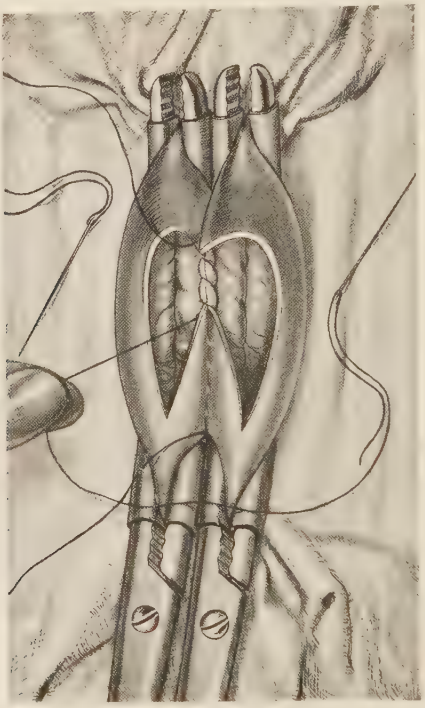

Fig. 1332.—Lateral Anastomosis.

The serosa-muscularis suture has been applied, the bowels incised, and the through-and-through suture is in process of application. One corner has been turned. Towels and gauze protect the environment.

with a needle on either end. The stitch is begun in the middle of the wound, the knot being tied in the middle of the thread, and then continued halfway around the circumference of the opening. When the middle of the side nearest the operator is reached, the needle on the other end is taken in hand and the opposite half sewed (Fig. 1333). This suture passes around both ends, and is tied on the side toward the operator. The mucosa should be inverted and not show along the suture line. The suture should be applied with such a degree of tightness as to close off the lumen of the bowel.

At this stage the clamps may be removed. The remainder of the outer stitch is now completed. One of the end needles which had been laid aside is

taken in hand and the suture continued around the end of the sutured opening at the same distance as before (Fig. 1334). This ends after rounding the corner, and the other needle is then used to complete the circumference of the suture. The two ends are tied and cut. The raw edges of the mesentery are caught by a few stitches to the flat surface of the mesentery upon which they lie (Fig. 1335).

Some surgeons do this operation with celluloid thread. This method may also be used for end-to-end anastomosis. When it is desired to secure more positive serosa-to-serosa apposition, the through-and-through suture may simply transfix the two walls with each thrust, passing back and forth leaving a loop on each mucosa, and not passing over the cut edges of the bowel.

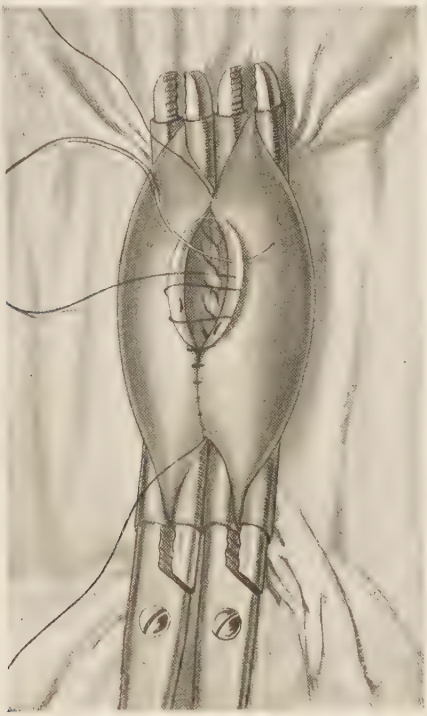

Fig. 1333.—Lateral Anastomosis.
Through-and-through suture continued. By placing the loop on the mucous membrane side, the inversion of the wound is insured.

A simple and easily extemporized *wooden clamp* for performing lateral anastomosis or gastroenterostomy, was devised by C. L. Gibson (Annals of Surg., May, 1915). It is made of the pieces of wood used as tongue-depressors. These are held together by elastic bands (Fig. 1336).

Lateral implantation (end-to-side anastomosis) may be done by any of the methods used for end-to-end or lateral anastomosis. After excisions in the ileocecal region, it has the advantage that the ileum may be implanted into the colon without the necessity of making another blind end. The simplest operation is that described above for lateral anastomosis. One bowel is clamped laterally and the other transversely. An opening is made in the first, as far as possible from the mesenteric border, and slightly longer than

the diameter of the afferent bowel. A through-and-through suture unites the wound edges circumferentially, and a musculoserosa suture is applied outside of this.

A. H. Gould devised an operation which obviates the danger of contracture of the opening ("Operations on the Intestines and Stomach"). The small intestine is closed by a clamp about 8 cm. (3 inches) from its end, and the large bowel by clamps some distance from the site of operation. The end of the small bowel to be implanted is split along its antimesenteric side for 1.25 to 2.5 cm (½ or 1 inch) (Fig. 1337). The projecting corners are cut off, leaving an oblique opening. The distal bowel is opened longitudinally

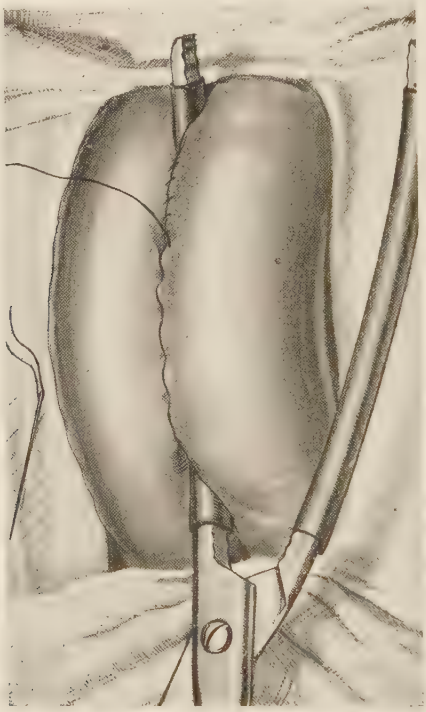

Fig. 1334.—Lateral Anastomosis.
The operation is about completed. A few stitches of the outer row remain yet to be taken. The clamps are loosened.

on its antimesenteric side for about 3.75 cm. (1½ inches). Guides are placed to invert the edges, and the mesenteric thread is united by a through-and-through suture (Fig. 1338). Other guides are placed and the suture is continued the same as that used in simple end-to-end anastomosis. For the seromuscular suture, which is the outer tier, an interrupted right-angle suture or the interrupted mattress stitch of Gould is used. A continuous mattress suture may be employed. The mesentery of the implanted bowel is sutured to the colon and the peritoneum beyond it.

Anastomosis with mechanical devices is employed less than formerly. These devices used were recommended by the additional speed which they contributed to the operation. Each possesses the disadvantage that it requires special knowledge and experience for its use, and complicates

the surgeon's armamentarium with one more instrument. These things have served an important function in the development of gastro-intestinal surgery, and rare occasions still arise when they may be of service.

Anastomosis with a button was perfected by J. B. Murphy. The instrument consists of two halves which when pressed together fasten by a spring



FIG. 1335.—LATERAL ANASTOMOSIS COMPLETED.
Section showing inside of bowel.

clutch. They are made both in round and oblong form (Fig. 1340). For end-to-end anastomosis a purse-string suture is placed in the ends to be joined. There are two ways of doing this: (1) A simple purse-string is applied in the outer coats before the bowel is opened. The bowel is then clamped in four places, and the resection done, 3 mm. (1/8 inch) from the



FIG. 1336.—ENTERO-ANASTOMOSIS CLAMPS EXTEMPORIZED FROM WOODEN SPATULA.

purse-string. Or (2) the resection is done and an over-and-over suture applied, passing with each stitch across the cut edge of the bowel. It is important that the suture in every case embrace the mesenteric angle by a stitch passed through the mesentery, redoubling upon itself and crossing in the midmesenteric line. Both of these stitches begin and end at the anti-

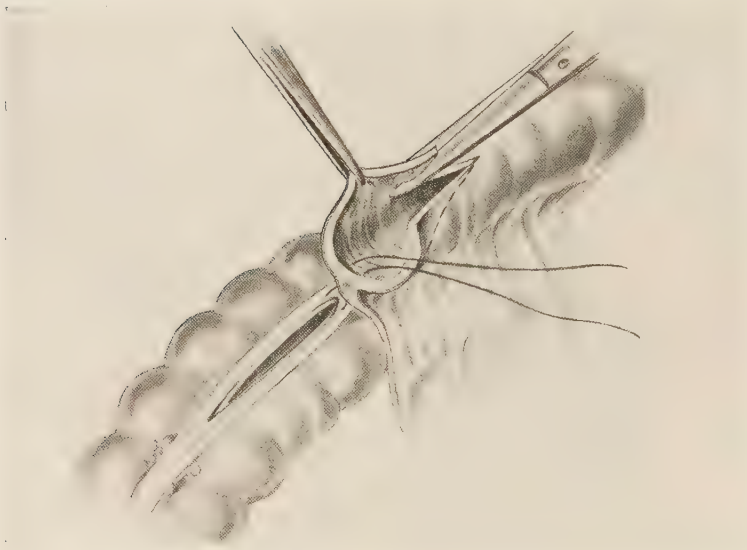

FIG. 1337.—END-TO-SIDE ANASTOMOSIS.
Operation of A. H. Gould. Showing first mattress stitch. Trimming off angles of bowel.



FIG. 1338.—END-TO-SIDE ANASTOMOSIS.
Operation of A. H. Gould. The corners of the smaller bowel have been cut off. The first mattress suture has been tied. Guides have been inserted to control the mesenteric third of the circumference, and the edges united by an over-and-over stitch. The third guide has been introduced.

mesenteric border. The first has the advantage that it can be put in without soiling the field of operation. This is an important point. It possesses the disadvantage that the mucosa is apt to roll out and unless it is trimmed off or pressed back may become engaged between the two serosa surfaces. The first method is more commonly used.



Fig. 1339.—End-to-side Anastomosis.
Operation of A. H. Gould. The outer layer of sutures has been applied.

The halves of the button are then grasped by the stem with forceps which are narrow so as not to bend the circle. The male button, the one with the smaller stem, is introduced into the proximal gut, and the female button into the distal gut, just far enough for the edges of the bowel to come down to the stem (Fig. 1341). The purse-string suture is then tied. Each half being fixed in a bowel end, the buttons are grasped through the bowel, the



Fig. 1340.—Anastomosis Buttons of Murphy.

forceps removed and the two halves pressed together. The mesentery is then sutured. A few interrupted musculoserosa sutures may be added (Fig. 1342) although not considered necessary. In this operation care should be taken that the button fits easily, that the pucker caused by the purse-string is evenly distributed, that the ends of the suture are cut short,

and that serosa is opposed to serosa as the parts come together. The button should have been examined and the clutch found to be effective. The surgeon should hold the two halves as an assistant removes the forceps,

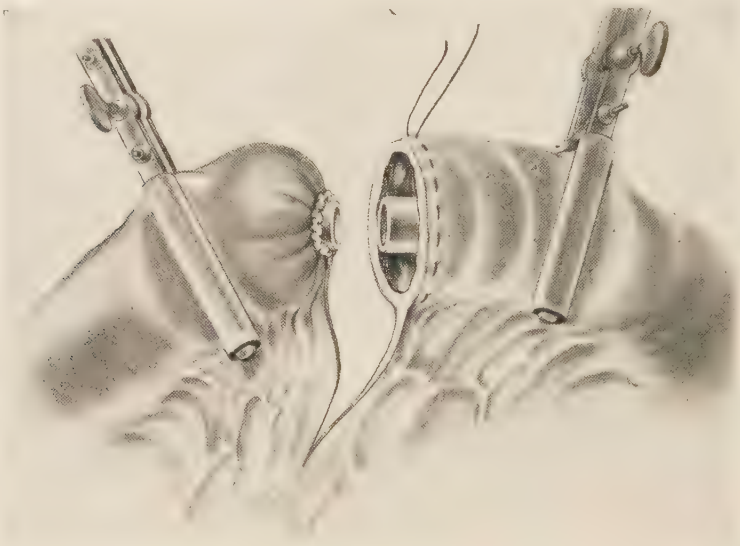

Fig. 1341.—End-to-end Anastomosis with Button.
The two halves of the button are placed in the bowel ends and each is held by a clamp. One purse-string has been tied down, the other is ready to be tied.

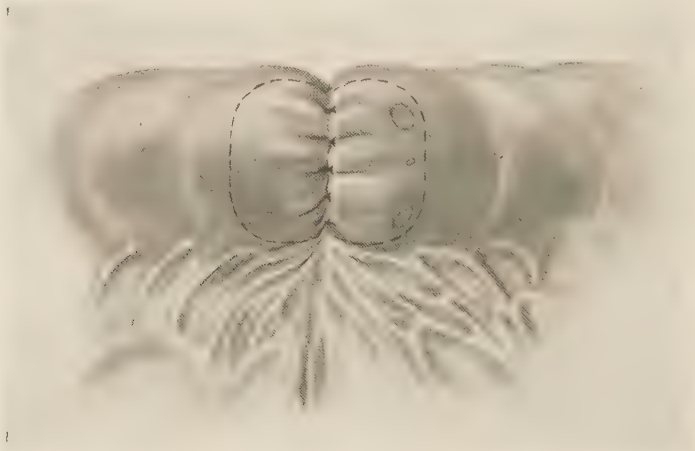

Fig. 1342.—End-to-end Anastomosis with Button.
The two halves of the button have been pressed together and the union reinforced with interrupted sutures.

care being taken that they do not slip back into the bowel. If the surgeon considers applying a serosa suture after the buttons have been pressed together, this should not be attempted in bowel wall which is so tightly drawn over the button that the suture threatens to tear out or perforate

the lumen. The button is liberated by pressure necrosis sometime usually during the second or third week, and passed with the feces.

For *lateral implantation*, *lateral approximation* and *lateral anastomosis* with buttons the same principle is used. The opening is made on the antimesenteric side of the bowel (Fig. 1343). When resection has been done, the mesentery is sutured to adjacent mesentery and peritoneum. An oblong button may be used for lateral junctions unless the bowel is very small.

Another method of making lateral anastomoses with the Murphy button, operated from within the bowel, was worked out by American surgeons.

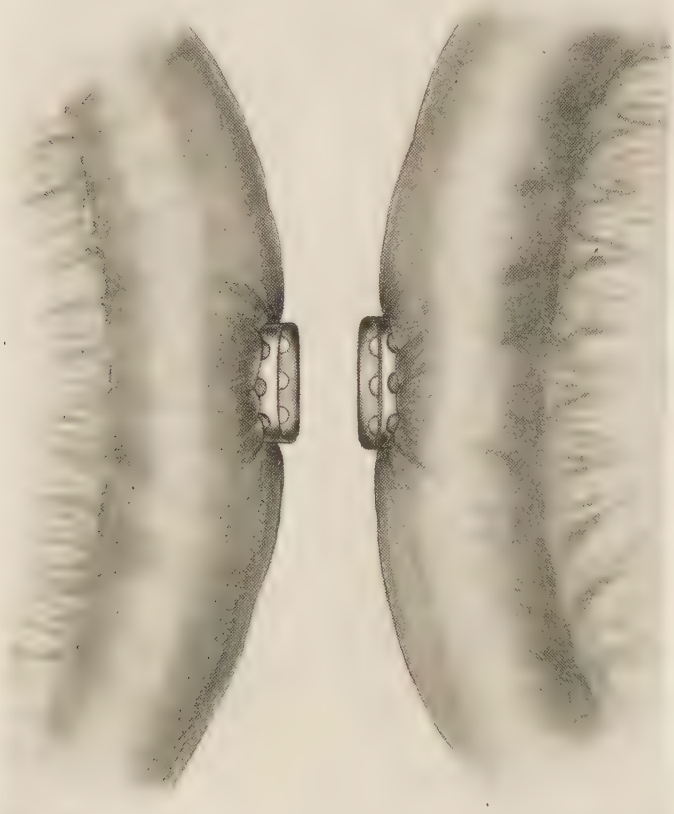

Fig. 1343.—Lateral Anastomosis with Oblong Button.
The oblong button is used as the largest round button is inadequate for most lateral unions.

It requires an opening in the bowel somewhere near the two sites of junction. This opening may be made for the purpose of introducing the button or it may be a part of another operation. Thus, in gastroenterostomy, when it is desired to join the two arms of the loop of jejunum, the operation is proceeded with as follows: after opening the jejunum for the stomach anastomosis and completing half of the suture, the male half of the button is introduced into the proximal arm of the loop, and the female half into the distal arm. This may be done with forceps or they may simply be dropped in

loosely and manipulated into place. The cylinder of the button is then pressed tightly against the antimesenteric wall of the bowel. Through the drumhead thus formed, two small crossing incisions are made, and the cyl-

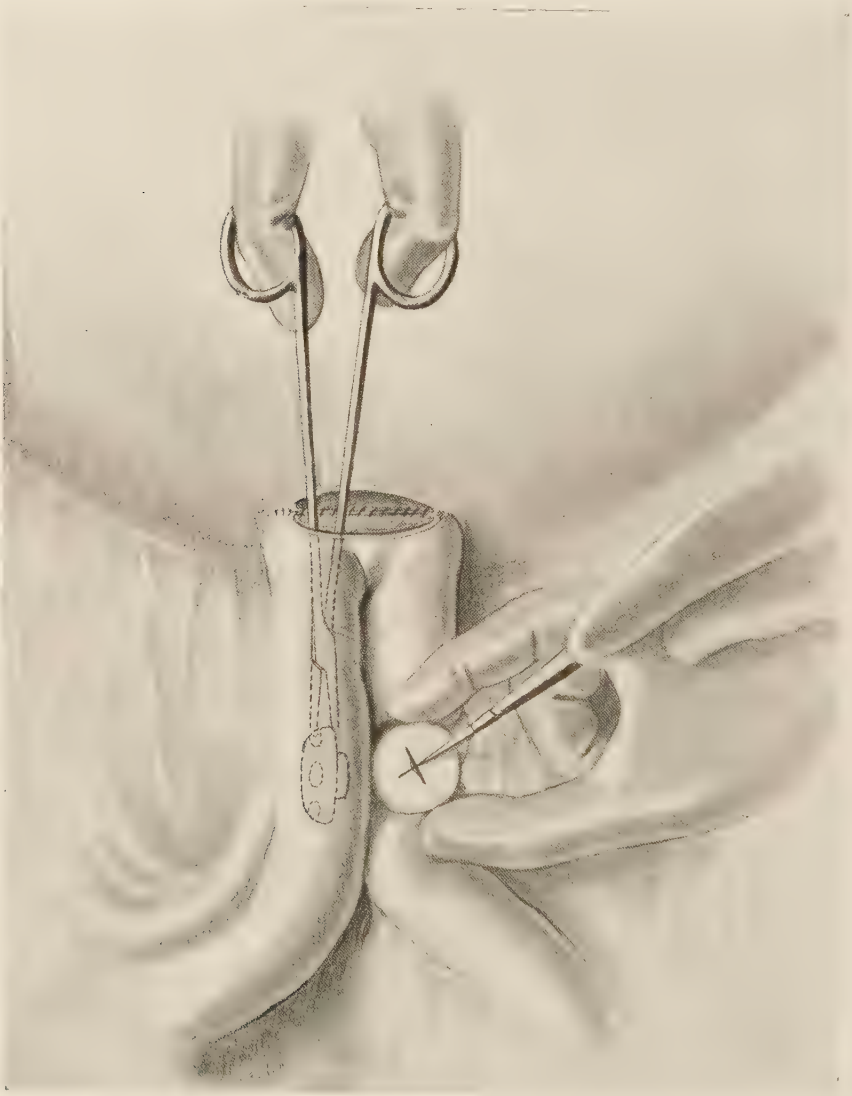

Fig. 1344.—Entero-enterostomy with Button from within the Bowel.

The first half of a gastro-enterostomy has been done, the halves of the button are passed respectively into each loop of intestine, one is held with a clamp, the other is controlled from the outside by the fingers. The intestine is cut to allow the passage of the stem of the button.

inder of the button pressed through. This is done on either side, the buttons being carefully steadied, and then the two halves are pressed together. No suture is required (Fig. 1344).

R. Finochietto (Surg., Gyn. and Obst., 1915) devised a simple method for bloodless aseptic introduction of the button. The viscus is emptied and the zone of operation occluded. The bowel or stomach wall is grasped at the place where the opening is to be made with hemostatic clamps having a long and broad contact surface on each jaw. The clamp is applied to a fold which is at right angles to the proposed place of incision, the clamp being placed so that it grasps the proposed place. If a cylin-

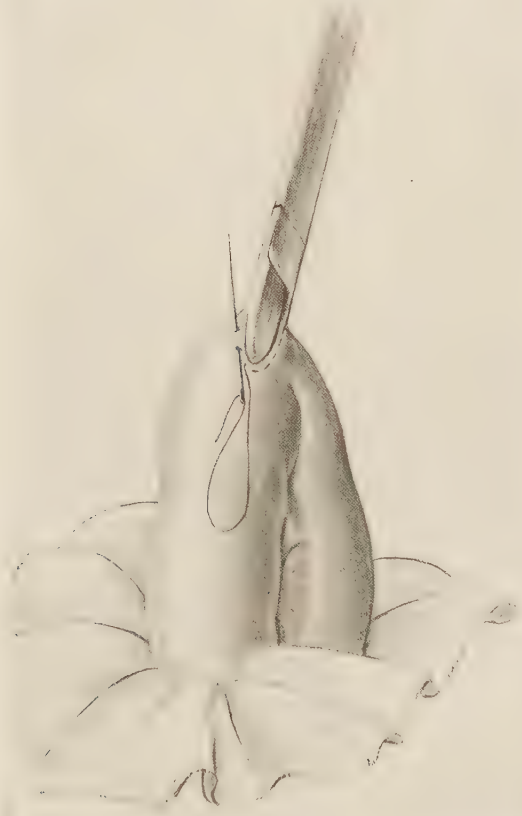

Fig. 1345.—Bloodless Aseptic Method of Placing Anastomosis Button.

A fold of bowel wall is grasped with broad hemostatic forceps at the place where the opening is to be made, the forceps are slowly but tightly closed, and a purse-string suture is inserted around the clamp.

dric button is to be used, the amount of wall grasped should be equal to three-fourths of the diameter of the button. If an oblong button is to be used the grasp of the clamp should be equal to one-half of the long diameter of the button. The forceps are slowly closed and locked. A purse-string suture is applied around the forceps (Fig. 1345). When the purse-string is completed, the forceps are removed, and the viscus is opened with scissors in the crushed line. The button is inserted and the purse-string suture tied (Fig. 1346).

Anastomosis with the segmented ring is aimed to increase the speed and facility with which the operation can be done. The ring, devised by F. B. Harrington (Boston Med. and Surg. Jour., Nov. 6, 1902), is made of hard aluminum in four segments all held together by a steel bar provided with a screw thread. The seromuscular purse-string sutures are passed around the bowel before it is cut and the first part of a surgeon's knot made. No. 2 plain catgut is used. The bowel is divided 3 mm. (⅛ inch) from the purse-string. A mesenteric mattress stitch is then introduced, as for simple anastomosis. The ring is then inserted in one end of the bowel, and the purse-string tied. The mesenteric suture is then tied, the ring inserted in the other

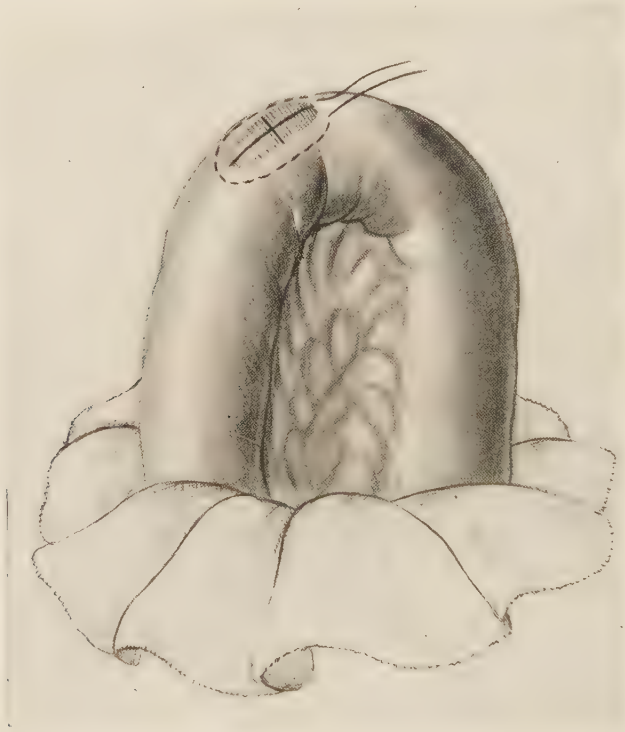

Fig. 1346.—Bloodless Aseptic Method of Placing Anastomosis Button.

The forceps, having crushed an area in the wall of the bowel, are removed; the bowel is opened with scissors in this area; the button is slipped in, and the purse-string suture tied.

opening, and the second purse-string tied. The handle emerging at the antimesenteric side supports the ring. A parallel continuous suture (Cushing) is then begun close to the handle and carried around the bowel. It is frequently knotted to prevent slipping. When it reaches the handle, the latter is unscrewed and removed, and the suture made to close the opening. The ring falls into four pieces which are passed with the feces. These rings are made in three different sizes. They may be used also for lateral anastomosis. Their value is as mechanical aids to the operation. The surgeon who has experience and skill in intestinal anastomosis does not need these mechanical aids.

Anastomosis with absorbable mechanical devices involves the same principles as have already been described. Bobbins of different materials, such as carrot, turnip, potato, and other digestible substances, have been employed. A. W. Mayo Robson (Sém. Méd., Paris, xii, 485, 1892) perfected a technic with a bobbin of decalcified bone. This can be sterilized and kept in alcohol. Bobbins of many sizes and shapes are used. They consist of simple cylinders with flanged ends (Fig. 1347). Bone plates were first employed by N. Senn.

In applying such a devise the first steps are the same as for the button anastomosis. The mesenteric stitch is placed, the bobbin is inserted, and the purse-string sutures tied. A continuous seromuscular suture is then applied.

Instead of using a bobbin to be retained, Coffey employed a simple straight cylinder of potato. The three preliminary mesenteric sutures, are inserted and the cylinder introduced in the bowel, and transfixed with two needles which catch overlapping edges of the intestine. This fixes all of the

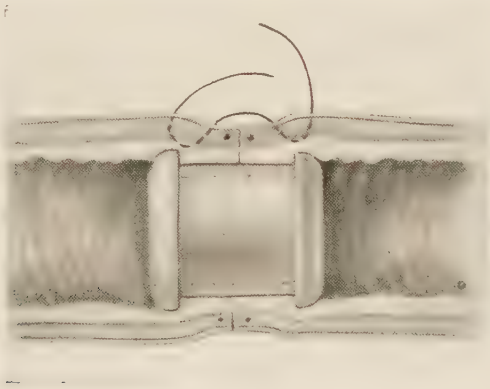

Fig. 1347.—Anastomosis with Aid of a Bobbin.
A purse-string suture ties the approximated ends of the bowel to the bobbin. A seromuscular suture completes the operation.

structures to be sewed, and the operation proceeds. When the anastomosis has been completed, the needles are withdrawn, and the cylinder moved away from the wound and crushed.

Anastomosis with especially devised forceps, clamps, holders and *ligatures* has been done in a great variety of ways.

The *rubber ligature*, devised and first used by F. Bardenheuer and J. M. Gaston, and perfected by T. A. McGraw, cuts out an opening by pressure necrosis. It was once applied in gastro-enterostomy and other lateral anastomoses. Several sizes were employed. The medium size is 4 mm. (3/16 inch) in diameter, and the smaller size is 3 mm. (1/8 inch); these are to be preferred. McLean (Jour. Mich. Med. Soc., Detroit, ii, 550, 1903) devised a needle for carrying the ligature which holds the latter by a sliding ferrule. A needle is placed on each end of the ligature. Clamps for occluding the intestine are not used. The two viscera are placed side by side and fixed by the first half of the seromuscular suture as for lateral anastomosis. The ligature is placed in such a position that it shall make a necrosis opening similar in length and position to that made by the incision in the ordinary operation (page 663). The needle is made to pierce the wall of the bowel at a right angle, care being taken that the mucous

membrane has been penetrated. The needle is then passed along inside of the bowel for 7 or 8 cm. (3 inches), and then caused to penetrate the wall and emerge at as near a right angle as possible. The needle is drawn out with a pair of artery forceps, until half of the ligature remains unsoiled. As the needle and ligature emerge they are wiped off with a piece of gauze and painted with tincture of iodin. The clean end is held to put the rubber on the stretch as it passes along. The same is done in the adjacent coil (Fig. 1348). A piece of strong silk is laid between the two ends and the ligature tied in a half knot. The silk is then tied tightly about the half knot to keep it from slipping. As the rubber ligature is being drawn up for tying, the handle of a pair of anatomic forceps should press back the line of suture to prevent its compression (Fig. 1349). The second half of the knot is tied and secured

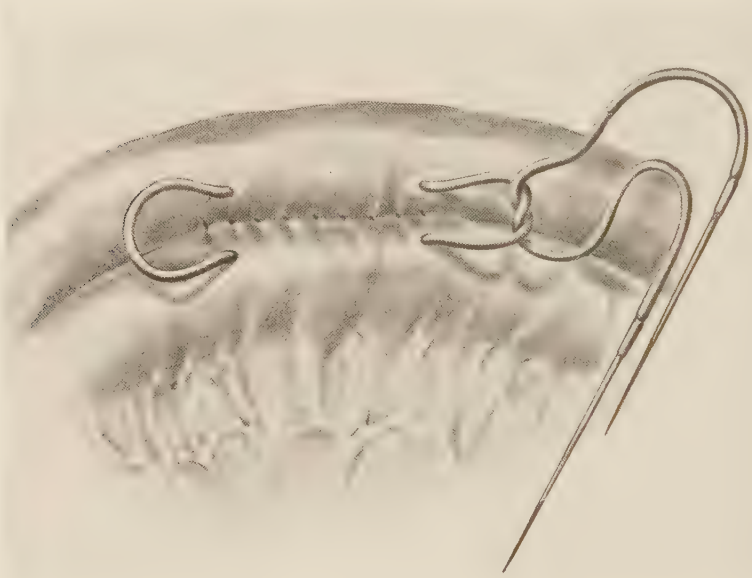

Fig. 1348.—Lateral Anastomosis with the Rubber Ligature.
The first row of seromuscular sutures has been placed. The rubber ligature has been introduced. Note needles of McLean.

by the silk ligature. The rubber should be tied as tightly as possible to insure cutting through, otherwise two holes will be cut and the ligature left transfixed by a bridge between them. The ends are then cut short. The seromuscular suture is continued in front of the ligature. This last half of the suture should be done with interrupted stitches (Fig. 1350). The ligature requires four or five days to cut through.

A *clamp method* devised by E. W. Andrews (Jour. Am. Med. Assoc., May 16, 1908) employs a clamp, each blade of which is pointed, and which is plunged into the bowel. The blades are closed and thus act as a clamp while the suturing proceeds, when the suture is completed the last loop is left loose, the blades of the clamp are firmly locked, and a chisel-pointed knife is slid along two grooves between the blades. This cuts the two bowel walls. A cautery blade follows this. The clamp is then withdrawn, and the suture tied.

A pair of *knitting needles* were used by V. and V. W. Pleth (Am. Jour. of Surg., July, 1909). The bowels are laid side by side, two rows of sutures inserted posteriorly, and a long steel knitting needle inserted in and out of each loop of bowel a distance equal to that of the desired opening. A long narrow forceps is then applied between the needles and the sutures back of both needles, grasping four thicknesses of bowel. The actual cautery is then used to burn through both bowel loops along the needles until the latter are released. The suture next to the opening is then completed, the loop next to the handle of the forceps not being pulled in place until the forceps are removed. The outside suture is then completed.

FIG. 1349.—LATERAL ANASTOMOSIS WITH THE RUBBER LIGATURE.
The ligature is being tied. The handle of a pair of forceps presses back the seromuscular suture line to prevent its compression. The silk ligature is ready to be tied about the first turn of the knot.

Intestinal Exclusion.—Excluding of some part of the intestine from carrying intestinal contents is accomplished by making anastomosis in such a way as to "short-circuit" the intestinal current. These operations are done for irremovable obstruction, for the purpose of securing rest for some diseased segment of the bowel, or for purposes of drainage. Tuberculosis of the intestine, ulcers, enterovaginal fistula, enterocystic fistula and intractable colitis represent some of the non-obstructive conditions for which the operation is done. Lateral anastomosis, lateral implantation, and end-to-end anastomosis are used. Besides enteroanastomosis there are essentially two forms of

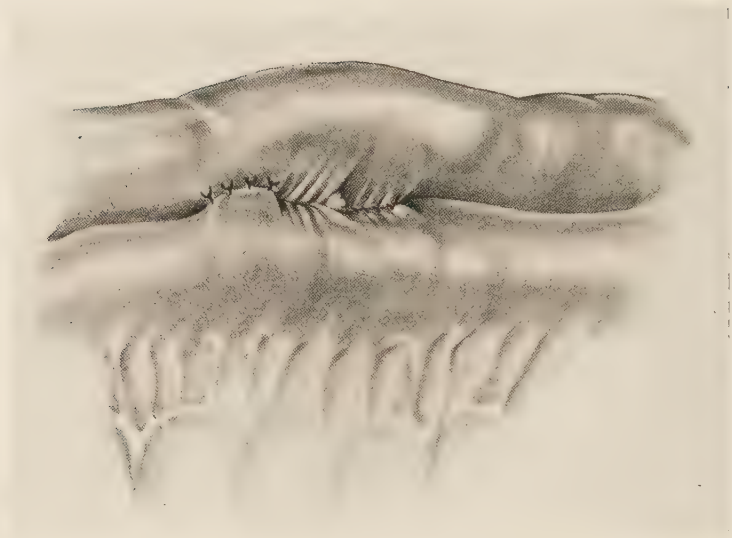

Fig. 1350.—Lateral Anastomosis with the Rubber Ligature.

The rubber ligature has been tied, the ends cut off, and the second half of the seromuscular suture started on the left. In the middle is shown the intestine puckered by the tied ligature. The two cut ends of the ligature are seen. At the right is seen the posterior row of seromuscular sutures. (*After Gould.*)

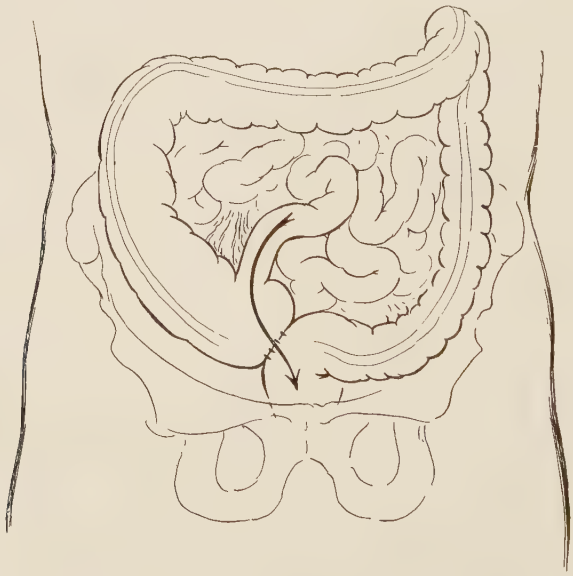

Fig. 1351.—Intestinal Exclusion by Rectocecal Anastomosis.

This gives direct drainage from cecum to rectum and excludes the great intestinal loop.

exclusion unilateral and bilateral. In the first, it is possible for intestinal contents to pass back into the excluded segment; in the second, the excluded segment is divided at both ends and entirely disconnected from the in-

Fig. 1352.—Intestinal Exclusion by Ileosigmoidostomy.
This gives direct drainage from ileum to sigmoid, but has the disadvantage that some intestinal contents pass the anastomosis and enter the cecum.

Fig. 1353.—Intestinal Exclusion by Ileosigmoidostomy and Occlusion of Ileum Distal to the Anastomosis.

testinal canal. In unilateral and bilateral exclusion, the excluded ends should be brought out as intestinal fistulæ for drainage. Exceptions

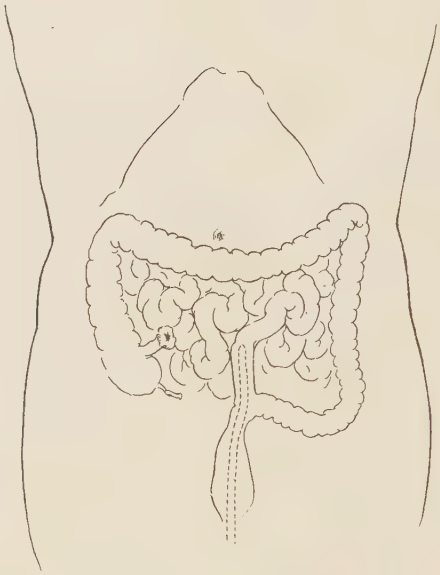

Fig. 1354.—Intestinal Exclusion by Ileosigmoid End-to-side Anastomosis.
The stump of the ileum is fixed in a button-hole wound in the abdominal wall. A, drainage tube is passed through the rectum above the anastomosis.

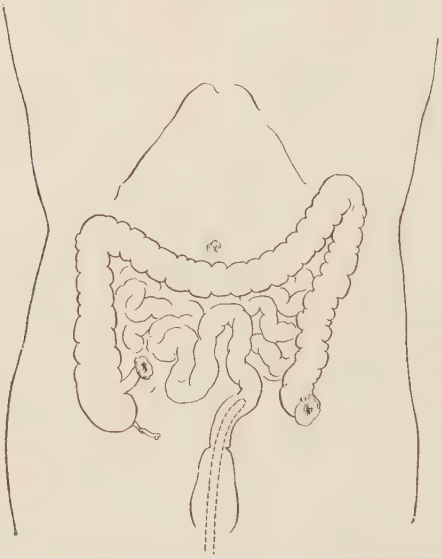

Fig. 1355.—Intestinal Exclusion by Ileosigmoidostomy.
The stump of the ileum and of the sigmoid are attached at openings in the abdominal wall. A tube is placed in the rectum above the anastomosis. This is the best of these procedures.

may be made to this, but it is the safest practice. The only part of the intestine where regurgitation is not apt to take place is at the ileocecal valve (Figs. 1351, 1352, 1353, 1354 and 1355).

After resection of a segment of colon the remaining segment may be excluded. Wherever this is done the excluded segment should be provided with fistulous openings for irrigation. This is no great inconvenience to the patient as the secretion from the empty bowel is very slight. It may be washed through every day with warm water and thus kept clean. Excluding the colon for chronic stasis is an easier and safer operation than resection, and it may help preserve the omentum (see page 645).

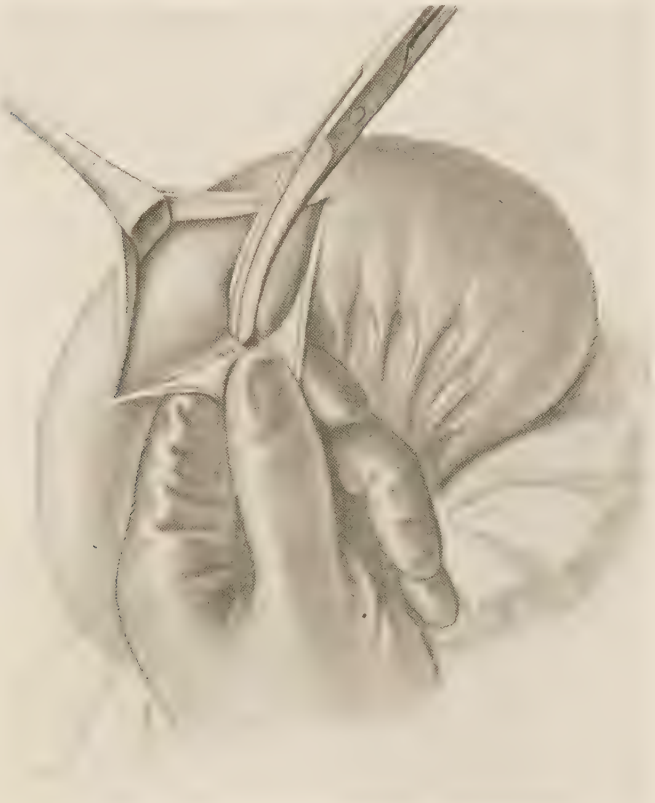

Fig. 1356.—Exclusion of Bowel by Mucous Membrane Constriction. The seromuscularis is incised and separated from the mucosa by blunt dissection.

Operations for closing the lumen of the intestine are performed, where exclusion of a portion of the bowel is desired. Such operations are done at the pylorus in connection with gastroenterostomy, and in the intestine between the points of an entero-enterostomy (see Formation of a Blind End, page 662).

Purse-string suture of the bowel after dividing it transversely is the simplest and easiest method. It is possible to make this an aspetic operation, by ligating the bowel tightly, dividing it with the thermocautery, sterilizing the mucous membrane of the stump; and burying the stump with a purse-string suture.

Transverse closure of the divided bowel is done with an over-and-over suture. Two layers of suture are usually applied. The division of the bowel is made parallel with the clamp which is applied transversely. Before applying the sutures the stump of mucous membrane beyond the clamp is sterilized.

Submuscularis-mucous-membrane occlusion is performed without dividing the bowel. Only the mucous membrane tube is occluded. A longitudinal incision is made in the bowel which passes through all of the coats except the mucous membrane. With a stroke of the knife on either side, the line of cleavage between the muscularis and the mucosa is discovered. The wound is then grasped with the fingers and the muscularis everted (Fig.

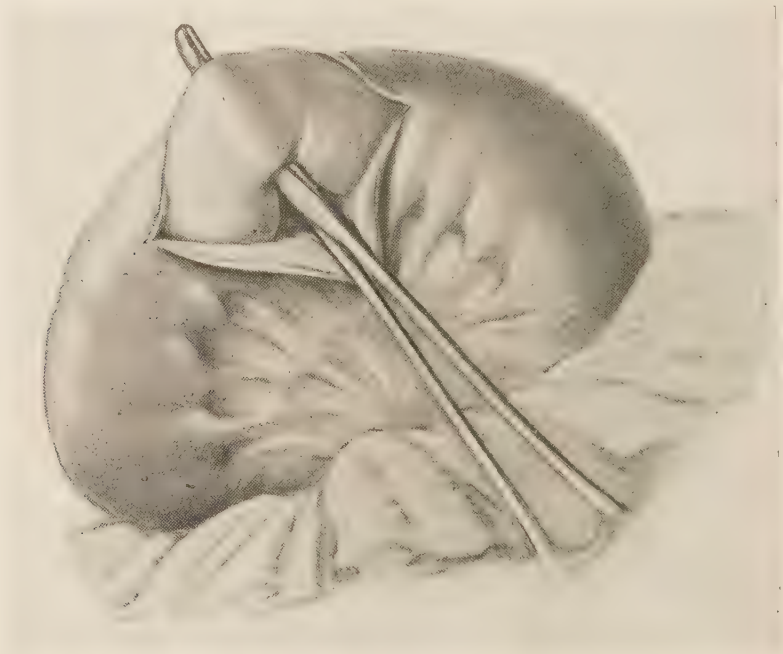

Fig. 1357.—Exclusion of Bowel by Mucous Membrane Constriction. Forceps are passed under the isolated tube of mucous membrane between the mesenteric vessels.

1356). As this is done the mucous membrane tube presents in the opening. By continuing the eversion of the muscularis, it is easy with or without a few strokes of the knife completely to isolate the mucous membrane tube. If the operation is done between two mesenteric arteries the muscularis may be peeled away from the mucosa without using a knife (Fig. 1357).

At this stage of the operation A. A. Straus (Jour. Am. Med. Assoc., Jan. 22, 1916) used a strip of fascia, taken from the anterior sheath of the rectus muscle, from the transversalis fascia, or from the outer side of the thigh. This piece of fascia, cut like a ribbon, is passed around the mucous membrane tube. One end of the fascia transplant is sewed to the mucous membrane tube with four or five interrupted sutures. Even traction is made on the other end and it is carried around the tube tightly enough to cause its complete collapse and occlusion, and sewed with interrupted sutures

to complete the circle. The free end is sewed, with a third row of interrupted sutures (Fig. 1358). The occluded mucous tube is then dropped back, and the serosa-muscularis wound closed with a running chain suture which catches the band of fascia as it passes along.

Enterostomy.—The formation of an intestinal fistula or artificial anus may be done with the view of making it temporary or permanent. Such openings may be required to relieve obstruction or for the purpose of drainage or treatment. Jejunostomy is usually done for the purpose of introducing nourishment below the site of a disease. Low ileostomy and colostomy are done usually to relieve obstruction, the opening being made above the disease. When an opening for artificial anus is made it should be as low in the bowel as possible. The lower in the abdominal wall the opening is made the greater is the possibility of hernia. The operations which will be described

Fig. 1358.—Exclusion of Bowel by Mucous Membrane Constriction.
A transplant of fascia has been sewed around the tube of mucosa. The seromuscularis is being closed. The needle catches also the wrapping of fascia.

are those done deliberately and not as emergency expedients when the first coil of intestine that presents is opened.

A temporary intestinal fistula is one which is to be closed after it has served a temporary purpose. Such a fistula in the lower part of the ileum is made as follows: A lateral intramuscular opening is made over the cecum through an incision (page 504) 5 to 7.5 cm. (2 to 3 inches) in length. The incision should be about 4 cm. (1½ inches) from the outer end of Poupart's ligament and parallel to it. The cecum is the guide to the end of the ileum. The obstruction is found and the bowel above it brought into the wound. If the obstruction cannot be identified any distended coil of intestine in the cecal region may be used. The gut should be placed in the general direction which it naturally occupies. Only the side farthest from the mesentery should project into the wound. Four fixation sutures are passed through the

outer coats of the bowel, two laterally and two at the ends, embracing a space about 2 cm. (¾ inch) wide and 4 cm. (1½ inches) long. These sutures are passed through the peritoneum and all the layers of the abdominal wall. The peritoneum is then sewed to the bowel with a continuous suture, leaving an elliptic knuckle presenting. The muscle and fascia of the wound are then closed down to the opening and the skin sewed to the elliptic bowel area as the peritoneum had been. If the intestine is not to be opened at once, the peritoneal suture may be omitted or the peritoneum and skin may be sewed together. It is best to make the opening two or three days later when the peritoneum has become well adherent. If the opening is to be made at once, a purse-string suture should have been placed in the ellipse; and after

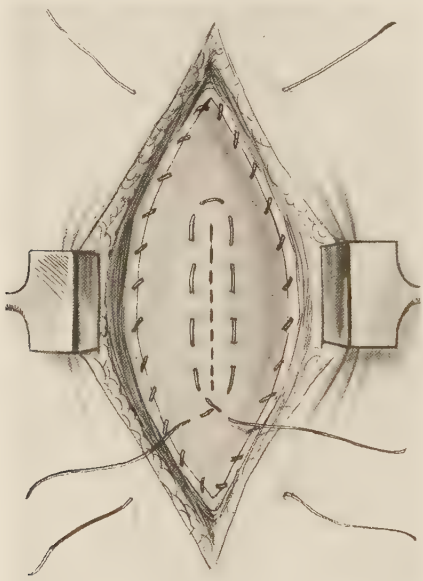

FIG. 1359. ENTEROSTOMY.

Construction of fecal fistula for drainage of intestine. The bowel is sutured to the abdominal wound; purse-string suture has been inserted; dotted line shows site of incision for opening into which tube is to be inserted. The incision through the peritoneum is about 5 cm. (2 inches) long, and the incision in the bowel about 2 cm. (¾ inch) long.

the gut has been sewed to the skin the wound should be painted with compound tincture of benzoin varnish, the opening should be made within this suture, a tube of good size quickly inserted, and the purse-string tied down upon it. The circle made by the purse-string should be about 13 mm. (½ inch) in diameter. The wound should be protected from soiling. The tube conveys away the intestinal contents (Fig. 1359). After a few days the tube may be removed. Unless there is obstruction below, this fistula tends to close spontaneously.

Sometimes these operations must be done after an abdominal section. If done soon afterward the wound of the abdominal wall may be reopened. When this is done little or no anesthetic need be used. For immediate opening of the bowel a segment may be freed of gas and closed in two places

by rubber-covered clamps. A purse-string suture is applied opposite the mesentery. A No. 12 soft rubber catheter is inserted as soon as the bowel is punctured, and the purse-string tied. A second purse-string should be applied, the clamps removed, and the bowel stitched to the abdominal wall.

Any of the methods used in gastrostomy may be employed for making an intestinal fistula. If it is desired that the fistula should close promptly after removing the catheter, the bowel may be incised longitudinally through the seromuscular coats and the catheter buried in the wall of the intestine after the method devised by Coffey for implanting the ureter into the bowel. C. W. Mayo passed the catheter through the omentum for security and to favor early closure of the fistula.

A temporary colostomy is made in the same manner. The feature of the temporary fistula is that only the side of the gut is made fast. No spur is formed. In these operations, intestinal contents pass on beyond the fistula, and if there is obstruction the distal arm should be washed out frequently. If it is desired that intestinal contents should not pass beyond the fistula, a spur or two distinct openings should be made, as described for carcinoma (page 582), for intestinal obstruction (page 595), and anterior sigmoidostomy (page 689).

A *permanent intestinal fistula* in the lower *small intestine* should not be made, unless (1) the entire colon requires to be removed or (2) is the seat of disease which occludes it. An anastomosis of the ileum with the rectum or colon below the disease is the operation of choice in either of these conditions. The large intestine has important functions and should not lightly be sacrificed. When such a fistula is made, the operation is done the same as in the colon.

Colostomy is preferably done in the left inguinal region in the sigmoid flexure. This is *inguinal sigmoidostomy*. When obstruction is located above the sigmoid, an intestinal exclusion, connecting the gut above the disease with the gut below the disease, is to be preferred to a higher colostomy. Thus, for irremovable obstruction of the cecum or ascending colon, an end-to-side implantation of the ileum just below the disease is to be preferred to the formation of a fecal fistula above the disease. The exceptions to this are: (1) in acute conditions a temporary fistula above the disease may be necessary to save the patient's life; and (2) in some cases the formation of a fistula may be preferred because of the greater immediate operative hazard of entero-anastomosis.

Colostomy which is to be at all permanent should make use of the separated muscle fibers of the abdominal wall for sphincteric action. For this reason the operation should be done through the oblique or the rectus muscles. Ryall (Lancet, London, July 3, 1909) secured transverse fibers from the rectus by splitting off a bundle from either side, and carrying one across below and one above the bowel.

The performance of *enterostomy for the relief of acute obstruction* must often be carried out as the most simple and expeditious operation possible. Often the patient is in an extremely depressed condition, and relief from intestinal distention, toxemia, and shock must be secured promptly. This condition often prevails after an abdominal operation. The patient should be removed to the operating room, but if psychic depression from fear is threatened by such a procedure the operation may be carried out with the patient remaining in bed. Under local anesthesia the wound should be opened, the patient understanding that a dressing is to be done; or the abdomen opened on the right side if there is no definite knowledge as to the loca-

tion of the obstruction. The distended coil of intestine which comes into the wound will be above the obstruction. If it is colon, so much the better.

The lower the opening in the bowel is made, the better is the promise of success. If the patient's condition is desperate no time should be given to selecting the lowest place. The very first coil of intestine that presents should be seized. A purse-string suture should be applied opposite the mesentery, making a circle about 2 cm. (¾ inch) in diameter. The bowel should be steadied by holding the suture with two clamps. Towels should be placed about it to prevent soiling the environment. At this point skill and coöperation are required. The bowel should be held in such a position that the fluid contents are farthest from the purse-string. A rubber or glass tube of fully 1 cm. (½ inch) in diameter should be in readiness. The bowel should be lifted up by catching it with forceps within the purse-string circle and quickly opened by snipping a fold with scissors or by a quick puncture with a sharp knife.

At once, as the cut is made, the assistant slips the tube into the intestine and ties down the purse-string suture while gas is escaping but before the fluid contents of the bowel have reached the opening. This should be done so nicely that the environment is not soiled. The opening made in the bowel need be only about half the size of the tube as the tube should stretch the opening and fit tightly. The omentum should be drawn down about the tube, a strip of gauze placed over the wound in the intestine and lead out beside the tube, and the rest of the abdominal wound closed. It is not necessary to stitch the bowel to the abdominal wall. The end of the rubber tube may be attached to the skin by an adhesive strip. The fistula usually closes promptly when the tube is removed.

This operation is capable of saving life by giving immediate relief to the obstruction. The subsequent steps must depend upon the location of the fistula and the nature of the obstruction. If the fistula is above the middle of the ileum the patient will soon suffer with inanition if all of the contents flow out. If it is in the lower ileum or colon it may continue to discharge without harm. Usually the purpose of the tube is to save the patient from death from obstruction. When the emergency has passed the tube is removed and the sinus permitted to close.

Left inguinal colostomy is done through the anterior abdominal wall. An incision 5 or 6 cm. (2 or 2½ inches) long, parallel with Poupart's ligament, is made. This incision crosses at right angles an imaginary line, drawn from the umbilicus to the left anterior superior spine of the ileum; its center is a little below this line, and it is placed about 4 cm. (1½ inches) internal to the iliac spine. The abdomen is opened by the intramuscular method (page 504). A finger is introduced into the left iliac fossa. It follows the inside of the abdominal wall, passes to the outer side of the sigmoid, and then, sweeping inward across the sigmoid mesocolon, engages the bowel and brings it into the wound. The sigmoid is recognized by its longitudinal bands, sacculations, appendices epiploicæ, and by its long mesocolon.

The direction of the bowel should be determined. This is not difficult if the mesocolon is followed as described above. In this way the bowel is brought out without being twisted, and its distal part is below. It should be drawn downward and distal bowel passed on below until stopped from further traction by its mesocolon. The object of pulling down the bowel as far as it will go, is that there should not be sagging bowel above to permit hernia of the attached loop.

If a *temporary fecal fistula* is to be made, two traction sutures, about 4.5 cm. (1¾ inches) apart, are introduced through the outer coats in the longi-

tudinal band farthest from the mesentery. These sutures lift the bowel into the wound. It is then made fast by one or two sutures on either side which pass through peritoneum and muscle of the abdominal wall. A figure-of-eight silkworm-gut suture or two at either extremity of the wound close it down to the bowel. The two guides continue to hold up the bowel while it is sewed fast to the skin, leaving about half of its circumference exposed at the middle of the wound. This exposes an elliptic area. The two guides, having been passed through the skin on either side, are then tied across the wound next to the bowel. If the bowel must be opened at once a purse-string circle is placed in the middle of the ellipse, a longitudinal incision made, a large glass tube inserted, and the purse-string tied about it. After adhesions have developed the tube may be removed. If there is no emergency, the bowel need not be opened until one or two days later; in which event a longitudinal incision is made through its wall about 2 cm. (7/8 inch) long.

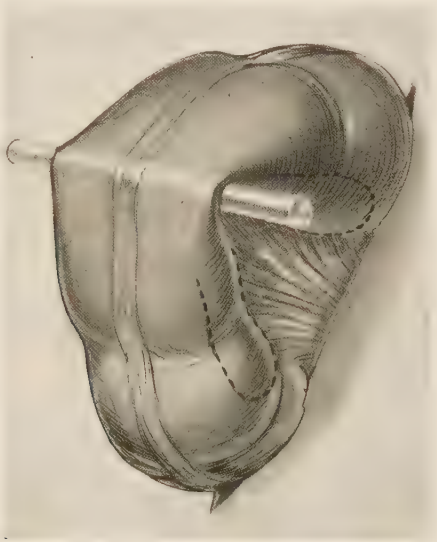

FIG. 1360.—COLOSTOMY.

The bowel is supported on a glass rod, passed through the mesocolon. The dotted lines show lines of suture to hold the two arms of the loop together to form a spur. The suture line should be shown farther from the mesocolon.

Such a fistula as this has the disadvantages that it discharges almost constantly, and the bowel between the fistula and the obstruction contains stagnant fecal material, which should be kept washed out to make the patient comfortable. For these reasons, it is usually best to plan a permanent fistula, even for temporary cases, unless the emergency makes the above operation more desirable.

For making a *permanent fecal fistula* (artificial anus), a loop of sigmoid is drawn out of the wound until the upper end is taut. A small opening is made in the mesentery near the bowel and a glass rod or similar support passed through to hold up the bowel. The two arms of the gut are then united on the outer side by a U-shaped line of suture (Fig. 1360). This is a continuous suture of catgut introduced with a curved needle. When it is pulled up tightly the two surfaces of bowel lie closely together, and a spur is formed by apposition of the bowel surfaces on the outer side of the mesocolon.

One end of this suture is passed through the edge of the parietal peritoneum in the middle of the wound on the outer side, and tied. Another suture catches the parietal peritoneum to the mesocolon near the rod on the other side. The excess of abdominal wound is then closed at either end

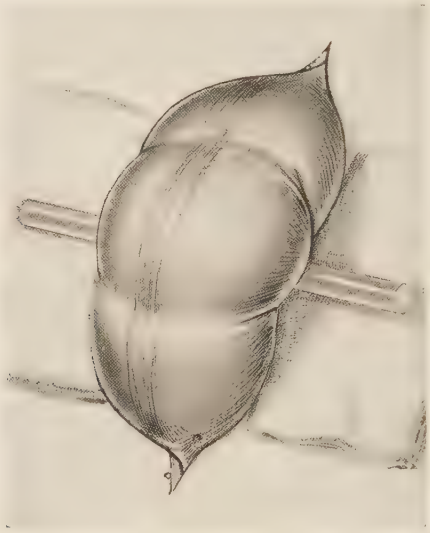

Fig. 1361.—Colostomy.
The union for the spur has been made, the bowel dropped back and sewed to the margin of the wound.

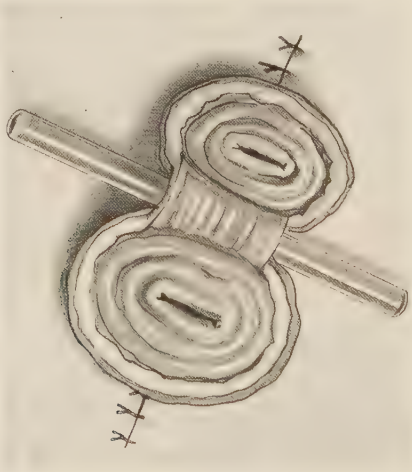

Fig. 1362.—Colostomy.
Projecting loop has been cut off. The glass rod is still left under a bridge of intestine to give support.

by one or two sutures, the suture nearest to the bowel catching it also, and holding up into the wound a well-relaxed loop of sigmoid. The extruded bowel is then fastened to the skin by a continuous suture (Fig. 1361).

Gauze is placed between the rod and the skin. If necessary a glass tube is at once fastened into the bowel.

If there is no urgency, the bowel is not sewed to the skin; the rod and the four stay sutures keep it in place. Vaselin is not used lest it prevent adhesions. The bowel is covered with rubber protective, and a wall of pads laid about it to prevent pressure. After adhesions have formed, in three or four days, or preferably after a week, the projecting bowel is cut off (Fig. 1362). Bleeding may require a running suture around the cut edge, usually no suture is needed. The bridge between is left to be supported by the rod for a week, when the rod is removed. This constitutes *high inguinal sigmoidostomy.*

The spur in this operation causes all the contents of the upper bowel limb to escape to the outer world, although some discharged material will drop into the lower limb. This may be prevented by closing it, as is sometimes done at the original operation, and dropping it back into the abdomen.



FIG. 1363.—COLOSTOMY.
Diagram showing method of supporting loop of bowel by a suture through the mesentery.

The spur also facilitates closure of the fistula, if at any time such an operation is desired. If there is a possibility that the opening may be only temporary, a smaller loop of gut should be left outside, and opened by a longitudinal incision.

By passing a suture through the mesocolon and fastening it to the abdominal wall on either side of the wound, the glass rod may be dispensed with. The incision should not be longer than 5 cm. (2 inches). The skin is freed for 2.5 cm. (1 inch) from the edge of the wound with a few strokes of the knife. The bowel is brought up. A strong chromic catgut suture is then passed backward through the whole thickness of the abdominal wall, excepting the skin, about 2 cm. (¾ inch) from the edge of the wound, then through the mesocolon about 2.5 cm. (1 inch) from the bowel, thence forward through the abdominal wall as far as the skin on the other side, across through the mesentery again, to be tied at the place of beginning (Fig. 1363). No other sutures need be used if the operation is done in two stages. Local anesthesia suffices. The bowel is opened longitudinally. The suture should

be placed about one-third of the distance from the lower end of the wound, in order to squeeze the lower more than the upper bowel.

The elimination of the sigmoid as a fecal reservoir means that feces are apt to discharge at frequent intervals. The opening, through the fibers of the abdominal muscles, gives some sphincteric control. In order to give better control to the artificial anus, various modifications of the simple operations have been made.

A *low inguinal sigmoidostomy* is done through the same incision as the above, about 4 cm. (1¾ inches) long. The *distal part* of the bowel is drawn out as far as it will come. This leaves the upper part of the sigmoid in the abdomen. The bowel is then surrounded by a purse-string suture at the level at which the distal part leaves the abdominal cavity. Two clamps are placed on the bowel above the suture. The bowel is divided between the clamps, and the mucous membrane sterilized with phenol. The upper



Fig. 1364.—Anterior Sigmoidostomy by the Flap Method.
Skin incised and flap turned back.

stump is simply covered with gauze. The distal stump is closed by a through-and-through suture, the clamp removed and the bowel inverted by tying the purse-string. It is fastened to the lower angle of the wound by one or two stitches through the peritoneum. The upper stump is then made more mobile by freeing it a little if this can be done without sacrificing its blood supply. It is left hanging out of the wound. The skin is then undermined for 4 or 5 cm. (1½ or 2 inches) external to the wound, and a second opening through the skin made just above the crest of the ileum. The bowel with its clamp is then passed beneath the bridge of skin. It is fixed to the peritoneum of the first wound by a few stitches. This wound is then sutured, the muscles being permitted to close about the gut. The free end is sewed to the skin of the second wound.

If the abdominal muscles do not have sufficient sphincter action to insure continence, a compressing pad, worn on a belt over the skin between the

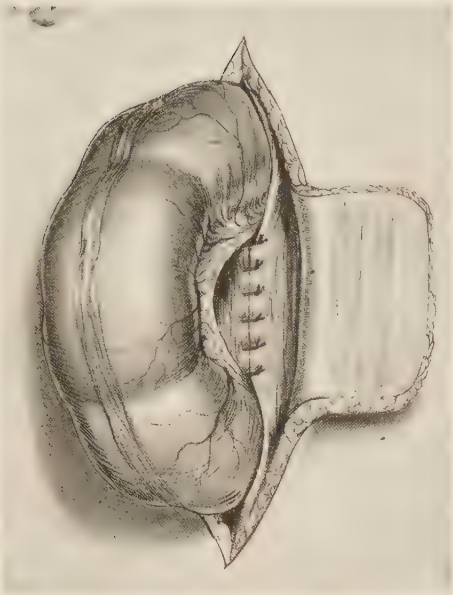

FIG. 1365.—ANTERIOR SIGMOIDOSTOMY BY THE FLAP METHOD.
The flap of skin and fascia has been turned back, the loop of sigmoid drawn out, the mesocolon split, and the rectus muscle sewed together behind the intestine.

FIG. 1366.—ANTERIOR SIGMOIDOSTOMY BY THE FLAP METHOD.
The flap has been sewed back in place under the loop of intestine. A glass tube for drainage may be introduced if immediate relief of obstruction is called for.

two wounds, will give control of the bowel. In the event of the sigmoid having a short mesentery, the artificial anus may be made in the first incision;

Fig. 1367.—Anterior Sigmoidostomy by the Flap Method.
The bowel has been amputated.

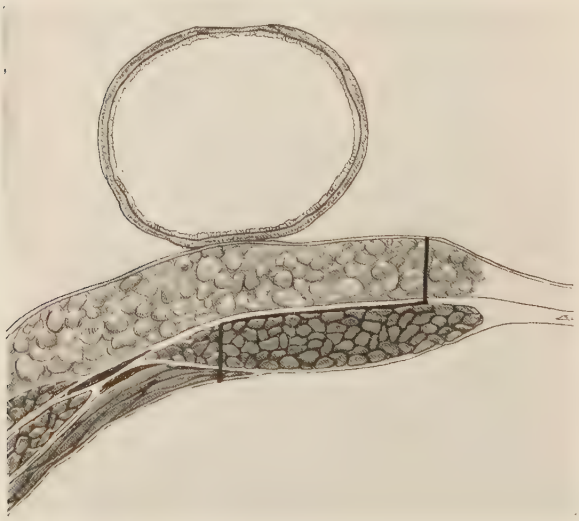

Fig. 1368.—Colostomy by the Flap Method.
Diagram of the operation for securing compression of the bowel by the muscles of the abdominal wall in order to maintain fecal control. The bowel is shown external to the abdomen. Note lines of division of skin and fascia and of rectus muscle.

and by rotating the bowel upon its long axis through half a circle, after the method of Gersuny, a sphincter effect may be secured.

An *anterior sigmoidostomy*, between the fibers of the rectus muscle, has been devised by Mixter, Wier, Audry and others. An incision is begun on a level with the umbilicus, in front of the junction of the outer and middle thirds of the left rectus muscle. This is about 7.5 cm. (3 inches) from the umbilicus. It passes downward about 5 cm. (2 inches), thence marks out a flap toward the median line about 4 cm. (1½ inches) long with a base 5 cm. (2 inches) broad, and passes downward for 5 cm. (2 inches) in the same direction as the beginning vertical incision. This incision passes through skin, fascia and the anterior sheath of the rectus muscle (Fig. 1364). The flap is dissected up, turned outward, the fibers of the rectus separated, and the abdomen opened. Care should be taken to spare the nerves passing

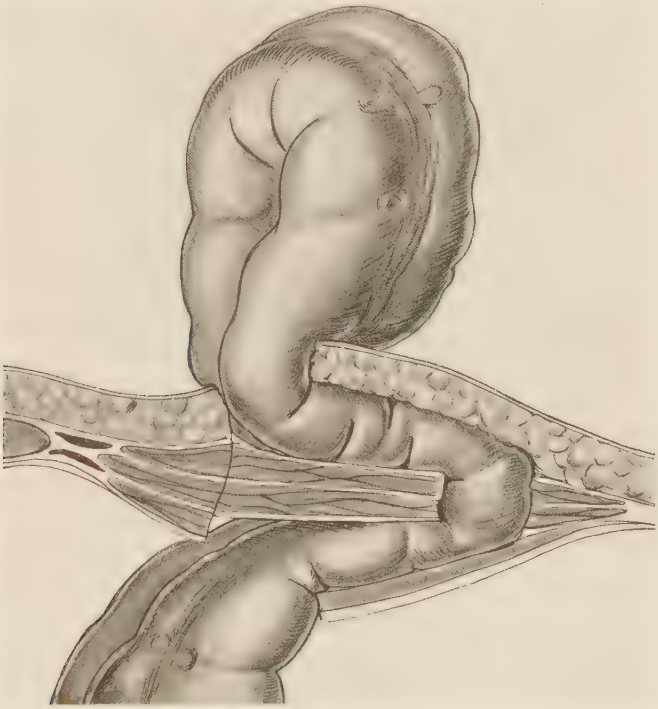

FIG. 1369.—COLOSTOMY BY THE FLAP METHOD.
Operation for carrying a loop of bowel through an opening in the oblique muscles in order to secure compression after the method of Gant.

from without to the inner fibers of the rectus by retracting them upward and downward. The sigmoid is brought out, with its upper segment pulled taut to prevent prolapse. Its mesentery is split at right angles to the long axis of the bowel for about 5 cm. (2 inches). The middle portion of the rectus, its posterior sheath, and peritoneum are united behind the gut with three figure-of-eight sutures of chromicized catgut (Fig. 1365). The skin-fascia flap is then brought through the cleft in the mesocolon and sewed back in place by two layers of sutures. This leaves the loop of sigmoid arching over the skin from one end of the wound to the other.

If immediate opening of the bowel is necessary, a circular purse-string suture is introduced and a large glass tube (Fig. 1366) inserted. To prevent

adhesions to the dressing, the bowel may be covered with vaselin or dusted with zinc oxid powder and covered with rubber protective tissue. After five days or a week the bowel loop is cut off at either end about 6 mm. (¼ inch) from the skin. Bleeding from the edges is checked by a continuous over-and-over stitch through the wall of the intestine, if necessary. If for any reason the bowel is cut away earlier than this or the patient's resistance is poor, a few stitches should fasten it to the skin. This leaves the two bowel openings separated by 5 cm. (2 inches), each is compressed by the rectus muscle, and the distal limb can be washed out or otherwise treated (Fig. 1367).

Another *operation for securing muscular control of the bowel* is carried out through a straight incision, but the bowel is brought through the muscle at an opening 4 cm. to the side of the skin and peritoneal opening. This causes

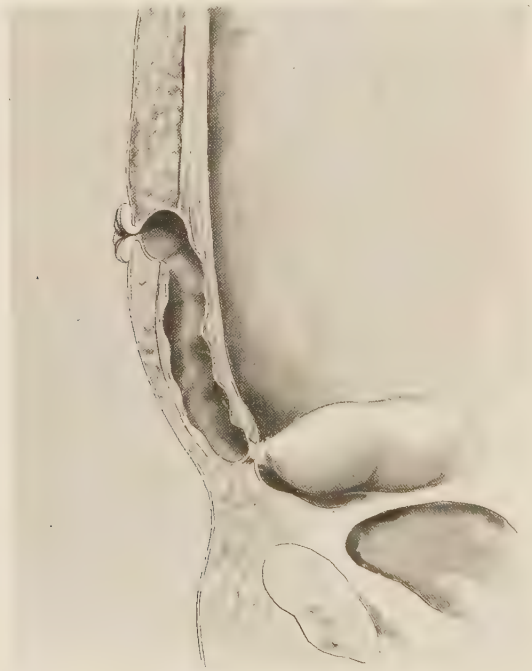

Fig. 1370.—Operation of Brinsmade for Making a Controllable Artificial Anus.

the bowel to make a loop in emerging between the fibers of the muscle (Fig. 1368).

The operation of Gant carries the loop of bowel through an opening in the oblique muscle in order to secure muscular compression (Fig. 1369).

An operation devised by W. B. Brinsmade (Trans. Am. Surg. Assoc., 1916) and highly recommended by him is carried out as follows: The abdomen is opened through a transverse suprapubic incision. The sigmoid having been divided a second small incision is made through the skin about 6 cm. (2½ inches) above the first incision to the left of the median line. A passage is made by blunt dissection between the fibers of the rectus and in front of the transversalis fascia. The proximal end of the bowel is drawn up through this passage and fastened by a few sutures to the peritoneum and to the skin at the place of exit (Fig. 1370).

For the *collection of fecal discharges* from a colostomy which has been done without the creation of a sphincteric control, or in which the discharges may come away unexpectedly, cups and sacks have been constructed to be worn constantly and held over the opening by belts and bands. H. B. Delatour (Med. Record, Nov. 15, 1913) devised such an apparatus of hard rubber, which has attached to it a removable rubber bag (Fig. 1371). This may be worn by the patient who is about on his feet.

Lumbar colostomy has little to recommend it. It is employed in order to avoid traversing the peritoneum; and is aimed usually to open the descending colon. The position of the descending colon is represented by a line, passing directly upward from a point 1.3 cm. (½ inch) posterior to the middle of the crest of the ileum, to the twelfth rib. This line marks the outer border of the quadratus lumborum muscle. An incision 10 cm. (4 inches) long, passing obliquely downward and forward has its middle crossing the middle of

Fig. 1371.—Colostomy Apparatus with Fecal Receptacle Devised by Delatour

this line. The fibers of the latissimus dorsi, external and internal oblique, are divided. The twelfth dorsal nerve is spared. The border of the quadratus lumborum is exposed. The transversalis muscle and fascia are divided, and the subperitoneal connective tissue uncovered. The kidney is pressed upward. If the distended colon does not bulge into the wound, the finger should loosen the connective tissue toward the psoas muscle, and the patient be turned so that the wound is rotated downward. The gut may be cleared, grasped with blunt forceps, brought toward the surface, and sutured in the wound. If the colon has a short mesentery, it may be divided; if this cannot be done the bowel may be divided; or if this is not possible, a transperitoneal operation must be done.

Jejunostomy.—This operation is done high in the jejunum. It may be used as a means of treating diseases of the stomach and duodenum which require rest or freedom from the irritation of food and the digestive processes. Through the jejunostomy tube food may be poured into the jejunum.

By allowing the patient to take water by the mouth, the digestive juices are diluted in cases of ulcer. A. W. Mayo Robson (British Med. Jour., Jan. 6, 1912) recommended jejunostomy, as useful in the following conditions: (1) Widespread cancer of the stomach too advanced for gastrostomy. By securing complete rest to the stomach, it stops hemorrhage, relieves pain, diminishes the size of the tumor and prolongs life very considerably. (2) In general cicatricial contraction of the stomach, due to the swallowing of caustic fluids, in which the stomach has been so far damaged that it no longer performs its functions or even allows of the passage onward of food. (3) In chronic ulcer of the stomach giving rise to hemorrhage, pain or vomiting and to malnutrition; and where the patient is too ill to bear partial gastrectomy, which can, however, be subsequently done if thought needful after the pa-

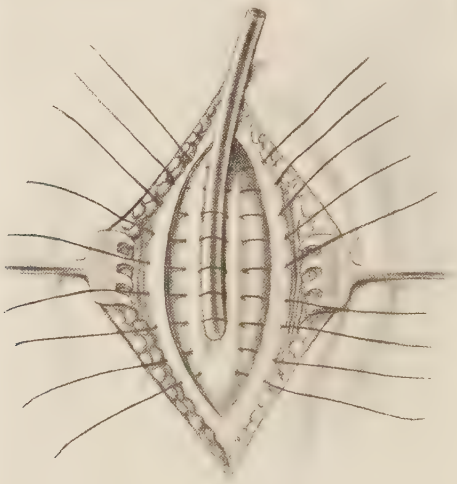

Fig. 1372.—Jejunostomy.

A rubber tube has been passed through a small punctured opening in the jejunum. The tube is placed along the outer surface of the bowel and sutures placed in such a manner as to envelop the tube in peritoneum. The sutures are passed through the parietal peritoneum.

tient's condition has been restored by adequate feeding. (4) In some cases of chronic duodenal ulcer, associated with hyperchlorhydria, in which there may be a fear of jejunal ulcer subsequently developing if gastroenterostomy be performed. (5) In certain cases of duodenal ulcer in very stout subjects in which it is extremely difficult to perform a gastro-enterostomy and in which violent hemorrhage has only recently occurred and may be again excited by dragging on the stomach. (6) In jejunal or gastrojejunal ulcer where the patient is thought to be too ill to bear one of the extensive operations previously mentioned; or where, the disease being slight, it is thought that the complete rest of the stomach and upper jejunum that can be given by a jejunostomy will at the same time relieve the hyperchlorhydria and cure the ulcer. Neumann has suggested the operation for hyperchlorhydria alone.

(7) In recurring hematemesis failing to yield to ordinary treatment and where on exploration no ulcer or other removable cause can be discovered. (8) In persistent vomiting threatening life, as in the severe and sometimes fatal vomiting of pregnancy, where no food whatever can be retained in the stomach. To these may be added: (9) Sloughing conditions and ulceration of the esophagus associated with gastritis. (10) Other conditions in which gastro-enterostomy is urgently indicated but cannot be done on account of adhesions, infection or other local reasons. (11) Cases in which the general condition of the patient is too low to tolerate gastro-enterostomy, but rapid jejunostomy may be done.

The operation is best done by the same method as that which Witzel applied to gastrostomy. A small rubber catheter is inserted through a small

Fig. 1373.—Jejunostomy with Entero-enterostomy.

An entero-anastomosis has been done and the rubber tube introduced into the summit of the loop which is made fast to the anterior abdominal wall. The tube passes into the distal arm of the loop.

opening on the convex side, and pushed into the bowel in a distal direction. It is then infolded as is done for gastrostomy for about 3 cm. (1¼ inch). The bowel should not be kinked or a spur formed. It should be sewed only to the peritoneum. This is to insure free passage onward for the duodenal juices. The line of sutures for burying the catheter is fastened to the anterior abdominal wall (Fig. 1372).

Robson short-circuited a loop of jejunum by entero-anastomosis (7.5 to 10 cm. (3 or 4 inches) from the summit of the loop; a small catheter is then introduced in a purse-string at the summit and passed into the distal arm beyond the anastomosis; and the fistula with the tube is then sewed to the skin (Fig. 1373). If a still shorter operation is indicated the tube may be introduced and the bowel sewed to the peritoneum, without an anastomosis

being made. Maydyl cut the bowel completely across, and implanted the proximal end into the side of the bowel below the distal end. The latter is then sewed to the skin (Fig. 1374).

These operations are done through the rectus muscle, just above the level of the umbilicus, on the left side. The catheter is No. 12 F. Fine linen suture may be used. The opening is made 30 or 45 cm. (12 or 18 inches) from the duodenum. The catheter must be kept in or the opening will close. If it comes out it must be replaced. Liquid feeding may be begun at once.

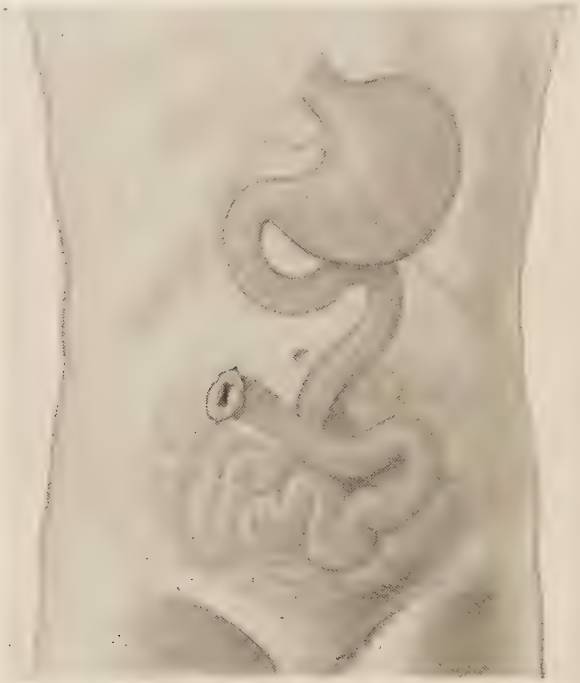

Fig. 1374.—Jejunostomy with Lateral Implantation.

The jejunum is divided. The cut end of the distal limb is implanted in the abdominal wall. The cut end of the proximal limb is implanted in the distal limb by end-to-side anastomosis.

THE STOMACH

Anatomy.—The stomach lies in the epigastric and left hypochondriac regions. Above and in front are the diaphragm, left and quadrate lobes of the liver, anterior abdominal wall, and cartilages of seventh, eighth and ninth ribs. Below and behind are the diaphragm, great vessels, spleen, pancreas, fourth portion of duodenum, splenic flexure of colon, and transverse colon and its mesocolon. The cardiac end or *fundus* reaches as high as the sixth left chondrosternal articulation, which is on a level with the fifth rib in the mammary line. It rests against the summit of the diaphragm above and behind the apex of the heart.

The *cardiac orifice* of the stomach is on a level with the seventh left chondrosternal articulation about 2.5 cm. (1 inch) from the sternum. This is the level to the left of the body of the tenth dorsal vertebra and of the tip of the spinous process of the ninth dorsal vertebra. It is about 2.5 cm. (1 inch) below the diaphragm, and about 11 cm. (4½ inches) behind the anterior wall of the abdomen.

The *pylorus* is on a level with the bony ends of the seventh ribs, the eleventh or twelfth dorsal spinous process and 5 to 7.5 cm. (2 or 3 inches) below the sterno-ensiform joint.

It lies slightly to the right of the median line. These relations are subject to great variations (Fig. 1375).

The stomach is covered everywhere with peritoneum excepting at the borders of the greater and lesser curvatures and at the triangular areas at either end. It is attached to the diaphragm by the esophagus, and to the posterior abdominal wall by the duodenum. The fundus is attached to the diaphragm by the gastrophrenic ligament, and to the spleen by the gastrosplenic omentum; the lesser curvature is connected to the liver by the gastrohepatic omentum; the pylorus and duodenum are connected to the liver by the duodenohepatic ligament; and the great omentum connects the greater curvature to the transverse colon and other structures to which it may adhere.

The structure of the wall of the stomach is similar to that of the intestine (page 621). It has the same coats. All except the peritoneal coats are thicker. The muscular coat, besides having longitudinal and circular fibers, has a layer of oblique fibers. This makes the wall of the stomach much thicker than that of the intestine.

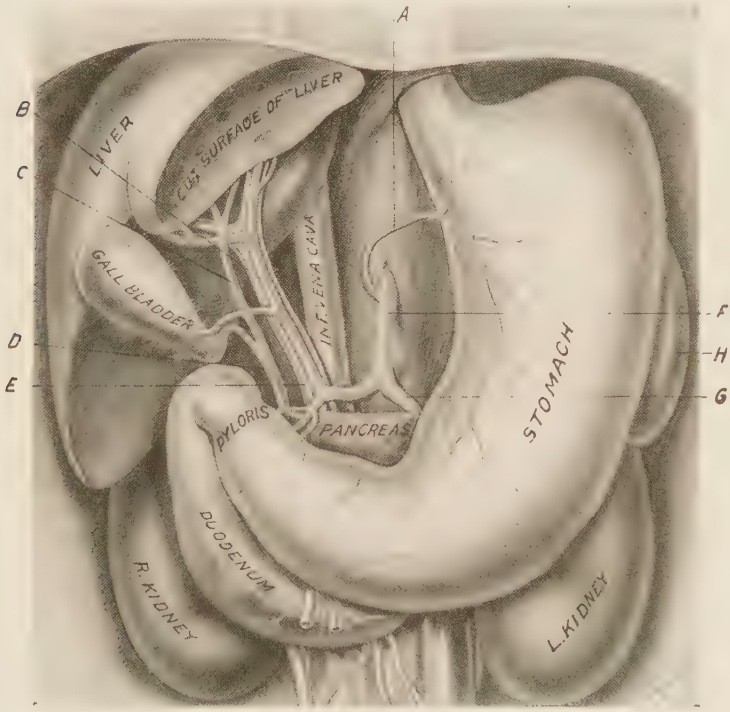

FIG. 1375.—THE STOMACH.

Showing the relations of the stomach and the adjacent organs. *A*, Left gastric artery; *B*, hepatic artery; *C*, hepatic duct; *D*, common bile-duct; *E*, portal vein; *F*, coelic axis; *G*, splenic artery; *H*, spleen. Note shape of stomach as revealed by *x*-ray.

The greater curvature crosses the abdomen about 4 cm. (1½ inches) above the level of the navel. The lesser curvature crosses in front of the first lumbar vertebra. The anterior wall of the stomach lies in contact with the anterior abdominal wall. This is a triangular area, having a transverse base line about 6.5 cm. (2½ inches) above the navel. The sides of the triangle measure about 13 cm. (5 inches) each.

The *lymphatics of the stomach* lead toward the greater and lesser curvatures, where are located between the folds of the greater and lesser omenta numerous lymph nodes. These are collected chiefly along the third of the greater curvature nearest to the pylorus, and along the lesser curvature. From these regions, the lymph vessels pass to the celiac glands lying along the aorta. The glands of the greater curvature lie along the right gastroepiploic artery. They are numerous around the pylorus, whence they pass to the liver and pancreas. The glands of the lesser curvature lie along the coronary artery from the pylorus

to the esophagus. The tendency of carcinoma is to grow toward these gland collections at the curvatures, and not toward the duodenum (Fig. 1376).

The *nerves of the stomach* are from the terminal branches of the pneumogastric and from the sympathetic branches of the solar plexus. The connection of the sympathetic nerves with the seventh, eighth and ninth dorsal spinal nerves gives the epigastric and shoulder manifestations of stomach disease. The intimate sympathetic connections of the stomach make this organ a centre of reflex disturbances referred from every region of the body.

Exposure of the stomach is secured through the incisions in the upper abdomen already described (page 504). The anterior wall of the stomach is easily brought into view. It is recognized by its thickness, compared with that of the intestine, by its being continuous with the great omentum below, by the gastrohepatic omentum passing upward, and by its pinkish-white opaque appearance. The fundus is best reached by an incision to the left of the median line.

Exposure of the posterior wall requires division of the great omentum as it hangs from the greater curvature. This is easily done by making a rent in it between its blood-vessels, and ligating any vessels which may require it. This operation gives access to the lesser peritoneal cavity between the

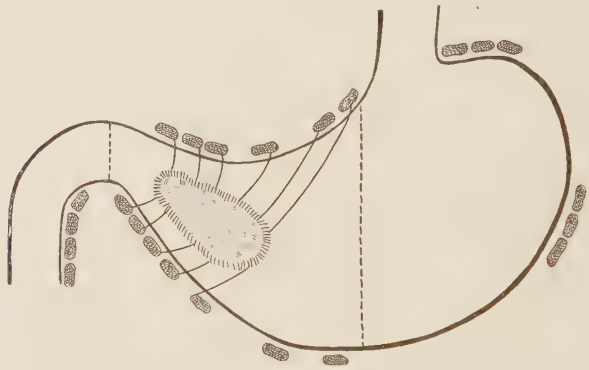

FIG. 1376.—LYMPHATICS OF STOMACH.
Showing lymphatic currents whereby cancer of the stomach is carried toward the lymphatic nodules. Dotted lines show incisions for partial gastrectomy.

stomach and transverse colon. Better access is secured by lifting up the omentum and dissecting it from the colon.

Gastric lavage (washing out the inside of the stomach) is employed to empty the stomach of its contents especially when the contents are of morbid character. The distance from the incisor teeth to the cardiac entrance of the stomach, by way of the esophagus in the average adult, is between 38 and 46 cm. (15 and 18 inches). For washing out the stomach the tube should pass 5 or 8 cm. (2 or 3 inches) beyond the cardia. The cardia is provided with a valve which prevents regurgitation of food but does not hinder the passage of objects from above downward. The most useful tube is made of soft rubber in the form of a catheter, and is called *stomach tube*. It should have two openings at the lower end. The usual stomach tube is about 1.3 to 1.8 cm. (½ to ¾ inch) in diameter and 63 to 75 cm. (25 to 30 inches) long. Such a tube is capable of reaching to the pylorus.

The stomach tube may be introduced with the patient sitting, or lying on the side or back. Before introducing a tube, false teeth should be removed. The patient should hold a basin to catch the copious flow of saliva which the tube excites. He should be instructed to breathe rapidly through

the mouth, not to strain or retch, to allow the saliva to flow out of the mouth, and not to grasp the tube. He should be told to raise the hand as a signal if he desires the operation discontinued or interrupted.

The contra-indications for lavage are acute inflammations of the esophagus, ulcer of stomach with symptoms of peritoneal irritation, advanced disease of heart or lungs, aneurism of the aorta, or advanced cirrhosis of the liver.

The surgeon should wash his hands in the presence of the patient. The patient should take a swallow of water, the tube should be taken from a basin of warm water in which it had been immersed, and the end passed over the tongue to the entrance of the esophagus. The patient should then be instructed to swallow, and as the first muscular effort at swallowing is made, the tube is pushed gently downward into the esophagus. It is then slid along until it enters the stomach. If any obstruction is met the tube should be halted. It should glide into the esophagus and stomach as though it were being swallowed. The surgeon should not think that it must be pushed in (see Esophageal Bougie, page 433).

In cases of cardiospasm there may be difficulty in passing the cardia. It may be necessary to allow some warmed olive oil to flow into the tube, or to use a silk woven tube which is stiffer than the soft rubber. Force should never be employed. All manipulations should be gentle.

When the tube has entered the stomach, warm water may be poured in by means of a funnel at the upper end. At first not more than 250 c.c. (½ pint) should be introduced. Then the upper end of the tube should be lowered below the level of the stomach over a vessel and the fluid allowed to siphon out. Following this 250 to 1000 c.c. may be poured in at a time, as the condition of the stomach warrants. It may be necessary to connect a longer tube to the stomach tube to bring the outlet lower than the level of the stomach. So much fluid that the patient has a sense of uncomfortable distention should not be poured in.

Instead of plain warm water, salt solution or boric acid solution may be used for special conditions. Usually plain water is best. The irrigation may continue until the fluid returns clear. The removal of the tube is easy.

Rarely cocainization of the pharynx may be necessary at the beginning of the first operation. Patients soon become accustomed to the tube and pass it themselves. The hands should be washed always before the operation.

Lavage is a most useful measure in the treatment of intestinal intoxications in which intestinal contents are regurgitated into the stomach. It is most useful in intractable vomiting of intestinal toxic origin. In acute dilatation of the stomach, of course, the contents are allowed to run out before water is poured in.

Duodenal lavage is practised by the gastroenterologists. The skillful operator can pass a tube, by way of the mouth, esophagus and stomach, into the duodenum. This permits of irrigation and treatment of the duodenum. The tube used is preferably of smaller caliber than the ordinary stomach tube. Through such a tube food may be introduced and *enteric feeding* practised. J. T. Pilcher (Long Island Med. Jour., June, 1914) advocated this measure as practicable in the treatment of certain cases of ulcer of the stomach.

Continuous gastric lavage is useful in cases of toxemia of peritonitis or intestinal obstruction, and in persistent vomiting. The tube used is of the type employed for duodenal irrigation. It should be of small caliber with a bulbous enlargement at the end. It should be introduced in the stomach, and fastened to the chin by adhesive plaster. Connected with the

stomach tube should be another tube passing down to a vessel below the level of the bed. The end of this tube should be under water. After the patient's stomach has been washed out the tube is left in place. By keeping the end under water, siphon action is secured and as fast as the duodenum pours fluid into the stomach it runs out through the tube. At frequent intervals the stomach may be washed out with soda solution or other fluid. Patients tolerate it well. A. B. Kanavel (Surg., Gynec. and Obst., October, 1916) who advocated this method, employed it in connection with continuous hypodermoclysis. The method may be used with continuous proctoclysis. Actual continuous irrigation may be practised by using a double tube, having one opening 8 cm. (3 inches) from the other, and permitting water to flow in and out of the stomach continuously.

Wounds and Rupture of the Stomach.—Perforations of the stomach are treated the same as in the intestine (page 566).

Inflammations.—*Gastritis due to caustics*, such as is caused by swallowing caustic fluids, must be treated according to the nature of the poison. Emptying the stomach, administering antidotes, and diluting the poison should be practised at once. Ulcer and scar contractions should be prevented as much as possible by (1) asepticity and by (2) prohibiting food by mouth. The mouth should be cleansed, antiseptic washes used and only sterile substances taken into the mouth (see Preparation for Operations on the Intestine, page 564, for methods for gastro-intestinal asepsis). At first food should not be given by mouth; the patient should have nutrient enemata. After a few days sterile fluids may be given by mouth. So long as epigastric pain and tenderness are present, solid food is best not given. In cases with ulceration or sloughing of the mucous membrane of the mouth, esophagus, and stomach, it is often best to make a high fistula in the jejunum, for feeding purposes. Through this the patient may be fed foods which have been treated with salivary and gastric ferments. Such a fistula should be made in the antimesenteric side of the bowel, after the method of a gastrostomy (pages 683 to 697).

Phlegmonous gastritis (suppuration in the stomach wall), because of the difficulty of diagnosis, is not apt to have surgical treatment promptly applied. Operation should be done, the stomach exposed, and the phlegmon incised. Diffuse cellulitis of the stomach wall is best treated by incisions down to the submucosa and drainage, just as for cellulitis elsewhere. R. W. Westbrook (Long Island Med. Jour., N. Y., December, 1916) operated upon such a case of a very acute type by incision and drainage.

Tuberculosis and syphilis of the stomach should be treated as elsewhere.

Cirrhosis of the stomach (plastic linitis) should receive internal treatment. When contracture of the stomach, pain, tenderness and vomiting, cause emaciation, operation is indicated. Gastroenterostomy has given relief. Often these cases are not true cirrhosis, but diffuse carcinoma. If gastrectomy cannot be done, and gastroenterostomy is not advisable, the patient may be given immediate relief by jejunostomy (page 697).

Perigastric adhesions which bind the stomach and give rise to symptoms, especially pain, should be divided and the stomach permitted to drop into normal position. When the adhesions are firm, care must be taken in their division, and after they have been divided, an inspection should be made for perforation. This is important because a large proportion of these cases have ulcer of the stomach or duodenum as the cause of the adhesions, and often the adhesions represent a plastic deposit which closed a perforation. Such perforations may be very small and not easily discovered. They should

be closed with a suture. If it is believed that an ulcer still exists, gastroenterostomy should be done.

To prevent the reformation of adhesions, an edge of omentum may be caught with a couple of sutures so that it is interposed between the previously adherent surfaces. While this does not really prevent adhesions, it does interpose tissue which is freely movable and capable of making a very loose connection. Other expedients for preventing adhesions have been discussed (see Peritoneal Adhesions, pages 515, 520 and 600).

Tumors of the Stomach.—*Benign tumors* of the stomach are uncommon. *Adenoma*, when sessile, should be excised and the wound closed. When the pylorus is involved the tumor may be removed by an incision placed in the direction of the axis of the bowel so that it can be closed transversely in order not to restrict the lumen. In the case of a larger tumor, pylorectomy may be required. Pedunculated tumors may be ligated and cut off. Such tumors may occlude the pylorus, and care should be taken to recognize them before an unnecessary pylorectomy or gastroenterostomy is done. *Myoma* should be removed. Unless this is done the tumor may reach a large size. *Lipoma* should be treated the same. *Cysts* should receive the same treatment as in other parts of the body. All benign tumors, even though they do not cause pain or obstruction, may give rise to ulceration of the mucous membrane and hemorrhage, and for this reason their removal is indicated.

Sarcoma of the stomach appears in several varieties. The treatment consists in wide extirpation. Partial or complete gastrectomy must be done.

Carcinoma of the stomach is amenable to surgical treatment and can be cured, when recognized early enough. Perfection in treatment must be aimed at because of the great prevalence of the disease; nearly one-third of all cancers occur in the stomach. Extirpation of the part of the stomach bearing the disease offers the only hope. Unlike the outer parts of the body, carcinoma developing in the stomach cannot be palpated at an early stage. Its presence can only be suspected at first. Patients, who during the cancer period, have loss of appetite, food stagnation in the stomach, gastric discomfort, and loss of weight, or the other less characteristic signs, should be subjected to stomach examination. If there is a diminution of digestive power, absence of free hydrochloric acid, food remnants found remaining longer than twelve hours, carcinoma should be suspected, and an exploratory operation done. Remnants of food are found in over 50 per cent. of cases. This is the most important indication for operation next to tumor.

The surgeon should not wait until the diagnosis can be made without question, for at that stage the disease is rarely curable. In the present state of diagnostic power, operation to be successful must be undertaken in the presence of some considerable doubt as to the diagnosis. If no tumor can be palpated and the diagnosis is not positive, the operation should be begun as an exploration. This can be done under local anesthesia. Everything for major operation should be ready. An opening through the abdominal wall, large enough to admit one or two fingers, is made in the epigastrium, opening the peritoneum to the left of the suspensory ligament of the liver. This permits palpation of the stomach and liver. If operable carcinoma is found, the operation necessary for its relief proceeds at once. If no carcinoma is found an opening large enough to admit the whole hand, and even to permit inspection, must be made in order to clear up questions of doubt. If still the disease cannot be discovered, surgery has registered a triumph; for the patient would have had the benefit of early operation had cancer been present. Diagnosis of the absence of cancer, in the presence of suspicious symptoms, is more useful to the patient than operation for cancer;

and the surgeon should find more satisfaction in the patient's good fortune in being without cancer than in his own skill in confirming a diagnosis of that disease.

If inoperable disease is found, the wound may be closed, and the patient soon returned home. If the wound must be enlarged to admit the hand, general anesthesia will be required.

In cases in which a tumor is present which is easily felt through the abdominal wall, operation should not be denied the patient. If it is found that it cannot be removed, relief may be given by a gastroenterostomy. If so much of the stomach is involved that this cannot be done, jejunostomy may be employed to prolong life and secure relief from hunger. Incurable growths in the cardiac end of the stomach may be given relief by gastrostomy which will prevent the patient from starving to death.

The operations, then, depend upon the stage of the disease. If the disease is still confined to the stomach wall, gastrectomy (partial or complete), sufficiently wide to clear the growth, is to be done. If the disease occludes the pylorus (partially or completely), if ulcerations or stagnation of food are present, gastroenterostomy is to be done provided the growth has extended beyond the possibilities of extirpation and provided there is enough healthy stomach wall proximal to the disease for the operation. If the extent of the disease is so great that neither of these operations can be done, jejunostomy is indicated. Gastrostomy is indicated in incurable growths in the region of the cardiac orifice.

It can rarely be said that the condition of the patient is so bad that operation could not be borne. None of these operations is so hard for the patient to bear as carcinoma of the stomach is. The palliative operations (gastroenterostomy, gastrostomy, jejunostomy) can all be done under local anesthesia, if needs be; and, if the suffering from inanition is serious, food may be given at once. The depression from these operations need not be considerable.

The only curative operation (partial or complete gastrectomy) is not a much more serious matter. The disease is so infinitely more serious that in all cases, in which the operation offers any hope, it should be undertaken.

Without operation, the disease terminates fatally in about a year from the onset of symptoms. With gastro-enterostomy life is prolonged about three months. Gastrectomy, if followed by recurrence, prolongs life about twelve months. The operative mortality in the hands of the average surgeon, following gastro-enterostomy for cancer, is about 15 per cent. Partial gastrectomy gives about the same mortality. In the hands of the highly skillful and experienced operators the figures are lower than this; in the hands of the less skillful they are higher. Death is from shock, peritonitis, or pneumonia.

Recurrence takes place in the majority of cases after gastrectomy; but even though it does, the patient has been relieved of an ulcerating, sepsis-breeding tumor, and life is prolonged and made more comfortable. Many surgeons are favoring gastrectomy even as a palliative measure, especially since its mortality is not much greater in this disease than that of gastro-enterostomy.

In performing gastrectomy, not only the primary cancer but the lymph-nodes, first in the line of lymphatic drainage, should be removed. This is a most important consideration of the operation and the surgeon should have well in mind their location.

In cases suffering with obstruction to the exit of food from the stomach, toxemia from fermentation of gastric contents, and inanition, gastro-enteros

tomy may be done; and after two or three weeks when the general condition has improved, partial gastrectomy may be performed.

It may be said that the surgical treatment of cancer of the stomach is as satisfactory and successful as that of cancer in other parts of the body. It will be more satisfactory when surgeons are willing to operate before a positive diagnosis is waited for. Positive diagnosis is not often made in time to guarantee a cure of the disease by operation. Operation should be done before the signs due to cancer itself are manifest. The indications for operation should be based on the functional disturbances which a beginning cancer produces.

The presence of a palpable tumor is not a sign of hopelessness in all cases. If the tumor is movable the case may be a very hopeful one. If the tumor is associated with early obstruction, meaning that it is at the pylorus, it may not have advanced very far; and a surgical cure may be hoped for. The fact that 75 per cent. of cancers of the stomach are at the pylorus makes early diagnosis more possible. Tumor and the symptoms of obstruction are the signs which indicate operation in many cases.

Unfortunately cancer of the body of the stomach, not involving the orifices, is rarely diagnosed early enough for a curative operation. Cancer of the cardiac orifice causes early obstruction, but its complete removal is more difficult than cancer of the pylorus.

The patients who are saved are largely in the category of those operated upon as an exploratory measure with only a tentative diagnosis. Patients submitted to exploratory operation under present conditions, W. J. Mayo says, with a probable diagnosis of cancer of the stomach, have a little over one chance in three of a radical operation being done at all, a little less than one chance in three of a palliative operation, and about one chance in three that the operation will be merely an exploration and nothing more.

In some cases the transverse mesocolon will be found involved in an otherwise hopeful case. Under such circumstances resection of the mesocolon should be added to the stomach operation. In other cases resection of a portion of colon may be necessary. The same may be said of the pancreas. The involved part of the pancreas may be removed, the stump of the duodenum closed with suture, and the closed end of the duodenum planted into the defect from which the pancreatic tissue was removed.

The means for restoring the continuity of the gastro-intestinal tract must depend upon the conditions in each case. Usually after removal of part of the stomach, the next step best taken is closure of the duodenum and stomach and the performance of an independent posterior gastrojejunostomy. If the remaining portion of the stomach is small, anterior gastroenterostomy may be done without making a new stomach opening.

It is well to consider doing a gastrojejunostomy as the first step in the operation if the patient is suffering from extreme malnutrition. After two or three weeks, when the patient is in better condition, the resection of the cancerous stomach may be done more safely. This method is rarely indicated because the risk of doing the complete operation at one stage is not much greater.

In certain doubtful cases gastrojejunostomy may be done. Such cases are tumor of the pylorus of doubtful character. If the tumor is inflammatory, it will subside; if malignant, secondary operation may be done. Some ulcers may be doubtful in their etiology; in such cases the palliative operation may be performed.

Gastrostomy is useful in cancer of the region of the cardiac orifice, which is not amenable to cure and which causes or threatens obstruction. Even

when obstruction is not threatened, it is often desirable to do a gastrostomy, placing the tube in such a position that it may easily be passed through the pylorus. With such an operation it is possible at feedings to pass the tube into the duodenum, and thus practise intestinal feeding, leaving the stomach at rest. Food that has been subjected to ptyalin, pepsin and hydrochloric acid digestion is injected into the duodenum. The stomach may be entirely protected from contact with food. It may be washed out through the tube and treated with medicated solutions. By this method it is possible to keep the patient well nourished, an ulcerating cancer clean and the stomach free from fermentation.

In such cases jejunostomy is often useful instead of gastrostomy; but it is especially in inoperable cancer of the body of the stomach in which gastro-enterostomy cannot be done, that it is called for. This operation gives rest to the stomach.

At the Mayo clinic cancer of the pyloric end of the stomach is recognized sufficiently early to do a resection of the stomach in fully 50 per cent. of the cases. The mortality of operation is about 10 per cent. In cases in which early diagnosis is made and operation done while the patient is in good condition the mortality is kept below 5 per cent. Of the cases which survive operation, 25 per cent. enjoy apparent immunity from recurrence for five years, and 38 per cent. remain well for three years. Few patients who recover from the operation have less than a year of relief.

Cancer infection, transplanted upon a raw surface or upon the peritoneum, must be guarded against in all operations for abdominal cancer. Rough handling should be avoided, and cancerous tissue when exposed should be kept covered with gauze pads. A knife which has cut through cancerous tissue should be sterilized before it is used to cut healthy tissue.

Inoperable abdominal carcinoma should be recognized before the abdominal incision is enlarged. The first incision should be long enough to admit only the exploring fingers. If it is then found that operation is not indicated, the small abdominal wound should be closed, the dressing reinforced with adhesive plaster, and the patient gotten up out of bed in a few days. The inoperable case that is operated upon and then kept in bed for a week or two has little hope of ever getting up again.

Hour-glass Stomach.—When the disease is due to ulcer, perigastritis or other benign condition, and gives rise to symptoms, operative treatment is indicated. These cases are not always simple, and an examination should always be made for other constrictions. Stenosis of the pylorus may exist at the same time, and demand pyloroplasty, pylorectomy or gastro-enterostomy in connection with the operation for the hour-glass stomach. It is important that a gastroplasty alone shall not be done in a case in which there is obstruction beyond.

Gastroplasty gives the best results in cases in which there is no ulcer, in which the constriction is near the center of the stomach, and the pylorus is not obstructed. This operation is curative. Dilatation of a stricture in these cases is not apt to give permanent results.

In cases of extreme constriction, gastrogastrostomy is sometimes done. For hour-glass stomach, combined with pyloric stenosis, a gastro-enterostomy, with an opening from each sac into the jejunum, was recommended by Weir and Foote (Medical Press, 1896).

In cases with ulceration present, the ulcerated wall of the stomach may be excised as a part of the pyloroplasty. This gives an opportunity to observe the patency of the pylorus. Such ulcerations may show distinct marks of malignancy, and a wider and curative operation may be done.

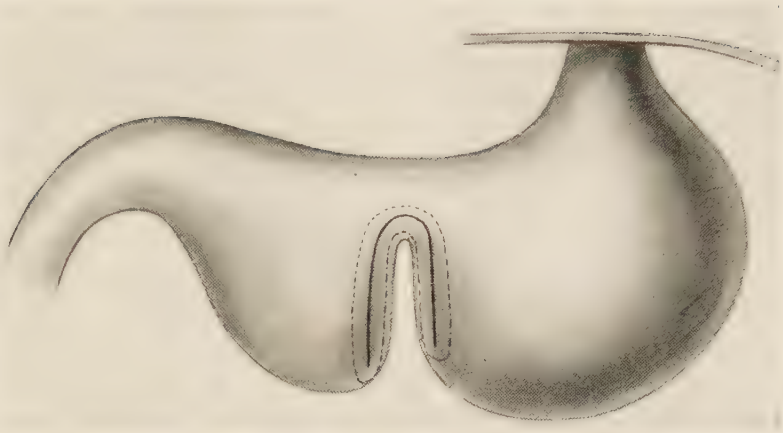

FIG. 1377.—GASTROPLASTY FOR HOUR-GLASS STOMACH.

The dotted line shows the place of the seromuscular suture. The stomach is incised along the heavy line. The posterior half of the suture is applied before the incision is made.

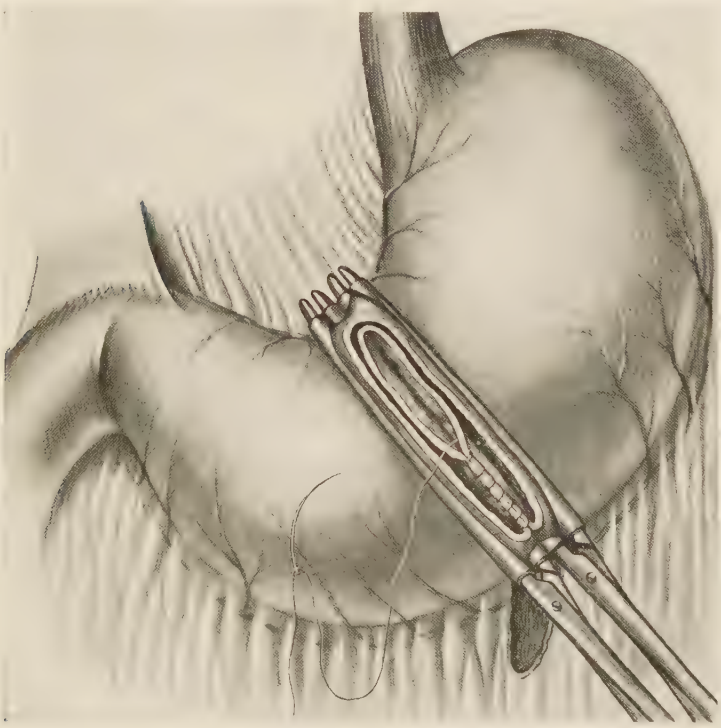

FIG. 1378.—GASTROPLASTY FOR HOUR-GLASS STOMACH.

Clamps are placed by making a small opening in the great and small omenta. The posterior seromuscular suture has been applied. The through-and-through suture is being introduced.

FIG. 1379.—GASTROPLASTY FOR HOUR-GLASS STOMACH.
Showing result after operation.

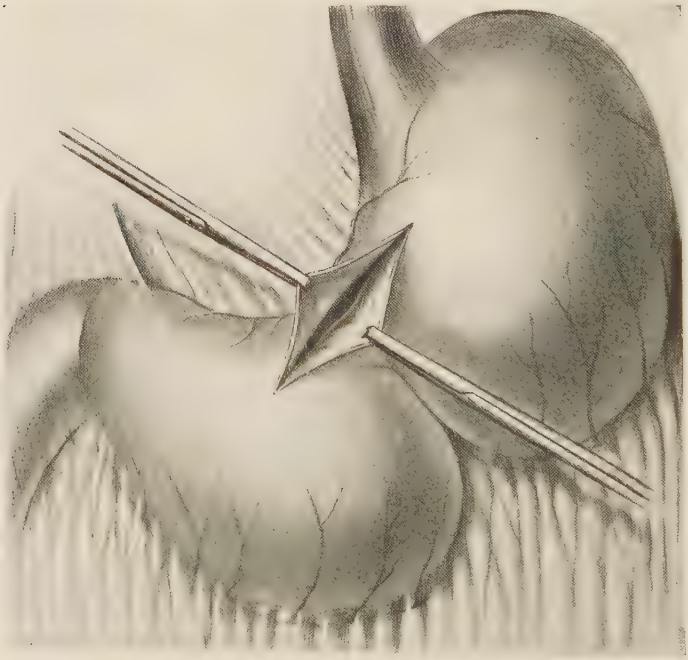

FIG. 1380.—HOUR-GLASS STOMACH TREATED BY CONVERTING TRANSVERSE INCISION INTO A VERTICAL INCISION.

Transverse incision has been made and a hemostatic clamp applied in the middle of each lip of the wound.

In order to make no mistakes, the whole stomach from cardia to pylorus should be inspected, as it might happen that gastro-enterostomy may be done at the distal pouch, a proximal pouch not being recognized. The surgeon should bear in mind that there may be more than two sacculations.

Gastroplasty for hour-glass stomach is best performed after the method of simple lateral enteroanastomosis with two layers of sutures. Clamps are applied as for resection of the middle portion of the stomach. The first half of a continuous seromuscular suture is applied with a curved needle, connecting the two sacks to be united just posterior to their nearest points (Fig. 1377). An incision, having the form of an inverted U, is then made through the wall of the stomach, and its edges united throughout by a continuous suture (Fig. 1378). When the through-and-through suture has

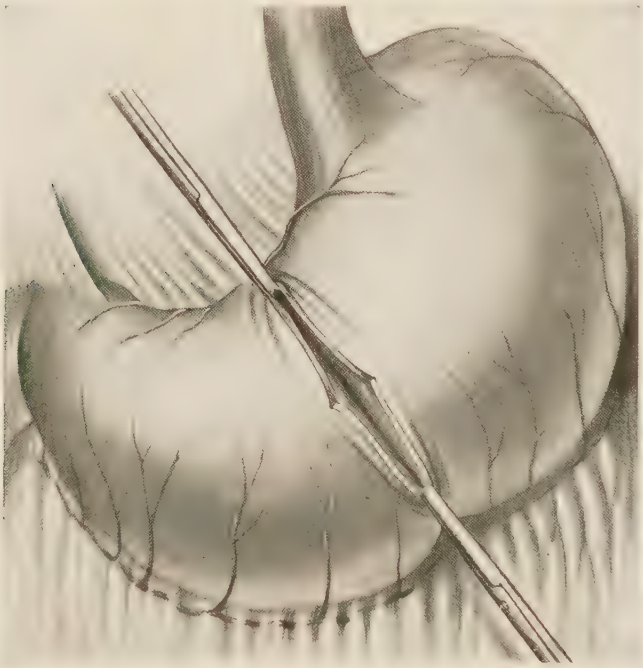

FIG. 1381.—HOUR-GLASS STOMACH TREATED BY CLOSING TRANSVERSE WOUND VERTICALLY. The wound is in position to be sewed.

been completed, the anterior half of the seromuscular suture is taken in hand and finished. By carrying the sutures and incision to the bottom of the two sacks, the continuity of the greater curvature is restored without interruption (Fig. 1379). If adhesions interfere, the use of clamps may be omitted.

In cases in which the contracture sulcus is less marked, *gastroplasty by a transverse incision*, closed vertically, may be done. A transverse fold of stomach, above the sulcus, is grasped by a clamp, and an incision made through the wall parallel with the lesser curvature. A small hemostat is applied in the middle of each lip of the wound and one at either extremity, not grasping mucosa (Fig. 1380). The stomach clamp is then removed, the first two hemostats separated from one another as far as possible, and the

stomach clamp reapplied at right angle to its first position. The four hemostats in the hands of two assistants help to adjust the incision in line. The wound is sutured in such a way that the two extremities of the incision are brought together, and the middle of each lip becomes the extremity (Fig. 1381). The hemostats are removed, the redundant mucous membrane is trimmed off, and the edges of the wound united by a through-and-through suture. When this is completed the clamp is removed, to be sure that bleeding has been controlled, and an outer seromuscular suture inserted.

For cases in which there is pyloric stenosis of an intractable character, gastroenterostomy with an opening from each sac into the jejunum, as advised by Weir and Foote, is to be recommended. This operation is of especial value in cases with ulceration of such a character, as to preclude excision (Fig. 1382).

Gastroptosis.—This condition should not be regarded as surgical until medical and hygienic treatment have failed (see Enteroptosis, page 616). In most cases, operation is not required. Correction of the faults of bad

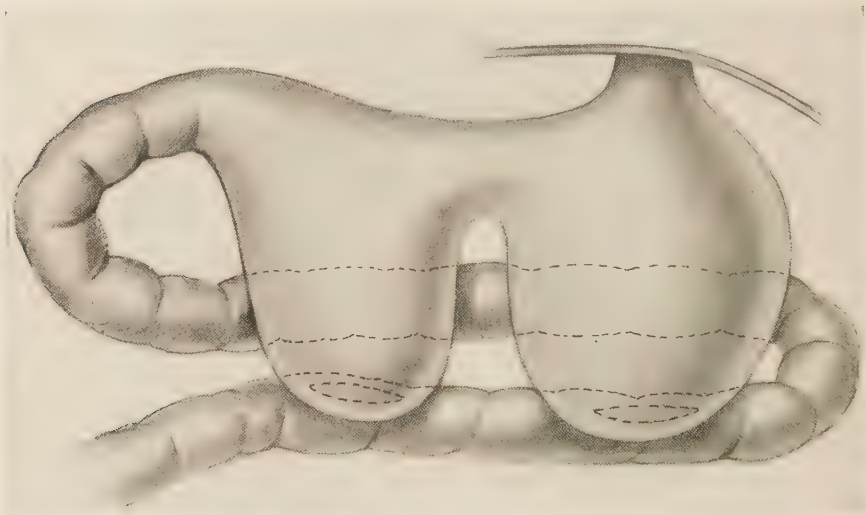

Fig. 1382.—Hour-glass Stomach Treated by Double Gastrojejunostomy.

living usually suffices for a cure. Abdominal massage and gymnastic exercises to strengthen the muscles of the abdominal wall are sometimes required. The avoidance of excessive fatigue and badly fitting clothes is important. Intrinsic diseases of the stomach, such as catarrh, pyloric stenosis, and atony, should receive their especial treatment. The patient should be fattened, if lean. Small meals more frequently are better than large meals.

Cases not amenable to the above measures may have their symptoms relieved by wearing a broad band across the abdomen to make backward pressure. Adhesive plaster strapping is used for this purpose. These expedients are not to be employed to the exclusion of exercises in cases in which there is hope of restoring the natural tone of the parts, as they are not curative but palliative, and tend to weaken the muscles which they supplement.

In women who have not had children, the abdominal walls are so firm

that pads and bandages cannot be made to exert enough pressure to affect the prolapsed viscera. The majority of cases in women who have borne children can be helped by a pressure pad. The pressure must be widely distributed over the hypogastrium; and it must be strong and constant. Such a pad may be made by a truss-maker; it should have a steel-spring belt on either side and a counter-pressure pad at the back (Figs. 1383 and 1384).

The pad should be applied as the patient lies on her back with the head of the bed lowered. The pelvis should be elevated to cause the abdominal contents to fall toward the diaphragm. The patient should take the exercises which strengthen the abdominal muscles. The pad need not be worn at night, but should be adjusted before the patient arises.

If these methods fail gastropexy is indicated. It should always be borne in mind that prolapse of the liver, kidneys and intestines, one or more, is

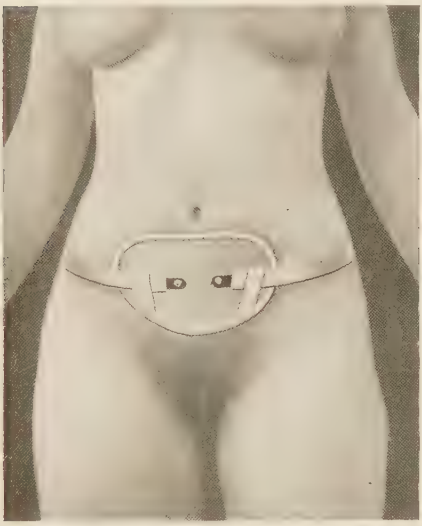

Fig. 1383.

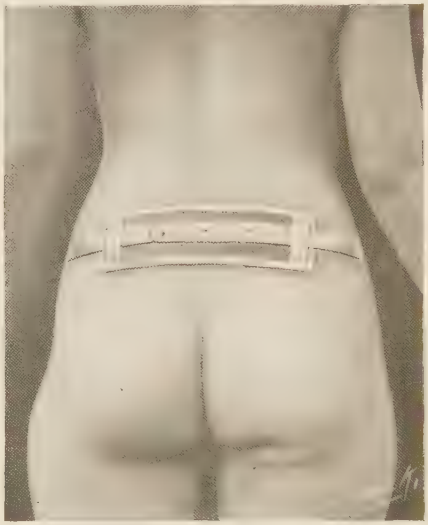

Fig. 1384.

Fig. 1383.—Gastroptosis Pad (Front View).
Fig. 1384.—Gastroptosis Pad (Rear View).

apt to be associated with gastroptosis and require treatment at the same time (see Enteroptosis, Hepatoptosis, and Nephroptosis; also Adhesive Plaster Strapping of Abdomen, page 520, Fig. 1197).

Gastropexy, for supporting the prolapsed stomach, may be done by one of several methods. The best of these consists in *shortening the suspensory ligament* of the stomach. This operation was suggested by H. D. Beyea (Univ. Penn. Med. Bull., February, 1903; Am. Med., viii, 1904). The abdomen is opened by an incision 7.5 cm. (3 inches) long in the median line, midway between the ensiform and the navel. The lesser curvature of the stomach and the lower surface of the liver are exposed. The gastrophrenic and gastrohepatic ligaments are then shortened by means of four or five rows of continuous sutures, throwing the ligament into folds. The sutures extend from the cardia to the pylorus, involve only the suspensory ligament, and when tied elevate the stomach as high as possible (Fig. 1385). Although the gastrohepatic omentum is thin and delicate, its folding in this

manner is sufficient to hold up the stomach. The results of this operation have been most gratifying.

Duret sewed the upper part of the anterior wall of the stomach to the peritoneum of the anterior abdominal wall. Coffey sewed to the abdominal wall about 2.5 cm. (1 inch) above the umbilicus, a transverse line of great omentum just below the stomach.

In some cases with dilatation, atony and hematemesis, gastro-enterostomy is required, but usually the operation of Beyea may be depended upon to cure these symptoms.

The operation done by T. Rovsing is as follows: Three strong silk sutures are passed in and out through the serosa of the anterior wall of the stomach

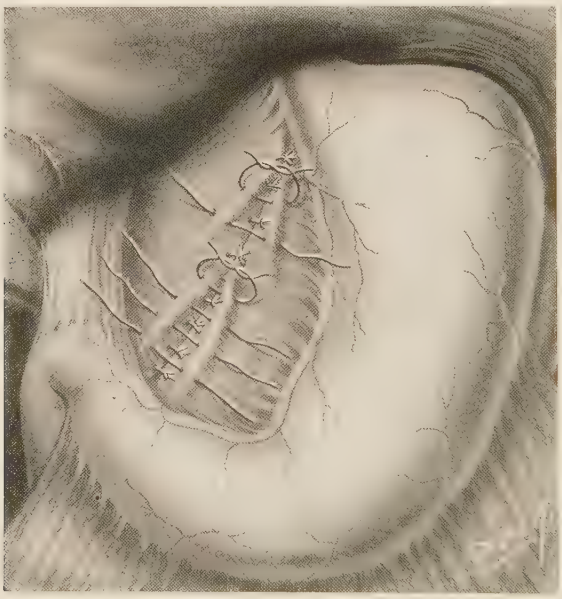

Fig. 1385.—Operation for Gastroptosis.
The first layer of sutures has been inserted. The second and third layers are in process of application.

parallel with the lesser curvature. The upper thread is just below the lesser curvature. The others are about 2 cm. (¾ inch) apart. The regions of the greater curvature and pylorus are not included. The serosa between the threads, the parietal peritoneum and the under surface of the liver to which it is desired that the stomach should adhere, are scarified with the point of a knife. The sutures are then passed through the entire thickness of the abdominal wall. The left ends are brought out at the rib margin, and the right ends about 3 cm. (1¼ inches) to the right of the median line (Fig. 1386). The abdominal wound is then closed, and the silk sutures are tied over a glass plate which is a little broader than the scarified stomach surface and which lies on a gauze pad between it and the skin. This holds the stomach surface flatly to the abdominal wall. The threads are removed at the end of four weeks (Fig. 1387).

Hepatopexy should be done at the same time if necessary. If the left lobe of the liver is greatly hypertrophied, it must be removed to prevent press-

ing down upon the stomach. Nephropexy must also be done if necessary. Gastro-enterostomy does these patients more harm than good. If enteroptosis is present, it also must be remedied, as there is no comfort in having one's stomach hung up in the attic while his bowels are left lying on the basement floor.

It happens in some of these cases, particularly in nulliparous women, that the hypogastric region is so constricted that it is difficult to press the stomach up in place. In these it becomes necessary to enlarge the hypogastric region of the abdomen. This was done by Rovsing by splitting the recti muscles and turning inward as a muscular flap a segment of the anterior part of the bellies of the muscle together with the anterior sheath. The anterior sheath in the new wall segment is brought to lie upon the peritoneum (Fig. 1388).

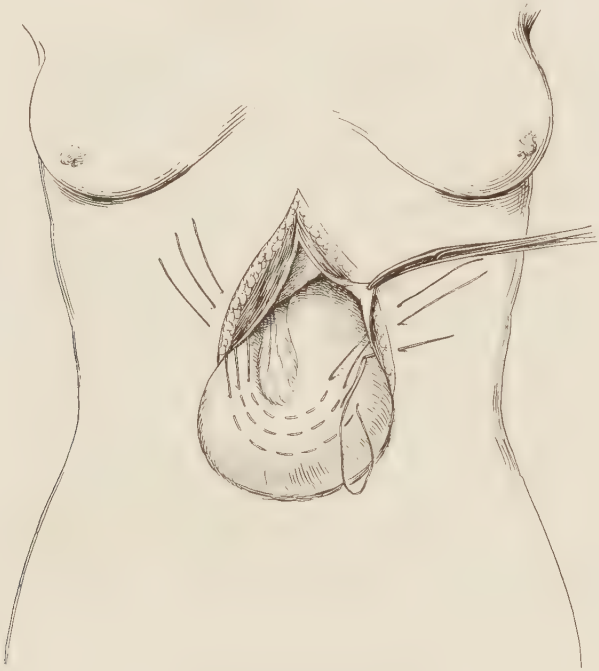

FIG. 1386.—GASTROPEXY.
Method of Rovsing. The stomach sutures are applied, the ends passing through the abdominal wall.

In all cases in which the *gastrocolic ligament* is elongated, permitting sagging of the *transverse colon*, it should be shortened. This is much better than doing a colopexy. The shortening is a very simple matter and is accomplished by turning up the colon and carrying six or eight rows of plicating sutures along the posterior surface of the gastrocolic ligament. The sutures should catch the greater curvature of the stomach (Fig. 1389).

Dilatation of the Stomach.—*Chronic atonic dilatation*, not due to obstruction at the outlet of the stomach, should receive medical and hygienic treatment. Rarely these measures fail. When they do, gastroplication or gastro-enterostomy may be resorted to. The first is an operation practically without risk and is worthy of trial. Gastro-enterostomy gives drainage

of the stomach, puts an end to stagnation, and permits the restoration of the normal functions.

Gastroplication consists in suturing the anterior wall of the stomach into one or more folds to take up the relaxed structures. The posterior wall is not sutured. Care should be taken that the sutures do not come near enough to the orifices of the stomach to cause obstruction. These operations were developed by Bircher and Weir. The stomach wall may be thrown into multiple folds (Fig. 1390) or one fold (Fig. 1391).

The stomach is exposed by a median incision between the ensiform and the navel. Sutures of chromicized catgut are passed through the seromuscular coats so as to cause folds parallel with the long axis of the stomach. In aggravated cases, having a greatly relaxed posterior wall, Gould favored gastro-enterostomy in connection with gastroplication.



Fig. 1387.—Gastropexy.
The wound is dressed and the sutures have been passed and tied over a gauze-covered glass plate.

Acute dilatation of the stomach, not due to pyloric obstruction, should be treated the same as *acute post-operative dilatation* (see page 615).

Foreign Bodies in the Stomach.—A single foreign body small enough to pass through the esophagus will usually pass through the pylorus and the intestinal canal. Such bodies sometimes require to be removed by operation because of cicatricial narrowing of the pylorus. Another class of bodies is made up of impacted masses of small articles, which become felted together into a ball of such size that it can only be removed by gastrotomy (see Gastrotomy, page 730). Such bodies should not be confused with tumor. When a foreign body is known to be passing through the bowel, the feces should be examined to determine its exit, and the surgeon should be prepared to operate for acute intestinal obstruction, should it become lodged (Fig. 1392).

Bodies with sharp points or edges are more serious. A needle should not

be permitted to pass through the gastrointestinal tract, but having been located by the *x*-ray should be removed by gastrotomy or gastroscopy. Pins are much less dangerous because the head usually goes first. If, however, the *x*-ray shows that the pin is not moving forward it should be removed. A sharp object, such as a tack, a pin, a sharp-edged piece of bone, metal or glass, which is small enough to pass through the pylorus may be treated by administering 7 to 15 Gm. (2 to 4 drams) of absorbent cotton, shredded out and drunk in glass of milk. If this is followed in an hour or so by a saline laxative the foreign body will usually be passed enveloped in the cotton. Or the cotton may be followed by some coarse food, such as potatoes, lettuce or spinach, to further envelop the foreign body.

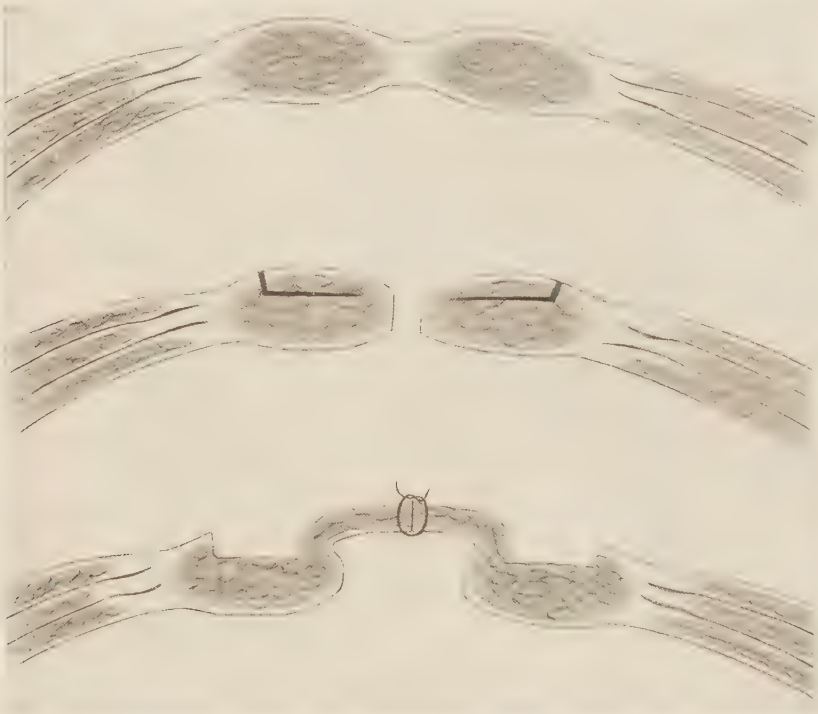

Fig. 1388.—Method of Enlarging the Abdominal Wall.
This method of Rovsing, for enlarging the abdominal wall by turning inward flaps from the recti muscles, is applicable to cases of virginal ptosis with tight muscles.

Volvulus of the Stomach.—If there is great distention, the stomach should be emptied and washed out through a stomach tube. If the tube cannot be passed, the distention must be treated after opening the abdomen. If the greatly distended stomach cannot be replaced it must be aspirated and emptied. The condition demands immediate laparotomy and untwisting of the stomach supports. To prevent recurrence, shortening of the gastrohepatic omentum, as for gastroptosis, should be done.

Stenosis of the Cardiac Orifice.—When due to cicatricial contracture, the treatment is the same as that of stricture of the esophagus (page 433) (see Cancer of the Esophagus, page 445; Operations on the Lower End of the Esophagus, pages 459, 756). Tumors of the cardiac end of the stomach are

to be treated by resection of the diseased segment and anastomosis of the esophagus to the remaining part of the stomach. Gastrostomy or jejunostomy is a last resort to prevent starvation (see Cancer of Cardia, page 756).

Cardiospasm should be treated by removal of the cause. Otherwise the same treatment as for spasm of the esophagus is indicated (see Spasm of Esophagus, page 442).

These cases may be relieved by operation as for stenosis. Dilatation proves effective in most cases. It is best done by means of the rubber dilating bag. This method has been worked out most successfully by H. S. Plummer (Northwestern Lancet, September, 1906). The method is simpler and more effective than gastrotomy or the introduction of dilating forceps from below. Mechanical stretching is the operation of choice. Some cases refuse to yield

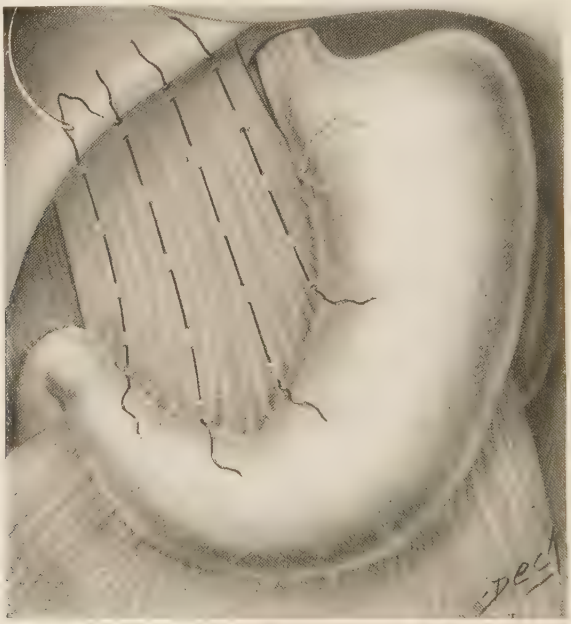

Fig. 1389.—Shortening the Gastrocolic Ligament for Gastroptosis. This operation is to be preferred above gastropexy. The shape of the stomach here shown is that which is determined by radiography.

to treatment by stretching, and other operation becomes necessary. W. Meyer (Am. Jour. Surg., June, 1912) in such a case opened the thorax, isolated the two pneumogastric nerves, and in doing so tore away the fine branches going to the esophagus. The dilated esophagus was reduced in size by esophagoplication. The patient was cured. He also performed cardioplasty successfully for intractable cases.

To *approach the cardia* for operation at the diaphragm, a median incision is made from the ensiform cartilage to the umbilicus. This is joined by a transverse incision about 2.5 cm. (1 inch) above the umbilicus extending to the tip of the ninth rib. The ninth, eighth and seventh ribs are divided near their cartilages through short incisions through the skin, a separate incision being made for each rib. The pleura should not be opened. The triangular flap of abdomen and chest wall is turned upward and outward. The left

lobe of the liver is drawn downward and to the right and the left lateral ligament of the liver is divided. This frees the liver from the diaphragm and exposes the region of the cardiac orifice. By drawing the stomach downward and to the left the esophagus may be drawn down through the diaphragm. By incising the diaphragm toward the right from the esophageal orifice the esophagus may be liberated and its lower end drawn into the abdomen.

Pyloric Stenosis.—*Congenital atresia* of the pylorus proves fatal because of the difficulty of recognizing the condition in time to apply successful treatment. If recognized early pyloroplasty or gastroenterostomy may save life.

Pyloric stenosis of infancy (wrongly called congenital hypertrophic stenosis), usually occurring in infants a few weeks old, should be treated at first by washing out the stomach once or twice a day with sterile water. For irrigation bicarbonate of soda solution 1:160 is useful. The water should have a temperature of 44°C. (112°F.). The nourishment should be breast milk. If this cannot be had, peptonized milk, diluted with an equal amount

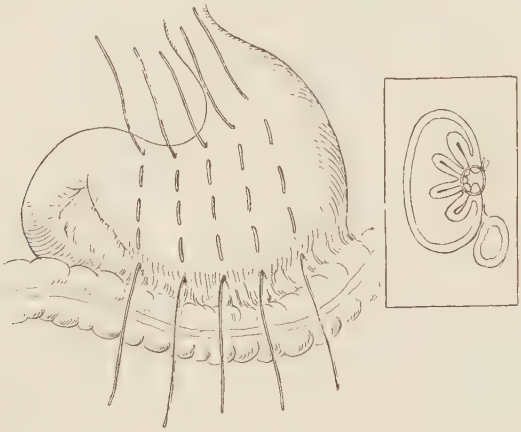

FIG. 1390.—GASTROPLICATION.
Showing method of reducing the size of the stomach by pleating its anterior wall.

of water, may be used. The feeding should be limited to the amount the child can take without having nausea. Usually from 30 to 90 c.c. (1 to 3 ounces) may be given every three or four hours. Sterilized water may be given between feedings. Some children should not have this much. Hypodermoclysis may be indicated in some. The child's weight should be watched. Many of these cases have probably been confused with some other condition. The tumor of the pyloric muscle cannot be cured by medical means, and if any cases have recovered they have represented a mild form of hypertrophy.

Drugs are probably of no use, although opium has been extolled in doses of from 0.0015 to 0.003 c.c. ($\frac{1}{40}$ to $\frac{1}{20}$ minim) of the tincture, shortly before each feeding, as a means of relaxing the pylorus. Cases not yielding to treatment by irrigation, medication and careful feeding should be operated upon. In the pronounced cases operation should be done at once. It is possible that the cases that yield to medical treatment are cases of spasm, and not organic stenosis.

The operations of most service are pylorotomy, pyloroplasty, pylorodiosis and gastro-enterostomy. Simple longitudinal incision through all of the

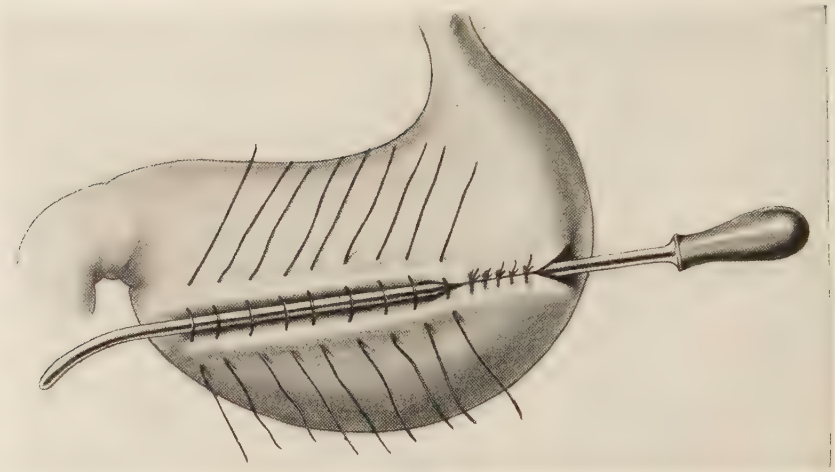

Fig. 1391.—Gastroplication.
For convenience the sutures are applied over a sound or staff which is withdrawn when the suturing is completed.



Fig. 1392.—Foreign Bodies Removed from the Stomach by the Author at a Single Operation.

pyloric structures except the mucous membrane is effective and safe without suture. This seems to give as good results as closing the wound transversely. Pylorectomy is rarely justifiable. Stretching the pylorus gives the lowest operative mortality and the best immediate results, but the permanence of the results are not so dependable.

The pyloroplastic operation of Finney would seem to be indicated in some cases. Nicoll (Glasgow Med. Jour., April, 1906) made a V-shaped incision and closed it as a Y by a single row of sutures. Of six infants, from six to ten weeks old, operated upon by this method, five recovered and remained apparently cured. This would not seem applicable to the dense indurated swellings.

S. Stillman (Jour. Amer. Med. Assoc., Nov., 6, 1909) reported 12 cases treated medically, with 6 deaths, and 10 cases treated by gastro-enterostomy, with 2 deaths. The cases operated upon are healthy children. The cases which survived medical treatment are not all well.

The surgeon should perform whichever operation seems best adapted to the individual case.

The disease has a mortality of about 50 per cent. in unoperated cases. If the disease is purely spasmodic at first, medical treatment may be sufficient. When actual hypertrophy of the pyloric muscularis develops, it is probable that medical treatment will not suffice. Still these children recover; and there seems to be no connection between the stenosis of infancy and that of later life. It is probable that the patients that recover without operation, ultimately recover completely.

The operative treatment is dangerous because the patients are very young and poorly nourished. Operation should be done if the vomiting does not abate. The persistence of the vomiting means loss of weight, dilatation of the stomach, and cessation of fecal movements. When operation is done hypodermoclysis is most important for getting fluids into the body. The patient should be kept quiet, and given 4 c.c. (1 dram) of castor oil at the end of the first twenty-four or thirty-six hours. Breast milk should be started as soon after operation as the child can take it. Very small doses should be given every two hours, at first 8 c.c. (2 drams), according to L. E. Holt. This should be gradually increased, alternating with boiled water. The head of the bed is kept elevated.

As to whether medical treatment or operation shall be adopted should depend on the severity of the symptoms.

The operation formerly done for this condition has been posterior gastro-enterostomy. In the hands of skilled surgeons the mortality of operation has been reduced to 14 per cent. It is doubtful whether this is the best operation for this disease, to be adopted as a routine procedure. Simple incision down to the mucous membrane has given good results, and may be found sufficient for many cases. A. A. Straus (Jour. Am. Med. Assoc., Oct. 30, 1915) amplified this procedure into a plastic operation. He made a longitudinal incision through all the pyloric structures except the mucous membrane, and freed the mucous membrane from the muscularis. Blunt scissors may be passed between the muscularis and the mucosa and by blunt dissection the whole circumference of the mucous membrane tube isolated. This is done more quickly than gastro-enterostomy, and apparently gives as good results. The pyloric wound should be covered with an edge of omentum.

It should be borne in mind that in true hypertrophic stenosis of infancy, there is an actual tumor of the pyloric muscularis, which cannot be cured by medical treatment. The condition is not one of muscular spasm. The

mortality from medical treatment is somewhere between 80 and 100 per cent. C. L. Scudder (Annals of Surg., 1914, vol. 59) reported a mortality of 14 per cent. following gastro-enterostomy.

Acquired hypertrophic stenosis in adults, not associated with ulcer or scar tissue, occurs in young adults, and is amenable to pyloroplasty or gastro-enterostomy. Operation should be preceded by a period of treatment by gastric lavage (see Pyloroplasty, page 740).

Carcinoma, or other tumor of the pylorus, is treated by resection (see Pylorectomy, page 747).

Cicatricial stenosis, commonly following ulcer, is best treated by gastro-enterostomy. Pyloroplasty may be done in some cases. Resection of the pylorus is indicated if there is induration without external adhesions. In skilled hands the ideal treatment is resection of the pylorus and pyloroplasty or gastroduodenostomy.

Spasmodic Stenosis.—There are cases of *persistent vomiting* no cause for which can be discovered clinically. These cases have been relieved by stretching the pylorus. It has been assumed that there was some pyloric spasm or stenosis and upon this theory the stomach has been exposed; often it has been difficult to say whether a lesion was present or not; but after performing gastrotomy, passing a dilator through the opening, and through the pylorus, dilating, and then suturing the small gastrotomy wound, the patients have been found to be cured. The simple operation of stretching the pylorus has sufficed.

Before operating on the pylorus, the surgeon should be sure that the vomiting is not due to angulation or other obstruction in the bowel. He should particularly guard against the mistake of performing gastroenterostomy, under the assumption of obstruction due to an intestinal lesion.

Ulcer of the Stomach.—The causative factor should be sought for and eliminated. The primary focus of infection may be at the root of a tooth, in infected adenoids, nasal sinuses, or in some other part of the body. It is possible that an infected appendix, Fallopian tube, gall-bladder, or anal fissure may be the nidus requiring attention. Old ulcers with calloused beds and constantly recurring symptoms, situated near the pylorus, should be treated by resection or other operation. Excision is the operation of choice and in all cases should be done when possible. In many instances the refusal of the patient, the physical condition of the patient, or other circumstances over which the surgeon has no control make operation impossible or compel its postponement. Under such circumstances palliative treatment becomes necessary.

Nonoperative treatment is indicated also in young ulcers with little induration. The treatment formulated by F. Smithies (Am. Jour. Med. Sci., 1917) provides for rest of the stomach. The patient should be kept quietly in bed. No food should be taken by mouth for three to seven days. This period is determined by the subsidence of gastric spasm. By chewing paraffin wax for fifteen minutes every hour hunger and thirst are allayed. Rectal feedings are given during the fasting period. From 500 to 1000 calories of nutrient mixture are given every twenty-four hours. This may be secured by using 30 c.c. (1 ounce) of 50 per cent. alcohol, and 30 Gm. of glucose in normal salt solution to make 240 c.c. of fluid. This is given at body temperature by the drop method. If rectal feeding for several days is necessary, proteids also should be used (see Nutrient Enemata, page 620). A little tincture of opium may be added to the first enema. From the fourth to the seventh day mouth feeding may be begun.

Large doses of alkalies increase the acid secretion and are not to be recommended. If an alkali is employed frequent small doses of milk of magnesia or calcined magnesia are best. Usually 0.3 to 0.6 Gm. (5 to 10 grains) of calcined magnesia every two or three hours suffice. Alkalies and lavage are not desirable and should be used only when especially called for. It is doubtful if such medicines as oils, bismuth, and iron have any curative value.

Most cases are capable of being healed by nonoperative treatment. If patients are given rest, quiet and freedom from worry, the natural tendency of the disease seems to be toward recovery. There are two principal methods of internal treatment: That of W. von Leube consists in rest in bed, medication, saline laxatives, heat to the epigastrium, prohibition of food by mouth until blood has disappeared from the stools and then gradual administration of fluid food. That of Lenhartz consists in rest in bed for at least four weeks, feeding from the beginning with steadily increasing quantities of beaten-up eggs and milk to neutralize or fix the acid gastric juice, ice-bag to the epigastrium, addition of fine solid food to the dietary after the first week and the administration of bismuth and iron.

A mixture may be made having a proportion of 45 c.c. (1½ ounces) of cream, 120 c.c. (4 ounces) of milk, and one egg. This is given every hour from 7 a.m. till 7 p.m. in doses of 15 c.c. (4 drams). The dosage is increased 15 c.c. (4 drams) every day. When the quantity at each feeding reaches 90 c.c. (3 ounces) the dose is not further increased for five days. At the end of the first week, a soft boiled egg and 30 Gm. (1 ounce) of strained oatmeal may be given twice daily, at 7 a.m. and at 7 p.m., and at 1 p.m. 30 Gm. (1 ounce) of broiled scraped beef and the same amount of well-cooked rice. From the tenth to the fifteenth day, the food should consist of 90 c.c. (3 ounces) of the egg-milk mixture at 9 and 11 a.m. and 3 and 5 p.m.; and 60 Gm. (2 ounces) of strained oatmeal with cream and glucose, and one or two thin slices of dry bread, and two soft eggs at 7 a.m. and at 7 p.m.; and chopped chicken or scraped beef, dry bread and rice at 1 p.m. From the fifteenth day to the end of the second month, small meals 3 times daily should be eaten. An egg and a glass of milk should be taken between meals and at bed time. This is practically the dietary advised by S. Harris (Southern Med. Jour., November, 1916). It may be begun two days after a hemorrhage. It is a highly useful regimen after gastroenterostomy.

A method of feeding in gastric and duodenal ulcers advocated by W. J. Stone (Jour. Am. Med. Assoc., Sept. 30, 1916) met hyperacidity by a restriction of carbohydrate diet. Neutral sodium citrate, 0.2 Gm. (3 grains), is given with every 30 c.c. (1 ounce) of milk to prevent the formation of curds. Albumin water is made of the white of one egg, in 500 c.c. (1 pint) of water, and is best flavored with orange, grape or lemon juice, but no sugar should be used. Custard should be made with but little sugar. Purée is made of peas, spinach or corn. Broth may be made of chicken, oysters or clams. Bacon should be broiled crisp, and the tough edge and cartilage removed. If the patient is badly in need of fluids, proctoclysis may be given. Retention of food in the stomach should be treated by gastric lavage. The following feeding schedule is followed:

Day	Food: amount and frequency	A.M.	P. M
1st	Milk, 2 ounces, every two hours	6	8
	Albumin water, 3 ounces, every two hours	7	9
2d	Milk, 2 ounces; cream, 1 ounce, every two hours	6	8
	Albumin water; 3 ounces, every two hours	7	9
3d	Milk and cream as above, every two hours	6	8
	Albumin water, as above, every two hours	7	9
	One soft boiled egg, with feeding at	7	7
4th	Milk and cream as above	6	8
	Albumin water as above	7	9
	One egg as above, with feeding at	7	7
	Soft, well cooked cereal, 3 ounces, with feeding at	8	2
5th	Milk and cream as above	6	8
	Albumin water as above	7	9
	One egg as above, with feeding at	7	1 and 7
	Cereal as above with feeding at	8	2
	Purée, 3 ounces, with feeding at	12 M.	6
6th	Milk and cream as above	6	8
	Albumin water as above	7	9
	One egg with 2 slices bacon, with feeding at	7	1 and 7
	Cereal as above, with feeding at	8	2 and 8
	Purée as above, with feeding at	12 M.	6
7th	Repeat above and 3 ounces broth, with feeding at	10	4
8th	Same as seventh, and broth with feeding at	10	4 and 10
9th to 14th	Same as eighth and ½ slice toast with three feedings. Custard, 3 ounces, may be substituted for one or two milk or albumin water feedings if desired		

Ferric chlorid 1 per cent. solution introduced through a stomach tube, and the same drug in gelatin lozenges have been used. Olive oil, linseed oil, and oil of sweet almonds have their advocates. Some medical authorities regard the mechanical activities of the stomach as being of more importance than the chemical in ulcer of the stomach, and permit only foods which are finely divided and macerated. Hyperchlorhydria may be reduced and controlled by regulating the intake of sodium chloride.

Hyperchlorhydria, which is a common feature of the disease, is amenable to medical treatment. Even though it be attended by pyloric spasm the case does not require surgical treatment unless motor disturbances are pronounced.

Operative treatment is called for in cases in which (1) despite medical treatment the symptoms of ulcer continue to cause distress or interfere with the patient's efficiency; (2) perforation occurs; (3) physical signs of food stagnation, dilatation, hour-glass contracture, or adhesions supervene; or (4) hemorrhage, as shown by occult blood in the feces, by hematemesis, or intractable anemia, persists. This means that cases which do not yield to palliative treatment should be operated upon.

The histories of most cases which come for surgical relief show that they have been too long deferred. Spasm of the pylorus, hyperchlorhydria, dilatation of the stomach, atony of the stomach, cicatricial contractures, hour-glass stomach, perforation, perigastric adhesions, cancer and a train of constitutional ills represent some of the conditions which may supervene if ulcer is left to run its course. To check the disease, when non-surgical measures have failed, excision of the ulcer or gastro-enterostomy or both should be employed.

In dealing with ulcer of the stomach and duodenum, there are two definite forms of gastro-enterostomy. One is gastrojejunostomy; the other is gastroduodenostomy. Gastroduodenostomy in these diseases is best

performed as a pyloroplasty. This means that the duodenum and stomach are connected by a larger opening than the natural pyloric opening. This operation gives access for the removal of duodenal or pyloric ulcers, and is properly speaking a gastro-enterostomy. When gastro-enterostomy is spoken of in this work in connection with gastric or duodenal ulcer, pyloroplasty is meant to be preferred if the ulcer is near the pylorus.

Operation offers relief to so large a proportion of cases—about 90 per cent. of those operated upon—and the hazard of gastro-enterostomy has been reduced to so low a degree—1 or 2 per cent. mortality in skilled hands—that even the cases which may be relieved by a tedious course of medical treatment are justified in electing operation. Unfortunately the mortality in the hands of the average surgeon is 6 to 8 per cent.; and when combined with resection it is 10 to 15 per cent.

Although the modern methods of diagnosis enable the surgeon to judge beforehand the location of the ulcer, still the operation should be regarded as diagnostic until the ulcer is discovered. Old ulcers may be recognized by the induration of the stomach wall, but recent ulcers may elude recognition.

If the ulcer is at the pylorus, and especially if associated with thickening of the wall, resection of the ulcer and tumor is indicated. Some surgeons even in these cases prefer to do gastro-enterostomy alone, which is less hazardous. If the ulcerated area is surrounded by adhesions, which would make resection difficult, gastro-enterostomy alone is usually done, although resection is the ideal operation. If the ulcer is not at the pylorus, simple resection of the ulcerated part of the stomach wall, and closure of the wound is indicated, without gastro-enterostomy, provided the surgeon feels satisfied there is no other ulcer, and the pyloric drainage of the stomach is perfectly adequate. This is often difficult to determine, and it is for this reason, therefore, that gastro-enterostomy may wisely be added to the resection.

While medical treatment may be expected to cure most cases of gastric ulcer, the cure is always doubtful for we know that commonly after such ulcers cease to give symptoms the ulcer, from a surgical standpoint, is still unhealed. It is therefore difficult to say when surgical treatment is indicated. In view of the uncertainty of medical treatment, the fact that cancer of the stomach is most prone to develop in ulcers, and the excellent results of operative treatment, operation may be said to be justified in all cases in which there are no positive contraindications. It is not advised that every gastric ulcer should be treated by operation, but surgical treatment should be applied in the cases not clearly cured by faithful medical treatment. The fact that we have evidence that at least 75 per cent. of stomach cancers develop in the beds of old ulcers is the reason for regarding all ulcers of the stomach as surgical disease and justifies their resection.

Ulcer near the pylorus, which is apt to be swollen and edematous, should not be mistaken for cancer. The fact that the swelling is so great that it can even be felt through the abdominal wall should not lead the surgeon to operate as for cancer.

Excision of the ulcer-bearing area is the operation of choice and especially in pyloric ulcers. This usually is best treated by a partial excision of the stomach wall, followed by pyloroplasty. In smaller ulcers an elliptical resection should be done, and the wound in the stomach closed as for gastrotomy.

The ulcer should be removed or destroyed in all cases operated upon for ulcer of the stomach, unless there is some pressing contraindication against its removal.

Ulcers of other parts of the stomach than the pylorus are best treated by excision. In many cases gastro-enterostomy also seems indicated because, if only excision of the ulcer is done, the diseased condition of stomach function seems not to be relieved, the wound may fail to heal properly, and later gastro-enterostomy may become necessary.

D. C. Balfour successfully treated ulcers of the lesser curvature with the actual cautery (Surg., Gyn. and Obst., vol. 19, p. 528, 1914). The peritoneum is dissected from the bed of the ulcer, and the cautery at a cherry red, is caused to burn out the ulcer, thus producing an artificial perforation into the stomach. The opening is closed with sutures, and the peritoneum sutured over all. At the lesser curvature the gastrohepatic omentum would naturally constitute the covering peritoneum. This operation should be followed by gastrojejunostomy or pyloroplasty for the sake of better gastric drainage.

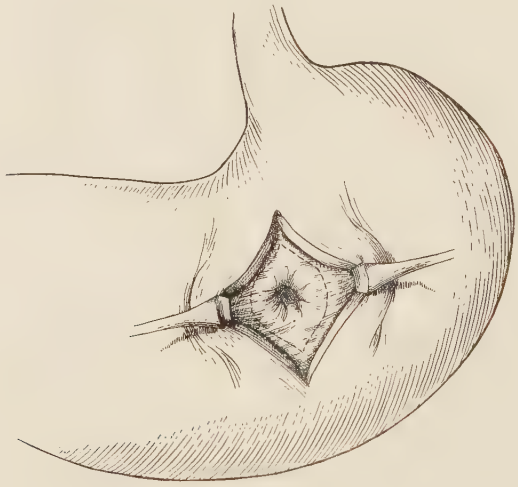

Fig. 1393.—Transgastric Excision of Ulcer of the Posterior Wall of the Stomach. The anterior wall has been incised and retracted. The ulcer is seen on the posterior wall. The dotted line indicates the line of incision for its removal.

Resection of the part of the stomach bearing the ulcer should be practised in the case of large or old indurated ulcers. Ulcers of the posterior wall of the stomach may be approached through an incision in the anterior wall (Fig. 1393), thus making a transgastric operation. After resecting the ulcer the two stomach wounds are closed (Figs. 1394 and 1395).

Excision of much of the stomach may be followed by direct anastomosis of the remaining part with the jejunum or duodenum. Even though excision is done, gastro-enterostomy also is often desirable. It gives rest to the stomach, secures drainage, relieves hyperchlorhydria, and cures ulcers which may not be capable of discovery for excision.

W. J. Mayo's results showed that by gastro-enterostomy alone, it was possible to secure permanent recovery in 80 per cent. of the cases in which medical treatment had failed; and that in nearly 10 per cent. more, improvement can be secured. His later figures showed improvement or cure in 98 per cent. of cases following gastrojejunostomy and excision or infolding of the ulcer.

The treatment of the complications resulting from gastric ulcer are each discussed separately (see Perforations of the Stomach, page 725; Gastric

Hemorrhage, page 727; Pyloric Stenosis, page 717; Operations on the Stomach, page 730).

About 80 per cent. of ulcers of the stomach are at the pylorus. The pylorus and duodenum are usually easily mobilized, and excision of the ulcer-

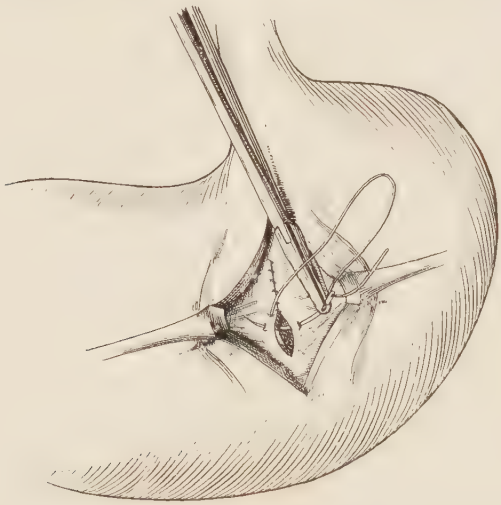

Fig. 1394.—Closing Wound in Posterior Wall of Stomach after Excision of Ulcer.

bearing area is not difficult. This may be done as a pylorectomy or as a pyloroplasty after the method of Finney. This course is in most cases preferable to gastrojejunostomy.

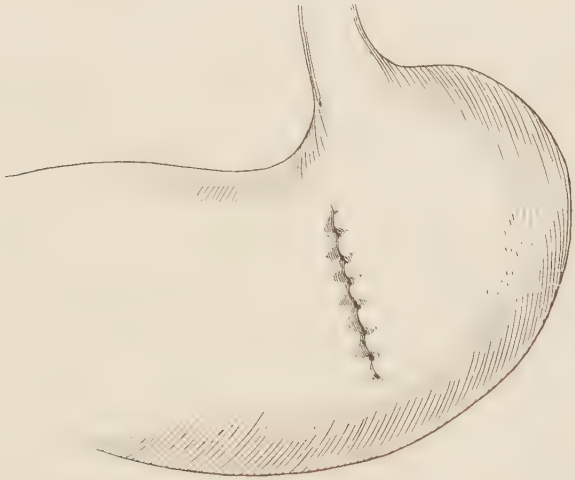

Fig. 1395.—Wounds of Stomach Closed after Transgastric Excision of Ulcer of Posterior Wall of Stomach.

In cases in which immediate relief is called for in a patient who has become much reduced by disease and suffering, or if adhesions are present which would make pylorectomy or pyloroplasty difficult, then gastrojejunostomy may be regarded as the operation of choice.

Pylorectomy or pyloroplasty may then be done later. After a weak patient has grown strong, it may be done to remove the ulcer and close the gastrojejunostomy openings. In the presence of adhesions it may be done to remove the ulcerated area after the gastrojejunostomy has proved its efficacy. And it may be done in cases in which the symptoms of ulcer have not been relieved by gastrojejunostomy.

The advisability of operating in two stages on weak patients should always be considered whether the operation is to be done for ulcer or for cancer.

Perforating ulcer of the stomach should be treated the same as perforating ulcer of the intestine (page 566). The abdomen should be opened at once, as soon as possible after the condition is recognized or suspected, and the perforation closed. Every hour that elapses after perforation the prognosis becomes more grave. Delay is unjustifiable. It is a serious error to temporize because shock is present, hoping to get the patient into better condition for operation. The danger of peritonitis is greater than that of shock. It is also a serious error to temporize in cases in which the symptoms are not pronounced, waiting until the condition more positively manifests itself. It is true that slow perforation may become sealed over by plastic exudate, and spreading peritonitis not occur. Many such cases, as disclosed by perigastric adhesions, heal spontaneously. But the possibility of fatal or serious peritonitis is so great that every case of perforation should be sutured. Mayo operated upon 543 cases of ulcer of the duodenum and stomach during a consecutive period. Of these, 27 were perforating. All the cases of acute perforation treated by simple suture, excepting one, recovered. Cases operated upon during the first twelve hours should be expected to recover. The mortality increases with the lapse of time. The mortality of the acute cases operated upon is not less than 50 per cent. in all hands because of the long average delay between perforation and operation.

Operation for perforating gastric ulcer should be done through a 10-cm. (4-inch) median incision above the umbilicus. Fluid is removed; and if the perforation does not come at once into sight, an inspection of the anterior wall of the stomach is made, beginning with the pyloric end. If the perforation is not found in the anterior wall, the posterior wall should be exposed. This may be done by making a rent through the great omentum between the stomach and transverse colon; or the omentum and the colon may be lifted up and the opening made through the transverse mesocolon. The soiled peritoneum should be cleansed, and the opening closed with two layers of sutures, first a through-and-through suture, and then a serosa suture of linen. If the soiling of the peritoneum has been considerable, as may occur in the case of a large perforation after a meal, the peritoneum should be irrigated and the abdomen closed with drainage. If the soiling has been slight or has involved but a small area, irrigation and drainage may be dispensed with. The resection of a perforated ulcer is not called for. Mayo has called attention to the fact that perforation cures the ulcer. As soon as perforation takes place, the main question is not of ulcer but of peritonitis.

The further treatment is that of peritonitis. When peritonitis has supervened, that condition should receive active attention. Ileus may have to be met later and foci of suppuration may require to be drained (see Peritonitis, page 546).

Some surgeons have advocated gastro-enterostomy after closure of the ulcer. This may be done, if the ulcer has long resisted medical treatment, if the mechanical and chemical function has been much altered, and if the condition of the patient will easily permit of prolonging the operation. If a

diffuse peritoneal infection has occurred, anastomosis should not be done. Gastro-enterostomy is indicated more in the chronic cases with the perforation closed by plastic exudate and a persistence of the symptoms of ulcer.

J. B. Deaver and many other surgeons excise the ulcer, close the wound, and perform posterior gastro-enterostomy. This treatment gives highly satisfactory results. Excision is always advisable because of the danger of cancer developing in the bed of gastric ulcer. So far as gastro-enterostomy is concerned, it is indicated only for the relief of pyloric obstruction and defective stomach drainage (see Gastric Ulcer, page 720).

Perigastric abscess from perforation of the stomach depends for its location upon whether the perforation is in the anterior or posterior wall. Anterior perforation may give abscess anywhere between the anterior abdominal wall and the stomach; it can usually be drained by incision through the abdominal wall; or it may extend over the liver and be reached by the incision described for subphrenic abscess (page 553). Perforation of the posterior wall infects the lesser peritoneal cavity; and the abscess may require to be reached through the thorax, or through the anterior abdominal wall and the anterior layer of the gastrocolic omentum (page 780).

Hemorrhage of the Stomach.—If it could be known that hemorrhage is arterial, then operation should be done at once. Capillary hemorrhage should not require to be controlled by operation. Nearly 100 per cent. of cases of obvious hemorrhage are arrested without operation, and it may be assumed that these represent capillary bleeding. A large number have loss of a smaller amount of blood, which is to be discovered only by chemical examination of the stools. It may be stated that the great majority of cases of hemorrhage need not be operated upon. Rest, the withholding of gastric feeding, ice, adrenalin chlorid, or astringents introduced through the stomach tube, and morphin hypodermatically, are the most effective expedients.

Adrenalin is, perhaps the most useful agent. It must be given at intervals of not more than an hour. The first doses may be 2 c.c. (30 minims) of a 1 : 1000 solution. The measures for increasing the coagulability of the blood should also be used (see Hemorrhage, Vol. I, page 334).

A simple hemorrhage, either large or small, should not call for operation unless an ulcer has been known to exist. In old chronic cases, operation is indicated at the first hemorrhage, as it not only is aimed to control the bleeding but it gives an opportunity to cure the ulcer at the same time.

Recurrent bleeding which persists despite treatment, even when no history of ulcer has been obtained, should receive surgical treatment.

In any case every effort should be made to secure the arrest of the hemorrhage before operating in order to operate in a quiescent stage if possible. Operation in a stage of extreme and recent acute anemia is very hazardous, but often not so hazardous as the continuation of the bleeding. It should also be borne in mind that a complicating carcinomatous degeneration may be present. This should be suspected if after the hemorrhage has stopped, every attempt to feed solid food is followed by bleeding.

There are few conditions in which decision may be more difficult. Whether operation shall be done must depend upon the general conditions, the surgical skill that can be secured, the resistance of the patient, and general facilities for operations and postoperative care.

After operating the surgeon cannot always be sure that his operation was of benefit or harm.

A middle-aged man without history of ulcer, vomited blood twice and was suffering with acute anemia. While I was at his bedside, it could be seen plainly that his stomach again

was filling with blood. I sent him to the hospital and operated as a last desperate measure five hours after the first hemorrhage. He had vomited a large quantity of blood when he went on the table, and was profoundly anemic. Upon opening the stomach no ulcer or bleeding point could be found. Three suspicious-looking spots were surrounded with a suture. No further bleeding took place; and the man had remained entirely well fifteen years later. It can not be known whether this operation was of any service; it probably was not.

T. Rovsing (Jour. Amer. Med. Assoc., Oct. 24, 1908, page 1476) successfully employed gastroscopy and diaphanoscopy for purposes of transillumination of the stomach as an aid to operation. With an electric light in the stomach introduced through the esophagus or through a very small puncture in the stomach wall, bleeding and the vessel from which it is taking place can be seen by the shadow through the stomach; and a sunken suture may be passed around the vessel. The ordinary cystoscope has been employed for this purpose by L. Kraft (Hospitalstidende, No. 20; May 19, 1909).

Operation for gastric hemorrhage must be regarded as being at first diagnostic. Some surgeons are strongly in favor of gastro-enterostomy alone, claiming that it relieves the condition which causes the hemorrhage. As an operative procedure, this operation is no more hazardous than gastrotomy, search for the bleeding point and ligation. It may be said, on one hand, that gastro-enterostomy has not always been followed by cessation of bleeding, and, on the other hand, that simple ligation has been followed by recurrence of hemorrhage because it did not cure the ulcer. Judgment is required.

A bleeding artery in an old ulcer should surely be ligated; and, if the condition of the patient will permit, it is best that the ulcer be excised. If excision is not done the healing of the ulcer will be facilitated by gastro-enterostomy. The surgeon must decide for each case which is the more important. If the condition of the patient will permit, after checking the hemorrhage, the operative treatment as for ulcer should be proceeded with if ulcer is present. If the hemorrhage has stopped, the ulcer should be dealt with. If the bleeding is continuing at the time of operation, direct hemostasis is the more important.

If bleeding is not going on, it will often be difficult to determine where it came from; and after a futile search, or ligation of suspected foci, hemorrhage may recur. The bleeding may have come from the duodenum. Gastro-enterostomy has more to offer for the majority of cases than attempts at direct ligation, if no active bleeding is seen.

The *technic of operation* begins with exposure of the stomach by a 10-cm. (4-inch) incision above the umbilicus. As a rule it is undesirable to wash out the stomach lest bleeding be excited. The anterior surface of the stomach should be scrutinized with a good light for evidences of ulcer. An area of induration, discoloration or puckering should be sought. If the outward signs of ulcer are discovered, it may be assumed that this is the site of hemorrhage. If the condition of the patient will permit, the ulcer should be excised (page 723).

If the patient's condition is bad and a short operation is essential, then simple ligation may be done without opening the stomach. This may be accomplished by observing through the serosa the vessel which goes to the ulcer. A curved needle may be passed under it and the vessel tied. If no vessel can be identified as the main supply of the ulcer, a continuous suture through the whole thickness of the stomach wall may be applied in such a manner as to sew together the raw surface without exposing it. This suture should be applied tightly in such a direction as to embrace the blood-vessels,

and after being tied should be covered by a second layer of serosa sutures. This is the operation of emergency, not of choice.

If no sign of ulcer is to be seen through the peritoneum, and direct treatment of the hemorrhage is to be undertaken, the stomach should be drawn forward, surrounded by protecting pads and opened. An incision in the long axis of the stomach in the middle of its anterior wall gives the best view. This wound should be held open by forceps grasping its edges. With the aid of good light, or an electric light introduced through the wound, the interior of the stomach should be inspected. To facilitate examination of the posterior wall a slit may be made in the omentum just below the stomach, and four fingers passed through it. The fingers behind the stomach may press forward into the wound for inspection the various parts of the mucous

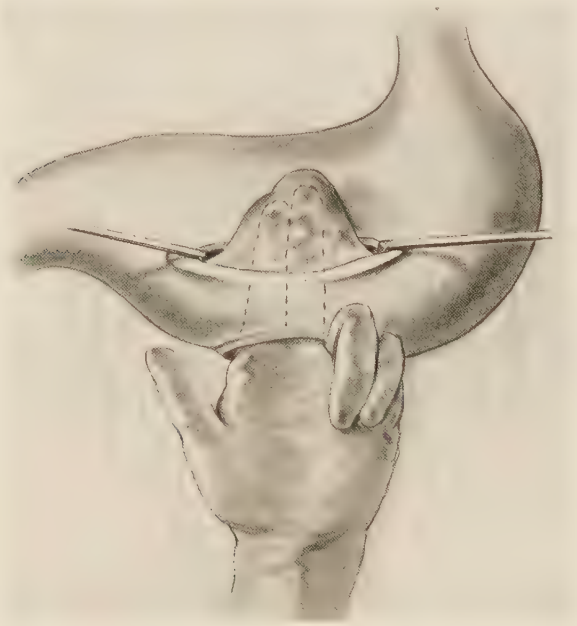

Fig. 1396.—Method of Locating Ulcer or Bleeding Point on Posterior Wall of Stomach.

The stomach is incised anteriorly; an opening is made in the great omentum just below the stomach and two fingers passed behind it. These two fingers press the posterior wall of the stomach forward into the wound. A large area of the mucous membrane of the posterior wall may thus be brought under inspection through a small anterior wound.

membrane of the posterior wall (Fig. 1396). The duodenum should be examined not only externally but it may be invaginated through the pylorus, if no ulcer can be found in the stomach.

If a bleeding point is discovered it should be caught with a broad-nosed clamp and ligated. The mucous membrane is very friable and will be cut through if the ligature is tied too tightly. The thermocautery may be used. An ulcer should be excised. An ulcer at the pylorus, if small, may be excised and the wound closed transversely so as to prevent narrowing of the lumen. A larger ulcer is best treated by pylorectomy, the main object being to prevent cancer. If the induration or adhesions are too extensive or if the con-

dition of the patient does not warrant pylorectomy, the bleeding point may be ligated and gastro-enterostomy performed.

The gastrotomy wound should be closed with two layers of sutures, a through-and-through suture closing the opening, and a seromuscular outside suture.

In all operations for hemorrhage preparations for the treatment of acute anemia should go on with the preparations for operation. If an infusion is needed it should be in readiness, and as soon as the bleeding opening has been closed the infusion should begin (Vol. I, page 346).

To recapitulate: (1) In desperate cases the bleeding ulcer may be discovered and the supplying vessel tied by passing a ligature with a needle through the stomach wall without opening the stomach. (2) If ulcer cannot be discovered externally and uncontrolled bleeding is going on, gastrotomy may reveal the bleeding point. (3) If the condition of the patient warrants it, the bleeding ulcer should be excised. (4) If the patient's condition is still good, gastroduodenostomy (pyloroplasty) or gastrojejunostomy may be added to the excision if indicated.

Gastric Tetany.—The treatment consists in relieving the causative disease if it can be discovered. Pyloric stenosis, hour-glass stomach, cancer, or any other condition producing stagnation of stomach contents or hyperchlorhydria should have applied to it its special treatment. I have reported a case cured by the removal of foreign bodies from the stomach (Annals of Surgery, December, 1904).

Lavage of the stomach may be depended upon to give temporary relief but success will not follow unless the washing is continued until the fluid returns clear. A sedative or even a general anesthetic may be required for the operation. Gastro-enterostomy, providing drainage of the stomach, may be depended upon as the most effective treatment. This operation has not failed to give relief in a large number of cases.

Operations on the Stomach

Gastrotomy.—This operation consists in opening the stomach by an incision. It is usually best that the stomach be washed out before operation. The stomach is exposed by an incision above the umbilicus, and inspected with reference to the condition demanding operation. The surrounding structures are protected. The least bleeding will be caused by the incision if it is made about midway between the greater and lesser curvatures in the line with the long axis of the stomach. This incision will be made toward the pylorus, the cardia, or in the middle of the stomach, depending upon the region to be exposed. After the object of the operation has been accomplished the incision is closed with two layers of sutures—a through-and-through suture approximating the edges of the wound, and an outer seromuscular suture—the same as employed for closing wounds of the intestine (page 626).

Gastrostomy.—This operation consists in making a permanent opening in the anterior wall of the stomach for purposes of feeding or treatment. It is employed especially in cases of obstruction of the esophagus. Many operations have been devised and modified. It is desirable that the orifice shall be made tight enough so that it shall not allow the escape of stomach contents upon the skin to produce irritation. The simple compression between the fibers of the rectus muscle is not enough of a sphincter action to close the opening. The operation must often be modified according to the mobility of the anterior stomach wall and according to the permanence desired.

Gastrostomy by means of an external flap was devised by H. H. Janeway (personal communication). The operation may be done under local anesthetic through a 4 cm. (1½ inch) incision. The incision is made parallel with the fibers of the rectus muscle over the inner third of the left rectus 3 or 4 cm. belew the costal cartilage. A wedge of stomach is pulled out through the wound by means of two clamps. An incision, 3 or 4 cm. long (Fig. 1396*a*), is made between the two clamps and two shorter incisions, 1.5 or 2 cm. long, are carried from the end of this toward the greater curvature. A flap is thus formed which is folded into a tube. The wound is closed without reducing the transverse dimension of the stomach, and in such a manner that the line of suture is continuous with that which closes the tube.

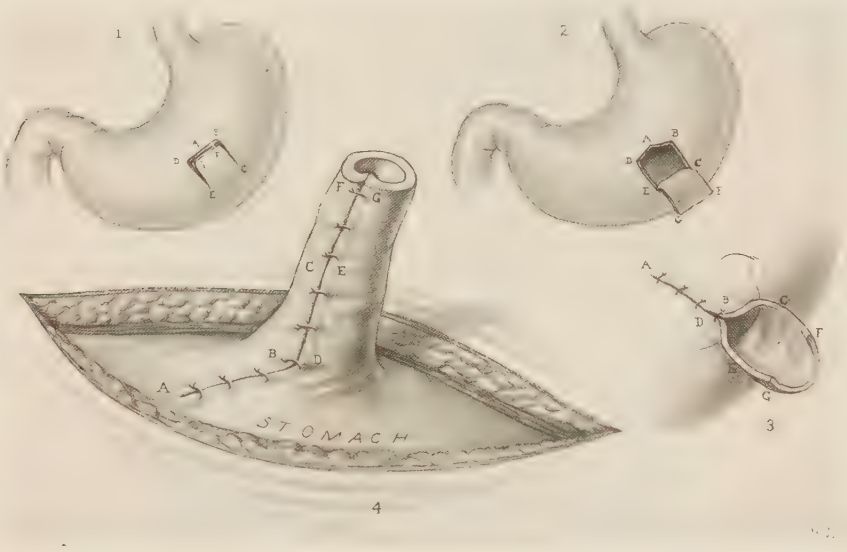

Fig. 1396*a*.—Gastrostomy, Method of Janeway.

1, The U-shaped incision is made on the anterior wall of the stomach. This forms a flap *E G F C*. 2, The flap *E G F C* is turned down. Its nourishment is from the artery of the greater curvature. 3, The point *A* is grasped and drawn upward. The side *D E G* is united with the side *B C F*. This closes the stomach wound and forms the tube of stomach-wall. 4, Showing stomach through abdominal wound. When the operation is completed, an elongated tube is formed, the transverse dimension of the stomach is not reduced, and when the tube is compressed by the fibers of the rectus muscle leakage is prevented.

The base of this artificial canal is sewed to the parietal peritoneum and posterior sheath of the rectus. The apex is sewed to the skin. When this operation is well done the patient is not obliged to wear a tube, the opening will not close nor leak, and the interior of the stomach may be examined at any time with the gastroscope.

Gastrostomy through an internal cone is done by the method devised by E. J. Senn. It is the most simple of the operations. A vertical incision about 5 cm. (2 inches) long is made over the outer third of the left rectus muscle. It begins about 2 cm. (¾ inch) below the costal margin. The fibers of the rectus are separated bluntly, care being taken not to divide the nerves passing to the inner two-thirds of the muscle. The peritoneum is opened. The stomach may be small and shrunken. The colon should be retracted downward,

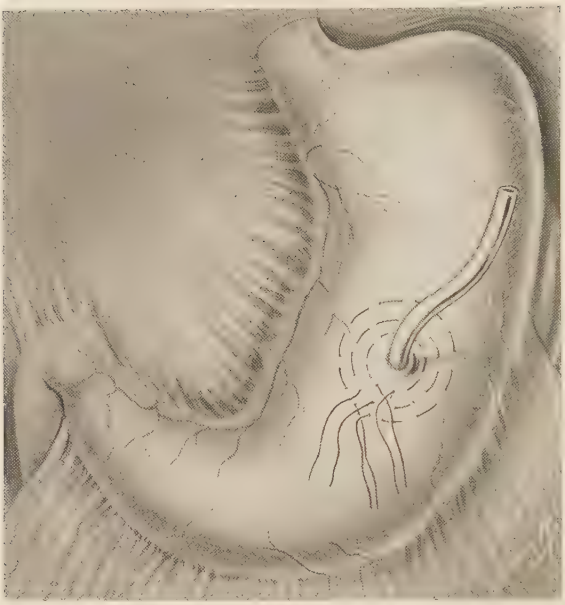

FIG. 1397.—GASTROSTOMY, METHOD OF SENN.
Showing sutures inserted and catheter introduced. The stomach here indicated has the shape disclosed by x-ray examinations.

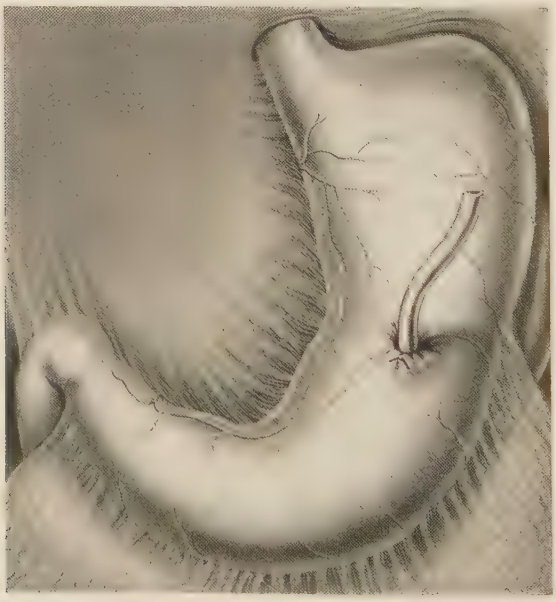

FIG. 1398.—GASTROSTOMY, METHOD OF SENN.
Showing purse-string sutures tied.

and the stomach brought forward into the wound. The point to be opened should be about midway between the lesser curvatures at the cardiac end of the stomach. A purse-string suture is applied with a diameter of about 2 cm. (¾ inch). The ends of the suture are left long for tying. Outside of this a second, third and a fourth purse-string suture are placed. These sutures should be about 6 mm. (¼ inch) apart. The diameter of the outer circle is about 5.7 cm. (2¼ inches). If haste is necessary three purse-strings about 1 cm. (⅓ inch) apart may be placed. The circle should not be any smaller than this. Having placed these seromuscular sutures, an opening is made in the center of the circle, and a No. 14 or 16 French catheter introduced. The opening should be made with a narrow sharp knife and should be small enough to make the tube fit snugly (Fig. 1397). The tube should be passed into the stomach about 5 cm. (2 inches). The inner purse-string is then tied

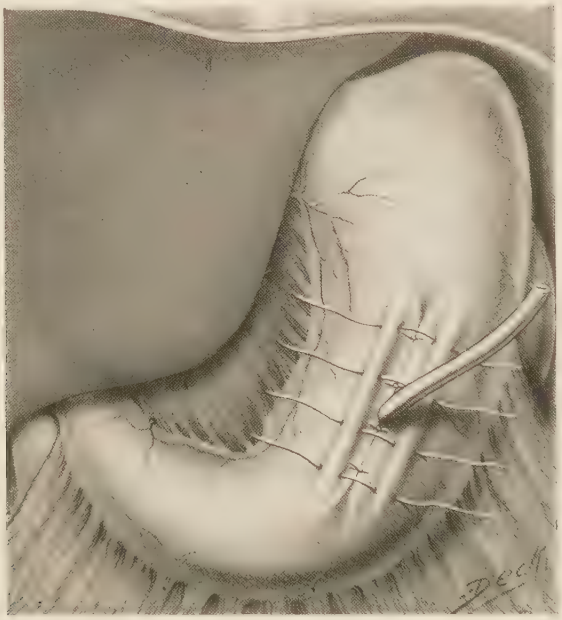

Fig. 1399.—Gastrostomy, Method of Kader.
The stomach-wall is inverted by two rows of sutures.

down as the tube is pushed in. Each purse-string is tied successively and the ends cut. The ends of the outer suture after being tied are then tied about the tube to prevent it from slipping. All of these sutures should be tied rather tightly. They invert an area of the stomach wall and the tube appears inside of the stomach at the apex of a cone.

The stomach is then fixed by two sutures, one above and one below the tube, passed through the peritoneum and posterior sheath of the rectus (Fig. 1398). These are tied and the peritoneum and other structures sutured as usual.

The tube which is fixed in the stomach is cut so as to leave about 7.5 cm. (3 inches) outside of the body. This is clamped. When it is desired to feed the patient, a second tube is connected with it, and fluid poured in through a funnel. In about ten days the tube will be found to be loose. It may then

be removed and a clean one introduced. A tube should be left in constantly, otherwise the opening is apt to become permanently contracted.

Water, milk, eggs, broths, porridges and soups may be fed in this way. Some patients prefer to masticate their food and feed themselves through the tube. The mouth and teeth should be kept well cleansed.

The *method of Kader* for performing this operation consists in making a fold instead of a cone, the stomach wall being inverted by two rows of sutures (Fig. 1399).

Gastrostomy through an external cone is done by a modification of the method of Franck. An incision 7.5 cm. (3 inches) long is made parallel to the left costal border and about 4 cm. (1½ inches) from it. The upper end of the incision is near the median line. The rectus fibers are separated vertically by blunt dissection and the peritoneum opened. A second in-

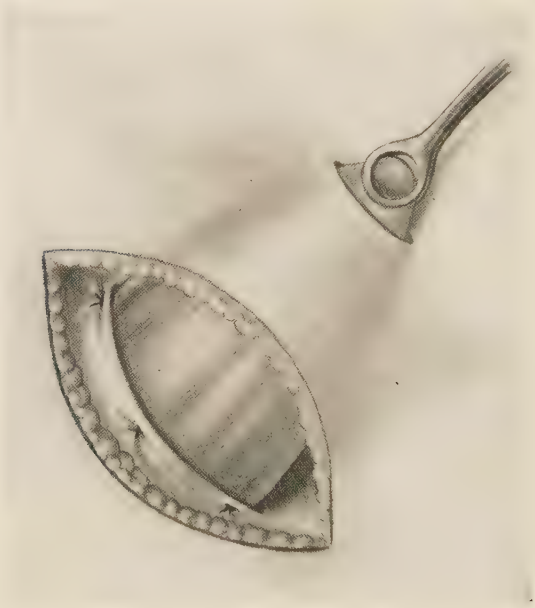

FIG. 1400.—GASTROSTOMY.
Modification of method of Franck. A cone of stomach is drawn out through a second small wound in the abdominal wall and sewed fast.

cision 2 cm. (¾ inch) long is made parallel to the first about 2.5 cm. (1 inch) above the costal margin, and carried through the skin and superficial fascia. The skin between the two incisions is undermined. The stomach at the cardiac end is picked up and pulled out far enough to reach the smaller opening, and fixed to the peritoneum and fascia by four sutures. The apex of the part grasped is then drawn under the skin to emerge at the smaller opening (Fig. 1400). This forms a cone with its apex at the small opening and its base at the larger. The apex is fixed to the fascia and skin by four sutures. The opening of the stomach may be made after a day or two, or a purse-string suture may be introduced and a catheter inserted at once. This operation is an unnecessary complication of what should be a simple procedure. It violates the surgical principle that, an operation to accomplish

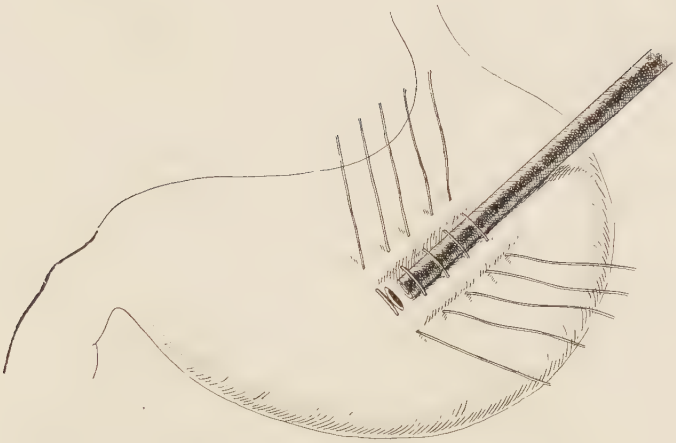

FIG. 1401.—GASTROSTOMY. OPERATION OF WITZEL.

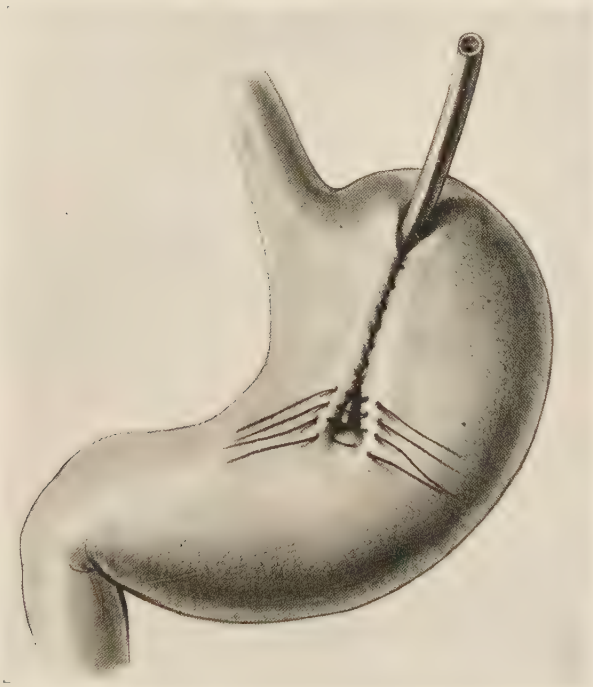

FIG. 1402.—GASTROSTOMY. OPERATION OF WITZEL.
Tube inserted and sutures tied.

its purpose should disturb the natural arrangement of structures as little as possible.

Gastrostomy by canalization of the stomach wall is done after the principle of Witzel. The stomach is exposed by a 10-cm. (4-inch) incision between the fibers of the left rectus muscle between the umbilicus and sternum. It is brought into the wound and a rubber tube or catheter (about 22 French) is laid upon its anterior wall and buried for 6 or 7 cm. (2½ inches) by a continuous seromuscular suture. This should be in the middle of its anterior wall, the tube lying in the direction of the long axis of the stomach. At the upper end of this line of suture an opening, just large enough to admit the tube, is made through the stomach wall (Fig. 1401). The end of the tube is

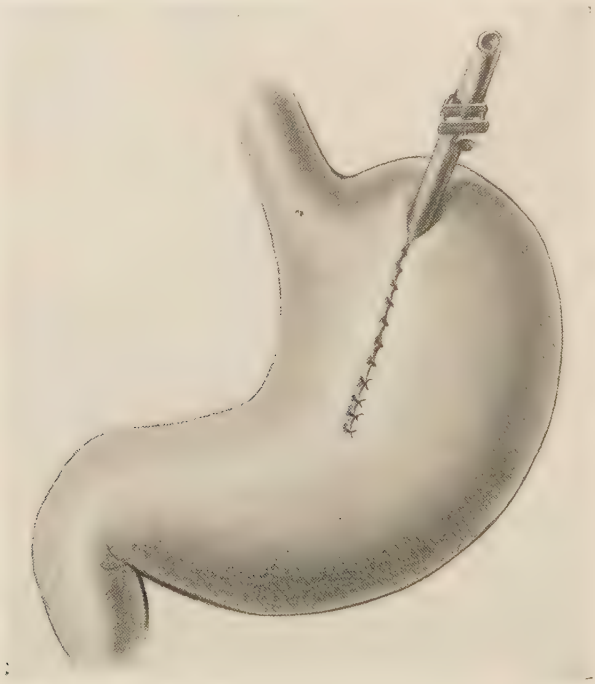

Fig. 1403.—Gastrostomy.
Operation of Witzel completed. The tube lies in the stomach and is clamped to prevent the escape of stomach contents.

then introduced into the stomach, and this part of the tube and opening covered in with about four interrupted sutures, which should have been introduced before the opening is made (Fig. 1402). Gould has called attention to the desirability of having the stomach opening toward the cardia. The tube may be buried by two rows of sutures if it is thought best. Many surgeons perform this operation with the tube passing in the direction of the pylorus—downward instead of upward. By using a larger tube, 25 or 30 French, a larger variety of food can be given.

The stomach is fixed to the abdominal wall by sutures passed through the seromuscular coats in the region of the tube and through the peritoneum and deep fascia. To prevent the stomach dropping away from the wound two of these sutures should pass through the anterior sheath of the rectus. The

tube emerges at the part of the wound where it lies most easily, and the abdomen is closed in the usual way.

The tube should project for about 5 cm. (2 inches) within the stomach, and be fixed by one of the abdominal wall sutures so that it cannot slip out for about a week. It should be clamped to prevent the escape of stomach contents (Fig. 1403). After a week it may be removed, and then introduced only for feeding. If too long an interval is allowed between the times of passage of the tube, the canal may be expected to close.

Patients upon whom gastrostomy is done are usually much in need of nourishment. For this reason in undernourished patients the tube when it is first introduced should be passed immediately on through the pylorus into the duodenum. After it has been fixed and the operation completed

FIG. 1404.—PYLORODIOSIS.
The pylorus is stretched by pressing the finger through it from the stomach toward the duodenum.

the patient may be given food which has been predigested with pepsin and hydrochloric acid. This may be done at once without fear of placing strain on the sutures. It may be left in the duodenum several days if necessary.

The technic for the application of purse-string sutures is given under Intestinal Sutures, page 626; and Vol. I, page 201.

Pylorodiosis consists in enlarging the outlet of the stomach by stretching. In malignant or cicatricial stricture this operation may give temporary relief. In some cases of spasm of the pylorus it is a useful procedure. Its field of application is small, and it is by no means without danger. Rupture of the duodenum and fatal peritonitis have been attributed to the operation. Serious bleeding may take place from the mucous membrane.

The *operation of Loreta* opens the stomach about 5 cm. (2 inches) from the

pylorus by an incision midway between the two curvatures and parallel with them. A bougie, finger or other dilating instrument is passed into the constricted pylorus while the hand steadies the parts. The dilation is

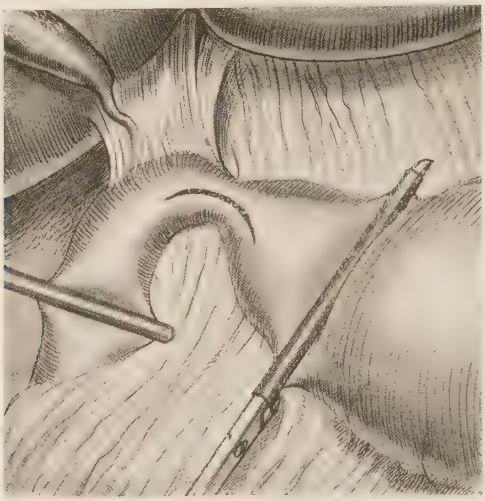

FIG. 1405.—PYLOROPLASTY. FIRST STAGE.
Stomach clamped for operation Showing line of incision.

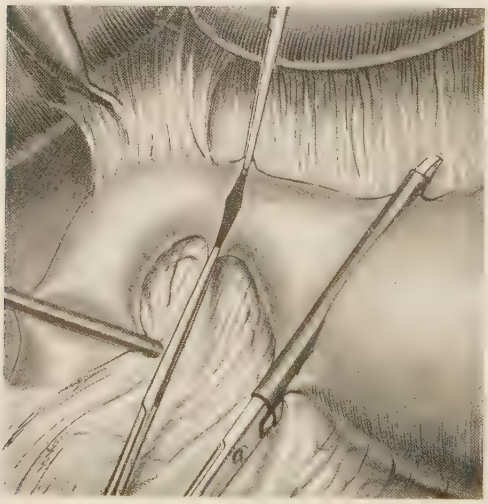

FIG. 1406.—PYLOROPLASTY. SECOND STAGE.
The lips of the wound are grasped at the middle with clamps and drawn apart until the direction of the wound is changed into that of a wound at right angles to the original incision. In this position it is sewed.

carried up to a little more than the normal size of the pylorus, if it seem safe. The wound is closed by two layers of sutures.

The *operation of Hahn* does not involve incision of the parts. The pylorus is grasped with the left hand, the tip of a gloved finger of the right hand

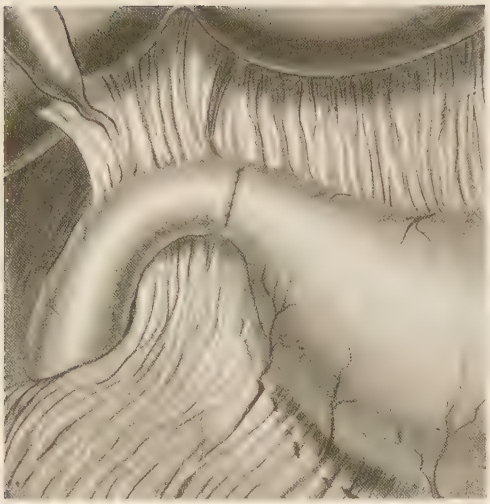

FIG. 1407.—PYLOROPLASTY. THIRD STAGE.
Result after wound has been closed with two layers of sutures—a through-and-through suture and a seromuscular suture.

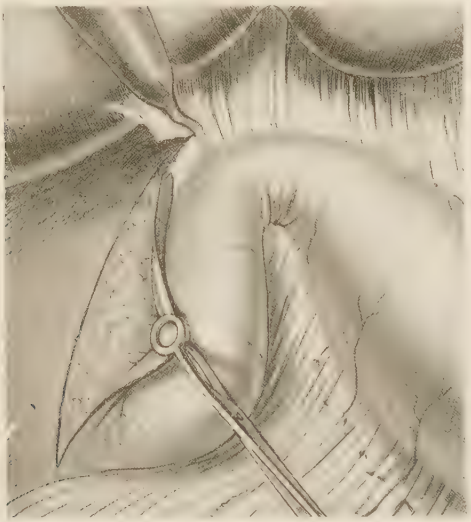

FIG. 1408.—FREEING THE DUODENUM FOR PYLOROPLASTY OR OTHER OPERATION REQUIRING GREATER MOBILITY.
Showing incision in peritoneum just external to duodenum and dissection of inner flap.

engages the wall of the stomach some distance away, and presses it into the pylorus (Fig. 1404). The fold of stomach to be pressed in should be not too near the pylorus. At first the little finger may be used. Care should be taken to engage the center of the pyloric opening and to press to the right and backward. This is one of the operations in which a cotton glove may with advantage be worn on the left hand. Not more than two fingers should be introduced.

Pyloroplasty is indicated as the operation of choice in (1) *simple pyloric stenosis;* it is of value in treating (2) *ruptured pyloric* or *duodenal ulcer;* it is indicated in the treatment of (3) *pylorospasm* in cases in which no definite cause can be found; and it serves all the purposes of gastroenterostomy in dealing with (4) *ulcers of the stomach* and *duodenum*, which are near the pylorus, and at the same time it permits dealing directly with the ulcer.

Pyloroplasty by a single incision is done according to the method of *Heineke* and *Mikulicz.* The abdomen is opened by an incision between the ster-

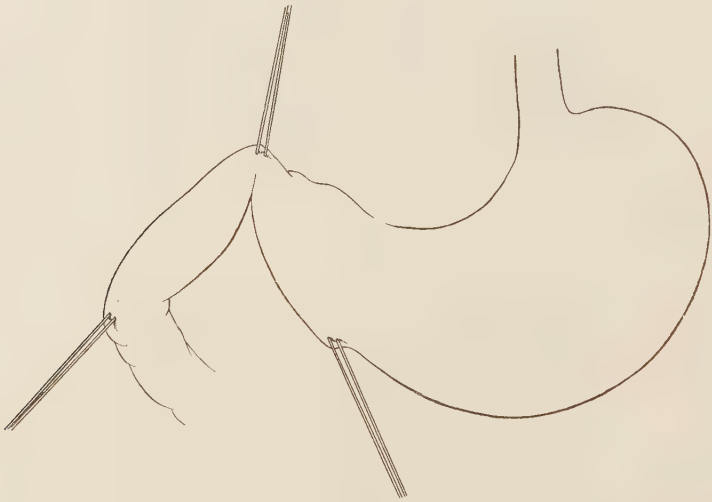

Fig. 1409.—Pyloroplasty. Operation of Finney. First Stage.
Showing position of traction sutures as the first step in the no-clamp operation.

num and navel. Adhesions about the pylorus are separated and clamps applied above and below, about 7.5 cm. (3 inches) from the stricture. The upper clamp is applied to the stomach with the posterior blade penetrating the gastrocolic omentum. An incision, about 2 cm. (¾ inch) long, following the natural curve of the canal, is made in front of the pylorus from the stomach to the duodenum. The interior of the pylorus is then inspected, and the incision is carried in either direction until healthy stomach and duodenum appear at its extremities. Redundant mucous membrane is cut away. The incision may be 5 cm. (2 inches) long (Fig. 1405). The middle of each lip is then grasped with narrow forceps, and drawn apart as far as possible. This causes the ends of the incision to approach (Fig. 1406). The wound is then sutured in this position, at a right angle to the original incision, with two layers of sutures as for gastrotomy (Fig. 1407).

For stenosis the incision may be as long as 7.5 cm. (3 inches). The center should be at the pylorus.

This operation is done for benign contractures, such as follow pyloric

ulcer. If there is much thickening, the operation may be difficult, and a diamond-shaped resection may be necessary in order to secure good approximation of the wound. Mayo has called attention to the fact that dense adhesions commonly follow the operation, which fix the pylorus in an abnormally high position. The operation should not be done if active ulceration and inflammation are present; nor can it be done where dense adhesions fix the pylorus. Moynihan regards it as an unsatisfactory operation. Most surgeons are agreed that it has a field in cases of narrow constriction, with a

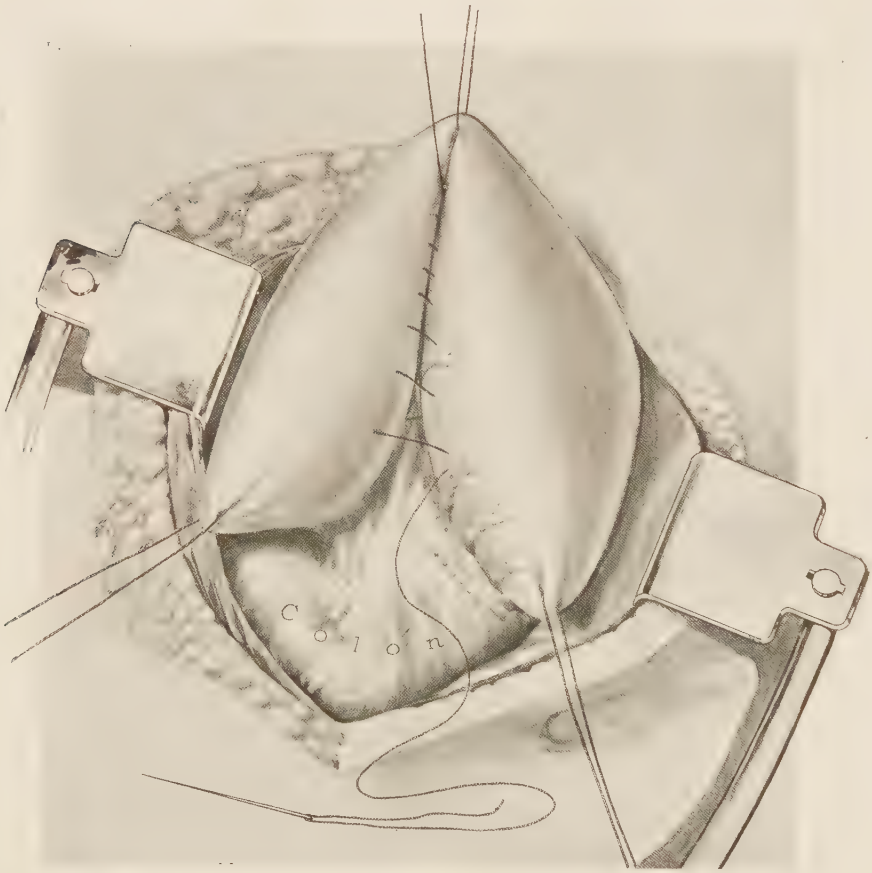

FIG. 1410.—PYLOROPLASTY. OPERATION OF FINNEY. SECOND STAGE.
The pyloric, duodenal and gastric traction sutures have been applied, and the posterior seromuscular suture is in process of application.

healed mucosa, and without dense perigastric adhesions. Of the cases operated upon by this method, about one-third have required subsequent operations for the relief of pyloric obstruction. This has been largely because the incision was too short.

Pyloroplasty combined with gastroduodenostomy is an operation devised by J. M. T. Finney (Bulletin Johns Hopkins Hosp., July, 1902). It is one of the most useful operations in gastric surgery, and is destined to play a larger rôle than has yet been its lot. An incision is made to the right of the median

line, its lower end at the level of the navel. It should be about 10 cm. (4 inches) long, and the pyloric region exposed. Adhesions should be divided. In order to give the duodenum greater mobility, so that it may be displaced inward, the peritoneum lying to the outer side of the descending part should be divided. This incision to the right of the duodenum divides vertically the delicate layer of peritoneum in front of the right kidney as it is about to

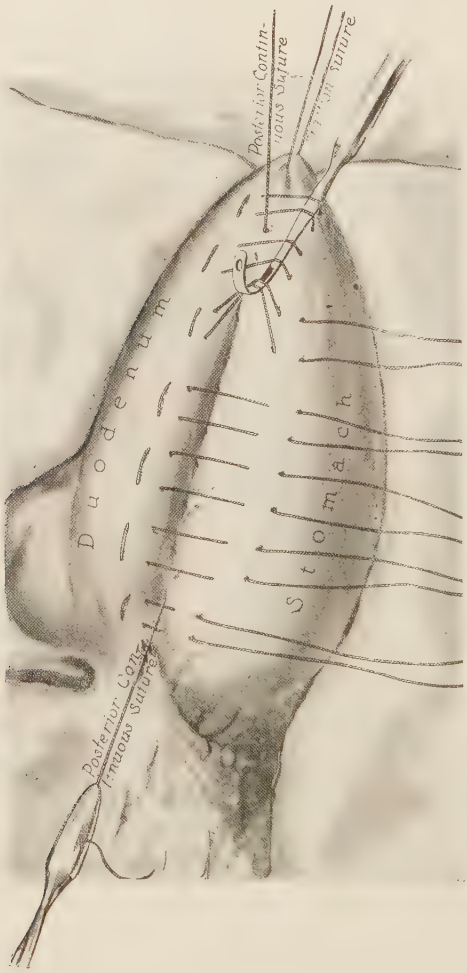

FIG. 1411.—PYLOROPLASTY. OPERATION OF FINNEY THIRD STAGE.
The posterior seromuscular suture has been applied. The anterior layer of mattress sutures is to be retracted by hooks.

pass to form the upper layer of the transverse mesocolon at the hepatic flexure. The incision ends above at the entrance to the foramen of Winslow. The duodenum may now be drawn inward, being raised from the vertebral column and the great vessels. If further relaxation is necessary the incision may be carried downward through the upper layer of the transverse mesocolon, and upward to divide the anterior peritoneal layer of the extreme

right edge of the gastrohepatic omentum. This latter division is carried across the suspensory ligament of the pylorus (Fig. 1408). At first it may seem that the pylorus and duodenum are so fixed that the operation cannot be done, but by division of the peritoneum and careful blunt dissection the operation becomes easily possible.

After about 7 or 8 cm. (3 inches) of duodenum have been freed sufficiently to permit the duodenum to be placed against the pyloric end of the stomach,

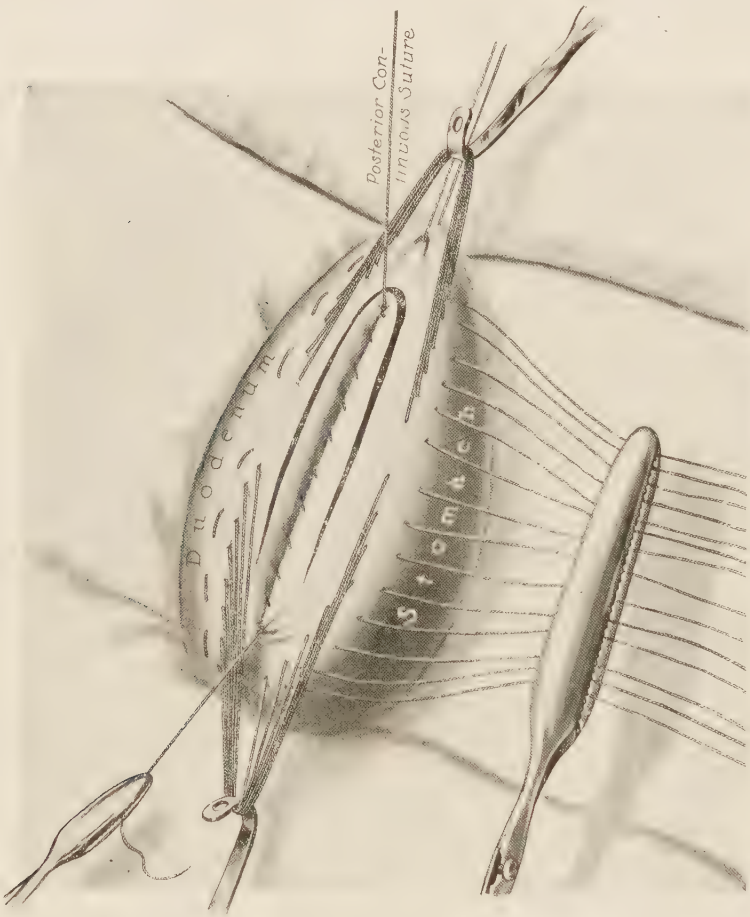

FIG. 1412.—PYLOROPLASTY. OPERATION OF FINNEY. FOURTH STAGE.
The anterior row of seromuscular mattress sutures are retracted above and below and the stomach and duodenum incised.

a suture to be used for traction is applied in the upper wall of the pylorus. A second traction suture is placed in the anterior wall of the stomach and a third suture in the anterior wall of the duodenum (Fig. 1409). These last two sutures should be at points equidistant from the duodenal suture (about 12 cm.) and mark the lower ends of the duodenal and gastric incisions respectively. Traction is then made upward on the pyloric suture and downward on the two other sutures. The two folds are brought together and su-

tured as for lateral anastomosis with a continuous suture. Silk is commonly used (Fig. 1410).

After the posterior suture has been completed and tied, the anterior layer of seromuscular sutures is inserted. This should be a row of interrupted mattress sutures which are not tied but hooked out of the way with an aneurism needle above and below (Fig. 1411).

The incisions in the stomach and duodenum are then made. The opening planned for should be about 10 cm. (4 inches) long. These are the same incisions as for lateral anastomosis excepting that they are connected above

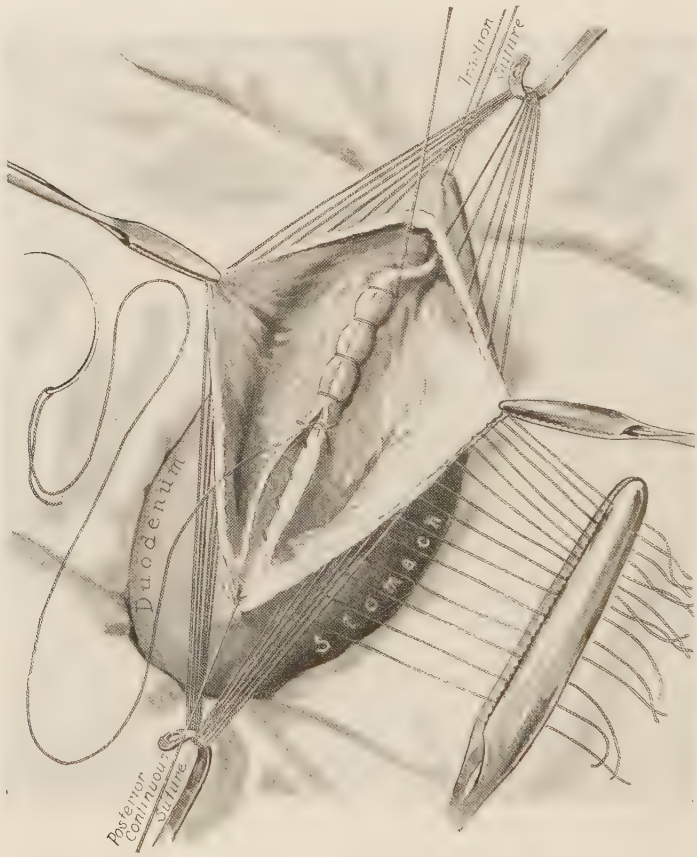

FIG. 1413.—PYLOROPLASTY. OPERATION OF FINNEY. FIFTH STAGE. Through-and-through suture in process of application.

at the pylorus (Fig. 1412). Hemorrhage is checked. The redundant mucous membrane is trimmed off. Ulcers are looked for and if present excised. The two edges of the spur are sewed together by a continuous through-and-through suture of catgut starting at the pylorus and continuing to the base (Fig. 1413). From this point it continues to unite the front of the opening ending at the pylorus. (Finney omits this anterior suture.) It should be interrupted at intervals by a tie. Chromicized catgut is used for the suture which passes through the mucous membrane. The

seromuscular mattress sutures are then tied completing the anastomosis (Fig. 1414). If a complete anterior through-and-through suture has not been applied there should be added to the anterior serosa suture a second layer of continuous sutures (Fig. 1415).

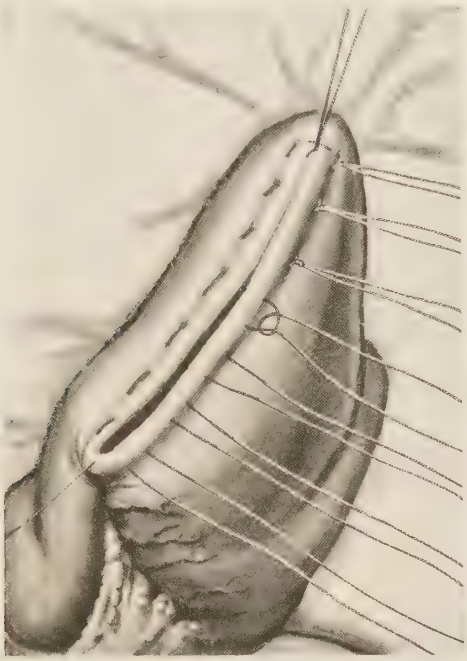

FIG. 1414.—PYLOROPLASTY. OPERATION OF FINNEY. SIXTH STAGE. Completion of operation by tying mattress sutures.

FIG. 1415.—PYLOROPLASTY. OPERATION OF FINNEY. Diagram showing result of operation. *A*, Before operation; *B*, after operation.

This operation may be done with clamps as employed in lateral anastomosis. The operation with clamps has the advantage that the parts are more firmly held and bleeding during the operation is not a factor (Figs. 1416 and 1417).

FIG. 1416.—PYLOROPLASTY WITH CLAMPS.
The stomach and duodenum are each grasped by the clamps

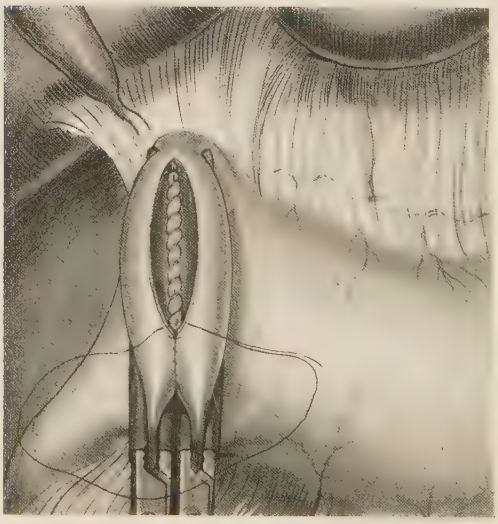

FIG. 1417.—PYLOROPLASTY WITH CLAMPS.
The posterior seromuscular and through-and-through sutures have been applied. The anterior through-and-through suture is in process of application.

Moynihan used an angular clamp (Fig. 1418) which gives more room and better apposition. He advised the operation in cases in which pyloric spasm is a prominent symptom, and where an ulcer is located near the pylorus. He regards gastro-enterostomy as easier and safer in the ordinary cases of pyloric stenosis with dilatation and hypertrophy of the stomach. All of these opinions are probably modified by the fact of greater experience with gastrojejunostomy. A surgeon who has had as much experience with this operation as with gastrojejunostomy should find it just as easily performed.

Gastroduodenostomy was done by Kocher through an oblique incision beginning at the middle line and passing 4 cm. (1½ inches) below and parallel to the right costal border. Everything is divided in this line, excepting that in muscular patients the transversalis muscle is split. A pad is placed under the liver and the organ retracted upward. The stomach and colon are held aside. The thin peritoneum in front of the right kidney is divided by a vertical incision 4 cm. (1½ inches) external to the second part of the duodenum. This incision is carried downward through the upper layer of the transverse mesocolon as far as the blood-vessels, after the method described for pyloroplasty combined with gastroduodenostomy (page 741). By blunt dissection with the finger passed into this wound, the duodenum is displaced forward and inward, separating it from the vertebral column, vena cava and aorta. The clamps for lateral anastomosis are placed so that the opening in the stomach shall be about 2 cm. (¾ inch) from the greater curvature parallel to it, and as near the pylorus as the disease will permit. The opening in the duodenum should be made on its anterior surface. The technic is the same as for lateral anastomosis of the intestines (Fig. 1419).

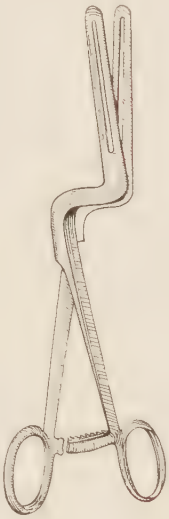

FIG. 1418.—ANGULAR CLAMP OF MOYNIHAN FOR PYLOROPLASTY.

Pylorectomy is done for carcinoma of the pylorus, in cases in which a cure of the disease seems possible. It may be done for ulcer in cases in which gastro-enterostomy cannot be accomplished with facility, and in which the area of ulceration and induration is extensive. When done for carcinoma, the lymphatic relations should be borne in mind (see Anatomy of Stomach, page 698).

A small incision is made midway between the ensiform cartilage and the umbilicus. Two fingers are introduced, and if the disease is found to be inoperable the wound is closed. If operation is decided upon, the wound is enlarged up to 10 or 13 cm. (4 or 5 inches). The gastrohepatic omentum is doubly tied close to the liver for a sufficient distance and cut between the ligatures. This frees and exposes the pyloric end of the stomach.

The control of hemorrhage is the next step. The four blood-vessels supplying the pylorus should be tied. The gastric artery is tied doubly and cut about 2.5 cm. (1 inch) below the cardiac orifice as it courses to the lesser curvature between the layers of the lesser omentum. The superior pyloric, coming from the hepatic artery, is doubly tied and divided. By passing the fingers beneath the pylorus the gastrocolic omentum is raised from the transverse mesocolon, and ligation of the right gastro-epiploic or the gastroduodenal artery is accomplished. The left gastro-epiploic is then tied at the point to which the resection is to be carried; and the gastrocolic omentum is tied and divided. In ligating the gastroduodenal artery and the

gastrocolic omentum the structures should be lifted forward in order to avoid the middle colic artery which passes beneath the transverse mesocolon (Fig. 1420).

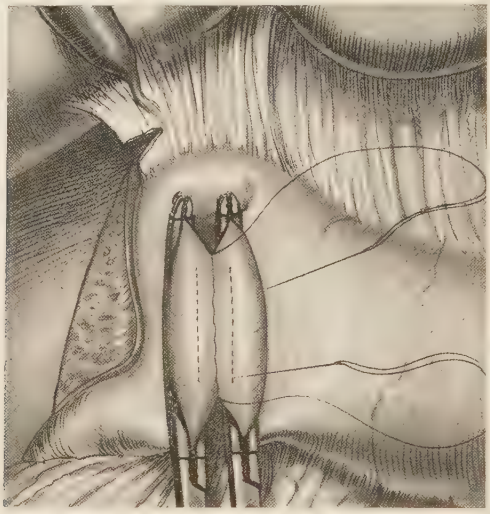

FIG. 1419.—GASTRODUODENOSTOMY.

The posterior seromuscular suture has been applied. The dotted lines show the places of incision. Note that the duodenum has been mobilized by incision and dissection of the peritoneum external to it.

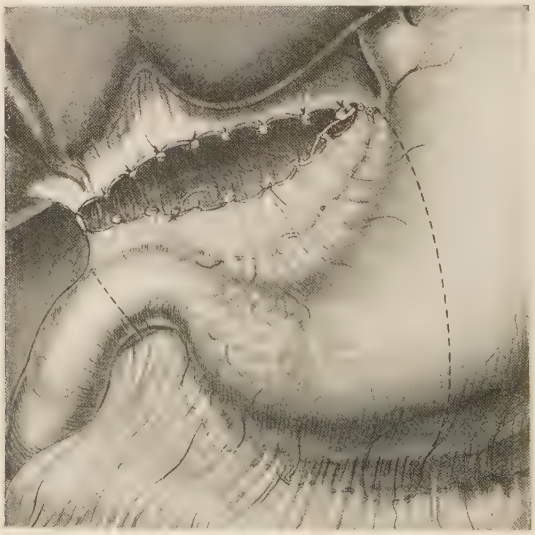

FIG. 1420.—PYLORECTOMY. FIRST STAGE OF OPERATION.

The gastrohepatic omentum has been tied and cut. Dotted lines show places of incision.

The duodenum is doubly clamped and divided between with the cautery. A running suture is applied through the distal stump and tied. The clamp

is removed. A purse-string suture, applied 2 cm. (¾ inch) below the end of the stump is tied down to invert the free end.

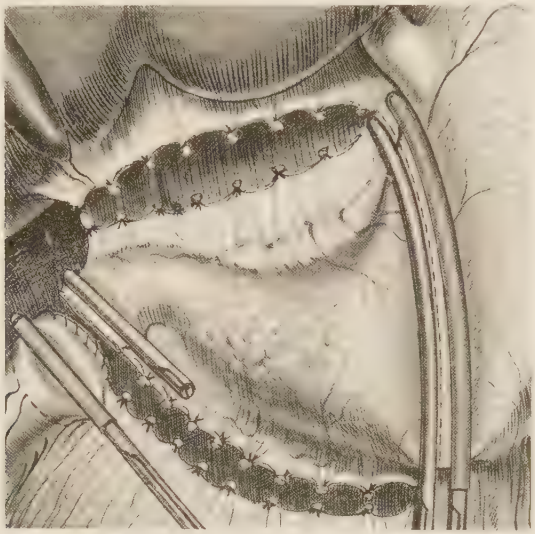

FIG. 1421.—PYLORECTOMY. OMENTA TIED AND CUT. ALL CLAMPS IN PLACE READY FOR THE RESECTION.
Distal stump of duodenum has been closed.

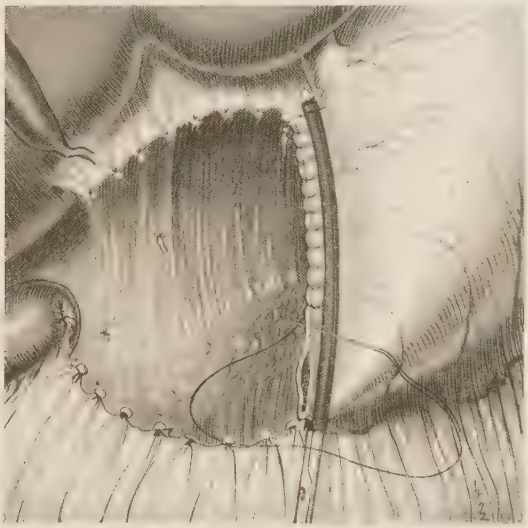

FIG. 1422.—PYLORECTOMY. RESECTION HAS BEEN DONE.
All clamps have been removed except last stomach clamp. Continuous suture applied to cut edge of stomach.

A long rubber-covered stomach clamp is then caused to grasp the stomach between the point at which the gastric artery was tied and the point of ligation of the left gastro-epiploic. This clamp should not be closed so tightly

as to damage the tissues. A second clamp, which need not be covered, is applied on the tumor side. The stomach is then divided with the cautery or scissors 1 cm. (⅓ inch) from the upper clamp. It is well to catch the edge of the stomach in several places with toothed forceps as it is divided, to prevent the retraction of its edges through the jaws of the clamp (Fig. 1421). The pyloric segment of the stomach, held by a clamp at each end is removed. The edge of the stomach remaining is then sewed over-and-over with a continuous suture from the greater to the lesser curvature and thence back again to the starting point and the ends of the suture tied. This suture passes through all the coats of the stomach, and prevents bleeding as well as leakage (Fig. 1422).

The clamp is then removed, and any point that bleeds is caught and tied. A continuous suture, involving only the seromuscular layers, is then applied

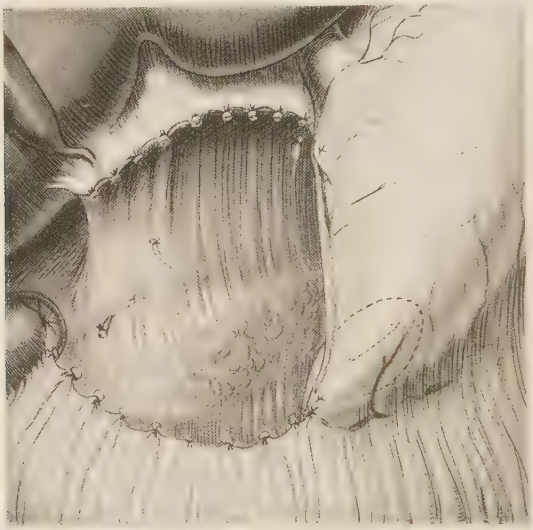

Fig. 1423.—Pylorectomy. Operation about Completed.
Posterior gastroenterostomy shown in dotted lines.

sufficiently far from the first suture to allow easy covering of the free edge. The operation is then continued by making a posterior gastrojejunostomy (Fig. 1423).

Billroth left the duodenum open, reduced the size of the stomach opening, and made a direct anastomosis of the duodenum and the lower end of the stomach (Fig. 1424). The results of this operation at first were not good. He then tried closing both viscera and doing gastrojejunostomy in the ordinary way. This latter operation has given the best results, although in suitable cases in which the operation can be done without tension, the end-to-end anastomosis is now employed by some surgeons with much success.

W. J. Mayo preferred the gastro-enterostomy, as there is no tension and the operation is done with uninjured tissues. The posterior operation is done if the patient's condition is good. If haste is necessary, anterior gastrojejunostomy is indicated. If great haste is necessary the anastomosis may be done with a button.

Gould showed that the tendency of the mucous membrane to project may be obviated by cutting the stomach wall obliquely so that more of the mucosa is cut away than the seromuscularis. Drainage should only be used if there has been accidental soiling of the wound (for After-treatment, see page 776).

Resection of the pyloric end of the stomach (partial gastrectomy and pylorectomy) in the hands of experienced surgeons gives a mortality of 8 or 10 per cent. Assuming a growth, the center of which is in the last third of the stomach close to the middle third on the anterior wall at the lesser curvature, the operation should consist of resection of the distal half of the stomach. The technic of operation as practised by W. J. Mayo and described by him (Jour. Am. Med. Assoc., May 14, 1910) is as follows:

The lesser peritoneal cavity is opened through the gastrohepatic omentum. The superior pyloric artery is ligated in two places as far as possible from the duodenum and cut between the ligatures. The superior border of the

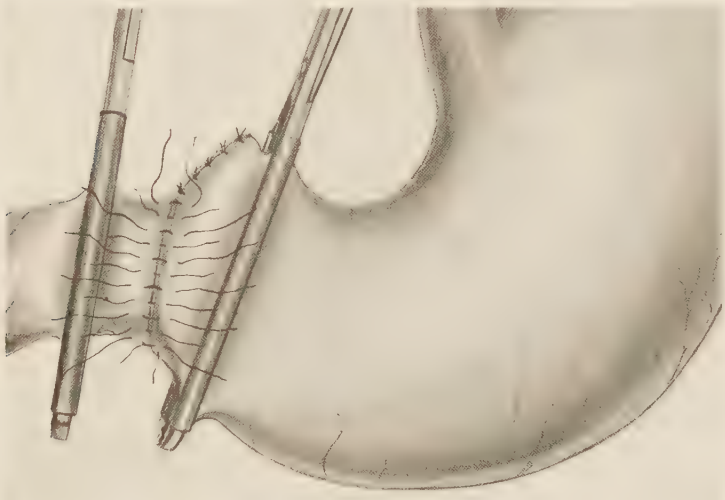

Fig. 1424.—Pylorectomy with End-to-end Anastomosis of Stomach and Duodenum.

duodenum is thus freed for a distance of 4 or 5 cm. (1½ or 2 inches). The object of this step is to include the glands which lie beside the artery. It should be remembered that the common bile duct lies close to the artery and must not be injured.

Adhesions of the stomach or duodenum to the liver should be separated. The stomach should be drawn downward and to the right and the gastric artery caught and ligated close to the celiac axis. This artery is best tied by passing a ligature in a needle and tying securely. The anterior and posterior gastric branches should be caught and tied so that the fat and glands and distal part of the vessel can be dissected free from the upper part of the lesser curvature, exposing a space 3 cm. (1½ inches) in extent next to the cardiac orifice. This dissection should be made very carefully because of the probable involvement of this region. The whole of the lesser curvature right up to the cardia should be included in the resection.

The greater curvature should be examined for the lymphatic glands. Even when not carcinomatous these glands are usually visible. Double ligatures should be tied about the left gastro-epiploic vessels to the left of

the glands and cut between. The anterior and posterior gastric vessels should be tied as they pass from the stomach. The greater curvature should thus be cleared or a distance of at least 3 cm. (1½ inches). The transverse colon is drawn into view so that the middle colic artery can be examined at intervals to avoid injury, and the gastro-epiploic vessels tied with the gastrocolic omentum in sections from left to right sufficiently close to the transverse colon to leave the glands lying on the vessels of the greater curvature by a good margin. If it be found that the avascular area, which lies in the circle of the middle colic vessel and the posterior layer of the mesocolic peritoneum, is attached to the growth, the attached peritoneum may be cut out and removed with the growth. The opening thus made in the transverse mesocolon may be used later through which to make the gastrojejunostomy. As the dissection proceeds to the right, the middle colic artery is exposed and traced to its origin in the superior mesenteric artery just at the lower



Fig. 1425.—Partial Gastrectomy.
The vessels have been tied and the omenta divided.

edge of the pancreas, otherwise it may be accidentally injured. Mayo states that Kronlein has shown that in three out of four cases obliteration of the middle colic vessel will lead to gangrene of a portion of the transverse colon and necessitate a coincident resection.

The next step in the operation is removal of the inferior gastroduodenal glands which lie below and to the right of the pylorus about the head of the pancreas and in the curve of the duodenum. The gastrocolic omentum is tied in sections close to the transverse colon, the fat and glands are lifted up from over the head of the pancreas, and the blood-vessels, anastomosing with the branches of the superior pancreatoduodenal artery, are tied. Separation is continued upward, clearing the inferior border of the duodenum for at least 5 cm. (2 inches) until the gastroduodenal artery is reached in the groove between the head of the pancreas and the duodenum behind the pylorus. Division of these vessels allows raising in one piece all this group of glands (Fig. 1425).

Next the posterior surface of the upper duodenum is separated from the pancreas. If the pancreas is adherent to the gastric growth, a piece is shaved off, allowing it to remain attached to the growth by adhesions. In some cases it becomes necessary to remove more or less of the pancreatic structure. If the involvement is extensive Mayo thinks it is better to leave this part of the operation until the stomach is either cut across and separated from the duodenum, or the line of stomach section on the cardiac side is finished and the stomach turned over in order that this portion of the dissection may be completed under inspection. If such injuries to the pancreas are properly cared for, he has not found that they give rise to serious consequences. As a rule these operations are more serious as they become extensive but he has not found any special mortality due to operable pancreatic complication. The method of treating such an injury to the pancreas is

Fig. 1426.—Partial Gastrectomy.
Clamps are placed to isolate the segment to be resected.

to cover it as far as practicable with the sheath and posterior peritoneum, and after completely closing the end of the duodenum, if possible, the stump of the duodenum should be buried in the wounded surface of the pancreas.

It will usually be found that the duodenum beyond the pylorus is not involved to any considerable extent, but to make sure it is best to remove about 2.5 cm. (1 inch) of it. Compression forceps are placed next to the pylorus, and 1.3 cm. (½ inch) below this clamps are placed on the duodenum. The duodenum is divided between, and both raw surfaces cauterized with the actual cautery. The pyloric end of the stomach is then turned over on the left side of the patient. The stump of the duodenum is sutured with a continuous catgut suture. The clamp is removed. About 2 cm. (¾ inch) below this a purse-string suture is placed about the duodenum, the ends of the catgut strands are cut short and the duodenal stump

invaginated in a manner similar to the stump of an appendix in appendectomy. A second suture is now placed on the duodenum; behind, it catches the pancreatic sheath so that the stump may be buried against the head of the pancreas. Finally the stumps of the adjacent tied gastrocolic and gastrohepatic omenta are so adjusted by fine sutures as to give further protection. The field of operation is searched for bleeding points and protected with gauze.

Next the stomach is drawn to the right and holding clamps placed from the space cleared on the greater curvature to the space cleared on the lesser curvature. When the stomach is cut across these clamps sometimes slip near the cardia and the stomach retracts. To prevent this Mayo uses a pair of bayonet holding clamps which are placed on the proximal side from above downward, grasping the upper part of the stomach halfway across. A

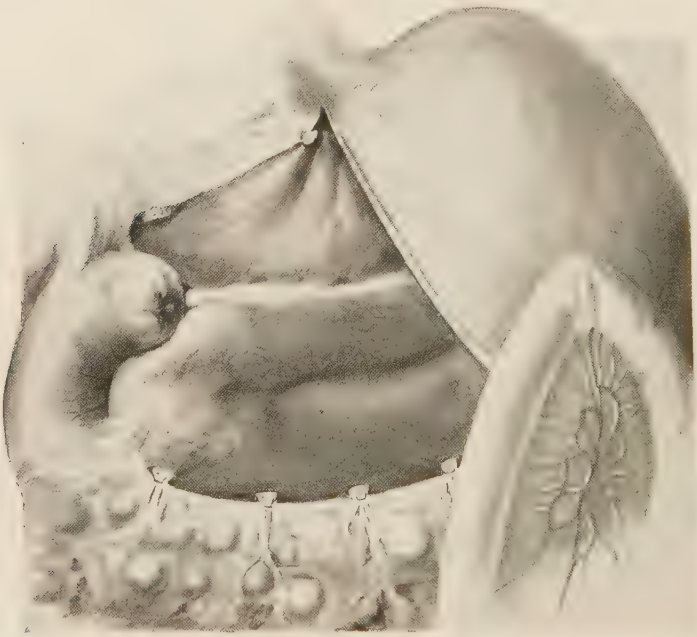

Fig. 1427.—Partial Gastrectomy with Anterior Gastro-enterostomy. The pyloric end of the stomach has been removed, the duodenum closed and the jejunum anastomosed anteriorly to the stomach.

clamp is now placed distally to prevent leakage from the end to be amputated, and the stomach divided between. The divided proximal gastric surface is cauterized with the actual cautery and the stomach turned in by a continuous chromic catgut suture beginning on the greater curvature. This suture is applied quite tightly. It starts on the mucous surface, passes through all the coats to the peritoneum and back on the opposite side through all the coats to the mucous membrane, and is then tied and the end cut. The suture now passes through all the coats from the mucous to the peritoneal coat and begins on the opposite side by passing through all the coats from the peritoneum to the mucous and then back on the same side from the mucous to the peritoneum. This is repeated on alternate sides until one-

half or two-thirds of the stomach is closed. The cut margins now approach the transverse holding clamp so closely that inversion can not be accomplished. This clamp is removed and the bayonet clamp, which grasps the upper part of the stomach to the left of the cardia, is depended on during the completion of the suture. A half dozen mattress tension sutures of medium-sized linen are now placed, turning in the catgut row, and over this a continuous suture of fine linen is applied (Fig. 1426).

Continuity of the gastro-intestinal canal is best secured by a posterior gastrojejunostomy with the jejunum passing to the left and as short as will

Fig. 1428.—Gastrojejunostomy Following Resection of Pyloric End of Stomach. Note that the size of the stomach orifice is reduced by suturing from above.

permit the intestine to reach the stomach without tension. In some cases the remaining pouch of the stomach is so small that anterior gastrojejunostomy on a 45-cm. (18-inch) loop, the jejunum running to the right, can be done more easily and quickly and has given equally good results in Mayo's hands (Fig. 1427).

The two-row suture method is preferred in performing gastro-enterostomy. But in addition to this it is recommended to stitch the intestine to the stomach 2.5 cm. (1 inch) above the proximal side with a mattress suture. A

second mattress suture is placed about 2 cm. (¾ inch) from the distal side, holding the intestine to the stomach. The object of this is to prevent the intestine from kinking at the anastomosis. It is possible in some cases to connect the duodenum directly with the stomach pouch. This can not often be done in operations for cancer, but it can commonly be practised in resections for ulcer. Mayo prefers closing the duodenal stump and doing an independent gastro-enterostomy.

The radical operation for cancer of the pyloric end of the stomach should begin with removal of the groups of lymphatics adjacent to the disease, and the ligation of the four vessels. W. J. Mayo proceeded in some cases after the method of E. Polya (Surg., Gyn. & Obst., xix, 1914). The diseased segment of the stomach is removed as above described. The stump of the duodenum is closed. An opening is then made in the transverse mesocolon and the upper part of the jejunum drawn through the opening.

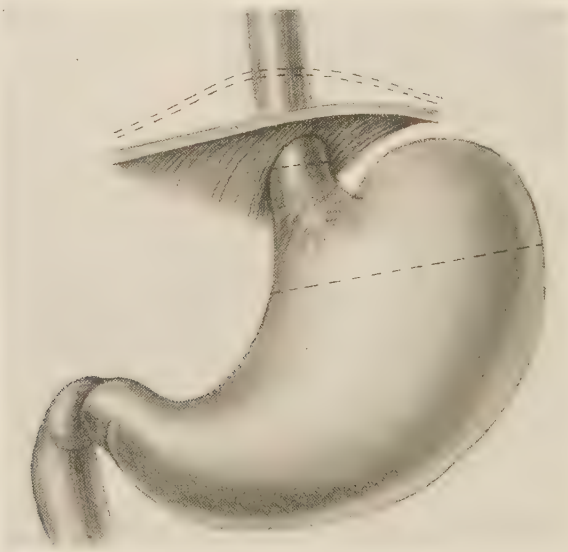

Fig. 1429.—Resection of Cardiac End of Stomach for Cancer. Showing lines of incision and upward displacement of diaphragm.

The stump of the stomach which is held in a crushing clamp and the raw edges of which have been cauterized is placed at the side of the loop and united by the serosa-to-serosa suture of fine silk as is done for gastro-enterostomy (Fig. 1428). If the opening in the stomach is larger than is needed, it can be reduced as the suture is applied.

Rubber-guarded holding clamps are then applied to the stomach and intestine, the crushing clamp is removed, the jejunum incised, and the through-and-through suture of chromicized catgut is applied around the whole circumference of the opening. The outer serosa suture is then completed. The anastomosis is then drawn through the opening in the transverse mesentery and the margin of the opening fastened to the wall of the stomach by a number of sutures.

Resection of the cardia for carcinoma can usually be done entirely through the abdomen, but in some cases so much of the esophagus is involved that a thoracic operation for resection of the lower esophagus must be added. For

gaining better access to the vault of the diaphragm, in addition to the abdominal incision, an incision may be made along the free border of the ribs on the left side and the seventh costal cartilage divided near the sternum. (See also operations for gaining access to the lower end of the esophagus, page 458.) By freeing the esophagus from the diaphragm, it is possible in many cases to draw it down 3 or 4 cm. (1¼ or 1½ inches) or more. As a matter of fact it is the upward displacement of the diaphragm with retractors that must be counted upon to give access to the esophagus. It is really easier to pull the stomach up into the thorax than to pull the esophagus down into the abdomen.

When sufficient mobility can be secured and the disease does not extend high, after the resection the stomach wound may partially be closed and the esophagus anastomosed at the left end of the stomach (Fig. 1429). Gastros-

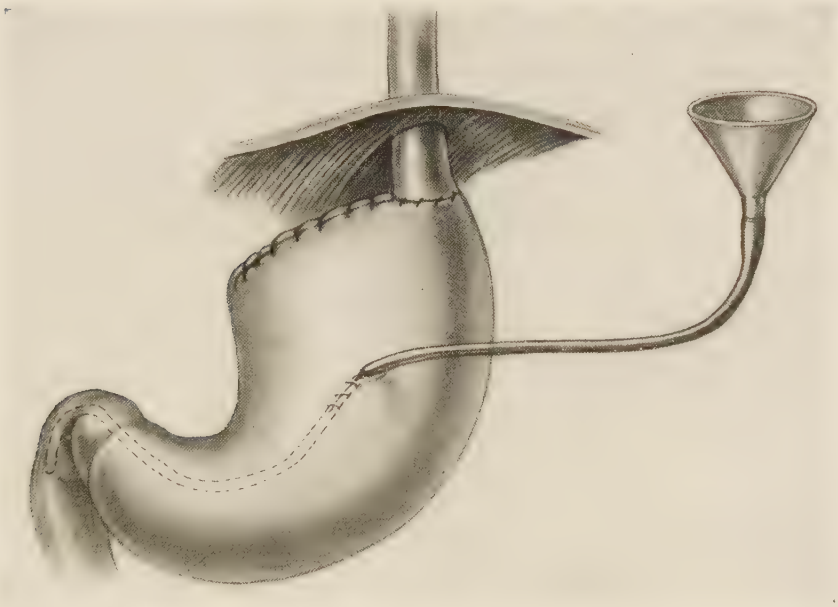

Fig. 1430.—Resection of Cardiac End of Stomach Completed. Gastrostomy has been added and the tube passed into the duodenum.

tomy should be added, and the tube placed in such a position that it can be passed through the pylorus into the duodenum. After the operation duodenal feeding should be practised, and the stomach occasionally cleansed with sterile water (Fig. 1430).

In a case operated upon by Kümmell (Verhandl. Deutsch. Gesells. f. Chir., 1910) there was so much separation after the resection that anastomosis could not be done. A tube connected with the esophagus was brought out through the wound for drainage, and a tube connected with the stomach was used for feeding. Later a single tube was inserted to connect esophagus and stomach. In a case such as this a loop of intestine may ultimately be used to complete the connection.

W. Meyer (Annals of Surg., December, 1915) advocated a two- or three-stage operation. The first operation begins with abdominal exploration with special reference to examination of the cardia, and closes with gastrostomy.

The second operation consists of excision of the tumor and establishment of a new exit for the esophagus, either laterally in the axillary line of the chest, or the whole proximal esophagus may be brought out of the mediastinum and implanted under the skin down the front of the thorax. This latter operation may be divided into two operations. This program means a transpleural operation. The esophagus is reached by subperiosteal resection of the sixth to the twelfth ribs. By connecting the esophagus, which is stitched to the skin, with the gastrostomy fistula, by a long tube, the patient may drink fluids (Fig. 1431).

Ach, of Munich, performed a one-stage operation as follows: Through a left oblique abdominal incision the cardia is examined. The esophagus is then exposed in the left side of the neck (see Cervical Esophagotomy, page 442), isolated, a tape passed around it, and the wound tamponed. The tumor is next exposed through the abdomen and isolated from its surrounding connections. The best exposure is secured by continuing

Fig. 1431.—Resection of Cardiac End of Stomach for Cancer.
Showing possibilities of connecting stump of esophagus and stomach by means of an external rubber tube as practised by J. H. Zaaijer of Leiden.

an incision from the epigastrium opposite the eighth left cartilage, downward and outward to the tip of the eleventh rib, thence upward and backward to the eighth interspace in the midaxillary line. The eighth, ninth and tenth ribs are divided in the axillary line, and the costal cartilage of the seventh near the sternum. The flap is retracted upward, the esophagus clamped and divided. The ligated esophagus is then dissected free in the posterior mediastinum, brought out through the neck wound, the esophageal opening in the diaphragm closed, and the esophagus implanted under the skin at the left of the sternum. The resection of the stomach is then completed at a safe distance beyond the disease, the stomach wound closed, and a gastrostomy done after the method of Witzel, the tube being brought out and later connected with the extrathoracic esophagus.

For bringing the diaphragm well into view it is desirable that the dorsal spine should be in strong lordosis. This may be accomplished by placing sand-bags behind the lower dorsal region or by using an operating table

which is capable of lowering both ends of the spine while remaining fixed at the center. The extraction of the esophagus is best done by inverting it in itself.

For further information on the subject the reader is referred to Meyer's admirable article, cited above.

Resection of gastric ulcer, whether done at the pylorus or elsewhere, is best accomplished by an incision removing an elliptic piece of the wall of the stomach. The ellipse should contain the indurated tissue external to the ulcer. Usually it should have its long axis in the direction of the axis

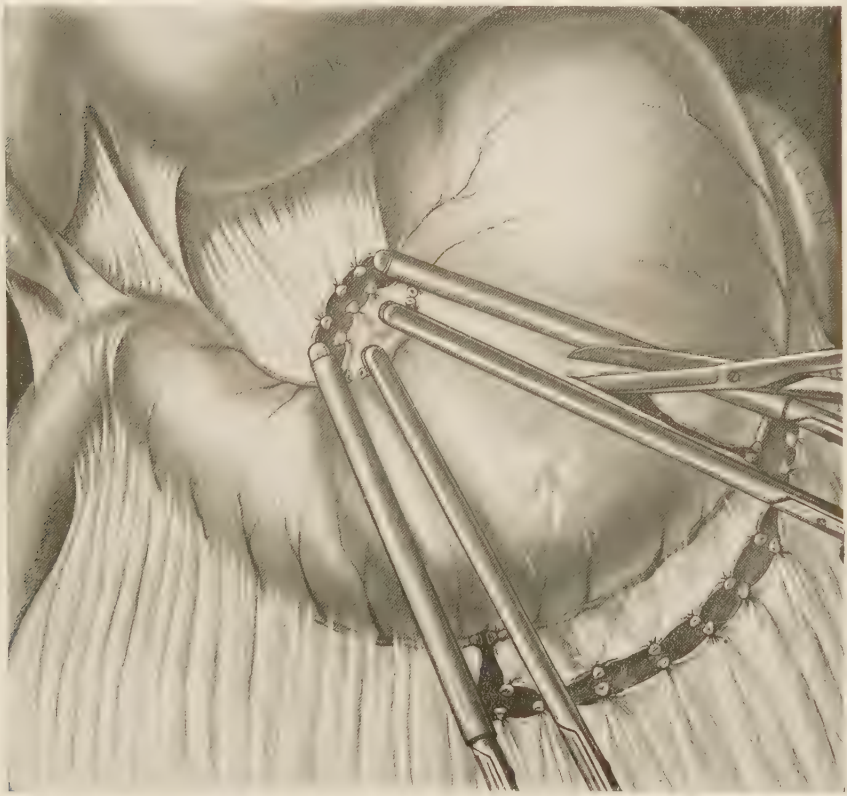

Fig. 1432.—Partial Gastrectomy.
Vessels tied; omenta cut; clamps applied; scissors cutting stomach.

of the stomach. At the pylorus this wound may usually be a part of the wound needed for pyloroplasty by the method of Finney. After simple excision the wound should be closed with two layers of sutures as for gastrotomy (page 730).

A small ulcer at the pylorus should be excised, and if gastro-enterostomy is not done the wound should be closed transversely so as to prevent narrowing of the pylorus. After excision of a large ulcer at the pylorus pyloroplasty, gastroduodenostomy or gastrojejunostomy should be done.

Partial gastrectomy consists in resection of some portion of the stomach wall. It is applied usually for malignant disease, ulcer or stricture. The technic is essentially the same as that described above for resection of the

pyloric end of the stomach. Operating for malignant disease, the stomach is exposed by a median incision as for pylorectomy, and examined. It is withdrawn from the abdomen, and the lines of resection determined. The vessels of the greater and lesser omentum running to the part of the stomach to be resected are doubly ligated. The omentum is divided between these ligatures. This frees the stomach along its lesser and greater curvatures. At the ends of the openings in the omenta the vessels of the stomach are doubly ligated and cut—these are the gastric artery at the lesser curvature and the epiploic vessels along the greater curvature. Two straight stomach

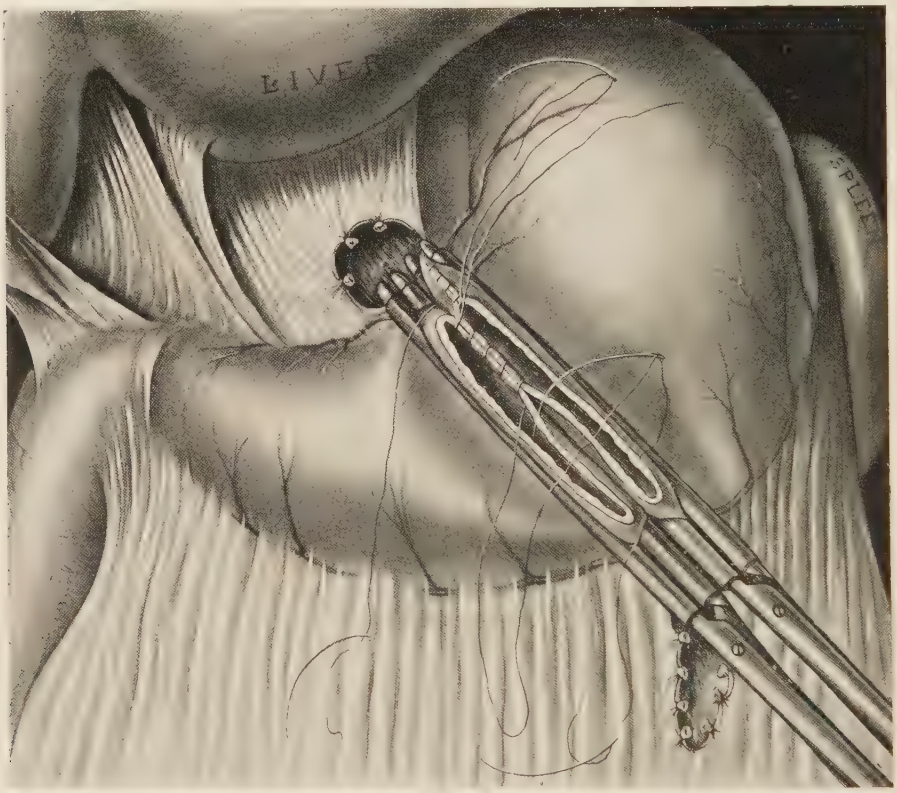

Fig. 1433.—Partial Gastrectomy.

The diseased segment has been removed and the cut ends approximated. The first half of the seromuscular suture has been applied. The through-and-through suture has been begun. Showing method of reducing size of the opening in the cardiac segment.

clamps, about 2.5 cm. (1 inch) apart, are then placed on either side of the diseased part (Fig. 1432).

Gauze pads are passed behind the stomach, and the diseased segment is cut away close to the two middle clamps. For this purpose scissors or the cautery knife may be used. Care should be taken not to soil the field of operation. The cut edges should be wiped clean. Having removed the resected portion, the free edges of the stomach are then brought together and placed in position for suturing. The cardiac end is usually larger than the pyloric end, and should be equalized by partially suturing one end of the

opening. A continuous seromuscular suture is first applied to the posterior half of the stomach. This suture is tied at the upper and lower ends and left long. A through-and-through suture of all of the coats of the stomach is then applied throughout the entire circumference of the openings (Fig. 1433). Some surgeons apply two such sutures in order to be sure that bleeding is controlled. Whether one or two are inserted, the suture should be tied or looped about at frequent intervals to prevent unequal drawing. When the through-and-through suture is completed, the second or anterior half of the seromuscular suture should be inserted. The clamps are removed. The gauze is taken away and the omental openings closed by a few sutures (Fig. 1434).

Fig. 1434.—Partial Gastrectomy.
Showing result of operation.

This is partial gastrectomy with reunion of the stomach wall. If reunion cannot be done then gastro-enterostomy is called for.

Total gastrectomy is rarely indicated. When much of the stomach is involved in disease, the disease usually has spread beyond the stomach, contraindicating gastrectomy; and if the disease has not so widely extended, then usually some of the stomach wall can be preserved. The details of the operation are essentially the same as will be found described under resection of the pyloric end of the stomach or partial gastrectomy (pages 747 and 751).

The stomach is exposed by median incision. The gastrohepatic omentum

is ligated doubly, from the duodenum to the esophagus, at eight or ten points. The gastrocolic omentum is similarly ligated along the greater curvature. The gastrophrenic and gastrosplenic omenta are also divided. The four main arteries supplying the stomach are ligated and divided as the ligation of the omenta progresses. These vessels are the gastric, the pyloric, the gastro-epiploica dextra, and the gastro-epiploica sinistra. Gauze pads are placed behind the stomach. The duodenum is then clamped with two clamps and divided between. The stomach is freed up to the esophagus, where two clamps are placed and the stomach cut away.

If the duodenum can be brought up to the esophagus an end-to-end anastomosis is made. The duodenum may be freed as described for gastro-duodenostomy (page 739, Fig. 1408). If the duodenum cannot be brought up to the esophagus without tension then an anastomosis should be made between the esophagus and a loop of jejunum, and a jejunojejunostomy done lower down (Fig. 1434*a*).

Gastro-enterostomy is one of the most useful operations performed on the stomach. Usually the term is limited to anastomosis of the stomach

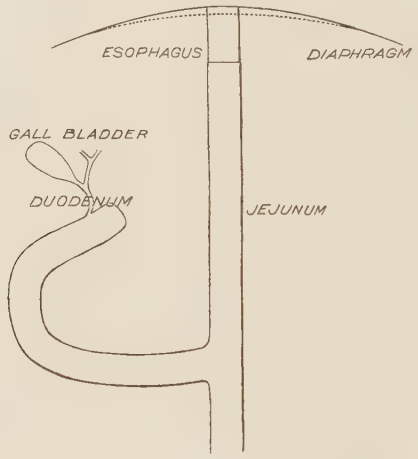

Fig. 1434*a*.—Diagram of Result after Gastrectomy.

The stomach has been removed; the stump of the duodenum is closed; the jejunum is divided; the distal stump is united to the esophagus; the proximal stump is connected with the jejunum at a lower point by end-to-side anastomosis.

and jejunum. When other anastomosis is specified it is given a distinguishing name. The object of the operation is to empty the stomach directly into the small bowel without the passage of its contents through the pylorus. Its chief indications are in (1) obstruction at the pylorus, (2) disease of the duodenum or pylorus requiring rest and freedom from irritation and in (3) diseases of the stomach in which better drainage of that viscus is required than can be secured through the pylorus. The operation of choice is done by the posterior route.

Posterior gastrojejunostomy is best done between the upper part of the jejunum and the posterior wall of the stomach, the junction being affected by making an opening through the transverse mescolon. The incision should begin about 5 cm. (2 inches) below the ensiform cartilage and extend below the level of the umbilicus. The abdomen is opened about 2 cm. (¾ inch) to the right of the median line, by retracting outward the rectus muscle. The

stomach is lifted forward with the transverse colon and the great omentum, and turned upward over the upper end of the abdominal opening. The omentum is pressed upward and the lower surface of the transverse mesocolon exposed (for Anatomy, see pages 503 and 769).

The part of the greater curvature which naturally lies lowest is then grasped by the fingers of the left hand while the right hand presses the transverse colon upward. Pressure upon the posterior wall of the stomach with the left hand causes the stomach to press against the superior surface of the transverse mesocolon and cause the under surface of the mesocolon to bulge about at its middle. A small vertical incision is made in the mesocolon at

FIG. 1435.—GASTRO-ENTEROSTOMY.
The stomach and intestine have been grasped by clamps, approximated, and the first layer of seromuscular sutures applied.

this point between the blood-vessels. As soon as the opening has penetrated both layers of the mesocolon it is enlarged by stretching up to about 7.5 cm. (3 inches) in length. Pressure upon the stomach with the left hand causes its posterior wall to present at the rent. It is grasped and drawn well through the opening.

The stomach is then grasped by a pair of stomach forceps including a fold for anastomosis. The site of the opening should be planned well toward the pyloric end, at the most dependent part of the stomach on its posterior wall. That means that it should pass down nearly to the greater curvature.

The opening should be oblique. Its lowest part should be 5 to 7.5 cm. (2 to 3 inches) to the left of the pylorus.

Mayo's rule is that the opening in the stomach shall begin at a point 2.5 cm. (1 inch) above the greater curvature on a line with the longitudinal portion of the lesser curvature and end at the bottom of the stomach 6.5 cm. (2½ inches) to the left.

The clamps should be applied so that the tips of the blades point toward the outer side of the patient's left hip and the handles toward the right shoulder.

Fig. 1436.—Showing Location of Incision in Jejunum for Gastro-enterostomy.

The next step is the identification of the end of the duodenum and the beginning of the jejunum. This is found by passing the hand along the lower surface of the root of the transverse mesocolon from left to right. The small intestine will be found emerging through the mesentery just at the right of the spinal column. By drawing the transverse colon forward out of the abdomen, and making traction to the right and upward, the beginning of the jejunum is easily brought into view. It should be picked up and the portion which naturally lies nearest the opening in the transverse mesocolon should be selected for anastomosis.

The rule should be to make the anastomosis as near the duodenum as possible without incurring the danger of tension. There should be an easy

relaxation of the loop. It should be borne in mind that an easy anastomosis, made while the stomach is turned up, may cause tension when the viscera drop back into their natural places. The clamp should be applied to the small intestine, grasping a fold of its free border. The fold exposed between the jaws of the forceps should be about 7.5 cm. (3 inches) long. The nearest point of this fold should be 7.5 or 10 cm. (3 or 4 inches) from the beginning of the jejunum. In some cases the distance between the beginning of the jejunum and the jejunal incision need be only 6 cm. (2½ inches). The intestine should be clamped so that the opening is made parallel to its long axis and on the antimesenteric side of the bowel.

The two clamps should then be brought together (or a three-bladed single clamp should be used), placing the fold of stomach beside that of the small intestine, and the rest of the stomach, intestines, and omentum returned to the abdomen (Fig. 1435). A small gauze pad is placed behind the two clamps, and the rest of the peritoneal field is covered with towels. The first half of the seromuscular suture is applied with a curved needle. The suture line should be at least 7.5 cm. (3 inches) long—a continuous suture.

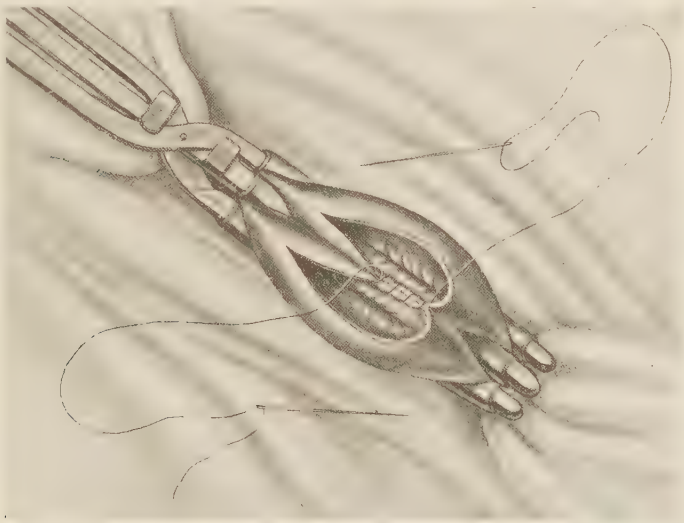

Fig. 1437.—Gastro-enterostomy.
Placing through-and-through suture.

Each end should be tied and left long with a needle on each one. Some surgeons prefer to make this row of interrupted sutures. If a continuous suture is used, the ends should be laid aside when the end is reached to be used later in making the anterior half of the seromuscular stitch. An incision is now made with a sharp knife through the seromuscular coats down to the mucous membrane (Fig. 1436). This incision is made in either viscus, about 7 mm. (¼ inch) from the seromuscular suture. It should be about 6 cm. (2½ inches) long. The mucous membrane which puffs out in this incision is grasped by forceps and a strip cut out so that the mucous edge of the wounds should be even with the seromuscular edges. Careful placing of flat sponges should prevent soiling of the field during the opening of the stomach and bowel.

The next step is the application of a through-and-through suture uniting

the stomach and intestine. This should be started at the middle of the base line and tied (Fig. 1437). For this suture chromicized catgut should be used. Linen, silk or other nonabsorbable suture should not be left in the mucous membrane, as it is dangerously apt to invite ulceration at the suture line (see Gastrojejunal Ulcers, page 580).

The suture is continued around the angle of the openings. When the angle has been passed, the needle on the other end of the suture is taken in hand and the suture completed. By this method the knot is tied at the nearer side of the anastomosis, which is better than tying at the angle where leakage is most apt to occur. For this suture a straight needle and No. 0 chromicized catgut is to be preferred. The suture should be fixed

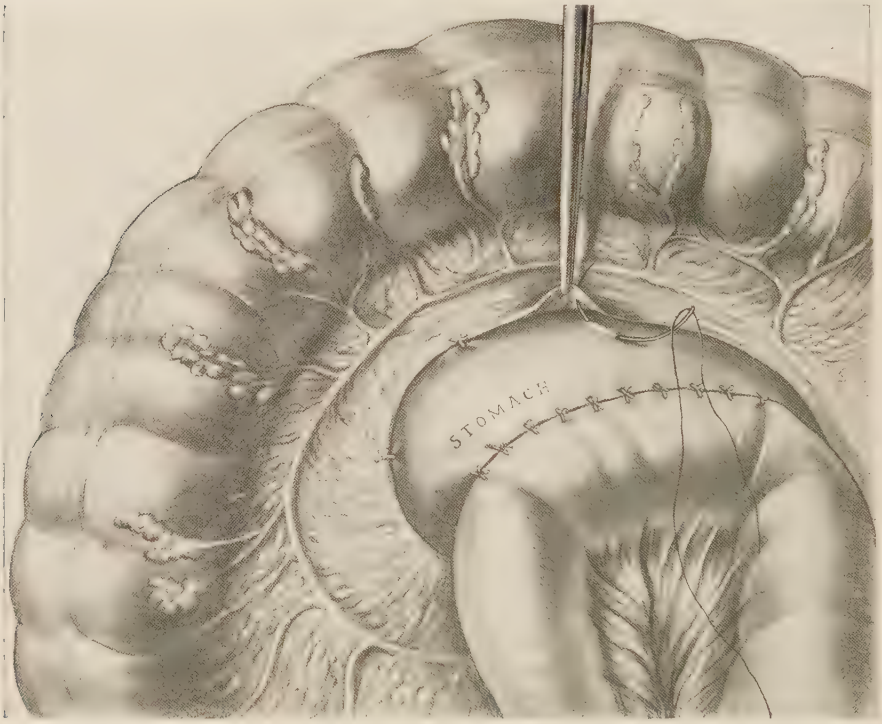

Fig. 1438.—Gastro-enterostomy.
The operation has been completed, and sutures holding the stomach to the mesocolon are being applied.

occasionally (every third or fourth stitch) by taking a loop about the thread in order to prevent puckering.

After completing the through-and-through suture, the wound region should be sponged off gently, the soiled protectors removed, clean towels put in place, and the surgeon's hands washed. The second half of the seromuscular suture is then completed. A curved needle is best for sewing about the two corners of the wound. Each end is used to sew about its respective corner. The two approach on the front and are tied and cut.

The clamps are then unlocked and the wound inspected for bleeding. If the result is satisfactory, the clamps are removed. An extra suture is placed at each end of the anastomosis line to take the tension from the

suture. The stomach about 13 mm. (½ inch) from the suture line, is fastened to the rent in the transverse mesocolon by three or four interrupted sutures, with the object of closing the opening to prevent intestine entering it and producing internal hernia (Fig. 1438). To prevent hernia behind the upper loop, it is well to suture the afferent loop of jejunum to the lower sur-

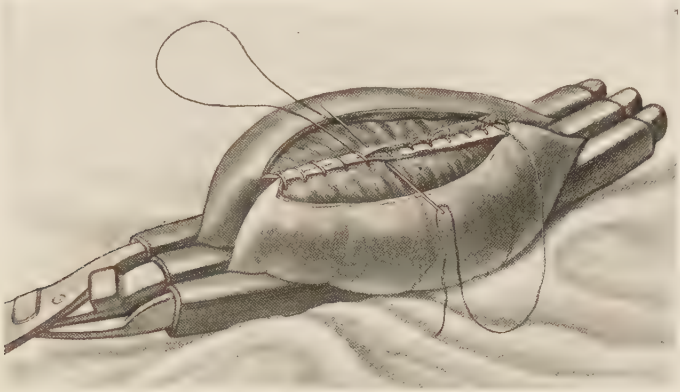

Fig. 1439.—Gastro-enterostomy with Three Posterior Rows of Sutures. The first row has been applied, the seromuscularis has been incised, and the second row is in process of application. (*Method of Mayo.*)

face of the transverse mesocolon with about four interrupted sutures as suggested by Moschcowitz and Wilensky (Surg., Gyn. & Obst., September, 1915).

W. J. Mayo modified the operation by placing first an interrupted suture in the seromuscularis; then the incisions were made down to but not through

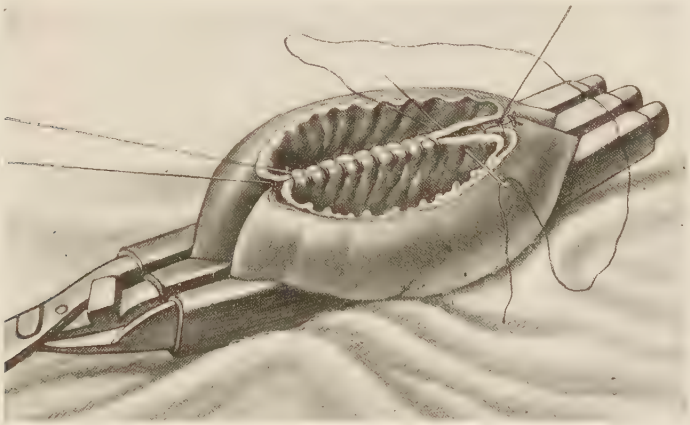

Fig 1440.—Gastro-enterostomy with Three Posterior Rows of Sutures. The third row of sutures, involving only the mucosa, is being placed.

the mucous membrane; an interlocking continuous suture of chromic catgut was then applied through the seromuscularis and covering the first row of sutures (Fig. 1439); the mucous membrane was then incised; and a continuous row of plain catgut sutures was applied to the mucous membrane (Fig. 1440). By this method three rows of sutures are applied to the posterior union.

F. T. Stewart (Annals of Surg., September, 1917) operated without clamps. The incision was made through the seromuscularis, and the vessels of the stomach and intestine each caught by a pair of clamps. The opposite intestinal vessel and the opposite stomach vessel were ligated together by a single ligature around both clamps. This is done on both the posterior and the anterior lines of union. These ligatures constitute a part of the union mechanism.

Most surgeons enter the abdomen through the sheath of the rectus muscle just to the right of the middle line. The round ligament of the liver should not be injured. When adhesions are present between the stomach and the mesocolon entrance into the lesser peritoneal cavity may be difficult or impossible. Blunt dissection may accomplish exposure of the posterior wall of the stomach sufficient for the anastomosis; or it may have to be abandoned and anterior gastro-enterostomy done instead.

FIG. 1441.—GASTRO-ENTEROSTOMY.
Showing position of bowel and stomach after operation.

Occasionally it is necessary to tie a small vessel in the mesenteric rent. After picking up the beginning of the jejunum, it is well to make some traction upon it to draw it out of the duodenojejunal fossa.

Adhesions at the beginning of the jejunum may require to be divided to give freedom of the bowel.

Some surgeons introduce an extra layer of sutures between the two just described. Half of this is done after incising the seromuscular coats and before the mucosa is incised. Some surgeons do not cut away redundant mucous membrane, but, after incising the viscera, proceed at once with the through-and-through suture. It is the practice of some operators to loosen the clamps as soon as the through-and-through suture is completed in order to discover hemorrhage. If bleeding occurs it should be stopped by interrupted sutures.

The extra suture, applied at either end of the anastomosis to prevent kinking and relieve the suture line of tension is important. It is neither necessary nor wise to make a loop or half turn in the bowel at the anastomosis. It should lie in its natural position (Fig. 1441). The jejunum passes from right to left, and in this position it should be connected to the stomach (Fig. 1442).

For the inner suture catgut is preferable because nonabsorbable suture may hang into the lumen of the bowel for a long time. The through-and-through mattress suture (Connell) is used by some. For the seromuscular suture celluloid linen (Pagenstecher), paraffined linen, or silk is to be preferred, although many surgeons use chromicized catgut.

Posterior anastomosis with the Murphy button may be done by the same technic as described for entero-anastomosis. It has been quite superseded by the suture method.

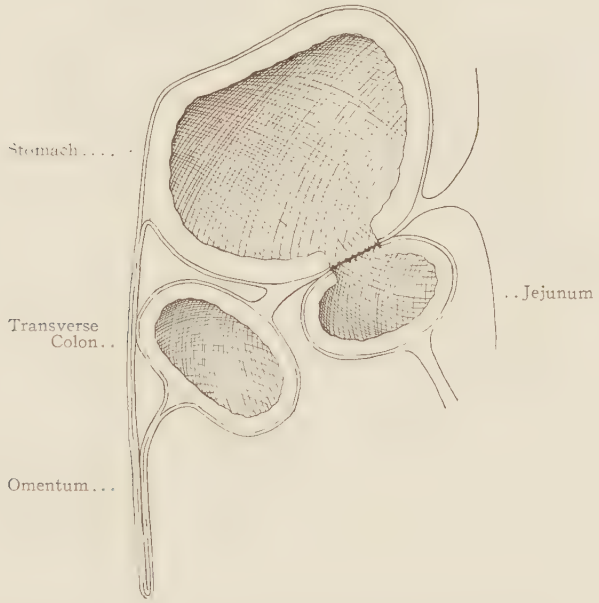

FIG. 1442.—POSTERIOR GASTRO-ENTEROSTOMY.
Vertical median section of abdomen showing stomach and intestines. Diagram.

W. J. Mayo called attention to the band which connects the jejunum to mesocolon, and sometimes turns it to the right. This band when prominent requires to be divided (Fig. 1443).

Anterior gastrojejunostomy is done when the posterior operation cannot be performed because of the presence of adhesions or abnormally short mesocolon. It is also to be preferred in obstructive cancer of the pylorus which cannot be removed. The operation is done speedily and safely; but for permanent drainage of the stomach it does not serve so well as the posterior operation. The abdomen is opened through the sheath of the right rectus muscle, and the stomach and transverse colon turned up as for posterior gastro-enterostomy. The beginning of the jejunum is identified and brought forward in front of the great omentum and colon. The bowel is followed down to a point which can be brought up to the stomach without tension. This is usually from 30 to 45 cm. (12 to 18 inches) from its begin-

ning. Tension is fatal to the success of the operation. The point selected is held by an assistant and the stomach, great omentum and colon are returned to the abdomen. The omentum falls mostly to the left side and the colon behind the loop. As the loop is lifted up to the stomach the anastomosed intestine should have its natural physiologic direction to continue the peristaltic wave from the stomach to the loop of bowel.

The opening into the stomach should be parallel with the greater curvature and as near the latter as possible. It should be about midway between the middle of the stomach and the pylorus. The intestine should be opened opposite the mesenteric attachment. Having determined these points



Fig. 1443.—Division of Mesocolic Band to Facilitate Gastro-enterostomy.

clamps are applied, the openings cut and the same method of suturing used, as for posterior gastro-enterostomy; or the operation may be done without clamps. The openings should be 5 to 6.5 cm. (2 to 2½ inches) long. The bowel should be anchored to the stomach by extra sutures. These sutures should be so applied as to make the attachment about twice the length required for the anastomosis. The object of this is to prevent rotation of the bwel (Fig. 1444).

The success of the operation is better assured if a jejunojejunostomy is done to unite the arms of the loop in such a way that the duodenal secretions shall be able to flow on in the intestine without having to mount up to the summit of the loop at the stomach (Fig. 1445).

In this operation unless the proximal loop is made long enough there is danger of tension which may cause (1) the union to fail, (2) the jejunum to become obstructed by pressure of the colon or (3) the colon to become obstructed by the jejunum. These are the chief reasons for the so-called "vicious circle" which was once common after this operation. To obviate this the proximal arm must be left relaxed, and with a relaxed proximal arm the duodenal contents have a long uphill journey before they can pass the stomach. For this reason lateral entero-anastomosis is indicated. This may be done very quickly with the Murphy button.

Fig. 1444.—Anterior Gastrojejunostomy.

The operation of Roux, called the Y-operation, consists in division of the bowel, the anastomosis of the distal stump with the stomach, and the anastomosis of the proximal stump with the distal stump at a convenient distance below the gastro-enterostomy. The operation is rarely indicated (Fig. 1446).

Exclusion of the pylorus was once practised much as a routine measure after gastrojejunostomy. This was done because it was observed that in many cases a "vicious circle" developed, the duodenal contents passing back through the anastomosis into the stomach and the stomach contents passing out through the pylorus. This accident is not apt to occur if the opening is made large enough, if the jejunum is free from kinks or other obstruction, if there is accurate union of the margins of mucous membrane,

if the opening is close to the lower border of the stomach, if the distal loop of the jejunum is placed toward the right side of the median line before closing the abdomen, if the operation is done without a loop or half turn in the bowel, and if the proximal arm is not so short that it is compressed or so long that it sags.

To prevent the vicious circle which follows these errors of technic, exclusion of the pylorus has been practised. It is also done in cases of duodenal ulcer, treated by gastrojejunostomy, in which it is desired to keep the duodenum free from gastric contents. It may be done by simply throwing a band of fascia about the pylorus and sewing it down tightly (Fig. 1447). Pyloric exclusion by means of infolding sutures (Fig. 1448) serves for a short time, but if catgut is used, the permeability of the duodenum is soon restored.

Fig. 1445.—Anterior Gastrojejunostomy.
Showing diagram of stomach and small intestine.

Simple ligature (Fig. 1449) of catgut soon melts away. To meet this objection silk and silver wire have been used. These are foreign bodies and highly objectionable. The sure method is division of the pylorus and suture (Fig. 1450). This is naturally most effective and permanent. Dissection free of the pyloric mucous membrane through a longitudinal incision, and separate ligation and division of the mucous membrane is permanent in its effect (Fig. 1451). A simple and satisfactory method consists in isolation of the mucous membrane of the pylorus and constricting it with a band of fascia taken from the rectus abdominis fascia or from the thigh (Fig. 1452).

Ordinary posterior gastro-enterostomy is not dangerous because if obstruction occurs at the intestinal kink, the loop of bowel between the pylorus and the anastomosis has vent into the stomach and the stomach can be washed

out. But if resection or occlusion of the pylorus is done, "duodenal death" takes place when obstruction occurs. Safer than occlusion of the pylorus is anastomosis of the amputated stomach with the duodenum.

Reconstruction of Wall of Gastro-intestinal Tract by Transplantation of Tissue.—After the loss of substance in the wall of the stomach or intestine following the excision of an ulcer tumor or injured area, it has been customary to close the wound. If such closure would cause too great a contraction, it has been customary to perform resection or anastomosis to obviate the difficulty. A. A. Strauss (Jour. Am. Med. Assoc., May 12, 1917) showed that

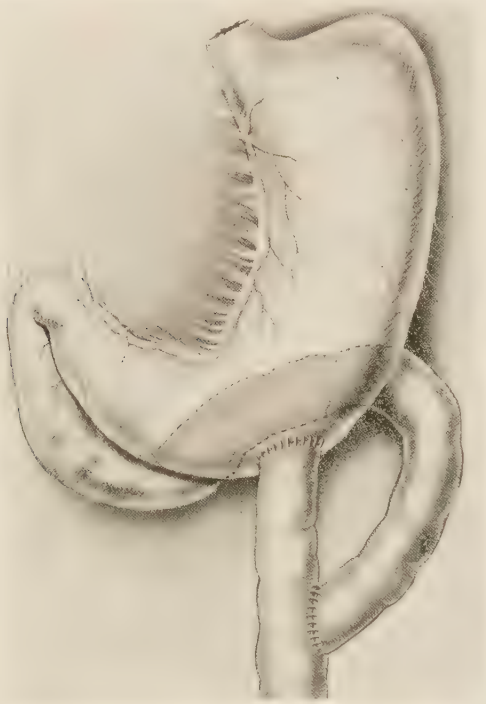

Fig. 1446.—Gastro-enterostomy by the Y-operation.

The bowel is divided, the distal stump is anastomosed with the stomach, and the proximal stump with the distal bowel at a convenient distance below the gastro-enterostomy. This is the ideal gastro-enterostomy, but not always the operation of choice.

it is possible in the duodenum, after resection of ulcer, to restore the wall of the bowel by means of a transplant of fascia. An incision is made through the right rectus muscle about 13 mm. (½ inch) to the right of the median line, extending from the ribs to the level of the umbilicus. The ulcer-bearing area is circumscribed by an elliptic incision through all the coats of the bowel excepting the mucosa. The grafts are then cut from the abdominal wall. A clamp is placed on the duodenum and the mucosa is separated from the muscularis for some distance around the wound. The ulcer is then excised.

The grafts are applied as follows: A transplant, composed of peritoneum, transversalis fascia and some adherent rectus muscle is cut from the inner edge of the wound. This transplant should have about the shape

of the wound to be filled. It should be sewed (Fig. 1453) with fine chromic catgut to the mucous membrane with the peritoneal surface inside of the bowel. The anterior sheath of the rectus muscle, is then exposed and an oval piece with some of the underlying muscle fibers is cut out. This second

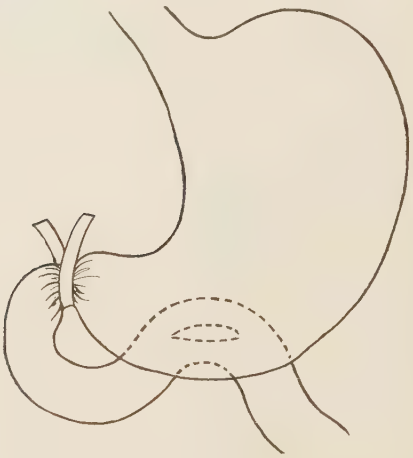

Fig. 1447.—Pyloric Exclusion after Gastro-enterostomy by Means of a Band of Fascia.

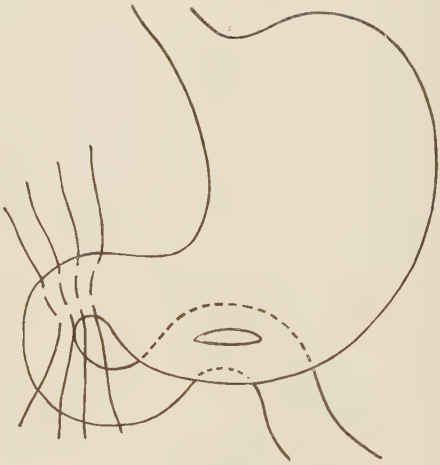

Fig. 1448.—Pyloric Exclusion by Means of Infolding Sutures.

transplant is placed on the first and sewed (Fig. 1454) with interrupted silk sutures in such a manner that its edges lie between the mucosa and the muscularis (Fig. 1455). The free edge of the omentum is then sewed over the whole wound surface.

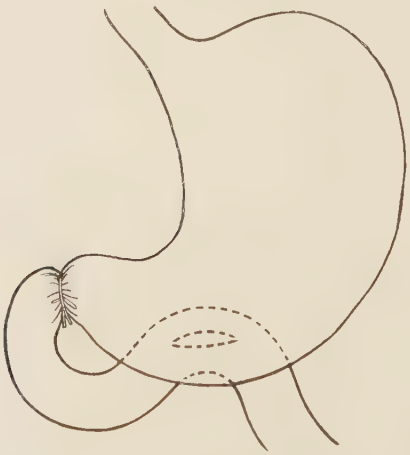

Fig. 1449.—Pyloric Exclusion by Means of Simple Ligation.

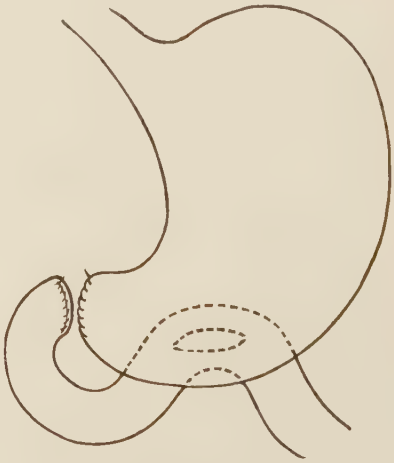

Fig. 1450.—Pyloric Exclusion by Division and Suture.

The operation may be simplified by dissecting up the mucosa in such a manner that only one transplant is needed. The same elliptic incision is made through the seromuscularis. A straight incision is carried from its

upper end back into the stomach for a distance of 5 cm. (2 inches), and the mucosa separated from the muscularis. The ulcer is then cut away. A transverse incision is made through the stomach mucosa and closed longi-

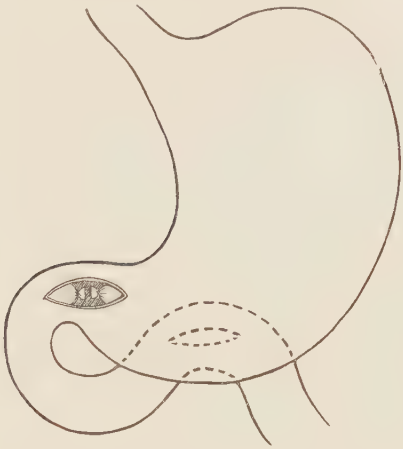

FIG. 1451.—PYLORIC EXCLUSION BY MEANS OF DOUBLE LIGATION AND DIVISION OF THE MUCOUS MEMBRANE.

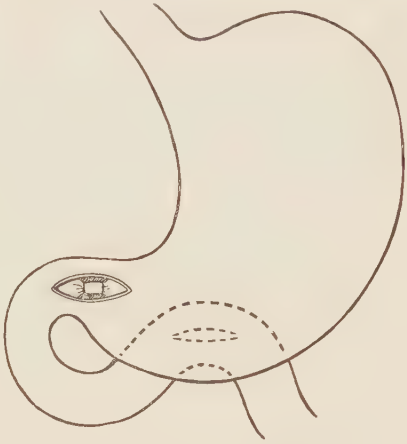

FIG. 1452.—PYLORIC EXCLUSION BY CONSTRICTION OF MUCOUS MEMBRANE WITH BAND OF FASCIA.

tudinally. This so frees the mucosa which can be closed transversely by suture (Fig. 1456). The transplant of fascia is then set in and sewed to the seromuscularis (Fig. 1457), and omentum sewed over all.

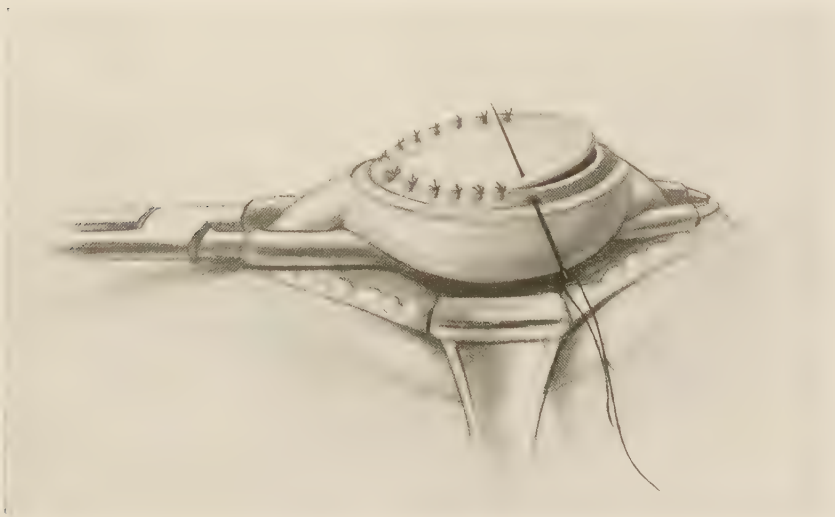

FIG. 1453.—RECONSTRUCTION OF PYLORUS AFTER EXCISION OF ULCER. Sewing first graft of fascia to mucous membrane. (*Method of Strauss.*)

It is possible that in the treatment of *ulcer of the duodenum* this method may come to supplant gastro-enterostomy. Strauss claims that it takes less skill, causes less shock, and can be done quicker.

The treatment of shock in cases of gastroplasty, pylorectomy, gastrectomy, and gastro-enterostomy is important. The preliminary treatment of these cases has been described (pages 499, 564). If the patient has not been able to take sufficient fluids, the body fluids should be increased by the proctoclysis for two days previous to operation. The washing of the stom-

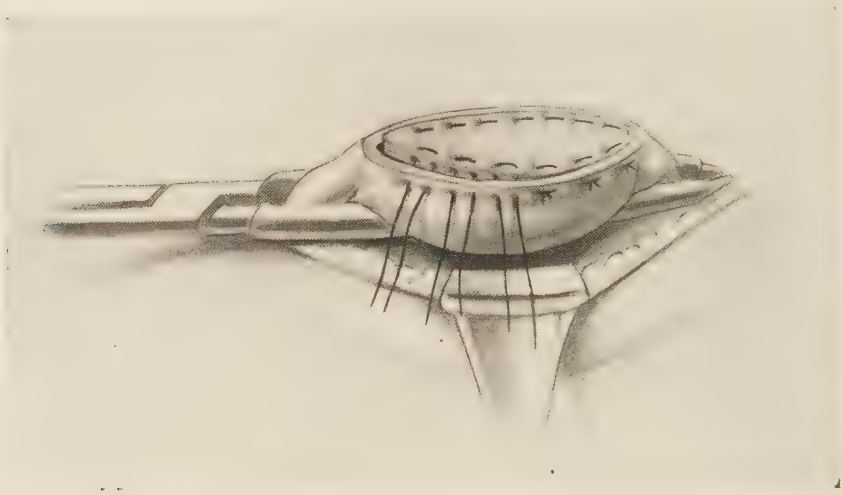

Fig. 1454.—Reconstruction of Pylorus.
Sewing second transplant to seromuscularis. (*Method of Strauss.*)

ach is best done on the day before operation. An injection of morphin should precede the anesthetic. Anesthesia is necessary only for the opening and closing of the abdominal wall; the morphin narcosis suffices for the most of the operation.

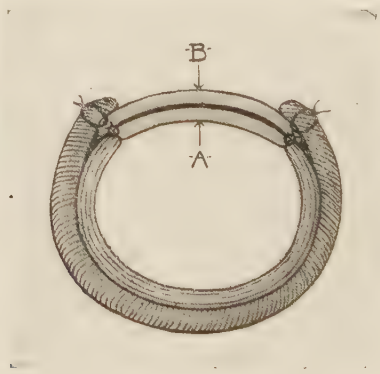

Fig. 1455.—Reconstruction of Pylorus.
Diagram showing wound closed by transplants of fascia after excision of ulcer. *A*, First graft of fascia; *B*, second graft of fascia.

By ligating the vessels supplying the parts to be excised, as a preliminary step, blood is saved. The shock of operation should be slight if these precautions are taken and the rest of the peritoneum protected from insult.

After operation the head and shoulders should be raised by four or five pillows. Rectal alimentation should be instituted. Hot water is given by mouth after twelve hours in teaspoonful doses. As the patient tolerates

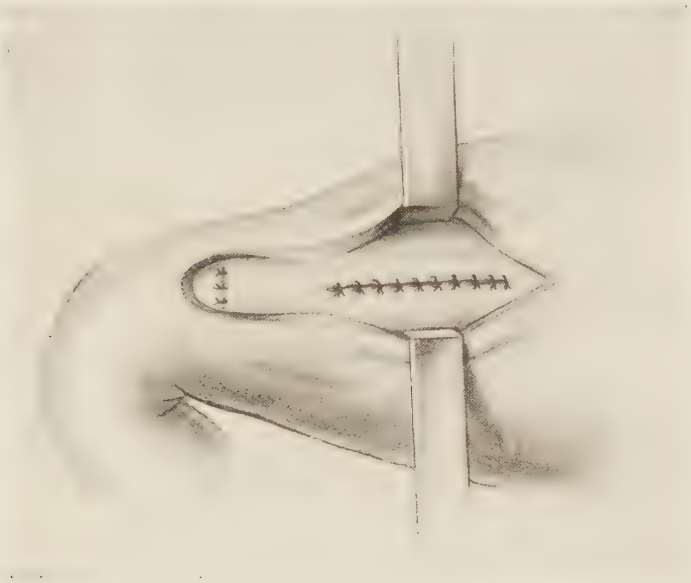

Fig. 1456.—Reconstruction of Pylorus after Excision of Ulcer. Mucous membrane closed. Transverse wound sewed longitudinally. (*Method of Strauss.*)

Fig. 1457.—Placing Transplant of Fascia and Muscle in Reconstruction of Pylorus.

this, the dose is increased to 30 c.c. (1 ounce) every hour. At the end of thirty-six hours careful experiments with liquid food are begun. (See Post-operative Treatment of Abdominal Cases, page 529.)

Feeding after Gastro-enterostomy, Pyloroplasty and Intestinal Operations.—The patient should be placed in a semisitting position, upon being put to bed after the operation. That means with the trunk nearly vertical. This position should be continued for several days. Twelve hours after the operation the patient may take by mouth, water in 4-c.c. (1-dram) doses. During the first forty-eight hours after operation the patient should take no food by mouth except water. Immediately after the operation continuous fluids should be given by the drip method by rectum (proctoclysis). This should be continued about a week. Plain water, salt solution, or glucose solution, may be used.

After twenty-four hours the water by mouth may be increased gradually up to 30 c.c. (1 ounce) every two hours. On the second day if fluids are tolerated 30-c.c. doses of water may alternate with 4-c.c. (1-dram) doses of egg-albumin. Then any nourishing liquid may be substituted for the egg-albumin or water. This means broth, weak tea or whey. The quantity of water and egg-albumin may be increased gradually until by the eighth day any liquid, in 60-c.c. (2-ounce) doses, may be taken every two hours. This means water, tea, peptonized milk, malted milk, strained soup, strained orange juice, peach juice, diluted grape juice, albumin water, whey or strained buttermilk.

On the ninth day the amount of liquid may be increased to 90 c.c. (3 ounces) every two hours. On the tenth day any liquid in 120-c.c. (4-ounce) doses. On the eleventh day a soft-boiled egg may be given in addition to the liquids. On the twelfth day two soft-boiled eggs may be allowed. On the thirteenth and fourteenth days soft food may be given. They may be such as soup, soft cereals with cream and invert sugar, custard, and mashed potato. On the fifteenth and sixteenth days soft restricted diet is allowed. On the seventeenth and eighteenth days any easily digestible food may be taken.

After this the diet should be restricted for three months to carefully selected easily digested foods, which should be taken in moderation. The patient should avoid hot foods, very cold foods, fried foods, fat soups, pork, liver, kidney, lobster, crabs, sardines, smoked and preserved meats, cabbage, cauliflower, radishes, cucumbers, corn, berries, pastries and cakes, fresh bread, preserves, strong tea and coffee and alcohol.

Bloody oozing from the wound in the intestine or stomach may take place in some cases. The temporary paresis which is always present to a greater or lesser degree causes retention of this blood in the stomach after gastro-enterostomy. This should be watched for. If the patient does not vomit it, the stomach should be washed out with small amounts of warm sterilized water.

The same rules for feeding which apply to gastro-enterostomy, apply also to intestinal resections, anastomoses and suturing.

THE PANCREAS

Anatomy.—The pancreas lies transversely across the posterior abdominal wall behind the peritoneum on a level with the first and second lumbar vertebræ. Its right end or head is embraced by the curving duodenum, and its tapering tail reaches to the hilum of the spleen. The common bile duct is usually embraced by the tissue of the head as it passes downward. The splenic artery runs along its upper border. The splenic vein lies behind it. The main duct of the pancreas (duct of Wirsüng) runs in its substance toward the head, and empties into the second part of the duodenum in close connection with the common bile duct. Commonly the two ducts join to form an ampulla (ampulla of Vater) which empties by a single opening at the apex of a papilla. These two ducts may empty into the duodenum through separate openings. A second duct (ducts of Santorini) often empties into one of the above ducts or has a separate mouth in the duodenum (Fig. 1458).

Wounds of the Pancreas.—An infected wound should be provided with drainage, and spreading pancreatitis should be watched for and guarded against. Traumatism to the abdomen, resulting in the rupture of other viscera, should prompt inspection for rupture of the pancreas. Immediate suture of a rupture should be done. Incised wounds and bullet wounds should either be sutured or drained or both. In suturing wounds of the pancreas the duct should not be occluded. In injuries in the region of the neck, the superior mesenteric vessels should be protected. When the gland is crushed or pulpified, hemorrhage should be arrested either by suture or packing, and drainage provided. Suturing must be done carefully with fairly heavy catgut as the tissue is friable and easily tears. The natural approach to the pancreas is through the mid-abdomen, and drainage of the pancreas is best provided through the route of approach in most cases; but as such drainage usually is between the coils of intestine, the feasibility of posterior drainage through the flank should always be considered.

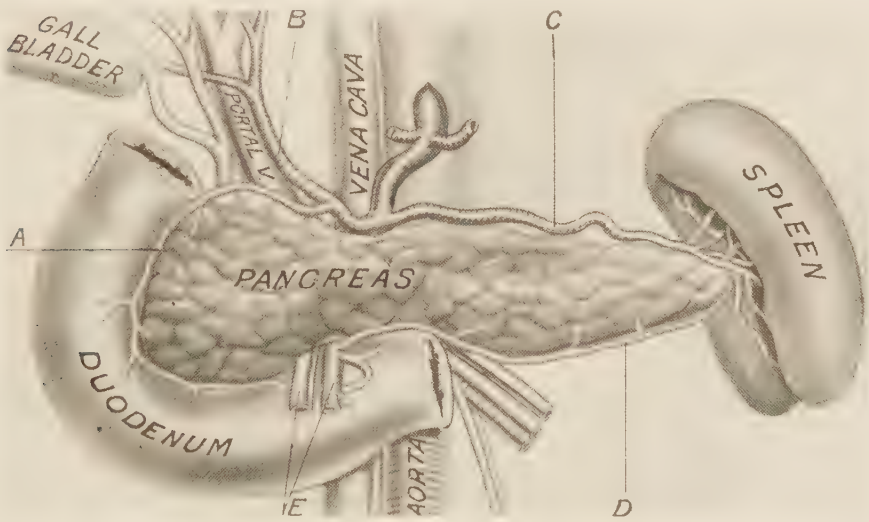

Fig. 1458.—Anatomic Relations of the Pancreas.
A, Superior pancreatic and duodenal artery; *B*, hepatic artery; *C*, splenic artery; *D*, inferior pancreaticoduodenal artery; *E*, inferior mesenteric vessels.

Approach to the pancreas is through the mid-abdomen. A sand-bag should be placed under the back. The abdomen should be opened by a free incision to the right of the median line above the umbilicus. The pancreas may be approached by one of four routes. (1) The *gastrohepatic route* is through the gastrohepatic omentum above the stomach. It is useful in thin people with prolapse of the stomach. (2) The *gastrocolic route* is opened by incising the gastrocolic omentum just below the stomach. This gives free access. A number of ligatures are required. (3) The *trans-mesocolic route* is through the mesentery of the transverse colon the same as for posterior gastro-enterostomy. It provides a circumscribed opening. (4) The *retro-omental route* is made by lifting up the apron of the great omentum; incising the serosa of the transverse colon at its line of juncture with the great omentum; and with the finger, covered with a piece of gauze, separating the omentum from the bowel throughout the length of the incision (Fig. 1458*a*).

The *retro-omental route* gives the best access. The incision may be 13 cm. (5 inches) long or longer. If care is taken there need be no bleeding. This route not only gives free access to the pancreas, but is the best means of *approach to the posterior wall of the stomach.* It also provides *exposure of the duodenum*, especially in its relation to the head of the pancreas.

Drainage of the pancreas, whether after traumatism, operations for tumor or incision for infections, is important. When the organ is wounded or incised, pancreatic juice escapes. This juice has the power (1) to digest plastic exudate and (2) to irritate the peritoneum. It also causes fat necrosis. Its presence in the tissues or peritoneum greatly increases the dangers of infection. Bacteria which would otherwise be destroyed, grow in the presence of this fluid. Drainage may fail to localize infection because the enzymes of the pancreas break down the plastic barriers.

A good-sized drainage tube surrounded by gauze is the most effective drainage.

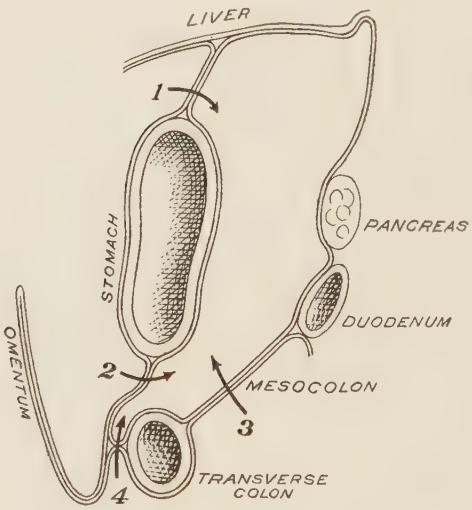

FIG. 1458*a*.—APPROACHES TO PANCREAS AND POSTERIOR WALL OF STOMACH.

1, Gastrohepatic route; 2, gastrocolic route; 3, transmesocolic route; 4, retro-omental route.

Acute Pancreatitis.—Acute infection may be expected to terminate fatally in the severe cases unless relieved by surgical means. The less acute cases may result in abscess or localized necrosis of the gland, which may find spontaneous drainage.

In certain mild cases recovery may be secured without operation. If all local irritation is removed, by washing out the stomach, by permitting no food by mouth, and by keeping the patient quiet the disease may be expected to subside. The patient should be carefully studied and watched.

Usually acute infection demands quick recognition and treatment. The omentum will commonly present the small round, pale yellow or white patches characteristic of fat necrosis. This confirms the diagnosis. The pancreas in these cases is intensely congested, the congestion extending outside of the capsule. The gland should be exposed as above described, and the intestines walled off. The gland will appear swollen and purplish in color. Hemorrhagic areas may be present. The important indication is to relieve the tension by incisions into the gland substance. After such treatment abundant provision for drainage should be made, as above described. Recovery will depend upon the promptness with which drainage is secured. Often the capsule will be found so diseased that nothing further than drainage down to the gland is indicated.

Operation should be done with the least possible traumatism. If jaundice is present, simple drainage of the gall-bladder should be secured.

Cholecystitis and gall-stones will be discovered in connection with some of these cases. If the condition of the patient will permit, the gall-bladder should be incised and drained. In some cases the pancreatitis follows the

occlusion of the ampulla of Vater by a stone, which causes bile to flow back into the pancreas through the duct of Wirsung and set up pancreatitis. Examination should be made for stone in the common bile duct. It is rarely wise to complicate the operation by removal of stone from the ducts in acute pancreatitis. The condition of the patient will rarely justify its removal at the first operation.

The surgeon should always be prepared for these cases. The diagnosis is difficult. But all acute surgical conditions of the upper abdomen should receive immediate operative treatment. In acute pancreatitis life may be saved by so doing.

Subacute Pancreatitis.—The less acute forms of infection may give rise to less violent symptoms, but abscess or gangrene may result and require operative relief. The bulging pancreas is exposed by dissecting bluntly through the gastrohepatic or gastrocolic omentum. Before opening an *abscess of the pancreas*, the peritoneum should be well walled off with gauze. Pus should be sponged out, and sloughs, which are commonly present, should be removed. If the protection of the peritoneum is adequate, these cases should be expected to do well. As the mortality is still high, when possible, an operation in two stages should be considered. Abscesses have been drained through the back at the costovertebral angle, and also by the transpleural route.

Chronic Pancreatitis.—In old chronic sclerosis of the pancreas due to alcoholism, syphilis or some infection such as typhoid, which does not give acute symptoms, surgery has little to offer. In cases in which the common duct is compressed by connective tissue of the inflamed pancreas, it may be dilated with a fine probe or freed by traction and lateral motions. In infections due to duodenal ulcer, the ulcer should be cured by gastroenterostomy or excision. The cases most amenable to surgical treatment are those due to stone. This is usually located in the common duct or its ampulla, and so situated as to prevent the free exit of pancreatic secretion. The catarrhal infection which may be present is transmitted to the pancreatic duct. Relief is secured by removal of the stone. An infection of the ducts without stone may be present, or the only stones may be located in the gall-bladder. In such cases drainage of the gall-bladder by cholecystotomy should be secured and continued until the bile becomes sterile. Drainage of the bile and pancreatic tract by this means has a decided curative effect upon pancreatitis. It is in these chronic infective cases that cholecystenterostomy may be of service in giving permanent free drainage of the gall-bladder, and relieving pressure at the mouth of the pancreatic duct. It is to be conceived that in cases in which the pancreatic duct empties into the common bile duct, and the mouth of the latter is narrowed by the cicatricial contractures following ulcer of the duodenum, the operation of cholecystenterostomy would create a new channel, and pancreatic and hepatic secretions would both reach the bowel by way of the gall-bladder.

Whether to do a cholecystostomy or a cholecystenterostomy may be difficult to decide. In cases in which the patient is very sick, with glycosuria or jaundice, the quicker operation is indicated. That is simple cholecystotomy, leaving a gall-bladder fistula. If the condition of the patient is good and there are no gall-stones or discoverable cholecystitis, permanent drainage into the bowel is the operation of choice. For in many of these cases no recognizable inflammation or infection of the gall-tract may be present; and if there is no other discoverable cause for the pancreatitis there remains nothing to do but drain the gall-bladder.

Gall-bladder drainage undoubtedly has a curative effect, and this is

probably due to the relief of pressure upon the pancreas. It permits freer discharge of pancreatic secretions.

Necrosis of the pancreas requires drainage by gauze or wick packing so that the peculiar secretions shall find external vent.

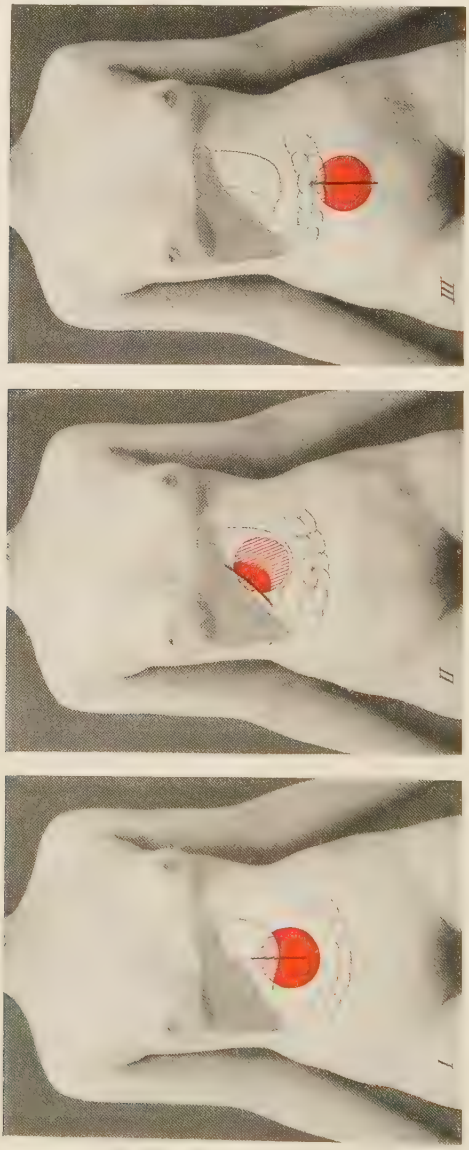

Fig. 1459.—Diagram of Cysts of the Pancreas.

Showing routes by which cyst may be attacked. I, Median approach between colon and stomach; II, Subcostal approach between liver and stomach; III, Median approach below transverse colon.

Tumors of the Pancreas.—Adenoma, carcinoma and sarcoma are all amenable to treatment by operation, and each has been successfully removed. How much of the gland is necessary for health is not known; but a number of cases of complete pancreatectomy with recovery have been reported. If possible some pancreatic tissue should be left, because, while it is possible

to supply the external secretion of the pancreas, supplying the internal secretion is difficult.

Cysts of the pancreas are more common and much more hopefully treated. The cyst is approached at one or the other sides of the median line, preferably making the approach directly in front of the tumor. Whether the cyst is to be attacked between the stomach and transverse colon, above the stomach, or below the transverse colon (Fig. 1459) must depend upon its place of greatest prominence. It will be found to present at one of these places.

The lowest mortality has followed operation, which is done in two stages. By this method, the cyst, bulging under the peritoneum, is made accessible by holding back the viscera by means of abundant gauze packing surrounded by rubber protective. After two days or more, when adhesions have developed, the innermost part of the gauze is removed and the cyst evacuated by aspiration. After the fluid has been removed, the cyst is freely opened, packed and drained. In some cases, as the first step of the operation, the cyst wall may be sutured to the edge of peritoneum of the abdominal wound.

In rare cases the cyst will be found so small, superficial, or isolated that its extirpation can be accomplished. If the cyst seems to be a part of malignant disease then an effort should be made to remove the whole growth. The interior should be explored. If it presents cauliflower excrescences, its malignancy may be assumed. A retention cyst is apt to contain crystalline deposits or stone.

The sinus following evacuation and drainage may be very slow in healing. It may close superficially and a reaccumulation of fluid take place (see Treatment of Sinuses, Vol. I, page 305).

Pancreatic Calculi.—Whether in the duodenal ampulla or in the pancreatic duct in the substance of the gland, stones of the pancreas are amenable to treatment. Operation after a correct diagnosis is most happy; but in a large proportion of cases pancreatic calculus has not been the condition operated for. In operations for gall-stones, when no disease of the gall-bladder excepting distention is found, examination should be made to determine whether a pancreatic stone has not caused the symptoms.

The best approach to the body of the pancreas is by a median abdominal incision, and thence through the gastrohepatic omentum. The stomach is pulled downward and to the left. By placing a sand-bag behind the patient's back the pancreas is pressed forward and easily brought into view. If a stone can be palpated the peritoneum overlying the gland should be incised at that point. After removal of the stone the wound should be closed. Drainage should always be provided.

In operating upon the pancreas the rest of the peritoneum should be walled off by gauze pads in order to prevent soiling with pancreatic fluid.

A stone located in the duodenal ampulla of the pancreatic duct may be reached by incising the duodenum as for duodenocholedochotomy. The interior of the duodenum being exposed, the stone is felt under the ampulla at the cholopancreatic opening, cut down upon, and removed. The wound in the front of the duodenum is closed in the usual manner.

If a chronic pancreatitis is found and no stone discovered as a causative factor, drainage of the gall-bladder can be applied. After symptoms of stone colic, when it is found that the gall-bladder is well filled but free from thickening and adhesions, and the cystic, hepatic and common ducts are free from stone; when the head of the pancreas is enlarged and hard and evidently the seat of chronic inflammation, it is most probable that stone will be found in the pancreatic duct near the duodenum.

THE SPLEEN

Anatomy.—The spleen lies in the left hypochondrium behind the ribs. It is almost entirely covered by peritoneum. It lies in close relation to the fundus of the stomach. Its long axis measures about 13 cm. (5½ inches). The hilum is directed inward and forward and is the place of entrance of the blood-vessels. Reflections of peritoneum, called ligaments, connect the spleen to the left kidney, to the stomach, and to the splenic flexure of the colon. The spleen is on a level included between two horizontal lines passing through the spinous processes of the ninth dorsal and first lumbar vertebræ. Its average weight is 150 Gm. (5 ounces). It receives its blood supply through the splenic artery from the celiac axis. The artery may be tied at the celiac axis or where it is joined bythe gastroepiploica sinistra.

Physiology.—The *effects of removal of the spleen* seem not to be serious. The organ seems not to be essential for life or health. After its removal there are an increase in the number of leukocytes, a decrease in the number of red blood-corpuscles, and a diminution in the amount of hemoglobin. These changes reach their maximum in about a month, after which the condition of the blood gradually returns to normal. Other changes such as lymphocytosis, slight eosinophilia, increase of mast cells, general enlargement of the lymphatic glands, or pain in the long bones may appear. Many other exceptional symptoms have been seen. There seem to be no ill, remote, after-results. Persons without the spleen go on in the enjoyment of health.

Injuries of the Spleen.—*Prolapse of the spleen* through a wound in the abdominal wall requires the treatment of two conditions: the prolapse and the injury to the spleen. If the organ is not wounded or its blood supply damaged, it should be returned to the abdomen and the wound closed. An unduly elongated pedicle should receive the treatment described for wandering spleen. If there is serious injury of the spleen itself, it should be treated as for wounds of the spleen.

Wounds of the spleen are so commonly associated with injury of the diaphragm, pleura, stomach, liver or other viscera that treatment must usually embrace also the consideration of other structures. *Gunshot* and *stab wounds* are almost invariably fatal from hemorrhage unless prompt operation is done. *Lacerated wounds* and *rupture of the spleen* are even more rapidly fatal unless immediate operation controls the bleeding. As a preliminary step the pedicle of the spleen should be compressed by soft clamps to close temporarily the splenic arteries. This is the first thing to be done as soon as the spleen is exposed. In simple wounds the application of mattress sutures is to be recommended. Good-sized catgut should be used and tied with sufficient force to control bleeding but not so tightly as to cut into the tissue.

The sutures should be inserted deeply so as to control the whole length of the wound. The operation is not complete unless an inspection of the whole surface of the organ is made to search for other wounds. If the deep parts of a wound or a wound of exit are not compressed by sutures, hemorrhage may continue. Gauze packing, the cautery, and forcipressure crushing are not so dependable as suture.

Splenectomy is indicated when the wounds are multiple or when extensive crushing or laceration does not lend itself easily to treatment by suture. This is the surest way of controlling bleeding; the operation is usually not difficult; the chief objection to it is that there is apt to be a temporary unbalancing of the system which does not give the patient as good a chance for recovery as when the organ is left.

Abscess of the Spleen.—As soon as a diagnosis is made the abscess should be evacuated. Adhesions to the abdominal wall will often determine the best approach. Usually it will be below the free border of the ribs, but in some cases the presence of cellulitis and occlusive pleuritis will indicate resection of ribs and the transpleural route. Often a wide opening must be left for the removal of sloughs.

Tuberculosis of the Spleen.—When the disease is a part of a general tuberculous infection the treatment should be hygienic. When the disease is localized and confined to the spleen splenectomy should be done. In cases of tuberculous enlargement of the spleen, with distressing local symptoms, even though other tuberculous foci may be present, splenectomy is indicated. The results of this operation have been satisfactory.

Tumors of the Spleen.—Cysts have been treated by simple drainage, injection with antiseptic irritants, marsupialization, extirpation of the cyst and splenectomy. The latter operation has given the best results. Powers collected reports of ten splenectomies for cystoma all followed by recovery. Small cysts may be excised without splenectomy. *Hydatid cysts*, if large, should be treated by splenectomy; if not involving all of the spleen, evacuation and drainage should suffice.

In considering splenectomy in any case the mobility of the organ should be considered. If its removal would be difficult because of the shortness of the pedicle or the presence of adhesions then incision and free drainage, together with the application of an irritating chemical or gauze packing to the interior of the cyst, should be considered. Primary solid tumors of the spleen are so extremely rare that but few data concerning their treatment are at hand. The same treatment is indicated as is applied to tumors in other regions. Secondary neoplastic deposits are scarcely amenable to surgical treatment.

Hypertrophy of the Spleen.—In *simple hypertrophy*, the origin of which is unknown, splenectomy is indicated only when the disease causes distress because of the weight or pressure of the spleen or because of mobility or rotation of its pedicle. The same is true in *malarial hypertrophy*.

Splenic anemia (Banti's disease) is a disease in which there seems to be reasons to believe that the later cirrhosis of the liver is due, at least in part, to toxic substances formed in the spleen, and early splenectomy is capable of checking the progress of the disease. But even in the later stages of the disease some successful cases have been reported. When cirrhosis and ascites already exist, splenectomy and operation for ascites should prove of service. The hazards of operation are not great, and without operation the result is fatal. As time has gone on, more and more favorable results have been reported until now this operation is a well-established therapeutic measure. Extraordinary care should be taken to avoid infection, as infected wounds after splenectomy seem to do very badly.

Hemolytic jaundice, pernicious anemia, biliary cirrhosis, and other diseases in which there is destruction of red blood cells seem to be benefited by splenectomy.

Many of these cases of hemolytic disease are so mild as not to call for splenectomy. If the case is progressive, no matter how mild, splenectomy should be done to forestall the inevitable crisis. The surgeon should not wait for the development of the splenic tumor in these cases, especially in the young. In older patients, without actual disability, operation is not imperative. Transfusion of healthy blood may be depended upon usually to give temporary improvement.

The mortality of operation is not high if done between crises. Elliott and Kanavel (Surg., Gyn., and Obst., xxi, 1915) reported forty-eight cases operated upon, with two deaths. The improvement in the blood picture after operation is often striking. E. B. Krumbhaar (Jour. Am. Med. Assoc., Sept. 2, 1916) collected information concerning 153 patients whose spleens were removed for pernicious anemia: 19.6 per cent. died within six weeks; 64.7 per cent. were improved; 15.7 per cent. were

not improved; none were restored to perfect health. The best results are secured if the operation is preceded by one or more blood transfusions. The patients who do badly after operation may be helped by transfusion. The far advanced cases are not improved by splenectomy.

Leukemia is no longer treated by splenectomy, as the operation is found not to give relief. In chronic myeloid leukemia, if treated early, the size of the spleen may be reduced and the blood picture changed to normal by the internal administration of benzol (benzene). The drug is given in milk or in gelatin capsules with an equal amount of olive oil. The beginning dose

FIG. 1459*a*.—SPLENECTOMY.

The splenic artery has been tied; the vein has been doubly ligated and cut; accessory vessels have been tied; and the ligature carrier is passing a ligature through the pedicle.

is 2.5 c.c. (40 minims) daily. The maximum daily amount is 6 c.c. (100 minims), given for 12 days each month. The *x*-ray applied to the spleen is effective. The blood and urine should be watched. Benzol and the *x*-ray combined are capable of giving pronounced results.

Wandering Spleen.—In simple cases of elongated pedicle the ligaments of the spleen may be shortened by folding and suture (splenopexy). *Twisted pedicle* may be treated in the same way; and even though some infarcts be present, the pedicle may be untwisted and the organ fixed in its normal position by sutures. Cases in which the spleen is decidely enlarged are best treated by splenectomy, as sutures are apt to tear out and adhesions give way if the organ is abnormally heavy. When rotation of the pedicle has resulted in complete occlusion of the main vessels splenectomy should be done.

Operations on the Spleen

Splenectomy is easy if there is a free pedicle, and difficult if the spleen is bound down by adhesions, has a short pedicle, and short ligaments, and the patient is fat. The abdomen may be opened behind or to the outer side of the left rectus muscle by a vertical incision beginning just below the free border of the ribs. The incision should be placed in front of the outer part of the rectus, the muscle retracted inward, and the abdomen entered through the posterior sheath of the muscle. This gives the least liability to hernia. Somewhat better access to the spleen is secured by an incision just external to the left rectus muscle. If necessary the incision may be continued upward along the rib margin. A sand-bag behind the back throws the posterior abdominal wall forward. The intestines are packed off with abdominal pads, and the spleen exposed. Adhesions are divided. The reflections of the peritoneum which confine the spleen are ligated and cut and the organ brought forward. Tension should not be made on the splenic vessels as they are very delicate and easily ruptured. As the spleen is dislocated forward and brought out of the abdomen the cavity which it occupied should be packed with warm wet gauze.

The vessels lie behind and internal to the spleen in the folds of peritoneum, connecting the spleen and left kidney. The vessels should be exposed by incising the peritoneum and bluntly dissecting them into view. If large, they should be ligated separately. Good-sized catgut should be used. The peritoneum or even the tail of the pancreas may be included in the ligature if necessary to prevent cutting the friable vessels. The accessory vessels passing to the stomach should not be overlooked. Care should be taken not to wound the stomach. It is best not to wound the pancreas (Fig. 1459*a*). After ligation of the vessels the organ is easily detached and the peritoneum replaced over the bed from which it was removed.

Resection of spleen may be done for tumor, injury or infective disease. The part removed should be of such a shape that the wound is easily closed. The shape of a wedge lends itself best to the operation. Hemorrhage may be prevented by temporarily clamping the pedicle with rubber-covered clamps. After the wound has been closed with deep mattress sutures the clamp may be removed and bleeding not expected. It is said that the splenic artery may be permanently ligated and necrosis will not occur if the vein is patent.

Splenopexy, for fixing wandering spleen, may be accomplished by shortening all of the ligaments with folds held by catgut sutures. It is not advisable to attempt fixation by passing sutures through the substance of the organ. It is friable; the sutures are apt to pull out; and serious hemorrhage is apt to occur.

Rydygier devised a method whereby, after exposing the spleen by a median incision or incision to the outer side of the left rectus muscle, the spleen is slipped into a pocket behind the peritoneum. A transverse incision through the peritoneum is made between the ninth and tenth ribs, and the peritoneum freed from its underlying connective tissue. After placing the spleen in this pocket, it is held by a few sutures which close the opening. Bardenhauer placed the spleen in such a pocket made by a longitudinal incision in the lateral abdominal wall.

INDEX OF NAMES

ABADIE, 161
Abbé, 108, 344, 438
Abbott, 354
Ach, 758
Achard, 402
Adams, 145
Adolph, 565
Albee, 350
Allport, 153
Andrews, 676
Audry, 693

BABLER, 558
Balfour, 595, 724
Ballance, 68
Banti, 785
Barraquer, 174
Beck, 413
Beebe, 390, 394
Beer, 126, 341, 562
Bellocq, 185
Bennet, 344, 711, 712
Bickham, 656
Billroth, 750
Bircher and Weir, 714
Blad, 558, 560
Bode, 528
Bogojawlensky, 88
Bönninghaus, 197
Bradford, 328
Brauer, 418, 424, 451
Brewer, 415
Brinsmade, 521, 694
Brophy, 265
Brown, 574
Bryant, 462
Butlin, 296

CALOT, 332
Cargile, 522
Carr, 19
Carrel, 562
Carter, 180
Charpy, 431
Chiari, 90
Chipault, 33, 48
Christiani, 394
Clark, 533, 547
Clubbe, 607
Coffey, 541, 675, 685, 712
Colton, 408
Connell, 636, 637, 651, 654, 769
Crile, 52, 231, 235, 391, 392, 393, 547
Crisler, 550
Cryer, 29
Cushing, 19, 25, 37, 38, 77, 82, 88, 92, 98, 106, 108, 110, 631, 634, 635, 636, 649, 654, 655, 656, 660, 662, 674
Czerny, 634, 635

DACOSTA, 103
Dahlgren, 29
Davis, 146
Deaver, 578, 579, 727
deForest, 247
Deguise, 377
Déjérine, 323
Delatour, 695
Dench, 321
deSchweinitz, 130, 159
Desmarest, 348
Desmarres, 150
Deutschmann, 135
DeWecker, 152
Dickinson, 515
Dieffenbach, 146
Dobson, 589
Döllinger, 110
Dowd, 574
Doyen, 27, 29, 30, 32

ECK, 561
Elliot, 162
Elliott and Kanavel, 785
Elsberg, 87, 341, 342, 343, 448
Emrich, 570
Estlander, 410
Ewald, 369

FENGER, 267
Fergus, 142
Ferguson, 269
Fetterolf, 189
Finney, 578, 725, 740, 741, 742, 743, 744, 745, 759
Finochietto, 673
Fisher, 529
Flexner, 67
Florio, 556
Foerster, 344
Foote and Weir, 706, 710
Fowler, 410, 528
Franck, 734
Franke, 347, 560
Frazer, 51, 348
Frazier, 37, 77, 87, 106, 107, 109, 111
Freeman, 388
French, 209
Freund, 419
Friedländer, 188, 418, 419, 445, 453, 459, 460
Friedman, 20, 22
Froehlich, 153

GAENSLEN, 344
Gallet, 671
Gant, 693
Gersuny, 692
Gibson, 147, 573, 665

Gigli, 29, 32
Gilbert, 402
Glück, 224, 231, 233, 234, 236
Gottstein, 187, 211, 437
Gould, 389, 633, 634, 654, 666, 668, 669, 678, 714, 736, 751
Gray, 117, 397, 431
Green, 243
Guthrie, 562

Haecker, 429
Hahn, 738
Halsted, 633, 634, 649
Hancock, 161
Harris, 721
Hartley, 106, 108, 671, 674
Haynes, 70, 98
Heine, 157
Heineke and Mikulicz, 740
Heitler, 426
Henle, 436
Herbert, 161
Herschell, 576
Hess, 142
Hirschsprung, 610
Holden, 232
Holt, 719
Horsley, 77, 108, 110
Hort, 576
Hudson, 28, 29

Jaboulay, 392
Jackson, 225, 239, 240, 242, 244, 422, 490, 602
Jamieson, 589
Janeway, 731
Jennings, 480
Jessett, 607
Jianu, 465
Jonnesco, 101
Junker, 188

Kader, 733, 734
Kanavel, 90, 702
Kanavel and Elliott, 785
Keen, 96, 437, 452, 541
Keetley, 572
Kellogg, 610, 611, 614
Kenyon, 38
Killian, 202, 225, 239, 240
Kirstein, 242
Klebs, 207
Knapp, 150, 152, 171, 174
Koch, 429
Kocher, 101, 106, 108, 109, 297, 393, 394, 424, 552, 562, 747
Körner, 314, 315
Kraft, 728
Krause, 78, 87, 88, 106, 108
Krönlein, 50, 752, 779
Krumbhaar, 785
Kuettner, 344
Kuhnt, 145
Kümmell, 757
Kuyk, 369

Lagrange, 157
Lamboth, 559
Landolt, 176
Lane, 261, 444, 602, 613, 614
Lang, 156
Larralde, 417
Lembert, 631, 632, 633, 635, 649
Lenhartz, 721
Lewisohn, 243
Lexer, 108, 110
Lilienthal, 420, 421, 662
Löffler, 207, 212
Lorenz, 327
Loreta, 737
Lotheissen, 439
Lothrop, 199
Ludwig, 362

McArdle, 599
McArthur, 88
McBurney, 510, 572
McGraw, 588, 675, 676
McLean, 675, 676
Martinache, 126
Maunsell, 607, 654, 655, 658, 661, 663
Mayer, 326, 698
Mayo, 384, 385, 386, 579, 642, 644, 685 705, 724, 741, 750, 751, 752, 753, 754, 755 756, 764, 767, 769
Meltzer, 446, 447
Ménière, 319
Metchnikoff, 613
Meyer, 420, 451, 452, 463, 467, 508, 509 716, 757, 759
Mikulicz, 375, 526
Mikulicz and Heineke, 740
Mixter, 693
Monks, 621
Montenovesi, 29
Moschcowitz and Wilensky, 767
Motais, 142
Moynihan, 595, 663, 741, 747
Mules, 159
Munro, 344, 532
Murphy, 418, 552, 635, 667, 669, 671, 771 769

Nicoll, 719

Ochsner, 436, 551, 548, 554, 616
O'Dwyer, 219, 237
Orth, 479

Pagenstecher, 769
Paget, 473
Panas, 152
Panse, 315
Peet, 561, 562
Percy, 492, 494
Perez, 188
Perier, 234
Peterson, 559
Pilcher, 228, 602, 701
Pleth, 662, 677
Plummer, 716
Poirier, 431
Politzer, 301, 306, 307
Polya, 756
Pope, 522
Porter, 390
Pott, 41

QUINCKE, 68

REID, 49
Richardson, 519, 543
Richter, 433
Riggs, 277
Robinson, 407, 410, 411, 412, 421, 449, 450, 451
Robson, 675, 696, 697
Rogers, 219, 220
Rosenow, 577
Rosenstein, 561
Rosenthal, 615
Routte, 560
Roux, 464, 465, 771
Rovsing, 712, 713, 715, 728
Ruth, 489
Ryall, 685

SALOMONI, 429
Sampson, 531
Sangman, 417
Sansum, 132
Sauerbruch, 451, 463, 464
Schede, 411, 461, 463
Schoene, 430
Schultz, 209
Scudder, 720
Sébileau, 235
Seiffer, 322
Senn, 675, 731, 732
Sharpe, 99
Sicard, 348
Sippy, 576
Sluder, 214
Smith, 168, 170, 171, 269
Smithies, 720
Spiller, 107, 109
Stewart, 552, 768
Stillman, 719
Stoffel, 347
Stone, 721
Straus, 682, 719
Strauss, 773, 775, 776, 777
Strempel, 533
Summers, 646
Szymanowski, 145

TALMA, 558
Teale, 150
Teschner, 353
Tewksbury, 414
Thomas, 323, 335
Thorner, 237
Torek, 418, 402
Trendelenburg, 430, 499
Türck, 636, 638, 639

ULLMANN, 658

VERHOEFF, 127, 152
Verning, 391
Vidal, 561
Vogel, 522
von Bergmann, 108, 439
von Bramann, 96
von Hacker, 436
von Leube, 721
von Mikulicz, 243
von Mutschenbacher, 370

WALKER, 660
Wallstein, 464
Warbasse, 546
Watson, 390
Weir, 572, 573, 671, 693
Weir and Bircher, 714
Weir and Foote, 706, 710
Westbrook, 702
Wiener, 153
Wilder, 132
Wilensky and Moschcowitz, 767
Witzel, 697, 736, 758
Wolff, 405
Woodyatt, 132

ZAAIJER, 758
Zanfel, 71
Zesas, 429
Ziegler, 156

INDEX OF SUBJECTS

Abadie's operation in glaucoma, 161
Abbé's method of dilating esophageal stricture, 438
Abbott's treatment of scoliosis, 354
Abdomen, 498
  concussion of, 535
  contusions of, 535
  landmarks, 503
  opening of, 504
    incisions for, 504
      combined, 510
      flap, 510
      lateral muscle-splitting, 507
        vertical, 507
      median, 507
        intramuscular, 506
        postmuscular, 504
      transverse, 507
        postmuscular, 510
  operations on, 498
  regions of, 499
  relaxed, 540
Abdominal carcinoma, inoperable, 706
  muscles, rupture of, 535
  operations, 498
    adhesions in, blunt dissection of, 522
      extensive, 523
      interintestinal, 522
      omental, 522
      to anterior abdominal wall, 522
      treatment, 522
    binder for dressings, 520
    bowel movements after, 531
    closure of peritoneum in, 516
      of wound in, 516
    complications after, 531, 534
    control of bleeding in, 515
    drainage in, 524
      aspiration in, 526
      by counteropening, 528
      dangers, 527
      depth necessary for, 528
      gauze for, 525
        non-adhering, 529
      indications for, 525
        methods, 526
      objections to, 525
      oiled gauze, 529
      rectal, 528
      withdrawal of, 527
    dressing wound in, 519
    elevated-head position after, 529
    emergency feeding after, 535
    feeding after, 534
    figure-of-eight suture in, 519
    hemorrhage in, 523
    increasing abdominal pressure after, 531
    infection of wound in, 537
Abdominal operations, instruments for, 504
    meteorism after, 532
    methods of dealing with, 520
    morphin after, 531
    nausea after, 531
    oxygen after, 531
    pain after, 532
    peritoneum in, 498
    pneumonia after, 534
    position of patient, 499
    preparation of patient, 499
    preventing leaving instruments in abdomen in, 516
    prevention of adhesions in, 521
    proctoclysis after, 533
    rectal tube after, 531
    retention of urine after, 533
    retraction of wound, 515
    shock after, 532
    sponging in, 515
    thirst after, 533
    time for getting up after, 534
    toilet of peritoneum in, 515
    treatment after, 529
    vomiting after, 531
  section, 504
    ilio-inguinal, 510
    low median, by superficial transverse incision, 513
    median, 510
    oblique postmuscular, 511
    subcostal oblique, 513
    vertical postmuscular, 512
  wall, 535
    actinomycosis of, 538
    blood-supply, 501
    cancer of, 538
    echinococcus cysts of, 538
    excessively fat, 538
    fibroma molluscum of, 538
    fibrosarcoma of, 538
    infections of, 536
    landmarks, 503
    lipoma of, 538
    nerve supply, 501
    nevus of, 538
    pendulous, 540
    relaxed, 540
    sarcoma of, 538
    stitch-hole abscesses in, 537
    structures of, 500
    tumors of, 538
    wounds of, 535
Abducens nerve, injuries of, 63
Abscess, alveolar, 277
  cerebellar, usual site, 50
  chronic peritoneal, 554
  extradural, 319
  extramammary, 474

Abscess in Pott's disease, 335
femoral, 337
from mixed infection, 337
inguinal, 337
lumbar, 337
of lower spinal region, 336
of middle cervical region, 336
of upper dorsal region, 336
psoas, 337
retropharyngeal, 335
intracranial, of otic origin, 319
localized, in peritonitis, 553
of anterior chamber of eye, 128
of brain, 73
indications for operation, 73
technic of operation, 74
of chest wall, 398
of esophagus, 432
of eyelids, 119
of lung, acute, 414
chronic, 415
rupturing into bronchus, 415
of mediastinum, 444
of neck, 361
of orbit, 137
of palate, 255
of pancreas, 781
of parotid gland, 379
of scalp, 24
of spine, non-tuberculous, 327
of spleen, 784
of tongue, tuberculous, 290
otic, usual site, 50
perigastric, from perforation of stomach, 727
peritonsillar, 212
retroperitoneal, 563
retropharyngeal, 205
secondary, in peritonitis, 553
stitch-hole, in abdomen, 537
subdiaphragmatic, 470
subphrenic, in peritonitis, 553
Absorbable mechanical devices for intestinal anastomosis, 675
Accessory sinuses of nose, 179
foreign bodies in, 188
thyroid glands, 380
Accidental wounds of scalp, 18
Accidents in cataract extraction, 167
Ach's method of resection of cardiac end of stomach, 758
Acoustic vertigo, operation on seventh nerve in, 112
Acquired stenosis of larynx, 218
of trachea, 218
Actinomycosis of abdominal wall, 538
of intestines, 575
of nasopharynx, 208
of tongue, 290
Adenitis, tuberculous, 368
non-surgical treatment, 369
operation in, 370
Adenofibroma of breast, 475
Adenoids, 208
climate in etiology, 208
evil results from, 208
fresh air in prophylaxis, 208
operation on, 211
Adenoids, operations on, anesthesia in, 209
chair for, 209
instruments for, 209
position of patient, 209
sitting position in, 209
without anesthetic, 208
soft, 208
treatment of, during first year, 211
Adenoma, cystic, of breast, 475
of intestines, polypoid, 582
of stomach, 703
Adenotome, Schultz's, 209
Adherent tonsils, 216
Adhesions in peritonitis, 546
methods of dealing with, in abdominal operations, 520
of intestines, chronic obstruction from, 610
perigastric, 702
Aditus ad antrum, 316
Adrenalin chlorid in nasal operations, 183
in hemorrhage of stomach, 727
Advancement of capsule of Tenon, 177
of rectus muscle, 176
Aërocele, 218
After-cataract, operations for, 174
Air embolism, 430
fresh, to prevent adenoids, 208
insufflation of, in hydrothorax, 402
Alæ nasi, collapse of, 195
Alcohol injections in coccygodynia, 358
Alimentary canal, operations on, preparation of patient for, 564
Allport's method of tattooing cornea, 153
Alternating strabismus, 175
Alum enema, 620
Alveolar abscess, 277
Ambulatory treatment of empyema, 407
Amebic colitis, 570
Anastomosis, intestinal, 646. See also *Intestinal anastomosis.*
of anterior nerve roots in spinal canal, 348
Andrews' clamp method of intestinal anastomosis, 676
Anemia, pernicious, 785
splenic, 785
Anesthesia, cocain, in eye operations, 118
for operations on pituitary body, 83
for tooth extraction, 278
holocain, in eye operations, 118
in adenoid operations, 209
in eye operations, 138
in nasal operations, 181
in operations on mouth, 245
in tonsillectomy, 213
Aneurism, arteriovenous, of cavernous sinus, 73
of scalp, 25
arteriovenous, 25
cirsoid, 25
Angina, Ludwig's, 362
Angioma of brain, 75
of breast, 475
of gums, 280
of lips, 254
of scalp, 25
Angular clamp for pyloroplasty, 747

Angulation of intestines, chronic obstruction from, 610
Ankyloblepharon, 119, 120
Anterior sclerotomy, 156
Antiseptics for eye use, 118
  in bronchiectasis, 419
Antrum, mastoid, 299
  maxillary. See *Maxillary antrum.*
  of Highmore. See *Maxillary antrum.*
Anus, artificial, 687
    closure of, 616
    operation for securing muscular control of, 694
  fissure of, chronic intestinal obstruction from, 610
  ulcer of, chronic intestinal obstruction from, 610
Aphthous ulcers of tongue, 290
Apituitarism, 83
Apoplexy, spontaneous cerebral, 58
      temporal craniotomy in, 58
Appendicostomy, 571
Appendix, anatomy, 624
  exposure of, incision for, 510
Arachnoid space, tapping of, 348
Arch, supra-orbital, 46
Arteries, carotid, wounds of, 360
  intercostal, wounds of, 398
  internal mammary, wounds of, 398
  middle meningeal, 47
Arteriovenous aneurism of scalp, 25
Arthritis deformans, Streptococcus viridans theory of, 613
  of sternoclavicular joint, 398
Artificial anus, 687
    closure of, 616
    operation for securing muscular control of, 694
  larynx, Glück's, 236
  pneumothorax in tuberculosis, 416
Ascites, 557
  anastomosis of saphenous vein with peritoneum in, 560
    of vena cava with portal vein in, 561
      with superior mesenteric vein in, 563
  aspiration in, 557
  drainage into bladder in, 561
  Eck's fistula in, 561
  intra-abdominal adhesions in, artificial formation of, 558
  nutmeg liver in, 558
  subcutaneous drainage in, 559
  tapping in, 557
Aspiration in ascites, 557
  in drainage in abdominal operations, 526
  in hydrothorax, 401
Asthma, thymic, 394
Atomizer, 181
Atonic dilatation of stomach, chronic, 713
Atresia of esophagus, 433
  of lacrimal canals, 136
  of puncta lacrimalia, 136
Atrophic rhinitis, 187
Atrophy of bones of skull, 41
  of optic nerve, 135
Atropin as mydriatic, 117
Auditory canal, external, 299, 304
      acute circumscribed inflammation of, 304
      animate bodies in, 305
      cellulitis of, 304
      cholesteatoma of, 306
      diffuse inflammation of, 304
      eczema of, 304
      epithelial plug in, 306
      examination of, 302
      exostoses of, 304
      foreign bodies in, 305
      impacted cerumen in, 305
      inanimate bodies in, 305
      keratosis obturans in, 306
      mycosis of, 304
      wounds of, 304
  nerve, injuries of, 63
  sensory center of brain, 45
Aural specula, 302
Auricle, 303
  boils of, 304
  cellulitis of, 303
  congenital defects, 303
  excessive development of, 303
  frost-bite of, 304
  furuncles of, 304
  hematoma of, 303
  lobule of, cleft, 303
  malformations of, 303
  perichondritis of, 303
  right, paracentesis of, 425
  skin diseases of, 304
  supernumerary, 303
  wounds of, 303
Auricular point, 45
Auriculotemporal craniotomy for exposure of Gasserian ganglion, 106
Autoserotherapy in hydrothorax, 402
Avulsion of scalp, 23
    complete, 23
Axilla, cancer of, extensive recurrent, 494
  lymphatics of, 472

Babies, mastoid operation on, 318
Back, painful, 350
Banti's disease, 785
Barraquer's method of cataract extraction, 174
Beer and Elsberg's method of laminectomy in medullary tumors of spinal cord, 341
Bellocq's canula in nasal hemorrhage, 185
Benign tumors of breast, 475
      incisions for removal, 477
    of stomach, 703
Bifid tongue, 286
  uvula, 255
Bilateral torticollis, 375
Biliary calculus, 780
  cirrhosis, 785
Binder for abdominal operations, 520
Bismuth paste in empyema, 412, 413
    in chronic suppurative otitis media, 310
Bites of insects on mouth, 247
Bladder, drainage into, in ascites, 561
Blad's method of drainage in ascites, 560
Blastomycosis of eyelids, 120

Blepharitis, 119
squamous, 119
Blepharophimosis, 119, 120
Blepharoplasty, 142
for resection of eyelids, 147
Blepharospasm, 120
Blepharotomy, 143
Blindness with brain tumors, 178
Blood-cysts, mesenteric, 564
Blood-vessels, wound of, cut-throat with, 360
Blowing nose in nasal infections, 186
Bode's position for drainage, 528
Body, ciliary. See *Ciliary body.*
Bogojawlensky's osteoplastic flap operation on pituitary body, 88
Boils of auricle, 304
Boldt's binder for abdominal dressings after operation, 520
Bone drill, brace for, 29
temporal, infections of, intracranial complications, 318
Bone-cutting forceps, linear, Hudson's, 29
Bones of ear, 299
of skull. See *Skull, bones of.*
turbinated, 179
Bone-saw, Gigli's wire, 29
Bönninghaus' method of obliterating maxillary antrum, 197
Bougies, esophageal, 434
olive, 434
Braces, metallic, in Pott's disease, 333
Bradford's frame in Pott's disease, 328
Brain, abscess of, 73, 319
indications for operation, 73
technic of operation, 74
anatomy, 43
angioma of, 75
auditory sensory center of, 45
bulging of, in operation, prevention, 51
carcinoma of, 75
compression of, 53
venesection for, 54
concussion of, 52
cortex, motor area of, anatomy, 44
sensory area of, 45
cortical function topography, 45
contusions of, 52
cystoma of, 75
decompression of, 54
electric reaction of motor areas, testing for, 51
endothelioma of, 75
fibroma of, 75
foreign bodies in, 63
glioma of, 75
gliosarcoma of, 75
hernia of, 64
hypophysis of. See *Pituitary body.*
inflammations of, 73
injuries of, 63
lateral ventricle of, 48
lipoma of, 75
myxoma of, 75
olfactory sensory center of, 45
operations on, advantages of outward dislocation in, 51
hexamethylenamin to prevent meningitis after, 52
Brain, operations on, lumbar puncture in, 51
preventing bulging in, 51
psammoma of, 75
reading center of, 44
sinuses of, 44
lateral, 47
skull and, relations, 46
special sensation areas of, 45
speech center of, 44
substance, hemorrhage into, 57
superior longitudinal sinus of, 47
surface topography, 44
syphilis of, 75
teratoma of, 75
topography of, 48
tuberculosis of, 75
tumors of, 75. See also *Tumors of brain.*
visual sensory center of, 45
wounds of, 61
bullet, 62
stab, 62
writing center of, 44
Blood-letting. See *Venesection.*
Branchial cysts of neck, 372
fistulæ of neck, 372
Breast, 471
adenofibroma of, 475
adenoma of, cystic, 475
angioma of, 475
benign tumors of, 475
caked, 473
cancer of, 477
contraindications to operation, 477
cure, 477
doubtful, operations in, 478
early and complete extirpation of, 477
extensive recurrent, 494
inoperable, 494
lines of incision in, 480
lymph glands in, 479
operation in, 477, 489
after-treatment, 488
closure of wound, 486, 492
drainage, 488
dressing, 488
radical cautery, 492
saving of blood, 486
shock in, 486
steps, 480
prevention, 477
prognosis, 478
recurrence, operations for, 478
tissues to be removed in, 479
congenital anomalies, 472
contusions of, 472
cystadenoma of, 475
cysts of, 476
dermoid cysts of, 477
female, anatomy 471
fistula of, chronic, 474
foreign bodies in, 472
hydatid cysts of, 477
hypertrophy of, 472
senile parenchymatous, 475
lipoma of, 475
lymphatics of, 472
male, cancer of, 497
chronic mastitis in, 497

Breast, male, tumors of, 497
myxoma of, intracanalicular, 475
neuralgia of, 473
nerves of, 475
papillomatous cysts of, 477
simple cysts of, 477
tuberculosis of, 475
tumors of, benign, incisions for removal, 477
mixed, 475
wounds of, 472
Bregma, 45
Brinsmade's operation for securing muscular control of artificial anus, 694
Bronchi, distention of, 419. See also *Bronchiectasis.*
foreign bodies in, 224
removal, 244
pneumotomy for, 456
strictures of, 422
Bronchiectasis, 419
advanced, 419
antiseptics in, 419
colloidal silver in, 419
ligation of pulmonary artery in, 420
mild, 419
phrenic neurectomy in, 420
pneumectomy in, 420
pneumolysis in, 420
pneumotomy in, 419
superheated air inhalations in, 419
thirst cure, 419
thoracoplasty in, 420
Bronchoscopy, 225, 239
lower, 243
position of patient for, 240
superior, 242
Brophy's method of operation in cleft-palate, 265
Bryant's method of posterior osteoplastic thoracotomy, 462
Bulbus oculi, 115, 116
Bullet wounds of abdominal wall, 535
compression treatment, 536
of brain, 62
of intestines, perforating, 567
of spine, 325
Burns of conjunctiva, 124
of cornea, 128
of larynx, 219
of neck, 373
of tongue, 288
of trachea, 219
Burrs, Doyen's, 27, 29
Hudson's, 28, 29
Bursal cysts of neck, 372
Button method of intestinal anastomosis, 667
lateral, 671

Cachexia hypophyseopriva, 83
Caked breast, 473
Calcium hypochlorite in peritonitis, 551
Calculi, biliary, 780
of salivary ducts, 291, 379
pancreatic, 783
Calot's high jacket in Pott's disease, 332
Camphorated oil in peritonitis, 551
Canal, external auditory, 299, 304. See also *Auditory canal, external.*
Fallopian, 299
Canals, lacrimal, atresia of, 136
enlargement of, 177
Cancer, abdominal, inoperable, 706
infection, 706
of abdominal wall, 538
of axilla, extensive recurrent, 494
of brain, 75
of breast, 477. See also *Breast, cancer of.*
of cardia, resection for, 756
of cecum, 589
of colon, 584
of descending colon, 590
of hepatic flexure of colon, 590
of intestines, 583, 588
of larynx, 223
of lower part of sigmoid, 591
of lymphatics of neck, 363
of male breast, 497
of middle and upper sigmoid, 592
of transverse colon, 590
of neck, extensive recurrent, 494
secondary, 372
of nipples, 473
of nose, 188
of pyloric end of stomach, radical operation for, 756
of pylorus, 720
of sigmoid, 589
of skull, 42
of splenic flexure of colon, 590
of stomach, 703
choice of operation in, 704
doubtful, exploratory operation in, 703
gastrectomy in, 704
gastro-enterostomy in, 704
gastrojejunostomy in, 705
gastrostomy in, 705
inoperable, 704
involvement of transverse mesocolon in, 705
operative mortality, 704
palliative operations in, 704
pyloric, operation for, 756
recurrence, 704
symptoms, 703
of thorax, extensive recurrent, 494
of thyroid gland, 381
of tongue, 292
excision in, 293. See also *Excision of tongue.*
operation in, 364
of upper part of rectum, 591
Cancrum oris, 247
Canthoplasty, 143
for enlarging palpebral fissure, 142
Canula, Bellocq's, in nasal hemorrhage, 185
Capsule, Tenon's, advancement of, 177
Capsulotomy, preliminary, for immature cataract, 168
Cardia, cancer of, resection for, 756
Cardiac orifice of stomach, 698
stenosis of, 715

Cardiolysis for pericardial adhesions, 424
Cardiorrhaphy, 427
Cardiospasm, 716
Cargile's membrane to prevent adhesions in abdominal operations, 522
Caries of ribs, 398
of teeth, 275
Carotid artery, wounds of, 360
gland, 395
Carr's clamp for scalp operations, 21
Carter's nasal splint, 180
Cartilages, costal, necrosis of, 398
resection of, in rigidity of chest, 421
laryngeal, dislocations of, 220
nasal, transplanting of, 192
Caseous tonsillitis, 212
Cataract, 132
after-, operations for, 174
artificial ripening in, 133
best time for operation, 133
congenital, 133
couching, 172
depressing, 172
discission of, 169
extraction, accidents in, 167
after-treatment, 166
combined, 166
linear, 170
of crystalline lens without incision of capsule in, 170
simple, 165
suction in, 173
suturing corneal wound after, 172
two-stage, 171
vacuum, 174
with capsule after subluxation, 171
without iridectomy, 165, 166
immature, intracapsular extraction, 171
preliminary capsulotomy for, 168
monocular, 133
needle operation for, 169
operations for, 165
partial, 133
ripe, 133
secondary, operations for, 174
traumatic, 133
immediate removal, 173
zonular, 133
Catarrhal acute laryngitis, 220
tonsillitis, 212
epidemic conjunctivitis, 122
esophagitis, acute, 432
inflammation, acute, of frontal sinuses, 199
of maxillary antrum, 195
chronic, of frontal sinuses, 199
of maxillary antrum, 195
Catheterization of Eustachian tube, 302
Cauliflower ear, 303
Caustics, gastritis due to, 702
Cautery, actual, in ulcer of stomach, 724
radical, in cancer of breast, 492
Cavernous sinus, arteriovenous aneurism in, 73
thrombosis of, 72
Cecostomy, 572
Cecum, anatomy, 624
Cecum, cancer of, 589
exposure of, incision for, 510
resection of, indications for, 642
tuberculosis of, 575
Cells, mastoid, 299
Cellulitis of auricle, 303
of external auditory canal, 304
of lips, 246
of neck, 361
superficial, 362
of parotid gland, 379
of scalp, 23
Cenencephalocele, 93
Cerebellar abscess, usual site, 50
Cerebellopontine angle, osteoplastic craniotomy for exposure of, 41
Cerebral abscess, usual site, 50
apoplexy, spontaneous, 58
temporal craniotomy in, 58
localization, 48
ventricles, lateral, puncture of, in hydrocephalus, 96
puncture of, in hydrocephalus, 95, 96
Cerebrospinal meningitis, epidemic, 67
carriers in, 67
Flexner's treatment, 67
lumbar puncture in, 67
rhinorrhea, 73
sinuses, 73
Cerumen, impacted, in external auditory canal, 305
Cervical esophagectomy, partial, 443
esophagotomy, external, 442
mediastinotomy in esophageal abscess, 433
pleura, 399
ribs, 373
Chair, French's, for adenoid operations, 209
Chalazion, 120
Chapped lips, 246
Chenopodium oil in amebic colitis, 570
Chest, rigidity of, 421
wall, abscess of, 398
inflammations of, 398
penetration of, wounds of lung with, 413
tumors of, 444
wounds of, non-penetrating, 397
penetrating, 397
Chiari's incision for nasal approach to pituitary body, 90
Children, acute simple rhinitis in, 186
Chipault's method of craniocerebral localization, 48, 49
primary lines, 48
secondary lines, 49
Chlorinated oil in peritonitis, 551
Choked disk, 135
Cholecystitis, 780
Cholesteatoma of external auditory canal, 306
Chondritis, 223
costal, 398
Chorda tympani, 299
Choroid, diseases of, 130
foreign bodies in, 130
injuries of 130

Choroid, rupture of, 131
tuberculosis of, 130
tumors of, 130
wounds of, 130
Choroiditis, 130
suppurative, 130
Cicatricial contractures of eyeball, old, operations for, 159
stenosis of esophagus, 433
of pylorus, 720
Ciliary body, diseases of, 130
inflammation of, 130
wounds of, 130
Circular occlusion method of intestinal anastomosis, 658
Circumscribed acute inflammation of external auditory canal, 304
Cirrhosis, biliary, 785
of stomach, 702
Cirsoid aneurysm of scalp, 25
Cisterna magna, drainage of, into cranial sinuses, in hydrocephalus, 98
Clamp method of intestinal anastomosis, 676
Cleansing mouth, 244
Cleft eyelids, 119
lobule of auricle, 303
Cleft-palate, 257
early pressure treatment, 258
etiology, 257
operation in, 258
after-treatment, 265
best time for, 258
disturbed phonation after, 266
failure of union, 265
for closing narrow cleft, 259
wide cleft, 262
incisions for, 261
instruments for, 258
jaw-compressing, 265
later, 258
position of patient, 258
suture of intermaxillary segment, 258
voice-training after, 266
with sliding flap, 261
Climate in etiology of adenoids, 208
Cocain anesthesia in eye operations, 118
hydrochlorid as mydriatic, 118
Coccobacillus fœtidus ozœnæ vaccines in ozena, 188
Coccygeal neuralgia, 357
Coccygodynia, 357
alcohol injections in, 358
massage in, 358
removal of coccyx for, 359
Coffey's operation for relaxed abdominal wall, 541
Colitis, 570
amebic, 570
colon irrigation in, 570
continuous irrigation in, 571
mucous, chronic intestinal obstruction from, 610
Collapse of alæ nasi, 195
peritoneal, 549
Colloidal silver in bronchiectasis, 419
Colon, acquired dilatation of, 614
Colon, acute flexures of, chronic intestinal obstruction from, 610
obstruction of, 598
angulations of, chronic intestinal obstruction from, 610
ascending, anatomy, 625
resection of, indications for, 642
cancer of, 584
congenital dilatation of, 614
descending, anatomy, 625
cancer of, 590
dilatation of, chronic intestinal obstruction from, 610
hepatic flexure, cancer of, 590
ptosis of, 616
perforation of, 582
resection of, preventing obstruction to passage of gas in, 644
splenic flexure, cancer of, 590
ptosis of, 616
transverse, anatomy, 625
cancer of middle of, 590
ptosis of, 616
resection of, with preservation of omentum, 646
sagging of, with elongation of gastrocolic ligament, in gastroptosis, 713
Colostomy, 573, 685
apparatus to collect feces after, 695
inguinal, left, 686
lumbar, 695
Colton's drainage tube in empyema, 408
Combined iridectomy and sclerotomy, 157
Compression of brain, 53
venesection for, 54
Concussion of abdomen, 535
of brain, 52
of spinal cord, 324
of thorax, 397
Condyloid point of inferior maxilla, 45
Congenital anomalies of breast, 472
cataract, 133
cysts of neck, 372
defects of external ear, 303
idiocy, 103
imbecility, 103
insanity, 103
stenosis of esophagus, 433
of larynx, 218
of trachea, 218
Conical cornea, operations for, 153
Conjunctiva, burns of, 124
diseases of, 121
eczema of, 123
foreign bodies in, 124, 127
hyperemia of, 121
inflammation of, 121. See also *Conjunctivitis.*
injections under, 151
operations on, 149
skin diseases involving, 124
tumors of, 124
wounds of, 121, 124
Conjunctivitis, acute contagious, 122
diphtheric, 123
diplobacillus, 122
epidemic catarrhal, 122

Conjunctivitis, follicular, 123
gonorrheal, 123
granular, 123
neonatorum, 122
non-gonorrheal, 122
phlyctenular, 123
pseudomembranous, 123
purulent non-specific, 121
simple, 121
sympathetic, 130
vernal, 123
Connell's end-to-end anastomosis with mattress sutures, 651
Constipation, chronic, in chronic intestinal stasis, 613
Contagious conjunctivitis, acute, 122
Continuous gastric lavage, 701
intestinal suture, 620
Contractures of eyeball, old cicatricial, operations for, 159
Contusions of abdomen, 535
of brain, 52
of breast, 472
of face, 115
of intestines, 565
of larynx, 219
of scalp, 17
of spinal cord, 324
of thorax, 396
of trachea, 219
Coprostasis, chronic intestinal obstruction from, 610
Cord, spinal. See *Spinal cord.*
Cornea, adhesions of, to iris, 156
burns of, 128
conical, operations for, 153
diseases of, 124
eczema of, 125
foreign bodies in, 127
inflammation of. See *Keratitis.*
method of inspection, 116
opacity of, 126
operations on, 152
paracentesis of, 152
tattooing of, 152
transplantation of, 153
tumors of, 128
ulcers of, 125
simple, 125
wounds of, 121, 128
Corneal opacity, 126
Coronal suture, 45
Corrosive esophagitis, 432
Corset, decompression, in scoliosis, 354
in Pott's disease, 334
in scoliosis, 353
Costal cartilages, excision of, for exposure of heart and pericardium, 424
necrosis of, 398
resection of, in empyema, 419
in rigidity of chest, 421
chondritis, 398
joints, arthritis of, 398
pleura, anatomy, 399
Couching cataract, 172
Cracks of tongue, 289
Craniocerebral localization, 48
Craniocerebral localization, Chipault's method, 48, 49
Reid's method, 49
topography, 45
Craniotabes, 41
Craniotomy for exposure of Gasserian ganglion, 106
auriculotemporal, 106
control of hemorrhage in, 109
dividing sensory root, 107
high temporal, 106
intracranial method, 107
low temporal, 106
mortality, 109
operation of choice, 109
position of patient for, 108
removing ganglion in, 107
part of ganglion in, 108
results, 110
special modifications, 108
subtemporal, 106
two-stage operation, 108
in intracranial hemorrhage in newborn, 61
osteoplastic, 30, 34
administration of anesthetic, 31
cutting bone flap in, 32, 33
flap method, 38
in occipital region, 31
incisions for, 31
intermuscular temporal, 36
method of applying drainage in, 35
occipital, bilateral, 38, 40, 41
unilateral, 37, 39
position on table for, 31
preparation of patient, 30
suboccipital, 36
temporal, 34, 36
two-stage operation, 32
subtemporal, 106
temporal, in spontaneous cerebral apoplexy, 58
Crile's method of laryngectomy, 235
of ligation of thyroid gland, 393
of thyroidectomy, 392
Crises, gastric, of tabes, excision of spinal ganglia in, 348
rhizotomy for, 347
Cryer's spiral osteotome, 28
Cryptophthalmos, 119
Crystalline lens, diseases of, 132
dislocation of, 134
extraction of, without incision of capsule, in cataract, 170
foreign bodies in, 133
Curvature of spine, lateral, 352. See also *Scoliosis.*
Curved needle for intestinal suture, 627
Cushing's approach in operations on pituitary body, 88
method for suboccipital unilateral craniotomy, 38
parallel continuous stitch in intestinal suture, 631
rubber tourniquet for scalp operations, 20, 21
Cut-throat with wound of air-passages, 360

Cut-throat with wound of blood-vessels, 360
Cyclitis, 130
Cyclodialysis, 157
  in glaucoma, 161
Cyst, Meibomian, 120
  mesenteric, 564
  of breast, 476
  of eyelids, 138
  of intestinal wall, 582
  of intestines, gaseous, perforation of, 581
  of jaws, 286
  of lung, echinococcus, 445
  of maxillary antrum, 197
  of neck, 372
  of omentum, 620
  of pancreas, 783
  of spleen, hydatid, 785
  of stomach, 703
  of teeth, 280
  of tongue, 292
  of umbilicus, 537
  of urachus, 538
  retroperitoneal, 564
  sebaceous, of face, 115
    of scalp, 24
Cystadenoma of breast, 475
Cystic mastitis, chronic, 474
Cystoma of brain, 75
  of lips, 254
Czerny's mucosa suture of intestine, 635

Dacryocystitis, 136
Davis' operation for ectropion, 146
Deafness, advanced tympanic, 319
Decompression corset in scoliosis, 354
  in brain tumors, 78
  in epilepsy, 101
  of brain, 54
Decortication of lung in chronic non-tuberculous empyema, 410
Defects, congenital, of auricle, 303
Deflections of nasal septum, 188
Deformities of jaws, 280
  of lower jaw, with defective occlusion, 283
  of skull, 42
Deguise's method of closing parotid salivary fistula, 377
Delatour's apparatus for collecting feces after colostomy, 695
Dench's operation in middle-ear disease with labyrinthine involvement, 321
Depressing cataract, 172
Dermoid cysts of breast, 477
  tumors of scalp, 24
DeSchweinitz's rules for enucleation of the eye, 130
Desmarres' operation for pterygium, 150
Detachment of retina, 134
DeWecker's operation for staphyloma, 152
Diabetes, soft eyeball in, 132
Diabetic iritis, 129
  retinitis, 134
Diaphragm, hernia of, treatment, 470
  thoracic exposure of, 467
Diaphragm, tumors of, treatment, 470
  wounds of, 398, 536
Diaphragmatic pleura, 399
Diaphragmotomy, subpleural, for subphrenic abscess, 554, 555
Dichloramin in peritonitis, 551
Dickinson's rubber retractor, 515
Dieffenbach's operation for ectropion, 146
Diffuse inflammation of external auditory canal, 304
Dilatation of colon, acquired, 614
    chronic intestinal obstruction from, 610
    congenital, 614
  of esophagus, 438
  of stomach, 713
    acute, 615, 714
    chronic, atonic, 713
    gastroplication in, 714
  postoperative, 615
Dionin in diseases of cornea, 124
  in eye diseases, 118
Diphtheria, 207
Diphtheric conjunctivitis, 123
Diplobacillus conjunctivitis, 122
Direct laryngoscopy, 240
Disk, choked, 135
Dislocations of crystalline lens, 134
Diverticula, intestinal, 603
  of esophagus, 438
    extirpation of, 439
Doyen's burr, 27, 29
  hand saw for linear bone incisions, 30
Drainage in abdominal operations, 524
  of maxillary antrum, 195
  of pancreas, 780
  in peritonitis, 547, 549
  subcutaneous, in ascites, 559
Drill, bone, brace for, 29
Drum, ear, 299. See *Tympanic membrane.*
Dry laryngitis, 222
Duboisin sulphate as mydriatic, 118
Duct, thoracic. See *Thoracic duct.*
Duodenal fistula, 582
  lavage, 701
  ulcer, 576
    gastrojejunostomy in, 578
    indications for operation in, 577
    intermittency in, 577
    jejunostomy in, 578
    operative treatment, 577
    perforating, 579
    permanent occlusion of pylorus for, 578
    pyloroplasty in, 578, 740
    reconstruction operation after, 775
Duodenostomy in corrosive esophagitis 432
Duodenum, anatomy, 621
  exposure of, route for, 780
  occlusion of, 615
  ulcer of, reconstruction operation after, 775
Dura mater, anatomy, 43
    venous sinuses of, thrombosis of, 70
      infective, 71
    wounds of, 61

Dysentery, tropical, 570
Dyspeptic ulcers of tongue, 289
Dyspnea after operation in harelip, 274
  thymic, 395

Ear, 299
  anatomy of, 299
  bones of, 299
  cauliflower, 303
  drum, 299. See *Tympanic membrane.*
  external. See *Auricle.*
  middle. See also *Middle ear.*
  ossicles of, 299
  postmeatal triangle of, 300
  running, 310
Ecchymosis of eyelids, 121
Echinococcus cysts of abdominal wall, 538
    of lung, 445
    of neck, 372
Eck's fistula in ascites, 561
Ectropion, 119, 120
  operations for, 144
Eczema of conjunctiva, 123
  of cornea, 125
  of external auditory canal, 304
  of nipples, 473
Edema of glottis, 221
  of optic nerve, intra-ocular, 135
    papilla, engorgement, 135
Effusion, non-infective meningeal, 68
Electric reaction of motor areas of brain, testing for, 51
Electrocautery in stricture of esophagus, 438
Electrode for testing electric reaction of motor areas and nerves, 51
Electrolysis for dilatation of esophageal stricture, 438
Elephantiasis nervosum of scalp, 24
Elevated-head position after abdominal operations, 529
Elevator for tooth extraction, 279
Elliot's method of trephining sclera in glaucoma, 162
Elongated mesocolon, 616
Elongation of uvula, 255
Elsberg and Beer's method of laminectomy in medullary tumors of spinal cord, 341
  apparatus for insufflation of lungs, 448
  extrusion treatment of medullary tumors of spinal cord, 342
  incision for frontal approach to pituitary body, 87
Embolism, air, 430
  gas, from artificial pneumothorax, 417
Emetin in amebic colitis, 570
Eminence, frontal, 46
Emphysema, 400
  of neck, 361
  pulmonary, rib resection in, 419
  subcutaneous, in artificial pneumothorax, 417
Empyema, 402
  after-treatment, 404
  ambulatory treatment, 407
  bismuth paste in, 412, 413
Empyema, chronic non-tuberculous, 409
      decortication of lung in, 410
      removing plastic deposits from lung in, 410
  combined operations in, 411
  delayed healing in, 404
  Estlander's rib resection in, 410
  internal thoracotomy for, 403
  muscle implantation in, 411
  of frontal sinuses, 199
  of maxillary antrum, 195
  of pericardium, 423
  operation for, 403
    without rib-resection, 408
  promoting expansion of collapsed lung after operation, 405
  rib trephining for, 407
  Schede's operation in, 411
  securing increase of intrapulmonary pressure after operation, 405
  simple intercostal thoracotomy in, 403
  suction in, after operation, 406
  thoracoplasty in, 410
  tuberculous, 413
  valve device in, 406
Encephalitis, acute, 73
Encephalocele, 92
  operation on, 93
Encephalocystocele, 93
Enchondroma of jaws, 286
Endameba buccalis, 277
Endonasal operations on lacrimal sac, 178
Endothelioma of brain, 75
Endolaryngeal operations, local anesthesia in, 218
End-to-end intestinal anastomosis by invagination method, 654
      of segments of unequal size, 656
    simple, 647
    with mattress sutures, 651
End-to-side intestinal anastomosis, 665
Enemata, 620
Engorgement edema of optic papilla, 135
Enlarged thymus, 395
Enterectomy, partial, 636
Enteric feeding, 701
Entero-enterostomy, 646. See also *Intestinal anastomosis.*
Enteroptosis, 616
Enterorrhaphy, 628. See also *Intestinal suture.*
Enterostomy, 573, 683
  for acute intestinal obstruction, 685
Entropion, 119, 120
  operations for, 143
Enucleation of eyeball, 121, 157
    grafting eyeball after, 160
    remote, insertion of artificial globe after, 159
    rules for, 130
    transplantation of fat into orbit after 160
  of growths in thyroid gland, 385
  of tonsils, 213, 214
Ependyma, diseases of, 65
Epicanthus, 119
Epidemic catarrhal conjunctivitis, 122

Epidemic cerebrospinal meningitis, 67
carriers in, 67
Flexner's treatment, 67
lumbar puncture in, 67
Epigastrium, lipoma of, 538
Epilepsy, 99
curative effects of operations, 101
decompression in, 101
focal, 101
from tumors, 101
internal treatment, 102
of spontaneous origin, 101
prophylaxis, 99
removal of sympathetic ganglia of neck in, 101
thymic, 385
traumatic causes, removal of, 100
with enlarged thymus, 101
Epileptic habit, 99
Epiphoria, 136
Episcleritis, 128
Epistaxis, 184
Epithelial plug in external auditory canal, 306
Epithelioma of face, 115
of gums, 280
of lower lip, 247
excision of lip for, 252
incomplete operation for, 250
operations for, 247–254
resection of lip for, 251
Epulis, 280
Erysipelas of scalp, 24
Eserin as miotic, 118
in acute intestinal stasis, 614
Esophageal bougies, 434
forceps, 440
Esophagectomy, partial cervical, 443
Esophagismus, 442
Esophagitis, acute catarrhal, 432
chronic, 433
corrosive, 432
gangrenous, 433
Esophagogastrojejunostomy, Roux's method, 464
Esophagoplasty, 464
Esophagoscopes, 243
Esophagoscopy, 243
Esophagotomy, external cervical, 442
internal, in stricture of esophagus, 438
Esophagus, abscess of, 432
anatomy, 430
atresia of, 433
congenital stenosis of, 433
diverticula of, 438
extirpation of, 439
fissures of, 433
fistula of, 439
foreign bodies in, 440
removal, 244
operation for, 441
hemorrhage from, 432
inflammations of, 432
resection of, of lower segment, 470
rupture of, 432
spasm of, 442
stenosis of, cicatricial, 433
Esophagus, stricture of, 433. See also *Stricture of esophagus.*
thoracic, resection of, 463
tumors of, 445
ulceration of, 432
ulcers of, 433
wounds of, 360, 431
Estlander's rib resection in empyema, 410
Ether, sulphuric, in peritonitis, 551
Ethmoid sinuses, 180
suppuration of, 197
operation in, by orbital route, 198
Ethyl morphin hydrochlorid, in eye diseases, 118
Eustachian tube, 299
catheterization of, 302
patency of, 301
Eventration in intestinal gangrene, 609
in intussusception, 607
Eversion of eyelid, method, 116
operation for, 144
Evisceration of eyeball, 159
Excision of costal cartilage for exposure of heart and pericardium, 424
of lacrimal sac, 178
of lower lip for epithelioma, 252
of non-toxic goiter, 385
control of hemorrhage, 388
results, 389
tracheotomy with, 389
of spinal ganglia in gastric crises of tabes, 348
of sternomastoid muscle in torticollis 375
of tongue for carcinoma, 293
after division of lower jaw, 297
after-treatment, 299
complete, 294
instruments for, 293
position of patient, 293
preparations, 293
through submaxillary incision, 297
without preliminary ligation of the vessels, 296
operation in trachoma, 151
Exclusion, intestinal, 677
of pylorus, 771
Exfoliative glossitis, 289
Exophthalmic goiter, 390
Exophthalmos, extreme, in hyperthyroidism, 391
pulsating, 137
in arteriovenous aneurism of cavernous sinus, 73
Exostoses of external auditory canal 304
Exposure of nasopharynx, 216
External angular process of supra-orbital arch, 46
auditory canal, 304. See *Canal, external auditory.*
ear. See *Auricle.*
Extirpation of diverticula of esophagus, 439
Extraction of cataract. See *Cataract extraction.*
of teeth, 278
anesthesia for, 278

Extraction of teeth, bleeding after, 279
technic, 278
with elevator, 279
Extradural abscess, 319
hemorrhage, 55
ligation of middle meningeal artery in, 56
infections, 65
of otic origin, 65
Extramammary abscess, 474
Extrapial hemorrhage compressing spinal cord, 325
Extrusion of iris, 121
of medullary tumors of spinal cord, 342
Eye, 115
anatomy, 115
anterior chamber of, abscess of, 128
drainage of, 152
antiseptics for, 118
diseases of, subconjunctival injections in, 179
muscles of, 116
disorders of, 135
operations on, 174
paralysis of, 135
operations on, 138
cocain anesthesia in, 118
dressings for, 138
holocain anesthesia in, 118
instruments for, 138, 139
materials for, 119, 138
position of patient, 118
of surgeon, 119
preparation of patient, 118
of region for, 138
shield for, 138, 140
Eyeball, adhesion of eyelids to, operations for, 150
enucleation of, 121, 157
grafting eyeball after, 160
remote, insertion of artificial globe after, 159
rules for, 130
transplantation of fat into orbit after, 160
evisceration of, 159
implantation of artificial globe after, 159
iron foreign bodies in interior, removal of, 160
old cicatricial contractures of, operations for, 159
operations on, 157
soft, in diabetes, 132
turning forward of lid margin away from, 120
of lid border toward, 120
wounds of, 121
Eyelids, absence of, 119
adhesion of, to eyeball, operations for, 150
blastomycosis of, 120
cellulitis of, 119
cleft, 119
cohesion at outer angle, 119
with ball, 119
congenital anomalies, 119
Eyelids, cysts of, 138
diseases of, 119
ecchymosis of, 121
eversion of, method, 116
operation for, 144
granular, 123
herpes zoster of, 119
inability to close, 120
inflammation of margins, 119
injuries of, 120
inversion of, operations for, 143
operations on, 138
ptosis of, 119
operations for, 138
resection of, blepharoplasty for, 147
seborrhea of, 119
tumors of, 120
turning forward of margin away from ball, 120
of border toward ball, 120
union between margins of, 119
upper, operation for restoration, 142
ptosis of, 120
wounds of, 121

Face, contusions of, 115
epithelioma of, 115
inflammations of, 115
injuries and diseases of, 115
moles of, 115
nevi of, 115
sebaceous cysts of, 115
tumors of, 115
wounds of, 115
Facial nerve, injuries of, 63
Fallopian canal, 299
Faradism in hyperthyroidism, 390
Fat, transplantation of, into orbit, after enucleation, 160
Fauces, operations on, 205
Fecal fistula, closure of, 616, 617
temporary, 619
permanent, 687
temporary, 686
with obstruction, closure of, 618
with spur, closure of, 618
Feces, impacted, chronic intestinal obstruction from, 610
Feeding after abdominal operations, 534
after intestinal operations, 778
after stomach operations, 778
enteric, 701
Femoral abscess in Pott's disease, 337
Fenger's operation in harelip, 267
Fergus' operation for ptosis of eyelids, 142
Ferguson's bandage for harelip, 269
Fetterolf's file for deviations of septum, 189
Fibro-adenoma of breast, 475
Fibroma molluscum of abdominal wall, 538
of brain, 75
of jaws, 286
of nasopharynx, 208
of peritoneum, 563
of scalp, 24
Fibroneuroma of scalp, 24
Fibrosarcoma, 280
of abdominal wall, 538

Fifth nerve, anatomy, 105
injuries of, 63
intracranial operations on, 105
for neuralgia, 115
Figure-of-eight suture, double, for closing abdominal wound, 519
for closing abdominal wound, 519
Finney's method of pyloroplasty with gastroduodenostomy, 741
Finochietto's method of introducing button for lateral intestinal anastomosis, 673
Fissure, anal, chronic intestinal obstruction from, 610
of esophagus, 433, 439
of lips, 246
of nipple, 473
of Sylvius, 46
Rolandic, 46
lower end, 46
Fistula, duodenal, 582
Eck's in ascites, 561
fecal, closure of, 618
temporary, 619
permanent, 687
temporary, 686
with obstruction, closure of, 618
with spur, closure of, 618
intestinal, closure of, 616
permanent, in lower small intestine, 685
temporary, 683
milk, 474
of breast, chronic, 474
of lacrimal gland, 136
of neck, branchial, 372
of umbilicus, 537
of urachus, 538
parotid salivary, 377
Fixation in torticollis, 373
Flexner's treatment of epidemic cerebrospinal meningitis, 67
Fluidity of vitreous, 134
Focal epilepsy, 101
Follicular conjunctivitis, 123
tonsillitis, 212
Forceps, esophageal, 440
Foreign bodies in accessory sinuses, 188
in brain, 63
in breast, 472
in bronchi, 224
pneumotomy for, 456
in choroid, 130
in conjunctiva, 127
in cornea, 127
in crystalline lens, 133
in esophagus, 440
operation for, 441
removal, 244
in external auditory canal, 305
in heart, 429
in larynx, 224
removal, 244
in maxillary antrum, 197
in nose, 188
in peritoneal sac, 544
in pharynx, 216
in sclera, 129
Foreign bodies in stomach, 714
removal, 244
in tongue, 287
in tonsils, 216
in trachea, 224
removal, 244
in vitreous, 134
intestinal obstruction from, 608
iron, in interior of eyeball, removal of, 160
Fowler's method of decortication of lung, 410
position for drainage, 528
Fractures of larynx, 219
of trachea, 219
Franck's method of gastrostomy through external cone, modified, 734
Franke's method of avulsion of intercostal nerves, 347
method of drainage in ascites, 560
Frazier's attachment for holding patient in craniotomy, 37
method of frontal approach to pituitary body, 87
French's chair for adenoid operations, 209
Friedman's safety-pin hemostat in scalp operations, 20, 21
Froehlich's method of tattooing cornea, 153
Frontal eminence, 46
sinuses, 179
catarrhal inflammation of, acute, 199
chronic, 199
empyema of, 199
free opening of, 199
obliteration of, 202, 205
wide opening of, 200
Frost-bite of auricle, 304
Functional scoliosis, 353
Fundus of stomach, 698
Fungus cerebri, 65
Furrows of tongue, 289
Furuncles of auricle, 304

Gaenslen's method of osteoplastic laminectomy, 344
Gag, mouth, 245
Galactocele, 477
Gall-bladder, exposure of, incision for, 513
Gall-stone disease, 780
Gall-stones, intestinal obstruction from, 608
Galvanism in hyperthyroidism, 390
Ganglia, sympathetic, of neck, removal, in epilepsy, 101
Gangrene of intestines, 609
eventration for, 609
of lung, 415
Gangrenous esophagitis, 433
stomatitis, 247
Gas embolism from artificial pneumothorax, 417
Gaseous cysts of intestinal wall, 582
Gasserian ganglion, exposure of, craniotomy for, 106

Gastrectomy in cancer of stomach, 704
partial, 751, 759
gastrojejunostomy after, 755
shock in, 776
total, 761
Gastric cancer, 703. See also *Cancer of stomach.*
crises of tabes, excision of spinal ganglia in, 348
rhizotomy for, 347
lavage, 700
continuous, 701
contraindications, 701
in peritonitis, 547, 550
indications for, 701
method, 700
ulcer, 720. See also *Ulcer of stomach.*
Gastritis due to caustics, 702
phlegmonous, 702
Gastrocolic ligament, elongation of, with sagging of transverse colon, in gastroptosis, 713
route of approach to pancreas, 779
Gastroduodenostomy, 747
pyloroplasty with, 741
Gastro-enterostomy, 762
feeding after, 778
in gastric cancer, 704
in gastroptosis, 713
in ulcer of stomach, 722
posterior, in pyloric stenosis, 719
shock in, 776
Gastro-esophagoplasty, Jianu's method, 465
Gastrohepatic route of approach to pancreas, 779
Gastro-intestinal tract, reconstruction of wall, by tissue transplantation, 773
Gastrojejunal ulcer, 580
Gastrojejunostomy after resection of pyloric end of stomach, 755
anterior, 769
in cancer of stomach, 705
in duodenal ulcer, 578
posterior, 762
Gastropexy in gastroptosis, 711
Gastroplasty by transverse incision in hour-glass stomach. 709
for hour-glass stomach, 709
shock in, 776
Gastroplication in dilatation of stomach, 714
Gastroptosis, 710
elongation of gastrocolic ligament with sagging of transverse colon in, 713
gastroenterostomy in, 713
gastropexy in, 711
hepatopexy in, 712
pressure pad in, 711
Gastroscopy, 244
Gastrostomy, 730
by canalization of stomach wall, 736
in cancer of stomach, 705
in stricture of esophagus, 436
through external cone, 734
through internal cone, 731
with external flap, 731
Gastrotomy, 730
in corrosive esophagitis, 432
Gauze drainage in abdominal operations, 525
Gibson's operation for resection of eyelids, 147
wooden clamp for lateral intestina anastomosis, 665
Gigli's wire bone saw, 29
Gingivitis, 277
Glabella, 45
Gland, carotid, 395
lacrimal, 136
thymus, 394
thyroid, 380
Glanders of nasopharynx, 208
Glands, internal jugular, 363
occipital, 363
parathyroid, anatomy, 380
parotid, 363
retro-auricular, 363
retropharyngeal, 363
salivary, 377
submaxillary, 363
submental, 363
subparotid, 363
substernomastoid, 363
supraclavicular, 363
thyroid, accessory, 380
Glaucoma, 131
intravenous injections of glucose in, 132
iridectomy in, 131
malignant, 132
mydriasis in, 118
operations for, 161
osmosis treatment, 131
Glioma of brain, 75
of retina, 135
Gliosarcoma of brain, 75
Globe. See *Eyeball.*
Glossitis, acute parenchymatous, 288
exfoliative, 289
superficial, acute, 288
chronic, 288
Glottis, edema of, 221
spasm of, 221
Glück's artificial larynx, 236
methods in laryngectomy, 233, 234
Glucose, intravenous injections of, in glaucoma, 132
Glycerin enema, 620
Goiter, 381
contraindications to operation in, 382
exophthalmic, 390
incision for, 382
indications for operation in, 382
inflammation of, 380
intrathoracic, 446
non-toxic, excision of, 382
control of hemorrhage in, 388
results, 389
operative treatment, 382
vascular, operation on, 388
Gonorrheal conjunctivitis, 123
iritis, 129
stomatitis, 247

Gottstein's treatment in atrophic rhinitis, 187
Gould's infolding right-angle mattress suture of intestines, 634
method of end-to-side intestinal anastomosis, 666
Gouty iritis, 129
Graduated tenotomy in heterophoria, 176
Grafting eyeball after enucleation, 160
of teeth, 279
Grafts, omental, in intestinal suture, 629
peritoneal, 544
Granular conjunctivitis, 123
eyelids, 123
Grattage operation in trachoma, 151
Graves' disease, 389
Green's direct-illumination esophagoscope, 243
Gridiron incision, intramuscular, in abdominal section, 510
Guillotine, 213
removal of tonsils with, 216
Gums, 274
angioma of, 280
epithelioma of, 280
inflammation of, 277
sarcoma of, 280
myeloid, 280
tumors of, 280
Gunshot wounds of tongue, 288
of spleen, 784

Habit, epileptic, 99
Habitual torticollis, 377
Hahn's method of pylorodiosis, 737
Halsted's right-angle mattress stitch in intestinal suture, 633
Hammock for lateral correction in scoliosis, 354
suspension, for applying jacket in Pott's disease, 329
Hancock's operation for glaucoma, 161
Hand saw, Doyen's, for linear bone incisions, 30
Hard-rubber bridge in saddle-nose, 194
Harelip, 206
deformed nostril with, 273
double, operation for, 271
lateral, operation for, 269
notched lip after, 273
operation for, 267
after-treatment, 273
dyspnea after, 274
failure of union in, 274
split-flap, 267
Harrington's segmented ring for intestinal anastomosis, 674
Harris' diet in ulcer of stomach, 721
Hartley-Krause method of removing Gasserian ganglion, 108
Haynes' operation in meningitis, 70
Head, diseases of, 17
injuries of, 17
support of, in Pott's disease, 353
tower, 42
Heart, 424
anatomy, 424
exposure of, by plastic flap, 426
Heart failure of newborn, 430
foreign bodies in, 429
massage of, for syncope, 430
operative exposure, 424
reanimation of, 430
suture of, 427
wounds of, 428
penetrating, 429
Heineke and Mikulicz's method of pyloroplasty, 740
Heine's method of cyclodialysis, 157
Hematemesis, 727
Hematoma of auricle, 303
of scalp, 17
Hematomyelia, 325
Hemolytic jaundice, 785
Hemorrhage after extraction of teeth, 279
after tonsillectomy, 214
control of, in abdominal operations, 515
in goiter excision, 388
extradural, 55
ligation of middle meningeal artery in, 56
extrapial, compressing spinal cord, 325
from esophagus, 432
from larynx, 223
from nose, 184
in abdominal operations, 523
control of, 515
in scalp wounds, control of, 18
into brain substance, 57
into retina, 135
into spinal cord, 325
into vitreous, 134
intra-abdominal postoperative, 524
intracranial, 54
in newborn, 60
craniotomy in, 61
labyrinthine, 319
of stomach, 727
operation for, 728
subarachnoid, 57
subdural, 56
Hemorrhagic cysts of neck, 372
retinitis, 134
Hemorrhoids, chronic intestinal obstruction from, 610
Hemostasis in mouth, 245
in nasal operations, 183
Hemostat, Friedman's, for scalp operations, 20, 22
Hemothorax, 400
Hepatopexy in gastroptosis, 712
Herbert's wedge-isolation operation for glaucoma, 161
Hernia cerebri, 64
of brain, 64
of diaphragm, treatment, 470
Herpes of lips, 246
of nasopharynx, 208
of tongue, 288
zoster of eyelids, 119
Herpetic keratitis, 127
ulcers of tongue, 290
Hess' operation for ptosis of eyelids, 142
Heterophoria, graduated tenotomy in, 176
partial tenotomy in, 176

Hexamethylenamin to prevent meningitis after brain operations, 52
High inguinal sigmoidostomy, 689
tracheotomy, 227
Highmore, antrum of, 179. See *Maxillary antrum.*
Hirschsprung's disease, chronic intestinal obstruction from, 610
Holocain anesthesia in eye operations, 118
Homatropin as mydriatic, 118
Hordeolum, 119
Hormonal in acute intestinal stasis, 614
Horny elevations of lips, 254
Hot-air treatment of chronic suppurative otitis media, 309
Hour-glass stomach, 706
gastroplasty for, 709
by transverse incision, 709
Hudson's burrs, 28, 29
linear bone-cutting forceps, 29
Hydatid cysts of breast, 477
of spleen, 785
Hydrencephalocele, 92
Hydrocephalus, 94, 350
acquired internal, 95
congenital, subtemporal drainage in, 96
ventricular, 95, 97
subperitoneal drainage in, 97
drainage of cisterna magna into cranial sinuses in, 98
external, 94, 95
puncture of cerebral ventricles in, 95, 96
Hydrothorax, 401
aspiration in, 401
autoserotherapy in, 402
insufflation of air in, 402
tuberculous, 413
Hygiene of mouth, 245
Hyoscin as mydriatic, 118
Hyperchlorhydria in ulcer of stomach, treatment, 722
Hyperemia of conjunctiva, 121
Hyperplastic nasopharyngitis, 205
rhinitis, 187
Hyperthyroidism, 389
dangers of non-operative treatment, 391
extreme exophthalmos in, 391
faradism in, 390
galvanism in, 390
ligation of thyroid gland in, 393
operative treatment, 391
quinin and urea injections in, 390
radium in, 390
thyreoprivic serum in, 390
thyroidectomy in, 392
x-rays in, 390
Hypertrophic stenosis of pylorus, acquired, 720
subglottic laryngitis, 219
Hypertrophy of breast, 472
senile parenchymatous, 475
of lacrimal gland, 136
of spleen, 785
of thymus gland, 446
of tongue, 290
of tonsils, chronic, 212
of turbinates, 186
Hypodermoclysis in peritonitis, 550
Hypophysis of brain. See *Pituitary body*
Hypopyon, 128
keratitis, 126
operation for, 152
Hypothyroidism, 394
Hysteria, traumatic, 103
Hysterical spine, 355

Idiocy, congenital, 103
Ileocecal valve, anatomy, 625
incompetent, 614
obstruction, 602
Ileocolostomy for tuberculosis of cecum, 575
in chronic intestinal stasis, 613
Ileum, anatomy, 624
Ileus, paralytic, 552
pituitrin in, 553
Ilio inguinal abdominal section, 510
Imbecility, congenital, 103
Imbedded tonsils, 216
Immature cataract, intracapsular extraction, 171
preliminary capsulotomy for, 168
Impacted cerumen in external auditory canal, 305
Implantation, muscle, in empyema, 411
Incompetent ileocecal valve, 614
Incomplete tonsillectomy, 213
Incus, 299
Infancy, pyloric stenosis of, 717
Infections, extradural, 65
of abdominal wall, 536
of intestinal canal, 569
of mediastinum, 444
of scalp, 23
of temporal bone, intracranial complications of, 318
Infective diseases of cranial bones, 41
processes in neck, 361
thrombosis of venous sinuses of dura mater, 71
Inflammations of brain, 73
of chest wall, 398
of conjunctiva, 121. See also *Conjunctivitis.*
of esophagus, 432
of face, 115
of lacrimal gland, 136
of lips, 246
of mouth, 246
of nipple, 473
of omentum, 620
of stomach, 702. See also *Gastritis.*
of thyroid gland, 380
Inguinal abscess in Pott's disease, 337
colostomy, left, 686
sigmoidostomy, 685
high, 689
low, 690
Inion, 45
Injuries, general, of neck, 360
of brain, 63
of choroid, 130
of head, treatment, 17
of intracranial nerves, 63
of larynx, 219
of meningeal sinuses, 64

Injuries of nose, 183
of peritoneum, 542
of spleen, 784
of tongue, 287
of trachea, 219
Inoperable abdominal carcinoma, 706
Insanity, 102
cases demanding operation, 103
congenital, 103
primary traumatic, 102
surgical treatment, 104
Insects, bites of, on mouth, 247
Instruments for operations on eye, 138
on nose, 180
leaving in abdomen in operations, prevention, 516
Insufflation of air in hydrothorax, 402
of lungs, 446
apparatus for, 447
Intercostal artery, wounds of, 398
thoracotomy, simple, in empyema, 403
Interintestinal adhesions in abdominal operations, 523
Intermuscular temporal craniotomy, 36
Internal angular process of supra-orbital arch, 46
sclerotomy, 157
Interpleural pneumolysis in tuberculosis, 418
Interrupted intestinal suture, 628
Interstitial keratitis, 127
mastitis, chronic, 474
Intestinal anastomosis, 646
by circular occlusion method, 658
by clamp method, 676
by lateral implantation, 665
by simple invagination, 661
end-to-end, by invagination method, 654
of segments of unequal size, 656
simple, 647
with mattress sutures, 651
end-to-side, 665
invagination method, with ring or bobbin, 658
knitting needles for, 677
lateral, 661, 663
button method, 671
forming blind end in, 662
technic, 663
rubber ligature method, 675
with absorbable devices, 675
with button, 667
with knitting needles, 677
with mechanical devices, 666
with segmented ring, 674
canal, infections of, 569
exclusion, 677
fistula, closure of, 616
permanent, in lower small intestine, 685
temporary, 683
obstruction, 595, 599
acute, 595
enterostomy for, 685
angulation in, 600
at ileocecal valve, 602
chronic, 610
Intestinal obstruction, desperate cases, 597
from adhesions, 600
from diverticula, 603
from foreign bodies, 608
from gall-stones, 608
from gangrene, 609
from intussusception, 604
from pericolic adhesions, 602
from strangulation by bands, 599
from stricture, 609
from volvulus, 608
in peritonitis, 553
operation in, 595
after-treatment, 598
preparations for, 595
operations, instruments for, 626
feeding after, 778
resection, 636
anastomosis after, 639
indications for, 639
sinus, closure of, 616
stasis, acute, 614
chronic, 610
colostomy for, 574
dietetic treatment, 611
ileocolostomy in, 613
Kellogg's treatment, 610
kinks from, 611
Lane's treatment, 614
vaccines in, 611
operation in, 611
suture, 628
continuous, 628
interrupted, 628
mattress interlocking stitch, 636
methods, 628
mucosa, 635
needles for, 627
omental grafts in, 629
parallel continuous stitch, 631
purse-string, 35
right-angle mattress stitch, 633
seromuscular, 629
mattress stitch, 633
simple right-angle stitch, 631
sterilization of mucous membrane in 630
toxemia, chronic, 610
wall, cysts of, 582
Intestines, actinomycosis of, 575
adenoma of, polypoid, 582
anatomy, 621
cancer of, 583, 588
contusions of, 565
diverticula of, 603
inflammation of, acute phlegmonous, 574
irrigation of, indications for, 571
large, anatomy, 624
surface topography, 625
lumen of, closure of, 681
by purse-string suture, 681
transverse, 682
operations on, 621
perforation of, 576
malignant, 581
of gaseous cysts, 581
suppurative, 581
prolapse of, 616

Intestines, rupture of, 566
sarcoma of, 583
strangulation by bands, 599
submuscularis-mucous-membrane occlusion of, 682
suture of, 628. See also *Intestinal suture.*
tubercular perforation of, 581
tuberculosis of, 574
tumors of, 582
ulcers of, 576
wounds of, non-perforating, with wounds of mesentery, 568
perforating, 567
suturing, 635
Intra-abdominal hemorrhage, postoperative, 524
Intracanalicular myxoma of breast, 475
Intracapsular extraction of immature cataract, 171
Intracranial abscess of otic origin, 317
complications of infections of temporal bone, 318
diseases, 42
hemorrhage, 54
in newborn, 60
craniotomy in, 61
injuries, 42
nerves, injuries of, 63
operations on fifth nerve, 105
for neuralgia, 115
on seventh nerve, 110. See also *Seventh nerve.*
structures, wounds of, 61
Intranasal treatment of sinus infections, 201
Intra-ocular edema of optic nerve, 135
Intrapulmonary pressure, increased for operations through mediastina and pleuræ, 446
Intraspinal tumors, 338
Intrathoracic goiter, 446
Intravenous injections of glucose in glaucoma, 132
Intubation of larynx, 237
indications for, 237
instruments for, 237
postoperative care, 239
technic, 238
Intussusception, 604
irreducible, 605
gangrenous, 607
non-gangrenous, 605
reducible, 605
resection in, 607
Invagination method of end-to-end intestinal anastomosis, 654
of segments of unequal size, 656
of intestinal anastomosis, simple, 661
with ring or bobbin, 658
Inversion of eyelids, operations for, 143
Inverted nipple, 472
Iodin in peritonitis, 550
Ipecac in amebic colitis, 570
Iridectomy, 154
combined with sclerotomy, 157
in glaucoma, 131, 161
Iridectomy with cataract extraction, 166
without cataract extraction, 165
Iridodialysis, 129
Iridotomy, 155
V-shaped, Ziegler's 156
Iris, adhesions of, to cornea, 156
diseases of, 129
extrusion of, 121
operations on, 154
tumors of, 129
wounds of, 129
Iritis, 129
diabetic, 129
gonorrheal, 129
gouty, 129
rheumatic, 129
syphilitic, 129
Iritoëctomy, 155
Iron foreign bodies in interior of eyeball, removal of, 160
Ironing for stiff neck, 373
Irrigation in peritonitis, 549

Jacket, plaster-of-Paris, in Pott's disease, 329, 335
Jackson's instruments for tracheoscopy and bronchoscopy, 239
method of direct laryngoscopy, 240
of superior bronchoscopy, 242
operation in cancer of breast, 490
Janeway's method of gastrostomy with external flap, 731
Jaundice, hemolytic, 785
Jaws, 280
cysts of, 286
defective occlusion of, 281
deformities of, 280
enchondroma of, 286
fibroma of, 286
lower, deformities of, with defective occlusion, 283
division of, excision of tongue for carcinoma after, 297
underdeveloped, 280
malocclusion of, with prognathism, 283
necrosis of, 286
odontoma of, 286
osteoma of, 286
osteomyelitis of, 283
periostitis of, 283
sarcoma of, 286
myeloid, 286
peripheral, 286
tumors of, 286
Jejunal ulcer, 580
Jejunostomy, 695
for duodenal ulcer, 578
indications for, 696
Jejunum, anatomy, 624
Jianu's method of gastro-esophagoplasty, 465
Joints, spinal, sprains of, 324
Jugular glands, internal, 363
vein, internal, wounds of, 360
Jury-mast in Pott's disease, 333

Kader's method of gastrostomy, 734
Kellogg's treatment of chronic intestinal stasis, 610

Keloids of scalp, 24
Kenyon's method of craniotomy by osteoplastic flap method, 38
Keratitis, 124
bullosa, 127
herpetic, 127
hypopyon, 126
interstitial, 127
neuroparalytic, 126
operation for, 152
phlyctenular, 125
vascular, 127
with pus in anterior chamber, 126
xerotic, 127
Keratoconjunctivitis, nodular lymphatic, 125
Keratoconus, operations for, 153
Keratosis obturans in external auditory canal, 306
of nasopharynx, 208
Killian's instruments for tracheoscopy and bronchoscopy, 239
operation for obliteration of frontal sinus, 202–205
Klebs-Löffler membranous pharyngitis, 207
Knapp's expression operation in trachoma, 150
method of cataract extraction, 171
operation for pterygium, 150
for staphyloma, 152
in secondary cataract, 174
Knitting needles for intestinal anastomosis, 677
Kocher's method of excision of tongue for carcinoma, 297
of gastroduodenostomy, 747
Körner's method in radical mastoid operation, 314
Krause's knife for operations on pituitary body, 87
Kredel's metal bobbins for scalp operations, 21
Krönlein's method of approach to pancreas, 779
of cerebral localization, 50
Kuhnt-Szymanowski operation for ectropion, 145
Kyphosis, 351

Labyrinthine disease, 319
radical mastoid operation in, 314
hemorrhage, 319
involvement following middle-ear suppuration, 320
Lacerated wounds of spleen, 784
Lacrimal apparatus, diseases of, 136
operations on, 177
canals, atresia of, 136
enlargement of, 177
gland, fistula of, 136
hypertrophy of, 136
inflammation of, 136
prolapse of, 136
removal of, 137, 178
of palpebral portion, 178
tumors of, 136
sac, endonasal operations on, 178
excision of, 178
Lacrimal sac, fistula of, 136
removal of, 136
sounds, 177
Lactation mastitis, 473
Lagophthalmos, 120
Lagrange's method of combined iridectomy and sclerotomy, 157
Lambda, 45
Lambdoid suture, 46
Lambotte's method of drainage in ascites, 559
Laminectomy, 339
for paralysis in Pott's disease, 337
in medullary tumors of spinal cord, 341
indications for, 339
lumbar, in meningitis, 70
osteoplastic, 344
postoperative case, 343
results, 343
Lane's operation for cleft palate, 261
treatment of chronic intestinal stasis, 614
Laryngeal cartilages, dislocations of, 220
nerve, recurrent, anatomy, 380
Laryngectomy, after-treatment, 236
exceptional conditions in, 234
one-stage, 231
partial, 231
phonation after, 236
total, 231
two-stage, 235
Laryngismus stridulus, 221
Laryngitis, acute catarrhal, 220
chronic, 222
dry, 222
hypertrophic subglottic, 219
membranous, 221
stridulous, 221
Laryngoscopy, direct, 240
Laryngotomy, median, 230
transverse, 230
Laryngotracheotomy, 227, 230
Larynx, 217
acquired stenosis of, 218
anatomy, 217
artificial, Glück's, 236
burns of, 219
cancer of, 223
congenital stenosis of, 218
contusions of, 219
examination, 217
foreign bodies in, 224
fractures of, 219
hemorrhage from, 223
inflammation, of, 220
injuries of, 219
intubation of, 237. See also *Intubation of larynx.*
malformations of, 218
operations on, 217, 226
removal of foreign bodies from, 244
spasm of, 221
syphilis of, 223
treatment, 217
tuberculosis of, 222
tumors of, 223
wounds of, 220
Lateral curvature of spine, 352. See also *Scoliosis.*

Lateral implantation method of intestinal anastomosis, 665
intestinal anastomosis, 661, 663
button method, 671
forming blind end in, 662
technic, 663
sinuses of brain, 47
tarsorrhaphy, 143
ventricle of brain, 48
Lavage, duodenal, 701
gastric, 700
continuous, 701
contraindications, 701
in peritonitis, 547, 550
indications for, 701
method, 701
Laxative enemata, 620
Left inguinal colostomy, 686
Lembert's simple right-angle stitch in intestinal suture, 631
Lenhartz's treatment of ulcer of stomach, 721
Lens, crystalline, diseases of, 132
dislocation of, 134
extraction of, without incision of capsule, in cataract, 170
foreign bodies in, 133
Leontiasis ossea, 41
Leprosy of tongue, 290
Leptomeningitis, 65
Leukemia, 786
Leukocythemic retinitis, 134
Leukoplakia of tongue, 289
Lewisohn's telescoping esophagoscope, 243
Ligaments of spine, relaxation of, 357
sprains of, 357
Ligation of middle meningeal artery in extradural hemorrhage, 56
of ophthalmic artery, 137
of pulmonary artery in bronchiectasis, 420
of thyroid gland, 393
Ligneous induration of neck, 362
Line, naso-inial, 46
nasolambdoidal, 45
Sylvian, 46
Linear extraction of cataract, 170
Lingual tonsil, diseases of, 290
Linitis, plastic, 702
Lip, lower, epithelioma of, excision of lip for, 252
incomplete operation for, 250
operations for, 247–254
resection of lip for, 251
notched-, operation for, 273
Lipoma of abdominal wall, 538
of brain, 75
of breast, 475
of epigastrium, 538
of peritoneum, 563
of scalp, 24
of stomach, 703
Lips, angioma of, 254
cellulitis of, 246
chapped, 246
cystoma of, 254
fissure of, 246
Lips, herpes of, 246
horny elevations of, 254
inflammations of, 246
permanent enlargement of, 255
tumors of, benign, 254
ulcers of, 246
wounds of, 246
Liver, nutmeg, ascites in, 558
Lobule of auricle, cleft, 303
Local anesthesia in endolaryngeal operations, 218
in nasal operations, 181
Localization, cerebral, Krönlein's method, 50
craniocerebral, 48
Chipault's method, 48, 49
Reid's method, 49
Lordosis, 352
Lorenz's reclining plaster-bed in Pott's disease, 327
Loreta's method of pylorodiosis, 737
Lothrop's operation in empyema of frontal sinuses, 199
Low inguinal sigmoidostomy, 690
tracheotomy 228
Lower bronchoscopy, 243
jaw, underdeveloped, 280
lip, epithelioma of, excision of lip for, 252
incomplete operation for, 250
operations for, 247–254
resection of lip for, 251
Ludwig's angina, 362
Lumbago, 350
Lumbar abscess in Pott's disease, 337
colostomy, 695
laminectomy in meningitis, 70
puncture, dangers of, in brain tumors, 77
in brain operations, 51
in epidemic cerebrospinal meningitis, 67
in non-infective meningeal effusion, 68
in tuberculous meningitis, 68
Lumbosacral pain, 350
Lungs, 413
abscess of, acute, 414
chronic, 415
rupturing into bronchus, 415
cysts of, echinococcus, 445
decortication of, in chronic non-tuberculous empyema, 410
gangrene of, 415
insufflation of, 446
apparatus for, 447
operations on, 453
operative exposure of, 453
in two stages, 456
of apex, 456
resection of, in tuberculosis, 416
rupture of, 413
tuberculosis of, 416. See also *Tuberculosis.*
tumors of, 445
wounds of, suturing of, 414
with penetration of chest wall, 413
with pleural infection, 414
Lupus of pharynx, 207

Lymphatic cysts of neck, 372
nodular keratoconjunctivitis, 125
Lymphatics of axilla, 472
of breast, 472
of neck, anatomy of 363
carcinoma of, 363
diseases of, 363
of stomach, 699
Lymph-glands of neck, tuberculous, 368
non-surgical treatment, 369
operation for, 370
Lymphoma of neck, malignant, 372

MACROCHEILIA, 255
Macroglossia, 290
Malarial hypertrophy of spleen, 785
Malformations of auricle, 303
of larynx, 218
of nasal septum, 188
of trachea, 218
Malignant glaucoma, 132
tumors. See *Cancer.*
Malleus, 299
Malocclusion of jaws with prognathism, 283
of lower jaw, 281
Malposition of puncta lacrimalia, 136
Mammary artery, internal, wounds of, 398
Massage, cardiac, for syncope, 430
in coccygodynia, 358
Mastitis, acute, 473
chronic, 474
cystic, 474
of male breast, 497
interstitial, chronic, 474
lactation, 473
stagnation, 473
Mastoid antrum, 299
cells, 299
operation, 316, 317
first change of dressing, 318
indications for, in acute otitis media, 308
on babies, 318
radical, 312
in labyrinthine disease, 314
indications for, in chronic suppurative otitis media, 311
Körner's method, 314
Panse's method in, 315
technic, 312
Mastoiditis, acute, operation for, 317
chronic, operation for, 316
radical, 312. See also *Mastoid operation, radical.*
Mattress sutures, end-to-end intestinal anastomosis with, 651
Maunsell's invagination method of end-to-end intestinal anastomosis, 654
Maxilla, inferior, condyloid point of, 45
Maxillary antrum, acute catarrhal inflammation of, 195
chronic catarrhal inflammation of, 195
drainage of, 195
empyema of, 195
foreign bodies in, 197
Maxillary antrum, free opening of, 196
mouth and, closure of sinuses between, 197
obliteration of, 196
tumors of, 197
sinus, 179
Mayer's operation in osteomyelitis of spine, 326
Mayo's method of posterior gastro-enterostomy, 767
McBurney's intramuscular gridiron incision for abdominal section, 510
point, 510
McGraw's rubber ligature method of intestinal anastomosis, 675
Meatus, inferior, of nose, 179
middle, of nose, 179
superior, of nose, 179
Median abdominal section, 510
low, by superficial transverse incision, 513
fistulæ of neck, 372
laryngotomy, 230
tarsorrhaphy, 143
Mediastina, 444
exposure of, anterior, 458
by median division of sternum, 459
posterior, 459
operations on, 458
with increased intrapulmonary pressure, 446
Mediastinotomy, cervical, in esophageal abscess, 433
Mediastinum, abscess of, 444
anterior, 458
infections of, 444
middle, 458
posterior, 458
superior, 458
tumors of, 446
Medullary tumors of spinal cord, extrusion treatment, 342
laminectomy in, 341
Megacolon, 614
Meibomian cyst, 120
Meltzer's method of insufflation of lungs, 447
Membrane, tympanic, 299
operations through, in chronic otitis media, 311
wounds of, 301
Membranous laryngitis, 221
pericolitis, 602
pharyngitis, Klebs-Löffler, 207
rhinitis, 186
stomatitis, 247
tonsillitis, 212
Ménière's disease, 319
Meningeal artery middle, 47
ligation of, in extradural hemorrhage, 56
effusion, non-infective, 68
sinuses, injuries of, 64
Meninges, diseases of, 65
tumors of, 75
wounds of, 61
Meningitis after brain operations, hexamethylenamin to prevent, 52

Meningitis, epidemic cerebrospinal, 67
carriers in, 67
Flexner's treatment, 67
lumbar puncture in, 67
lumbar laminectomy in, 70
of otic origin, 66
operative treatment, 69
subdural, 65
pyogenic organisms in, 66
syphilitic, 68
tuberculous, 68
Meningocele, 92, 349
spurious, 25
Mercurial ulcers of tongue, 290
Mercury for dilatation of esophageal stricture, 435
Mesenteric blood-cysts, 564
cysts, 564
triangle, 625
tumors, 563, 564
vein, superior, anastomosis of, with vena cava, in ascites, 563
vessels, stoppage of, gangrene of intestines from, 609
Mesentery, long, chronic intestinal obstruction from, 610
wounds of, 568
non-perforating wounds of intestine with, 568
Mesocolon, elongated, 616
transverse, involvement of, in gastric cancer, 705
Metallic braces in Pott's disease, 333
Meteorism after abdominal operations, 532
Meyer's method of resection of cardiac end of stomach, 758
operation in cardiospasm, 716
pneumatic cabinet for negative and positive pressure in thoracic surgery, 451
transverse abdominal incision, 508
Micrococcus catarrhalis vaccines in ozena, 188
Middle ear, 306
curettage of, in chronic suppurative otitis media, 311
inflammation of, acute, 306. See also *Otitis media, acute.*
Midsagittal point, 45
Midzygomatic point, 45
Mikulicz's gauze envelop drain in abdominal operations, 526
method of pyloroplasty, 740
Milk and molasses enema, 620
fistula, 474
Milliner's needle for intestinal suture, 627
Miotics, use of, 118
Mixed enema, 620
Molasses and milk enema, 620
Moles of face, 115
Monocular cataract, 133
Morphin after abdominal operations, 531
Motais' operation for ptosis of eyelids, 142
Motor area of brain cortex, anatomy, 44
electric reaction of, testing for, 51
Mouth, 244
examination of, 245
hemostasis in, 245
hygiene of, 245
inflammations of, 246
insect bites on, 247
maxillary antrum and, closure of sinuses between, 197
operations on, anesthesia in, 245
Mouth-gag, 245
Moynihan's angular clamp for pyloroplasty, 747
method in intestinal suture, 628
Mucocele of maxillary antrum, 197
Mucosa suture of intestine, 635
Murphy's button method of intestinal anastomosis, 667
Muscæ volitantes, 134
Muscle implantation in empyema, 411
Muscles of eye, 116
disorders of, 135
operations on, 174
paralysis of, 135
Mycosis of external auditory canal, 304
of nasopharynx, 208
of tonsils, 212
Mycotic stomatit s, 246
Mydriatics in glaucoma, 118
use of, 117
Myelocystocele, 349
Myeloid sarcoma of gums, 280
of jaws, 286
Myelomeningocele, 349
Myoma of stomach, 703
Myxoma of brain, 75
of breast, intracanalicular, 475

Nasal cartilage, transplanting of, 192
cavities, infections of, 186
duct, occlusion of, 136
infections, specific, 188
septum, 179
anatomy, 89
deflections of, 188
forceps, 191
malformations of, 188
perforation of, 195
submucous resection of, 190
speculum, 181
splints, 180
synechia, 195
Nasion, 45
Naso-inial line, 46
Nasolambdoidal line, 45
Nasopharyngitis, hyperplastic, 205
syphilitic, 205
Nasopharynx, actinomycosis of, 208
adenoids of, 208. See also *Adenoids.*
exposure of, 216
fibromata of, 208
glanders of, 208
herpes of, 208
keratosis of, 208
mycosis of, 208
operations on, 205
tumors of, 208
Nausen after abdominal operations, 531
Neck, 360

Neck, abscess of, 361
branchial cysts of, 372
fistulæ of, 372
burns of, 373
bursal cysts of, 372
cancer of, extensive recurrent, 494
secondary, 372
cellulitis of, 361
superficial, 362
congenital cysts of, 372
cysts of, 372
echinococcus cysts of, 372
emphysema of, 361
general injuries of, 360
hemorrhagic cysts of, 372
infective processes in, 361
ligneous induration of, 362
lymphatic cysts of, 372
lymphatics of, anatomy of, 363
carcinoma of, 363
diseases of, 363
lymphoma of, malignant, 372
median fistulæ of, 372
nerves of, wounds of, 360
stiff, ironing for, 373
tuberculous lymph-glands of, 368
non-surgical treatment, 369
technic of operation for, 370
tumors of, 372
solid, 372
Necrosis of costal cartilages, 398
of jaws, 286
of pancreas, 782
of ribs, 398
Needle operation for cataract, 169
Needles used for intestinal suture, 627
Nephritic retinitis, 134
Nerves, intracranial injuries of, 63
of neck, wounds of, 360
of stomach, 700
optic, diseases of, 135
recurrent laryngeal, anatomy, 380
roots, relation of, to spine, 323
spinal accessory, resection of, in torticollis, 376
posterior roots of, division of, 344. See also *Rhizotomy*.
operations on, 344
Neumann's operation in middle-ear disease with labyrinthine involvement, 321
Neuralgia, coccygeal, 357
alcohol injections in, 358
massage in, 358
removal of coccyx for, 358
facial, intracranial operations on fifth nerve for, 115
of breast, 473
rhizotomy for, 346
Neurasthenia, surgical treatment, 105
traumatic, 103
Neurectomy, phrenic, in bronchiectasis, 420
Neuritis, orbital optic, 135
Neurofibromatosis, multiple, of scalp, 24
Neuroparalytic keratitis, 126
Neuroses, posttraumatic, 102
surgical treatment, 105
Neurotic spine, 355
Nevus of abdominal wall, 538
of breast, 475
of face, 115
of scalp, 25
Newborn, heart failure of, 430
intracranial hemorrhage in, 60
craniotomy in, 61
Nicoladoni's method in salivary fistula, 378
Nipples, diseases of, 473
eczema of, 473
fissures of, 473
inflammations of, 473
inverted, 472
retracted, 473
tumors of, 473
Nodular lymphatic keratoconjunctivitis, 125
Nodules of tongue, tuberculous, 290
singers', 222
Non-gonorrheal conjunctivitis, 122
Non-infective meningeal effusion, 68
thrombosis of sinuses of dura mater, 72
Non-penetrating wounds of abdominal wall, 535
of chest wall, 397
Non-perforating wounds of intestine, with wounds of mesentery, 568
Non-specific purulent conjunctivitis, 121
Non-suppurative otitis media, chronic, 319
peritonitis, acute, 554
Non-tuberculous empyema, chronic, 409
rarefying osteitis of spine, 326
Nose, 179
accessory sinuses of, 179
anatomy of, 179
bleeding from, 184
blowing of, in nasal infections, 186
cavities of, infections of, 180
foreign bodies in, 188
hemorrhage from, 184
infections of, blowing nose in, 186
inferior meatus of, 179
injuries of, 183
middle meatus of, 179
operations on, 179
anesthesia in, 181
antiseptic preparations in, 183
cleansing preparations in, 183
hemostasis in, 183
instruments for, 180
local anesthesia in, 181
vasoconstriction in, 183
saddle-. See *Saddle-nose*.
scab formation in, 187
septum, 179
superior meatus, 179
tumors of, 188
wounds of, 183
Nostril, deformed, with harelip, 273
Notched-lip, after operation for harelip, 273
Nutmeg liver in ascites, 558
Nutrient enemata, 620

Oblique postmuscular abdominal section, 511
subcostal abdominal section, 513

Obliteration of frontal sinus, 202–205
of maxillary antrum, 196
Obstruction of intestines, 595. See also *Intestinal obstruction.*
Occipital glands, 363
Occlusion, defective, deformities of lower jaw with, 283
of jaws, 281
of duodenum, 615
of nasal duct, 136
Ochsner's method in stricture of esophagus, 436
treatment of peritonitis, 548
Ocular torticollis, 377
Odontoma, 280
of jaws, 286
O'Dwyer instruments for intubating larynx, 237
method of intubating larynx, 237
Oil enema, 620
Olfactory sensory center of brain, 45
Olive bougies, 434
oil to prevent adhesions in abdominal operations, 521
Omental grafts in intestinal suture, 629
Omentum, 620
adhesions of, in abdominal operations, 522
cysts of, 620
inflammations of, 620
preservation of, in resection of transverse colon, 646
strangulation of, 620
torsion of, 620
tumors of, 620
Opacities, corneal, 126
in vitreous, 134
Operations on conjunctiva, 149
on eye, 138
on eyelids, 138
on intestines, 621
on lungs, 453
on mediastina, 458
on nose, 179
on pharynx through neck, 367
on skull. See *Skull, operations on.*
on spleen, 787
on stomach, 730
on tonsils through neck, 367
Operative wounds of scalp, 19
Ophthalmia. See *Conjunctivitis.*
sympathetic, 130
Ophthalmic artery, ligation of, 137
Opium in peritonitis, 547
Optic nerve, atrophy of, 135
diseases of, 135
intra-ocular edema of, 135
tumors of, 135
wounds of, 135
neuritis, orbital, 135
papilla, engorgement edema of, 135
Orbicularis muscle, spasm of, 120
Orbit, abscess of, 137
diseases of, 137
outer wall of, resection of, 163
periostitis of, 137
sinus infections perforating into, 201
transplantation of fat into, after enucleation, 160
Orbit, tumors of, 137
removal, 163
Orbital muscles, 116. See also *Muscles of eye.*
optic neuritis, 135
Organic scoliosis, 354
Orthodentistry, 280
Osmosis treatment of glaucoma, 131
Ossicles of ear, 299
removal of, in chronic suppurative otitis media, 311
Osteitis of cranial bones, prevention, 41
of spine, non-tuberculous rarefying, 326
Osteoma of jaws, 286
of skull, 42
Osteomyelitis of jaws, 283
of spine, 326
Osteoplastic craniotomy, 30. See also *Craniotomy, osteoplastic.*
laminectomy, 344
thoracotomy, anterior, 458
posterior, 459
Osteotome, spiral, Cryer's, 28
Othematoma, 303
Otic abscess, usual site, 50
Otitis media, acute, 306
incision of tympanic membrane in, 307
indications for mastoid operation in, 308
suppurative, 307
chronic non-suppurative, 319
labyrinthine and perilabyrinthine involvement following, 321
suppurative, 308
bismuth paste in, 310
curettage of middle ear in, 311
drying powders in, 309
ear-drops in, 309
gauze drainage in, 309
hot air in, 309
operation in, indications for, 310
radical, 312. See also *Mastoid operation, radical.*
through membrana tympani in, 311
removal of ossicles in, 311
suction treatment, 310
vaccines in, 310
Oxycephaly, 42
Oxygen after abdominal operations, 531
Ozena, 187

Pachymeningitis externa, 65
hemorrhagica, 57
syphilitic, 65
Paget's disease of nipples, 473
Pain after abdominal operations, 532
lumbosacral, 350
Painful back, 350
Palate, cleft-, 257. See also *Cleft-palate.*
perforations of, 266
soft, abscess of, 255
acute infections of, 255
adhesions of, 256
diseases of, 255
tumors of, 255
ulcers of, 255

Palpebral fissure, canthoplasty for enlarging, 142
portion of lacrimal gland, removal of, 178
Panas' operation for ptosis of eyelids, 141
for staphyloma, 152
Pancreas, 778
abscess of, 781
anatomy, 778
approach to, 779
cysts of 783
drainage of, 780
necrosis of, 782
tumors of, 782
wounds of, 779
Pancreatic calculi, 783
Pancreatitis, acute, 780
chronic, 781
subacute, 781
Pannus, 124
Panophthalmitis, 130
Panse's method in radical mastoid operation, 315
Papilla optic, engorgement edema of, 135
Papillomatous cysts of breast, 477
Paracentesis of cornea, 152
of right auricle, 425
ventricle, 425
Paraffin injections in saddle-nose, 194
Paralysis agitans, rhizotomy for, 348
in Pott's disease, 337
spastic, rhizotomy in, 346
Paralytic ileus, 552
pituitrin in, 553
torticollis, 377
Parasitic stomatitis, 246
Parathyreopriva, 394
Parathyroid glands, anatomy, 380
diseases of, 394
transplantation of, 394
Parenchymatous acute glossitis, 288
senile hypertrophy of breast, 475
Parotid glands, 363
abscess of, 379
anatomy, 377
cellulitis of, 379
salivary fistula, 377
Pars anterior of pituitary body, 83
intermedia of pituitary body, 83
nervosa of pituitary body, 83
Partial cataract, 133
laryngectomy, 231
Patient, preparation of, for abdominal operations, 499
for operations on alimentary canal, 564
Pendulous abdominal wall, 540
Penetrating wounds of abdominal wall, 535
of chest wall, 397
of esophagus, 431
of heart, 429
Penetration of chest wall, wounds of lung with, 413
Percy's radical cautery operation for cancer of breast, 492
Perforating duodenal ulcer, 579
typhoid ulcer, 580
ulcer of stomach, 726
wounds of intestines, 567
Perforation of colon, 582
of gaseous cysts, 581
of intestines, 581
of intestines, 576
malignant, 581
suppurative, 581
tuberculous, 581
of nasal septum, 195
of palate, 266
of stomach, perigastric abscess from, 727
Pericardial adhesions, cardiolysis for, 424
Pericardiocentesis, 422
Pericardium, 422
empyema of, 423
operative exposure, 424
serous effusion in, 422
tumors of, 445
wounds of, 422
Pericardotomy for serous effusion, 423
in empyema, 423
Perichondritis, 223
of auricle, 303
Pericolic adhesions, 602
veils, 602
Pericolitis, 576
membranous, 602
Pericranial pneumatocele, 24
Périer's method of laryngectomy, 234
Perigastric abscess from perforation of stomach, 727
adhesions, 702
Perilabyrinthine involvement following middle-ear suppuration, 320
Periostitis of cranial bones, prevention, 41
of jaws, 283
of orbit, 137
Periotomy in vascular keratitis, 127
Peripheral sarcoma of jaws, 286
Peritoneal abscess, chronic, 554
collapse, 549
sac, foreign bodies in, 544
Peritoneum, 498, 541
anastomosis of saphenous vein with, in ascites, 560
anatomy, 541
closure of, in abdominal operations, 516
denuded surfaces of, 542
fibroma of, 563
injuries of, 542
lipoma of, 563
protection of, in abdominal operations, 515
sarcoma of, 564
toilet of, in abdominal operations, 515
traumatism of, 542
tumors of, 557
Peritonitis, 546
acute, 546
general, 548
local, 548
non-suppurative, 554
septic, 548
adhesions in, 546
best time for operation in, 546
calcium hypochlorite in, 551
camphorated oil in, 551
chlorinated oil in, 551

Peritonitis, dichloramin in, 551
drainage in, 547, 549
gastric lavage in, 547, 550
hypodermoclysis in, 550
intestinal obstruction in, 553
iodin in, 550
irrigation in, 546, 549
local suppurative, 548
localized abscess in, 553
of duodenal region, 557
operation in, 549
opium in, 547
period of constitutional reaction in, 547
prevention of spread, 546
proctoclysis in, 547
rectal injections in, 549
secondary abscess in, 553
sodium hypochlorite in, 551
subphrenic abscess in, 553
suction drainage in, 549
sulphuric ether in, 551
suppurative, local, 548
tuberculous, 554
acute miliary, 554
dry, 554
exudative, with serum, 554
suppurative, 556
vasomotor disturbance in, 549
Peritonsillar abscess, 212
Perityphlitis, 576
Permanent fecal fistula, 687
Pernicious anemia, 785
Peronin in eye diseases, 118
Peterson's method of drainage in ascites, 559
Pharyngitis, membranous, Klebs-Löffler, 207
Pharyngotomy, lateral, 368
subhyoid, 229
suprahyoid, 229
Pharynx, foreign bodies in, 216
lupus of, 207
operations on, through neck, 367
tuberculosis of, 207
Phlebotomy. See *Venesection.*
Phlegmon, sublingual, 362
woody, 362
Phlegmonous gastritis, 702
inflammation of intestines, acute, 574
Phlyctenular conjunctivitis, 123
keratitis, 125
Phonation after laryngectomy, 236
disturbed, after cleft-palate operation, 266
Phrenic neurectomy in bronchiectasis, 420
Physostigmin salicylate as miotic, 118
Pia mater, anatomy, 43
Pia-arachnoid anatomy, 43
wounds of, 61
Pilocarpin hydrochlorid as miotic, 118
Pinguecula, 124
Pituitary body, nasal approach to, 89
operations on, 82
anesthesia in, 83
approach by bucconasal route, 92
by frontal route, 85
by nasal route, 88
choice of, 83
Pituitary body, operations on, combined frontal and nasal, 90
high nasal, 90
nasal, with removal of septum, 88
routes of approach, 82
simple transnasal, 88
surgical anatomy, 83
total removal, 83
tumors of, 83
Pituitrin in acute intestinal stasis, 614
in paralytic ileus, 553
Plaster-bed, reclining, in Pott's disease, 327
Plaster-of-Paris jackets in Pott's disease, 329–335
Plastic linitis, 702
Pleth's knitting needle method of intestinal anastomosis, 677
Pleura, 399
anatomy, 399
cervical, 399
costal, 399
diaphragmatic, 399
infection of, with wounds of lung, 414
operations through, with increased intrapulmonary pressure, 446
pulmonary, 399
tumors of, 445
wounds of, 399
Pleural shock from artificial pneumothorax, 417
Pleurisy with effusion from artificial pneumothorax, 417
Plexiform neuroma of scalp, 24
Plug, epithelial, in external auditory canal, 306
Pneumatocele, pericranial, 24
Pneumectomy, 456
in bronchiectasis, 420
in tuberculosis, 416
Pneumolysia, interpleural, in tuberculosis, 418
Pneumolysis in bronchiectasis, 420
in tuberculosis, 418
Pneumonia after abdominal operations, 534
Pneumothorax, 400
artificial, gas embolism from, 417
in tuberculosis, 416
indications for, 417
length of treatment, 418
mortality in, 417
pleural infection from, 417
shock from, 417
pleurisy with effusion from, 417
results, 418
subcutaneous emphysema in, 417
Pneumotomy, 456
in bronchiectasis, 419
Point, auricular, 45
condyloid, of inferior maxilla, 45
midsagittal, 45
midzygomatic, 45
superior Rolandic, 46
supra-auricular, 45
Sylvian, 46
Poliomyelitis, anterior, 326
Politzer's bag for inflating middle ear, 301

Polymastia, 472
Polypoid adenomata of intestines, 582
Polyps of maxillary antrum, 197
Polythelia, 472
Pope's method of preventing adhesions in abdominal operations, 522
Portal vein, anastomosis of, with vena cava, in ascites, 561
Posterior cervical nerves, resection of, in torticollis, 376
  sclerotomy, 157
Postmeatal triangle of ear, 300
Postmuscular oblique abdominal section, 511
  vertical abdominal section, 512
Postoperative dilatation of stomach, 615
  intraabdominal hemorrhage, 524
  vomiting, 615
Posttraumatic neuroses, 102
Postural scoliosis, 352, 353
Pott's disease, 327
    abscess in, 335. See also *Abscess in Pott's disease.*
    after-treatment on recumbent frame, 334
    ambulatory treatment, 329
    Bradford's frame in, 328
    care of skin in, 334
    corset in, 334
    duration of treatment, 338
    head support in, 333
    horizontal fixation in, 327
    jacket applied in, for cervical and upper dorsal disease, 332
        high, 332
        suspension hammock in, 329
        with patient in prone position, 329
          on back, 331
          suspended, 331
    jury-mast in, 333
    Lorenz's reclining plaster-bed in, 328
    lumbar involvement in, 334
    metallic braces in, 333
    operations on bodies of vertebræ in, 337
    operative treatment, 338
    paralysis in, 337
    prognosis, 335
    recumbent treatment, 327
  puffy swelling of cranial bones, 41
Pressure-pad in gastroptosis, 711
Processus pyramidalis, 380
Proctoclysis after abdominal operations, 533
  in peritonitis, 547
Prognathism, 281
  with malocclusion, 283
Prolapse of intestines, 616
  of lacrimal gland, 136
  of spleen, 784
Psammoma of brain, 75
Pseudomembranous conjunctivitis, 123
Psoas abscess in Pott's disease, 337.
Psoriasis of tongue, 289
Psychoses, traumatic, 102
Pterygium, 124
  operations for, 149
Ptosis of eyelids, 119
Ptosis, of eyelids operations for, 138
  of hepatic flexure of colon, 616
  of splenic flexure of colon, 616
  of transverse colon, 616
  of upper eyelid, 120
Puffy swelling of cranial bones, 41
Pulmonary emphysema, rib resection in 419
  pleura, 399
Pulsating exophthalmos, 137
    in arteriovenous aneurism of cavernous sinus, 73
Puncta lacrimalia, malposition of, 136
Puncture, lumbar, 348. See *Lumbar puncture.*
Purse-string suture for closing lumen of intestines, 681
    of intestines, 635
Purulent non-specific conjunctivitis, 121
Pus in vitreous, 134
Pylorectomy, 747
  partial, 751
    gastrojejunostomy after, 755
  shock in, 776
Pyloric end of stomach, cancer of, operation for, 756
        resection of, 751
          gastrojejunostomy after, 755
  stenosis, 717
    acquired hypertrophic, 720
    cicatricial, 720
    congenital, 717
    indications for operation in, 719
    mortality from, 719
    of infancy, 717
    posterior gastro-enterostomy in, 719
    simple, pyloroplasty in, 740
    spasmodic, 720
  ulcer, ruptured, pyloroplasty in, 740
Pylorodiosis, 737
Pyloroplasty, 740
  angular clamp for, 747
  by single incision, 740
  feeding after, 778
  in duodenal ulcer, 578
  indications for, 740
  with gastroduodenostomy, 741
Pylorospasm, pyloroplasty in, 740
Pylorus, anatomy, 698
  carcinoma of, 720
  exclusion of, 771
  permanent occlusion of, in duodenal ulcer, 578
Pyorrhea alveolaris, 277
Pyothorax, 402. See also *Empyema.*

Quinin and urea injections in hyperthyroidism, 390
Quinsy, 212

Rachitic spine, 350
  torticollis, 377
Radical mastoid operation. See also *Mastoid operation, radical.*
Radium in hyperthyroidism, 390
Ranula, 291
Reaction, electric, of motor areas of brain, testing for, 51

Reading, brain center of, 44
Receptaculum chyli, septic infection of, 361
Rectal drainage in abdominal operations, 528
injections in appendicitis, 549
tube after abdominal operations, 531
Rectum, upper part, cancer of, 591
Rectus muscle, advancement of, 176
folding operation on, 176
internal, tenotomy of, in strabismus, 175
shortening of, 176
Recurrent laryngeal nerve, anatomy, 380
Redundant sigmoid, chronic intestinal stasis from, 612
Reid's method of craniocerebral localization, 49
Relaxation of ligaments of spine, 357
Relaxed abdominal wall, 540
Resection, double, in non-toxic goiter, 385
intestinal, 636
of ascending colon, indications for, 642
of cardia for cancer, 756
of cecum, indications for, 642
of colon, preventing obstruction to passage of gas in, 644
of costal cartilages in rigidity of chest, 422
in tuberculosis, 419
of esophagus, of lower segment, 470
of eyelids, blepharoplasty for, 147
of outer wall of orbit, 163
of part of lobe of thyroid gland, 389
of posterior cervical nerves in torticollis, 376
of pyloric end of stomach, 751
gastrojejunostomy after, 755
of spinal accessory nerve in torticollis, 376
of spleen, 787
of thoracic esophagus, 463
of trachea, 237
of transverse colon, with preservation of omentum, 646
of ulcer of stomach, 759
submucous, of nasal septum, 190
Retina, detachment of, 134
diseases of, 134
glioma of, 135
hemorrhage into, 135
Retinitis, 134
diabetic, 134
hemorrhagic, 134
leucocythemic, 134
nephritic, 134
syphilitic, 134
Retracted nipples, 473
Retractors for abdominal operations, 514, 515
Retro-auricular glands, 363
Retro-omental route of approach to pancreas, 779
Retro-orbital tubercle, 46
Retroperitoneal abscess, 563
cysts, 564
disease, 563
Retroperitoneal infection 563
umors, 563
R tropharyngeal abscess, 205
in Pott's disease, 335
glands, 363
Rheumatic iritis, 129
torticollis, 377
Rhinitis, acute simple, 186
in children, 186
atrophic, 187
chronic, 186
simple, 186
hyperplastic, 187
membranous, 186
suction treatment, 186
Rhinoliths, 188
Rhinophyma, 188
Rhinorrhea, cerebrospinal, 73
Rhizotomy, 344
in gastric crises of tabes 347
in neuralgia, 346
in spastic paralysis, 346
Ribs, caries of, 398
cervical, 373
necrosis of, 398
resection, in pulmonary emphysema, 419
syphilis of, 398
tuberculosis of, 398
Rib-trephining for empyema, 407
Richardson's double figure-of-eight suture, 519
Ridge, superciliary, 46
of supra-orbital arch, 46
Riggs' disease, 277
Rigidity of chest, 421
Ripening, artificial, in cataract, 133
Robinson's apparatus for intratracheal insufflation, 450
method of thoracoplasty, 410
muscle implantation in empyema, 411
Robson's decalcified bone bobbin for intestinal anastomosis, 675
technic for jejunostomy, 697
Rogers' laryngeal intubation tube, 220
Rolandic fissure, 46
lower end, 46
point, superior, 46
Roller forceps operation in trachoma, 150
Root infections of teeth, 275
Rosenstein's method of drainage in ascites, 561
Round shoulders, 351
Routte's method of drainage in ascites, 560
Roux's method of anterior gastrojejunostomy, 771
of esophagogastrojejunostomy, 464
Rovsing's method of gastropexy, 713
Rubber ligature method of intestinal anastomosis, 675
Running ear, 310
Rupture of abdominal muscles, 535
of choroid, 131
of esophagus, 432
of intestines, 566
of lung, 413
of spleen, 784
of stomach, 702

Rupture of thoracic duct in abdomen, 361
in thorax, 361
traumatic, of tympanic membrane, 306
ulcerative, of tympanic membrane, 306
Ruth's operation in cancer of breast, 489
Rydygier's method of splenopexy, 787

SAC, lacrimal. See *Lacrimal sac.*
Sacro-iliac joint, diseases of, 355
tuberculosis of, 355
Saddle-nose, 192
hard-rubber bridge in, 194
paraffin injections in, 194
swinging up half of lateral cartilage in, 193
Safety-pin hemostat, Friedman's, in scalp operations, 20, 22
Sagittal suture, 46
Salivary calculi, 291, 379
fistula, parotid, 377
glands, 377
tumors of, 379
Saphenous vein, anastomosis of, with peritoneum, in ascites, 560
Sarcoma of abdominal wall, 538
of gums, 280
myeloid, 280
of intestines, 583
of jaws, 286
myeloid, 286
peripheral, 286
of peritoneum, 564
of skull, 42
of stomach, 703
of thyroid gland, 381
formation in nose, 187
Scalp, 17
abscess of, 24
accidental wounds of, 18
avulsion of, 23
complete, 23
cellulitis of, 23
contusions of, 17
erysipelas of, 24
hematoma of, 17
infections of, 23
preparation of, for operation, 19
tumors of, 24
wounds of, control of hemorrhage in, 18
infection in, 18
operative, 19, 20
suture of, 19
Schede's method of approach for resection of thoracic esophagus, 463
operation for obliterating empyema cavities, 411
Schultz's adenotome, 209
Sclera, diseases of, 128
foreign bodies of, 129
operations on, 156
simple trephining of, in glaucoma, 162
staphyloma of, 129
trephines, 163
tumors of, 129
wounds of, 129
Scleritis, 128
Sclerokerato-iritis, 128
Sclerotomy, anterior, 156
Sclerotomy combined with iridectomy, 157
for glaucoma, 161
internal, 157
posterior, 157
with trephine in glaucoma, 162
Scoliosis, 352
causes, 352
corset for, 353
decompression corset in, 354
exercises in, 353
functional, 353
hammock for lateral correction in, 354
inclined plane seat in, 353
organic, 354
postural, 353
posture in, 352
prophylactic treatment, 352
self-suspension in, 353
structural, 354
Scopolamin hydrobromid as mydriatic, 118
Sebaceous cysts of face, 115
of scalp, 24
Seborrhea of eyelids, 119
Secondary cataract, operations for, 174
Section, abdominal, 504. See also *Abdominal section.*
Self-suspension in scoliosis, 353
Senn's method of gastrostomy through internal cone, 731
Sensory area of brain cortex, 45
Septic infection of receptaculum chyli, 361
peritonitis, acute, 548
Septum, nasal, 179. See *Nasal septum.*
Seromuscular intestinal suture, 629
Serous effusion in pericardium, 422
Serum treatment of hyperthyroidism, 390
Seventh nerve, injuries of, 63
intracranial operations on, 110
operation on, in acoustic vertigo, 112
in tinnitus, 112
two-stage, by mastoid route, 113
tumors of, removal of, 113
Shield for eye, 138, 140
Shock in abdominal operations, 532
in stomach operations, 776
Shortening of rectus muscle, 176
Shoulders, round, 351
Sigmoid, acute flexures of, chronic intestinal obstruction from, 610
anatomy, 625
angulations of, chronic intestinal obstruction from, 610
carcinoma of, 589
lower part, cancer of, 591
middle and upper, cancer of, 592
redundant, chronic intestinal stasis from, 612
Sigmoidostomy, anterior, 693
inguinal, 685
high, 689
low, 690
Silver, colloidal, in bronchiectasis, 419
Simple rhinitis, acute, 186
chronic, 186
Singers' nodules, 222
Sinuses, accessory, foreign bodies in, 188
of nose, 179

Sinuses, cavernous, arteriovenous aneurysm of, 73
thrombosis of, 72
cerebrospinal, 73
cranial, drainage of cisterna magna into, in hydrocephalus, 98
ethmoid, 180
suppuration of, 197
operation by orbital route in, 198
frontal, 179. See *Frontal sinus.*
infections of, intranasal treatment, 201
perforating into orbit, 201
intestinal, closure of, 616
maxillary, 179. See *Maxillary antrum.*
meningeal, injuries of, 64
of brain, 44
lateral, 47
pericranii, 24
sphenoid, 180
suppuration of, 198
superior longitudinal, of brain, 47
venous, infections of, 318
thrombosis of, 318
Sixth nerve, injuries of, 63
diseases of auricle, 304
involving conjunctiva, 124
Skull, 26
base of, anatomy, 43
bones of, atrophy, 41
diseases of, 41
effects of pressure on, 41
infective diseases of, 41
osteitis of, prevention, 41
periostitis of, 41
Pott's puffy swelling of, 41
syphilis of, 41
tuberculosis of, 41
tumors of, 42
brain and, relations, 46
cancer of, 42
deformities of, 42
landmarks of, 45
measure for determining thickness of, 32
operations on, 26
head prepared for, 33
instruments for, 26
osteoplastic craniotomy, 30
trephine for, 26, 27.
osteoma of, 42
sarcoma of, 42
steeple, 42, 178
sutures of, 45, 46
topography of, 48
Smithies' nonoperative treatment of gastric ulcer, 720
Smith's operation in cataract, 170
preliminary capsulotomy for immature cataract, 168
Soap enema, 620
Sodium hypochlorite in peritonitis, 551
Soft palate. See *Palate, soft.*
Sound, introduction of, in stenosis of esophagus, 433
lacrimal, 177
Spasm of esophagus, 442
of glottis, 221
of larynx, 221
of orbicularis muscle, 120
Spasmodic stenosis of pylorus, 720
torticollis, 376
Spastic paralysis, rhizotomy in, 346
Special sensation, brain areas of, 45
Specific nasal infections, 188
Specula, aural, 302
nasal, 181
Speech, brain center of, 44
Sphenoid sinuses, 180
suppuration of, 198
Spiller-Frazier method of dividing sensory root of Gasserian ganglion, 107
Spina bifida, 349
Spinal accessory nerve, resection of, in torticollis, 376
canal, anastomosis of anterior nerve roots in, 348
cord, concussion of, 324
contusion of, 324
extrapial hemorrhage compressing, 325
hemorrhage into, 325
tumors of, 338
medullary, extrusion treatment, 342
laminectomy in, 341
spinal decompression in, 344
ganglia, excision of, in gastric crises of tabes, 348
nerves, anastomosis of anterior roots of, in spinal canal, 348
posterior roots of, division of, 344. See also *Rhizotomy.*
operations on, 344
Spine, 322
abscess of, non-tuberculous, 327
anatomy, 322
hysterical, 355
joints of, sprains of, 324
lateral curvature of, 352. See also *Scoliosis.*
ligaments of, relaxation of, 357
neurotic, 355
osteitis of, non-tuberculous rarefying, 326
osteomyelitis of, 326
rachitic, 350
relation of nerve roots to, 323
sprains of ligaments of, 357
tuberculosis of, 327. See also *Pott's disease.*
tumors of, 338
wounds of, bullet, 325
stab, 325
Spiral osteotome, Cryer's, 28
Spleen, 784
abscess of, 784
anatomy, 784
cysts of, 785
effects of removal of, 784
hydatid cysts of, 785
hypertrophy of, 785
injuries of, 784
operations on, 787
physiology, 784
prolapse of, 784
resection of, 787
rupture of, 704
tuberculosis of, 785
tumors of, 785
twisted pedicle of, 785

Spleen, wandering, 785
wounds of, 784
Splenectomy, 787
Splenic anemia, 785
Splenopexy, 787
Splints, nasal, 180
Spondylitis deformans, 326
traumatic, 326
tuberculous, 327. See also *Pott's disease.*
typhoid, 326
Spondylolisthesis, 350
Sponging in abdominal operations, 515
Spontaneous cerebral apoplexy, 58
temporal craniotomy in, 58
thrombosis of sinuses of dura mater, 72
Sprains of ligaments of spine, 357
of spinal joints, 324
Spurious meningocele, 25
Squamous blepharitis, 119
suture, 46
Stab wounds of brain, 62
of spine, 325
of spleen, 784
Stagnation mastitis, 473
Stapes, 299
Staphyloma, 128
of sclera, 129
operations for, 152
Stasis, intestinal, acute, 614
chronic, 610
chronic constipation in, 613
colostomy for, 574
from redundant sigmoid, 612
Status lymphaticus, 395
thymicus, 394
Steeple skull, 42, 178
Stenosis, acquired, of larynx, 218
of trachea, 218
congenital, of larynx, 218
of trachea, 218
of cardiac orifice of stomach, 715
of esophagus, cicatricial, 433
congenital, 433
pyloric, 717. See also *Pyloric stenosis.*
Stephanion, 45
Sternoclavicular joint, arthritis of, 398
Sternomastoid muscle, excision of, in torticollis, 375
Sternothoracotomy, transverse, 459
Sternum, median division of, to expose mediastina, 459
Stewart's method of posterior gastroenterostomy, 768
Stitch-hole abscesses in abdominal wall, 537
Stoffel's method of partial rhizotomy, 347
Stomach, 698
adenoma of, 703
anatomy, 698
benign tumors of, 703
cancer of, 703. See also *Cancer of stomach.*
cardiac orifice, stenosis of, 715
cirrhosis of, 702
cysts of, 703
dilatation of, 713
acute, 615, 714
Stomach, dilatation of, chronic atonic, 713
gastroplication in, 714
foreign bodies in, 714
removal, 244
fundus of, 698
hemorrhage of, 727
operation for, 728
hour-glass, 706
gastroplasty for, 709
by transverse incision in, 709
inflammations of, 702
lavage, 700. See also *Gastric lavage.*
lipoma of, 763
lymphatics of, 699
myoma of, 703
nerve supply, 700
operations on, 730
operative exposure of, 700
perforation of, perigastric abscess from, 727
postoperative dilatation of, 615
pyloric end, resection of, 751
gastrojejunostomy after, 755
rupture of, 702
sarcoma of, 703
syphilis of, 702
tube, 700
introduction of, 700
tuberculosis of, 702
ulcer of, 720. See also *Ulcer of stomach.*
volvulus of, 715
wall, canalization of, gastrostomy by, 736
posterior, route of approach, 780
suppuration in, 702
washing out, 700. See also *Gastric lavage.*
wounds of, 702
Stomatitis, 246
gangrenous, 247
gonorrheal, 247
membranous, 247
mycotic, 246
parasitic, 246
Stone's dietetic treatment of ulcer of stomach, 421
Strabismus, 174
alternating, 175
complete tenotomy of internal rectus in, 175
indications for operation in, 175
open operation in, 175
special conditions in, 176
subconjunctival operation in, 175
unilateral, 175
Strangulation of omentum, 620
Strauss's method of reconstruction of pylorus by transplantation of tissue, 773
Streptococcus infection of teeth, 276
viridans theory of arthritis deformans, 613
Stricture of bronchi, 422
of esophagus, 433
dilatation of, by electrolysis, 438
rapid, 438
with mercury, 435
with sound, 433
gastrostomy in, 436
internal esophagotomy in, 438

Stricture, of esophagus, introduction of sound for, 433
operative treatment, 436
of intestines, 609
chronic obstruction from, 610
Stridulous laryngitis, 221
Structural scoliosis, 354
Struma, 381
Strumitis, acute, 380
chronic, 381
Stye, 119
Subarachnoid hemorrhage, 57
Subconjunctival injections, 151
in eye diseases, 179
operation in strabismus, 175
Subcostal oblique abdominal section, 513
Subcutaneous drainage in ascites, 559
emphysema in artificial pneumothorax, 417
tenotomy in torticollis, 374
Subdiaphragmatic abscess, treatment, 470
Subdural hemorrhage, 56
meningitis, 65
pyogenic organisms in, 66
Subglottic laryngitis, hypertrophic, 219
Subhyoid pharyngotomy, 229
Sublingual phlegmon, 362
Submaxillary glands, 363
Submental glands, 363
Submucous resection of nasal septum, 190
Suboccipital osteoplastic craniotomy, 36
Subparotid glands, 363
Subperitoneal drainage in congenital ventricular hydrocephalus, 97
Subphrenic abscess in peritonitis, 553
Subpleural diaphragmotomy for subphrenic abscess, 554, 555
Substernomastoid glands, 363
Subtemporal craniotomy, 106
for exposure of Gasserian ganglion, 106
drainage in congenital hydrocephalus, 96
Sucking thumbs, prevention, 280
Suction apparatus for removing brain tumors, 78
treatment of rhinitis, 186
of suppurative otitis media, 310
Sulphuric ether in peritonitis, 551
Summers' method of resecting transverse colon with preservation of omentum, 646
Superciliary ridge, 46
Superficial glossitis, acute, 288
chronic, 288
Superheated air inhalations in bronchiectasis, 419
Superior bronchoscopy, 242
Supernumerary auricle, 303
Suppuration in stomach wall, 702
of ethmoid sinuses, 197
operation in, by orbital route, 198
of sphenoid sinuses, 198
Suppurative choroiditis, 130
otitis media, acute, 307
chronic, 308
perforation of intestines, 581
peritonitis, diffuse, 548
local, 548
Suppurative tonsillitis, 212
Supra-auricular point, 45
Supraclavicular glands, 363
Suprahyoid pharyngotomy, 229
Supra-orbital arch, 46
Suspension hammock to apply jacket in Pott's disease, 329
Suture coronal, 45
Sutures, figure-of-eight, for closing abdominal wound, 519
in abdominal operations, 519
intestinal, 628. See also *Intestinal suture.*
lambdoid, 46
of heart, 427
of scalp wounds, 19
sagittal, 46
Swallowing tongue, 287
Sylvian fissure, 46
line, 46
point, 46
Symblepharon, 119, 120
operations for, 150
Sympathetic ophthalmia, 130
Synchysis, 134
Synechia, anterior, division of, 156
nasal, 195
Syphilis of bones of skull, 41
of brain, 75
of larynx, 223
of ribs, 398
of stomach, 702
of thyroid gland, 381
of tongue, 290
Syphilitic iritis, 129
meningitis, 68
nasopharyngitis, 205
pachymeningitis, 65
retinitis, 134
Szymanowski-Kuhnt operation for ptosis of eyelids, 145

Tabes, gastric crises of, excision of spinal ganglia in, 348
rhizotomy for, 347
Tapping arachnoid space, 348. See *Lumbar puncture.*
in ascites, 557
Tarsorrhaphy, 143
lateral, 143
Tattooing cornea, 152
Teale's operation for symblepharon, 150
Teeth, 274
alveolar abscess of, 277
caries of, 275
condition of, as factor in surgical treatment, 274
cysts of, 280
dead, filling and crowning of, 276
decay of, prevention, 274
extraction of, 278. See also *Extraction of teeth.*
grafting of, 279
prophylactic care of, 276
root infections of, 275
streptococcus infection of, 276
tumors of, 280

Temporal craniotomy, high, for exposure of Gasserian ganglion, 106
in spontaneous cerebral apoplexy, 58
low, for exposure of Gasserian ganglion, 106
osteoplastic craniotomy, 34, 36
Temporary fecal fistula, 686
intestinal fistula, 683
Tenon's capsule, advancement of, 177
Tenotomy, complete, of internal rectus in strabismus, 175
graduated, in heterophoria, 176
open, in torticollis, 375
partial, in heterophoria, 176
subcutaneous, in torticollis, 374
Teratoma of brain, 75
Tetany, 394
thymic, 395
Thirst after abdominal operations, 533
cure in bronchiectasis, 419
Thoracic duct, diseases of, 361
rupture of, in abdomen, 361
in thorax, 361
wounds of, 361
esophagus, resection of, 463
exposure of diaphragm, 467
Thoracoplasty in bronchiectasis, 420
in empyema, 410
in tuberculosis, 418
Thoracotomy, intercostal, simple, in empyema, 403
osteoplastic, anterior, 458
posterior, 459
Thorax, 396
anatomy, 396
cancer of, extensive recurrent, 494
concussion of, 397
contusions of, 396
tumors of, 444
Thorner's instruments for intubating larynx, 237
Thrombosis of cavernous sinus, 72
of venous sinuses, 318
of dura mater, 70
infective, 71
Thrush, 246
Thumb sucking, prevention of, 280
Thymectomy, 395
Thymic asthma, 394
dyspnea, 395
epilepsy, 395
tetany, 395
Thymus gland, 394
enlarged, 395
epilepsy with, 101
hypertrophy of, 446
Thyreodectin in hyperthyroidism, 390
Thyreoprivic serum in hyperthyroidism, 390
Thyroid gland, anatomy, 380
cancer of, 381
enucleation of growths in, 385
inflammations of, 380
ligation of, after-treatment, 393
hyperthyroidism, 393
lobe of, resection of part, 389
sarcoma of, 381
Thyroid gland, secretion, conditions of deficiency of, 394
syphilis of, 381
tuberculosis of, 381
glands, accessory, 380
Thyroidectomy, 382, 392
after-treatment, 393
anesthesia for, 392
Thyroiditis, acute, 380
chronic, 381
Thyrotomy, 230
Thyrotoxicosis, 389
Tinnitus, operation on seventh nerve in, 112
Tongue, 286
abscess of, tuberculous, 290
actinomycosis of, 290
bifid, 286
burns of, 288
cancer of, 292
excision for, 293. See also *Excision of tongue for carcinoma.*
operation in, 364
congenital defects, 286
cracks of, 289
cysts of, 292
dyspeptic, 289
foreign bodies in, 287
frenum of, ulcers of, 290
furrows of, 289
herpes of, 288
hypertrophy of, 290
inflammations of, 288
injuries of, 287
leprosy of, 290
leukoplakia of, 289
nodules of, tuberculous, 290
psoriasis of, 289
root, tumor of, 389
swallowing, 287
syphilis of, 290
trichinosis of, 290
tuberculosis of, 290
tumors of, 291, 292
Tongue, ulcers of, 289
aphthous, 290
dyspeptic, 289
herpetic, 290
mercurial, 290
traumatic, 290
wounds of, 287
gunshot, 288
Tongue-tie, 287
Tonsillectomy, 213
after-treatment, 214
anesthesia in, 213
hemorrhage after, 214
incomplete, 213
indications for, 213
position of patient for, 213
results, 214
Tonsillitis, acute, 212
catarrhal, 212
caseous, 212
chronic, 212
follicular, 212
membranous, 212

Tonsillitis, suppurative, 212
Tonsillotome, 213
Tonsillotomy, 213
Tonsils, adherent, 216
diseases of, 212
enucleation of, 213, 214
hypertrophy of, chronic, 212
imbedded, 216
lingual, diseases of, 290
mycosis of, 212
operations on, through neck, 367
removal of, 213
partial, 213
with guillotine, 216
tumors of, 216
palliative treatment, 216
Tooth powders, formulæ for, 275
Torek's method of exposing thoracic esophagus, 462
Torsion of omentum, 620
Torticollis, 373
acute, 373
bilateral, 375
chronic, 373
stretching and manipulation in, 373
division of posterior muscles in, 375
excision of sternomastoid muscle in, 375
fixation in, 373
habitual, 377
ocular, 377
open tenotomy in, 375
paralytic, 377
rachitic, 377
resection of posterior cervical nerves in, 376
spinal accessory nerve in, 376
rheumatic, 377
spasmodic, 376
subcutaneous tenotomy in, 374
treatment after operation, 375
Total laryngectomy, 231
Tower head, 42
Toxemia, chronic intestinal, 610
Trachea, 217
acquired stenosis of, 218
burns of, 219
congenital stenosis of, 218
contusions of, 219
examination, 217
foreign bodies in, 224
removal, 244
fractures of, 219
inflammations of, 220
injuries of, 219
malformations of, 218
operations on, 217, 226
resection of, 237
treatment, 217
tumors of, 224
wounds of, 220
Tracheoscopy, 225, 239
position of patient for, 240
Tracheotomy, 226
high, 227
indications for, 225
low, 228
operative complications, 228
Tracheotomy, postoperative care, 229
complications, 229
tubes, 227
with excision of non-toxic goiter, 389
Trachoma, 123
operations for, 150
true, 124
Transmesocolic route of approach to pancreas, 779
Transplantation of cornea, 153
of fat into orbit after enucleation, 160
of nasal cartilage, 192
of parathyroid glands, 394
Transverse laryngotomy, 230
Traumatic cataract, 133
immediate removal, 173
hysteria, 103
insanity, primary, 102
neurasthenia, 103
psychoses, 102
rupture of tympanic membrane, 306
spondylitis, 326
thrombosis of sinuses of dura mater, 72
ulcers of tongue, 290
Traumatism of peritoneum, 542
Trephine, 26, 27
sclera, 163
Trephining of sclera, simple, in glaucoma, 162
Triangle, mesenteric, 625
postmeatal, of ear, 300
Trichinosis of tongue, 290
Trigeminal nerve. See *Fifth nerve.*
Tropical dysentery, 570
Tube, Eustachian, 299. See also *Eustachian tube.*
Tubercle, retro-orbital, 46
Tuberculin in nodular lymphatic kerato-conjunctivitis, 125
Tuberculosis, artificial pneumothorax in, 416
drainage of lung cavities in, 416
interpleural pneumolysia in, 418
of bones of skull, 41
of brain, 75
of breast, 475
of cecum, 575
of choroid, 130
of intestines, 574
of larynx, 222
of pharynx, 207
of ribs, 398
of sacro-iliac joint, 355
of spine, 327. See also *Pott's disease.*
of spleen, 785
of stomach, 702
of thyroid gland, 381
of tongue, 290
pneumectomy in, 416
pneumolysis in, 418
resection of costal cartilages in, 419
of lungs in, 416
thoracoplasty in, 418
Tuberculous abscess of tongue, 290
adenitis, 368
nonsurgical treatment, 369
technic of operation for, 370

Tuberculous empyema, 413
hydrothorax, 413
lymph-glands of neck, 368
non-surgical treatment, 369
technic of operation for, 370
meningitis, 68
nodules of tongue, 290
perforation of intestines, 581
peritonitis, 554
spondylitis, 327. See also *Pott's disease.*
Tubes, tracheotomy, 221
Tumors, brain, blindness with, 178
epilepsy from, 101
intraspinal, 338
of abdominal wall, 538
of brain, 75
active treatment, 76
antisyphilitic treatment in, 76
blindness with, 178
curative treatment, 77
dangers of lumbar puncture in, 77
decompression in, 78
indications for operation, 75
localizing indications, 75
palliative operations in, 78
results of operation, 82
suction apparatus in, 78
two-stage operations in, 78
of breast, mixed, 475
of chest wall, 444
of choroid, 130
of conjunctiva, 124
of cornea, 128
of cranial bones, 42
of diaphragm, 470
of esophagus, 445
of eyelid, 120
of face, 115
of gums, 280
of intestines, 582
chronic obstruction from, 610
of iris, 129
of jaws, 286
of lacrimal gland, 136
of lips, benign, 254
of lung, 445
of male breast, 497
of maxillary antrum, 197
of mediastinum, 446
of meninges, 75
mesenteric, 563, 564
of nasal cavity, benign, 188
of nasopharynx, 208
of neck, 372
solid, 372
of nipples, 473
of nose, 188
of omentum, 620
of optic nerve, 135
of orbit, 137
removal of, 163
of palate, 255
of pancreas, 782
of pericardium, 445
of peritoneum, 557
of pituitary body, 83
of pleura, 445
Tumors of root of tongue, 389
of salivary glands, 379
of scalp, 24
of sclera, 129
of seventh nerve, removal of, 113
of spinal cord, 338
medullary, extrusion treatment, 342
laminectomy in, 341
spinal decompression in, 344
of spine, 338
of spleen, 705
of stomach, 703
of teeth, 280
of thorax, 444
of tongue, 291, 292
of tonsils, 216
palliative treatment, 216
of trachea, 224
of umbilicus, 537
of vertebræ, 338
retroperitoneal, 563
Turbinated bones, 179
hypertrophy of, 186
removal of, 186
Türck's mattress interlocking stitch for intestinal suture, 636
Turpentine enema, 620
Tympanic deafness, advanced, 319
membrane, 299
examination of, 302
incision of, in acute otitis media, 307
traumatic rupture of, 306
ulcerative rupture of, 306
wounds of, 301
Typhlitis, 576
Typhoid spine, 326
spondylitis, 326
ulcer, perforating, 580

Ulceration of esophagus, 432
Ulcerative rupture of tympanic membrane 306
of cornea, 125
Ulcer, gastrojejunal, 580
jejunal, 580
of cornea, 125
simple, 125
of duodenum, 576. See also *Duodenal ulcer.*
of esophagus, 433
of frenum of tongue, 290
of intestines, 576
of lips, 246
of soft palate, 255
of stomach, 720
actual cautery in, 724
dietetic treatment, 721
excision of, 723
gastro-enterostomy in, 722
hyperchlorhydria in, treatment, 722
indications for operation in, 722
limitations of medical treatment, 723
near pylorus, 723
non-operative treatment, 720
perforating, 726
resection of, 759

Ulcer of stomach, results of operation in, 724
of tongue, 289
aphthous, 290
dyspeptic, 289
herpetic, 290
mercurial, 290
traumatic, 290
of uvula, 255
perforating typhoid, 580
Ullmann's invagination method of intestinal anastomosis with ring or bobbin, 658
Umbilicus, cysts of, 537
diseases of, 537
fistula of, 537
infections of, 537
tumors of, 537
Unilateral strabismus, 175
Urachus, cysts of, 538
diseases of, 538
fistulas of, 538
Urine, retention of, after abdominal operations, 533
Uveitis, 130
Uvula, bifid, 255
diseases of, 255
elongation of, 255
Uvulotomy, 255

Vaccines, Coccobacillus fœtidus ozœnæ, in ozena, 188
in chronic intestinal stasis, 611
suppurative otitis media, 310
Micrococcus catarrhalis, in ozena, 188
Vacuum extraction of cataract, 174
Vascular goiter, operation on, 388
keratitis, 127
Vasoconstriction, local, in nasal operations, 183
Vena cava, anastomosis of, with mesenteric vein, in ascites, 563
with portal vein, in ascites, 561
Venesection in compression of brain, 54
Venous sinuses, infections of, 318
thrombosis of, 318
Ventricle, lateral, of brain, 48
right, paracentesis of, 425
Verhoeff's method of tattooing cornea, 152
Vernal conjunctivitis, 123
Vertebræ, operations on bodies of, in Pott's disease, 337
tumors of, 338
Vertical postmuscular abdominal section, 512
Vertigo, acoustic, operation on seventh nerve in, 112
Visceral injuries, 535
Visual sensory center of brain, 45
Vitreous, diseases of, 134
fluidity of, 134
foreign bodies in, 134
hemorrhage into, 134
opacities in, 134
pus in, 134
Vogel's method of preventing adhesions in abdominal operations, 522
Voice, training of, after cleft-palate operation, 266
Volvulus, 608
of stomach, 715
Vomiting after abdominal operations, 531
postoperative, 615
von Hacker's method in stricture of esophagus, 436
von Leube's treatment of ulcer of stomach, 721

Walker's circular occlusion method of intestinal anastomosis, 660
Wandering spleen, 786
Wedge-isolation operation of Herbert in glaucoma, 161
Wen of scalp, 24
Witzel's method of gastrostomy by canalization of stomach wall, 736
Woody phlegmon, 362
Wounds of abdominal wall, 535
of air-passages with cut-throat, 360
of auricle, 303
of blood-vessels, cut-throat with, 360
of brain, 61
bullet, 62
stab, 62
of breast, 472
of carotid artery, 360
of chest wall, non-penetrating, 397
penetrating, 397
of choroid, 130
of ciliary body, 130
of conjunctiva, 121, 124
of cornea, 121, 128
of diaphragm, 398, 536
of dura mater, 61
of esophagus, 360, 431
of external auditory canal, 304
of eyeball, 121
of eyelids, 121
of face, 115
of heart, 428
penetrating, 429
of intercostal artery, 398
of internal jugular vein, 360
mammary artery, 398
of intestines, non-perforating, with wounds of mesentery, 568
perforating, 567
suturing of, 635
of intracranial structures, 61
of iris, 129
of larynx, 220
of lips, 246
of lung, suturing of, 414
with penetration of chest wall, 413
with pleural infection, 414
of meninges, 61
of mesentery, 568
non-perforating wounds of intestine with, 568
of nerves of neck, 360
of nose, 183
of optic nerve, 135
of pancreas, 779
of pericardium, 422
of pia-arachnoid, 61
of pleura, 399

Wounds of scalp, accidental, 18
control of hemorrhage in, 18
infection in, 18
operative, 19, 20
suture of, 19
of sclera, 129
of spine, bullet, 325
stab, 325
of spleen, 784
of stomach, 702
of thoracic duct, 361
Wounds of tongue, 287
gunshot, 288
of trachea, 220
of tympanic membrane, 301
Writing, brain center of, 44

Xanthelasma, 120
Xerotic keratitis, 127
X-rays in hyperthyroidism, 390

Ziegler's V-shaped iridotomy, 156
Zonular cataract, 133